

INTERLEUKIN-8 EXPRESSION DIFFERENCES IN CHRONIC AND ACTIVE CHRONIC INFLAMMATION GASTRIC MUCOSA BIOPSY WITH HELICOBACTER PYLORI INFECTION

Muhammad Arif¹, Siti Nurdjanah², Neneng Ratnasari³

¹Specialty of Internal Medicine, Department of Internal Medicine, Faculty of Medicine, Universitas Gadjah Mada-Dr Sardjito General Hospital

^{2,3}Gastroenterohepatology division, Department of Internal Medicine, Faculty of Medicine, Universitas Gadjah Mada-Dr Sardjito General Hospital

ABSTRACT

Background: Infection with *Helicobacter pylori* (HP) estimated to occur in 50% of the population in the world. *Helicobacter pylori* infection causes inflammation of the gastric mucosa and gastric epithelial release of interleukin-1 β , interleukin-6, interleukin-8 and tumor necrosis factor α . Interleukin-8 plays a role in the degree of chronic inflammation of the gastric mucosa and gastric cancer risk. There has been no research on differences in the expression of interleukin-8 is based on chronic and chronic active inflammation on biopsy of the gastric mucosa with *Helicobacter pylori* infection in Hospital Dr. Sardjito.

Objective: To prove the differences in the expression of interleukin-8 of chronic inflammation and gastric mucosal biopsy active chronic infection with *Helicobacter pylori*.

Methods: This study used a cross-sectional design. Examined the expression of interleukin-8 on the rest of the biopsy sample HP (+) in August 2009 to March 2014. Classification of chronic inflammatory and chronic active obtained through histopathology report. Categorical numerical data from the two groups, unpaired, the distribution is not normal: Mann-Whitney test. Differences were considered significant if it was obtained $p < 0.05$ with a confidence interval of 95%.

Results: There were 41 samples of gastric mucosa biopsy preparations, comprising 9 samples of chronic inflammation and 32 samples of chronic inflammatory active of the gastric mucosa. The median value of the expression of IL-8 eptitel surface on chronic inflammation by 83 (40-94)% and the active chronic inflammation by 82 (19-94). Comparison test with Mann Whitney U test. From the statistical calculations p value = 0.887 with $p > 0.05$

Conclusion: There is no difference in the expression of interleukin-8 in inflammatory chronic active and chronic inflammation of the gastric mucosa with *Helicobacter pylori* infection.

Keywords: *Helicobacter pylori*, interleukin-8, chronic inflammation and chronic inflammatory active.

Abstrak

Latar belakang: Infeksi *Helicobacter pylori* (HP) diperkirakan terjadi pada 50% populasi di dunia. Infeksi *Helicobacter pylori* menyebabkan inflamasi mukosa lambung dan epitel lambung melepaskan interleukin-1 β , interleukin-6, interleukin-8, dan tumor necrosis factor α . Interleukin-8 berperan dalam derajat inflamasi kronik mukosa lambung dan risiko terjadinya kanker lambung. Belum ada penelitian tentang perbedaan ekspresi interleukin-8 berdasarkan pada inflamasi kronik dan kronik aktif pada biopsi mukosa lambung dengan infeksi *Helicobacter pylori* di RSUP Dr. Sardjito

Tujuan Penelitian: Untuk membuktikan adanya perbedaan ekspresi interleukin-8 pada inflamasi kronik dan kronik aktif biopsi mukosa lambung dengan infeksi *Helicobacter pylori*.

Metode: Penelitian ini menggunakan desain potong lintang. Dilakukan pemeriksaan ekspresi interleukin-8 pada sisa sampel biopsi HP (+) bulan Agustus 2009 sampai Maret 2014. Klasifikasi inflamasi kronik dan kronik aktif diperoleh melalui laporan histopatologi. Data numerik-kategorik dari 2 kelompok, tidak berpasangan, distribusi tidak normal: uji Mann-Whitney U. Perbedaan dianggap bermakna jika didapatkan $p < 0,05$ dengan interval kepercayaan 95%

Hasil: Didapatkan 41 sampel preparat biopsi mukosa lambung, terdiri 9 sampel inflamasi kronik dan 32 sampel inflamasi kronik aktif mukosa lambung. Nilai median ekspresi IL-8 epitel permukaan pada inflamasi kronik sebesar 83 (40-94)% dan pada inflamasi kronik aktif sebesar 82 (19-94). Dilakukan uji komparasi dengan uji Mann Whitney U. Dari perhitungan statistik didapatkan nilai $p=0,887$ dengan $p > 0,05$.

Simpulan: Tidak terdapat perbedaan ekspresi interleukin-8 pada inflamasi kronik dan inflamasi kronik aktif mukosa lambung dengan infeksi *Helicobacter pylori*.

Kata Kunci: *Helicobacter pylori*, interleukin-8, inflamasi kronik dan inflamasi kronik aktif.

Background

Infection with *Helicobacter pylori* (*H. pylori*) estimated to occur in 50% of the population in the world. *H. pylori* infection is more common in developing countries amounting to 70-90% and only 40-50% in industrialized countries (Kuster, 2006). Research in Yogyakarta, the prevalence of *H. pylori* infection in patients with chronic dyspepsia who underwent endoscopy at Hospital Dr. Sardjito is 15.6%¹.

Helicobacter pylori infection causes inflammation of the gastric mucosa. *Helicobacter pylori* cause a persistent infection in most infected individuals. Acute inflammation is characterized by infiltration of neutrophils into the surface epithelium and lamina propria last from 1 to 4 weeks and gradually replaced by a chronic mononuclear infiltrates in the lamina propria (chronic inflammation). Chronic Inflammation by *Helicobacter pylori* infection is the main cause of infection-related cancer, *Helicobacter pylori* so-called type I carcinogen (definite) since 1994 by WHO. The risk of gastric cancer incidence in *Helicobacter pylori* infection in developed countries by 1-

2%, and in developing countries by 60-80%^{2,3,4}.

During inflammation occurs recruitment of neutrophils followed by T and B-lymphocytes, plasma cells, and macrophages in the infected epithelial gastric mucosa. Gastric epithelial release of interleukin-1 β , interleukin-6, interleukin-8 and tumor necrosis factor α . Interleukin-8 is the most important neutrophil-activating chemokine expressed in gastric epithelial cells, as interleukin-8 is able to recruit lymphocytes and neutrophils. Furthermore, neutrophils release toxic metabolites, lysosome enzymes, reactive oxygen species (ROS) and reactive nitrogen species (RNS) thus creating the gastric mucosal epithelial damage^{5,6,7}.

Several studies have demonstrated an association of IL-8 levels of gastric mucosa, gastric mucosal inflammation degree and risk of gastric cancer. Yamaoka research indicates more severe degrees of severity in *H. pylori* positive than negative. Polimorfonuclear (PMN) and mononuclear (MN) cell infiltration are more severe in the CagA positive strains. CagA positive strongly associated with high levels of IL-8 gastric mucosa⁸. Research Bakir, 2008,

found the expression of interleukin-8 increased by severity infiltration neutrophil, lymphocytes and atropi⁹. Research Oh, 2002, the expression of interleukin-8 on duodenal gastric metaplasia associated with the degree of inflammation and *Helicobacter pylori* colony density¹⁰.

Given the role of interleukin-8 in the degree of chronic inflammation of the gastric mucosa and gastric cancer risk, researchers want to know about the differences in the expression of interleukin-8 based on chronic and chronic active inflammation in gastric mucosa biopsy on Indonesian people with *Helicobacter pylori* infection.

The purpose of this study was to prove the existence of differences in the expression of interleukin-8 in chronic inflammation and gastric mucosal biopsy active chronic infection with *Helicobacter pylori*.

Research methods

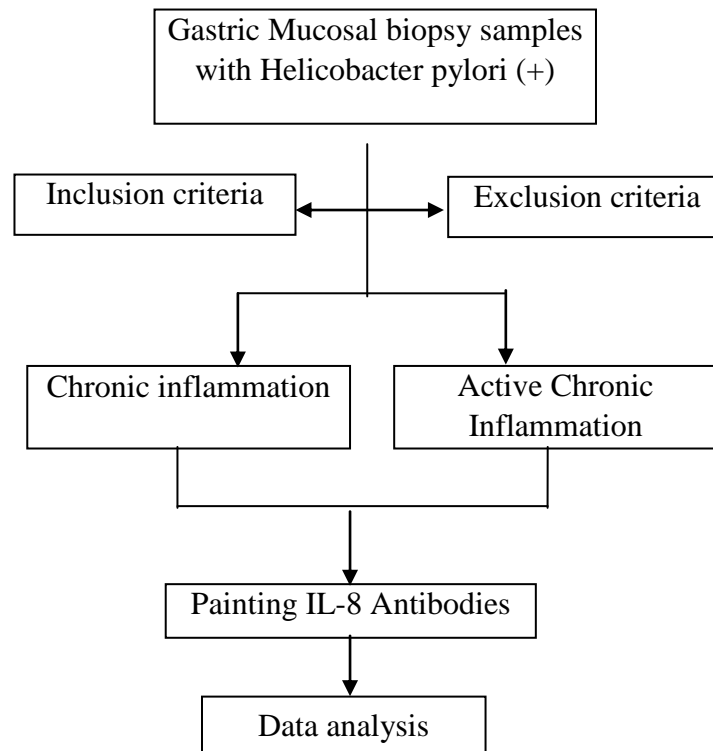
The study design was cross-sectional (cross-sectional). The study conducted in the laboratory of the department of Pathology Dr. Sardjito from January 2014 until January 2015. The study used endoscopic biopsy samples of patients with dyspepsia,

which have *Helicobacter pylori* infection in August 2009 to March 2014.

Inclusion criteria for the study: preparation endoscopy with biopsy of anatomical pathology examination obtained active chronic inflammation and chronic infection with *Helicobacter pylori*, a biopsy sample taken from a minimum of 1 antrum and 1 corpus gastric mucosa, and worthy of biopsy samples for examination interleukin-8. Exclusion criteria: biopsy samples taken does not qualify the examination and the data readout no anatomic pathology biopsy. The independent variable in this study is the expression of IL-8, and the dependent variable is the histopathological inflammation of the gastric mucosa.

Endoscopic biopsy samples infected with chronic inflammatory *Helicobacter pylori* that meet the inclusion and exclusion criteria examined interleukin-8 using the monoclonal antibody technique. The readings of the expression of interleukin-8 carried by one-person pathologist were from the laboratory Anatomical Pathology Dr. Sardjito.

The following lines of inquiry



Biopsy samples obtained by endoscopic examination in building integrated central surgical department of Dr. Sardjito. Helicobacter pylori-positive status is discovered bacteria H. pylori in the gastric mucosa biopsy, chronic inflammation is found mononuclear cells (lymphocytes) and plasma in gastric mucosa biopsy, chronic active inflammation was found lymphocytes, plasma and polymorphonuclear (neutrophils) in

biopsy of the gastric mucosa, the expression of interleukin-8 is a vast proportion of the superficial epithelium that express interleukin-8 per total superficial epithelial.

Sample readings performed 3 times by an observer (intra-observer agreement) then performed the reliability test using Cronbach Alpha. In this study showed Cronbach Alpha = 0.962 which means that the readings

are consistent and proper to be used for research.

Results and Discussion

Table 1. Characteristics of Basic Research Subjects

Variable	n (%)	Mean \pm SD
Age (years)		50,58 \pm 14,42
Gender		
Man	26 (63,4)	
Woman	15 (36,6)	
histopathologic features		
Chronic inflammation	9 (22,0)	
Active chronic Inlamation	32 (78,0)	
Histopathology features of active chronic inflammation mild (PMN +)	26 (63,4)	
Moderate (PMN ++)	6 (36,6)	
chronic inflammation		
Man	7(77.8)	
Woman	2(22,2)	
Active chronic inflammation		
Man	19(59,4)	
Woman	13(40,6)	

Subjects in this study were 41 biopsy samples from patients undergoing gastroduodenal endoscopy with chronic dyspepsia diagnosis of *Helicobacter infection pylori* from August 2009 - March 2014. The basic characteristics of research subjects is shown in Table 1. The mean age in this study was 50.58 \pm 14 , 42 years with the oldest 82 years of age and the youngest 26 years old. Samples from patients with male sex as much as 26 samples (63.4%) and female gender 15 samples (36.6%). Histopathologic

features of gastric biopsy with chronic inflammation as much as 9 samples (22%) were found in men as much as 7 samples (77.8%) and women 2 samples (22.2%), and active chronic inflammation as much as 32 samples (78%) were obtained in men as much as 19 samples (59.4%) and 13 women (40.6%).

Expression of interleukin-8 in the gastric mucosa of chronic inflammation in this study, the median of 0.83 (0.40 to 0.94)% and active chronic inflammation median of 0.82

(0.19 to 0.94)% (Table 2). Do Mann-Whitney U test and the results obtained $p = 0.887$ ($p > 0.05$). The results obtained showed no significant difference between the expression of

interleukin-8 group of chronic inflammatory and chronic active inflammation of the gastric mucosa with *Helicobacter pylori* infection.

Table 2. Expression of Interleukin-8 Based on histopathological Gastric Mucosal Inflammation (n = 41)

Category	n	Expression of IL-8 (%) Median (min-max)	(p-value)
chronic inflammation	9	0,83 (0,40-0,94)	0,887*
Active chronic inflammation	32	0,82 (0,19-0,94)	

*Mann-Whitney U test

The study also compared the expression of interleukin-8 in active chronic inflammation of the gastric mucosa by the degree of infiltration of PMN cells (Table 3). Interleukin-8 expression in gastric mucosa without infiltration of PMN obtained a median of 0.83 (0.40 to 0.94) %, with mild infiltration (PMN +) obtained a median 82 (19-94) % and the infiltration medium (PMN ++) obtained a mean $62 \pm 2.7\%$. Kruskal-Wallis test showed no significant difference between the expression of interleukin-8 group without PMN

infiltration, infiltration and infiltration were mild gastric mucosa with *Helicobacter pylori* infection ($p = 0.345$). Results in this study that there was no difference in the expression of interleukin-8 in inflammatory chronic active and chronic inflammation, and there is no significant difference in the expression of interleukin-8 on gastric mucosal inflammation without PMN infiltration, chronic inflammation of mild and moderate active gastric mucosa with *Helicobacter pylori* infection.

Table 3. Expression of Interleukin-8 Based on the degree of infiltration of PMN

PMN infiltration degrees	N	Expression of IL-8 (%) [median (min-max) / mean (SD)]	(p-value)
Without PMN	9	0,83 (0,40-0,94)	0,345*
Mild (PMN +)	26	0,82 (0,19-0,94)	
Moderate (PMN ++)	6	0,62 ± 2,7	

*Kruskal-Wallis test

These results differ from previous research studies that states there is a relationship between the expression of interleukin 8 with the degree of inflammation of the gastric mucosa^{8,9,10,11}. Some things that affect differences in the expression of interleukin-8 results in this study with the results of previous research cannot be conducted due to the exclusion of confounding factors such as: Host with IL-8-251 genotype A / A and IL-8-251 A / T express interleukin-8 is higher than the genotype IL-8-251 T / T, virulence factors of *Helicobacter pylori* positive Vaca express

interleukin-8 on the corpus higher than Vaca negative and positive *Helicobacter pylori* CagA expressing interleukin-8 in the antrum five times higher than CagA negative, *Helicobacter pylori* colony density is closely linked with the expression of interleukin-8, smoking increases the expression of interleukin-8, the use of drugs known as proton pump inhibitors (PPI), the use of non-steroidal anti-inflammatory drugs (NSAIDs), alcohol consumption, extra gastroduodenal diseases affecting the expression of IL-8^{8,12,13,14,15}.

Tabel 4. Expression of Interleukin-8 Based Sex

Category	N	Expression of IL-8 (%) [median (min-max) / mean (SD)]	(p-value)
Man	26	0.83 (0.19-0.94)	0.139*
Woman	14	0.67±0.24	

* Mann-Whitney U test

Interleukin-8 expression by the epithelial cells of the gastric mucosa in men in this study, the median of 0.83 (from 0.19 to 0.94)% and in women mean of 0.67 ± 0.24 (Table 4). To know is there any difference between the expression of interleukin-8 group of men and women then tested the Mann-Whitney U (distibusi abnormal data) and the results obtained $p = 0.139$ ($p > 0.05$). The results obtained showed no significant difference interleukin-8 expression of the gastric mucosa with *Helicobacter pylori* infection between men and women.

These results are in contrast to studies conducted by Moshkowitz et al (2012) also demonstrated the expression of interleukin 8 in men is greater in women¹⁶. Kato 2004 study, the expression of interleukin-8 in men with chronic gastritis greater than premenopausal women. While the expression of interleukin-8 between men and postmenopausal women not different¹⁷. This is presumably due to

hormonal differences between men and women. Women have the hormones estrogen and progesterone are able to maintain the stability of the gastric mucosa, so chronicity occurs less frequently in women. In this study does not distinguish whether the sample derived from postmenopausal women or not, so that the different results of this study with other studies could not be known whether due to hormonal differences. Differences may also occur because not done confounding factors such as genotype host, the virulence of *Helicobacter pylori*, *Helicobacter pylori* colony density, smoking, drinking alcoholic beverages, use of PPI medications, OAINs and comorbid disease patients

Conclusions and Suggestions

There were no differences in the expression of interleukin-8 in inflammatory chronic active and chronic inflammation of the gastric mucosa biopsy with *Helicobacter*

pylori infection. For further research is necessary to control for confounding factors such as genotype host, the virulence of *Helicobacter pylori*, *Helicobacter pylori* colony density, smoking habits and use of PPI medications and NSAIDs and comorbid disease patients.

Literature

1. Arrosy, Ratnasari, N., Indrarti, F., 2012, Prevalence Of *Helicobacter pylori* Infection Based On Histopathology Of Gaster And Duodenum In Dr. Sardjito Hospital, Yogyakarta September 2009-September 2010.
2. Versalovic J., 2003, *Helicobacter pylori* Pathology and Diagnostic Strategies. *Am J Clin Pathol*, 119:403-12.
3. Kozlowski W., Jochymski C. & Markiewicz T., 2006. Chronic Gastritis: Gastritis and Gastric Cancer – New Insights in Gastroprotection, Diagnosis and Treatments, 5:75-92.
4. Wroblewski, L., Peek, R., Wilson, K.T., 2010, *Helicobacter Pylori* And Gastric Cancer: Factors That Modulate Disease Risk, *Clinical Microbiology Reviews*, 23 (4) 713–739.
5. Gionchetti, P., Vaira, D., Campieri, M., Holton, J., 1994, Enhanced Mucosal Interleukin-6 And -8 In *Helicobacter Pylori* Positive Dyspeptic Patients., *Am J Gastroenterol*, 89(6):883-887.
6. Suerbaum, S., Michetti, P., 2002, *Helicobacter Pylori* Infection, *N Engl J Med*, 347 (15) : 1175-1186
7. Hannelien, V., Karel, G., Sofie, S., 2012, The Role Of Cxc Chemokines In The Transition Of Chronic Inflammation To Esophageal And Gastric Cancer, *Biochimica Et Biophysica Acta* 1825, 117–129
8. Yamaoka, Y., Kodama, T., Kita, M., Imanishi, J., Kashima, K., 1999, Relation Between Clinical Presentation, *Helicobacter Pylori* Density, Interleukin 1 β And 8 Production, And CagA Status, *Gut*; 45 : 804–811
9. Bakir, W.A., Hussain, A., Faisal, M., 2008, Gastric Mucosal Interleukine-8 (IL-8) And Interleukine-1beta (IL-1 β) Levels In Atrophic Gastritis And Gastric Carcinoma Patients., *J Fac Med Baghdad*. 50 (4)
10. Oh, Y.S., Hong, S.J., Kim, J.O., Cho, J.Y., Lee, J.S., 2002, Effect of *Helicobacter pylori* Infection on Mucosal Interleukin-8 Expression in Gastric Metaplasia, *Korean J Gastroenterol*, 39(3):161-166.
11. Mariadi, I.K., Kurniari, P.K., Wibawa, I.D.N., Purwadi, 2011, Interleukin 8 Berhubungan dengan Derajat Gastritis pada Pasien Terinfeksi *Helicobacter Pylori*, *J Peny Dalam*, Volume 12 Nomor 2, 98-102
12. Taguchi, A., Ohmiya, N., Shirai, K., Mabuchi, N., Itoh, A., Hirooka, Y., 2005, Interleukin-8 Promoter Polymorphism

- Increases the Risk of Atrophic Gastritis and Gastric Cancer in Japan, *Cancer Epidemiol Biomarkers Prev*; 14(11) : 2487-93.
13. Patel, S.R., 2011, *Determinants Of Helico Bader Pylori Density In The Human Stomach And Implications In Diseas, University Of Nottingham*
 14. Shimoyama, T., Everett, S.M., Fukuda, S., Dixon, M.F., Crabtree. J.E., 2001, Influence Of Smoking And Alcohol On Gastric Chemokine Mrna Expression In Patients With Helicobacter Pylori Infection, *J Clin Pathol* ; 54:p332–334
 15. Graham, Opekun, A.R., Yamaoka, Y., Osato, M.S., El-Zimaity, H.M. 2003, Early Events in Proton Pump Inhibitor-Associated Exacerbation of Corpus Gastritis, *Aliment Pharmacol Ther*, 17: 193–200
 16. Moshkowitz,M., Horowitz,N., Beit-Or,A., Halpern,Z, Santo,E 2012. Gender Associated differences in urea breath test for Helicobacter Pylori Infection referrals and results among dyspeptic patients, *World J Gastrointestinal Pathophysiology*, vol3, p80-4
 17. Kato S, et all. 2004. Sex differences in mucosal response to Helicobacter pylori infection in the stomach and variations in interleukin-8, COX-2 and trefoil factor family 1 gene expression. *Aliment Pharmacol Ther* 2004; 20 (Suppl. 1): 17–24.