



5 (2), 2019, 117-123

Received 2019-19-08; Revised 2019-10-09; Accepted 2019-28-10

Available online at : <http://ejurnal-analiskesehatan.web.id>

## Analysis of Obesity And Axillary Lymph Nodes on Mammography

\*Aysegul Akdogan Gemici, Ersoy Bayram, Nigar Gultekin, Ercan Inci

Health Science University, Bakirkoy Dr.Sadi Konuk Training and Research Hospital,  
Department of Radiology,Istanbul, Turkey.

\*E-mail: [aysegulakdogan@yahoo.com](mailto:aysegulakdogan@yahoo.com)

DOI: 10.31964/mltj.v0i0.235

**Abstract:** Fat-infiltrated lymph nodes mostly seen on mammograms (MG) of the elderly and obese women. We analyzed the fat infiltration of lymph nodes for its potential use in estimating body mass index (BMI). 2D digital MG of 157 women assessed by one breast radiologist and one radiology resident. For each patient, the largest lymph node chosen as the index by analyzing the medial, lateral oblique (MLO) views. The width and length of the node and the hilum, the cortex, and the Hilo-cortical ratio (HCR) were measured. Breast density was categorized according to the ACR BI-RADS 4th edition and divided into two groups as dense and non-dense. Obesity was defined as BMI  $\geq 30$  kg/m<sup>2</sup>, overweight as BMI  $<30$  and  $\geq 25$  kg/m<sup>2</sup>, normal weight as BMI  $<25$  kg/m<sup>2</sup>. The association of lymph node dimensions and hilum dimensions, breast density, and age with BMI were analyzed. P  $<0.05$  were considered as statistically significant. Good inter-observer agreements were found for most measurements, although the agreement of cortex width was low. The lymph node dimensions, hilum dimensions, HCR increased significantly with increasing BMI for the measurements of reader 1 ( $p < 0.001$  for all). In reader 2, only widths of lymph node and hilum related ( $p < 0.05$ ). Cortex width was not associated with BMI. There was a statistically significant relationship between BMI and mammographic density. Obese women had more non-dense breasts ( $p < 0.001$ ). Conclusion axillary lymph node fatty content was found related to BMI and could use as an indicator of obesity.

**Keywords:** obesity; body mass index; axillary lymph node dimension; mammography; breast density

### INTRODUCTION

Obesity is a serious, multi-factorial, chronic illness that affects patients of all ages that continues to increase in prevalence (Ludwig J,1980). The obesity epidemic has presented new challenges and prompted investigators to perform research on the obesity-related disease. It is a risk factor that increases the incidence and mortality of many cancers (Gallagher EJ, 2015). Endometrial, renal, colorectal, and breast carcinomas have related to obesity (Rota M, 2015; Zhang X, 2015; Chan DS, 2014).

The most accepted measure for obesity is body mass index (BMI), which was used 150 years ago by Quetelet. It calculated by dividing the body weight by the square of the height (kg/m<sup>2</sup>). Anthropometric measurements have also use for abdominal obesity, which is related to metabolic syndrome (Alberti KG, 2006). In this era, different imaging methods have been used, especially for estimating visceral fat and liver steatosis. Of the imaging options, magnetic resonance imaging (MRI) is considered the safest and most sensitive technique. Dual-energy X-ray absorptiometry (DEXA) and computed tomography (CT) can also use for the

**Corresponding Author:** Aysegul Akdogan Gemici

Health Science University, Bakirkoy, Dr.SadiKonuk ©TrainingandResearchHospital,  
Department of Radiology, Istanbul,Turkey.

E-mail: [aysegulakdogan@yahoo.com](mailto:aysegulakdogan@yahoo.com)

quantification of the visceral fat, and different image techniques and sequences use. Mammography does not count among these imaging methods, but it has some features that give an idea about a woman's BMI (Hudson S, 2018; Florio Alexander RM, 2018). Firstly, breast density, which is the amount of radio-dense tissue in the breast, has been shown as a well-established risk factor along with age and BMI (Hudson S, 2018; McCormack VA, 2006). BMI positively correlated with fatty breasts, independent of age (Hudson S, 2018; Hart V, 2015). Also, the axillary lymph nodes seen in screening mammograms have been investigated as a biomarker for obesity recently (Florio Alexander RM, 2018). They see in very different sizes and structures in mammograms. The cortex and fatty hilum are the main parts of them. The fatty hilum size, in particular, increases when fat infiltration occurs with aging and weight gain (Florio Alexander RM, 2018). Lipomatous atrophy happens with aging. Also, with weight gain, ectopic fat accumulation, which sees in different organs and systems, causes many pathologies related to obesity. These are structural, metabolic, and inflammatory changes that mainly cause organ dysfunction. Considering these adverse effects, obesity-related lymphatic disorders might be related to fat-infiltrated lymph nodes.

Screening mammograms have been used widely in breast cancer screening, and these can accept as the most accessible modality for evaluating lymph nodes without adding any costs. Fat-infiltrated lymph nodes mostly seen on mammograms of the elderly and obese women; however, in the literature, only one study was found that investigated the fatty changes of lymph nodes related to obesity (Florio Alexander RM, 2018). We aimed to analyze the fat infiltration of lymph nodes for its potential use in estimating BMI.

## **MATERIALS AND METHOD**

An institutional review board approved this retrospective study. Patients randomly selected from the list of mammography work stations from January through February 2019. Two-dimensional full-field digital mammograms were obtained using Selenia Hologic units (Hologic Incorporated, Bedford, Massachusetts, USA). Images reviewed on Barco 3-megapixel MDCG-3221 monitors (Kortrijk, Belgium). One breast radiologist with eight years' experience and one radiology resident made the measurements of the lymph nodes.

For each patient, the medial-lateral oblique (MLO) views reviewed for visible axillary lymph nodes. The single largest lymph node within either axilla was chosen as the index node and was included for analysis if at least 80% of the node was visible. Two observers measured the width and length of the node and hilum. Also, the lymph node cortex measured as the radio-dense outer part of the node, and the lymph node hilum measured as the central radiolucent area (Figure 1).

The Hilo-cortical ratio (HCR) defined as the width of the fatty hilum divided by the width of the dense cortex. We evaluated the association of lymph node dimensions and hilum dimensions, breast density, and age with BMI. Obesity defined as BMI  $\geq 30$  kg/m<sup>2</sup>, overweight as BMI  $<30$  and  $\geq 25$  kg/m<sup>2</sup>, and normal weight as BMI  $<25$  kg/m<sup>2</sup>.

Breast density scored as 1, 2, 3, and 4 according to the percentage of fibroglandular tissue ( $< 25\%$ ,  $25-50\%$ ,  $50-75\%$ , and  $>75\%$ , respectively) in accordance with the 4th version of the American College of Radiology Breast Imaging Reporting and Data System (ACR BI-RADS) lexicon (American College of Radiology, 2003). The women then assigned to two different groups. Group 1

consisted of women with grade 1 or 2 breast density, and group 2 comprised women with grade 3 or 4 breast density.

All statistical analyses were conducted using SPSS Ver. 20.0 (SPSS, Chicago, IL) and MedCalc (Mariakerke, Belgium) software. We did a descriptive analysis of all variables. We used one-way analysis of variance (ANOVA) tests to compare BMI with the measurements of the lymph nodes. Multivariable linear regression models were used to assess the independent associations of lymph node dimensions (length and width) with BMI, adjusting for age and breast density. Inter-rater reliability between the two readers was assessed using the Pearson correlation coefficient using a standard interpretation of the strength of association. The measurements reported in the manuscript are the measurements of reader 1 (AAG). P-values <0.05 were considered statistically significant.

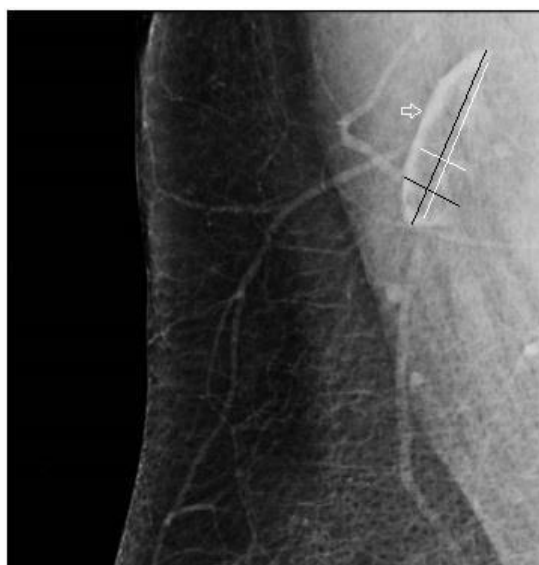


Figure 1- Screening mammogram of a 55 year old female with BMI of 32: Right medial lateral oblique (MLO) view demonstrates and fat infiltrated axillary lymph nodes. Measurement axes are seen as follows: total node length (long black line), hilum length (long white line), total node width (short black line), hilum width (short white line), and cortical width (white arrow).

## RESULTS AND DISCUSSION

Axillary lymph nodes detected in 81.5% of the patients (128/157). They were commonly visible in women with higher BMI and low mammographic density. The overall lymph node dimensions, hilum dimensions, and HCR increased significantly with increasing BMI from normal to obese for the measurements of reader 1 ( $p < 0.001$  for all). In reader 2, EB, only widths of lymph node and hilum related with BMI ( $p < 0.05$ ). (Reader AAG measurements shown in Table 1). However, cortex width was not associated with BMI in both the reader's evaluation ( $p = 0.52$  for EB,  $p = 0.26$  for AAG).

Table 1: Comparisons According to BMI Classification

		BMI	n	mean±SD	Min-Max (Median)	ap
Reader 1	Lymph node length	Normal	29	18,57±8,00	9-41 (15,5)	0,001**
		Overweight	47	20,59±7,38	8-43 (20)	
		Obese	52	24,98±7,89	11-47 (24)	
	Lymph node width	Normal	29	10,23±2,76	6-16 (10)	0,001**
		Overweight	47	12,15±4,63	5-31 (12)	
		Obese	52	14,02±3,88	8-25 (12,5)	
	Hilus length	Normal	29	11,53±7,03	5-31 (9,5)	0,001**
		Overweight	47	13,13±6,99	4-36 (12)	
		Obese	52	17,37±7,75	5-39 (16)	
	Hilus width	Normal	29	6,17±2,56	3-12 (5)	0,001**
		Overweight	47	7,63±4,78	2-29 (6)	
		Obese	52	9,59±3,95	4-20 (9)	
	Cortical thickness	Normal	29	4,43±1,3	2-7 (4)	0,260
		Overweight	47	4,87±1,36	2-10 (5)	
		Obese	52	4,93±1,41	2-8 (5)	
Hilocortika I ratio	Normal	29	1,48±0,7	0,71-3,67 (1,25)	0,021*	
	Overweight	47	1,74±1,51	0,67-9 (1,2)		
	Obese	52	2,23±1,4	0,57-7 (2)		
Reader 2	Lymph node length	Normal	29	23,75±7,57	12,8-40,2 (24)	0,374
		Overweight	47	23,27±8,62	8,2-54,80 (22,3)	
		Obese	52	25,62±9,21	2,5-46,6 (24,45)	
	Lymph node width	Normal	29	11,84±3,35	1,9-18,6 (12,1)	0,014*
		Overweight	47	13,00±4,44	6,3-27,70 (11,9)	
		Obese	52	14,93±5,01	7,5-28,3 (13,6)	
	Hilus length	Normal	29	16,27±7,33	5,4-34,8 (14,6)	0,404
		Overweight	47	15,51±7,24	4,5-42,7 (15)	
		Obese	52	17,58±8,29	5,5-37,4 (16,05)	
	Hilus width	Normal	29	7,96±3,07	3,6-16,5 (7,4)	0,044*
		Overweight	47	8,59±4,1	1,9-22,5 (8,7)	
		Obese	52	10,22±4,88	3,1-23,4 (10,05)	
	Cortical thickness	Normal	29	4,88±1,82	1,5-10,9 (4,6)	0,527
		Overweight	47	5,07±1,91	2,7-11 (4,4)	
		Obese	52	5,32±1,45	3-9,4 (5,25)	
Hilocortika I ratio	Normal	29	2,00±1,6	0,61-8,2 (1,48)	0,656	
	Overweight	47	1,84±1,09	0,27-6,43 (1,67)		
	Obese	52	2,07±1,17	0,61-5,14 (1,78)		

<sup>a</sup>One-Way Anova Testi\*\*p<0,01

\*p<0,05

Useful to existing inter-observer agreements found for most measurements, with a Pearson correlation coefficient of 0.72 for lymph node length, and 0.73 for hilum length. The moderate inter-observer agreement found with a Pearson correlation coefficient of 0.62 for lymph node width, 0.65 for hilum width. The inter-observer deal of cortex width was seen as low. In both observers, the correlations between the width of the lymph node and hilus, and length of the lymph node and hilus were found high, but there were no statistically significant relationships between cortical thickness and width of hilus or lymph node (Table 2). There was a statistically significant relationship between BMI and mammographic density. Obese women had more non-dense breasts ( $p < 0.001$ ) (Table 3).

Table 2a: The relationship between cortical thickness and width of lymph node hilus

		Cortical thickness	
		r	p
Reader 1	Lymph node width	0,086	0,329
	Hilus width	-0,082	0,354
Reader 2	Lymph node width	0,211	0,017*
	Hilus width	0,116	0,191

r=Pearson Correlation

Table 2b: The Relationship Between Lymph node Width and Hilus Width

		Lymph node width	
		r	p
Reader 1	Hilus width	0,927	0,001**
Reader 2	Hilus width	0,895	0,001**

r=Pearson Correlation      \*\* $p < 0,01$

Table 2c: The Relationship Between Lymph node Length and Hilus Length

		Lymph node lenght	
		r	p
Reader 1	Hilus lenght	0,794	0,001**
Reader 2	Hilus lenght	0,900	0,001**

r=Pearson Correlation      \*\* $p < 0,01$

Table 3: Evaluation of BMI by Density

		Density 1		Density2		<sup>a</sup> p
		n	%	n	%	
BMI	Normal	32	36,4	56	63,6	0,001**
	Overweight	54	51,9	50	48,1	
	Obese	92	75,4	30	24,6	

<sup>a</sup>Pearson Chi-Square      \*\* $p < 0,01$

Obesity affects cancer development and cancer progression (Calle EE, 2003). The role of obesity in tumorigenesis and cancer progression analyzed in three widely held hypotheses: unopposed estrogen, adipokines, and insulin play an essential role (Nieman, KM, 2013). The reasons for these are that increased breast epithelial and tumor cell proliferation stimulated by hyperinsulinemia and tumor growth fueled adipokines within the microenvironment (McGowan MM, 2013).

Breast cancer mortality is higher in obese women than in non-obese women due to being presented at an advanced stage (Stark A, 2010). Also, death attributed to co-morbidities, including stroke, metabolic syndrome, and cardiovascular disease. We also thought that the higher mortality rate in obese women might be associated with increased fat content in the lymph node. Therefore, lymph nodes can easily infiltrate by tumor cells. In Obeid et al.'s (Obeid JP, 2017) study, they concluded that peri-tumoral fat was associated with axillary lymph node metastasis and peritumoral adipokines and microenvironment affect tumor progression. It might also might that lymph nodes infiltrated with fatty hilum are more prone to be a host for tumor cells with a similar mechanism. Thus, analyzing the lymph node fatty hilum and cortex from screening mammograms gains importance. Also, by mammographic density analysis, BMI, which is the essential biomarker of obesity, can already be predicted.

In the literature, it concluded that higher BMI was associated with fatty breast density (Gillman J, 2016). In our study, there was a strong relationship between BMI and breast density in the same way as in the literature. Also, we found that the width of the lymph node and hilum related to BMI (Table 1). Two observers with different levels of experience in breast imaging were mostly in moderate agreement with the measurements of axillary lymph nodes. However, a low deal sees in the analyses of lengths. Even though both observers chose the same lymph nodes, they performed measurements without seeing all parts of the nodes. It thought that the incompatibility of the measurements was caused by estimating the missing piece of the node.

The only related study was by Florio et al., who concluded that all measurements with high intraobserver reliability were positively related to BMI (Florio Alexander RM, 2018). Our study suggests that only the width of the hilum and lymph nodes could use as an indicator of BMI. The axillary region might be examined using screening mammograms in which lymph nodes can analyze without extra cost. There are some limitations to the present study. The study population is low. The impact of the fatty changes of the nodes in malignant cell dissemination not investigated because it was beyond the scope of our study.

## CONCLUSION

Axillary lymph node fatty content found related to BMI. Especially, measurements of width appeared to have high reliability between the observers and could use as an indicator of BMI.

## REFERENCES

- Alberti KG, Zimmet P, Shaw J. (2006). Metabolic syndrome--a new world-wide definition. A Consensus Statement from the International Diabetes Federation *Diabet Med*, 23(5):469-480.
- American College of Radiology. *ACR BI-RADS Atlas—Mammography*. 4th ed. Reston, Va: American College of Radiology, 2003.

- Calle EE, Rodriguez C, Walker-Thurmond K, Thun MJ. (2003). Overweight, obesity, and mortality from cancer in a prospectively studied cohort of U.S. adults. *N Engl J Med*,24;348(17):1625-1638.
- Chan DS, Vieira AR, Aune D, Bandera EV, Greenwood DC, McTiernan A et al. (2014). Body mass index and survival in women with breast cancer-systematic literature review and meta-analysis of 82 follow-up studies. *Ann Oncol*, 25(10):1901-1914.
- Florio Alexander RM, Haider SJ, MacKenzie T, Goodrich ME, Weiss J, Onega T. (2018). Correlation between Obesity and Fat-infiltrated Axillary Lymph Nodes Visualized on Mammography. *Br J Radiol*, 91(1089):20170110.
- Gallagher EJ, LeRoith D. (2015). Obesity and diabetes: the increased risk of cancer and cancer-related mortality. *Physiol Rev*, 95(3):727–748.
- Gillman J, Chun J, Schwartz S, Schnabel F, Moy L. (2016). The relationship of obesity, mammographic breast density, and magnetic resonance imaging in patients with breast cancer. *Clin Imag*, 40(6):1167-1172.
- Hart V, Reeves KW, Sturgeon SR, Reich NG, Sievert LL, Kerlikowske K et al. (2015). The effect of change in body mass index on volumetric measures of mammographic density. *Cancer Epidemiol Biomarkers Prev*, 24(11):1724-1730.
- Hudson S, Vik Hjerkind K, Vinnicombe S. (2018). Adjusting for BMI in analyses of volumetric mammographic density and breast cancer risk. *Breast Cancer Res*.29;20(1):156.
- Ludwig J, Viggiano TR, McGill DB, Oh BJ. (1980). Nonalcoholic steatohepatitis: Mayo Clinic experiences with a hitherto unnamed disease. *Mayo Clin Proc*, 55:434-438.
- McCormack VA, dos Santos SI. (2006). Breast density and parenchymal patterns as markers of breast cancer risk: a meta-analysis. *Cancer Epidemiol Biomarkers Prev*,15:1159-1169.
- McGowan MM, Eisenberg BL, Lewis LD, Froehlich HM, Wells WA, Eastman A et al. (2013). A proof of principle clinical trial to determine whether conjugated linoleic acid modulates the lipogenic pathway in human breast cancer tissue. *Breast Cancer Res Treat*, 138(1):175-183.
- Nieman KM, Romero IL, Van Houten B, Lengyel, E. (2013). Adipose tissue and adipocytes support tumorigenesis and metastasis. *Biochim Biophys Acta*, 1831:1533–1541.
- Obeid JP, Stoyanova R, Kwon D, Patel M, Padgett K, Slingerland J et al. (2017). Multiparametric evaluation of preoperative MRI in early stage breast cancer: prognostic impact of peri-tumoral fat. *Clin Transl Oncol*, 19(2):211-218.
- Rota M, Rumi F, Bagnardi V, Maso Dal L, Zucchetto A, Levi F et al. (2015). Modelling body mass index and endometrial cancer risk in a pooled-analysis of three case–control studies. *BJOG*, 123(2):285-292.
- Stark A, Stahl MS, Kirchner HL, Krum S, Prichard J, Evans J. (2010). Body mass index at the time of diagnosis and the risk of advanced stages and poorly differentiated cancers of the breast: findings from a case-series study. *Int J Obes*, 34(9):1381-1386.
- Zhang X, Wu K, Giovannucci EL, Ma J, Colditz GA, Fuchs CS et al. (2015). Early life body fatness and risk of colorectal cancer in U.S. women and men—results from two large cohort studies. *Cancer Epidemiol Biomark Prev*, 24(4):690–697.