

Existence of the Parasympathetic Postganglionic Nerve Terminals in the Taste Disk of the Fungiform Papillae of the Bullfrog, *Rana Catesbeiana*

KATSUHIRO INOUE and YOSHINOBU OHKUBO

Laboratory of Oral Structure and Function, Institute for Dental Science, Matsumoto Dental College

JUNPEI NAITO

Laboratory of Animal Structure and Function, School of Agriculture, Nagoya University

YASUYUKI KITADA

Department of Oral Physiology, Okayama University Dental School

Summary

An investigation was made of the precise origin of the efferent nerve terminals in the fungiform papillae of the bullfrog's tongue. Some axonal enlargements originate from the parasympathetic postganglionic neurons in the glossopharyngeal nerve. Axonal enlargements containing large dense-cored vesicles (100-120 nm in diameter) and small, clear synaptic vesicles (50-60 nm in diameter) were in close contact with the supporting cell in the taste disk. These results seem to provide morphological evidence for the existence of an efferent control system in the taste disk of the bullfrog.

Introduction

Efferent control of the gustatory system has been postulated from electron-physiological evidence (Brush and Halpern, 1970¹⁾, Chernetski, 1964²⁾, Esakov, 1961⁴⁾, Hellekant, 1971⁵⁾, Kimura, 1961⁹⁾, Zaiko and Lokshima, 1962¹⁵⁾), but there is inadequate morphological evidence for such a conclusion. The glossopharyngeal nerve of the frog consists of afferent nerve fibers originate from the jugular ganglion and efferent nerve fibers originate from the superior cervical ganglion (sympathetic nerve) or the medulla (parasympathetic nerve). After cutting of the glossopharyngeal nerve trunk above the jugular ganglion, degeneration nerve fibers were not found in the fungiform papillae. On the other hand, when glossopharyngeal nerve trunk was cut under the jugular ganglion, most of the myelinated nerve fibers in the fungiform papillae were degenerating, but not unmyelinated nerve fibers (Inoue and Kitada, 1991⁷⁾). We also reported the existence of neurons within the lingual branch of the glossopharyngeal nerve and identified them to the parasympathetic postganglionic neurons (Inoue and Kitada, 1991⁷⁾). These findings show that unmyelinated nerve fibers in the

fungiform papillae are efferent and originate from the parasympathetic postganglionic neurons. Furthermore, axonal enlargements of the remaining unmyelinated nerve fibers were in close contact with the Merkel-like basal or supporting cells in the taste disk of the fungiform papillae (Inoue et al. 1992⁹⁾). We examined experimentally whether remaining axonal enlargements in the taste disk are nerve terminals and originate from parasympathetic postganglionic neurons. We found that the nerve terminals originated from parasympathetic postganglionic neurons within the lingual branch of the glossopharyngeal nerve were present in the taste disk of the frog fungiform papillae.

Materials and Methods

Fourteen bullfrogs (*Rana catesbeiana*) weighing 250–470 g were anesthetized by immersing in a solution of MS-222 (tricaine methanesulfonate, 2 g/liter). The glossopharyngeal and hypoglossal nerves were cut at the level of the angle of the mouth (Fig. 1A). After surgery, frogs were killed on day 28 or 56 (group A), or on day 28 after the surgery, the lingual branches of the left glossopharyngeal nerve were cut in the body of the tongue (Fig. 1B) and then frogs were killed 7 days after additional nerve transection (group B). For electron microscopy, frogs were anesthetized with MS-222 and perfused through the heart with 100 ml of a mixture of 1% glutaraldehyde and 4% paraformaldehyde in 0.1 M phosphate buffer, pH 7.4, for 10 minutes. After perfusion, the tongue of the left side was removed and cut into small pieces. Tissues were then immersed for 2 hours in the same fixative at 4 °C and postfixed for one hour at room temperature in 1% OsO₄ dissolved in 0.1 M phosphate buffer, pH 7.4. They were treated for conventional electron microscopy.

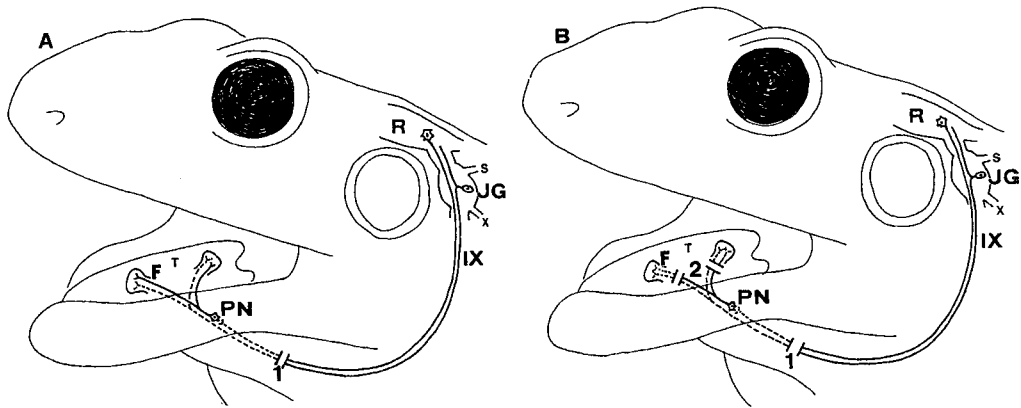


Fig. 1 : A : The glossopharyngeal nerves were cut at the level of the angle of the mouth. B : On day 28 after the surgery A, the lingual branches of the left glossopharyngeal nerve were cut in the body of the tongue. 1 and 2, positions of the cut in the glossopharyngeal nerve; IX, glossopharyngeal nerve; X, vagus nerve; F, fungiform papilla; JG, jugular ganglion; PN, postganglionic neuron; R, rhomben cephalon; S, sympathetic trunk; T, tongue.

Results

After cutting of position 1 in Fig. 1A, no signs of the degeneration were found on the axons in the taste disk of the fungiform papillae. In the taste disk, the persisted axons were transformed into irregularly shaped enlargements of varying sized and more distinct features. Some axons made close contact with the supporting cells in the taste disk. The enlargements of the axoplasm,

probably nerve endings, were filled with large dense-cored vesicles (100–120 nm in diameter) and small, clear synaptic vesicles (50–60 nm in diameter) (Figs. 2 and 3).

After cutting of position 1 and 2 in Fig. 1B, clear signs of the degeneration were observed in axonal enlargements in just under the taste disk or in taste disk of the fungiform papillae. A large dense body, the accumulation of large dense-cored vesicle, and dissolution of the microtubular structure, and disappearance of the synaptic vesicles were found in the degenerative axonal enlargements. Degenerative axonal enlargements also made close contact with the supporting cells (Figs. 4–7).

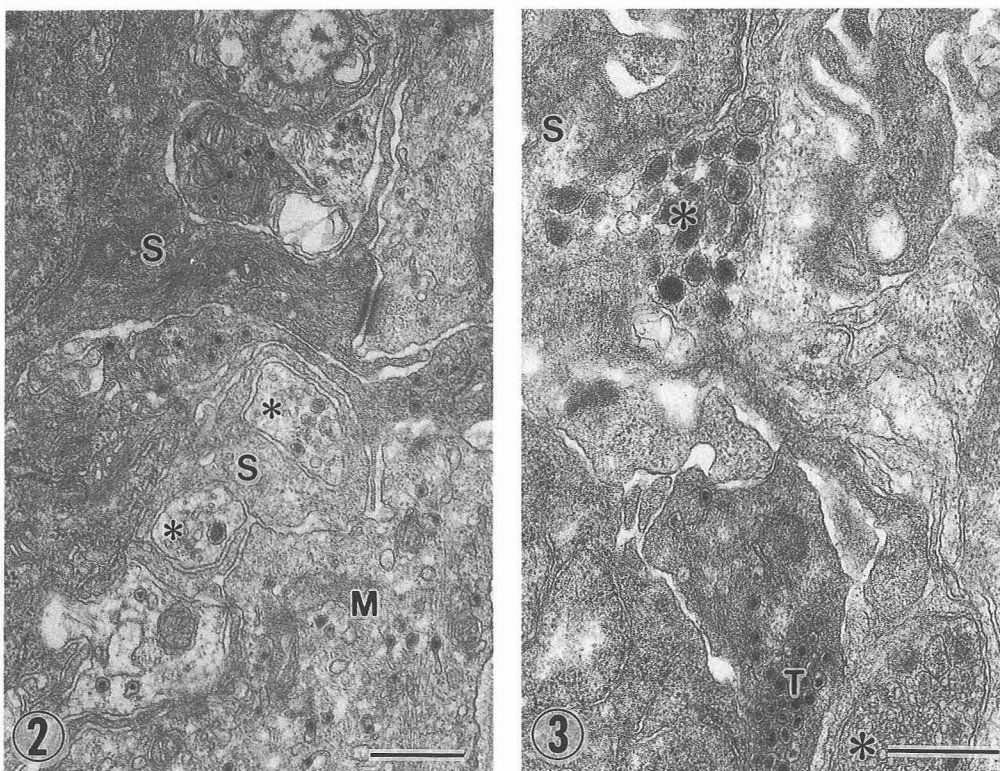
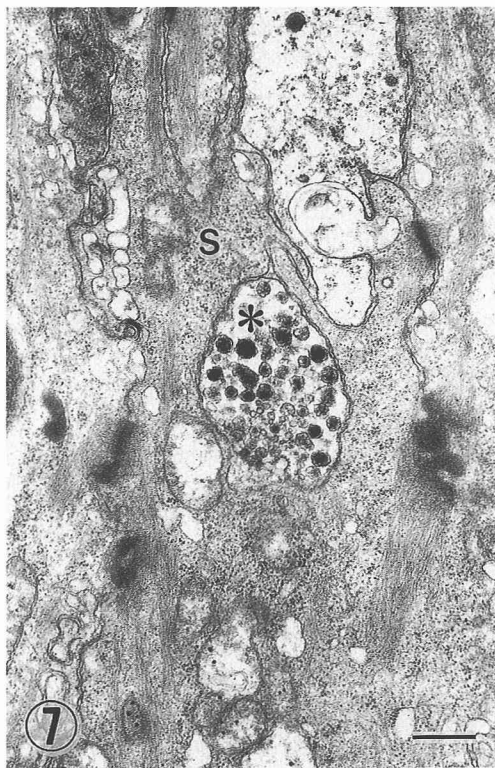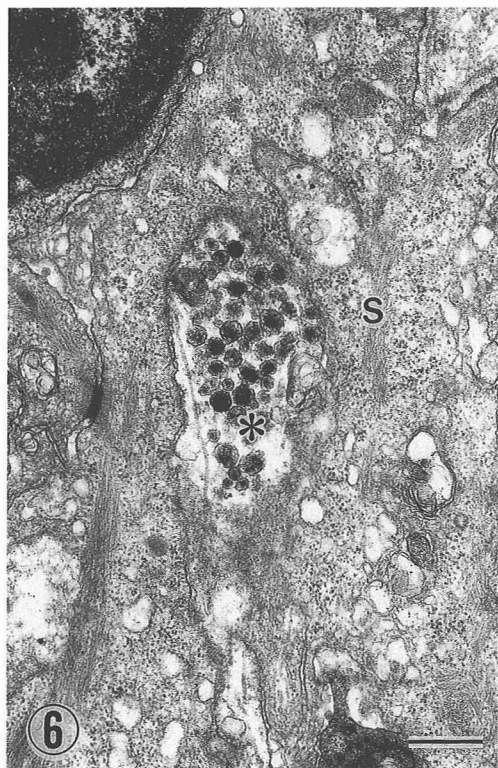
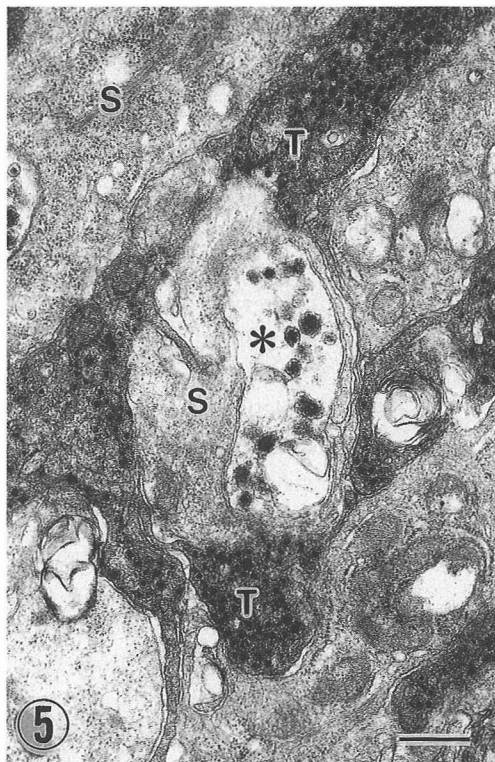
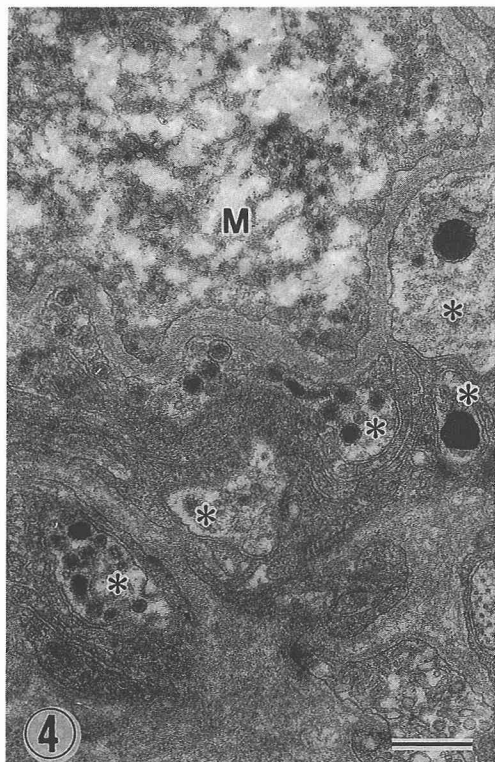


Fig. 2: Twenty-eight days after cutting position 1 (see Fig. 1A). Intact axons (*) in the taste disk of a fungiform papilla. M, Merkel-like basal cell; S, supporting cell. Bar=500 nm.

Fig. 3: Fifty-six days after cutting position 1. Axoplasmic enlargements (*) containing small, clear synaptic vesicles and large dense-cored vesicles in close contact with a supporting (S) or taste cell (T) in the taste disk of a fungiform papilla. Bar=500 nm.

Figs. 4-7: Seven days after cutting of position 2 on day 28 after section position 1 (see Fig. 1B). Fig. 4. Degenerating axons (*) just under the taste disk in a fungiform papilla. M, Merkel-like basal cell. Bar = 500 nm. Figs. 5-7. Degenerating axoplasmic enlargements (*) containing small, clear synaptic vesicles and large dense-cored vesicles in close contact with a supporting (S) in the taste disk of a fungiform papilla. T, taste cell. Bar=500 nm.



Discussion

After cutting of the glossopharyngeal and hypoglossal nerves of each side at the level of the angle of the mouth, some unmyelinated nerve fibers in the near or in the taste disk remained intact. These remaining unmyelinated nerve fibers were transformed into irregularly shaped enlargement of varying sized and more distinct features just under and within the taste disk. This is good agreement with our previous findings (Inoue *et al.*, 1992⁸⁾). It is not likely that these persistent unmyelinated nerve fibers are sympathetic, although the glossopharyngeal nerve contains sympathetic nerve fibers. Because adrenergic nerve fibers, considered sympathetic nerve in nature, disappear from the fungiform papillae within 14 days after cutting of the sympathetic trunk (Inoue and Kitada, 1988⁶⁾). These remaining unmyelinated nerve fibers were not afferent, since afferent nerve fibers originate from neurons in the jugular ganglion. They seemed to originate from parasympathetic postganglionic neurons within the glossopharyngeal nerve under the jugular ganglion (Inoue *et al.*, 1992⁸⁾). Axonal enlargements were found in the taste disk on 28 days after cutting the glossopharyngeal nerve at the level of the angle of the mouth. Therefore, the characteristics of the remaining axonal enlargements are parasympathetic. Axonal enlargements contained large dense-cored and small, cleared synaptic vesicles. Axonal enlargements containing large dense-cored and small synaptic vesicles are similar to the synaptic endings, postulated to be efferent synaptic endings from morphological criteria, in the taste organs of frogs (Nomura *et al.*, 1975¹¹⁾, Sbarbati *et al.*, 1988¹²⁾, Witt, 1993¹³⁾, mammals (Murray, 1971¹⁰⁾, Yoshie *et al.*, 1990¹⁴⁾) and fishes (Desgranges, 1966³⁾). However, their characteristics were not described. Axonal enlargements of the persistent unmyelinated fibers were filled with large dense-cored vesicle and small, clear synaptic vesicles degenerated after cutting the lingual branches of the glossopharyngeal nerve in the body of the tongue. These findings show that axonal enlargements originate from parasympathetic postganglionic neurons within the lingual branch of the glossopharyngeal nerve. We found axonal enlargements containing large sense-cored and small synaptic vesicles were in close contact with the supporting cells in the taste disk. Therefore, our results strongly suggest that they are parasympathetic nerve terminals. These results seem to provide morphological evidence for the existence of a parasympathetic efferent control system in the taste disk.

References

- 1) Brush, A. D. and Halpern, B. P. (1970) Centrifugal control of gustatory responses. *Physiol. Behav.* **5** : 743—746.
- 2) Chernetski, K. E. (1964) Sympathetic enhancement of peripheral sensory input in the frog. *J. Neurophysiol.* **27** : 493—515.
- 3) Desgranges, J. C. (1966) Sur la double innervation des cellules sensorielles des bourgeons du gout des barbillons du Poisson-chat. *C. R. Acad. Sc. Paris*, **263** : 1103—1106.
- 4) Esakov, A. I. (1961) Concerning the efferent control of receptors. *Biull. Eksp. Biol. Med. USSR*, **51** : 3—8.
- 5) Hellekant, G. (1971) The effect of stomach distension on the efferent activity in the chorda tympani nerve of the rat. *Acta Physiol. Scand.* **83** : 527—531.
- 6) Inoue, K. and Kitada, Y. (1988) On the origin and course of sympathetic nerve fibers in the fungiform papillae of the frog's tongue. *Okajima Folia Anat. Jpn.* **65** : 171—176.
- 7) Inoue, K. and Kitada, Y. (1991) Parasympathetic postganglionic cells in the glossopharyngeal nerve trunk and their relationship to unmyelinated nerve fibers in the fungiform papillae of the frog. *Anat. Rec.* **230** : 131—135.
- 8) Inoue, K., Yamaai, T. and Kitada, Y. (1992) Parasympathetic postganglionic nerve fibers in the

- fungiform papillae of the bullfrog, *Rana catesbeiana*. *Brain Res.* **596** : 299—304.
- 9) Kimura, K. (1961) Factors affecting the response of taste receptors of rat. *Kumamoto Med. J.* **14** : 95—99.
 - 10) Murray, R. G. (1971) Chapter 2. Ultrastructure of taste receptors. In L. M. Beidler (Ed.) *Handbook of Sensory Physiology Vol. IV Chemical Senses Part 2* pp. 31—50. Springer-Verlag Berlin, Heidelberg.
 - 11) Nomura, S., Muneoka, Y., and Kanno, Y. (1975) The ultrastructure of taste organs of a frog (*Rana Catesbeiana*)-three types of synapse and junctions between taste cells. *Jap. J. oral Biol.* **17** : 371—384.
 - 12) Sbarbati, A., Franceschini, F., Zancanaro, C., Cecchini, T., Claroni, S. and Osculati, F. (1988) The fine morphology of the basal cell in the frog's taste organ. *J. Submicrosc. Cytol. Pathol.* **20** : 73—79.
 - 13) Witt, M. (1993) Ultrastructure of the taste disc in the red-bellied toad *Bombina orientalis* (Discoglossidae, Salientia). *Cell Tissue Res.* **272** : 59—70.
 - 14) Yoshie, S., Wakasugi, C., Teraki, Y. and Fujita, T. (1990) Fine structure of the taste bud in guinea pigs. I. Cell characterization and innervation patterns. *Arch. Histol. Cytol.* **53** : 103—119.
 - 15) Zaiko, N. S. and Lokshina, E. S. (1962) The reflex reaction of gustatory receptors of the tongue in direct stimulation of gastric receptors (or receptors of the stomach). *Bull. eksp. Biol. Med. USSR*, **53** : 12—14.

抄録：カエル味覚器内の副交感性神経終末の存在について

井上勝博, 大久保義信 (松本歯大・総歯研)
内藤順平 (名古屋大学・農学部)
北田泰之 (岡山大学・歯学部)

ウシガエル舌の茸状乳頭内の遠心性の神経終末の起源について調べた。両側の舌咽神経、舌下神経を口角付近で切断し、カエルを2つのグループに分けた。第一のグループは切断後28日目と56日目に灌流固定した。第二のグループでは切断後28日目に、さらに残存する左舌咽神経を、舌体内で切断し、7日目に麻酔下で灌流固定した。左側の茸状乳頭を取り出し、通常のエポキシ樹脂法でエポキシ樹脂に包埋した。右側の茸状乳頭はコントロールとした。超薄切片を作成し、電子顕微鏡で観察した。第一のグループでは、茸状乳頭内の無髄線維だけが残存していた。無髄線維は taste disk 内で種々の大きさに拡張し、中には大型の有芯小胞と小型のシナプス小胞が多数認められ、神経終末と考えられた。これらの神経終末は味細胞、支持細胞、メルケル細胞と非常に密接な関係が見られ、特に支持細胞とは接触していた。第二のグループでは taste disk 内の神経終末に明瞭な変性像が見られた。これらの所見は、すでに報告されている、舌咽神経内の副交感性神経細胞の存在と合わせて考えると、taste disk 内に副交感性的神経終末の存在を示している。副交感性神経終末と味細胞、支持細胞、メルケル細胞との密接な関係は、味覚の遠心制御の形態学的根拠を示すものと思われる。