

A NEW METHOD OF CATARACT EXTRACTION  
CONSISTING IN THE RETENTION OF A CORNEO-CONJUNCTIVAL BRIDGE

-----

T H E S I S

SUBMITTED FOR THE M.D. GLASGOW

by

NEVEN GORDON CLUCKIE

M.B. Glasgow, 1880 - L.F.P.S. Glasgow, 1880

-----

Late Assistant Surgeon, Glasgow Ophthalmic Institute  
Ophthalmic Surgeon, Eye Infirmary, Greenock, and  
Royal Victoria Eye Infirmary, Paisley

-----

ProQuest Number:27626758

All rights reserved

INFORMATION TO ALL USERS

The quality of this reproduction is dependent upon the quality of the copy submitted.

In the unlikely event that the author did not send a complete manuscript and there are missing pages, these will be noted. Also, if material had to be removed, a note will indicate the deletion.



ProQuest 27626758

Published by ProQuest LLC (2019). Copyright of the Dissertation is held by the Author.

All rights reserved.

This work is protected against unauthorized copying under Title 17, United States Code  
Microform Edition © ProQuest LLC.

ProQuest LLC.  
789 East Eisenhower Parkway  
P.O. Box 1346  
Ann Arbor, MI 48106 – 1346

## HISTORICAL OUTLINE

-----

Operations for the removal of the lens have been known since the third century. At that date Antyllus and later Lathyrion attempted its removal from the eye; later in the tenth century Ali-Abas did operations by suction; after him Abulkasem continued that system which the Persians also adopted. It was not till 1707 that St. Ives by means of an incision in the cornea, withdrew the lens substance by a curette; this operation was not generally adopted. Daviel in 1745 first extracted the crystalline lens through a corneal incision. Daviel's methods were modified by La Faye, Wenzel, Richter, Barthe, and Beer; these modifications referred more to the size, situation of wound and kind of instruments. Daviel's extraction was that in which he removed the lens through the pupil and a semicircular corneal wound, at its upper or lower segment sufficient to permit of its easy exit from the eye. The complications arising from this method such as the iris falling upon the edge of the knife, led Desmarres to continue his incision and thereby removed a piece of the iris instead of withdrawing his knife and delaying the operation.

It was in 1856 when Desmarres adopted the removal of

the lens with iridectomy. Von Graefe also performed iridectomy in all such cases, but these two distinguished ophthalmologists only did this operation in complicated cases, whereas in 1860 Waldu advised that an iridectomy should be performed in all cases of extraction of the lens. Waldu's method was to remove the lens by means of a spoon through a small corneal incision, with iridectomy. Bowman, Critchett and Taylor modified this instrument but the smallness of the incision of the cornea led to bruising of the internal structures and other complications and to the final relaxation of this method.

Mooren in 1862 advised iridectomy to be done several weeks before extraction, so as to lessen the danger of suppuration of the wound. No doubt the preliminary iridectomy in certain cases has its advantages but such an operation is quite unnecessary in most uncomplicated cases. Jacobson operated in the corneo-scleral region, excising a large part of the iris, but owing to the risks of prolapse of vitreous, it was not generally adopted by the profession. For over a century, 1745 till 1860, eye surgeons were content to employ Daviel's operation and during that long period many attempts were made to improve on his method, but it was not till 1865 that Graefe revolutionised the operation for cataract by introducing a small linear incision instead of the flap operation of Daviel.

The chief points of Graefe's method are that he made his incision at the extreme periphery of the cornea, by a sawing motion he completed his section, cutting out in the cornea one millimetre from the corneo-scleral junction above, he next excised a portion of the iris, opened the capsule, and expelled the lens by pressure and counter-pressure. Should there remain lens debris he applied gentle circular pressure to the closed eyelids. If that was not successful he introduces a small spoon into the anterior chamber. Arlt and others preferred the incision to be more corneal so as to obviate the escape of vitreous.

-----  
 lens was the essential origin of vision and that in front of it was capable of being removed and could be replaced by doing so. In 1666 Kepler the lens was a refracting body and had no effect notwithstanding that important discovery Maestre and others continued to operate by depressing the vitreous, more on account of its simplicity

OPERATION BY SUCTION, DEPRESSION AND COUCHING  
-----

Suction operations which were first practised by the Persians, were tried by Langier of Paris in 1847, and by Desmarres, Teale and Bowman, but their experience was not satisfactory and they were abandoned. The pumping methods of Langier were useless, except in very liquid cataracts; the pumping was apt to withdraw vitreous as well as the softened lens. In cases of soft cataracts greater benefits can be derived by needling the lens substance, allowing it to escape into the anterior chamber, and performing linear extraction a few days later.

The opinion was held in the time of Celsus that the lens was the essential organ of vision and that the opacity in front of it was capable of being removed and vision could be restored by doing so. In 1604 Koplér proved that the lens was a refracting body and had no other use. Yet notwithstanding that important discovery Maitre-Jean, Brisseau, and others continued to operate by depressing the lens into the vitreous, more on account of its simplicity than its success in restoring vision.

Such an operation is now only known historically, and it was found in the hands of Dupuytren and others to be the

cause of irido-cyclitis, panophthalmitis, etc. as the couched lens never absorbed, but acted as a foreign body, detached the retina or was found lying against the ciliary processes and iris, and acted as a constant irritant to these delicate structures. It is sufficient to say of this operation that it is a relic of barbarism.

Smith's intracapsular method of extraction of the lens may be all he claims for it but the writer's experience leads him to doubt the successful claims advanced by its author and he rather prefers to deal with the capsule in a secondary operation than risk his patient's eye by attempting the removal of the lens in its capsule, which must be attended by escape of the vitreous in a great many cases.

The most generally adopted method of cataract extraction now in vogue is that known as the 'combined' operation which consists of a corneal section with a conjunctival flap and an iridectomy so called in contra-distinction to the simple operation in which the lens is extracted without section of the iris.

The technique of this operation is briefly as follows:- After the conjunctival sac has been thoroughly flushed by sterilised saline solution an incision is made by entering the point of the cataract knife at the visible margin of the cornea, passing it through the anterior chamber and after the exit of its point at the opposite corneal margin a

semicircular flap is cut upwards, the curved portion being constituted by the margin of the transparent cornea and small conjunctival flap.

A portion of the iris is next removed with the view of preventing prolapse and subsequent incarceration of the iris in the corneal wound. The capsule of the opaque lens is freely incised by the cystotome, after which, by gentle pressure, the lens is extracted.

In the simple operation the steps are the same but the corneal flap may be larger, no portion of the iris is removed, and the circular pupil resulting gives a better appearance.

The objection to this method of operation is the occasional occurrence of prolapse of the iris rendering a subsequent iridectomy necessary.

In the present thesis I propose to describe a new method of cataract extraction which I claim has certain advantages over existing methods.



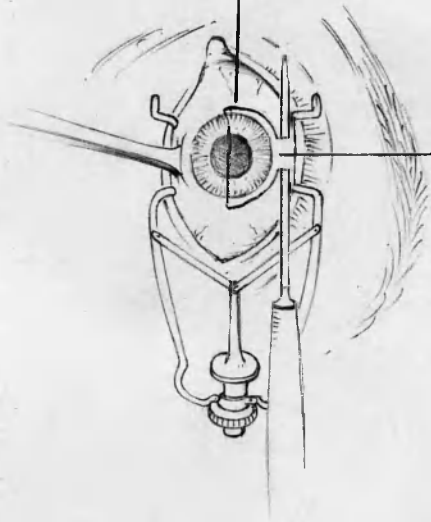
TECHNIQUE OF THE AUTHOR'S METHOD  
-----

Since the introduction over half a century ago of Von Graefe's method of extracting the lens by linear incision, ophthalmic surgeons have been content to perform their cataract operations under the conditions laid down by that distinguished surgeon, believing his operation to be the safest and most successful under all circumstances. There are few but will admit that even under the most favourable conditions, his method has certain imperfections which expose the eye to undesirable complications, the greatest of these being the sudden removal of all nourishment from fully one third of the cornea, whereby union is delayed and resistance to possible microbial infection is diminished.

Many attempts have been made to combat these defects, but Von Graefe's operation to-day occupies the position it did on its introduction into ophthalmic surgery.

Any improvement which will reduce these risks of infection and the danger of non-union of these delicate structures is of the greatest importance, it has occurred to me that such can be done, by retaining a corneo-conjunctival attachment, and this has given me highly satisfactory results. It is well known that Von Graefe's operation for cataract con-

Cornual puncture  
and Corneal  
puncture,



Corneo-  
Conjunctival  
Bridge.

sists in making a complete section of the cornea, through its upper segment. The operation I will describe is a modification of Von Graefe's.

It consists in the performance of Von Graefe's operation up to a point that leaves a connecting flap between cornea and conjunctiva, about 8 millimetres broad. Instead of completing the corneal section in the usual way the Graefe's knife is passed from cornea under the bulbar conjunctiva (avoiding implicating the sclerotic) and is carried backwards under it for 10 to 12 mm. and is then withdrawn leaving cornea and conjunctiva intact. Some difficulty may be experienced in obtaining a sufficiently long bridge, e.g., in cases of deep seated eyes, prominent orbital ridges, or narrowing of the palpebral fissure, but even a small bridge will be found sufficient to enable the delivery of the lens and to insure rapid union. (See diagram)

When the bridge has been made, the next step is to rupture the capsule in the ordinary way; then a hook or small spatula is placed under the conjunctival bridge which is put on the stretch, and by the ordinary means of pressure and counter pressure the lens is delivered, under the stretched bridge or on either side of it. The operation is always performed with the pupil fully dilated; if I cannot get the pupil dilated, an iridectomy on the nasal side is performed and thereafter the lens is delivered.

I claim that by means of this corneo-conjunctival bridge the continuity between the separated cornea and conjunctiva is maintained, and its nourishment is not interfered with as in the usual method, where complete division is carried out. Moreover, the parts are kept in more accurate position, thereby favouring rapid and certain union, and it follows that the chances of the anterior chamber being re-established in a shorter time is greater than when complete section is made. By this method, I have never had non union of the corneal wound.

The risk of the edge of the upper eyelid getting between the lips of the wound during the operation, or the conjunctival flap turning in upon itself and being caught in the wound, as sometimes happens, is under this method impossible. There is less likelihood of the iris or vitreous prolapsing or the cortical substance being caught in the wound from the fact that the "bridge" gives greater freedom for examination and restoration of the parts.

In sickness from shock, from local or general anaesthesia, the "bridge" acts as a safe barrier in preventing the usual prolapses. In the very old and infirm it is specially valuable. Corneal astigmatism is lessened and the resulting scar is practically nil, leaving the eye as normal looking as it is possible after a cataract extraction.

In conclusion, should there be found any difficulty in



## ADVANTAGES OF A CORNEO-CONJUNCTIVAL BRIDGE

-----

- 1 It ensures immediate union of the parts
- 2 The vitality of the whole corneal section is preserved.
- 3 Microbic infection is retarded if not altogether prevented.
- 4 There is less chance of prolapse of iris or vitreous.
- 5 The closure of the anterior chamber is more immediate.
- 6 There is greater security in examining and re-examining the eye after operation, or of removing lens debris.
- 7 There is no risk of upper lid getting between the corneal wound or of the conjunctival flap turning in upon itself and preventing union, as may happen in Graefe's operation.
- 8 In cases of sickness, of delirium, nervousness, or such like complications during or after operation the "bridge" has a powerful influence in protecting, maintaining, and assisting the eye to rapid recovery and restoration of vision.
- 9 Corneal astigmatism in many cases has been lessened.
- 10 In very old, frail and delicate patients, or those suffering from chest or bladder affections the "bridge" speaks for itself.

-----

C A S E S  
-----

The following are particulars of thirty cases operated on by the corneo-conjunctival bridge method.

**CASE 1 - D. M. F., 68 years**

Right eye operated upon March 21st, 1912. Pupil well dilated by atropine. Immature cataract, no iridectomy performed, some lenticular substance left in the anterior chamber. No other complications. Patient became restless and rose out of bed five hours after operation; he continued restless, temp. 102.5°. Administered 10 grains aspirin, eye examined following day, wound healed, and eye quiescent. Towards evening the patient became restless and delirious, was removed to private ward, had 31 of Bromidia three times and gradually became quieter and slept for five and a half hours. Patient became much better, and continued so till the fifth day when he again became delirious, was found trying to get out of the window, later was found on the street by a policeman and brought back to hospital and was discharged still suffering from delusions on 29th March, 1912. Through all this disturbance the eye remained quiet

and vision was for distance  $\frac{6}{18}$ , with plus 13 sph. and 3 Jager with plus 18 sph.

In this case the wound healed immediately and the "bridge" maintained wound in position. Otherwise as he was going about without surgical dressings the eye must have been lost.

**CASE 2 - Mrs D., Aged 68 years**

Left eye operated on March 18th, 1911. During the section iris fell forward on knife and small piece was removed; the lens delivered without difficulty. The eye examined on second day showed cornea hazy, <sup>except at bridge</sup> anterior chamber empty. Hot fomentations were applied several times daily and solution of atropine twice daily. Anterior chamber reformed in two days. Striate keratitis persisted for some time. Vision was  $\frac{6}{24}$ , with plus 12 sph. and plus 2 cyl. axis  $90^{\circ}$  and was able to read Jager No. 3 with plus 15 sph. and plus 2 cyl. axis  $90^{\circ}$ .

In this case if it were not for the "bridge" necrosis of cornea would have caused loss of eye.

**CASE 3 - R. D., male, Aged 36**

Was struck on right eye by piece of steel, 3rd January, 1909. Six months later he became blind from cataract and was operated on 18th November, 1911. There was haemorrhage



from iris and difficulty in delivering the lens owing to posterior synechiae; the wound had healed on examination the following day and the eye made an excellent recovery. He was dismissed on December 5th, 1911. Vision  $\frac{6}{12}$  with plus 12 sph. plus 1 cyl. axis  $180^{\circ}$  and read Jager No. 6 with plus 16 sph. and plus 1 cyl.  $180^{\circ}$ .

CASE 4 - J. P., male, Aged 65 years

Pupil dilated. Operated on November 30th, 1911. No iridectomy. There was no difficulty in delivering lens, wound healed rapidly, dismissed one week after operation.

A capsular cataract was needed 3 weeks after and at present vision  $\frac{6}{9}$  with plus 13 sph. and plus 1.5 cyl. axis  $90^{\circ}$ , with plus 15 sph. and plus 1.5 cyl. axis  $90^{\circ}$ , reads Jager 2.

CASE 5 - M.D., Male, Aged 72 years, a cooper

Extraction of right lens. The pupil partially responded to atropine. While section was being made, a small piece of iris was caught on knife but there was no other complication and no difficulty in extracting lens. Immediate union took place. Three weeks later the capsule was needed, and the patient made an excellent recovery, vision being  $\frac{6}{9}$  with plus 12 sph. and plus 16. Jager No. 2.

This patient had a troublesome cough and weak heart,

and had to sit up in bed, and on third day was allowed up. The "bridge" proved of greatest value in this case.

CASE 6 - Mrs C., Aged 54 years

Operation on left eye on 12th January, 1912. Iridectomy performed. No complications, left bed on third day. Vision  $\frac{6}{6}$  with plus 11 sph. and with plus 14 sph. reads No. 1 Jager. Discharged 22nd January. The wound healed the following afternoon.

CASE 7 - Mrs C., Aged 39 years

Had been blind in the left eye for six months and was admitted for operation on January 11th, 1912. The operation was performed the following day. No iridectomy employed. The lens was very soft and there was difficulty in delivering it. It slipped backwards into the vitreous and a scoop extraction was performed. There was slight escape of vitreous, but the complication did no harm and the wound healed in two days. There was no iritis, although the pupil was slightly oval in shape. The patient suffered no pain, slept and rested well and was able to be up third day after operation. She was dismissed after ten days' residence, and one fortnight later got glasses. But for slight deformity in shape of pupil, the eye is perfectly normal, not even mark of section showing.

With plus 10 sph. and plus 1.5 cyl. axis horizontal  
 $\frac{6}{9}$  with plus 13 sph. and plus 1.5 cyl. horizontal. Jager 1.

**CASE 8 - Mrs C., Aged 60 years**

Left eye operated upon January 19th, 1912. There was difficulty in removal of lens. Iridectomy was performed; lens slipped back into fluid vitreous, and was removed by vectis; wound healed in two days. Slight iritis with exudate in anterior chamber, which slowly disappeared under treatment and patient dismissed on February 26th. Prescription of glasses postponed until complete recovery of the eye.

**CASE 9 - Mrs McP., Aged 66 years**

Operated on 5th February, 1912. In attempting to continue section from cornea to conjunctiva the knife cut through the flap, the lens was safely delivered without iridectomy. For over a week the wound did not heal and there was slight iritis. At the end of second week could count fingers at 3 ft. distance. Dismissed February 23rd. Vision  $\frac{6}{24}$  with plus 12 sph. plus .2 cyl. axis  $90^{\circ}$ . Reads No. 6 Jager with plus 16 sph. plus 2 cyl.  $90^{\circ}$

**CASE 10: Wm. W., Aged 73 years**

Operated on left eye on 26th July, 1911, with immediate union. No complications. No iridectomy and no difficulty

in delivery lens. Eserine solution was used after operation. Dismissed on August 3rd. Vision  $\frac{6}{12}$  with plus 10 sph. and plus 1.5 cyl. 90° and plus 13 sph. plus 1.5 cyl. 90°. Reads No. 2 Jager.

**CASE 11 - Joseph McC., Aged 65 years**

Was operated on for cataract on November 16th, 1911. It was a corneal section, with a broad conjunctival bridge. There was no iridectomy and no difficulty in delivering the lens. The eye did well with excellent vision till 10 days after operation when he complained of itching feeling in eyelids. He rubbed his eyes, causing profuse haemorrhage into anterior chamber. The wound was re-opened except at the bridge. After treatment the blood re-absorbed. The eye gradually improved and when he was dismissed on December 2nd, his eye looked perfectly normal, not even the mark of the section showing. His vision was  $\frac{6}{6}$  with plus 12 sph. and with plus 15 sph. No.1 Jager.

**CASE 12 - Robert B., Aged 68 years**

On August 1st, 1910, he was operated on for cataract of his left eye with  $\frac{6}{6}$  vision and was admitted again on July 8th, 1911 for cataract extraction of right eye. The bridge operation was performed. There was no iridectomy and no difficulty in delivering the lens. The eye was found healed by next morning, but a week after operation he rubbed his

eye (during sleep). There was blood in anterior chamber, and the eye was inflamed. The blood became absorbed in four days, but there was iritis ensued. This condition gradually improved after treatment and he was dismissed on July 31st with  $\frac{6}{12}$  vision.

**CASE 13 - Mrs H., Aged 37 years**

Was operated on for cataract of left eye about a year ago with  $\frac{6}{9}$  vision. Since that time right eye has been gradually becoming blind. She was operated on June 17th by corneo-conjunctival bridge method. The sclerotic was involved in wound. An irido-cyclitis developed and there was no vision. She was dismissed on July 10th but was readmitted for treatment on August 5th suffering from sympathetic ophthalmia. After treatment the inflammation subsided, but she remained totally blind. She was dismissed on August 21st, 1911. The wound healed immediately although there was irido-cyclitis.

**CASE 14 - Robert McP., Aged 60 years**

Was operated on for cataract on June 17th. The operation was done by the corneo-conjunctival bridge method. There was no prolapse of the iris or iridectomy although some lenticular substance remained. The eye was healed the following day and the patient was dismissed on July 1st. Vision  $\frac{6}{6}$  with plus 12 sph. and with plus 16 sph. No. 1 Jager.

**CASE 15 - George R., Aged 61 years**

Had cataract extraction performed on the left eye on November 11th, 1909. He was dismissed on November 20th, 1909. With plus 13 sph. he had  $\frac{6}{9}$  and with plus 16 sph. Jager No. 2, up to the beginning of June 1910 was able to do his work entirely dependent on the operated eye, his right eye being at that time blind. He was admitted again on June 3rd, 1911, and had his right eye operated on. The wound healed rapidly but on fourth day after operation he rubbed his eye causing haemorrhage into anterior chamber. The blood was absorbed in 24 hours and the eye gradually improved. Vision was  $\frac{6}{18}$  with plus 10 sph. plus 2 cyl. 90° with plus 14 sph. and plus 2 cyl. 90° read No. 5 Jager.

**CASE 16 - E. H., Aged 75 years**

Operated on 6th April, 1911. There were no complications during removal of lens and the wound was found healed the following afternoon. Entropion of the lower lid occurred and gave some trouble. She was dismissed on May 2nd, 1911. Vision was plus 11 sph.  $\frac{6}{12}$  with plus 14 sph. No. 3 Jager.

**CASE 17 - Mrs F., Aged 67 years (a morpho maniac)**

Operation on left eye 13th April, 1911. Dismissed on 19th. No complications. Vision  $\frac{6}{24}$  with plus 12 sph. Jager No. 4 plus 16 sph. Immediate union took place.

**CASE 18 - Mrs B., Aged 85 years**

Operated on right eye 19th April, 1912, dismissed on 13th May, 1912. No complications. Immediate union. Vision  $\frac{6}{12}$  with plus 11 sph. Reads Jager No. 2 with plus 14 sph.

**CASE 19 - Capt. McK., Aged 70 years**

Operated on left eye on 17th April, 1912, dismissed 7th May, 1912. Vision plus 9 sph. plus 1 Cyl. axis  $180^{\circ}$   $\frac{6}{9}$ . No. 2 Jager with plus 12 sph. and plus 1 cyl. axis  $180^{\circ}$ . Immediate union of wound.

**CASE 20 - R. McC., Aged 69 years**

Operated on left eye 29th March, 1912. No complications during operation. Immediate union of the parts. Small quantity lenticular substance left in anterior chamber, with plus 12 sph. and 1.75 cyl.  $90^{\circ}$   $\frac{6}{6}$  plus 15 sph. and plus 1.75 cyl.  $90^{\circ}$ . Jager No. 1.

**CASE 21 - Mrs C., Aged 66 years**

Operation on right eye on 14th March, 1912. No complications, lens easily removed and immediate union resulted. Vision  $\frac{6}{12}$  and Jager No. 2 with plus 13 sph. and plus 16 sph. respectively.

CASE 22 - Mrs D., Aged 57 years

Operated on 5th February, 1912, dismissed 26th February.  
Slight prolapse of iris nasal side repositied by spatula and  
massage to cornea.  $\frac{1}{4}\%$  Eserine instilled after operation;  
immediate union of wound. Vision plus 13 sph.  $\frac{6}{6}$  plus 16  
sph. Jager No. 1

CASE 23 - Thos. A., Aged 60 years

Operated on left eye on 25th January, 1911, dismissed  
10th February. Immediate union. Vision  $\frac{6}{6}$  with plus 13 sph.  
and plus 2 cyl. axis  $90^{\circ}$  with plus 16 sph. plus 2 cyl. axis  
 $90^{\circ}$ . No. 1 Jager.

CASE 24 - O. T., Aged 63 years

Operated on myopic eye on 25th January, 1912, dismissed  
10th February, 1912. No complications, immediate union.  
Vision  $\frac{6}{6}$  with plus 8. sph. and with plus 11 sph. No. 1 Jager.

CASE 25 - S. F., Male, Aged 55 years

Operated on 4th December, 1911. No complications.  
Union of wound complete following day. Slight lenticular  
substance left in anterior chamber. Gradually absorbed.  
Dismissed 22nd December, 1911. Vision  $\frac{6}{12}$  with plus 12 sph.  
and plus 1.5 cyl.  $180^{\circ}$  and plus 16 sph. plus 1.5 cyl.  $180^{\circ}$   
Jager No. 4



CASE 26 - D. G., Male, Aged 83 years

Operated on left eye 5th November 1911. (Previous operation elsewhere. No vision) Had been blind for four years. No complications. No iridectomy. Immediate union. Dismissed 27th November, 1911. Vision  $\frac{6}{6}$  with plus 11 sph. and Jager No. 1 with plus 16 sph.

CASE 27 - A. W., Male, Aged 72 years (Very stout, 16 stone)

Operated on 26th October, 1911, dismissed 11th November, 1911. No complications. Immediate union. Vision  $\frac{6}{9}$  with plus 8 sph. plus .75 cyl.  $180^{\circ}$ . Jager No. 2 12 sph. and plus .75 cyl.  $180^{\circ}$ .

CASE 28 - T. A., Aged 60 years

Second eye operated on October 6th, 1911. No complications, immediate union. Vision  $\frac{6}{6}$  with plus 13 sph. and Jager No. 1 with plus 16 sph.

CASE 29 - Mrs G., Aged 75 years, frail delicate woman

Operated on 23rd September, 1911. During rupture of capsule lens passed into fluid vitreous, and could not be seen; it was allowed to remain. She had good vision up till two months ago. Eye became painful, irido-cyclitis set in and the eye was removed when the lens found adhering to ciliary body. The wound united immediately after operation.

CASE 30 - Mrs K., Aged 76 years

Operated on right eye on July 17th, 1910, dismissed on 2nd August, 1910. There were no complications. Immediate union. Vision was  $\frac{6}{12}$  with plus 13 sph. and plus 1.25 cyl. 90°. Jager No. 4 with plus 16 sph. and plus 1.25 cyl. 90°

It will be observed that the chief feature in these thirty cases of cataract extraction was immediate union of the wound. This I consider to be due to the conjunctival bridge maintaining nourishment to the wound.

Steven Gordon Luckie. M. B.

31<sup>st</sup> May 1912.

-----