

SUPPURATION IN THE NASAL ACCESSORY SINUSES.
ITS PATHOLOGY, ETIOLOGY, DIAGNOSIS AND TREATMENT,
AND WITH SPECIAL REFERENCE TO CASES.

by

Charles H. McIlraith, M.A., M.B., C.M. (Glasgow)

Submitted as a Thesis for the Degree of M.D.,
at the University of Glasgow. October 1895.

=====

ProQuest Number:27552899

All rights reserved

INFORMATION TO ALL USERS

The quality of this reproduction is dependent upon the quality of the copy submitted.

In the unlikely event that the author did not send a complete manuscript and there are missing pages, these will be noted. Also, if material had to be removed, a note will indicate the deletion.



ProQuest 27552899

Published by ProQuest LLC (2019). Copyright of the Dissertation is held by the Author.

All rights reserved.

This work is protected against unauthorized copying under Title 17, United States Code
Microform Edition © ProQuest LLC.

ProQuest LLC.
789 East Eisenhower Parkway
P.O. Box 1346
Ann Arbor, MI 48106 – 1346

I N T R O D U C T I O N .

During the last two years, as Resident Medical Officer at the Hospital for Diseases of the Throat etc., Golden Square, London; I have had the good fortune to see and take part in the treatment of a considerable number of cases of suppuration in the accessory cavities of the nose. My attention was drawn to these cases more forcibly, when I found, that in the still scanty literature of the subject, a great diversity of opinion exists especially as regards the Pathology and Etiology. I have endeavoured, in these few pages, to place together some information on these two points; at the same time I have made this a more or less complete resumé of the subject. With this end in view, I have thought it best to give a short account of the anatomy of the region and have then passed on to the discussion of the Pathology and Etiology. Finally, I have dealt with the symptoms, diagnosis and treatment of suppuration in the various sinuses, more especially as manifested, in a series of cases.

My thanks are due to the members of the staff of the Hospital here, for the free hand they have given me in the investigation of their cases and allowing me to take part in their treatment.

WORKS CONSULTED.

MacDonald: Diseases of the Nose etc., 1892

Lennox Browne: The Throat and its Diseases. 4th. ed.

Mc.Bride: Diseases of the Throat, Nose, and Ear, 1894.

Burnett: Diseases of the Ear, Nose, and Throat, 1893

Bosworth: Diseases of the Nose and Throat.

Watson: Diseases of the Nose, 1875 *

Louis: Diseases of the Head and Neck, 1848

American Laryngological Associations Transactions, 1886, 1893.

Berliner, Klinisch Wochenschrift, 1887, 1888.

Annales des Maladies de L'Oreille du Larynx, etc., 1887

British Medical Journal, 1893

Quain's Anatomy, vol. i. 9th ed:

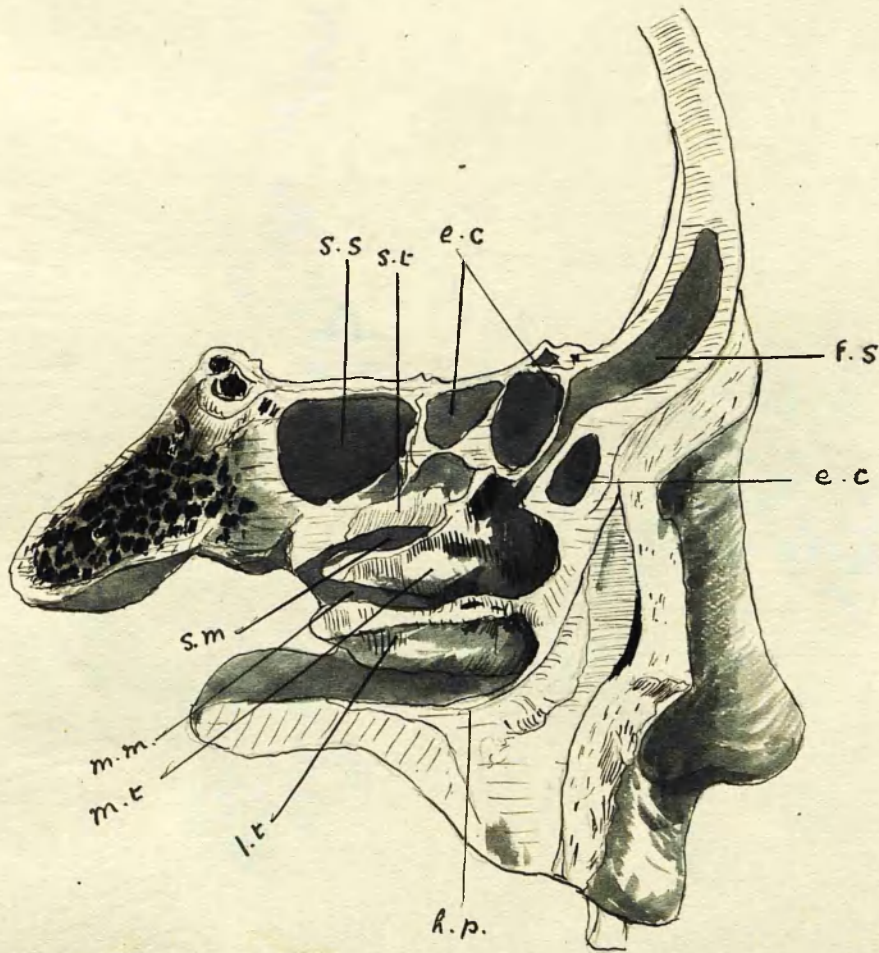
=====

A N A T O M Y

- of -

THE NASAL ACCESSORY SINUSES

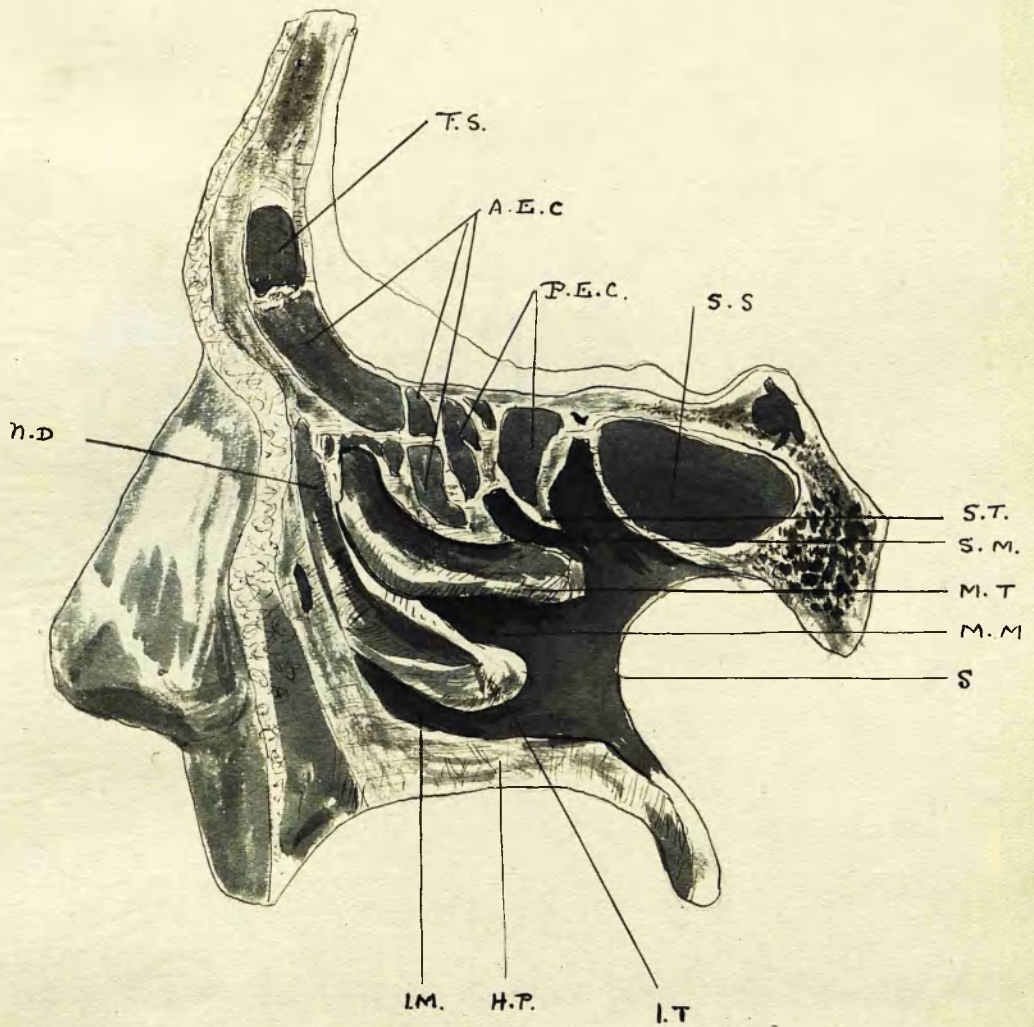
=====



Section through the Right side of the nose external to the plane of the middle and inferior turbinates.

- | | | |
|-------------------------|-------------------------|------------------------|
| h.p. Hard palate | i.t. Inferior turbinate | S.S. Sphenoidal Sinus. |
| i.m. Inferior meatus | m.t. Middle " | e.c. Ethmoidal Cells. |
| i.t. Inferior turbinate | S.t. Superior " | f.s. Frontal Sinus. |
| S. Septum | | |
| m.m. Middle meatus | | |

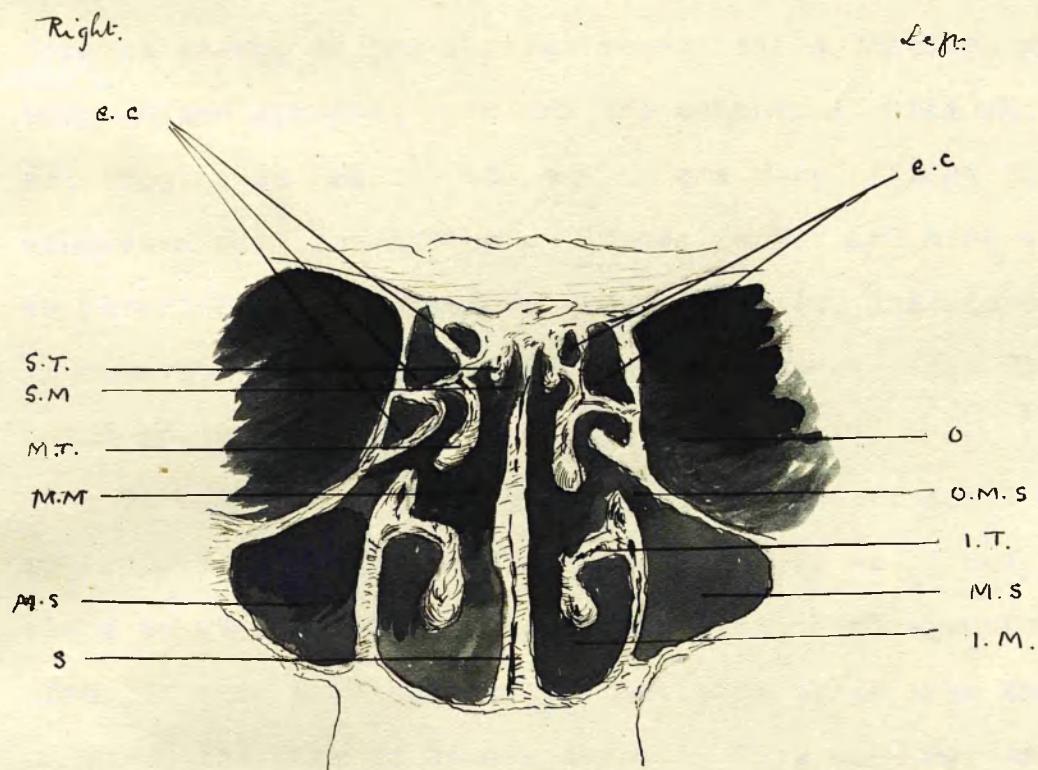
From Dr. Onodi's Atlas of the nasal cavity etc. (Clair Thomson)



The outer wall of the sup. nasal fossa has been removed.

F.S.	Frontal Sinus	M.T.	Middle Turbinate
A.E.C.	Anterior Ethmoidal Cells	M.M.	Middle Meatus
P.E.C.	Posterior	S	Septum
S.S.	Sphenoidal Sinus	I.T.	Inferior Turbinate
S.T.	Superior Turbinate	I.M.	Inferior Meatus
S.M.	Superior Meatus	H.P.	Hard Palate
		N.D.	Nasal duct.

(After Orsini: Atlas of the Nose etc. St. Clair Thomson)



Section through the orbit; the Maxillary Sinus; + the Ethmoidal Cells.

S.T.	Superior turbinate.	e.c.	Ethmoidal Cells
S.M	Superior meatus.	O	Orbit
M.T.	Middle turbinate.	M.S	Maxillary Sinus
M.M	Middle meatus.	O.M.S	Opening of Maxillary Sinus
I.T	Inferior turbinate.	S	Septum.
I.M.	Inferior meatus.		

(After Onodi: Atlas of the Nasal Cavity + Sinuses, St Clair Thomson.)

Communicating with the nasal passages and opening into them by narrow openings are eight air spaces or sinuses, four on each side; viz., the maxillary sinus or antrum of Highmore, so-called, situated within the superior maxillary bone; the frontal sinus, in the frontal bone; the sphenoidal sinus in the body of the sphenoid bone and the ethmoidal cells which although not forming in reality one cavity are more or less intimately connected with one another. These latter are also divided into an anterior and a posterior group of cells, associated with an anterior and a posterior point of communication with the nasal passages.

To understand thoroughly the influence of nasal diseases on suppuration in these sinuses I think it would not be out of place to give a few details of the anatomical structure of the nose; or more particularly of that part of it into the formation of which the Ethmoid bone enters. This bone may be said to consist of two symmetrical halves or lateral masses, situated one on each side of the vertical plate; and separated from it by a slight interval which forms the superior meatus of the nose. Each lateral mass consists of a meshwork of cells - the Ethmoidal Cells - which are hemmed in as it were by the cribriform plate above, the orbital plate on the outside and a thin lamella of bone on the inner side, i.e. from the superior meatus. From

each lateral mass springs the middle turbinated bone, a broad thin plate of bone which passes downwards and is somewhat curved on itself with its convexity looking inwards. Beneath this and in continuation with an extension forwards of the orbital plate a long thin lamella of bone the uncinata process passes downwards and backwards to articulate with the superior maxilla and with the inferior turbinated bone - or turbinate process - of the superior maxilla by delicate bony plates which form a septum as it were between the nasal cavity on the one side and the antrum of Highmore, on the other. This latter cavity they more or less completely close in. Above the inferior turbinate process of the Ethmoid, i.e. the middle turbinated bone there is a short sharp folded portion which at the anterior end is merged in the middle turbinated bone but which posteriorly is quite free from it and which forms the superior turbinate process and the superior turbinated bone. This latter overhangs the superior meatus, while the middle turbinate overhangs the middle meatus.

Beneath the middle turbinate and on its outer aspect there is a deep groove running downwards and backwards, the hiatus semilunaris, the lower lip of which is formed by the uncinata process already described. At the anterior extremity of this groove is a passage the infundibulum which communicates with the anterior ethmoidal cells and either through them or along

with them, with the Frontal sinus. At the posterior extremity is situated the opening into the maxillary sinus, - the Ostium Maxillare. The posterior ethmoidal cells open into the superior meatus and at the upper and posterior extremity of this is the opening into the sphenoidal sinus.

Of these cavities the maxillary sinus is by far the largest. It is irregularly pyramidal in form and is simply hollowed out of the superior maxillary bone. Its size is variable, depending on the one hand on a diminished absorption of the bone in fetal life and on the other hand on encroachment on its size by bulging in, either of the inner wall of the nose or the canine fossa in its external aspect. The outer alveoli of one or more of the molar teeth form prominences in its floor and sometimes the fangs of the teeth penetrate it. It begins to form early in fetal life, about the fourth month, and at birth there is a fully developed cavity which enlarges with the further development of the superior maxillary bone. The cavity communicates with the nose by the Ostium maxillare as already stated.

The Frontal sinus is a prism shaped cavity situated between the inner and outer tables of the frontal bone and the floor of which is formed by the orbital plate. It is separated from its fellow of the opposite side by a thin lamella of bone which is nearly always perforated; the two cavities thus usually communicating with one another. At birth these

cavities do not exist. They begin to appear about the second year of life and increase in size as age advances, enlarging by absorption of the cancellated bony tissue. This cavity communicates by the Infundibulum with the hiatus semilunaris and by it with the middle meatus of the nose.

The Ethmoidal cells are irregularly shaped cells, communicating with each other and grouped into two masses, the anterior and the posterior ethmoidal cells, so called. The lateral masses of the Ethmoid are practically composed of these cells covered in by thin laminae of bone from the orbit on the one side and the superior meatus of the nose on the other. The anterior group of cells communicates by an opening or openings in common with the frontal sinus at the infundibulum or close to it in the hiatus semilunaris. The posterior cells open into the superior meatus. The ethmoidal cells are not present at birth and only begin to form about the third or fourth year, and by bony absorption they become gradually larger until fully developed in the adult.

The Sphenoidal sinuses occupy the body of the sphenoid bone. They are separated from one another by a median septum but are often in communication by openings in this. They open in the roof of the nose at its most posterior part and above the superior meatus. In development the body of the sphenoid is formed by the junction of two portions the posterior of which

carries the wings of the sphenoid while the anterior is formed by the sphenoidal turbinate bones which appear usually after birth. Each of these latter bones is composed of thin plates of bone inclosing a cavity which enlarges as age progresses to form the sphenoidal sinus. They are fully developed in the adult.

P A T H O L O G Y

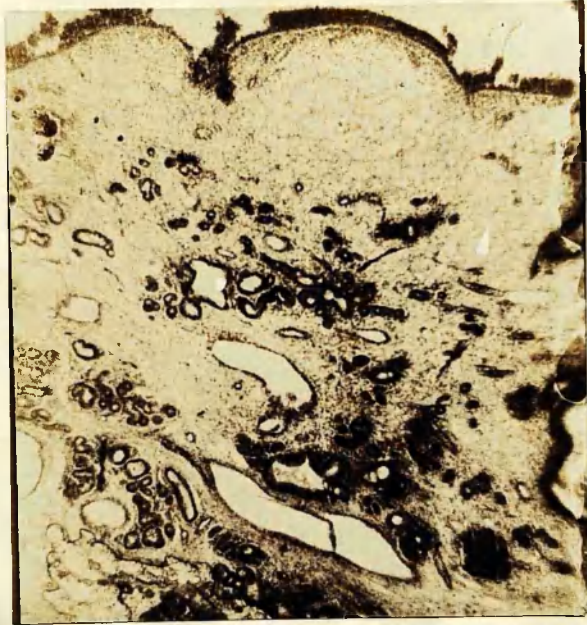- of -

THE NASAL ACCESSORY SINUSES

=====

Hypertrophic Rhinitis

Slight oedematous infiltration.
The section shows marked
dilatation of the glandular
elements.



Polypoid Mucous Membrane

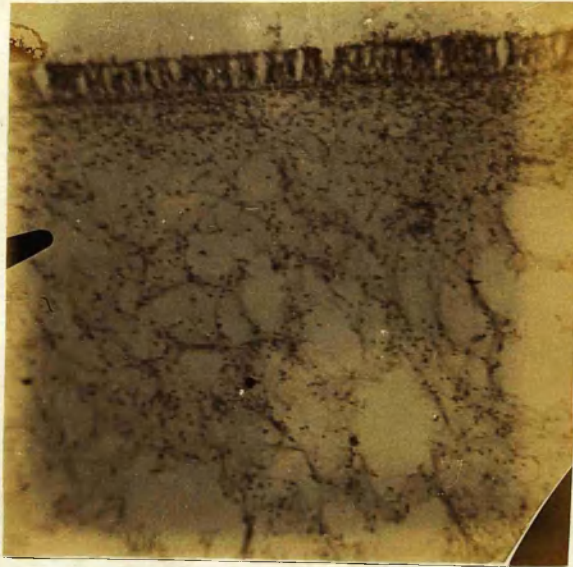
marked round celled infiltration.



Nasal Polypus -

(high power)

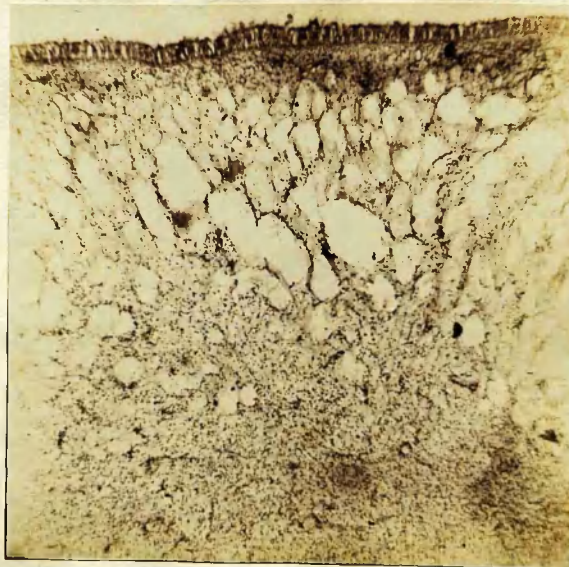
Showing mucous spaces.



Nasal Polypus.

(low power)

Showing mucous spaces and
round cell infiltration.



Polypid Mucous Membrane
from Maxillary Antrum -
Showing end cell infiltration.



Polypoid Mucous Membrane
from Frontal Sinus.

Showing round-cell infiltration,
& mucous spaces.

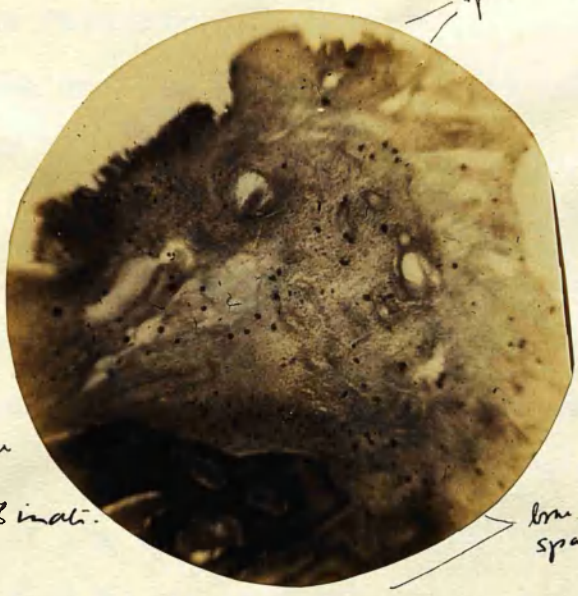


Polypoid Mucous Membrane
from Ant. Ethmoidal Cells.

Showing round cell infiltration.



Epithelial lining.



outside

Polypoid mucous membrane
outside to inside middle tubular.

bone with large absorption spaces.

showing.

Polypoid mucous membrane, with superficial ciliated epithelium.

enlarged vascular spaces.

Thickened peristernum.

no marked wood cell infiltration.

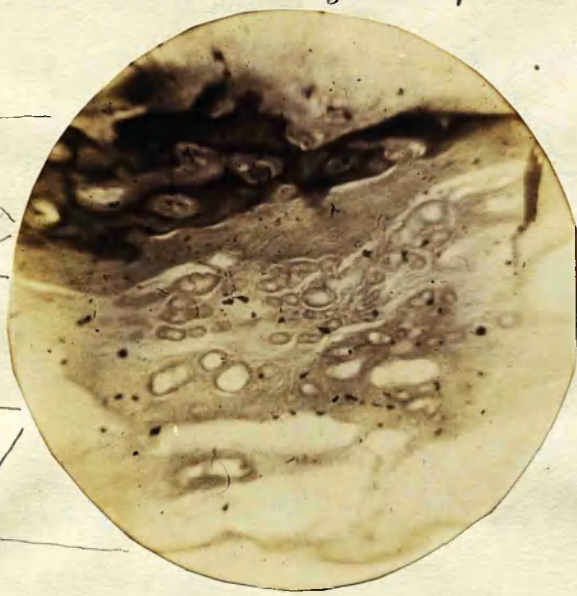
Bone with large absorption spaces.

bone

peristernum

layer of dilated
mucous glands

layer with large
mucous spaces.



From

within

mid. tubular

In studying the Pathology of suppuration in the Nasal Accessory Sinuses, we must consider what takes place in inflammatory conditions of the nasal mucous membrane; seeing that the mucous membrane lining the cavities is continuous with, and almost identical in structure with that in the nose.

Now, inflammation occurring in the nose begins with a hyperæmia of the mucous membrane. This gets swollen up and is frequently studded over with minute patches of ecchymosis due to rupture of some of the fine blood vessels ramifying in it. At first this swelling may be so great as to partially obstruct the nasal passages and so give rise to the feeling of having a stuffed nose. In this stage there is little or no exudation. Later on the swelling increases, being then largely due to œdematous infiltration which involves not only the superficial but the deeper layers of the mucous membrane including the periosteum. This exudation, consisting of blood plasma and leucocytes, soon finds its way to the surface and is poured out as a profuse discharge of sero-mucous with probably some blood cells. With the onset of this discharge the swollen mucous membrane somewhat subsides and the discharge gets more serous in character. In course of time, possibly some weeks or even longer, leucocytes get poured out more abundantly and the result is finally a discharge of pus.

The acute inflammatory process very soon either results in resolution or in a chronic morbid process. In some cases hypertrophy takes place and at other times if the discharge is of long standing an atrophy of the mucous membrane may result. One of the most frequent results, however, of a chronic inflammation of the nasal mucous membrane is the establishment of what may be called, a myxomatous condition. The tissue which still presents the ordinary character of inflamed mucous membrane a meshwork of connective tissue with large serous spaces, with here and there dilated mucous glands scattered through it, with round celled infiltration depending on the extent and acute character of the inflammatory process and covered superficially with ciliated epithelium, gets infiltrated with serous fluid to such an extent as to develop a soft, jelly like thickening of the tissue. In some cases this goes on to the formation of mucous polypi, which grow sometimes single, sometimes in quantity and often to large size, completely blocking up the nasal passages.

That nasal polypi are simply hypertrophic conditions of the nasal mucous membrane is I think now fully conceded by most Rhino-Pathologists. That hypertrophic Rhinitis and Polypi are allied conditions I admit but that the one is the outcome of the other I cannot believe. In numbers of cases, we meet with polypi growing with slender pedicles, in which there is no true

hypertrophy of the rest of the mucous membrane. They usually occur, however, where the membrane is myxomatous. I have sectioned and seen sections of a considerable number of these growths and I have not seen what could be called a true myxoma or yet a fibrous myxoma, such as you meet with growing from the inferior turbinate or in the naso-pharynx. That they grow usually from the middle turbinate and especially from that part of it in the hiatus semilunaris is due probably to the fact that gravity has a certain influence on their development and also that there are some peculiarities in that portion of the nasal mucous membrane which lends itself to their development that they are comparable to similar conditions of the septum and inferior turbinate must be admitted. That they are due to carious or necrosed bone; especially the condition described by Woakes as necrosing ethmoiditis I do not believe, as in all the cases I have examined I have met with none apart from syphilis in which the bone had undergone necrosis. Even in those cases in which we get polypoid mucous membrane outside and inside some of the ethmoidal cells there is nothing in the intervening bone to suggest caries or necrosis.

Now whereas these changes are constantly seen going on in the nasal mucous membrane and especially in that portion of it over the middle turbinate; it can also be fairly well presumed that the same changes occur in the mucous membrane lining the

the sinuses. This in no way differs anatomically from and is simply a continuation of that in the nose. In fact in sup-
puration of the sinuses we always find these lined with polypoid
mucous membrane and frequently with true polypi in them. The
only difference lies in a perhaps greater abundance of round
cells; although the tissue still presents the characters of the
mucous membrane with mucus infiltration.

Now in the case of the maxillary antrum and the Frontal
and Sphenoidal sinuses we have single cavities, opening as we
have seen, by comparatively small openings into the nasal pas-
sages. If then the inflammatory process attacks the mucous
membrane lining these cavities we have a similar result to
that taking place in the nose, with this difference, that in
their case the normal openings get blocked up by the swollen
membrane and the discharge does not get free exit. The swelling
as we have seen is temporary in the acute disease and conse-
quently after some days of discomfort to the patient the swelling
subsides somewhat and there is a copious discharge of pus, at
once relieving all symptoms.

Unfortunately the patient is liable to the occurrence of
these attacks more or less frequently repeated and each suc-
ceeding attack leaves the mucous membrane more and more injured
until we get the sinuses lined with the polypoid mucous membrane
and sometimes, as previously stated, containing polypi, and

accompanied by the constant purulent secretion of the chronic condition.

That a chronic discharge of pus from these sinuses frequently takes place, without presenting the definite symptoms of empyema, I fully believe. In fact I would class a considerable number of cases of muco-purulent rhinitis, which resist ordinary treatment, under the title of chronic catarrh of the sinuses. In cases where the nasal passages are free and the openings from the sinuses are large the swollen mucous membrane may not be able to completely retain the discharge and we may not for some time at least get the characteristic symptoms of empyema. Sooner or later, however, in many of these cases, the mucous membrane gets more and more polypoid or gets much more swollen during an attack of acute rhinitis; a complete stoppage of the opening occurs and a true empyema results. Very often in these cases the nasal mucous membrane gets polypoid and true polypi may even result, possibly due to the irritation of the discharge and possibly to direct spread of the inflammatory process.

Of course the question of the direct spread of the inflammatory process from the nose into the sinuses and vice versa may arise. It has been asserted that this never occurs. Bosworth, for example, in his Diseases of the Nose and Throat, Vol. I. p. 466, states that, "a catarrhal inflammation of the nose is

the result of local conditions, which do not, in any degree probably, operate in the maxillary sinuses. In other words, so-called nasal catarrh is a perversion of function of the normal respiratory apparatus of the nose, and its causes only operate on those tissues and would have no effect on the delicate membrane lining the antrum." Yet we find constantly that in acute nasal catarrh we have patients who undoubtedly exhibit symptoms of acute catarrh of their sinuses.

No doubt a chronic condition might arise from the blocking in and decomposition of the normal discharge within these cavities by some condition of the nose itself, in which the nasal passages are small and the openings into the sinuses are blocked by polypi, polypoid mucous membrane or an hypertrophied condition of the mucous membrane over the middle turbinate. If the normal discharge get blocked in and decomposed it would set up a certain amount of irritation in the lining membrane of these cavities and the oftener the recurrence, the more sure the development of an acute inflammation of the membrane itself. Then again the process may be initiated in the maxillary antrum by the formation of an abscess or a chronic inflammation round the fang of a decayed tooth; seeing that in a considerable number of cases we get the outer alveolus of the molar teeth in the floor of the antrum. Foreign bodies in the sinuses and tumours whether benign or malignant may by their presence set

up irritation or by blocking up the openings cause a retention of the discharge and so produce suppuration.

In the case of the Ethmoidal cells circumstances are somewhat different. Here we have a mass of cells separated more or less from one another and varying in size. When inflammation occurs in the lining membrane of these, this undergoes the usual changes resulting in a myxomatous condition. This, if it exists for a time gives rise to a distension of the cells. In some cases it leads to a protrusion of the myxomatous tissue from the cells and the further development of these buds as it were, into true polypi; which, usually of small size, are to be found more or less blocking up the infundibulum, the hiatus semilunaris and the space between it and the wall of the maxillary antrum. Sometimes they are also to be found in the superior meatus, especially posteriorly. That this is the origin of only a small proportion of cases of nasal polypus has been amply shown by Zuckerkandl,⁺ who made an exhaustive study of their origin and who found them to arise from the ethmoidal cells in only 9 % of his cases.

As I have stated previously, the commonest origin of the nasal Polypus is from the nasal mucous membrane itself along the lips of the hiatus semilunaris.

+ Zuck^rer^kandl: Normal und Pathologische Anatomie der Nasenhöhle, Vienna 1882. p. 78 etc.

As another result of the inflammatory process and the distension of the cells, we have these getting gradually extended in the body of the ethmoid and even into the middle turbinate. When this occurs we have a distinct bulging of the middle turbinate into the middle meatus, pressing close against the septum and forming a distinct ovoid mass. In this way we have the middle turbinate or at any rate a large portion of it converted as it were into a large bony cyst. By and by the nasal mucous membrane lining this gets myxomatous and thus we may have this myxomatous condition both outside and inside these distended cells.

In the course of the distension of the cells absorption of the thin bony walls of the cells may take place and in some cases the mucous membrane lining this may be so thinned as to give the feeling of bare bone to a probe, especially as the thin membrane is easily ruptured by even gentle manipulation. This same feeling can sometimes be got in even a healthy nose. It is probably this feeling of bare bone which gave rise to the idea of the disease described by Woakes as necrosing ethmoiditis. As I have stated previously I have never come across a case of true necrosis apart from tertiary syphilitic trouble.

While the myxomatous changes have been occurring, however, we have the usual increased secretion which helps to the cellular distension; the normal openings of the cells being already

partially if not wholly closed. This may at first give rise to acute abscess but failing immediate resolution or if there are closely repeated attacks, chronic suppuration results, the pus finding its way either through the anterior or posterior ethmoidal cells.

As a result also of the distension of the cells we may have exophthalmos resulting; but this condition I have never witnessed. The patients, however, have frequently complained of a sense of fulness in the orbit.

That suppuration in the antrum and other sinuses is not an infrequent accompaniment of disease of the ethmoidal cells cannot be wondered at. In fact, many of the worst cases which we meet with are thus complicated. The same bulging of the ethmoidal cells and development of polypoid and swollen mucous membrane in the hiatus semilunaris, where most of the sinuses have their openings, must lead to stoppage of the middle meatus and along with it the opening of these sinuses and leading to the retention of their normal secretions and possible subsequent decomposition with results which I have already indicated. However, in most cases, the same causes which give rise to the ethmoidal trouble would also give rise to that in the other sinuses; although in the case of the ethmoid, isolated cells would be more apt to get their openings blocked and thus the disease would probably have laid a hold on them sooner.

If the pus gets completely blocked in any of these sinuses, it may make its way through some of the bony walls, reaching the orbit through the os-planum from the ethmoid cells and sometimes by natural weak places in the bony walls from the frontal and maxillary sinuses. It may bulge out the superior maxilla in the canine fossa or beneath the inferior turbinate. In the case of the frontal sinus it may make its appearance in the forehead just above the junction of the nasal bone with the frontal. Finally it may give rise to septic meningitis and sometimes to cerebral abscess.

=====

ETIOLOGY
of
SUPPURATION IN THE NASAL ACCESSORY CAVITIES

It is not my intention to discuss the etiology of each individual sinus by itself as I regard the origin of suppuration in the various sinuses as due in the majority of cases to a common cause and that cause, some nasal trouble, more or less marked

No doubt in the case of the Antrum the statement has been made and opinions are divided as to whether suppuration in it is due to dental or nasal trouble.

McBride,¹ Lennox Browne,² Beverley Robinson,³ Bryan,⁴ Baratoux,⁵ Boucheron,⁶ Fraenkel,⁷ Moldenhauer⁸ and Schech,⁹ state that the commonest cause of suppuration in the antrum is in carious teeth while on the other hand McDonald,¹⁰ Bosworth,¹¹

-
1. McBride. Diseases of the Throat, Nose & Ear. 1894 Ed.
 2. Lennox Brown, The Throat and its Diseases, p. 508-528
 3. Beverley Robinson, American Laryngological Associations Transactions, 1886, p. 181
 4. Bryan, Diseases of the Ear, Nose & Throat, Burnett, p. 744.
 5. Baratoux, Annales des Maladies de L'Oreille, du Larynx &c. (1887, p. 203.
 6. Boucheron " " " " "
 7. Fraenkel, Berliner Klinisch Wochenschrift, 1887, p. 273.
 8. Moldenhauer, as cited by Bosworth.
 9. Schech, Diseases of Mouth, Throat & Nose. Eng. Ed. 1886. (p. 276-278.
 10. McDonald, Treatise on the Diseases of the Nose & its accessory cavities, 1892, p. 171.
 11. Bosworth, Diseases of the Nose & Throat, Vol. 1. p. 465-467.

Zuckerkandl,¹² Chatellier,¹³ Zeim,¹⁴ and Krause¹⁵ assert that it is essentially nasal in origin.

In the cases which it has been my privilege to see disease of the teeth can be considered as the cause of the suppuration in only a small per centage.

In about half the cases there was marked dental caries but in only 16.1 % of them was there no marked nasal trouble present and even if we take into consideration the number of cases in which the teeth were bad before the nasal trouble developed the percentage is only 40.8 % or less than half.

The importance of dental caries in the causation is much lessened if we remember the fact that it is an exceedingly frequent complaint and the association of it with other diseases is as common as in the case of suppuration in the sinuses.

On the other hand it is not to be wondered at that the teeth were formerly described as the sole cause⁺ from the frequency of the perforation of the inner alveolus by the fangs of the teeth of the upper jaw - more especially those of the bicuspidis

12. Zuckerkandl, Normal und Pathologische Anatomie der Nasenhöhle (p. 137. Also Brit. Med. Jour. Aug. 24th. 1895.

13. Chatellier, Annales des Maladies de L'Oreille, du Larynx &c. (1887, p. 203.

14. Zeim, Berliner Klinisch Wochenschrift 1888.

15. Krause, Berliner Klinisch Wochenschrift 1887. p. 228.

+ Louis. Diseases of Head and Neck 1848, p. 167.

and the molars.

Is it not as conceivable, however, to suppose the dental caries as due to interference with the nutrition of the teeth in these cases as to suppose the suppuration as following on the caries. If as I have previously stated, when discussing the pathology of the subject chronic inflammation of the mucous membrane tends to develop an œdematous condition of it which ultimately pervades the periosteal layers as well as the more superficial it would be the natural outcome to suppose a more or less cutting off or at any rate a perverting of the nutrition of the teeth which had perforated the bony alveolus and were only covered by this unhealthy mucous membrane. Further support is given to this from the fact that in none of the cases was there any history to be got of symptoms pointing to the formation of an alveolar abscess immediately prior to the development of the discharge from the nose.

Besides, the study of the diseases of the nose is a more or less recent one and probably in a great number of the cases formerly ascribed to dental trouble, nasal trouble was never inquired into.

That the same conditions which cause suppuration in the other sinuses hold good in the antrum must also be taken into account. We can have suppuration in the Frontal, Ethmoidal, and Sphenoidal sinuses apart from the antrum being involved. There

are no teeth in this case to cause the trouble; we must look for the causation in the nose or in the cavities themselves. The anatomical conditions and the pathological results are the same. Inflammation is just as liable to attack the mucous membrane of the one as of the other, and that the maxillary antrum would be most frequently involved, is not to be wondered at, seeing that it lends itself more readily to the retention of discharge than is the case with the other sinuses. In it, we have usually the ostium maxillare situated at the upper part of its inner wall and at a place in the hiatus semilunaris where blocking of it can be more easily produced, than with the openings of the ethmoidal cells or the frontal sinus in the infundibulum.

Apart then from a comparatively small number of cases in which the antral trouble begins with disease of the teeth, I take it that the majority of the cases, as I have previously stated are due to the same cause as suppuration in the other sinuses.

These causes are either acute or chronic rhinitis accompanied by hypertrophy or polypoid degeneration and in a few cases syphilitic and malignant disease of the nose. Some few cases of frontal and antrum suppuration are due to foreign bodies within these cavities.

That suppuration in the sinuses is sometimes the result

of an extension of the inflammatory process from the nose into the sinuses is in my opinion certain. That this is the most frequent cause has been asserted by Zuckerkandl,¹ Chatellier, Krause and others but Bosworth² holds that the disease rarely, if ever extends by a continuity of tissue but is rather due to a catarrhal condition of the membrane itself within the sinuses caused by a blocking in of the discharges by closure of the natural orifices. I take it that we can have it occurring either way. We frequently get symptoms pointing to inflammatory catarrh within the sinuses, in acute inflammatory conditions of the nasal mucous membrane, where the time during which the rhinitis has been present is so short that simple closure of the openings into the sinuses and the consequent retention of the discharge could not produce the symptoms. The condition of the nasal mucous membrane, and especially that portion of it in the middle meatus, does not in many of those cases give the appearance as if it were of itself sufficient to close the openings. If on the other hand, the natural openings get blocked up, be it by polypi, hypertrophic rhinitis, or malignant disease of the nose and the discharge gets pent up within any of those cavities, in course of time this would set up a suppurative inflammation

(1) As previously quoted.

(2) Disease of the Nose & Throat. p. 466.

within the sinuses and the attendant results previously mentioned

Similarly we can have the discharge of a syphilitic nose finding its way into the cavities and causing irritation and inflammation there. The same is the case in atrophic rhinitis. In many of the cases we get a history of the patient having suffered from continual colds in the head; these getting more and more frequent till the discharge becomes constant. In one of my cases these symptoms have followed Influenza and in another Scarlet fever.

A few cases are due to the presence of foreign bodies within the sinuses; nearly always confined to the antrum or the frontal sinus. In the antrum it may be due to supernumerary teeth, may be congenital. Stumps of teeth, in dental operations, may be accidentally driven into the cavity or portions of dental or other instruments be lost there and, acting as foreign bodies, set up inflammation.

In the Frontal sinus, it is usually the larvæ of insects that have found their way into the cavity that act as foreign bodies. These cases are most frequently described in American literature.

In addition to the above mentioned causes, suppuration in the sinuses has been described as following on any of the acute infectious diseases. Tubercle has also been ascribed as a cause.

Watson¹ has described suppuration in the antrum following traumatism at birth; Kuckenbacker,² following the use of the galvano-cautery; and Langenbeck,³ following Malgaigne's operation for division of the infraorbital nerve.

-
- (1) Watson. Diseases of the Nose. P. 156.
 - (2) Küchenbecker, as quoted by Burnett.
 - (3) Langenbeck, as quoted by Bosworth.

No.	Name	Age	One side or both	Complicated with	Nasal trouble	Teeth	Remarks.
1	Jessie Rundle	27	Right	Acute Rhinitis	marked	bad	
2	Maria Bohlmann	35	Left	Ethmoidal frontal	marked	bad	After nasal trouble.
3	George Cross	22	Right	Ethmoidal	marked		
4	Mrs. Harris	24	Both	Ethmoidal	marked		
5	Miss Benglass	32	Right	Atrophic rhinitis	"	bad	After nasal trouble.
6	Sarah Kemp	55	Right	Chr. Rhinitis		"	
7	Mary Hurley	52	Double	Polypi	marked	"	
8	Nathaniel Smith	65	Right	Sarcoma of Nose	marked		
9	Frederick Dobby	38	Both	Spec. rhinitis	marked		
10	Eliza Worth	30	Right	Hypertrophic Rhinitis.	"		
11	Bessie Ingram	18	Left	Polypi	"		
12	Lilly Walton	20	Both	Polypi	"		
13	Ellen Hurley	23	Left	Hypertrophic Rhinitis.	"	bad	After nasal trouble
14	James Penn	42	Both	Frontal Sinus polypi	"	"	After nasal trouble.
15	Mrs. Senior	25	Right	Ethmoidal	"		
16	Mary Eagles	46	Left	Ethmoidal polypi	"		
17	James Kemp	37	Both	Chr. Rhinitis	"	bad	
18	Edith Pratt	18	Left	Hypo: Rhinitis		"	
19	Mary Butcher	16	Left	Polypi	marked	"	
20	Mrs. Saunders	57	Right	Polypi	"	"	

continued.

No.	Name	Age	One side or both	Complicated with	Nasal trouble	Teeth	Remarks
21	Phillip Connor	49	Right			bad	
22	Fred ^k .Maddison	26	"	Polypoid hypertrophy	marked	"	
23	Eliza Dodwell	64	Left	Polypi		"	
24	John Burd	52	Right	Ethmoidal polypi	marked	"	After nose trouble.
25	Annie King	24	Left	Ethmoidal polypi	"	"	
26	Agnes Parker	42	Both	Polypi	"	"	
27	Mrs. Hurley	52	Left	Polypi	"	"	
28	Mrs. Greenyer	31	"	Polypi, frontal sinus.	"		
29	Miss O'Brien	32	Right	Hyp. Rhinitis	"		
30	Eliza Bodgner	52	"	" "	"		
31	Selina Palmer	42	Both	Polypi	"		
32	John Barnes		Left	Hyp. Rhinitis	"		
33	Mary Gage	35	Both	Polypi	"	bad	
34	Mary Bennett	40	"	Ethmoidal polypi	"		
35	Violet Atkins	21	"				
36	Wm. Coombs	35	Right	Hyp. Rhinitis		Very bad	
37	Thos. Sewell	15	Left	" "		bad	
38	Fred. Pearson	21	Both	Polypi	marked	"	
39	Wm. Roberts	40	"	"	"	Always good	
40	John Broker	25	Left			bad	

continued.

continued.

27.

No.	Name	Age	One side or both	Complicated with	Nasal trouble.	Teeth	Remarks.
41	Alex. McLane	22	Left			bad	
42	Marg ^t .Davidson	28	"	Polypi, frontal sinus, ethmoid	marked		
43	Jessie Broker	27	Left	Polypi, ethmoid	"		
44	Myra Rushton	25	Right	Polypi	marked		
45	Alice White	21	"	"	"		
46	Mary Hoad	19	"			bad	
47	Char. Manners	50	"	Hypertrophic Rhinitis		"	
48	John Williams	47	"	Hypertrophic Rhinitis Polypoid mucous membrane.	marked		

S U P P U R A T I O N
in the
M A X I L L A R Y A N T R U M .

The maxillary antrum is the largest of the sinuses and suppuration in it is more frequent than in any of the others. The reasons why this should be so have been already dwelt upon. The pus discharge is usually one sided although in a considerable number of cases a double discharge has been noted.

I have already dwelt upon the Etiology of suppuration in the sinuses. The subjoined table shows the relative frequency of cases due to nasal and dental trouble. Among the nasal cases are included two, one of which began after Influenza and another after Scarlet fever.

Synopsis of cases of Antrum Suppuration.

Total number of cases	49
---------------------------------	----

Teeth bad, no nose trouble	8
--------------------------------------	---

Teeth came bad after nose trouble	5
---	---

Teeth bad, but marked nasal trouble	12
---	----

	25
--	----

Cases in which there was marked nasal trouble.

Polypi in nose	15
--------------------------	----

Polypi and Ethmoidal suppuration	10
--	----

Polypi, Ethmoid and Frontal sinus	4
---	---

Atrophic Rhinitis	1
-----------------------------	---

" " Syphilitic	1
--------------------------	---

Acute Rhinitis	1
--------------------------	---

Chronic Rhinitis, with hypertrophy	7
--	---

Sarcoma of nose.	1
--------------------------	---

	40
--	----

Congenital Teeth and Antrum	1
---------------------------------------	---

SYMPTOMATOLOGY.

The symptoms vary according to the acuteness or chronicity of onset, the existing cause, and the patency of the ostium maxillare. Usually a patient comes complaining of discharge from, in the most part, one side of the nose and down the back of the throat. This has persisted for some time, probably years. The general health had always been fairly good, until he or she got what appeared to be a "cold in the head." At first the discharge was clear and watery and then it became purulent. This attack passed off, only to be followed by another which lasted longer than the first and after a succession of these attacks, the discharge of yellow matter from the nose got constant. At the onset of the complaint, the nose got somewhat blocked up and pain was experienced in one or other cheek bone. Occasionally frontal headaches were present and sometimes pain over the eyes. As the discharge from the nose came on, the pain and headache passed away. The matter discharged had at first no smell and left no nauseous taste in the mouth. The sense of smell and taste were still present. By and by the discharge got more constant and it was then noticed to come away more freely on stooping or bending the head forward.

Then a nasty smell was experienced by the patient and the discharge got more and more nauseous. The headaches got more severe and were scarcely absent and with the increasing amount of the discharge, the patient was ultimately driven to consult some one about himself.

Such is a typical case as it presents itself; but a considerable variation in the symptoms exists. In a few cases there is marked redness, heat, and some swelling of the cheek. Occasionally there is bulging of the jaw in the canine fossa and sometimes the inner wall of the antrum is so expanded into the nose as to press the inferior turbinate against the septum and so occlude the nasal passages.

Pain is not a constant feature, when present, it is usually of a dull aching character, referred to the cheek bone; but when there is closure of the ostium maxillare, neuralgic pains intra and supra orbital are complained of.

Fœtor and a nauseous taste in the mouth may be absent throughout. When present, the fœtor is usually only noticeable to the patient himself; thus differing markedly from that in ozœna where the sense of smell to the patient is usually lost.

The amount of pus also varies. Its colour is usually pale yellow and quite fluid although occasionally mixed with mucus. The purulent discharge is usually unilateral, but in a considerable number of the cases I have seen it was double. Out of 49

cases,

The Right side only was involved in	20	cases
The Left " " " " "	16	"
Both sides were " "	13	"

Patients also frequently notice that the pus flows more freely with the head held down. This is more marked in those cases, where the occupation is one in which stooping is a necessity and where the discomfort caused by the discharge constantly trickling from the nose forces the patient to seek relief.

DIAGNOSIS.

A Patient has come before us complaining of a discharge of matter from the nose. On examination, it will be noticed that there is pus oozing from under the anterior extremity of the middle turbinate on its outer side and filling the middle meatus. If it is mopped away with cotton wool more will be seen to follow in the same direction. The nasal mucous membrane will be seen to be pale and œdematous, often markedly so, and in several cases the origin of the pus will only be seen on removing one or more nasal polypi. There is no ulceration of the nasal mucous membrane to be seen. There are no evidences of syphilis, Tubercle or Malignant disease. The patient is not a child and consequently not subject to the purulent rhinitis of childhood. No foreign body can be detected in the nose and nasal diphtheria can easily be eliminated. In such a case, we must suppose the purulent discharge to come from one or more of the sinuses. If the patient furthermore give us a history such as I have previously sketched, we can fairly well presume the source to be suppuration in the antrum. This would be rendered more certain, if a reappearance of the pus takes place, when, the nasal fossæ having been made sufficiently clear and the pus mopped away, the patient has been instructed to lie on a couch with the head down and to the opposite side from which the discharge comes.

Occasionally, on percussion over the antrum, dullness more or less marked can be made out when pus is present in it but this is of doubtful value. More important is a feeling of pain or a sensation, as if the cheek were wooden, which is often experienced by the patient on percussion over the malar bone. Succussion of the antrum has been tried; but I should consider it as of no value owing to the size of the cavity involved and the fact that we would probably have it almost quite filled up with the pus; conditions which would go against the production of the succussion sound.

What is known as intra-oral illumination is in some cases of great value; but there are so many conditions, which may interfere with the results, that as a diagnostic method it is uncertain.

This aid to diagnosis was put forward by Voltolini but the method was improved by Heryng. A small electric lamp suitably mounted is placed within the mouth of the patient, the lips being firmly closed. The room is darkened and the heads of both observer and patient are covered with a dark cloth. The Electric current is turned on and if the antrum be healthy, the face will be illuminated as high as the orbital ridge. The absence of or marked diminution in this translucency constitutes the element of differential diagnosis. Illumination by the electric light has however proved disappointing and misleading. In one of my cases, that of Phillip Connor it was used and gave

on both sides marked diminution of the translucency but in only one antrum was there pus found on drilling into the cavity.

"Rualt has well remarked, having on one occasion been disappointed not to find pus in a case where transillumination showed a beautiful sub-orbital umbra, we can have opacity without empyema, but we cannot have empyema without opacity. Probably if there be not empyema in such a case, there is some other intra antral disease which accounts for the umbra."¹

Exploration of the antrum itself forms a much more valuable means of diagnosis. It can be carried out without any risk; is a comparatively simple test and is free from any objection. Schmidt advises puncture with an aspirating syringe through the internal wall of the antrum in the inferior meatus. Mickulicz and Thornwald advise puncture in the same region but in addition they syringe out the cavity, through the opening thus made to observe whether pus comes from the neighbourhood of the ostium maxillare.² By far the best method and one which at the same time may be of use in treatment, is puncture through the canine fossa or if the teeth are carious, through the alveolus, the first or second molar tooth both having been extracted. Through this puncture the antrum can be syringed out and observation made as to pus being present.

(1) Lennox Brown, Diseases of Throat, etc. 4th ed. p. 629.

(2) As quoted by Lennox Brown.

TREATMENT.

The treatment of acute inflammation of the antrum differs in no respect from that of acute rhinitis of which it is the accompaniment.

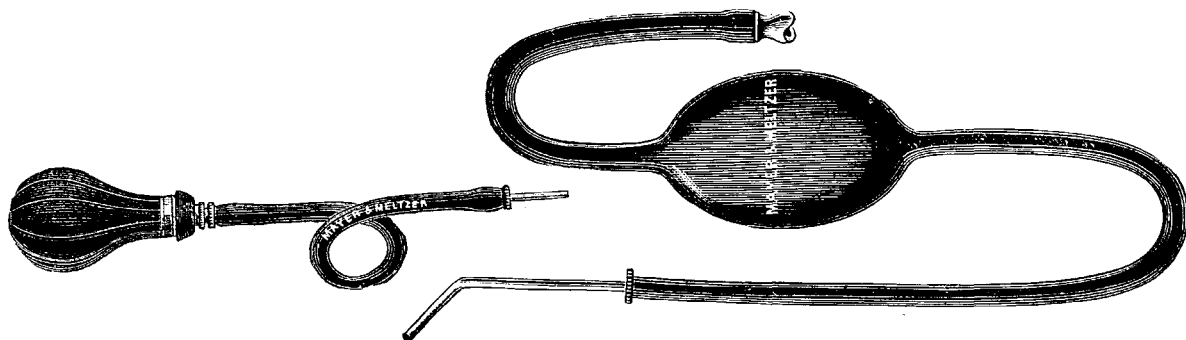
The use of a mild sedative lotion such as Boracic acid gr.x. ad. 1 oz. or Boroglyceride gr. 20 or 30 to the ounce; Ferriers' snuff of Bismuth and Morphia; or a powder consisting of Pulv. Belladonna fo , grs, 20. Morphia Sulph. grs. 2. Pulv, Gum acacia $\frac{1}{2}$ oz. insufflated into the nose will usually cure the rhinitis and so free the opening into the sinus. If there is much pain Cocaine Hydrochlorate a 10 % solution on cotton wool will give great relief. With the subsidence of the nasal trouble the mucous membrane of the antrum usually regains its normal condition.

In chronic cases, the main feature in the treatment lies in the production of efficient drainage into the nostril, the making of a free opening into the antrum, and the thorough cleansing of the cavity. If the disease has its origin in dental caries, the teeth should first of all be extracted. If due to nasal polypi, chronic rhinitis, hypertrophic or atrophic, or other nasal disease, these conditions should be as far as possible remedied; our object being to produce thorough patency in the middle meatus and so free the ostium maxillare.

The best method of opening into the antrum is that through the alveolus, the first or second molar tooth having been extracted, or through the canine fossa where these are healthy. The drill which answers best is one figured beneath. The diameter of the drill is $\frac{1}{8}$ of an inch and by means of the screw on its stem the perforating distance can be regulated.



After the cavity has been drilled either a Hovell's or MacDonald's antrum syringe can be used to wash out the cavity.



The lotions most useful for the washing out of the antrum are weak antiseptics; e.g. permanganate of potash, sanitas or Listerine. In some cases weak astringents are useful. After washing out a spiral wire tube of silver (Ellis) with a flange at its one end is inserted into the antrum. This can be

removed daily or oftener if necessary, to allow of the antrum being syringed, and while keeping the opening patent also provides for a certain amount of drainage.

While I consider this method of most value; there has been a considerable difference of opinion as to the best means of treating suppuration in the antrum. I merely intend to indicate the various methods which have been and are employed.

Hunter in 1771 advocated opening the antral cavity through the inferior meatus. This is also the German method as put forward by Miculicz and Krause. Hartman and Michel advise what they term local medication and the thorough cleansing of the nose by forcing currents of medicated air through it.¹

Storck also advocates local treatment.²

The retention of the Ellis tube and the irrigation of the cavity will depend upon the duration of the discharge. In some cases of long standing suppuration, it will be found necessary to make a more thorough exploration of the cavity. In order to do this an incision is made through the gingivo - labial - mucous membrane, semi-circular in shape, with its convexity downwards and in such a way that the flap thus marked out when elevated from the bone freely exposes the canine fossa. The bone is then removed in an upward and backward direction by a $\frac{1}{2}$ inch

(1) As quoted by MacDonald; Disease of the nose P. 185.

(2) As quoted by Bosworth; Disease of the nose & Naso-pharynx
(P. 475.)

trephine or by chisel and mallet. The lower edge of this opening being on a level with the upper margin of the alveolus. Through the opening thus made the cavity of the antrum can be freely explored, and granulations and Polypi removed by the sharp spoon. Hemorrhage as a rule is easily checked. The cavity is then packed with strips of iodoform gauze, these being changed daily until a permanent opening remains. This usually takes place in a month or six weeks.

PROGNOSIS.

An acute catarrhal inflammation of the antrum probably always results in resolution, chronic disease rarely if ever yields except to treatment. Some of those cases may go on for years, and apart from the inconvenience caused by the discharge and some impairment of general health cause no danger to life.

S U P P U R A T I O N

in the

ETHMOIDAL CELLS

=====

Suppuration in the Ethmoidal cells, whether it takes place as the accompaniment of an acute Rhinitis, or independently, due to the blocking of the infundibulum and the hiatus semilunaris, or as the result of injury and the consequent retention and decomposition of the discharges, is of more serious import. As I have already stated, (see Etiology) the mischief tends to spread from cell to cell, these getting filled up with polypi or polypoid mucous membrane and the bony laminae undergoing distension and absorption. Thus we may have the disease spreading by direct extension towards the orbit on the one hand and the anterior fossa of the skull on the other. As a result further of the distension of the cells, and the formation of nasal polypus which sooner or later follows in all these cases, we get Empyema of the Antrum and Frontal sinus associated with the suppuration in the Ethmoidal cells.

SYMPTOMATOLOGY

The usual history of an acute catarrh of the Ethmoid cells is, that after feelings of slight malaise and a feeling of stuffiness in the nose, and more especially in the lower frontal region, the patient gets an attack of severe neuralgic pain situated in the frontal and supra orbital regions and also sometimes across the bridge of the nose. This pain after lasting one or two days is relieved by a flow of pus taking place from the nose, and may entirely cease or with the recurrence of colds in the head, may pass on to the chronic condition. In this, the chief symptoms are the intermittent discharge of pus from the nose and the neuralgic pains in the forehead which get more and more severe as the disease progresses and may even spread over the face; and which get alternately better or worse as the discharge finds exit from or accumulates in the cells. The nose soon gets blocked up; at first a mere feeling of stuffiness being experienced, due to the lateral distension of the cells and the consequent obstruction of the superior meatus and to a slight degree the middle meatus of the nose. Later the nose gets quite blocked as the polypoid mucous membrane within the cells, gets "crowded out", and makes its appearance in the meatus as tiny polypoid buds which ultimately develop into

true nasal polypi, at the same time the mucous membrane over the middle turbinate has probably become polypoid or polypi have formed from it.

As a further result of the distension of the cells and a pressing out of the os-planum a bulging of the eye on the affected side may occur, even early in the disease. More frequently, a dull aching pain at the back of the eye or a feeling of tenseness within the orbit are the only symptoms which call attention to the encroachment on its cavity. Occasionally in the acute attack there is some redness and swelling of the external parts over the bridge of the nose and at the inner canthus of the eye.

=====

DIAGNOSIS

On examination, pus will be found oozing from under the anterior extremity of the middle turbinate on its outer side and filling the middle meatus. If the anterior cells only are involved, pus will probably be observed only in this situation; but with a post-rhinoscopic mirror, it will be seen issuing from the superior meatus as well, if the disease has spread to the posterior cells.

The mucous membrane over the middle turbinate will be seen swollen, pale and œdematous and even polypoid. True nasal polypi may be present and on removal these will be found to have their origin high up in the infundibulum at the anterior end of the hiatus semilunaris. The anterior extremity of the middle turbinate may be found much swollen and forming a bony cyst, on removal of which it will be found lined with polypoid mucous membrane or even containing small polypi.

On clearing the nasal passages, the middle turbinate will be found much swollen and pressed close against the septum so as to occlude the upper portion of the middle and the whole of the superior meatus.

There will not be marked increase in the amount of the discharge on holding the head forward, as in the case of the antrum;

but the patient may find it come away more abundantly in the morning, on getting up. The erect position favours the flow of the discharge from the ethmoidal cells as well as from the other sinuses, except the antrum, where it somewhat checks the flow.

The nature, situation and deep seated character of the pain, the swelling of the turbinate, and more especially the presence of exophthalmos, would, apart from the situation of the pus altogether, be our surest guides to suppuration in the Ethmoidal cells.

TREATMENT.

The main element in the treatment of suppuration in the Ethmoidal cells is in the thorough disinfection and cleansing of the nasal cavities and the sinuses themselves. In acute cases and even in some chronic cases probably all that will be required is the use of some sedative cleansing lotion, e.g. Solution of Boroglyceride grs. 60 to the o Boric acid gr. \bar{X} to the o . or even the ordinary alkaline lotion consisting of

Sodæ Bicarb.

Sodæ Biborat $\frac{\bar{a}\bar{a}}$ grs. V

Acid Carbolie grs. 2

Water to 1 oz.

In most cases, however, there will be the necessity for surgical interference. If there are polypi present, these must be removed. If hypertrophic rhinitis this must be remedied by the judicious use of the cauterly or the cold snare. If the anterior end of the turbinate is much hypertrophied this must be removed. In some cases this would suffice to render the openings into the sinuses sufficiently patent to provide for free drainage and the efficient cleansing of the cells. In the majority of cases, however, some more drastic treatment must be

pursued. The anterior end of the middle turbinate or even a greater portion of it must be removed and the partitions between the cells broken down. This may be accomplished by means of a probe, but by far the best way is to gradually nibble away the bony walls by means of a pair of cutting forceps with handles bent at more or less obtuse angle. (Symons punch-forceps.)

The ethmoid cells can thus be opened up and scraped out with a curette. Sometimes after opening up and scraping, judicious packing with small strips of gauze will help to keep the mucous membrane under control and prevent over free granulation. In most cases, however, the further use of simple cleansing lotions and the occasional use of the forceps or the galvano-cautery will be sufficient to promote recovery.

One of the best methods of irrigating the ethmoidal cells is that of Dr. MacDonald. He states, "By allowing the head to hang backwards over the end of a couch, so as to assume an in-

verted position, it is possible to fill up completely the nasal cavities with fluid. After a little practice a patient will be able to keep his head in this position for fifteen or twenty minutes at a time, although it always entails more or less headache afterwards." In this method he states that he has cured a case that had resisted the ordinary lines of treatment.¹

Schech² has advised more radical treatment, viz., the splitting open of the external nose; but for various reasons this method of treatment would not lend itself to favour until at any rate all other methods had signally failed to produce relief, not necessarily a cure.

-
1. Vide British Medical Journal, Dec. 15th. 1894, p. 1359.
 2. As quoted by Bosworth, Diseases of the Nose and Throat. Vo.. I. p. 485.

PROGNOSIS.

The large majority of cases due to catarrhal inflammation speedily end in resolution, chronic cases, however, are exceedingly liable to resist treatment for a considerable time owing to the difficulty there is, in completely laying open the cells and producing free drainage. If, however, the disease confines itself to the Ethmoidal cells there is no immediate danger to life but there is always the possibility to be borne in mind, of its spreading to neighbouring cavities, to the orbit and also of setting up the grave conditions of septic meningitis and cerebral abscess.

S U P P U R A T I O N

in the

FRONTAL SINUS

Acute suppurative catarrh of the Frontal sinus is a comparatively frequent accompaniment of acute rhinitis; perhaps more so than in the other sinuses, judging from the symptoms complained of in most cases of "cold in the head". Empyema of the sinus is, however, rare: and when it does occur there is usually well marked nasal trouble and often suppuration in one or more of the other accessory cavities. The probable reason of its rarity is to be found in the morphological difference between its opening and those of the other sinuses. The opening into it is situated at its most dependent part and also high up in the nose and anterior in the hiatus semilunaris. The openings into the anterior and posterior ethmoidal cells, and the antrum are situated laterally and are thus more easily occluded.

SYMPTOMATOLOGY

The chief symptoms of the acute stage are a feeling of stuffiness in the nose accompanied by severe headache of a boring character referred to the root of the nose, the frontal region and the supra-orbital ridge. The pain is usually intermittent and is increased by any effort or by the use of stimulants and is often accompanied by a feeling of nausea; or even sickness may be present. Sometimes there is redness and swelling over the frontal eminence; and pain on percussion or on pressure over the upper margin of the orbit is frequently elicited. The pain is usually one-sided, but may radiate well over that side. As the discharge accumulates, the pain increases in intensity but is quickly relieved when exit is given to the discharge; or on resolution taking place, in the acute catarrhal condition of the nasal mucous membrane.

In the chronic condition, a dull heavy headache passing into an acute lancinating pain in the forehead and over the eye, as the discharge accumulates in the sinus, is the most prominent symptom. It is usually intermittent in character.

So long as the discharge gets free exit this may be the only symptom but when the canal gets closed the pain increases in intensity, swelling and redness may appear, as previously

stated, over the frontal region and even an abscess may form at the root of the nose and inner angle of the eye, pus having made its way through at this point. Occasionally the pus makes its way through the posterior wall and sets up purulent meningitis or even cerebral abscess, with their attendant symptoms.

DIAGNOSIS.

Pus coming from high up in the infundibulum together with symptoms such as I have described would probably point to suppuration in the Frontal sinus. In most cases, however, we ought to make sure that the antrum is not involved, by exploratory puncture or otherwise. Sometimes a probe suitably bent or an Eustachian catheter can be passed into the sinus through the infundibulum. If this be followed by a flow of pus on withdrawal or pus be syringed from it, diagnosis would be almost certain.

TREATMENT.

In acute cases all that will be required is the use of a weak antiseptic solution to syringe the nose and the use of Ferrier's snuff if the pain is severe. As the nasal catarrh undergoes resolution the symptoms will subside.

In chronic cases, the treatment is the same as in the case of the other sinuses; viz., the thorough cleansing and disinfection of the nasal passages and the sinus itself after free


drainage from that cavity has been provided. If polypi or hypertrophied mucous membrane be present, this must be removed and the passage in the infundibulum thoroughly cleared. If the middle turbinate be enlarged it may be necessary to remove more or less of its anterior end and in most instances this will be sufficient to allow of a free irrigation of the cavity. In some cases, however, an opening must be made through the bony wall of the sinus to provide efficient drainage. The eyebrow is shaved and the parts thoroughly cleansed. An incision is then made from the root of the nose outwards along the lower border of the supra-orbital ridge for about three quarters of an inch. This must stop short of the supra-orbital notch. The flap is elevated upwards and by means of a quarter inch trephine or the chisel and mallet an opening is made into the sinus. The polypoid mucous membrane is curetted away and a rubber drainage tube is inserted through the infundibulum into the nose. Through this the cavity and the nose can be well irrigated once or twice daily, depending on the amount of the discharge. When the parts are sufficiently healed, usually in about three weeks, the rubber tube is replaced by one of silver of the following shape

The patient can readily remove this and syringe out the sinus for himself. Very good results have followed on this operation. When suppuration has ceased the silver tube can be removed and the wound quickly heals. There is no appreciable scar when the eyebrow has grown again.

PROGNOSIS AND COURSE.

If the source of the suppuration has been recognised and treated early, the course of the disease is usually towards recovery. There is no danger to life. If, on the other hand, suppuration has gone on for some time and blocking in of the discharge takes place, we may have the formation of abscess, pointing at the inner angle of the orbit; or even the infection of the cranial cavity giving rise to the grave conditions of septic meningitis and cerebral abscess.

S U P P U R A T I O N
in the
SPHENOIDAL SINUS.



That catarrhal inflammation within the sphenoidal sinus takes place is probable but symptoms pointing to it are usually wanting. This is probably due to the fact that for anatomical reasons, the opening into it is less liable to be blocked up than the openings into the other sinuses. When chronic suppuration, however, has taken place we can get definite symptoms presenting themselves. I have only met with one case apart from necropsy; and for it I am especially indebted to Dr. Bond, one of our staff who brought it under my notice. I have given a short account of it among the cases. Probably many cases of so-called post-nasal catarrh with purulent discharge are in reality due to sphenoidal sinus trouble.

SYMPTOMATOLOGY.

The interrupted flow of foetid pus, sometimes mixed with a considerable amount of mucous into the nose and the post-nasal space may be the only symptom if the opening of the sinus into the superior meatus is free. If on the other hand this gets closed up, there is also an intense pain present in the deeper parts of the head and the nape of the neck.

In some cases this pain is neuralgic in character involving all the branches of the trigeminus, and the dental branches of the superior maxillary have also been the seat of neuralgia. Ocular symptoms have also occurred, optic neuritis, exophthalmos, and amaurosis, as cited by Bosworth.¹

DIAGNOSIS.

Discharge of pus from the nose more especially into the naso-pharynx, which on posterior rhinoscopic examination was seen to be coming from the superior meatus, usually on one side, would indicate suppuration in either the sphenoidal sinus or the posterior ethmoidal cells. Associated with the deep seated pain such as I have mentioned, one would presume the sphenoidal sinus to be the seat of the discharge. In the case of the posterior ethmoidal cells, there would probably also be symptoms indicating disease in the anterior cells and in the absence of this, diagnosis of sphenoidal suppuration would be strengthened

1. Bosworth: Diseases of the Nose and Throat. p. 487-488.

Further diagnostic evidence would be furnished by the results of pressure on the cranial nerves as previously indicated

Sometimes a straight catheter can be passed into the sinus and pus washed away as in the case quoted.

TREATMENT

The treatment in this as in the other sinuses consists in the thorough cleansing of and the providing of efficient drainage from the cavity. As I have stated, the cavity can sometimes be syringed out; but in the majority of cases this cannot be accomplished. Operative treatment is very difficult and even dangerous. Sometimes the opening can be reached and enlarged by a probe or a curette passed through the nostril and cautiously manipulated. Schaeffer and Bronner have thus gained access to the cavity.¹

In the majority of cases we must rely on the use of weak antiseptic lotions carefully syringed into the nostril in the direction of the opening.

1. As quoted by Bosworth: p. 491.

PROGNOSIS.

The prognosis of chronic suppurative inflammation within the sphenoidal sinus is very grave, owing to the difficulty experienced in the thorough cleansing of the cavity. In my case, the careful use of lotions has evidently effected a cure, at any rate, marked benefit has followed.

If the suppuration continue long it is apt to set up bony necrosis and so pass towards the cavernous sinus, resulting in septic meningitis or cerebral abscess.

C A S E I.

Empyema of Right maxillary Antrum: following Acute Rhinitis.

J - R - . Age 27. Female. Jan. 10. 1895. Attended hospital complaining of profuse discharge from the right nostril and down the back of the throat, four years duration.

In 1891, she had a severe "cold in the head" accompanied by Right facial neuralgia, as the pain passed off she had profuse yellow discharge from the nose, the discharge having previously been watery. This lasted about six weeks, and got better. Since that time she has had constant colds in the head, and lately the discharge has got continuous. Her right nostril gets stopped up, she has aching pain in the right cheek, and then profuse discharge.

She has never had polypi.

She has slight hypertrophy of Right middle turbinate. Pus present in middle meatus; and flows away more freely when she is in the recumbent position. Her teeth are not good, including the right upper molars.

C A S E II.

Empyema of Left maxillary Antrum and Hypertrophic Rhinitis.

Ellen Henley. Age 23. Female. June 15. 1895. Attended hospital complaining of discharge down the back of the throat; 9 months duration.

At first she noticed that the left side of the nose got stopped up. This continued for a day or two, and then there was a discharge of "congested blood" from that side. Had numbed pain round the left eye and she states that her eye got quite swollen. A fortnight afterwards had a second attack after which she had the discharge daily. She uses 3-4 handkerchiefs a day. Has pain in face when she bends forwards and in that position the discharge comes away more freely. She gets a deep seated pain in the left temporal region at times.

Has never suffered with toothache and teeth of upper jaw good.

21 months ago got suddenly right facial paralysis, but otherwise her health has been good.

Considerable pus present in left nostril, inferior and middle meati. On mopping dry it is seen to come from outer edge of middle turbinate. Discharge in quantity in the naso-

pharynx now marked left Pain on percussion beneath left eye. There is marked hypertrophy of both the inferior and middle turbinates on the left side. The mucous membrane over the left middle turbinate is much polypoid, and gives the appearance of a double turbinate. It is pressed down against septum and is much bulging outwards.

C A S E III.

Empyema of Right Maxillary Antrum.-

F.-O.B. Age 32. Female. July 1894. Admitted to hospital with constant discharge from the nose, three or four years duration.

Began with a severe cold in the head, after which she was constantly getting colds. The nose got frequently stopped up. Gradually the discharge got more and more persistent.

She has frequent pain under the right eye of a deep seated character and close along the frontal ridge.

Much pus coming down from outer side of Right middle turbinate. There is marked hypertrophy of turbinates. Teeth of upper jaw good. General health has always been fairly good.

An incision was made over the upper alveolar margin and above the molar teeth, semilunar with its convexity downwards. The flap was elevated and the antrum opened with a half inch trephine. Considerable amount of pus and mucous membrane much polypoid. This was scraped out. The cavity was dusted with Iodoform and packed. This was changed frequently.

Almost quite well and ceased to attend. October 1894.

C A S E IV.

Empyema of Left maxillary Antrum: Nasal Polypi.

B - I.- Age 18. Female. August 1893. Had attended hospital with Nasal Polypi and discharge from the nose in 1882. The polypi had been removed but the discharge continued from both sides of the nose. It came on two or three years previously with stoppage up of the nose.

Now she has much discharge from both sides of the nose but, not much down the naso-pharynx. It is greenish in colour. She uses three to four handkerchiefs a day. Gets offensive smell in the nose at times. The discharge comes away more freely on stooping. Has been subject to headaches, starting from the top of the nose across the forehead.

She has never suffered with her teeth.

September 18. 1893. Left antrum drilled, much pus; as also Right antrum, but no result.

May 13. 1895. Has kept antrum constantly irrigated but pus still continues. Opened with large opening through the canine fossa and packed.

July 9. 1895. Still slight discharge from Right side, none left.

No pain, no headache. Polypi remains absent.

C A S E V.

Empyema of Left maxillary antrum: following Influenza.-

E - P - ,Age 18. Female. June 19. 1895. Attended hospital complaining of constant discharge from and stoppage up of left nostril of three months duration. She had an attack of Influenza immediately previously and after that ,seemed as if she had a constant cold in the head. Has not suffered from headaches, pain in the face. The discharge was thick and yellow and she used three to four handkerchiefs daily. Has always had bad teeth:

There is much pus in left nostril. The inferior turbinate left is small: there is a large polypus present growing from the outer side of the middle turbinate. The septum is deflected to the left.

There is some atrophy of both inferior and middle turbinates on the right side.

On percussion, she states that the left cheek feels harder than the Right.

C A S E VI.

Right maxillary Antrum Empyema: Dental caries.

S - K - . Age 55. Female. Attended hospital May 9th. 1892 on account of pain in the head, bad smell and discharge from nose on and off for seven years. The discharge came from the right side only, was greenish yellow in colour and she had to use about four handkerchiefs daily. The discharge did not seem to come more freely with the head held in any one position. She got "dreadful" pain over the right eye and also headaches severe. Her teeth were extensively carious and she had frequently suffered from alveolar abscesses.

There was no nasal trouble present except some chronic rhinitis sicca.

May 9. 1892 Right antrum drilled, after extraction of teeth and much pus.

February 5. 1895. Tube left out.

Present condition: very little discharge down the back of the throat: no pain: headache (frontal) only occasionally.

C A S E VII.

Empyema of Right maxillary antrum: following on specific Rhinitis

F - D - , Age 38. Male. June 1894. Attended hospital complaining of constant discharge of thin yellow offensive matter from the nose, some weeks duration: he had previously attended the hospital with ulceration of the nostril, tertiary syphilis; but has ceased attending for some time.

The discharge comes away from the right side of the nostril and more freely when he holds his head down. It has a very offensive smell. He has never had any pain although he sometimes suffers with vertex headaches at night. He has never had polypi, and teeth have always been good.

He has marked atrophic rhinitis with the mucous membrane of the turbinate much furrowed. Considerable pus in Right nostril. Comes away from outer side of turbinate, after mopping away and with head held forward.

Antrum drilled and tube inserted.

Present condition: Atrophic rhinitis: no pus in antrum.

C A S E VIII.

Acute Ethmoiditis:

T - H - , Age 21. Male. August 13. 1895. Has had constant purulent discharge from left nostril for twelve months Always suffered with what he thought to be colds in the head. Neuralgic pains in face and stoppage up of the nose. The pain was always worse in the nose when the discharge ceased.

Three days ago he began to have pains in the nose, across the bridge of the nose and deep seated pains in head. The left nostril then began to swell up and he got a sensation of fulness in the left eye. Discharge almost nil last two days. Nose is much swollen: outer wall of nose bulging in so as to press the inferior turbinate against septum. Part of the swelling of the inferior turbinate goes down under cocaine. The middle turbinate is much swollen and pressed against the septum There is swelling, redness and some oedema of nose over nasal bone left. Some amount of pus present in middle and inferior meati . Antrum explored - no pus.

August 23. 1895. with the use of Boracic lotion for the nose, the swelling of the turbinate has subsided, and there has been profuse discharge with a relief of the symptoms.

C A S E IX.

Ethmoid Suppuration

H - M - , Age 16. Male. January 25th. 1895. Admitted with stoppage of the nostrils of three months duration. Has had discharge from the left nostril off and on for two or three years. About three months ago he noticed that his nose got stopped up first on one side and then on the other.

No pain in the nose.

About the same time he noticed that when he blew his nose there was a discharge of yellow matter from both sides of nose - he thinks.

Never had it back of throat. No offensive smell. No disagreeable taste in mouth.

Both inferior turbinates are somewhat enlarged.

Right middle turbinate closely pressed against septum. Mucous membrane somewhat polypoid. Small polypus growing from outer side of it anteriorly.

Left: Pus in middle meatus and coming down from outer side of middle turbinate. The middle turbinate presents "cleavage".

The inner portion with the bone is pressed against the septum while outside it there is what appears to be a second mid-turbinate, firm and with polypoid mucous membrane.

Post-nasal thickening slight.

Speaks with a markedly nasal voice.

Teeth good.

No headaches.

No pain on percussion either over frontal or malar regions.

C A S E X.

Suppuration in Ethmoidal Cells: Nasal Polypi: Right
Maxillary Antrum.

Mrs. H - Age 23. May 22. 1894. Admitted with profuse discharge from nose and down back of throat since twelve years of age. Right side always the worst.

Also intense frontal headache off and on for the same length of time.

Previous to 12 years of age had suffered with frequent colds in the head accompanied by headache.

She seemed to get gradually worse and then the discharge came on. The headache she had more or less always.

Went to London Hospital and attended Dr. Woakes for two years.

Had her nose burnt, off and on, about every three weeks for the two years.

She thought she fely better and ceased to attend. But six months afterwards she felt that her nose was getting stopped so that she could not breathe through it. Went to St. Thomas's where she had a large polypus removed from the left side. She did not attend more than one month, feeling better. Twelve months after began to get stopped up and discharge got worse. She then

came on to the hospital here - nine months ago.

Had several polypi removed from both sides at that time. No difference in the quantity of discharge or in the headache.

Five months ago had Right Antrum opened. Almost no discharge from this: tubes removed after one month.

In November had Left Antrum opened. No discharge. Tube left out in one week:

Had had pain across bridge of nose between eyes and both cheeks. This has only been noticed since she had the polypi removed nine months ago:

Her headache always began between the eyes and thence spread all across the forehead.

Had Scarlatina when 10 years of age. No other illness except English cholera at four years of age.

No history of injury to nose.

Nasal system deflected to left, especially the upper and posterior portion: slight deflection to Right anteriorly:

Right middle turbinate pressing against septum. Polypoid mucous membrane: Right inferior turbinate enlarged and polypoid

Left middle turbinate polypoid: Left inferior turbinate large.

Pus oozing from both sides of both middle turbinates: i.e. in the middle meatus and towards superior meatus:

Some post-nasal ethmoids.

No enlargement of the turbinate posteriorly: considerable
pus in naso-pharynx.

Some pharyngitis.

Had frontal sinus explored; no pus.

C A S E X I .

Suppuration in Ethmoidal Cells and Frontal Sinus.

L - R - : Age 23. Female. Admitted with profuse discharge from the nose and down the back of throat, of five years duration.

Got a blow on the nose and after it she found that the nose got very swollen, more marked on the right side. She had no bleeding from the nose at the time and no sign of bruising at the time. She thinks it was three or four days after the blow when the swelling was noticed. At this time she got some yellow discharge from the nose, principally the right side.

She went to Westminster Hospital and had it burnt, and some polypi removed. Attended there four months and then she went to St. Thomas's. Attended there 18 months and had only lotions to use but had polypi removed on three occasions. Went then to Bartholomew's and had an operation performed under CHCL₃, both sides of nose. Was better for about two months and then got worse again. After that she had several pieces removed. Attended there nearly two years and was not much better. Came up to this Hospital six months ago and had polypi removed: One month later under CHCL₃, had antrum on both sides opened: was

better for a time. Ever since that time has had small pieces removed:

Previous to the blow on the nose it was never stopped up - could always breathe freely through it. But at the same time as she got the blow she had a bad cold in the head:

Two months previous to this she had had scarlet fever very bad.

Three years before this scarlet fever she had measles:

Since that time she has always been fairly well except for the discharge from the nose:

She has never had frontal headache and no pain over the maxilla. Had slight pain in left eye six months ago but this got better after her operation.

When the antrum was drilled the tubes were removed after three days as there was no discharge from them.

Considerable amount of pus in nose both sides.

Septum nasi deflected to the Right.

Right middle turbinate, polypoid mucous membrane, pressed close along septum: pus oozing by the side of it.

Right inferior turbinate has had a large piece of it removed

Left middle turbinate hypertrophied and polypoid. Large space between it and septum.

Left inferior turbinate normal size anteriorly: mucous membrane very polypoid posteriorly: posterior $\frac{1}{2}$

Pus high up and close to infundibulum small polypoid granulations from among which pus appears to ooze.

C A S E XII.

Acute Frontal Sinus:

H - U - , Age 69. Female. July 14. 1895. Admitted to hospital, complaining of intense pain in left side of forehead and feeling of stoppage up of nose; one weeks duration. One year ago had polypi removed and pieces from the middle turbinate, she had had constant discharge from the nose and pain in forehead off and on last five years. After the pain passed off there was marked increase in the amount of discharge. There is marked redness, swelling and bogginess over the left frontal region and much pain on percussion. On examination a considerable portion of the middle turbinate has been apparently removed. What remains is observed to have the mucus membrane over it much swollen and pressed close against the septum. There is pus coming down from the outer side. A probe can be passed upwards, to the region of the frontal sinus and is followed by pus on with drawal.

A Catheter was passed into the sinus and pus syringed out. She had an alkaline lotion to use for the nose, to which some Ext. Belladonæ was added.

July 22. 1895. Much better but a considerable discharge of pus. Swelling absent. Complains of tingling pains over

left side of head.

Present condition much improved, except as to discharge.

C A S E XIII

Suppuration in maxillary Antrum (both sides) and Frontal Sinus
left.

I - P - . Age 42. Male. September 16. 1893. Attended hospital complaining of discharge from, and polypi in nose, 18 years duration. He had had polypi removed frequently on previous occasions. He had a considerable amount of purulent discharge in both nostrils. After the removal of the polypi, the pus was found to come away more freely on bending the head forward. He had frequent pain across the nose and heaviness over the eye.

Occasionally pain was severe in the forehead.

September 25. 1893. The antrum on both sides was drilled and much pus washed out. Ellis' tubes were inserted and the cavities daily irrigated.

April 6. 1894. No pus in either antrum but much high up in nose on left side.

January 3. 1895. Frontal headaches and pain above nose have been much more severe. Still much discharge. The left frontal sinus opened and much pus evacuated. The mucus membrane was markedly polypoid.

Present condition, quite cured

C A S E XIV.

Frontal Sinus. Empyema : Suppuration in Sphenoidal Sinus.

Mrs S - Age 35. June 6 1895. Admitted to hospital complaining of constant discharge of purulent matter from the nose and down back of throat, of two years duration; the discharge coming almost completely from the left side.

Sometime previously to two years ago, she had what she thought were recurrent attacks of cold in the head. The nose got stopped up, she got bad, frontal headaches and immediately following on these, profuse discharge from the nose. These began to get more frequent in their recurrence, and she felt a great heaviness in the head accompanied by occipital pain. Two years ago her nose got quite blocked up. She sometimes had pain beneath the left eye. Her frontal headaches began at a spot about $1\frac{1}{4}$ inches above the bridge of the nose on the left side and spread round to the inner Canthus of the left eye. She never suffered much from her teeth. Nine months she had several polypi removed from left nostril. The middle turbinate mucous membrane was curetted and polypoid portions removed on several occasions but the discharge continued. This was not increased by placing the head in any special position.

June 7. 1895. The antrum was drilled but no pus being present the left frontal sinus was opened with chisel and mallet.

Considerable pus present. The mucous was much polypoid. This was curetted and a rubber drainage tube inserted. The wound was healing well and there was very little discharge from the nose when on June 26th. 1895 her temperature rose, and she got redness and swelling round it.

This was apparently erysipelatous; and as a result an abscess of the Septum and over the bridge of the nose was formed. These were opened and the periosteum was found to be extensively separated from the bone.

She got much better, and remained so until July 17 1895, when her temperature again rose and she developed symptoms of Cerebral meningitis and died ten days later.

On autopsy a considerable amount of pus was present in both frontal sinuses. There was extensive acute necrosis of both the anterior and posterior wall. This had spread through on the right side to the inner table of the skull. There was much septic meningitis of the bone and a considerable accumulation of pus between the lobes of the cerebrum. The ethmoidal cells were healthy no pus in antrum but much in the sphenoidal sinus.

C A S E XV.

Suppuration in Sphenoidal Sinus.

D - I - Age 20. Female. Nov. 16. 1892. Attended hospital with profuse discharge from back of nose and stoppage up of nose, six months duration. She had suffered from constant colds in the head from childhood, the last six months discharge got constant, thick and yellow in the morning, and then white and sticky during the day. The discharge had sometimes an offensive smell but she had always a nauseous taste in the mouth. She suffered with constant deep seated pain in back of head. These were at times very sharp and accompanied by head aches across back of the head. There was some hypertrophy of the turbinate especially posteriorly.

On removal of this a probe guided in an upward and backward direction could be made to pass into the sphenoidal sinus and was followed by pus on withdrawal.

Name age & Date of Attendance	Nature of Complaint and duration	Discharge from one side of nose only or both and down back of the throat.	Discharge increased on holding the head in any one position	Colour of the discharge	Smell or nauseous taste in the mouth	Stops up eye of the nose.	Pain or headache or site of it.	Polypus or other nasal tumour	Bad Teeth	Colds in the head frequently	Duration of attendance Diagnosis Treatment & Present condition.
R - 7 - 35. Male May 1893	Difficulty in breathing through the nose and discharge. 4 years.	Left side only: not much down the back of the throat.	not noticed	Dark Yellow	Smell sometimes very bad: nauseous taste at times.	Frequently stopped up.	Heaviness about the eyes - principally beneath the lower eye.	Marked hypertrophic rhinitis. Cauterized etc.	Teeth bad.	Had colds in the head frequently.	1 year. Suppuration in left maxillary antrum; antrum drilled: turbinate cauterized & pieces removed. Very little discharge now: not discolored; no pain etc.
E - K - 24. Female. June 1893	Discharge from the nose. 4 years.	Left side only: and down the back of the throat.	not noticed.	Light Yellow.	Smell at times bad: not much nauseous taste in mouth.	Stopped up.	Pain in upper part of nose; across the bridge & accompanied by frequent neuralgic headaches over the eyes.	Polypus removed on several occasions.	Very bad.	Colds in the head for a very long time.	Suppuration in Ethmoidal Cells: ? Antrum. Antrum not drilled: Polypus removed & pieces of turbinate & much relief
F - M - 26. Male. Nov 1894.	Offensive discharge from and stoppage up of the nose. 1 year.	Left side only: and down the back of the throat.	When the head was held forward.	Yellow.	Bad Smell & nauseous taste.	Much stopped up.	Pain under & slightly over left eye.		Bad Teeth	Frequent colds in the head	8 months. Suppuration in left maxillary antrum: Antrum drilled. (left) now discharge very little; no pains; no headache and no stoppage of nose.
P - O.C. - 49 Male. 27. 2. 92.	Perennial discharge from the nose. Some years.	Both sides but more so right. not much down the back of the throat.	not noticed	Yellow		Much stopped up:	No marked pain at any time	Several polypus removed.	Teeth bad.		2 years. Suppuration in the Right maxillary antrum: nasal Polypus. Rt. antrum drilled - no discharge - no pain. V. slight discharge from the left nostril now.
R - S - 57 Female. 19. 9. 94.	Discharge from and stoppage up of the nose. 10 years.	Right side & down back of the throat.	Discharge much more free on leaning forward	Yellow.	Not bad smell but nauseous taste very bad.	Stopped up mostly at nights.	Pain over right eyebrow and very bad piddly headaches.	Many polypus removed.	Teeth bad.		8 months. Suppuration in the Right maxillary antrum: Polypus. July 1894. Antrum drilled Sept. 1894. Opened through the canine fossa. Much improved: very slight discharge: no pain etc.

Name Age & date of attendance	Nature of the Complaint & duration	Discharge from one side of nose into & down the back of the throat.	Discharge in bed or holding the head in any one position.	Color of the discharge	Smell or nauseous taste in the mouth	Stopped up of the nose	Pain or headache & site of it.	Polypus in nose, trouble.	Teeth bad	Cells in the head pusiness	Duration of illness Diagnosis nature of treatment & Present condition
M - B - 16 Female 9-9-93.	Discharge from the nose and nasal polypus. 2 years.	Left side only.	Not noticed	Yellow		Frequently stopped up.	Pain in cheek (left) at times.	Several polypus removed at different times	Bad teeth		10 months Suppuration in the deep maxillary antrum: Polypus antrum drilled: Polypus removed Frequently: No Polypus in pus since July 1894.
J - K - 37 Male Oct 1892.	Discharge from the nose. 6 years.	Both sides: at first the right; also down the back of the throat.	Discharge was very free when the head was held down.	Yellow	Bad smell and nauseous taste in the mouth	Very much stopped up before the discharge.	Pain in the eyes: "Felt as if the forehead was just going to open."	Hypertrophic Rhinitis	Teeth bad	Constant cells in the head.	2 years. Suppuration in both maxillary antra. March 1893 Antrum drilled on both sides. Teeth better till Jan 1895. Now very little discharge.
M - L - 46 Female June 1892.	Discharge from the nose. Some years.	Especially the left side and down the back of the throat.	In the daytime, when sitting, from the nose - at night, when lying down, from the back of the throat.	Yellow.	Bad smell rarely.	Much stopped up.	Pain in the left temple; bridge of the nose; eyes & back of the head accompanied by intense headache.	Polypus removed on several occasions.	-	-	3 years - Suppuration in Ethmoidal Cells and Left Maxillary Antrum: nasal Polypus. Left antrum drilled and Ethmoidal Cells opened up. Scarcely any discharge now no pain or headache.
Mrs. S - 25. Female Feb. 1893.	Discharge from the right side of the nose. 2 years.	Right side only and down the back of the throat.	When the head was bent back or forward, the discharge was increased.	Yellow	Bad smell and nauseous taste in the mouth.	Sometimes stopped up.	Pain across nose and under and above right eye. Side headaches Sometimes.	Several polypus removed.	-	Frequent cells in the head.	2 years. Suppuration in Ethmoidal Cells and R. Maxillary Antrum: nasal Polypus. Right antrum drilled and Ethmoidal Cells opened up. Now discharge much less: no pain: no headache.
J - P - 42 Male Sept. 1893	Discharge from the nose and polypus. 18 years.	Both sides but more especially the right also down the back of the throat.	When the head was held down.	Thick Yellow discharge	Bad smell Sometimes and nauseous taste in the mouth.	Constantly stopped up.	Pain in the forehead & intense heaviness over the eyes.	Numerous polypus removed	Teeth bad when younger.	Frequent cells in the head	18 months. Suppuration in both Maxillary Antra also Frontal sinuses: nasal Polypus: Both antra opened April 1894. R. antrum opened - coming from June 1895. Frontal sinuses opened. Now quite well.

Name age date of attendance	Nature of Complaint & duration	Discharge from one side of the nose or both & down the back of the throat.	Discharge increased on holding the head in any one position	Color of the discharge	Smell or nauseous taste in the mouth	Stopped up of the nose.	Pain or headache or site of.	Polypsi or other nasal growth.	Teeth bad	Colds in the head prevailing	Duration of attendance Diagnosis nature of treatment & Present condition.
L - R - 23 Female Sept 1893.	Profuse discharge from the nose. 5 years.	Both sides but more so the right. also down the back of the throat.	Not noticed	Yellow	Bad smell at times	Much stopped up.	Much pain over the nose and left eye Frontal headaches severe.	Numerous polypsi removed both sides.	?	Frequent colds in the head.	10 months. Suppuration in Ethmoidal Cells: ? Frontal sinuses. Antea drilled - no pus. Polypsi removed & Ethmoidal Cells opened into. Would not have operation in Frontal sinuses. Now much improved.
L - H - 23 Female June 1895.	Discharge from the nose & down the back of the throat. 9 months.	Left side only & back of the throat.	Discharge very much thicker when the head was held forward	Yellow.		Often stopped up.	Pain in left side of face and numb feeling over left eye: Headache in the temporal region.	Hypertrophic Rhinitis		Frequent colds in the head	4 months Suppuration in the Left Maxillary Antrum - Antea opened in the canine fossa Now quite well.
L - W - 20 Female Sept 1893.	Discharge from the nose. 4 years.	Both sides but more so the left. also down the back of the throat.	When the head was held down the discharge was more prof.	Yellow	Sometimes bad smell & nausea taste in the mouth in the morning.	Very often stopped up.	Pain in the left side of the head from the eye to the back of the head.	Polypsi removed on several occasions.		Colds in the head frequent	5 months. Suppuration in both Maxillary Sinuses. Both antea drilled 1894 antea opened in canine fossa. Slight discharge at times now - Pain - head occasional.
B - J - 18. Female Nov 1892.	Discharge from the nose and difficulty in breathing. 2-3 years.	Both sides: Very little down back of throat.	Discharge was increased on stooping down.	greenish yellow	at times bad smell	Much stopped up.	Pain in head & headache from the top of the nose across the forehead	Polypsi removed		Frequent.	2 years. Suppuration in the Left Maxillary Antrum: nasal Polypsi: ? Ethmoid. Right Sept 93. Left Antea drilled - pus Right no pus May 95. Left Antea opened Now no pus left side. Some pus Right.
L - W - 30. Female May 1895.	Discharge from the nose. Some years.	Right side only. also down the back of the throat.	Discharge more on holding the head forward.	Yellow		Frequently stopped up.	No marked pain			Very Bad.	5 months Suppuration in the Right Maxillary Antrum: Right Antea drilled. Almost no pus now.

Name Age + date of attendance	Nature of Complaint & duration.	Discharge from one Side of nose or both & down back of throat.	Discharge more profuse with head held in any position.	Color of the discharge	Bad smell in nose - nauseous taste in the mouth.	Stopping up of the nose.	Pain - headache & site of.	Polypos or nasal tumble.	Bad teeth	Colds in the head previous	Period of attendance Diagnosis & treatment Present condition.
Mrs. H — age 52. Female. Feb. 1895	Discharge from nose. 4 years.	Both sides but more especially the left. and down the back of the throat.	On holding the head forward	Yellow	no bad smell or nauseous taste in the mouth	much stopping up of the nose		Several Polypos removed both sides.	Just bad	Come on after a Succession of colds.	8 months. Suppuration in Right Maxillary Anterior: nasal polypos. Polypos removed. Left anterior opened through the canine fossa. Quite well.
Agnes B — age 42. Female. April 1895.	Chronic discharge from the nose. 9 years.	Both sides but more so Right. Also down the back of the throat.	on stopping or on getting her to lie in the recumbent position and on the left side.	Yellow.		much.	Supposed much from neuralgia especially on the right side: Worst headaches severe at times.	Several Polypos removed the last 6 years.	Just very bad.		6 months. Suppuration in Right Maxillary anterior: Polypos. Right anterior opened freely in canine fossa: Polypos removed. Discharge now almost ceased.
Lucy R — age 23 Female. May 1895.	Profuse discharge from nose and down the back of the throat. 5 years.	Both sides.	on bending head forward or on lying back	Yellow.		much.	Pain severe in Right eye & in the forehead.	Several Polypos removed.	Just bad.	Frequent colds in the head	5 Suppuration in Right Frontal Sinus, & Ethmoidal cells? Had both antra drilled but no pus present. Required to have frontal sinus opened. Condition just the same.
Joe — B — 52 Male March 1895	Discharge down the back of the throat. 20 years.	Right side only & back of throat.	much increased by bending forward	Yellow		Frequent stopping up of the nose.	Deep dull heavy feeling in head at times. Pain or pressure over Rt. cheek bone.	Polypos removed.	Just bad but come after nose tumble commenced		6 months. Suppuration in Right Maxillary Anterior. Anterior drilled now very little discharge.
Jessie R — age 27 Jan. 1895	Profuse discharge from Right nostril and down back of the throat. 4 years	Right only	on holding head forward.	Yellow.	at times bad smell.	much.	Pain in right cheek.		Just bad.	Several colds in the head at times.	3 months. Suppuration in Right Maxillary Anterior. Anterior drilled Quite well.

Name age & date of attendance	Nature of Complaint & duration	Discharge from one Side of nose or both and down back of the throat.	Discharge more free with head held in any one position.	Colour of discharge.	Smell or Nauseous Taste in mouth	Stoppage up of the nose.	Pain or headache and site of.	Polyppus or nasal tumble.	Bad teeth	Cold in the head. Previously	Period of attendance at Hospital: U Diagnosis: Treatment & Present Condition.
Thos. P — age 15. Male. July 1894	Discharge from and stoppage up of the nose 1 year.	Left side.	not noticed by himself. came away more free when he was placed in the recumbent position.	Yellow	Bad taste in mouth but no smell.	Frequently	No pain or headache.	Chr. Rhinitis	Just all good	always having cold in the head.	12 months: ? Suppuration in left maxillary antrum: His parents would not have him operated on. No improvement.
Mr. S — P — age 42 Female. March 1894.	Stoppage up of the nose and discharge. 6 years.	Principally the left side.	Came away more free when holding the head back.	Yellow.	No bad smell or taste.	Constant.	Pain in the left cheek & headache at top of the head.	Polyppi removed both sides.	Just bad.	Frequent cold in the head.	12 months: Suppuration in left maxillary antrum: nasal Polyppi: Polyppi removed and left antrum drilled. Dents well run.
Mary B — age 30 Female. July 1895.	Discharge from and stoppage up of the nose. 8 years.	Both sides but principally the left.	Not noticed.	Yellow		Very much	Some pain across the eyes; accompanied by neuralgic pains in the forehead & back of the head. Pains at rest of nose.	numerous polyppi removed since 1888	No bad teeth	Frequent cold in the head	3 months. Left antrum empyema: Suppuration in Ethmoidal cells: nasal Polyppi. Left antrum drilled — Ethmoidal cells opened up both sides: Much improved: Pain principally from ethmoidal cells right.
F — O'S. — age 32 Female July/94	Constant discharge from nose. 3 years.	Right side.	On holding the head forward	Yellow	Bad smell & nausea Taste in the mouth.	at times	Frequent pain in the R. eye, at inner angle of eye and along the frontal ridge. No headache	Hypertrophic rhinitis.	No bad teeth	Frequent.	4 months. Right maxillary antrum empyema. Rt. antrum opened in common proca. almost no discharge now.
J — K — age 37 Male. Feb 1895.	Purpish yellow discharge from nose and down the back of the throat. 6 years.	Both sides but more marked on the right.	on stooping or holding the head forward.	Yellow		Very much	No pain or headache complained of.	Polyppi		Frequently.	8 months. Suppuration in both maxillary antra: nasal Polyppi — Polyppi removed: Rt. antrum drilled. 1892. Left antrum drilled. March 1893 & Feb. 95. .. opened in common proca. Dents well run.

Name Age Date of attendance	Nature of Complaint and duration	Discharge from side of nose both and down throat.	Discharge runs free with head held in any one position	Color & Discharge	Smell or nauseous taste.	Stops up of nose	Pain or headache and site of.	Polypos or nasal tumor	Bad teeth	Old in head, previously.	Period of attendance. Diagnosis Nature of treatment Present condition.
Mrs. H — 24. Female. July 4, 1893	Pain in head: + Purpos discharge from nose and down back of throat. 12 years.	At first left side only: now both.	When stopping	Yellow	Bad Smell at times — nauseous taste in the morning.	Could not breathe through the nose.	Pain in the cheek bones: forehead and top of the head. Headaches frequent at top of head.	Polypos frequently extracted	Never bad till after nasal tumor removed	Reports.	Since July 1893. Unilateral suppuration: Polypos Antrum. Polypos removed. Antrum drilled: Frontal sinus opened: lower ethmoidal cells opened. No marked improvement except as to pain and headache.
Geo. B — 25. Mal. Xmas 1894.	Discharge from nose and down the back of the throat and bad smell in nose. 2 years.	Left side only & down back of throat.	Not noticed.	Yellow	at times bad smell	Yes.	No pain but deep seated frontal headache.	—	Yes	—	12 months Suppuration in left maxillary Antrum. Antrum drilled. Very little discharge from the stopping up of nose. No pain etc.
Mary G — 35 Female. May 1893	Stopping up of nose and discharge from nose. 2 years.	Both sides.	No.	Yellow	Yes & occasionally nauseous taste.	— Yes.	Fulness behind eyes and aching in eyes & forehead	Several polypos removed.	Bad. had all before last 14 years.	Yes.	6 months Suppuration in left maxillary Antrum. Antrum drilled. (left) Still slight discharge at times: no stopping up of nose: no polypos: no pain.
Geo — B — 40 Mal Fall 1895	Incessant nasal Catarrh 9 years	Both sides. and back of throat.	Drawing the chin in towards the neck increased the discharge	Yellow.	Yes bad smell & nauseous taste in the morning.	—	Pain behind the eyes & severe shooting pains over the top of the head and in the forehead.	Polypos removed.	Bad.	—	6 months. Suppuration in left maxillary Antrum. Antrum drilled. Great improvement Slight discharge at times.
Wm R — 40 Mal July 1894.	Nasal Catarrh and Polypos (18 months). 14 years.	Both sides. and back of the throat.	Not noticed	Pale Yellow.	Could not smell but had a salty taste in the morning.	Yes.	No pain or headache	Several polypos removed at different times.	Had always bad teeth.	14 years Summer & winter.	3-4 months Double maxillary Antrum Empyema Both antra drilled: itched — — Much improved.

Name, age & date of attendance	Nature of Complaint & duration.	Discharge from one side of nose or both & down back of the throat.	Discharge more profuse with head held in any one position	Coloring of the discharge	Smell or nausea or taste in mouth.	Stoppage up of nose.	Pain or headache and site of	Polyposis or nasal trouble	Bad Teeth	Colds in the head, previously	Period of attendance at the Hospital. Diagnosis, nature of treatment and Present condition.
Wm C — 35 Mch. Jan 1893.	Pain in the head. Blocking of the nostrils and discharge from nose & throat. 7 years duration	Right side & down back of throat.	When head was held forward.	Deep Yellow	Bad smell & slight & very little nausea taste.	Stung at night.	Pain over each eye and in R. cheek bone. Headache about temples.	Hypertrophic Rhinitis	Very bad.	Not often.	4 months. Suppuration in Maxillary Sinus, Right. Antrum drilled Very little discharge, at times no stoppage of nose; no pain; very seldom headaches.
Eliza B — 52 Female. Jan 1894.	Discharge from the nose and neuralgic pains in right temple. 2 years.	Right side & a good deal down back of throat.	More profuse when she lay down & threw her head back.	Yellow, "like discharge from a boil."	Very offensive to her at first. Nauseous taste.	Sometimes, very much.	Neuralgic pains in right temple, frequent. The eyes also ached.	Hypertrophic Rhinitis		Frequently after influenza & sinusitis.	1 month. Suppuration in Right Maxillary Antrum. Much improved after operation: but still a little discharge down the back of the throat. No pain: no head ache.
Miss A — 21 Female. Jan 1894.	Discharge from the nose & down throat. 6 months.	Both sides	Not noticed	Yellow	Offensive smell at times.	Very often the nose stopped up.	No pain:	Hypertrophic Rhinitis.		Often.	8 months: Suppuration in left Maxillary Antrum. Turbinates cauterized: Antrum drilled: Much improved: no discharge stoppage of nose occasionally.
Fred P — 21 Male. Jan 1893.	Unable to breathe through nose and discharge from nose and down the back of the throat. Several years duration	Both sides. also back of throat.	Not noticed.	Whitish Yellow.	Bad smell and nausea, taste in the morning.	Frequently	—	Had many polypi extracted.	Very bad teeth.	Very often had colds in the head.	10 weeks: Suppuration in Maxillary Antrum: Nasal Polypi. Polypi removed & antra drilled. Much better, but has slight discharge still.
Mary H — 19 Female. July 1895.	Discharge from the nose. 3 years.	Right side & down back of throat	When holding the head down.	Yellow	Bad smell in nose at times.	Sometimes	Pain down the nose, and the eye & neuralgic pains in forehead.		Bad	Sever since childhood	7 months: Suppuration in Right Maxillary Antrum. Would not have it operated on if not improved.

Name age & date of attendance	Nature of Complaint & duration.	Discharge from one side of nose or both.	Discharge increased on holding head in any one position.	Color of the discharge	Bad smell or nausea taste.	Stoppage up of nose	Pain or headache and site of.	Polypi or other nasal trouble	Bad teeth	Colds in the head previous	Duration of attack Diagnosis. Treatment & Present Condition.
7 - D - age 38 male Aug 1893	offensive discharge from the nose 18 months.	Left side only and down the back of the throat.	Increased when the head was held down.	Yellow	Very bad smell at times & nauseous taste in the mouth.	Sometimes stopped up.	No marked pain but headaches over the eyes almost constantly.	Atrophic Rhinitis: Sphilitic. Sphilitic 20 years previous.		Frequent colds in the head.	18 months Suppuration in the left Mucillary Antrum. Antrum drilled Mucel improved: a very little discharge at times.
M - H - 52 Female. Jan 1894.	Discharge from the nose. 2 years.	Both sides & sometimes down the back of the throat.	Not noticed.	Yellow	Bad smell at times.			Polypi removed on several occasions	Just bad.	Colds - the head constantly	Since Jan 1894 Suppuration in both Mucillary Sinuses: Polypi Jan 1894: Both antra drilled Jan 1894. Tube left out of right 7th Sept tube left out & opened - Laminaria Now quite well.
S - K - 55. Female March 1892	Pain in the head: Bad smell in & discharge from the nose. 7 years.	Right side & slightly down the back of the throat.	Not noticed	Yellow - greenish hue.	Bad smell & nausea taste.		Pain over the right eye and headaches from right eye to the back of the neck.	Chen Ulceritis.	Just bad.	Frequent colds in the head.	3 years. Suppuration in the Right Mucillary Antrum: Jan 1892. R ^t antrum drilled July 1895. Tube left out. Mucel improved: slight nasal-pharyngeal catarrh now.
H - V - 69 Female August 1895	Intense pain in left side of forehead: & stoppage up of the nose. Has discharge from the nose. (1 week) up to 5 years.	Discharge from the left side only. 5 years.	More marked when she gets up in the morning.	Yellow	Yes.	Does not get frequently stopped up.	Pain in left forehead triglyppanus all over left side of head Intense headaches. Pain on pressure in over frontal region. swelling & bossiness over frontal region.	Has had polypi removed. How much acute swelling of the mucous membrane of the mid- turbinat	Just bad	Frequent.	53 months. Acute Frontal Sinus Empyema: Catheter passed into infundibulum & pus washed out. Mucel relieved.
J - G - 31 Female Nov 22 nd 1894.	Discharge from the left nostril intense frontal headache. Discharge came on after scarlet fever when a child. Headache 2 years.	Discharge from both sides but more marked left also down the back of the throat.	On holding the head forward	Yellow	Bad smell & nausea taste at times.	More frequently stopped up.	Intense frontal pain & headache. Pain at back of the eyes. Pain usually begins at outer angle of eye.	Numerous polypi removed at different times.	Just bad	Frequent.	9 months. Frontal Sinus empyema : nasal Polypi. August 1894. Both antra drilled - no pus. Nov. 1894. Frontal Sinus opened small pus etc. Discharge almost nil but headache still at times.