

Robotic Transversus Abdominis Release (TAR): is it possible to offer minimally invasive surgery for abdominal wall complex defects?

Transversus Abdominis Release (TAR) Robótico: é possível oferecer cirurgia minimamente invasiva para os defeitos complexos da parede abdominal?

MARIA VITÓRIA FRANÇA DO AMARAL¹; JOSÉ RICARDO GUIMARÃES¹; PAULA VOLPE, TCBC-SP²; FLÁVIO MALCHER MARTINS DE OLIVEIRA, TCBC-RJ³; CARLOS EDUARDO DOMENE, TCBC-SP²; SÉRGIO ROLL, TCBC-SP⁴; LEANDRO TOTTI CAVAZZOLA, TCBC-RS¹.

ABSTRACT

We describe the preliminary national experience and the early results of the use of robotic surgery to perform the posterior separation of abdominal wall components by the Transversus Abdominis Release (TAR) technique for the correction of complex defects of the abdominal wall. We performed the procedures between 04/2/2015 and 06/15/2015 and the follow-up time was up to six months, with a minimum of two months. The mean surgical time was five hours and 40 minutes. Two patients required laparoscopic re-intervention, since one developed hernia by peritoneal migration of the mesh and one had mesh extrusion. The procedure proved to be technically feasible, with a still long surgical time. Considering the potential advantages of robotic surgery and those related to TAR and the results obtained when these two techniques are associated, we conclude that they seem to be a good option for the correction of complex abdominal wall defects.

Keywords: Robotics. Hernia, Abdominal. Minimally Invasive Surgical Procedures

INTRODUCTION

Abdominal hernias represent a major public health problem, as it is believed that about 10% to 15% of the world population has or will have ventral abdominal hernias throughout life and it is estimated that more than 20 million herniorrhaphies are performed annually worldwide^{1,2}. In addition, they are responsible for great morbidity, causing abdominal pain and discomfort resulting in dismissal from work and consequent economic loss, besides decrease in quality of life³.

The repair of abdominal hernias has been the object of study of many researchers due to its diversity in the form of presentation and its rate of relapse. Its recurrence rate is about 24% after the first repair, 35% after the second and 39% after the third⁴. However, this rate varies according to the technique used for correction.

Open surgery with suture closure was the first technique used and its recurrence rate reaches

more than 50%. This rate decreased considerably after the advent of meshes in the treatment of hernias, dropping to about 32% and, in selected cases, further reduced with the implementation of laparoscopy, with rates of 14 to 17%. Despite the notable reduction in recurrence rates of abdominal hernias with these advances, the search for new techniques and devices that could decrease them further continued, especially in the complex effects of the abdominal wall. The use of the component separation technique in the treatment of abdominal hernias attempts to minimize these indices, with reports of recurrence rates of 10 to 22%⁵.

There is no gold standard for treating all ventral hernias, since the hernia and patients' characteristics are very heterogeneous. For the correction of bulky defects in which there is loss of domicile, it is important to take the peculiarities presented by these hernias into consideration. In addition to reducing stress at the surgical site, it is also desired to restore the functionality of the abdominal wall, which is compromised in such

1 - Clinics Hospital of Porto Alegre, Service of General Surgery, Porto Alegre, Rio Grande do Sul State, Brazil. 2 - Nine of July Hospital, Service of Surgery of the Digestive System, São Paulo, São Paulo State, Brazil. 3 - Oswaldo Cruz German Hospital, Service of General Surgery, São Paulo, São Paulo State, Brazil.

cases, and to expand the abdominal cavity so that it can receive the herniated contents back and prevent complications such as compartment syndrome.

Among the options for reducing tension in the repair of these hernias are the use of meshes, muscle-aponeurotic flaps, autologous and heterologous grafts, progressive pneumoperitoneum and separation of components of the abdominal wall. Restoration of abdominal wall functionality can be achieved with the component separation technique. The expansion of the abdominal cavity can be done with progressive pneumoperitoneum, with the pharmacological blocking of the abdomen lateral musculature with the use of botulinum toxin or with the separation of components⁶⁻⁸.

In view of all these peculiarities presented by bulky hernias, their treatment is still a challenge for surgeons⁶. Among the techniques mentioned, the concomitant use of a mesh and the separation of abdominal wall components presents potential advantages, as the components separation allows that all goals in the hernia treatment are achieved, that is, restoration of abdominal wall function, expansion of the abdominal cavity and tension reduction. However, since in these cases the strength of the abdominal muscle fascias often reduced, the mesh reinforcement would be adequate⁷. The components separation, however, is associated with complications such as skin ischemia, dehiscence, surgical site infection and formation of seroma due to extensive dissection of the subcutaneous tissue. With this, this technique underwent modifications and alternatives of muscle separation were developed^{5,7}. One of them was the posterior separation of components, which has the advantage of avoiding subcutaneous dissection. Moreover, when performed by a minimally invasive technique (such as robotics), it is associated with lower rates of postoperative morbidity and shorter hospital stay⁵.

The methods of posterior component separation are based on creating a space between the rectus abdominis muscle and its posterior sheath of six to eight centimeters for placement of the mesh in the position called sublay or retromuscular. However, this technique is inadequate for the treatment of major wall defects, as it does not allow dissection beyond the lateral border of the rectus sheath, rendering this

space insufficient⁹. The methods developed to increase this potential space, including TAR, reduced recurrence rates to 3-6%^{5,9}.

The objective of this study was to describe the Brazilian preliminary experience in the performance of the posterior separation of components of the abdominal wall by the transversus abdominis release technique with the use of a robotic system in the correction of complex defects of the abdominal wall and its early results. The procedures were performed at the Clinics Hospital of Porto Alegre (Porto Alegre, RS), Osvaldo Cruz German Hospital (São Paulo, SP) Nine of July Hospital (São Paulo, SP) between 04/02/2015 and 06/15/2015.

TECHNICAL NOTE

All patients signed an informed consent agreement, including the use of data with confidentiality.

We started the procedure by puncturing the space of Palmer with a Veres needle for instillation of the pneumoperitoneum; we placed two trocars in the medial axillary line, with a distance of 10cm between them and docked the robot. We then performed a review of the abdominal cavity with release of adhesions. We made an incision in the rectus posterior sheath 0.5cm from its medial border. Next, we developed the retro-muscular space, extending it in the longitudinal axis from the xiphoid to the pubis, and laterally until the semilunar line. We identified the neurovascular bundle to preserve it (Figure 1). At 0.5cm medial to the semilunar line, we made an incision in the rectus posterior sheath to expose the transversus abdominis muscle. We opened the posterior lamina of the rectus sheath, identifying the preperitoneal space. We then dissected this space from the xiphoid to the suprapubic portion (Figure 2). We measured the defect to place the mesh. We placed the contralateral portals in mirror and inserted the mesh, fixing it in three cardinal points. We then docked the robot on the contralateral side behind the trocars to perform the same steps on the other side. After opening the posterior lamina of the rectus sheath for the development of the retro-muscular space and identification and development of the preperitoneal space, we closed the posterior lamina of the rectus sheath and the peritoneal defects. We

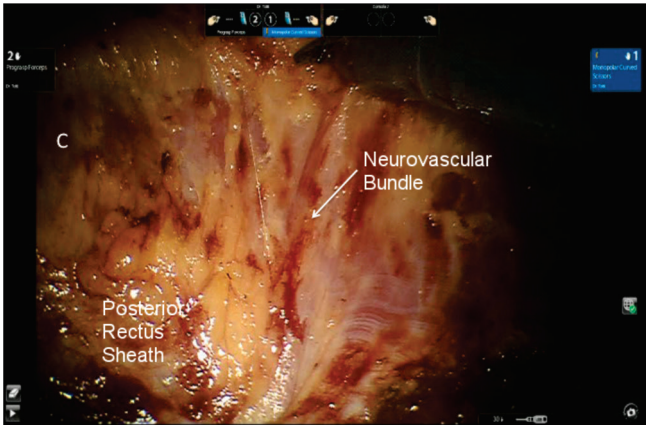


Figure 1. Dissection of the rectus posterior sheath.

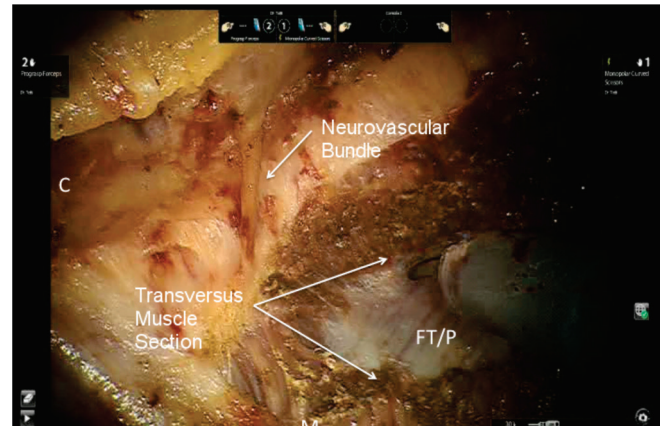


Figure 2. Transversus muscle section – TAR.

then unrolled the mesh and complemented its fixation at the other cardinal points. We closed the anterior aponeurosis, removed the portals under direct vision and closed the wounds.

The defect size ranged from seven to 15cm, with an average size of 11cm. The surgical time ranged from four to seven hours, with an average of five hours and 40 minutes. The hospitalization time ranged from two to five days, with an average of three days.

We evaluated the procedure's late outcome through the outpatient visits within a period of up to six months after surgery. Of the six patients submitted to the procedure, two presented postoperative complication: one developed hernia through the peritoneum and the other presented mesh extrusion, both complications corrected with a new surgical procedure. We observed no other complications and, to date, all patients have a good clinical course.

DISCUSSION

TAR has been shown to be a good option for the correction of complex abdominal wall defects. With this technique, the placement of the mesh is more appropriate, since the mesh should extend eight to ten centimeters beyond the edge of the defect in the repair of large hernias. In addition, one can avoid the nerve section with TAR. The same does not happen with other techniques of posterior separation of the components, which end up causing atrophy of the rectus abdominis muscle and consequent abdominal flaccidity^{5,9}. It is also associated with low recurrence

rates, as mentioned above, and can be performed by robotic surgery, which presents potential advantages over other techniques used to correct abdominal wall defects by adding the pros of minimally invasive surgery.

When comparing open surgery with the use of the mesh and the laparoscopic surgery, it was found that the laparoscopic surgery has the advantages of allowing smaller incisions and consequently less surgical aggression. It presents a lower infection rate in the surgical site, allowing shorter hospitalization time, besides allowing the identification of hernial processes that could not be perceived by open surgery¹⁰⁻¹². However, its recurrence rate, despite being lower than that of open surgery, did not reduce significantly. In addition, the long-term pain index presented by some patients is still a therapeutic challenge¹³.

When comparing laparoscopic surgery with robotics, it was observed that the robot allows the accomplishment of angular movements due to the articulation of the clamp cuff, making complex procedures such as TAR feasible by minimally invasive technique. In addition, with the robot, lysis of adhesions on the abdomen anterior wall is facilitated and the sutures can be made with adequate force and tension and with short movements. The 3D view generated by the robot facilitates the unwinding of the mesh and allows its better positioning, besides helping in the accomplishment of the suture^{14,15}.

In the study by Novitsky *et al.*⁹, 24% of the patients had surgical site infection and 2% had hernia recurrence. Our mean surgical time was higher than

that reported by them (340 minutes and 235 minutes, respectively) and our mean hospitalization time was shorter (3 days and 5.1 days, respectively).

We conclude that the national experience in the use of robotic surgery to perform TAR in the correction of abdominal wall complex defects showed

that the procedure is feasible, with an index of complications similar to the open one. However, new studies need to be performed to complement these findings, since our study presents a small sample and a short period of postoperative segment, our results being preliminary.

R E S U M O

Descrevemos a experiência preliminar nacional na utilização da cirurgia robótica para realizar a separação posterior de componentes da parede abdominal pela técnica *transversus abdominis release* (TAR) na correção de defeitos complexos da parede abdominal e seus resultados precoces. As cirurgias foram realizadas entre 02/04/2015 e 15/06/2015 e o tempo de acompanhamento dos resultados foi de até seis meses, com tempo mínimo de dois meses. O tempo cirúrgico médio foi de cinco horas e 40 minutos. Dois pacientes necessitaram reintervenção por laparoscopia, pois um desenvolveu hérnia por migração peritoneal da tela e um teve escape da tela. A cirurgia provou ser factível do ponto de vista técnico, com um tempo cirúrgico ainda elevado. Tendo em vista as vantagens potenciais da cirurgia robótica e aquelas relacionadas ao TAR e os resultados obtidos ao se associar essas duas técnicas, conclui-se que elas parecem ser uma boa opção para a correção de defeitos complexos da parede abdominal.

Descritores: Robótica. Hérnia Abdominal. Procedimentos Cirúrgicos Minimamente Invasivos.

REFERENCES

- Mayagoitia Gonzalez JC. Hernias de la pared abdominal; el nacimiento de una sociedad médica. Rev Col Bras Cir. 2010;37(1):4-5.
- Dabbas N, Adams K, Pearson K, Royle G. Frequency of abdominal wall hernias: is classical teaching out of date? JRSMB Short Rep. 2011;2(1):5.
- Park AE, Roth JS, Kavic SM. Abdominal wall hernia. Curr Probl Surg. 2006;43(5):326-75.
- Slater NJ, Montgomery A, Berrevoet F, Carbonell AM, Chang A, Franklin M, et al. Criteria for definition of a complex abdominal wall hernia. Hernia. 2014;18(1):7-17.
- Pauli EM, Rosen MJ. Open ventral hernia repair with component separation. Surg Clin North Am. 2013;93(5):1111-33.
- Melo RM. "Hérnia complexas" da parede abdominal. Rev Col Bras Cir. 2012;40(2):90-1.
- Heller L, Chike-Obi C, Xue AS. Abdominal wall reconstruction with mesh and components separation. Semin Plast Surg. 2012;26(1):29-35.
- Barbosa MV, Ayaviri NA, Nahas FX, Juliano Y, Ferreira LM. Improving tension decrease in components separation technique. Hernia. 2014;18(1):123-9.
- Novitsky YW, Elliott HL, Orenstein SB, Rosen MJ. Transversus abdominis muscle release: a novel approach to posterior component separation during complex abdominal wall reconstruction. Am J Surg. 2012;204(5):709-16.
- Misiakos EP, Machairas A, Patapis P, Liakakos T. Laparoscopic ventral hernia repair: pros and cons compared with open hernia repair. JSLS. 2008;12(2):117-25.
- Misiakos EP, Patapis P, Zavras N, Tzanetis P, Machairas A. Current trends in laparoscopic ventral hernia repair. JSLS. 2015;19(3):e2015.00048.
- Liang MK, Berger RL, Li LT, Davila JA, Hicks SC, Kao LS. Outcomes of laparoscopic vs open repair of primary ventral hernias. JAMA Surg. 2013;148(11):1043-8.
- Beldi G. Technical feasibility of a robotic-assisted ventral hernia repair. World J Surg. 2012;36(2):453-4.
- Ballantyne GH, Hourmont K, Wasielewski A. Te-lerobotic laparoscopic repair of incisional ventral hernias using intraperitoneal prosthetic mesh. JSLS. 2003;7(1):7-14.
- Abdalla RZ, Garcia RB, Costa RID, Luca CRP, Abdalla BMZ. Procedimento de Rives/Stopppa modificado robô-assistido para correção de hérnias ventrais da linha média. ABCD, arq bras cir dig. 2012;25(2):129-32.

Received in: 18/10/2016

Accepted for publication: 15/12/2016

Conflict of interest: none.

Source of funding: none.

Mailing address:

Maria Vitória França do Amaral

E-mail: mariavitoria.301@gmail.com

cavazzola@gmail.com