

PELVIC PAIN AND DISPAREUNIA: A BENIGN CYSTIC
MESOTHELIOMA CASE REPORT

DOR PÉLVICA E DISPAREUNIA: RELATO DE UM CASO DE MESOTELIOMA
CÍSTICO BENIGNO

Helena von Eye Corleta¹, Marcia Komlós², Edison Capp¹, Maria Francisca Lopes³

ABSTRACT

Benign cystic mesothelioma is a rare tumor originated from mesenchymal cells of the abdominal and pelvic peritoneum. This rare tumor should be considered in the differential diagnosis of young women presenting with abdominal pain and a multicystic abdominal mass.

Key words: Benign cystic mesothelioma, pelvic pain, dispareunia.

RESUMO

O mesotelioma cístico benigno é um tumor raro originado de células mesenquimais do peritônio abdominal e pélvico. Este tumor raro deve ser considerado no diagnóstico diferencial de mulheres jovens apresentando dor abdominal e massa abdominal multicística.

Unitermos: Mesotelioma cístico benigno, dor pélvica, dispareunia.

¹ Department of Obstetrics and Gynecology, School of Medicine, Universidade Federal do Rio Grande do Sul (UFRGS); Service of Gynecology and Obstetrics, Hospital de Clínicas de Porto Alegre, Porto Alegre, RS, Brazil; Clínica Gerar de Fertilização Assistida, Porto Alegre, RS, Brazil.

² Department of Obstetrics and Gynecology, School of Medicine, Universidade Federal do Rio Grande do Sul (UFRGS); Service of Gynecology and Obstetrics, Hospital de Clínicas de Porto Alegre, Porto Alegre, RS, Brazil.

³ ANATPAT, Laboratory of Surgical Pathology, Porto Alegre, RS, Brazil.

Correspondence: Dr. Helena Corleta, Rua Ramiro Barcelos, 910 cj 905, 90035-001, Porto Alegre, RS, Brazil. Fax: (+55-51) 3311-6588. E-mail: hcorleta@portoweb.com.br.

INTRODUCTION

Benign cystic mesothelioma (BCM) is a rare tumor that originates in the peritoneum and may involve the surface of the bladder, rectum, ovary or *cul de sac*. The incidence is of 0.1-1.0 case per million people every year (1), and occurs mostly in women of reproductive age. The women-men rate is 5:1.

The present study reports a case of BCM diagnosed in a 21-year-old female presenting with abdominal pain and a pelvic cystic mass.

CASE REPORT

A 21-year-old nulligravida, white, single, sexually active woman had a history of pelvic pain and dispareunia

for 6 months. Two previous ultrasounds were suggestive of hydrosalpinx, and the patient had been treated for inflammatory pelvic disease, without improvement. The patient had been using oral contraceptives for 2 years. Abdominal examination on admission revealed abdominal distention; gynecologic examination was suggestive of a pelvic mass. Videolaparoscopy was performed and revealed multiple cysts containing clear and gelatinous material, the largest with 5 cm in diameter. Fallopian tubes and ovaries were normal, as well as the rest of the peritoneal cavity. The cysts were aspirated, and the capsule was sent to examination. The pelvic peritoneum of the *cul de sac* was cauterized. Pathology report revealed BCM.

After surgery, the patient showed improvement of symptoms, and two years later, was asymptomatic, without evidence of recurrence.

DISCUSSION

Mesotheliomas are mesenchymal tumors originated from cells that cover serous cavities. In the peritoneum (site affected in 20% of cases), mesotheliomas may manifest themselves as benign adenomatoid tumors, malignant mesotheliomas or BCM (2,3). Patients presenting with diffuse malignant mesotheliomas show an overall median survival of 6 to 10 months. Adenomatoid tumors are rare and are most commonly found in the genital tract. They are benign and do not tend to recur. BCM is a borderline lesion between these two entities (4).

Mennemeyer & Smith were the first to report the mesothelial origin of these tumors, in 1979 (4). The etiology remains obscure (3); however, a possible role of chronic peritoneal irritation and previous laparotomy has been described (5). Reactive origin, previous history of abdominal surgery, endometriosis, or pelvic inflammatory disease may also be involved (6). The present patient had been submitted to an abdominal surgery two years before the diagnosis of BCM. In contrast with what is observed in malignant mesotheliomas, no relation with asbestosis was found.

The most common symptoms associated with BCM include chronic pelvic or abdominal pain, distention, and presence of abdominal mass on examination (6,7,8). Dispareunia, urinary urgency and frequency may also be present (2,6). Sometimes, abdominal mass is absent, and the tumor is discovered incidentally on laparotomy. These tumors may grow in the peritoneal cavity and compress other organs. Invasion of organs has been observed but is difficult to explain (7). Symptoms differ from those of malignant mesotheliomas, which present ascites in most cases. Although the diagnosis of BCM may be suggested

by ultrasonography (US), computerized tomography (CT) and magnetic resonance (MR), definitive diagnosis is made only after histological examination (7).

The cysts may range from several millimeters to several centimeters in diameter (7). They are filled with a clear, watery fluid, sometimes serous to gelatinous. Microscopic appearance consists of cystic spaces lined with one to several layers of cubical or flattened cells embedded in a delicate fibrous stroma (figure 1A), with numerous microvilli and well formed desmosomal junctions. They often have a "hobnail" or "picketed fence" appearance (figure 1B). Focuses of epithelial hyperplasia may also be noticed. Some atypias are often present and may lead to misdiagnosis of serous carcinoma or malignant mesothelioma (4).

Differential diagnosis should be made with cystic malignant mesothelioma, ovarian cystadenoma, cystadenocarcinoma, cystic lymphangioma, angiosarcoma of serous membranes, cystic smooth muscle tumors, visceral cysts, pancreatic neoplasms, endometriosis and adenomatoid tumors (7,8). Many of these pathologies are similar in terms of image findings and clinical appearance and can be differentiated only by histological examination.

Treatment consists of complete surgical resection, and preservation of pelvic organs is indicated (6). Recurrence may occur in as much as 50% of cases, and usually takes place 1 to 27 years after the primary treatment. Recurrence is also managed with resection, and morbidity is related to local dissemination and recurrence (2,7,8). Metastasis or malignant degeneration has never been reported. Fatal complications related to local recurrence and surgery have been described (9,10).

In conclusion, the present study reported a case of peritoneal BCM in a 21-year-old patient. The exact etiology was unclear, but could be associated with a previous

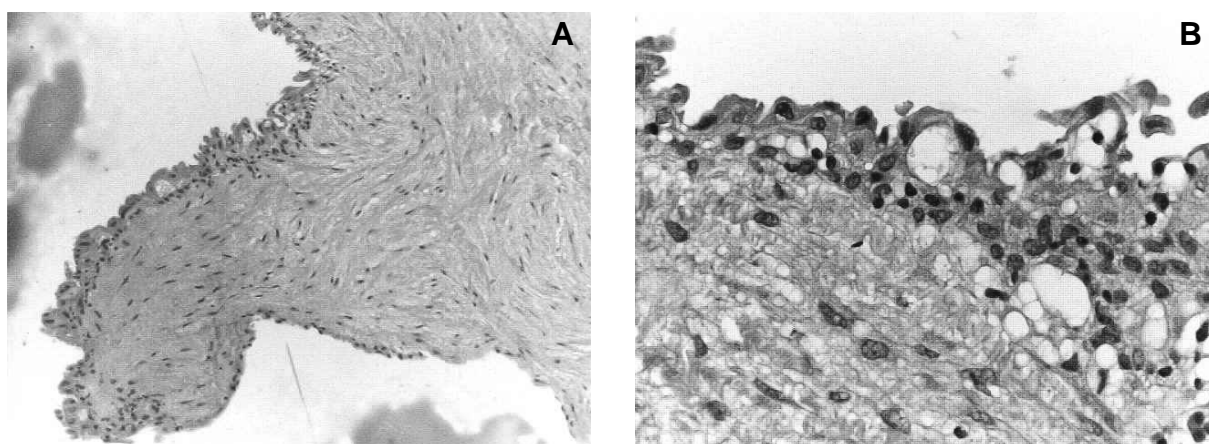


Figure 1. (A) Detail of one of the mesothelial-lined cysts embedded in a delicate fibrous stroma (H&E - 250X). (B) Hobnail-shaped cells in an area of mesothelial hyperplasia (H&E-400X).

surgery. Although peritoneal BCM is rare in occurrence, it should be considered in the differential diagnosis of young women presenting with abdominal pain and a multicystic abdominal mass (10).

REFERENCES

1. Toma GD, Nicolanti V, Plocco M. Cystic peritoneal mesothelioma: report of a case. *Surg Today* 2000;30(1):98-100.
2. O'Neil JD, Ros PR, Storm BL, Buck JL, Wilkinson EJ. Cystic mesothelioma of the peritoneum. *Radiology* 1989;170:333-7.
3. Hatsube Y, Mukai K, Silverberg SG. Cystic mesothelioma of the peritoneum - report of five cases and review of the literature. *Cancer* 1982;50:1615-22.
4. Mennemeyer R, Smith M. Multicystic, peritoneal mesothelioma. *Cancer* 1979;44:692-8.
5. Takenouchi Y, Oda K, Takahara O, et al. Report of a case of benign cystic mesothelioma. *Am J Gastroenterol* 1995;90(7):1165-7.
6. Schneider V, Partridge JR, Gutierrez F, Hurt WG, Maizels MS, Demay RM. Benign cystic mesothelioma involving the female genital tract: report of four cases. *Am J Obstet Gynecol* 1983;145(3):355-9.
7. Ozgen A, Akata D, Akhan O, Tez M, Gedikoglu G, Ozmen MN. Giant benign cystic peritoneal mesothelioma: US, CT, and MRI findings. *Abdom Imaging* 1998;23:502-4.
8. Omeroglu A, Husain A. Multilocular peritoneal inclusion cyst (benign cystic mesothelioma). *Arch Pathol Lab Med* 2001;125(8):1123-4.
9. De Toma G, Nicolanti V, Plocco M, Cavallaro G, Amato D, Letizia C. Cystic peritoneal mesothelioma: report of a case. *Surg Today*, 2000; 30: 98-100.
10. Weiss SW, Tavassoli FA. Multicystic mesothelioma. An analysis of pathologic findings and biologic behavior in 37 cases. *Am J Surg Pathol* 1988;12:737-46.