



## Odontogenic infections: severe complications associated with diabetes mellitus

Angelo Luiz Freddo<sup>a</sup>, Fernando Vacilotto Gomes<sup>a</sup>, Carlos Alberto Medeiros Martins<sup>b</sup>,  
Guilherme Genehr Fritscher<sup>b</sup>, Marcos Antonio Torriani<sup>c</sup>

### Abstract

**Objective:** Ludwig's angina is a severe form of diffuse cellulitis occurring in the cervicofacial region, with aggressive characteristics that systemically affect the patient and can lead to death. Disease severity is due to the formation of extensive laryngeal cellulitis, which evolves to edema of the glottis and consequently acute respiratory obstruction. The rapid progression of infection and the establishment of a severe general medical condition requires fast diagnosis and adequate management in order to improve prognosis.

**Case Report:** This paper describes two cases of Ludwig's angina in patients with diabetes mellitus treated at public hospitals in southern Brazil, with a focus on clinical characteristics, disease evolution, and treatment.

**Conclusion:** Depending on the patient's systemic conditions and the kind of established treatment, it may guide the diseased prognosis. One of the patients had a favorable outcome, whereas the other developed mediastinitis and died.

**Keywords:** Ludwig's angina; soft tissue infections; cellulitis; diabetes mellitus; mediastinitis

<sup>a</sup> Department of Oral Surgery and Orthopedics, Federal University of Rio Grande do Sul (UFRGS), Porto Alegre, RS, Brazil

<sup>b</sup> Department of Oral and Maxillofacial Surgery, Pontifical Catholic University of Rio Grande do Sul (PUCRS), Porto Alegre, RS, Brazil

<sup>c</sup> Department of Oral Surgery, Federal University of Pelotas (UFPe), Pelotas, RS, Brazil

### Infecções odontogênicas: complicações severas associadas à diabetes mellitus

#### Resumo

**Objetivo:** A angina de Ludwig é uma das formas mais graves de celulite difusa da região cervicofacial, apresentando características agressivas que comprometem sistemicamente o paciente, podendo levá-lo ao óbito. Isso ocorre devido à intensa celulite na região de laringe, podendo evoluir para um edema de glote, com consequente obstrução respiratória aguda. Sua disseminação ainda pode ter um trajeto descendente envolvendo estruturas torácicas, caracterizando uma mediastinite. Esta agressividade na evolução do processo infeccioso e no estabelecimento de uma condição geral grave exige um diagnóstico rápido e uma conduta adequada visando favorecer o prognóstico.

**Relato de Caso:** Este trabalho apresenta dois casos de Angina de Ludwig, em pacientes com Diabetes Mellitus, atendidos em dois hospitais do Rio Grande do Sul, Brasil, analisando as características clínicas, bem como a evolução da doença e a terapêutica utilizada para cada caso.

**Conclusão:** Dependendo da condição clínica do paciente, assim como, do tratamento de escolha utilizado, favorecerá ou não o prognóstico do paciente. Verificou-se um resultado favorável com a cura do paciente e o outro evoluiu para medistinite e óbito.

**Palavras-chave:** Angina de Ludwig; infecções dos tecidos moles; celulite; diabetes mellitus; mediastinite

**Correspondence:**  
Angelo Luiz Freddo  
[angelofreddo@gmail.com](mailto:angelofreddo@gmail.com)

**Received:** November 06, 2012  
**Accepted:** February 11, 2013

**Conflict of Interests:** The authors state that there are no financial and personal conflicts of interest that could have inappropriately influenced their work.

**Copyright:** © 2013 Freddo et al.; licensee EDIPUCRS.

This work is licensed under a Creative Commons Attribution-NonCommercial 3.0 Unported (CC BY-NC 3.0).

ISSN: 1980-6523

## Introduction

Ludwig's angina is among the most severe forms of diffuse cellulitis occurring in the cervicofacial region, and is frequently caused by a local odontogenic infection [1]. The condition is defined as an aggressive and rapidly progressive infectious process that usually affects the airways and therefore can lead to death. Odontogenic infections affecting mandibular second and third molars are the most common etiologic factor: the rate of patients diagnosed with Ludwig's angina who report a recent history of toothache has ranged from 50 to 80% in different studies [2-5].

The anatomical characteristics of the neck facilitate the spread of infections to deep cervical spaces, potentially affecting vital structures such as upper airways and other organs of the thoracic cavity. Locoregional spread of the infectious process takes place via different routes, e.g., hematogenic and lymphatic routes, but primarily through cervical fascias, affecting and involving multiple cervical spaces and potentially leading to complications such as aspiration pneumonia, acute myocardial infarction, rupture of carotid arteries, mediastinitis, septicemia, and multiple organ failure.

On the one hand, modern dental care and the use of antibiotics have successfully managed to interrupt disease spread in many cases and increase patient survival [5,6]. On the other hand, underlying conditions and other comorbidities, e.g., decompensated diabetes, may change the course of infection and produce poor outcomes.

The aim of this study was to describe two cases of Ludwig's angina in patients with systemic conditions (diabetes and hypertension), seen at the emergency services of two public hospitals located in southern Brazilian state of Rio Grande do Sul. The clinical characteristics of the two patients are described, as well as disease evolution and the treatment approach used in each case.

## Case Report 1

A 51-year old white female patient presented at the emergency unit of Hospital Cristo Redentor – Grupo Hospitalar Conceição, Porto Alegre, southern Brazil, with fever, prostration, neck pain, and dysphagia. The patient reported having undergone an unsuccessful surgical procedure eight days before, under local anesthesia, for the removal of root canal debris. Radiographic examination (panoramic radiograph) revealed the presence of debris on the left side of the mandibular body, around tooth no. 37 (Fig. 1).

During anamnesis, the patient informed she had decompensated type II diabetes mellitus and uncontrolled hypertension. Physical examination revealed trismus and swelling of the floor of the mouth, with tongue elevation and facial cellulitis affecting the left submandibular region.

Upon hospital admission, empiric antibiotic therapy was initiated with intravenous clindamycin 600 mg every 8 hours. Emergency laboratory exams revealed leukocytosis

and high glucose levels, in addition to high blood pressure.

After five days of hospitalization, dysphagia and dyspnea worsened, and the patient showed signs of aspiration pneumonia, which caused her immediate admission to the intensive care unit (ICU). The patient was intubated (orotracheal) and sedated. Once the patient was stabilized, she was taken to the operating room for extraoral drainage of the left sublingual and submandibular abscess, under general anesthesia. An extraoral incision was made at the left submandibular region for the collection of purulent material, and a no. 40 Penrose drain was placed for continued drainage (Fig. 2). A nasogastric probe was also used for feeding due to dysphagia.

Anaerobic culture evidenced gram-positive cocci and gram-negative bacilli. This finding, combined with clinical signs, raised the suspicion of anaerobic infection.

Antibiotic therapy was changed to intravenous vancomycin 1 g every 12 hours due to the presence of hospital-acquired pneumonia, plus intravenous imipenem 500 mg every 6 hours. Dressings were changed daily, and the amount of secretion collected was observed.

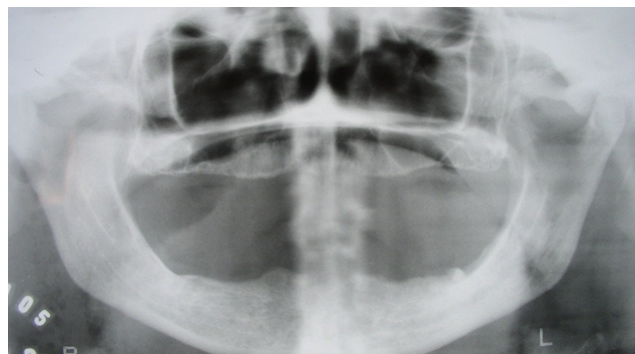


Fig. 1. Panoramic radiograph showing root canal debris at the region of tooth no. 37 (potential cause of submandibular abscess).

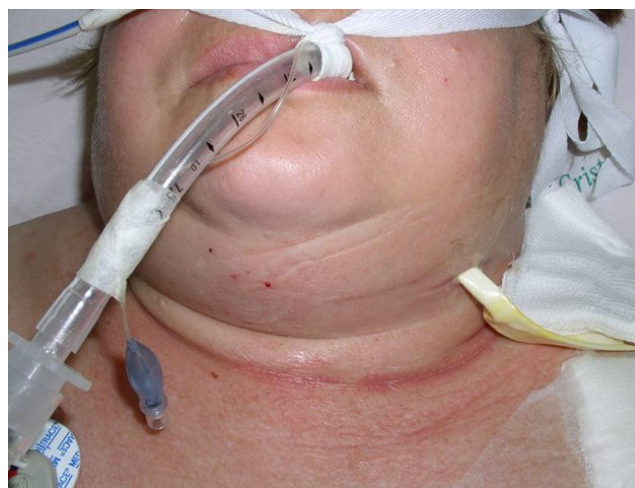

Fig. 2. Extraoral drainage of submandibular abscess and placement of a Penrose drain.

After eight days of hospitalization, swelling and other signs of inflammation improved, and diabetes became stable. The patient was then operated for the removal of root canal debris. After additional 15 days in the hospital, healing was confirmed by blood tests and the patient was discharged.

## Case Report 2

A 58-year old white male patient presented at the School of Dentistry of Universidade Federal de Pelotas (UFPel), Pelotas, southern Brazil, with pain, cellulitis affecting the left half of the face, and left submandibular lymph node lesions. The patient was conscious and breathing well, but showed prostration and fever. Intraoral physical examination revealed extensive decay of tooth no. 37, which was probably causing the infection. Also, several teeth were absent, and tooth no. 47 showed mobility (data confirmed on panoramic radiograph) (Fig. 3).

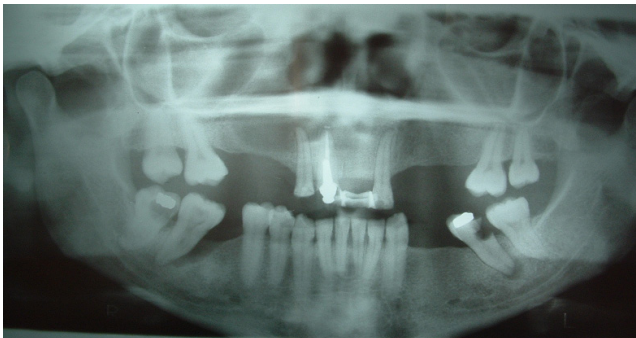


Fig. 3. Panoramic radiograph showing severe periodontal and dental condition.

During anamnesis, the patient reported having type II diabetes mellitus and not being under any type of medical or pharmacological treatment. He denied allergies to any drugs or any other systemic conditions. Antibiotic therapy was started with oral amoxicillin 500 mg every 8 hours. On the following day, signs of infection receded, and tooth no. 37 was extracted under local anesthesia. Surgery was performed without interferences, and (immediate and late) postoperative care instructions were given to the patient in writing. The patient was referred to the public health care unit located closest to his home address for the treatment of diabetes. Analgesics were prescribed, with oral paracetamol 750 mg every 6 hours, and amoxicillin was maintained for 7 days after surgery.

One week later, the patient presented at the dental clinic to remove intraoral sutures. The patient was prostrated and showed mild pain, fever, mild trismus, and a swelling of woody consistency on the left side of the floor of the mouth and left half of the face. The patient reported not having sought treatment for diabetes. Intraoral examination revealed plaque accumulation on sutures. The patient was

prescribed oral amoxicillin 500 mg plus metronidazole 400 mg every 8 hours, paracetamol 750 mg and antiseptic oral rinsing with a 0.12% chlorhexidine gluconate solution. The patient was once again instructed to seek a health care unit in order to treat diabetes and had a new visit scheduled at the School of Dentistry for three days later, which he did not attend.

Approximately 15 days after suture removal, the patient was admitted to the Public Emergency Service of the municipality of Pelotas. The patient showed prostration, dysphagia, fever, with a diffuse, woody swelling involving the whole floor of the mouth and cervical region, dyspnea, tachycardia, and cutaneous erythema involving most of the cervical and thoracic region (Fig. 4).

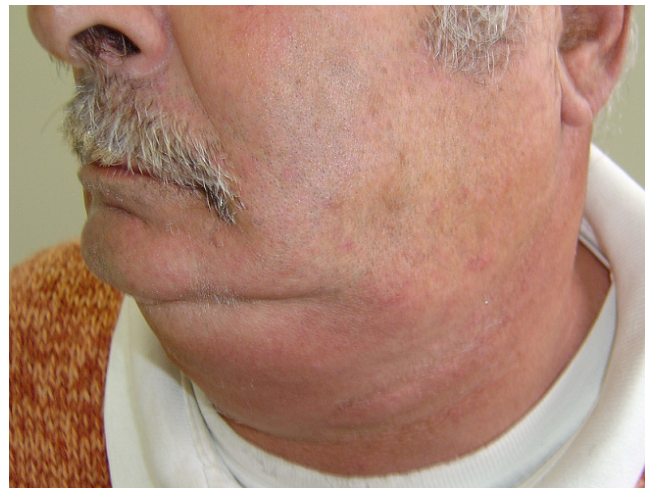

Fig. 4. Swelling in the left submandibular and cervical region.

After hospital admission, the patient was referred to the departments of thoracic surgery and infectious disease, based on the clinical signs of thoracic disease. He was submitted to routine examinations and was diagnosed with mediastinitis (Fig. 5). Antibiotic therapy was initiated with intravenous cephalotin 500 mg every 6 hours, metronidazole 500 mg every 8 hours, and gentamicin 80 mg every 12 hours. Laboratory tests performed at the emergency unit revealed leukocytosis and high glucose levels, in addition to high blood pressure.

After three days of hospitalization, the patient developed signs of aspiration pneumonia and a feeling of suffocation. The patient was immediately referred to the ICU, and orotracheal intubation and sedation were performed.

Antibiotic therapy was changed to intravenous vancomycin 1 g every 12 hours due to the presence of severe lung infection, plus intravenous imipenem 500 mg every 6 hours. The patient was monitored during his stay at the ICU, but died two days after the change in the antibiotic therapy regimen as a result of multiple organ failure.

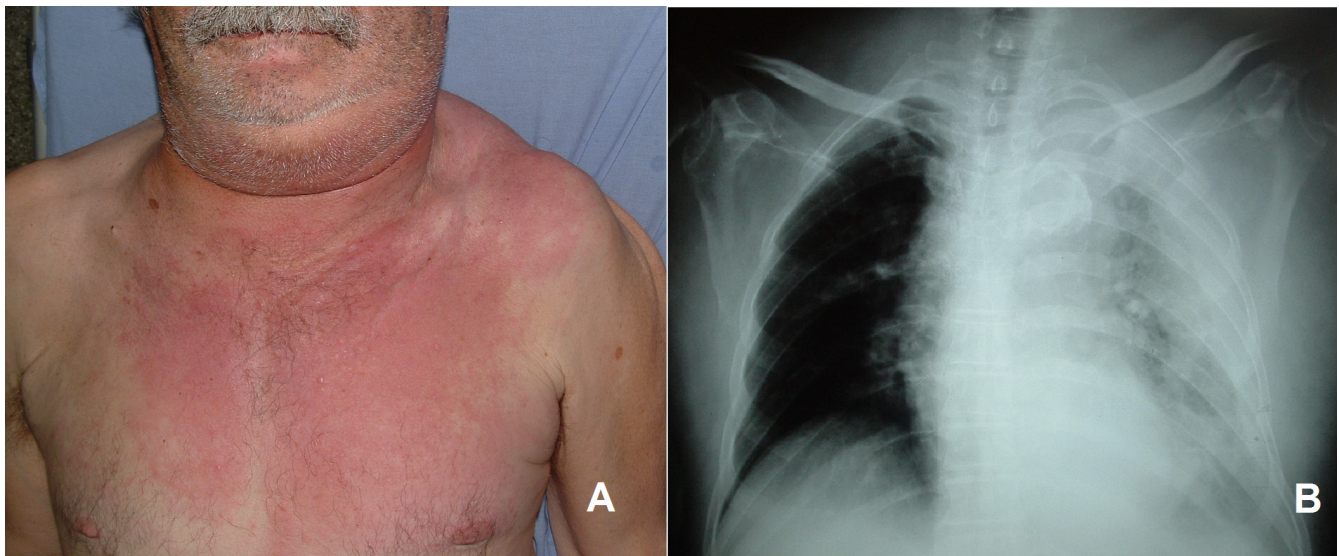


Fig. 5. (A) Erythema in the cervical and thoracic region, characteristic of Ludwig's angina. (B) Chest X ray showing fluid in the left lung.

## Discussion

Ludwig's angina is an infectious process that spreads through the posterior margin of the mylohyoid muscle into the submandibular space [4]. Classically, infections affecting the cervical spaces may occur at any age and similarly affect both males and females [6]. However, one study has revealed a higher prevalence of neck infections in the 51-60-year age group and in females [4]. Most cases are diagnosed in healthy subjects, although some systemic conditions may contribute to their occurrence, e.g., diabetes mellitus, neutropenia, aplastic anemia, glomerulonephritis [1,2], alcohol abuse, lupus erythematosus, AIDS, and cancer. The cases here described had decompensated type II diabetes. This finding underscores the importance of a thorough clinical assessment of the patient's overall condition whenever signs of infection are present, as the association between deep neck infections and conditions such as diabetes may increase the severity of infection, posing additional difficulties to treatment [6].

The etiology of deep neck infections is associated with odontogenic infections where the apices of affected molars lie below the insertion of the mylohyoid muscle and very close to the submandibular space [1,2]. Our two cases showed major dental involvement resulting from caries-related structural damage and the maintenance of infectious foci in the mouth. In the first case (female patient), root canal debris were found at the region of tooth no. 37 after a failed attempt to extract the tooth; in our second case (male patient), radiography revealed the presence of severe periapical disease in the same tooth.

The infectious process of Ludwig's angina starts with a mild manifestation and can quickly progress with uni- or bilateral induration of the upper cervical region, painful symptoms, tongue elevation, fever, dysphagia [2,7-10], aerodigestive tract obstruction, lethargy [6], halitosis, and

mouth opening limited to 20-30mm [1]. Radiographically, radiolucent areas are observed surrounding the affected teeth, often with radiolucent lines suggesting the presence of fistulae [9,11]. Patients usually have a recent history of tooth extraction or poor oral hygiene habits [1]. Both of our patients showed radiographic findings compatible with extensive tooth destruction and the presence of root canal debris. As a result, both cases originated from a periapical inflammatory process into a more severe condition, namely Ludwig's angina; in our male patient, angina evolved to an even more severe condition (mediastinitis), which culminated in systemic infection and death.

Once the diagnosis of infection in the cervicofacial region is established, after a thorough anamnesis, practitioners should be alert for the presence of infections affecting the submandibular and cervical regions. The basic principles guiding treatment of infection at these spaces include upper airway control, antibiotic therapy, and surgical drainage [6], usually performed at hospital emergency units [12]. Infectious etiologic agents should be removed as soon as possible, so as to maximize treatment outcomes [1].

When treating a patient with Ludwig's angina, the first priority is airway monitoring. All patients diagnosed with this condition have to be managed with care, as the abscess will usually involve several cervical spaces, decreasing or even obstructing the flow of air. Orotracheal intubation, tracheostomy, or cricothyroidotomy should therefore be considered as appropriate whenever risk of asphyxia is present [4-6,12]. Spitalnic and Sucov [2] however, consider intubation to be a high risk procedure in these patients, due to the possibility of abscess rupture and infectious material aspiration. In our first case, clinical worsening over the first days of hospitalization and the presence of systemic comorbidities, such as type II diabetes and decompensated hypertension, motivated the decision to transfer the patient

to the ICU and intubate her before abscess drainage. Our second patient was also admitted to the ICU due to the need for airway management (he already showed a feeling of suffocation), but he evolved to a more severe clinical status.

The second priority in the treatment of these patients is antibiotic therapy, which should be initiated as soon as possible. Infection is typically polymicrobial, including both streptococci and staphylococci [1,11,12]. Because oral infections usually have gram-positive cocci, penicillin should be the antibiotic of choice, at high doses [1,2,11]. Clindamycin and cephalotin have a mechanism of action similar to that of penicillin [10] and are also highly effective against gram-positive cocci, including penicillin-resistant strains [13]. Anaerobic coverage should be added (metronidazole) because of the recent increase of penicillin-resistant bacterial strains. The empiric combination of clindamycin, penicillin, and metronidazole is recommended [1,4].

Following bacteriological confirmation, antibiotic treatment should be adjusted as appropriate. In our first case, therapy started with intravenous clindamycin 600 mg every 8 hours. However, based on bacterial culture results, we decided to change it to intravenous vancomycin 1 g every 12 hours, combined with intravenous imipenem 500 mg every 6 hours. Vancomycin is widely used in patients with severe infection, e.g., resistant hospital-acquired infections. Imipenem, in turn, is a broad-spectrum antimicrobial agent indicated in the treatment of patients with septicemia and hospital-acquired pneumonia. Similarly to vancomycin, imipenem is also used to prevent endocarditis in hospitalized and medically compromised patients. In our case no. 2, empiric antibiotic therapy was initiated with oral amoxicillin 500mg and subsequently combined with oral metronidazole 500 mg. Following hospital admission and worsening of infection, the pharmacological therapy was changed to intravenous cephalotin 500 mg, metronidazole 500 mg, and gentamicin 80 mg, which is also effective against septicemia and pneumonia. As the clinical status of the patient worsened, we changed antibiotic therapy once again to vancomycin 1 g and imipenem 500 mg, but the patient developed mediastinitis and septicemia, followed by death due to multiple organ failure.

According to the literature, several treatment approaches can be adopted in cases of mediastinitis. Usually, empiric antibiotic therapy is initiated and subsequently adjusted based on bacteriological findings. Mediastinal drainage is indicated for the collection of purulent material, but was not possible in our case no. 2 because of fast disease progression and early death. Several complications can be observed in these patients, including renal and respiratory insufficiency, sepsis, and pleural empyema [3,14]. One previous study has shown mortality rates around 30 to 50% in cases where the infectious process reaches the mediastinum [15].

The third priority in the treatment of Ludwig's angina is surgical drainage, once infection is certainly suppurative, regardless of fluctuance [2,7,8,12]. Surgical drainage has two

primary objectives: 1) to eliminate purulent collections and 2) to decompress facial and cervical spaces. Once infection is controlled, infected teeth should be removed so as to guarantee complete drainage of the abscess and elimination of the etiologic agent [1,7,8,14]. Multiple incisions may be necessary, and the location and size of the first incision will depend on the anatomic spaces involved. Sometimes it may become necessary to extend the incision to the midline, affecting the superficial lobe of the submandibular gland. In those cases, mylohyoid muscles are divided in order to decompress facial spaces and drains placed so as to prevent the accumulation of new necrotic and purulent debris [1,14].

In our case no. 1, in addition to prioritizing systemic stabilization, the medical team decided to surgically drain the suppurative material using one incision only; following edema reduction and control of the patient's clinical status, the infected tooth was extracted. In our case no. 2, the tooth was extracted early, once the patient showed a clinically stable condition at the time. Nevertheless, he was twice instructed to seek medical assistance for the treatment of diabetes, but ignored the instructions. Fifteen days after tooth extraction, the patient presented with several clinical signs compatible with Ludwig's angina and was immediately hospitalized; however, his condition was extremely severe by then, including a diagnosis of mediastinitis. Mediastinitis became the focus of treatment, and the patient died before the medical team could perform cervical drainage.

Ludwig's angina is a major infectious disease that should be rapidly diagnosed and treated to avoid progression to more severe, highly morbid conditions. Taking into consideration the large number of patients with poor dental health associated with significant underlying conditions (especially diabetes), and therefore their susceptibility to infectious processes, it is extremely important that dental surgeons be prepared to recognize and evaluate these symptoms and indicate an effective emergency treatment, so as to avoid complications that are extremely severe and difficult to treat.

## References

- Zanini FD, Stefani E, Santos JC, Perito LS, Krueh NF. Angina de Ludwig: relato de caso e revisão do manejo terapêutico. *ACM Arq Catarin Med* 2003;32:21-3.
- Spitalnic SJ, Sucov A. Ludwig's angina: case report and review. *J Emerg Med* 1995;13:499-503.
- Furst IM, Ersil P, Caminti M. A rare complication of tooth abscess: Ludwig's angina and mediastinitis. *J Can Dent Assoc* 2001;67:324-7.
- Bross Soriano D, Arrieta Gómez J, Prado Calleros H, Schimelmütz Idi J, Jorba Basave S. Management of Ludwig's angina with small neck incisions: 18 years experience. *Otolaryngol Head Neck Surg* 2004;130:712-7.
- Greenland KB, Acott C, Segal R, Riley RH, Merry AF. Delayed airway compromise following extubation of adult patients who required surgical drainage of Ludwig's angina: comment on three coronal cases. *Anaesth Intensive Care* 2011;39:506-8.
- Sennes LU, Imamura R, Angélico FV, Simoceli L, Frizzarini R, Tsuji DH. Infecções dos espaços cervicais: estudo prospectivo de 57 casos. *Rev Bras Otorrinolaringol* 2002;68:388-93.
- Duprey K, Rose J, Fromm C. Ludwig's angina. *Int J Emerg Med* 2010; 3:201-2.
- Costain N, Marrie TJ. Ludwig's angina. *Am J Med* 2011;124:115-17.
- Rana RS, Moonis G. Head and neck infection and inflammation. *Radiol Clin North Am* 2011;49:165-82.



10. Krishnan V, Johnson JV, Helfrick JF. Management of maxillofacial infections: a review of 50 cases. *J Oral Maxillofac Surg* 1993;51: 868-73.
11. Lemonick DM. Ludwig's angina: diagnosis and treatment. *Hosp Physician* 2002;38:31-7.
12. Hasan W, Leonard D, Russell J. Ludwig's angina-a controversial surgical emergency: how we do it. *Int J Otolaryngol* 2011; 2011:231816.
13. Sandor GK, Low DE, Judd PL, Davidson RJ. Antimicrobial treatment options in the management of odontogenic infections. *J Can Dent Assoc* 1998;64:508-14.
14. Rowe DP, Ollapallil J. Does surgical decompression in Ludwig's angina decrease hospital length of stay? *ANZ J Surg* 2011;81:168-71.
15. Pinto A, Scaglione M, Scuderi MG, Tortora G, Daniele S, Romano L. Infections of the neck leading to descending necrotizing mediastinitis: role of multi-detector row computed tomography. *Eur J Radiol*. 2008;65:389-94.

