

COMPARATIVE ANALYSIS OF THREE ROTARY INSTRUMENTS USED FOR CORONAL PRE-ENLARGEMENT IN RADICULAR DENTIN THICKNESS AND ROOT CANAL AREA OF MANDIBULAR MOLARS

ABSTRACT

PURPOSE: The purpose of this study was to evaluate the increase of the cervical area and dentin thickness in mesial and distal walls of the mesial canals from mandibular molars after the use of LA Axxess (LA), CP Drill (CP) and Gates-Glidden (GG) rotary instruments. **MATERIAL AND METHODS:** Sixty root canals from thirty mandibular first molar were sectioned 3 mm below the cement-enamel junction, divided in 3 groups (n = 20 root canals, each) according to rotary instrument used, and the cervical images were captured before and after pre-enlargement instrumentation. The increase of the instrumented cervical area (mm²) and the dentin removal thickness (mm), at mesial and distal walls were calculated using Image tools software, by comparison of images. Data were analyzed by ANOVA and Tukey tests (p=0.05). **RESULTS:** All rotary instruments promoted thickness reduction in dentin walls. In mesial wall, all rotary instruments promoted similar thickness reduction of dentinal wall and did not differ from each other (p>0.05). In distal wall, LA Axxess instrument promoted higher dentin thickness reduction than other groups (p<0.05). The three rotary instruments promoted different increase at the instrumented cervical area (p<0.05), LA promoted the highest increase area and GG and CP presented similar results. **CONCLUSION:** LA 20/0.06 promoted the highest thickness reduction in distal wall and increase of cervical area of root canal. On the other hand, CP was the safest instrument, with lower dentin removal of distal wall and similar increased area to GG.

JORDÃO-BASSO, Keren Cristina Fagundes*
KUGA, Milton Carlos*
KEINE, Katia Cristina*
GALOZA, Marina Oliveira Gonçalves*
SÓ, Marcus Vinicius Reis**

KEYWORDS

Cervical preparation. Root canal treatment. Rotary instruments.

INTRODUCTION

The adequate cleaning and shaping of the root canals is fundamental to the success of endodontic treatment.¹ The crown-down procedures are commonly recommended to root canal instrumentation because it reduces interference in radicular cervical third allowing an easier access to the radicular apical third.^{2,3} Several instruments are proposed to cervical pre-enlargement, such as ProTaper, K3, Gates-Glidden, LA Axxess or ultrasound tips to perform this step.⁴⁻⁶ On the other hand, coronal pre-enlargement also increases the accuracy of apical size determination during instrumentation.^{4,7}

Gates-Glidden are used to coronal pre-enlargement improving the tactile sense in order to feel the apical constriction in curved canal and also routinely used during biomechanical instrumentation of the root canal.^{7,8} The diameter of the #2 Gates-Glidden bur (0.70 mm) is considered safe for the coronal pre-enlargement of mesial canals of mandibular molars.⁹ When #2 and #3 Gates-Glidden burs are used for the straight up and down motion, they remove, statistically, more dentin at the furcation (danger zone) than Canal Openers using straight up and down motion or in an anti-curvature motion.¹⁰

Another recommended instrument to coronal pre-enlargement is LA Axxess burs (SybronEndo - Orange - CA - USA), which consists of titanium nitrite-treated stainless

steel with inactive tips. These burs have 19 mm long and are presented in #20, # 35 and #45 sizes, with 0.06 taper.¹¹ Root canal pre-enlargement with LA Axxess burs showed more accurate binding of the files to anatomical diameter.³ When #20 and #30 instruments were used to coronal pre-enlargement, they did not damage the dentin structure from distal wall of mesial root canal of mandibular molars.⁵

Recently, a new instrument for coronal pre-enlargement of the root canal has been recommended. CP Drill (Helse - Ribeirão Preto - SP - Brazil) is manufactured in surgical steel and has 7 mm active long and inactive tip. However, there are no studies assessments about coronal pre-enlargement in mesial root canals of mandibular molars or cervical interferences elimination using this instrument.

Despite these burs are routinely used in endodontic clinical procedures, all care should be taken for instrumentation of mesial roots of mandibular molars, because this root has a thin distal wall in cases of bifurcation. Damage to this area might conduct the instrument and perforate the periodontal junction of the furcal region.⁵ The coronal pre-enlargement increases the diameter of the radicular cervical third by dentin removal in mesial and distal walls. An excessive dentin removal in these walls may cause perforations and endodontic complications with posterior tooth loss.

Due to the importance of coronal pre-enlargement and its consequences, the objectives of this study were to evaluate the amount of dentin removal, in distal (danger zone) and mesial walls, of mesial canals of human mandibular first molar and the increase in coronal root canal diameter promoted by three instruments (Gates-Glidden, LA Axxess and CP Drill).

MATERIAL AND METHODS

This study was approved by the Research Ethics Committee of the Fundação Municipal de Educação e Cultura de Santa Fé do Sul (033/2010). Thirty unrestorable human permanent mandibular first molars, extracted because of extensive coronal tissue destruction, were radiographed and stored in 0.1% thymol, at 4°C. Teeth were excluded from this study if they exhibited a distance greater than 3 mm between the cement-enamel junction and the root bifurcation, previous endodontic manipulation, incomplete root formation, calcification, internal or external resorption, or curvature greater than 40 degrees.

Coronal access was performed using a #1014 diamond bur (KG Sorensen -São Paulo - SP - Brazil) followed by a #3082 diamond bur (KG Sorensen). Mesial root canals were accessible to K#10 and K#15 files (Dentsply Maillefer, Ballaigues, Switzerland) after

coronal access. Then, the teeth were embedded in acrylic resin (JET Resin - São Paulo - SP - Brazil) blocks using a flask system measuring 17 mm in height and 12 mm in width, according to the technique proposed by previous studies.^{11,12}

The flask could be opened or closed by 2 guiding pins and screws that provided stability to the assembly, preventing undesirable movements of the resin blocks. After acrylic resin curing, the blocks were removed and placed on an Isomet 1000 precision saw (Buehler - Lake Bluff - Chicago - IL -USA) equipped with a 0.3 mm diamond disc (Extec Corporation - Enfield - Connecticut - CT, USA). A horizontal section was made 3 mm below the cement-enamel junction.

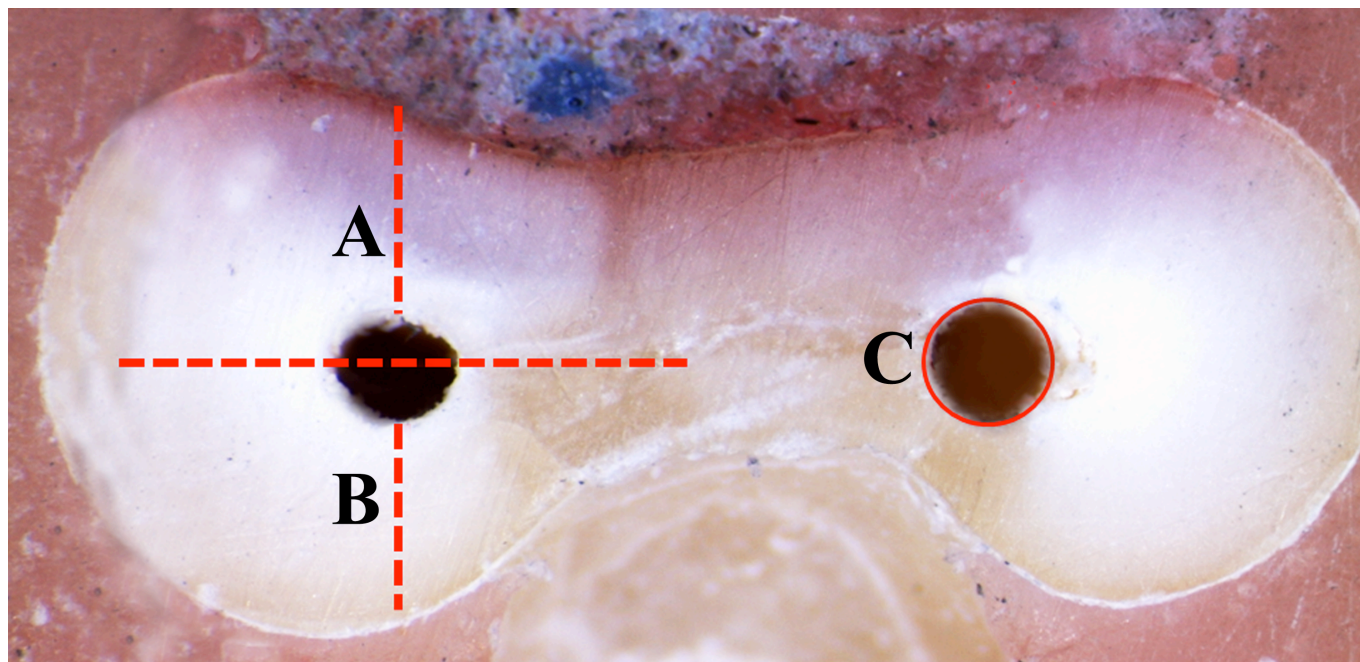
The blocks were separated and the cervical areas of the teeth were photographed using a stereomicroscope, at 30 X (Leica Microsystems, Wetzlar, Germany) with LAS EZ software at a 1:4 scale for initial measurements. The coronal portion was delimited with two marks prepared by 1/4 diamond bur (KG Sorensen, São Paulo, SP, Brazil), one at the mesial portion and the other one at the distal portion (furcal region), creating an imaginary line passing through the centre of each mesio-buccal and mesio-lingual canal.

The resin blocks were reassembled in the flask and divided into 3 groups, according

to the instruments used for coronal pre-enlargement: G1 (n=20 root canal, in 10 mesial roots) - LA Axxess, instrument size 20/0.06; G2 (n=20 root canal, in 10 mesial roots) - CP Drill,

unique size; and G3 (n=20 root canal, in 10 mesial roots) - Gates-Glidden burs # 1 and #2.

Figure 1: Representative image of coronal root canal third. (A) mesial wall; (B) distal wall; (C) root canal area analysed.



A 15 K-file was inserted into the embedded teeth with anti-curvature movements before the instruments were used, in order to verify the orientation of the canal axis and the absence of obstructions or ledge. For coronal pre-enlargement, all the evaluated instruments were inserted 1 mm beyond the crosscut area (4 mm below the cement-enamel junction). The rotary instruments were used in a low speed rotation motor (Dabi - Ribeirão Preto - SP - Brazil), at 12,000 rpm for all instruments.

After using the instrument in each group, the resin blocks with the teeth were removed from the flask and new images were taken. The pre and post-instrumentation images of the coronal root canal were measured by Image Tools 3.01 software (UTHSCSA, San Antonio, TX, USA). The total area of the root canal before and after the use of each instrument was measured. Then, the increase of the instrumented area in mm² was calculated. Furthermore, the thickness of the mesial and distal walls (danger zone) was established. Data were submitted to ANOVA and Tukey test at a 5% significance level.

RESULTS

There were no differences among the instruments for the dentin removal at the mesial wall ($p>0.05$). But at the distal wall, LA Axxess removed significantly more dentin than CP Drill and Gates-Glidden ($p<0.05$). On the

other hand, Gates-Glidden promoted higher dentin removal than CP Drill ($p<0.05$), only in distal wall. There were no perforations in the evaluated groups.

Table 1: Average and standard deviation (mm) of dentin removal in the mesial and distal walls and increased area (mm²) after use of several instruments to coronal pre-enlargement.

GROUPS	MESIAL WALL	DISTAL WALL	INCREASED AREA
G1 (LA Axxess)	0.142 (0.093) ^a	0.327 (0.254) ^a	0.477 (0.275) ^a
G2 (CP Drill)	0.143 (0.119) ^a	0.187 (0.073) ^b	0.360 (0.140) ^b
G3 (Gates-Glidden)	0.133 (0.110) ^a	0.226 (0.130) ^c	0.373 (0.137) ^b

For the increased area analysis, there were significantly differences among the instruments after the coronal pre-enlargement. The LA Axxess increased significantly the area of the coronal third from the root canal, in comparison to the CP Drill and Gates-Glidden ($p<0.05$). Gates-Glidden promoted similar increase of the area of coronal third from the root canal, in comparison to CP Drill ($p>0.05$). Table 1 shows the mean and standard deviation of dentin removal (mm), in the mesial and distal walls, and an increase of the area of the coronal root canal (mm²) after the use of several rotary instruments.

DISCUSSION

There are no differences among the several instruments in relation to amount of dentin removed in the mesial wall. In distal

wall, there were differences among the three instruments, whereas LA Axxess promoted the highest and CP Drill promoted the lowest dentin removal. There were differences among the three instruments in the coronal pre-enlargement, in sequence, LA Axxess > Gates-Glidden = CP Drill.

Several methodologies have described the assessment of the pre-enlargement effects using rotary instruments in the dentin wall thickness.^{3-5,11} In this study, all steps were similar to methodology described by Bramante et al.¹² This methodology allows sectioning the teeth, and the root canal area and the thickness of the dentin walls may be compared before and after instrumentation by digitalized images.¹¹

The dentin removal of mesial wall was similar among groups, once the instruments

promoted dentin removal on average from 0.133 mm to 0.143 mm. Nevertheless, the LA Axxess burs had higher dentin removal regarding the distal face, whereas the CP Drill burs had the lowest. These findings are in agreement with previous studies that reported caution to use these instruments.^{5,11}

On the other hand, the Gattes-Glidden burs exhibited average values of dentin removal from 0.133 and 0.226 mm, for mesial and distal walls, respectively. This fact is due to the design of their active long, which is short (2.1 to 4.0 mm), elliptical and only with three cutting edges, promoting dentinal removal uniformly.^{13,14}

LA Axxess and CP Drill have active long of 12 mm and 7 mm, respectively. These instruments can be used for dentinal removal in mesial wall, as well as in distal wall through anticurvature cinematic.¹⁴ These characteristics promote a cinematic difference to Gates-Glidden burs, which use only straight up and down motion.

Even with different characteristics, no differences in the increased area were observed between GG and CP Drill. Despite the small diameter of active long of the CP Drill instrument, this instrument promoted an increased area of radicular coronal third similar to the one promoted by GG. This characteristic makes this instrument safe and suitable option for coronal pre-enlargement.¹⁵

Therefore, within the limitations of this study, it is possible to observe that all instruments increased the root canal area and removed dentin from the mesial and the distal wall (danger zone). Caution should be taken when using LA Axxess. The safest instrument was CP Drill.

CONCLUSION

CP Drill was the safest instrument to coronal pre-enlargement, promoting similar increase of coronal area like GG burs, and lower dentinal removal of the distal walls (danger zone) in comparison to LA Axxess or GG.

REFERENCES

1. Schilder H. Cleaning and shaping the root canal. *Dent Clin North Am* 1974;18:269-96.
2. Nakamura VC, Cai S, Candeiro GT, Ferrari PH, Caldeira CL, Gavini G. Ex vivo evaluation of the effects of several root canal preparation techniques and irrigation regimens on a mixed microbial infection. *Int Endod J*. 2013;46:217-24.
3. Barroso JM, Guerisoli DM, Capelli A, Saquy PC, Pécora JD. Influence of cervical preflaring on determination of apical file size in maxillary premolars: SEM analysis. *Braz Dent J*. 2005;16:30-4.
4. Pecora JD, Capelli A, Guerisoli DMZ, Spanó JCE, Estrela C. Influence of cervical preflaring on apical file size determination. *Int Endod J*. 2005; 38:430-5.

5. Sanfelice CM, da Costa FB, Reis Só MV, Vier-Pelisser F, Souza Bier CA, Grecca FS. Effects of four instruments on coronal pre-enlargement by using cone beam computed tomography. *J Endod.* 2010;36:858-61.
6. Maia-Filho EM, Souza EM, Meneses EO. Effect of Gates Glidden, La Axxess, SX and ultrasound on the circularity and area of mesial canals of mandibular molars. *RSBO.* 2013;10:234-9.
7. Ashwini TS, Bhandari S. The influence of cervical preflaring of root canal on determination of initial apical file using Gates Glidden drills, Protaper, Race and diamond-coated Galaxy files. *J Contemp Dent Pract.* 2012;13:554-8.
8. Khan IU, Sobhi MB. Detecting the apical constriction in curved mandibular molar roots--preflared versus nonflared canals. *J Ayub Med Coll Abbottabad.* 2003;15:47-9.
9. Zuckerman O, Katz A, Pilo R, Tamse A, Fuss Z. Residual dentin thickness in mesial roots of mandibular molars prepared with Lightspeed rotary instruments and Gates-Glidden reamers. *Oral Surg Oral Med Oral Pathol Oral Radiol Endod.* 2003;96:351-5.
10. Isom TL, Marshall JG, Baumgartner JC. Evaluation of root thickness in curved canals after flaring. *J Endod.* 1995;21:368-71.
11. Duarte MAH, Bernardes RA, Ordinola-Zapata R, Vaconcelos BC, Bramante CM, Moraes IG. Effects of Gates-Glidden, LA Axxess and orifice shaper burs on the cervical dentin thickness and root canal área of mandibular molars. *Braz Dent J* 2011;22:28-31.
12. Bramante CM, Berbert A, Borges RP. A methodology for evaluation of root canal instrumentation. *J Endod* 1987;13:243-5.
13. Schmitz Mda S, Santos R, Capelli A, Jacobovitz M, Spanó JC, Pécora JD. Influence of cervical preflaring on determination of apical file size in mandibular molars: SEM analysis. *Braz Dent J.* 2008;19:245-51.
14. Abou-Rass M, Frank A, Glick DH. The anticurvature filing method to prepare the curved root canal. *J Am Dent Assoc* 1980;101:792-4.
15. Tennert C, Herbert J, Altenburger MJ, Wrbas K-T. The effect of cervical preflaring using different rotary nickel-titanium systems on the accuracy of apical file size determination. *J Endod* 2010;36:1669-72.