



## Strathprints Institutional Repository

**Bolster, Nigel M and Giardini, Mario E and Livingstone, Iain AT and Bastawrous, Andrew (2014) How the smartphone is driving the eye-health imaging revolution. Expert Review of Ophthalmology, 9 (6). pp. 475-485. ISSN 1746-9899 , <http://dx.doi.org/10.1586/17469899.2014.981532>**

This version is available at <http://strathprints.strath.ac.uk/50949/>

**Strathprints** is designed to allow users to access the research output of the University of Strathclyde. Unless otherwise explicitly stated on the manuscript, Copyright © and Moral Rights for the papers on this site are retained by the individual authors and/or other copyright owners. Please check the manuscript for details of any other licences that may have been applied. You may not engage in further distribution of the material for any profitmaking activities or any commercial gain. You may freely distribute both the url (<http://strathprints.strath.ac.uk/>) and the content of this paper for research or private study, educational, or not-for-profit purposes without prior permission or charge.

Any correspondence concerning this service should be sent to Strathprints administrator: [strathprints@strath.ac.uk](mailto:strathprints@strath.ac.uk)

For Production:

*Expert Review of Ophthalmology*

REVIEW

Issue 0906

9 figures – Figs 1-7 reproduced with permissions, others are original

US ENGLISH

**How the smartphone is driving the eye-health imaging revolution**

**Bolster, Nigel M**

Corresponding Author

University of Strathclyde - Biomedical Engineering  
Wolfson Centre 106 Rottenrow Street , Glasgow G4 0NW  
United Kingdom

**Giardini, Mario E**

University of Strathclyde - Biomedical Engineering  
Wolfson Centre 106 Rottenrow Street , Glasgow G4 0NW  
United Kingdom

**Livingstone, Iain A. T.**

Glasgow Centre for Ophthalmic Research  
Tennent Institute of Ophthalmology Greater Glasgow & Clyde Gartnavel General Hospital , Glasgow  
G12 0YN  
United Kingdom

**Bastawrous, Andrew**

London School of Hygiene and Tropical Medicine - International Centre for Eye Health (ICEH)  
Clinical Research Department Faculty of Infectious & Tropical Diseases Keppel Street, London WC1E  
7HT, United Kingdom

**Abstract**

The digitization of ophthalmic images has opened up a number of exciting possibilities within eye care such as automated pathology detection, as well as electronic storage and transmission.

However, technology capable of capturing digital ophthalmic images remains expensive. We review the latest progress in creating ophthalmic imaging devices based around smartphones, which are readily available to most practising ophthalmologists and other medical professionals. If successfully developed to be inexpensive and to offer high quality imaging capabilities, these devices will have huge potential for disease detection and reduction of preventable blindness across the globe. We discuss the specific implications of such devices in high, middle and low-income settings.

**Keywords**

Smartphone, imaging, mHealth, fundoscopy, ophthalmoscopy, anterior segment imaging, slit-lamp, retina, mobile phone, telemedicine

## Introduction

It has long been well established that ophthalmic imaging techniques are of high value to ophthalmologists, general practitioners and other specialists alike[1, 2]. Retinal imaging, for example, is important for the detection of eye diseases, such as diabetic retinopathy[3, 4], age-related macular degeneration[5] and glaucoma[1, 6], as well as the characteristic changes in the fundus that are related to systemic diseases, such as hypertension[7, 8], malaria[9, 10] and neurological conditions[11]. For this reason every medical doctor is expected to be able to use basic ophthalmic imaging devices such as the direct ophthalmoscope[12].

Ophthalmic images have been photographically recorded since the end of the 19<sup>th</sup> century[13, 14]. The relatively recent introduction of digital imaging technologies has accelerated the advancement of ophthalmic image capture by allowing fast and exact duplication, electronic storage and transmission and instant access to results by dispensing with the need for film development. Digitization of ophthalmic images has also allowed these images to easily interface with computing resources. Consequently, a field of automated image analysis directed at detecting pathology, such as the presence and stage of diabetic retinopathy[15-17], glaucoma[18, 19] and retinopathy of prematurity (ROP)[20], has emerged, presenting the prospect of screening programmes where the number of images requiring manual assessment is dramatically reduced[21-25].

The advancement of mobile telephony in recent years has been rapid and extensive. In particular, the development of smartphones has taken mobile connectivity to a new level. Smartphones are mobile devices which combine the simple communication capabilities of their predecessors, namely voice calls, short text and multimedia message services (SMS and MMS), with capabilities including an operating system allowing application installation and upgrade[26], more powerful computer processing, high resolution digital cameras and global positions systems (GPS), as well as accelerometers and other sensors. As such they are a rich technological resource which, due to their size and intended use, is carried by their user to wherever they go.

1  
2  
3 Cellular phones with built in digital cameras have been manufactured since the beginning of the 21<sup>st</sup>  
4  
5 century[27]. Improvement in the quality of the images captured by phone-mounted cameras has  
6  
7 been quick and profound in the time since their introduction. Recent handsets are capable of  
8  
9 capturing images of quality comparable to that of mainstream digital cameras, with Nokia's Lumia  
10  
11 1020, for example, including a 41 megapixel camera sensor[28]. Acquisition of high quality videos by  
12  
13 cellular phones has also been developed, with most modern handsets being capable of recording at  
14  
15 1080p resolution (1920 x 1080 pixels per frame), with the latest handsets, such as the Samsung  
16  
17 Galaxy Note 3, being able to record 4K video (4096 x 2160 pixels per frame) [29].  
18  
19

20  
21 It was reported in 2013 that 65% of U.S. adults owned a smartphone, with that proportion being  
22  
23 expected to continue rising over the coming months and years[26]. This trend is not only noted in  
24  
25 high-income countries but also in middle and low-income countries[30]. China, for example, is  
26  
27 reported to have 95% cell phone ownership and 37% smartphone ownership whereas Kenya has  
28  
29 82% cell phone ownership and 19% smartphone ownership[31]. There is therefore no question that  
30  
31 smartphones are increasingly becoming part of people's lives globally. In the specific case of medical  
32  
33 professionals they offer particular promise, with it being reported as early as 2010 that in the United  
34  
35 Kingdom, for example, 80% owned a smartphone[32]. Consequently the new field of mobile health,  
36  
37 widely known as "mHealth" has emerged[33-35]. Potential applications of mHealth include patient  
38  
39 assessment tools, patient education tools, healthcare professional education and reference tools  
40  
41 and patient record and administration tools[36].  
42  
43  
44

45  
46 The quality of an image captured by a digital camera relies on a number of factors. Firstly the size,  
47  
48 separation and number of picture elements (pixels) on the camera detector. However these sensors  
49  
50 have advanced such that the most modern smartphone cameras' image quality is limited by factors  
51  
52 relating to their optics rather than their detector. The "sharpness" of a digital image, that is the  
53  
54 contrast at a particular spatial frequency, (known as the modulation transfer function or the point  
55  
56 spread function) is fundamentally limited by diffraction[37]. How close a given camera will come to  
57  
58  
59  
60

1  
2  
3 achieving this fundamental limit depends on the quality of its optics. Further to this, higher order  
4  
5 aberrations such as spherical, astigmatic and comatic aberration, field curvature and distortion all  
6  
7 reduce the quality of the image formed on the detector[38]. The challenges faced by the engineers  
8  
9 who design smartphone camera optics are substantial. Camera modules are generally required to  
10  
11 be low-cost and capture a wide range of possible scenes, necessitating that lower quality plastic  
12  
13 components be used. The whole camera is also required to be thin, putting a tight constraint on the  
14  
15 maximum distances allowed between components. Furthermore, smartphone cameras have a fixed  
16  
17 focal length and fixed aperture size with a fairly large “F-number” (the ratio of the focal length to  
18  
19 diameter of the entrance pupil, which describes the camera’s ability to collect light)[39] typically  
20  
21 ranging from 2.0 to 2.4[40]. It should also be noted that how any digital camera encodes and  
22  
23 compresses the image can also lead to loss of image quality[41]. As such the firmware and software  
24  
25 of the device also play an important role in the quality of any digital image. Nevertheless, despite  
26  
27 the many difficulties associated with the design of smartphone cameras, the increase in image  
28  
29 quality captured by these devices in recent years has been so profound that their use in applications  
30  
31 such as medical imaging is now a genuine possibility, which ought to be given real consideration.  
32  
33

34  
35  
36 In this paper we discuss recent efforts to enable smartphones to capture digital ophthalmic images  
37  
38 and thus to increase healthcare professionals’ ability to attain the advantages of mHealth within the  
39  
40 specialism of ophthalmology. In our analysis, we include commercially available solutions, where  
41  
42 they exist, as well as recently reported research in this area.  
43  
44

#### 45 **Displaying Ophthalmic Images with Smartphones**

46  
47  
48 A simple question which should be asked of smartphones is whether they are capable of displaying  
49  
50 ophthalmic images, captured using conventional ophthalmic digital cameras, of high enough quality  
51  
52 to allow assessment of a patients’ eye health. Kumar et al.[42] conducted a study where 110 fundus  
53  
54 images of diabetic patients captured using a non-mydratic retinal camera (8MP charge-coupled  
55  
56 device (CCD) camera, model TRC-NW300, Topcon, Tokyo, Japan), were stored in a secure picture  
57  
58  
59  
60

1  
2  
3 archiving and communication system. They were then assessed by viewing on both the gold  
4  
5 standard, a desktop workstation (Optiplex 755, Dell, Round Rock, Texas, USA) via a secure website,  
6  
7 and an iPhone 4 (Apple Inc, Cupertino, CA, USA) via second generation (2G) cellular networks. The  
8  
9 images were then assessed independently by two ophthalmologists. The detection of retinopathy  
10  
11 related were found to be in strong agreement between the phone display and desktop monitor, with  
12  
13 the sensitivity (true positives/(true positive + false negative)) and specificity (true negatives/(true  
14  
15 negative + false positives)) being greater than 89% except for the detection of microaneurysms.  
16  
17 Agreement regarding microaneurysms was a little lower one ophthalmologist recording a sensitivity  
18  
19 and a specificity of 72.3% and 89.6% respectively and the other ophthalmologist recording 72.2%  
20  
21 and 80.0% respectively. Thus it is clear that microaneurysms are more difficult to detect on an  
22  
23 iPhone 4 compared with a standard display. It should also be noted that handsets released since the  
24  
25 study was conducted have improved image quality and size. The iPhone 6 Plus (Apple Inc,  
26  
27 Cupertino, CA, USA), for example, has a 5.5-inch (diagonal) display with a contrast ratio of 1300:1  
28  
29 and a pixel density of 401 pixels per inch (ppi) compared to the iPhone 4's 3.5-inch display with  
30  
31 respective values of 800:1 and 326ppi[42,43]. It would thus be interesting to see whether future  
32  
33 studies record an improvement in microaneurysm detection compared to the discussed study or  
34  
35 whether the disagreement between devices is due to factors unrelated to display  
36  
37 quality. Nevertheless, the authors concluded that the ophthalmic images transmitted through both  
38  
39 smartphone and internet techniques matched well with each other. Thus, it should therefore be  
40  
41 noted that, even if it were impossible to capture ophthalmic images using a smartphone camera,  
42  
43 images captured by means of conventional digital ophthalmic photography may, at least, be  
44  
45 assessed by viewing these on a smartphone screen. This in itself is a step forward, given the  
46  
47 prevalence of smartphones amongst doctors[32], as it allows such images to be instantly shared  
48  
49 between medical professionals, regardless of their location. It also clarifies that any sufficiently high-  
50  
51 quality images captured using the following techniques may be viewed on the smartphone in situ as  
52  
53 well as on conventional displays upon exporting.  
54  
55  
56  
57  
58  
59  
60

1  
2  
3 **Indirect Ophthalmoscopy** Lord et al. reported a method for capture of fundus images on a  
4  
5 smartphone apart from a slit-lamp, using standard equipment[44]. Their technique involved holding  
6  
7 a 20D lens in one hand, as per traditional indirect ophthalmoscopy, whilst holding and positioning a  
8  
9 pen light, for illumination, and an iPhone, for image capture, in the other hand. An example of an  
10  
11 image acquired using this technique is shown in Figure 1. This technique was found to be rather  
12  
13 cumbersome and thus the acquisition of high quality images difficult[45]. However the widespread  
14  
15 introduction of smartphone designs incorporating a light emitting diode (LED) flash on the handset's  
16  
17 back face, alongside the phone's camera, allowed for the pen light to be dispensed with and a  
18  
19 technique that was much more comfortable for the ophthalmologist, and hence more effective,  
20  
21 could be demonstrated, as shown in Figure 2[45]. Using the stock iOS camera application while  
22  
23 capturing a video stream with flash enabled, provides a consistent coaxial light source. The use of  
24  
25 video also allows individual frames to be extracted after acquisition for use as still images, meaning  
26  
27 the practitioner need only get a good view of the fundus at some point during the procedure and  
28  
29 does not require an additional action to activate the shutter-release on top of achieving the desired  
30  
31 view.  
32  
33

34  
35 The ease-of-use of the above technique was further enhanced by Haddock et al.'s introduction of  
36  
37 the 'Filmic Pro' (Cinegenix LLC, Seattle, WA, USA) specialist smartphone photography  
38  
39 application[46]. The software allows independent control of the focus, exposure and flash light  
40  
41 intensity during video filming. Still images could then be extracted from the video after recording.  
42  
43 They reported that this allowed high quality images of fundus images of animals, as well as  
44  
45 comatose and awake adults, to be more consistently produced compared to the methods described  
46  
47 above.  
48  
49

50  
51 Similarly, Lin et al. were able to capture fundus images of neonatal patients using the camera and  
52  
53 LED flash of an iPhone 4S and HTC One (HTC Corp, New Taipei City, Taiwan) in conjunction with a  
54  
55 30D lens[47]. Specifically, the authors investigated the feasibility of using smartphones in screening  
56  
57 for retinopathy of prematurity (ROP). Although the technique still required scleral indentation, a  
58  
59  
60



1  
2  
3 method which often causes the patient distress, the use of smartphones allowed photographic  
4  
5 records to be made, as opposed to drawings or written notes alone, without the use of an expensive  
6  
7 retinal camera. An example image from the study, from which the authors were able to detect plus  
8  
9 disease is shown in Figure 3. The study therefore shows the considerable advantage of techniques  
10  
11 involving smartphones in ROP screening, particularly given the importance of good record keeping  
12  
13 when monitoring neonatal patients' retinal development.  
14  
15

16  
17 Myung et al. recently developed a prototype which aims to aid digital image capture from indirect-  
18  
19 ophthalmoscopy using a smartphone[48]. The system, shown in Figure 4, consists of a light-weight  
20  
21 3d printed arm that attaches to an iPhone 5 (Apple Inc, Cupertino, CA, USA) and holds a condensing  
22  
23 lens at an adjustable fixed distance from the camera optic. As per Haddock et al. the authors also  
24  
25 used the 'Filmic Pro' app for video frame extraction and illumination brightness adjustment. The  
26  
27 smartphone's native LED flash was used as light source and the handset's autofocus adjusted for any  
28  
29 differences in participant refractive error. The authors used the system to capture images of firstly,  
30  
31 a model eye, and then latterly a sample of good quality, normal and abnormal fundal images on  
32  
33 dilated study participants. Although the working distance of the system was adjustable, the authors'  
34  
35 found that extending this beyond a certain distance caused overall size and stability issues. They  
36  
37 also found that allowing this distance to be adjusted during imaging greatly reduced the system's  
38  
39 ease of use. Nevertheless, such a solution does appear to offer a feasible means for acquiring digital  
40  
41 images during indirect ophthalmoscopy and promises to be a useful tool for the field  
42  
43  
44 ophthalmologist and even non-specialists.  
45  
46

#### 47 **Anterior Segment Imaging and Slit-lamps**

48  
49  
50 Barsam et al. demonstrated a technique for capturing digital anterior segment images using a  
51  
52 smartphone by simply aligning, by hand, the camera optic of an iPhone 3G (Apple Inc, Cupertino, CA,  
53  
54 USA) with one of the eyepieces of a BM 900 slit lamp[49]. Although this method allowed capture of  
55  
56 digital anterior segment images without the need for an expensive slit-lamp camera (typical cost  
57  
58  
59  
60

1  
2  
3 15000 USD), it is more difficult than the standard technique and still requires a slit-lamp, meaning  
4  
5 the full system is still rather expensive and relatively immobile. Since this study was published, a  
6  
7 host of smartphone slit-lamp adapters have been made commercially available with prices varying  
8  
9 from 75 to 520 USD. It has even been shown that a “Do-it-yourself” adapter can be assembled for  
10  
11 approximately 15 USD using simple, readily available components[50]. Whilst such adapters  
12  
13 improve on Barsam et al.’s study, by removing the need for the user to hold the handset in position  
14  
15 for the duration of the examination, they are still dependent on the availability of a slit-lamp and on  
16  
17 the expertise to use such an instrument. This can often be an issue for acquiring such images  
18  
19 outside of well-equipped ophthalmology department. For example, Myung et al. have recently  
20  
21 demonstrated a means of eliminating the need for a slit-lamp in the acquisition of digital anterior  
22  
23 segment images[51]. The authors first attempted to acquire images by attaching a commercially  
24  
25 available smartphone camera macro lens and using the native flash of an iPhone 5 at a working  
26  
27 distance of approximately 2.5cm from the subject’s eye. However it was found that, even when  
28  
29 using Filmic Pro to control the illumination intensity, the brightness of the flash was too  
30  
31 uncomfortable for study participants at the close working distance necessitated by the macro-lens’  
32  
33 focal length. This prompted the authors to develop a simple adapter, Figure 5, which combined the  
34  
35 macro lens with an external LED light source with a brightness selected for patient comfort. The  
36  
37 adapter is pocket-sized and can be easily attached and detached from any handset. There are a  
38  
39 number of limitations to the adapter, notably that it does not have the ability to create a slit of light  
40  
41 that can be used to estimate the depth of a corneal pathology or for capturing cells or flare. Also, the  
42  
43 relatively short working distance results in the necessity for disinfection between uses. However the  
44  
45 authors were able to use this system to capture high quality anterior segment images of subjects  
46  
47 displaying a number of different pathologies, allowing them to claim that they had sufficient quality  
48  
49 images with regards to the clarity of the cornea, quality of the epithelium, fluorescein uptake, state  
50  
51 of the conjunctiva, shape of the pupil, health of the iris, presence or absence of a hyphaema or  
52  
53 hypopyon in the anterior chamber and the appearance of the eye-lids and lashes. Thus, given the  
54  
55  
56  
57  
58  
59  
60

1  
2  
3 low production cost, ease of use and reported quality of images this design offers the potential for a  
4  
5 very useful anterior segment imaging tool, applicable to a variety of settings, included those in which  
6  
7 resources are limited.  
8  
9

10 Two notable, commercially available smartphone-compatible slit lamps are the PSL One and Classic  
11  
12 (Keeler, Windsor, U.K.). Both these models have many of the features of a regular slit lamp with the  
13  
14 added benefit of being lightweight and durable[52]. The combination of these slit lamp models and  
15  
16 Keeler's iPhone 4 adapter provides the user with the genuine ability to conduct mobile digital slit  
17  
18 lamp photography. However, with the portable slit lamps costing between 2750 GBP[53] and 4000  
19  
20 GBP[54] and the adapter costing an additional 90 GBP[55] this remains an option that has a price  
21  
22 beyond that which most non-specialists are able to afford. It has been reported that the slit lamp  
23  
24 adapter is also compatible with the Hagg-Streit 900 BM and SL-3F (Topcon Corp., Tokyo, Japan) slit  
25  
26 lamps if a varying degree of adaptation is applied[56].  
27  
28

### 30 **Direct and Monocular Indirect Ophthalmoscopy**

31  
32  
33 Currently, the most widely used smartphone compatible monocular indirect ophthalmoscope is the  
34  
35 'Panoptic' with 'iExaminer' attachment (Welch-Allyn Inc., Skaneateles Falls, NY, USA). The Panoptic  
36  
37 itself, according to its manufacturer, is of a design that improves upon that of a classical monocular  
38  
39 indirect ophthalmoscope by introducing 'Axial PointSource Optics' allowing a field-of-view of 25°  
40  
41 (compared to approximately the 5° of conventional direct ophthalmoscopes) along with an increased  
42  
43 magnification[57], with the distance between the operator's and patient's eye being a fixed distance  
44  
45 between two eye-pieces, reducing the complexity of the procedure compared to standard  
46  
47 ophthalmoscopes. Indeed, it has been reported that whilst accuracy of diagnosis for various  
48  
49 pathologies remains at least as good compared to conventional direct ophthalmoscopy, ease of use  
50  
51 and patient comfort are significantly increased[58, 59].  
52  
53  
54  
55  
56  
57  
58  
59  
60

1  
2  
3  
4  
5  
6  
7  
8  
9  
10  
11  
12  
13  
14  
15  
16  
17  
18  
19  
20  
21  
22  
23  
24  
25  
26  
27  
28  
29  
30  
31  
32  
33  
34  
35  
36  
37  
38  
39  
40  
41  
42  
43  
44  
45  
46  
47  
48  
49  
50  
51  
52  
53  
54  
55  
56  
57  
58  
59  
60

Blanckenberg et al. used a Panoptic which was customised, as shown in Figure 6, so to allow fundus images to be captured using a wireless enabled digital camera[60]. These images were then communicated to a mobile phone via Wi-Fi and uploaded to a web application via 2G/3G cellular networks. An image analysis algorithm was then applied which determined whether the images were of acceptable quality and the results reported back to the field via SMS. The system was thus capable of capturing images with a 25° viewing angle for a cost significantly less than the commercial options available at the time, the authors estimating that twelve healthcare centres could be equipped with such a system for the same cost as a single standard fundus camera, however they noted that even this is a cost which the district health service in Cape Town, where the trial was conducted, could not afford.

Following the work of Blanckenberg et al., Welch Allyn released the 'iExaminer' attachment in February 2013. The attachment is an adapter that allows an iPhone 4 or 4s to be inserted in place of the operator's eyepiece allowing fundus images to be viewed through the phone's camera, thus allowing digital images to be captured and distributed via wireless or cellular networks. To date the iExaminer is the only ophthalmoscope capable of smartphone integration which has achieved FDA approval[61]. However as the instrument is only compatible with the iPhone 4 and 4s models, the system is already two generations behind the smartphone market with Welch Allyn expressing that a version compatible with the iPhone 5 series will not be available in 2014. The Panoptic, iExaminer and 'pro' application (enabling emailing, printing, and storing additional patient files within the storage capacity of the phone) together typically cost the end user more than 700 USD in total (www.medisave.com), putting it in the premium ophthalmoscope price range.–

The 'Ocular Cellscope' (Maamari et al, Figure 7) entails independent LEDs, with multiple lenses and polarizers, in a configuration similar to that of the Panoptic with iExaminer, producing mydriatic images comparable with commercial dedicated desktop fundus photography systems (Topcon TRC-50EX )[62]. Working with the iPhone 4S (Apple Inc, Cupertino, CA), the Ocular Cellscope captures

1  
2  
3 high resolution (2652x2448 pixel) images with a wide 55 degree field of view in a single capture, with  
4  
5 potential to expand this field using digital mosaic techniques of multiple captures.  
6  
7

8 Giardini et Al. have demonstrated a novel approach in creating a smartphone adapter, shown in  
9  
10 Figure 8, which deflects the phone's LED flash in a way so that a light source co-axial to the phone's  
11  
12 camera is created, allowing fundus images to be displayed and captured using the phone's stock  
13  
14 camera app or using bespoke software[63]. An example image is shown in Figure 9 alongside that of  
15  
16 a standard retinal camera for comparison. As the operator is not required to put their eye in contact  
17  
18 with an eye-piece the device can be kept at arms' length from the operator whilst images are  
19  
20 captured, increasing comfort for the patient and making the experience less intimidating,  
21  
22 particularly for children. The retina is brought into focus by the camera's autofocus feature by  
23  
24 simply by tapping on the screen. The device can therefore be used by any operator familiar with the  
25  
26 use of a smartphone after a brief induction session, without the need for any clinical training. The  
27  
28 authors demonstrated a design using a Galaxy SIII GT-I9300 (Samsung C&T Corp., Seoul, Republic of  
29  
30 Korea) smartphone. The authors report that interim results for 300 of 2100 dilated eyes imaged in  
31  
32 Nakuru, Kenya show no clinically significant difference between remotely graded vertical cup to disk  
33  
34 ratios measured using the smartphone unit's images compared to those measured using a standard  
35  
36 retinal camera images (DRS+ Haag Streit CenterVue, Italy) ,with a p-value, the probability that  
37  
38 differences occurred by chance, of 0.98. Such low-cost solutions, when compared to existing  
39  
40 smartphone-based solutions, present a potential means for overcoming the cost barriers highlighted  
41  
42 by Blanckenberg et al.[60].  
43  
44  
45  
46  
47

#### 48 **Safety considerations**

49  
50 All of the techniques and devices discussed in this paper require some form of illumination. The safe  
51  
52 limits for the intensity a subject's eye may be exposed to, across the electromagnetic spectrum, are  
53  
54 clearly outlined in ISO15004-2:2007[64]. It is important that, if trying to replicate any of the  
55  
56 techniques detailed in this paper, that the illumination source being used meets these standards. It  
57  
58  
59  
60

1  
2  
3 has been verified that the indirect ophthalmoscopy technique detailed by Bastawrous falls within  
4 these limits when an iPhone 4 is used[65], however it should be noted that some smartphones now  
5 include exceptionally bright xenon flashes[28] and, as such, it is important to check the applied  
6 illumination source's adherence to the referenced standard. If the move to brighter smartphone  
7 flashes becomes a general trend then there may be a need in the future to decouple entirely from  
8 the native flash and use LED sources independent from the flash. Smartphone flashes are, after all,  
9 designed for general purpose photography and not with ophthalmic applications in mind.  
10  
11  
12  
13  
14  
15  
16  
17  
18

### 19 **Expert Commentary**

20  
21 There are currently appropriate commercially available means for ophthalmic specialists to capture  
22 good quality digital images of the anterior segment and fundus using smartphone cameras.  
23  
24 However the specialist skills required and/or the cost of the instruments currently available has thus  
25 far either prevented or severely limited general practitioners and other non-ophthalmic specialists  
26 from also gaining this ability. Whilst inexpensive and non-specialist-friendly means have been  
27 demonstrated, the publication of more robust analyses of these prototypes' capacity to detect  
28 common eye pathology, compared to standard techniques, is required in order to consolidate the  
29 scientific literature validating their clinical use. Hence, these instruments are not currently  
30 commercially available. As such, accessibility to the ability to easily electronically store, share and  
31 display ophthalmic images presently remains reserved to ophthalmic specialists.  
32  
33  
34  
35  
36  
37  
38  
39  
40  
41  
42  
43

### 44 **Five Year View**

45  
46 80% of all blindness is avoidable[66]. There is therefore tremendous scope for reducing blindness  
47 and visual impairment by introducing effective screening in situations where it currently doesn't  
48 exist, dramatically improving millions of lives. The World Health Organization (WHO) recently  
49 announced its 'Global Action Plan 2014-2019' for universal eye-health[67]. This document calls for  
50 "eye care services to become an integral part of primary health care and health systems  
51 development". As commercially available smartphone ophthalmic imaging devices are developed  
52  
53  
54  
55  
56  
57  
58  
59  
60

1  
2  
3 over the next five years, their ease-of-use will approach that of a smartphone. The availability of  
4  
5 such affordable, high quality and easy to use smartphone imaging devices will have profound effects  
6  
7 on eye care worldwide. The resulting changes to eye care will differ depending on the current state  
8  
9 of the healthcare system in question. What is certain, however, is that the global impact to eye-  
10  
11 health will be extensive, providing that adequate resources are supplied to developing and  
12  
13 integrating these emerging devices across all income settings.  
14  
15

16  
17 The initial impact will be in helping to achieve the first objective of the Global Action Plan by  
18  
19 generating evidence with respect to the magnitude and cause of visual impairment, in order to  
20  
21 advocate for greater political and financial commitment by respective governments. The devices will  
22  
23 then become an integral part of on-going screening programmes allowing the continued early  
24  
25 detection of what are presently the main causes of blindness, dramatically reducing the number of  
26  
27 persons suffering from preventable blindness.  
28  
29

30  
31 In the final part of this review we discuss the possible nature of the changes to eye care in low,  
32  
33 middle and high income settings.  
34  
35

36  
37 Diabetic retinopathy is currently the leading cause of blindness in those between the ages of 20 – 74  
38  
39 years in high-income countries, such as the United States[68]. However, a number of high-income  
40  
41 countries lack effective screening programmes for the disease[69, 70]. Given the prevalence of  
42  
43 type-2 diabetes globally[71] the development of a means of screening for and treating patients in  
44  
45 the early stages of the disease is of paramount importance if the development of blindness in  
46  
47 diabetes patients is to be slowed or prevented[72].  
48  
49

50  
51 Use of an ophthalmoscope for funduscopy in a primary healthcare setting is useful for the diagnosis  
52  
53 of a host of eye and non-eye related pathologies. However, those primary healthcare physicians  
54  
55 who are entirely comfortable performing a patient examination using an ophthalmoscope are in the  
56  
57 minority. For example, it has been reported that in Canada only 52.3% of resident family care  
58  
59  
60

1  
2  
3 doctors feel competent in performing funduscopy, even though over 95% felt it was an important  
4  
5 skill to have[73]. The proportions comfortable performing other eye assessments, such as slit-lamp  
6  
7 examination and anterior depth assessment, were equally poor (45% and 10% respectively). The  
8  
9 field data reported by Giardini et al.[63] suggests that there is potential for smartphone imaging to  
10  
11 improve general practitioners' and non-eye specialists' comfort in performing funduscopy and  
12  
13 provides a strong basis for our prediction that smartphone imaging devices similar to their adapter  
14  
15 will greatly increase the proportion of practicing doctors who feel comfortable performing basic  
16  
17 ophthalmic examinations. This can consequently reduce the number of referrals to  
18  
19 ophthalmologists, delivering faster diagnoses and reducing the time and resource burdens on  
20  
21 healthcare systems. This improvement can be further compounded through the introduction of  
22  
23 complementary technologies such as mid-price (1000-3000 USD), portable, smartphone  
24  
25 incompatible fundus cameras, such as the Epipole[ (Epipole Ltd., Rosyth, UK) and CAVCAM (Retivue  
26  
27 LLC, Charlottesville, VA, USA) fundus cameras, the latter of which is based on a commercial digital  
28  
29 single lens reflex (DSLR) camera and produces images comparable to those of current desktop  
30  
31 systems[74].  
32  
33  
34  
35

36 Furthermore, as Giardini et al. report that even operators with a minimal background in  
37  
38 ophthalmology were able to capture sufficiently good quality optic nerve images compared to the  
39  
40 reference standard[62]. Indeed, Farley et al. showed in their study of community health centres that  
41  
42 primary care physicians, advanced practice nurses and physicians' assistants equipped with a  
43  
44 nonmydriatic retinal camera can detect a high instance of microvascular abnormalities in patients,  
45  
46 once given training in identifying such abnormalities from fundus photographs and if provided with  
47  
48 good quality images[75]. We predict that the development of the smartphone based  
49  
50 ophthalmoscopes discussed in this paper will allow cost effective, primary care based screening  
51  
52 programmes to be established, potentially reducing the complications of diabetic retinopathy, along  
53  
54 with a variety of other eye related pathologies such as glaucoma and macular degeneration, in high-  
55  
56 income settings. Such programmes may be particularly important in the case of diabetic retinopathy  
57  
58  
59  
60



1  
2  
3 in the coming years given that it has been predicted that, in the United States alone, the number of  
4  
5 those suffering from the condition is to almost treble by 2050[76].  
6  
7

8 Similarly, papilloedema, which describes swelling of the optic nerve head, a sign of clinically  
9  
10 significant brain involvement in many disease processes, including intra-cranial lesions such as  
11  
12 tumour, haemorrhage or aneurysm, as well as such systemic diseases as malignant hypertension, is  
13  
14 typically detected with direct ophthalmoscopy outside specialist eye centres. Any technology that  
15  
16 improves the ease of examination and transmission of disc images has potential to improve  
17  
18 detection of the many life-threatening conditions in which optic nerve head swelling is a hallmark.  
19  
20  
21  
22 90% of those suffering from visual impairment live in low-income countries[77], where the lowest  
23  
24 concentration of ophthalmologist is found[78, 79]. There is therefore tremendous scope for  
25  
26 smartphone imaging to facilitate the prevention and curing of avoidable blindness in low-income  
27  
28 countries.  
29

30  
31 Patient navigation by the deployment of “community healthcare workers”, that is non-clinical staff  
32  
33 native to a local population or sub-population, has been noted to be an effective means of tackling  
34  
35 many of the issues preventing effective healthcare in low-income settings[80]. Within eye-care such  
36  
37 barriers include lack of community or family support[81], lack of awareness of available  
38  
39 treatments[82] and scepticism of evidence based medicine[83]. Smartphone ophthalmology will  
40  
41 allow such non-clinically trained workers to be armed with the tools that are needed to conduct a  
42  
43 screening programme where they can reach the most isolated patients without the need for  
44  
45 expensive equipment, infrastructure or medical training.  
46  
47

48  
49 The ability to conduct screening programmes for pathologies related to preventable blindness will  
50  
51 allow governments and non-government organisations to mount campaigns to address the  
52  
53 imbalance in the quantity of blind people distributed in low-income regions. We predict that the  
54  
55 ability to do so in combination with the training and retaining of significantly more ophthalmologists  
56  
57  
58  
59  
60

1  
2  
3 and eye-health workers in low-income countries will allow many of these countries to achieve the  
4  
5 Global Action Plan goals laid out by the WHO.  
6  
7

8 Moreover, smartphone ophthalmology will not only allow for a one-off drive to achieve the Global  
9  
10 Action Plan but will also allow the infrastructure to be put in place for long-term, ongoing,  
11  
12 population-wide screening for the causes of preventable blindness in low and middle-income  
13  
14 countries, meaning that the reduction in instances of preventable blindness achieved in order to  
15  
16 reach the WHO's targets can be maintained over the short, medium and long term.  
17  
18

19 Further to this, as in high-income settings, granting non-specialists the ability to comfortably  
20  
21 diagnose eye pathologies will improve the care administered to those who are suffering from  
22  
23 diseases which are not primarily eye problems. Smartphone fundus imaging will, for example,  
24  
25 provide a simple means of diagnosing infectious diseases[9, 10, 84-87] such as dengue fever[87] and  
26  
27 malarial retinopathy[9, 85, 86], a unique set of retinal abnormalities related to cerebral malaria  
28  
29 which is commonly over-diagnosed when other non-imaging tests are used. Therefore smartphone  
30  
31 ophthalmoscopes such as those detailed in this paper promise to provide a feasible means of triage,  
32  
33 even when an ophthalmologist is not present.  
34  
35  
36

37 Furthermore non-communicable disease and their associated complications are not restricted to  
38  
39 high-income settings. Indeed it is in middle-income countries where the highest numbers of those  
40  
41 between the ages of 20 and 79 suffering from type-2 diabetes are to be found, a number which is  
42  
43 due to increase by 50% by 2030[70]. Thus it is in these settings, where practicing ophthalmologists  
44  
45 are few and difficult to access, where population-wide screening for associated complications such  
46  
47 as diabetic retinopathy is most sorely needed. However, given the prevalence of smartphones in  
48  
49 low and middle-income countries and its expected rise[88], so will the proportion of health workers  
50  
51 comfortable with operating smartphone-based ophthalmic devices. Thus such smartphone based  
52  
53 devices will offer a vital tool in preventing an epidemic of non-communicable disease related eye  
54  
55 complications.  
56  
57  
58  
59  
60

1  
2  
3 However, a note of caution must be sounded with regards to our above predictions. Despite its  
4  
5 immense potential, thus far a very low proportion of the relatively numerous mHealth technology  
6  
7 pilot studies conducted have gone on to full integration into healthcare systems[89-91].  
8

9  
10 Smartphone ophthalmic imaging's full potential will only be realised if mHealth in general is  
11  
12 accepted into healthcare systems at large. It has therefore been noted that it is vital that  
13  
14 technologists, clinicians and policy makers work together to develop the common standards and  
15  
16 frameworks that are necessary for integration of mHealth in general[89, 91].  
17

18  
19 Finally, the future development of smartphone imaging for ophthalmology is tied to the future  
20  
21 development of smartphones themselves. Herein lies both one of the greatest opportunities for  
22  
23 these emerging techniques and one of the greatest challenges. The rapid development of  
24  
25 smartphones has seen their image capture quality increase drastically over recent years, as has  
26  
27 processing power, data storage and many other features. However the physical design of  
28  
29 smartphones has also altered greatly, which is a key parameter whose continued evolution could  
30  
31 pose problems for any ophthalmic imaging industry attempting to piggy-back on the mainstream  
32  
33 mobile phone industry. By means of example, established ophthalmic imaging manufactures already  
34  
35 appear to have fallen behind with the failure to implement device updates following the launch of  
36  
37 the iPhone 5 series (the iExaminer, for example, being the only smartphone ophthalmoscope on the  
38  
39 market with FDA approval, has yet to be adapted to integrate with handset updates). As such new  
40  
41 smartphone-centric manufacturers may need to emerge in order to develop an industry capable of  
42  
43 innovating and providing robust clinical verification of these innovations at a pace matching that of  
44  
45 the wider mobile phone market.  
46  
47  
48  
49  
50  
51  
52

#### 53 **Financial & Competing Interests Disclosure**

54  
55 This work has been supported by the Authors' home institutions, namely, University of Strathclyde,  
56  
57 Glasgow Centre of Ophthalmic Research and London School of Hygiene and Tropical Medicine (UK).  
58  
59  
60

1  
2  
3 The Authors' work is also supported by The Queen Elizabeth Diamond Jubilee Trust. The Authors  
4  
5 have no other relevant affiliations or financial involvement with any organization or entity with a  
6  
7 financial interest in or financial conflict with the subject matter or materials discussed in the  
8  
9 manuscript apart from those disclosed.  
10

11  
12  
13  
14  
15 **Key Issues: 8 – 10 bullet points summarizing the review**  
16

- 17  
18  
19  
20  
21  
22  
23  
24  
25  
26  
27  
28  
29  
30  
31  
32  
33  
34  
35  
36  
37  
38  
39  
40  
41  
42  
43  
44  
45  
46  
47  
48
- Smartphones, mobile devices capable of telephony, installing and running software applications are evolving towards being ubiquitous devices owned by large portions of the global population.
  - Studies have shown that display quality on smartphones is sufficient to assess ophthalmic images with equal or better quality than desktop monitors.
  - Smartphones are increasingly being fitted with high quality digital cameras.
  - A number of hardware solutions have been developed which allow anterior segment, indirect and direct ophthalmoscopy images to be captured using a smartphone camera.
  - Several studies have so far reported smartphone ophthalmic imaging as having comparable quality to reference standards.
  - Commercially available solutions remain above the affordability threshold for many settings.
  - There has been recent progress which suggests that in the coming one to three years genuinely inexpensive solutions may emerge.
  - The benefits of these devices will be felt across high, middle and low income settings.

49  
50 **References**  
51

- 52  
53  
54  
55  
56  
57  
58  
59  
60
1. Chatziralli IP, Kanonidou ED, Keryttopoulos P et al. The value of fundoscopy in general practice. The open ophthalmology journal, 6, 4 (2012)
  2. Welch E. No fundoscopy, no defence. MPS Casebook, 22(2) (2014)
  3. Fong DS, Aiello L, Gardner TW et al. Retinopathy in diabetes. Diabetes care, 27(suppl 1), s84-s87 (2004)

- 1
- 2
- 3
4. Tarr JM, Kaul K, Wolanska K et al. Retinopathy in diabetes. In: Diabetes. (Springer, 2013) 88-106
5. Lim LS, Mitchell P, Seddon JM et al. Age-related macular degeneration. *The Lancet*, 379(9827), 1728-38)
6. Kwon YH, Fingert JH, Kuehn MH et al. Primary Open-Angle Glaucoma. *New England Journal of Medicine*, 360(11), 1113-24 (2009)
7. Liew G, Wong TY, Mitchell P et al. Retinopathy predicts coronary heart disease mortality. *Heart*, 95(5), 391-4 (2009)
8. Sairenchi T, Iso H, Yamagishi K et al. Mild Retinopathy Is a Risk Factor for Cardiovascular Mortality in Japanese With and Without Hypertension The Ibaraki Prefectural Health Study. *Circulation*, 124, 2502-11 (2011)
9. Beare NAV, Taylor TE, Harding SP et al. Malarial Retinopathy: A Newly Established Diagnostic Sign in Severe Malaria. *The American Journal of Tropical Medicine and Hygiene*, 75(5), 790-7 (2006)
10. Lynn WA, Lightman S. The eye in systemic infection. *The Lancet*, 364(9443), 1439-50)
11. Bidot S, Bruce BB, Newman NJ et al. Nonmydriatic retinal photography in the evaluation of acute neurologic conditions. *Neurology: Clinical Practice*, 3(6), 527-31 (2013)
12. Benbassat J, Polak BCP, Javitt JC. Objectives of teaching direct ophthalmoscopy to medical students. *Acta Ophthalmologica*, 90(6), 503-7 (2012)
13. Gerloff O. Über die Photographie des Augenhintergrundes. *Zeitschrift für Psychologie und Physiologie der Sinnesorgane*, 29, 397-403 (1891)
14. Scheimpflug T. Die Verwendung des Skioptikons zur Herstellung von Karten u. Plänen aus Photographien (1898)
15. Mookiah MRK, Acharya UR, Chua CK et al. Computer-aided diagnosis of diabetic retinopathy: A review. *Computers in Biology and Medicine*, 43(12), 2136-55 (2013)
16. Winder RJ, Morrow PJ, McRitchie IN et al. Algorithms for digital image processing in diabetic retinopathy. *Computerized Medical Imaging and Graphics*, 33(8), 608-22 (2009)
17. Abramoff MD, Garvin MK, Sonka M. Retinal imaging and image analysis. *Biomedical Engineering, IEEE Reviews in*, 3, 169-208 (2010)
18. Nayak J, Acharya U R, Bhat PS et al. Automated Diagnosis of Glaucoma Using Digital Fundus Images. *J Med Syst*, 33(5), 337-46 (2009)
19. Bock R, Meier J, Nyúl LG et al. Glaucoma risk index: Automated glaucoma detection from color fundus images. *Medical Image Analysis*, 14(3), 471-81 (2010)
20. Aslam T, Fleck B, Patton N et al. Digital image analysis of plus disease in retinopathy of prematurity. *Acta Ophthalmologica*, 87(4), 368-77 (2009)
21. Prasanna PJ, Shubham, Bhagatt N, Madabhushi A. Decision Support System for Detection of Diabetic Retinopathy Using Smartphones. *7th International Conference on Pervasive Computing Technologies for Healthcare and Workshops*, (2013)
22. Niemeijer M, Abramoff MD, van Ginneken B. Information fusion for diabetic retinopathy CAD in digital color fundus photographs. *Medical Imaging, IEEE Transactions on*, 28(5), 775-85 (2009)
23. Hani AFM, Nugroho H, Nugroho HA et al. Toward a Fully Automated DR Grading System. *5th European Conference of the International Federation for Medical and Biological Engineering*. 663-6 (2012)
24. Fadzil MA, Izhar LI, Nugroho H et al. Analysis of retinal fundus images for grading of diabetic retinopathy severity. *Medical & biological engineering & computing*, 49(6), 693-700 (2011)
25. Quellec G, Russell SR, Abramoff MD. Optimal filter framework for automated, instantaneous detection of lesions in retinal images. *Medical Imaging, IEEE Transactions on*, 30(2), 523-33 (2011)
26. The Nielsen Company. *The Digital Consumer Report Feb 2014*. (2014)

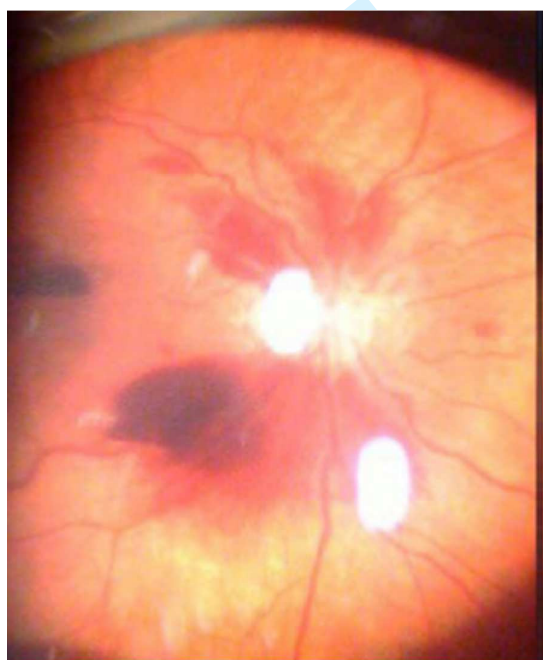
- 1  
2  
3 27. Greenspun P. History of photography timeline. <http://photo.net/history/timeline>, (2000)  
4 [Last accessed 16 October 2014]  
5 28. Nokia Lumia 1020. Microsoft Devices. Available at: [http://www.nokia.com/gb-](http://www.nokia.com/gb-en/phones/phone/lumia1020/)  
6 [en/phones/phone/lumia1020/](http://www.nokia.com/gb-en/phones/phone/lumia1020/) (2013) [Last accessed 16 October 2014]  
7 29. Galaxy Note 3. Samsung. Available at: [http://www.samsung.com/uk/consumer/mobile-](http://www.samsung.com/uk/consumer/mobile-devices/galaxy-note/smartphones/SM-N9005ZWEITU)  
8 [devices/galaxy-note/smartphones/SM-N9005ZWEITU](http://www.samsung.com/uk/consumer/mobile-devices/galaxy-note/smartphones/SM-N9005ZWEITU) (2013) [Last accessed 16 October  
9 2014]  
10 30. Bastawrous A, Hennig B, Livingstone I. mHealth Possibilities in a Changing World.  
11 Distribution of Global Cell Phone Subscriptions. *Journal of Mobile Technology in Medicine*,  
12 2(1S), 22-5 (2013)  
13 31. Pew Research. Emerging Nations Embrace Internet, Mobile Technology. (2014)  
14 32. A Survey of Mobile Phone Usage by Health Professionals in the UK. d4 Available at:  
15 <http://www.d4.org.uk/research/survey-mobile-phone-use-health-professionals-UK.pdf>  
16 (2010) [Last accessed 16 October 2014]  
17 33. DeRenzi B, Borriello G, Jackson J et al. Mobile Phone Tools for Field-Based Health care  
18 Workers in Low-Income Countries. *Mount Sinai Journal of Medicine: A Journal of*  
19 *Translational and Personalized Medicine*, 78(3), 406-18 (2011)  
20 34. Martínez-Pérez B, de la Torre-Díez I, López-Coronado M. Mobile health applications for the  
21 most prevalent conditions by the World Health Organization: review and analysis. *Journal of*  
22 *medical Internet research*, 15(6) (2013)  
23 35. Fiordelli M, Diviani N, Schulz PJ. Mapping mHealth research: a decade of evolution. *Journal*  
24 *of medical Internet research*, 15(5) (2013)  
25 36. Bastawrous A, Cheeseman RC, Kumar A. iPhones for eye surgeons. *Eye*, 26(3), 343-54 (2012)  
26 37. Hecht E. Optics: Pearson New International Edition. Pearson Education Limited, 467-73  
27 (2013)  
28 38. Mahajan VN. Optical Imaging and Aberrations: Part 1. Ray Geometrical Optics. (SPIE  
29 Bellingham, 1998)  
30 39. Smith W. Modern Optical Engineering, 4th Ed. McGraw-Hill Education, 183 (2007)  
31 40. Six-way camera shootout. GSMarena. Available at:  
32 [http://www.gsmarena.com/six\\_way\\_camera\\_shootout-review-998p2.php](http://www.gsmarena.com/six_way_camera_shootout-review-998p2.php) (2013) [Last  
33 accessed 21 October 2014]  
34 41. Sayood K. Introduction. In: Introduction to Data Compression (Fourth Edition). Morgan  
35 Kaufmann, 1-11 (2012)  
36 42. Kumar S, Wang EH, Pokabla MJ et al. Teleophthalmology assessment of diabetic retinopathy  
37 fundus images: smartphone versus standard office computer workstation. *Telemedicine*  
38 *journal and e-health : the official journal of the American Telemedicine Association*, 18(2),  
39 158-62 (2012)  
40 \*\* Study providing quantitative data of retinopathy related changes detected when viewing fundus  
41 images on a smartphone compared to a desktop monitor.  
42 43. iPhone 6 Plus. Apple Inc. Available at: <https://www.apple.com/uk/iphone/compare/> (2014)  
43 [Last accessed: 21 October 2014]  
44 44. Lord RK, Shah VA, San Filippo AN et al. Novel Uses of Smartphones in Ophthalmology.  
45 *Ophthalmology*, 117(6), 1274-.e3 (2010)  
46 45. Bastawrous A. Smartphone Fundoscopy. *Ophthalmology*, 432-3.e2 (2012)  
47 46. Haddock LJ, Kim DY, Mukai S. Simple, inexpensive technique for high-quality smartphone  
48 fundus photography in human and animal eyes. *Journal of ophthalmology*, 2013, 518479  
49 (2013)  
50 \* Describes a technique for capturing images from indirect ophthalmoscopy using a 20D lens and a  
51 smartphone with greater ease than methods discussed elsewhere.  
52 47. Lin S-J, Yang C-M, Yeh P-T et al. Smartphone fundoscopy for retinopathy of prematurity.  
53 *Taiwan Journal of Ophthalmology*, 4(2), 82-5 (2014)  
54  
55  
56  
57  
58  
59  
60

- 1  
2  
3 \* Demonstrates a technique for acquiring images of pre-term babies with a field-of-view large  
4 enough to detect retinopathy of prematurity.  
5 48. Myung D, Jais A, He L et al. 3D Printed Smartphone Indirect Lens Adapter for Rapid, High  
6 Quality Retinal Imaging. *Journal of Mobile Technology in Medicine*, 3(1), 9-15 (2014)  
7 \*\* Important description of a prototype adapter that allows a 20D lens to be attached to a  
8 smartphone at variable working distance. Ease-of-use is reported to be such that non-  
9 specialists can capture good quality images.  
10 49. Barsam A, Bhogal M, Morris S et al. Anterior segment slitlamp photography using the  
11 iPhone. *Journal of cataract and refractive surgery*, 36(7), 1240-1 (2010)  
12 50. Chan JB, Ho HC, Ngah NF et al. DIY-Smartphone Slit-Lamp adaptor. *Journal of Mobile  
13 Technology in Medicine*, 3(1), 16-22 (2014)  
14 51. Myung D, Jais A, He L et al. Simple, Low-Cost Smartphone Adapter for Rapid, High Quality  
15 Ocular Anterior Segment Imaging: A Photo Diary. *Journal of Mobile Technology in Medicine*,  
16 3(1), 2-8 (2014)  
17 \* Describes a prototype device for capturing anterior segment images using a smartphone.  
18 52. Thibos L. In *The News/New Products*. *Optometry and Vision Science*, 89(9), 1424-30 (2012)  
19 53. Keeler 3010-P-2001 PSL One Hand-Held Slit Lamp. Onecall Medical Supplies. Available at:  
20 [http://www.oncallmedicalsupplies.co.uk/keeler-3010-p-2001-psl-one-hand-held-slit-](http://www.oncallmedicalsupplies.co.uk/keeler-3010-p-2001-psl-one-hand-held-slit-lamp.html)  
21 [lamp.html](http://www.oncallmedicalsupplies.co.uk/keeler-3010-p-2001-psl-one-hand-held-slit-lamp.html) (2013) [Last accessed 20 October 2014]  
22 54. Keeler PSL Classic Portable Slit Lamp. Williams Medical. Available at:  
23 [http://www.wms.co.uk/Ophthalmology/Ophthalmology\\_Instruments/Keeler\\_PSL\\_Classic\\_P](http://www.wms.co.uk/Ophthalmology/Ophthalmology_Instruments/Keeler_PSL_Classic_P)  
24 [ortable\\_Slit\\_Lamp](http://www.wms.co.uk/Ophthalmology/Ophthalmology_Instruments/Keeler_PSL_Classic_P) (2014) [Last accessed 20 October 2014]  
25 55. Keeler iPhone 4 adapter for PSL One. HCE Health-Care Equipment. Available at:  
26 <http://www.hce-uk.com/epages/HCE->  
27 [UK.sf/en\\_GB/?ObjectPath=/Shops/Healthcare/Products/HLO075.1](http://www.hce-uk.com/epages/HCE-) (2014) [Last accessed 20  
28 October 2014]  
29 56. Dragnev D, Mahmood U, Williams C et al. Telemedicine. *InTech*, 3-25 (2013)  
30 57. Welch Allyn. PanOptic Ophthalmoscope: A difference you can see. Available at:  
31 <http://intl.welchallyn.com/promotions/PanOptic/default.htm> (2014) [Last accessed 16  
32 October 2014]  
33 58. Petrushkin H, Barsam A, Mavrakakis M et al. Optic disc assessment in the emergency  
34 department: a comparative study between the PanOptic and direct ophthalmoscopes.  
35 *Emergency medicine journal : EMJ*, 29(12), 1007-8 (2012)  
36 59. McComiskie JE, Greer RM, Gole GA. Panoptic versus conventional ophthalmoscope. *Clinical  
37 & Experimental Ophthalmology*, 32(3), 238-42 (2004)  
38 60. Blanckenberg MW, Christo, Sheffer C. Development of a Mobile Phone Based  
39 Ophthalmoscope for Telemedicine. 33rd Annual International Conference of the IEEE EMBS,  
40 (2011)  
41 \* Describes a prototype for diabetic retinopathy screening with a mechanism for central evaluation  
42 of remotely captured images and automated quality analysis.  
43 61. Mann EA. iExaminer 510(k) Summary Administration, USFaD (2012)  
44 62. Maamari RN, Keenan JD, Fletcher DA et al. A mobile phone-based retinal camera for  
45 portable wide field imaging. *Br J Ophthalmol*, 98(4), 438-41 (2014)  
46 \* Describes a prototype of similar design to commercial units but demonstrates how images with a  
47 much improved field-of-view can be achieved through image stitching techniques.  
48 63. Giardini ME, Livingstone IAT; Jordan S, et al. A Smartphone Based Ophthalmoscope.  
49 *Proceedings of the 36th Annual International Conference of the IEEE Engineering in  
50 Medicine and Biology Society*, 2177-80 (2014)  
51 \*\* Low-cost smartphone based ophthalmoscope reportedly being used to collect substantial data  
52 from field trials in low-income settings.  
53  
54  
55  
56  
57  
58  
59  
60

- 1
  - 2
  - 3
  - 4
  - 5
  - 6
  - 7
  - 8
  - 9
  - 10
  - 11
  - 12
  - 13
  - 14
  - 15
  - 16
  - 17
  - 18
  - 19
  - 20
  - 21
  - 22
  - 23
  - 24
  - 25
  - 26
  - 27
  - 28
  - 29
  - 30
  - 31
  - 32
  - 33
  - 34
  - 35
  - 36
  - 37
  - 38
  - 39
  - 40
  - 41
  - 42
  - 43
  - 44
  - 45
  - 46
  - 47
  - 48
  - 49
  - 50
  - 51
  - 52
  - 53
  - 54
  - 55
  - 56
  - 57
  - 58
  - 59
  - 60
64. International Standard, ISO 15004-2.2: 2007 Ophthalmic Instruments. In: Light Hazard protection. International Organization for Standardization (Geneva, Switzerland, 2007)
65. Kim DY, Delori F, Mukai S. Smartphone photography safety. *Ophthalmology*, 119(10), 2200-1 (2012)
66. Pascolini D, Mariotti SP. Global estimates of visual impairment: 2010. *British Journal of Ophthalmology*, *bjophthalmol-2011-300539* (2011)
67. World Health Organization. Universal Eye Health: A Global Action Plan (2013)
68. Klein R, Klein BEK. Diabetes In America, 2nd edition. National Institute of Diabetes and Digestive and Kidney Diseases, 293-338 (1995)
69. Hazin R, Barazi MK, Summerfield M. Challenges to establishing nationwide diabetic retinopathy screening programs. *Current opinion in ophthalmology*, 22(3), 174-9 (2011)
70. Hazin R, Colyer M, Lum F et al. Revisiting Diabetes 2000: Challenges in Establishing Nationwide Diabetic Retinopathy Prevention Programs. *American Journal of Ophthalmology*, 152(5), 723-9 (2011)
71. Whiting DR, Guariguata L, Weil C et al. IDF Diabetes Atlas: Global estimates of the prevalence of diabetes for 2011 and 2030. *Diabetes Research and Clinical Practice*, 94(3), 311-21 (2011)
72. Turner R, Holman R, Cull C et al. Intensive blood-glucose control with sulphonylureas or insulin compared with conventional treatment and risk of complications in patients with type 2 diabetes (UKPDS 33). *lancet*, 352(9131), 837-53 (1998)
73. Noble J, Somal K, Gill HS et al. An analysis of undergraduate ophthalmology training in Canada. *Canadian Journal of Ophthalmology / Journal Canadien d'Ophthalmologie*, 44(5), 513-8 (2009)
74. Tran K, Mendel TA, Holbrook KL et al. Construction of an Inexpensive, Hand-Held Fundus Camera through Modification of a Consumer "Point-and-Shoot" Camera. *Investigative Ophthalmology & Visual Science*, 53(12), 7600-7 (2012)
75. Farley TF, Mandava N, Prall FR et al. Accuracy of primary care clinicians in screening for diabetic retinopathy using single-image retinal photography. *The Annals of Family Medicine*, 6(5), 428-34 (2008)
76. Saaddine JB, Honeycutt AA, Narayan K et al. Projection of diabetic retinopathy and other major eye diseases among people with diabetes mellitus: United states, 2005-2050. *Archives of Ophthalmology*, 126(12), 1740-7 (2008)
77. World Health Organization . Visual impairment and blindness. Fact Sheet N 282 (2013)
78. Bastawrous MA, Hennig BD. The global inverse care law: a distorted map of blindness. *The British journal of ophthalmology*, 96(10), 1357 (2012)
79. Resnikoff S, Felch W, Gauthier T-M et al. The number of ophthalmologists in practice and training worldwide: a growing gap despite more than 200 000 practitioners. *British Journal of Ophthalmology*, 96(6), 783-7 (2012)
80. McCord GC, Liu A, Singh P. Deployment of community health workers across rural sub-Saharan Africa: financial considerations and operational assumptions. *Bulletin of the World Health Organization*, 91, 244-53b (2013)
81. Briesen S, Geneau R, Roberts H et al. Understanding why patients with cataract refuse free surgery: the influence of rumours in Kenya. *Tropical Medicine & International Health*, 15(5), 534-9 (2010)
82. Yin Q, Hu A, Liang Y et al. A Two-Site, Population-Based Study of Barriers to Cataract Surgery in Rural China. *Investigative Ophthalmology & Visual Science*, 50(3), 1069-75 (2009)
83. Ojabo CO, Alao O. Cataract surgery: limitations and barriers in Makurdi, Benue State. *Nigerian journal of medicine : journal of the National Association of Resident Doctors of Nigeria*, 18(3), 250-5 (2009)
84. Klotz SA, Penn CC, Negvesky GJ et al. Fungal and parasitic infections of the eye. *Clinical microbiology reviews*, 13(4), 662-85 (2000)



- 1  
2  
3 85. Beare NA, Southern C, Chalira C et al. Prognostic significance and course of retinopathy in  
4 children with severe malaria. *Archives of Ophthalmology*, 122(8), 1141-7 (2004)  
5 86. Kochar DK, Shubhakaran, Kumawat BL et al. Ophthalmoscopic abnormalities in adults with  
6 falciparum malaria. *QJM*, 91(12), 845-52 (1998)  
7 87. Lim W-K, Mathur R, Koh A et al. Ocular manifestations of dengue fever. *Ophthalmology*,  
8 111(11), 2057-64 (2004)  
9 88. Worldwide Quarterly Mobile Phone Tracker. International Data Corporation, (2014)  
10 89. Kay M. mHealth: New horizons for health through mobile technologies. World Health  
11 Organization, (2011)  
12 90. Bastawrous A, Armstrong MJ. Mobile health use in low- and high-income countries: an  
13 overview of the peer-reviewed literature. *J. R. Soc. Med.*, 106(4), 130-42 (2013)  
14 91. Tomlinson M, Rotheram-Borus MJ, Swartz L et al. Scaling up mHealth: where is the  
15 evidence? *PLoS medicine*, 10(2), e1001382 (2013)  
16  
17  
18  
19



41  
42 Figure 1. Fundus image captured using a 20D lens, iPhone (Apple Inc, Cupertino, CA, USA) and a pen  
43 torch.  
44

45  
46 Reproduced with permission from [44].  
47  
48  
49  
50  
51  
52  
53  
54  
55  
56  
57  
58  
59  
60

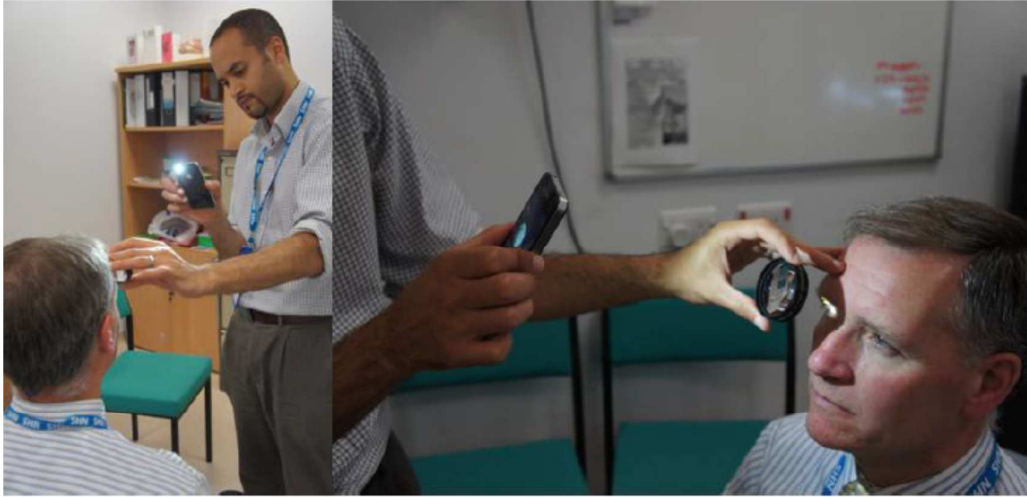

Figure 2. Capturing fundus images using an iPhone 4's (Apple Inc, Cupertino, CA, USA) native light emitting diode (LED) flash rather than a pen torch.

Reproduced with permission from [45].

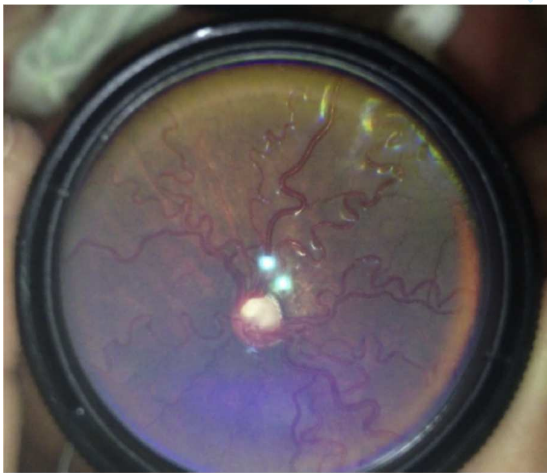


Figure 3. Plus disease in a pre-term infant could be diagnosed from an image captured using a smartphone's camera and light emitting diode (LED) flash by applying an eyelid speculum and performing scleral indentation.

Reproduced with permission from [47].



Figure 4. The '3D Printed Smartphone Indirect Lens Adapter' developed by Myung et al. consists of a condensing lens held at a fixed length from the Smartphone's camera by a 3d printed adapter.

Reproduced with permission from [48].



Figure 5. Smartphone adapter for anterior segment imaging developed by Myung et al.

Reproduced with permission from [51].




Figure 6. Panoptic monocular indirect ophthalmoscope (Welch-Allyn Inc., Skaneateles Falls, NY, USA) customised so to capture images with a wireless enabled digital camera. A cellphone then received these images for long-distance transmission.

Reproduced with permission from [60].




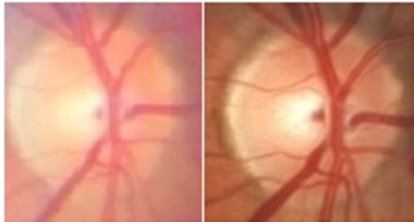
Figure 7. The Ocular Cellscope (left) captures fundus images with a 55 degree field of view. Multiple images can then be “stitched” together by specialist software to produce an image with an even

1  
2  
3 wider field of view (right).  
4

5 Reproduced with permission from [62].  
6  
7  
8  
9  
10



11  
12  
13  
14  
15  
16  
17  
18  
19  
20  
21  
22  
23  
24  
25  
26 Figure 8. A simplified smartphone adapter developed by Giardini et al. promises to overcome the  
27  
28 cost barriers presented to screening in many settings.  
29



30  
31  
32  
33  
34  
35  
36  
37  
38  
39  
40  
41  
42  
43 Figure 9. Optic nerve as captured by the adapter reported in Giardini et al. (left) and a standard  
44  
45 desktop fundus camera (Topcon Corp., Tokyo, Japan) (right).  
46  
47  
48  
49  
50  
51  
52  
53  
54  
55  
56  
57  
58  
59  
60