

CASE REPORT

Magnetic Resonance Spectroscopy in Ring Enhancing Lesions

R SETH, V KALRA, U SHARMA* AND N JAGANNATHAN*

*From Departments of Pediatrics and *Nuclear Magnetic Resonance, All India Institute of Medical Sciences, New Delhi, India.*

Correspondence to: Dr Rachna Seth, Assistant Professor, Department of Pediatrics, All India Institute of Medical Sciences, New Delhi 110 029, India.

drrachnaseth@yahoo.co.in

Received: January 13, 2009;

Initial review: January 29, 2009;

Accepted: July 3, 2009.

We report a 4 year old girl with ring enhancing lesions in brain CT, initially diagnosed as neurocysticercosis but did not respond to cysticidal therapy. A Magnetic resonance spectroscopy (MRS) revealed lipid peaks suggestive of tuberculoma which was successfully treated with antituberculosis therapy. This report highlights the role of MRS in the diagnosis of ring enhancing lesions.

Key words: *Ring enhancing lesions, Magnetic Resonance Spectroscopy, Neurometabolites.*

The two most common etiologies of inflammatory granulomas encountered in clinical practice include neurocysticercosis (NCC) and tuberculomas, the differentiation between the two has defied conventional investigations. Clinical and radiological criteria. We highlight the role of magnetic resonance spectroscopy (MRS) in differentiating between these lesions.

CASE REPORT

A 4 year old girl with normal development presented with sudden onset multiple episodes of right sided complex partial seizures. There was no history of fever, vomiting, weight loss, altered sensorium or visual complaints. History of contact with a case of tuberculosis was positive.

On examination the child was well built with stable vitals. BCG scar was present. Systemic and neurological examination was normal. Chest X ray was normal and mantoux test was not reactive. Serology (IgG) for NCC was positive. CT scan revealed presence of three ring enhancing lesions (9.6-13mm in size) with enhancing eccentric foci in left frontal and both parietal regions with mild to moderate perilesional edema. There was no evidence

of midline shift. There was no evidence of papilledema/intraocular cysticercosis on ophthalmological examination. The child was given conventional antiepileptics and first course of cysticidal (Albendazole for 28 days and steroids for 2 months).

However, The child continued to have multiple seizures and also developed right lower limb paresis and papilledema while on antiepileptics, cysticidal therapy and steroids. Repeat CT head done 12 weeks after completion of the first cysticidal course showed persistence of the three ring enhancing lesions as in previous CT with increased perilesional edema. The child was administered a course of praziquantal and steroid. Seizures persisted even after this therapy and there was no radiological improvement. A magnetic resonance imaging (MRI) confirmed the CT findings. Magnetic resonance spectroscopy (MRS) identified a lipid peak in all the lesions (**Fig 1**) and a diagnosis of tuberculoma was considered. The choline/creatine ration was greater than 1, N-acetyl aspartate (NA) was reduced.

The patient was subsequently started on 4-drug antitubercular drug therapy (2HRZE 10HR) with steroids 8 weeks. The child responded to antituberculosis therapy. The headache,

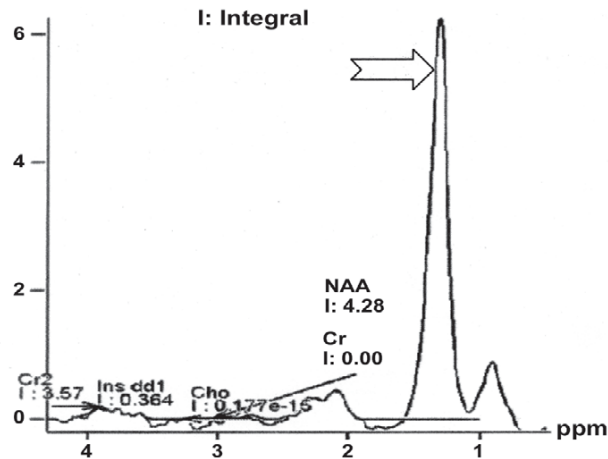


FIG.1 The arrow denotes the lipid peak identified in the spectrum obtained during MRS.

monoparesis and papilledema also resolved. CT done 6 months after starting ATT showed calcification of the left parietal lesion. A disc enhancing lesion was seen in the left frontal region. The lesion in right parietal region showed gliosis with reduction of perilesional edema. Perilesional edema around the left sided lesions (frontal and parietal) had resolved.

DISCUSSION

The diagnostic dilemma of inflammatory granulomas is highlighted from the case history discussed. Common causes of inflammatory granulomas include NCC (commonest) followed by tuberculosis, toxoplasmosis, cerebral abscess and fungal lesions. This child presented with seizures, showed a positive serological response towards NCC and CT findings were compatible with NCC (<20mm, regular outline and no midline shift)(1) yet the child was actually suffering from tuberculous granulomatous lesions where we expect larger lesions (>20mm) with an irregular outline and midline shifts(1). The patient was given two courses of cysticidal with no clinical/radiologic improvement and this prompted us to review our diagnosis.

MR spectroscopy identified lipid peaks in all the lesions and raised the suspicion of tuberculoma. In a study by Pretell, *et al.*(3) MR Spectroscopy was used to differentiate single enhancing brain lesions as due

to tuberculomas or neurocysticercosis. Tuberculomas ($n=4$) had a high peak of lipids, more choline and less N acetylaspartate and creatine. The choline/ creatine ratio was greater than 1 in all tuberculomas but in none of the cysticerci ($n=6$)(2). Similar findings in tuberculomas have been reported by Kumar, *et al.* and Jayasunder, *et al.*(3-5). MRS findings of cysticercosis include a combination of elevated levels of lactate, alanine, succinate and choline and reduced levels of NAA and creatine(6).

To conclude, misdiagnosis of inflammatory granulomas may occur. MRS could be a useful noninvasive alternative to determine their etiology.

Contributors: RS: Concept, work up of patient and manuscript; VK: Concept, design and contribution to manuscript; US and NJ: MR spectroscopy and its analysis.

Funding: None.

Competing interests: None stated.

REFERENCES

1. Rajshekhar V, Haran RP, Prakash GS and Chandy MJ. Differentiating solitary small cysticercus granulomas and tuberculomas in patients with epilepsy. *J Neurosurg* 1993; 78: 402-407.
2. Pretell, EJ, Martinot C Jr, Garcia HH, Alvarado M, Bustos JA, Martinot C. Differential diagnosis between cerebral tuberculosis and neurocysticercosis by magnetic resonance spectroscopy. *J Comput Assist Tomogr* 2005; 29: 112-114.
3. Kumar A, Kaushik S, Tripathi RP, Kaur P, Khushu S. Role of in vivo proton MR spectroscopy in the evaluation of adult brain lesions: Our preliminary experience. *Neurol India* 2003; 51: 474-478.
4. Gupta RK, Pandey R, Khan EM, Mittal P, Gujral RB, Chhabra DK. Intracranial tuberculomas: MRI signal intensity correlation with histopathology and localized proton spectroscopy. *Magn Res Imaging* 1993; 11: 443-449.
5. Jayasunder R, Singh VP, Raghunathan P, Jain K, Banerji AK. Inflammatory granulomas: evaluation with proton MRS. *NMR Biomed* 1999; 12 : 139-144.
6. Pandit S, Lin A, Gahbauer H, Libertin CR, Erdogan B. MR spectroscopy in neurocysticercosis. *J Comput Assist Tomogr* 2001; 25: 950-952.