

Importance of Etiologic Diagnosis of Hydrocephalus as Illustrated by a Case of Walker Warburg Syndrome

Shubha R. Phadke

Jagannath Pahi

R.V. Phadke*

S. Pradhan**

S.S. Agarwal

Walker Warburg syndrome (WWS) is an autosomal recessive disease presenting with hydrocephalus with or without encephalocele. It is associated with a high risk of recurrence. There are many other syndromes (single gene determined and chromosomal) which are associated with hydrocephalus or neural tube defects and there is a need of reaching etiological diagnosis in all such cases.

Case Report

A 11/2-month-old female child was brought to the Genetic Clinic as a case of hydrocephalus. The baby was born to a non-consanguineous Hindu couple. The first child of the couple had occipital encephalocele and died on the first day. He was not investigated. There was no history of exposure to any known or probable teratogen during this pregnancy especially vitamin A or its analogue. During antenatal period of the second pregnancy, the

ultrasonography done at 18 weeks was reported to be normal. In the last trimester, ultrasound examination showed dilatation of lateral ventricles.

The child at one and half months age was weak with poor reflexes and had a weight of 3 Kg (<3rd centile), length of 54 cm (25th centile) and head circumference of 38 cm (50th centile). She had a large anterior fontanelle, prominent forehead, setting sun sign in right eye; microphthalmia and microcornea in the left eye. She had developed central corneal opacity after birth in the right eye and hence, the examination of anterior chamber and fundus was not possible. Intraocular tension in the right eye was normal. There was left sided cleft lip.

Radiographs of skull, spine and hand did not show any abnormality. The CT scan of brain showed markedly dilated lateral ventricles. Third ventricle was also dilated. Cerebral mantle was very thin and it appeared smooth, suggestive of type II lissencephaly. It is important to note that inspite of extremely thin cerebral mantle and marked dilatation of ventricles, the head circumference was not grossly enlarged, which supports the diagnosis of lissencephaly as against severe hydrocephalus. The magnetic resonance imaging of brain confirmed the smooth surface of cerebral hemispheres and showed small cerebellum with aplasia of inferior part of vermis (*Fig. 1.*). The presence of lissencephaly and microphthalmos suggested the diagnosis of WWS.

The diagnosis was supported by myopathic EMG pattern and raised creatinine phosphokinase levels on two occasions (1430 u/l and 825 u/l) in the child. The chromosomes could not be studied as the lymphocyte culture failed.

The poor prognosis regarding life and mental development, and 25% risk of

*From the Departments of Medical Genetics, "Radiology and **Neurology, Sanjay Gandhi Post-Graduate Institute of Medical Sciences, Raebareli Road, Lucknow 226 014.*

Reprint requests: Dr. Shubha R. Phadke, Assistant Professor, Department of Medical Sciences, Sanjay Gandhi Post Graduate Institute of Medical Sciences, Raebareli Road, Lucknow 226 014.

CASE REPORTS

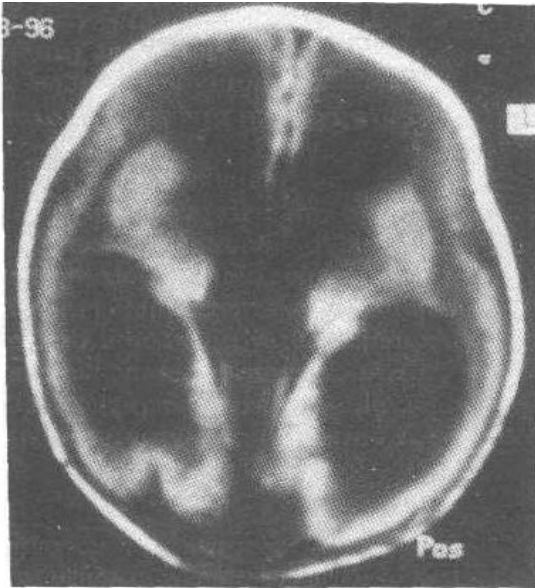


Fig. 1 T1 weighted MR axial images showing dilated ventricles with thin, smooth and featureless cortex.

recurrence in next pregnancies was explained to the couple. The child died at 3 months of age.

Discussion

WWS is an autosomal recessive disorder manifested by characteristic brain and eye malformations. The presence of lissencephaly, ventricular dilatation, microphthalmia, cerebellar hypoplasia, congenital muscular dystrophy and cleft lip in the present case is diagnostic of WWS(1). Corneal opacity in the case had developed after birth, probably as a result of exposure keratitis as the right eye used to remain partially open. Dobyns *et al.*(2) reviewed a large series of patients of this diagnosis. Their data shows that four abnormalities were present in all patients checked for these anomalies; Type II lissencephaly, cer-

ebellar malformation, retinal malformation and congenital muscular dystrophy. Two other frequently observed abnormalities were ventricular dilatation with or without hydrocephalus and anterior chamber malformation. Other less frequently occurring abnormalities are macrocephaly, microcephaly, Dandy-Walker malformation, posterior encephalocele, microphthalmia, ocular coloboma, congenital contractures, genital abnormalities in males and cleft lip/palate. The median survival is 9 months. WWS is autosomal recessive with variable phenotype in siblings. In the present case, the previous sibling had posterior encephalocele which could be a manifestation of WWS. However, since that child was not investigated in detail, the diagnosis could have been missed. The diagnosis of WWS is important not only because of poor prognosis for life and mental development but for high risk of recurrence (25%). In the presence of eye abnormalities, CPK helps in confirming the diagnosis.

We shall like to stress that there are many syndromes associated with hydrocephalus and with encephalocele and hence, reaching the etiological diagnosis in each case presenting as hydrocephalus or encephalocele by detailed investigations of newborn is essential for providing prognosis, risk of recurrence and better prenatal diagnosis during next pregnancy.

REFERENCES

1. Greenberg F. Walker-Warburg Syndrome. *In: Birth Defects Encyclopedia*. Ed. Buyse ML. Dover, Center for Birth Defects Information Services, 1989; pp 1774-1775.
2. Dobyns WB, Pagon RA, Armstrong D, Curry CJR, Greenberg AG, Grix A, *et al.* Diagnostic criteria for Walker-Warburg Syndrome. *Am J Med Genet* 1989; 32:195-210.