

# SEASONAL GONADAL CHANGES IN ADULT FRESHWATER MUSSEL, *PARREYSIA FAVIDENS* VAR. *MARCEUS* (BENSON)

BY V. Y. PATIL\* AND D. V. BAL, F.A.SC.

(Zoology Laboratory, Institute of Science, Bombay)

Received January 29, 1966

## ABSTRACT

1. Seasonal gonadal changes in adult mussels were observed.
2. The spawning starts in the month of March and continues up to October indicating a prolonged breeding period.
3. After the start of the spawning, lipid globules appear in the lumen of the follicles.
4. In the male, spermatocytical morulae appear after the start of the spawning.
5. No indeterminate sex condition or hermaphroditism is noticed.

## INTRODUCTION

SEX in Pelecypoda is a subject of great interest. The members of this group are either unisexual or hermaphrodite. In some members, the peculiar phenomenon of sex change also occurs. Most of the work on sex and seasonal gonadal changes has been done on oysters (Amemiya, 1925, 1929 *a* and 1929 *b*; Coe, 1932, 1934 and Rao, 1953 and 1956), *Mya* (Coe and Turner, 1938), *Teredo* (Coe, 1936), *Venus* (Loosanoff, 1937), *Lamellidens* (Bloomer, 1931) and *Anodonta* (Bloomer, 1930, 1934, 1935 and 1939), but the Indian freshwater mussel, *Parreysia favidens* var. *marceus* has received very little attention in this respect. The present study is an attempt in elucidating the seasonal changes in the adult of this species of mussel.

For this study, adult mussels ranging between 50–60 mm. in length were collected from the Mula River, Kirkee (Poona), during the period, August 1960 to July 1961. A record was kept of the sex and gonad condition of each specimen. The extent of gonad development was judged by adopting

---

\* Present address: Zoology Department, Rajaram College, Kolhapur.

the stages described in Table I. These stages were based on the macroscopic and microscopic changes in the structure of the gonad of the mussel.

#### OBSERVATIONS AND DISCUSSION

##### *Structure of the Gonad*

*P. favidens var. marcens* is unisexual. In both the sexes, gonads are paired organs consisting of tubulo-alveolar follicles, scattered in-between the intestinal loops. On each side, a gonoduct is present. It starts from the posterior end of the visceropedal mass and runs in the anterio-dorsal direction. It opens at the tip of the genital papilla located in the inner suprabranchial chamber, below and anterior to the excretory pore. The ductules of gonadal follicles unite to form lateral ducts which in turn open in the main gonoduct. The wall of the gonad follicle is made up of a thin layer of connective tissue fibres. The lumen of the follicle is lined by a single layer of germinal epithelium. In testicular follicle (Fig. 1) spermatogonia, spermatocytes, spermatids and sperms are present. The sperm (Fig. 7) has a rectangular head, slightly broad at its posterior end and a long tail. Apart from these, spermatocytical morulae (Fig. 3, SC.M.) are also seen. In ovarian follicle oocytes in various stages of development are present. The follicles show presence of globules (Figs. 3 and 6, GL.) as observed in *Lamellidens marginalis* by Bloomer (1931).

Results of the seasonal gonadal changes in an adult mussel are shown in Tables II and III and Figs. 1 to 8.

The sequence of the sexual cycle in adult mussels during different months of the year is as follows:

In January, more than 70% mussels are in the maturing stage (Figs. 1 and 4) and the remaining show spent condition (Figs. 3 and 6). In maturing mussels, the follicles present in the anterior part of the visceropedal mass show a large number of lipid globules (Figs. 3 and 6, GL.), a few residual gametes indicating the spent condition. But the follicles present in the posterior part of the mass show rapid growth which results in the formation of fresh spermatocytes and sperms in the male and oocytes in the female. In the testicular follicle, spermatocytical morulae (Fig. 1, SC.M.) are also seen. Lipid globules are present in both male and female follicles.

In February and March, maturing as well as mature (Fig. 2) mussels are present. However, a few spawned individuals are noticed in the month of March. In maturing mussels, the gonadal development extends towards the anterior end of the visceropedal mass, which therefore becomes thick.

TABLE I

*Showing the Macroscopic and Microscopic Structure of the Gonad*

Stage	External features	Histological features
1. Immature	Viscero-pedal mass thin, sexes distinguishable	Gonad follicles few and small. Germ cells give rise to gonidia with clear cytoplasm. Male follicles lined by spermatogonia and spermatocytes. Female follicles lined by oogonia and oocytes attached to the wall. Each oocyte is with fibrillar granulated cytoplasm and spherical vesicular nucleus with distinct nucleoli.
2. Maturing	Viscero-pedal mass slightly thick and firm. Follicles are large and compactly arranged in the posterior part of the viscero-pedal mass.	Gonad follicles compactly arranged with slight interfollicular connective tissue. Male follicles with sperms and very few spermatocytical morulae. Spermatogonia, spermatocytes and spermatids arranged in radiating strands from the follicular wall (Fig. 1). Female follicles with a few oogonia and young oocytes (Fig. 4).
3. Mature	Viscero-pedal mass gorged; follicles turgid, closely packed.	Gonad follicles attain maximum size. Male follicles packed with sperms and few spermatocytes (Fig. 2). Spermatocytical morulae absent. Female follicles packed with many fully grown oocytes (Fig. 8). The gills show preparation for receiving the eggs.
4. Partially Spent	Viscero-pedal mass slightly loose in the posterior region. In the female, gills show presence of embryos in various stages of development.	Follicles firm with ova or sperms and few lipid globules. Male follicles with sperms at the centre and a few spermatocytical morulae towards the periphery. Female follicles with a few oocytes and lipid globules (Fig. 5).
5. Spent	Viscero-pedal mass thin and watery. In the female, gills show presence of fully developed glochidia.	Follicles filled with lipid globules. Male follicles with spermatocytical morulae and few residual sperms (Fig. 3). Female follicles filled with lipid globules and few residual oocytes (Fig. 6).

TABLE II

Showing Percentage Composition of Males of *Parreysia favidens* var. *marcens* in Different Maturity Stages during August 1960 to July 1961

Months	No. of specimens examined	Maturing stage %	Mature stage %	Partially spent stage %	Spent stage %
1960					
August	73	..	2.85	70.27	26.88
September	78	..	..	28.34	71.66
October	115	..	..	5.90	94.10
November	84	7.78	..	..	92.22
December	59	41.53	...	..	58.47
1961					
January	70	77.21	4.29	..	18.50
February	66	69.22	30.78	..	...
March	63	30.86	66.95	2.19	..
April	72	8.29	72.73	18.98	..
May	80	..	63.65	36.35	...
June	79	..	51.83	48.17	..
July	66	...	21.94	78.06	...

In the males, spermatogenesis proceeds resulting in the formation of columns of sperms with the tails towards the lumen (Fig. 2). The spermatocytical morulae reduce in number. In the females, mature oocytes (Fig. 5, OV.) get detached from the follicular wall and lie free in its lumen. The mature oocyte (Fig. 8) is spherical in shape with distinct vitelline membrane. In both the follicles, lipid globules decrease in number. In mature individuals, the follicles are packed with only sperms (Fig. 2) or only ova (oocytes) ready for discharge. The interlamellar junctions of the gills in female are elongated. Consequently the water tubes become very wide indicating that mussels are ready to receive the eggs therein (marsupium) for further development.

TABLE III

*Showing Percentage Composition of Females of Parreysia favidens var. marcens in Different Maturity Stages during August 1960 to July 1961*

Months	No. of specimens examined	Maturing stage %	Mature stage %	Partially spent stage %	Spent stage %
1960					
August	57	..	2.50	68.38	29.12
September	60	..	..	25.72	74.28
October	75	..	..	3.30	96.40
November	81	4.64	..	..	95.36
December	54	37.87	..	..	62.13
1961					
January	46	77.33	..	..	22.67
February	47	77.00	23.00	..	..
March	43	27.19	70.18	2.63	..
April	43	3.83	78.63	17.54	..
May	36	..	59.41	40.59	..
June	39	..	38.89	61.11	..
July	44	..	17.35	79.70	2.95

In individuals which have commenced spawning, the posterior part of the visceropedal mass becomes slightly flabby while the anterior part remains thick indicating a partially spent condition (Fig. 5). The follicles in the posterior part of the visceropedal mass show appearance of lipid globules (Fig. 5, GL.). In the females, fertilised eggs are present in the gills.

In April and May, mussels are either in the mature or partially spent stage. In mature mussels the visceropedal mass is full with mature gametes. In partially spent mussels, the visceropedal mass in the posterior region becomes very thin. The vesicular connective tissue between the follicles increases. The follicles show presence of globules. In the male, spermat-

cytical morulae appear towards the periphery of the follicle. In the female follicles are present lipid globules and a few residual oocytes (Fig. 6). The gills contain glochidia and fertilised eggs in various stages of development.

In June and July, the percentage of partially spent mussels increases and that of mature decreases.

In August, September and October the percentages of spent individuals (Figs. 3 and 6) increases and that of partially spent decreases.

Due to the rapid discharge of sperms or ova, the partially spent mussels enter into the spent condition. The spent mussels have their visceropedal mass very thin containing watery fluid. In males, the follicles have a large number of lipid globules (Fig. 3, GL.), spermatocytical morulae (Fig. 3, SC.M.) and a few residual sperms (Fig. 3, S.). In females, the follicles have one or two residual oocytes (Fig. 6, OV.) and lipid globules. The gills in the female contain glochidia.

In November, a majority of the mussels are in spent stages (Figs. 3 and 6) with the remaining in maturing condition (Figs. 1 and 4). In spent mussels the follicles in the posterior part of the visceropedal mass have a functional germinal epithelium. A few follicles show well-developed spermatogonia (Fig. 1, SG.) or oogonia (Fig. 4, OG.). The beginning of gonadal activity indicates the onset of the next breeding season. The gills attain their normal form. In maturing mussels the incipient gonadal activity is indicated by the posterior part of the visceropedal mass becoming slightly thick. The follicles have maturing gametes.

In December, the percentage of spent individuals decreases and that of maturing ones increases. It appears that in *P. favidens var. marcens*, the resting stage is very short as this mussel is a prolonged breeder. The mussels after the spent stage enter into the maturing stage for the next breeding season.

From the foregoing account it is clear that lipid globules in the gonadal follicles appear only after the start of spawning. The lipid globules practically fill the lumen of the follicle showing spent condition. These lipid globules serve as a reserve food material for the next breeding season. In the male gonadal follicles, spermatocytical morulae also appear after the start of spawning. The sex is distinguishable in adult mussels throughout the year. The sexually inactive stage (resting stage) is very short. Only a part of the gonad at a time is in the resting phase for a very short duration.



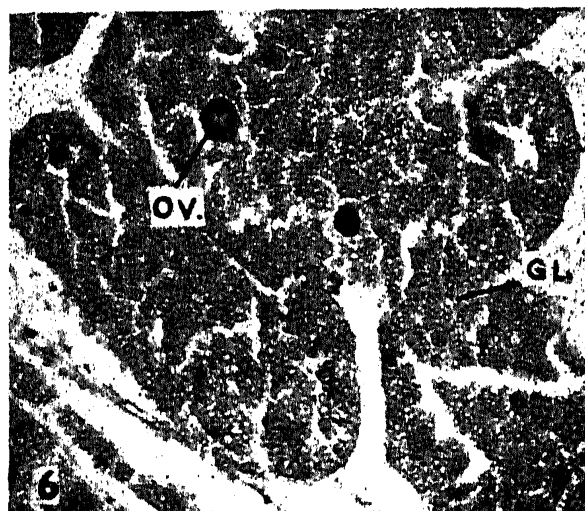
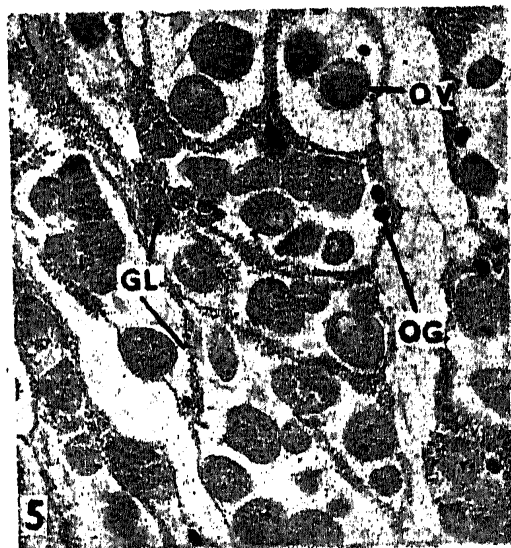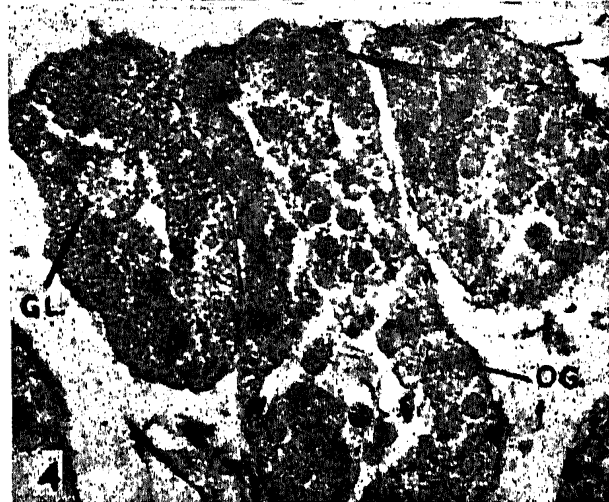
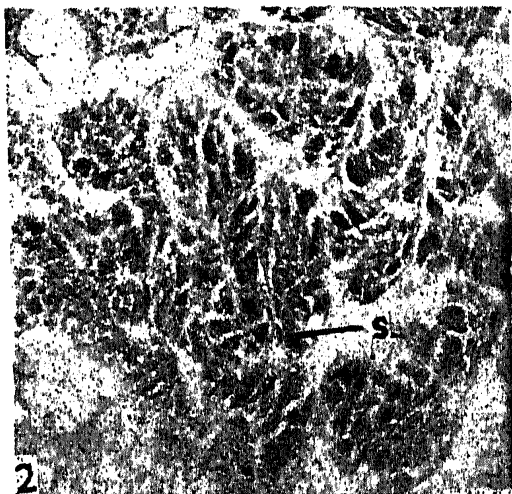
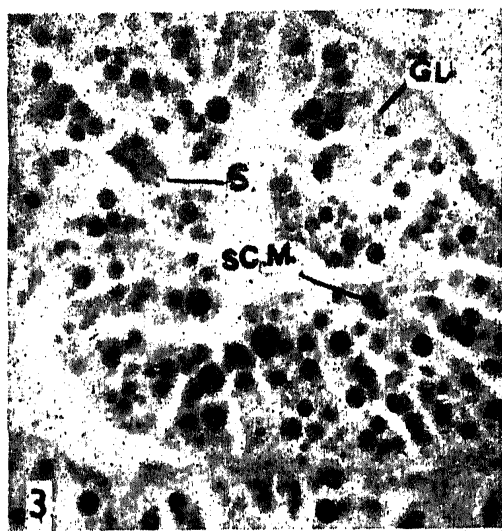
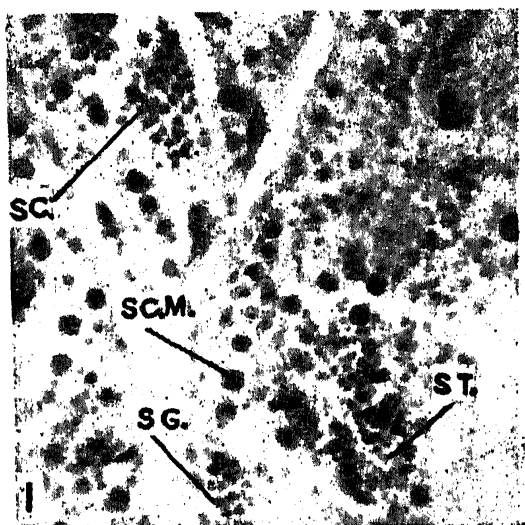
From Tables II and III it is evident that the rapid spawning takes place in the months of June, July and August. This is probably due to the sudden change in the climate.

#### ACKNOWLEDGEMENT

Authors are grateful to Dr. K. V. Rao, Bombay, for his critical study of the manuscript.

#### REFERENCES

- Amemiya, I. .. "Hermaphroditism of the Portuguese oyster," *Nature*, 1925, 116, 608.
- ..... .. "On the sex changes of the Japanese common oyster (*Ostrea gigas* Thunberg)," *Proc. Imp. Acad.*, Tokyo, 1929 a, 3, 284-86.
- ..... .. "A preliminary note on the sexuality of a dioecious oyster, *Ostrea gigas* Thunberg," *Jap. J. Zool.*, 1929 b, 2, 99-102.
- Bloomer, H. H. .. "A note on the sex of *Anodonta cygnea*," *Proc. Malac. Soc.*, Lond., 1930, 19 (1), 10-14.
- ..... .. "A note on the anatomy of *Lamellidens marginalis*, Lamarck and *L. thwaitesii*, Lea," *Ibid.*, 1931, 19 (6), 270-72.
- ..... .. "On the sex and sex modification of the gill of *Anodonta cygnea*," *Ibid.*, 1934, 21 (1), 21-28.
- ..... .. "A further note on the sex of *Anodonta cygnea*," *Ibid.*, 1935, 21 (5), 304-21.
- ..... .. "A note on the sex of *Anodonta* Lamarck," *Ibid.*, 1939, 23 (5), 285-97.
- ..... .. "The seasonal production of spermatozoa and other note on the biology of *Anodonta cygnea*," *Ibid.*, 1946, 27 (2), 62-68.
- Coe, W. R. .. "Sexual phases in the American oyster (*Ostrea virginica*)," *Biol. Bull.*, Woods Hole, 1932 a, 63, 419-41.
- ..... .. "Development of the gonads and the sequence of the sexual phases in the California oyster (*Ostrea lurida*)," *Bull. Scripps Inst. Ocenogr., Tech. Ser.*, 1932 b, 3, 119-39.
- ..... .. "Alternation of sexuality in oysters," *American Naturalist*, 1934, 68, 236-52.
- ..... .. "Sequence of functional sexual phases in *Teredo*," *Biol. Bull.*, Woods Hole, 1936, 71, 122-32.
- and Turner, H. J. .. "Development of the gonads and gametes in the soft-shell clam (*Mya arenaria*)," *J. Morph.*, 1938, 62, 91-111.



FIGS. 1-8



- Loosanoff, V. L. .. "Development of the primary gonad and sexual phases in *Venus mercenaria* Linnaeus," *Biol. Bull.*, Woods Hole, 1937 *a*, 72, 389-405.
- 
- .. "Seasonal gonadal changes of adult clams, *Venus mercenaria* Linnaeus," *Ibid.*, 1937 *b*, 72, 406-16.
- Rao, K. V. .. "Sex change in the oviparous Indian backwater oyster, *Ostrea madrasensis* Preston," *Curr. Sci.*, 1953, 22, 377-78.
- 
- .. "Seasonal gonadal changes in the adult backwater oyster, *Ostrea (Crossostrea) madrasensis* Preston from Ennur near Madras," *Proc. Ind. Acad. Sci.*, 1956, 44 B, 332-56.

## EXPLANATION OF PLATE II

- FIG. 1. Maturing testicular follicle. (SG., spermatogonium; SC., spermatocyte; ST., spermatid; SC.M., Spermatocytical morula.)
- FIG. 2. Mature testicular follicle. [S., sperms (Spermatozoa).]
- FIG. 3. Testicular follicle in spent condition. (S., residual sperms; SC.M., spermatocytical morula; GL., lipid globule.)
- FIG. 4. Maturing ovarian follicle. [OG., oogonium (young oocyte); GL., lipid globule.]
- FIG. 5. Ovarian follicle in partially spent condition. [OV., mature oocyte (ovum); other letters as in Fig. 4.]
- FIG. 6. Ovarian follicle in spent condition. (OV., residual ovum; GL., lipid globule.)
- FIG. 7. Sperm.
- FIG. 8. Mature oocyte (ovum).