

CHARACTERISTIC OF OVARIAN AND ESTRADIOL CONCENTRATIONS IN THE FOLLICULAR FLUID OF SLAUGHTERED ACEH CATTLE

Mulyadi Adam¹, Gholib Gholib^{1*}, Hafizuddin Hafizuddin², Rumi Sahara Zamzami³, and Muhammad Bahi⁴

¹Laboratory of Physiology, Faculty of Veterinary Medicine, Universitas Syiah Kuala, Banda Aceh, Indonesia

²Laboratory of Reproduction, Faculty of Veterinary Medicine, Universitas Syiah Kuala, Banda Aceh, Indonesia

³Study Program of Veterinary Medicine, Faculty of Veterinary Medicine, Universitas Syiah Kuala, Banda Aceh, Indonesia

⁴Departement of Chemistry, Faculty of Mathematics and Natural Sciences, Universitas Syiah Kuala, Banda Aceh, Indonesia

*Corresponding author: gholib@unsyiah.ac.id

ABSTRACT

The objective of this study was to characterize the morphology of ovary from slaughtered Aceh cow and measuring the concentration of estradiol in the follicular fluid to examine the potential utilizing for in-vitro fertilization (IVF) development in Aceh cattle. In total, 30 pairs of ovaries were collected from 30 Aceh cattle slaughtered at Banda Aceh abattoir. Morphological characteristics of ovaries observed were the size of ovaries, weight of ovaries, number of follicles, the diameter of follicles, corpus luteal (CL), and volume of follicular fluid. The follicular fluid was aspirated using a disposable syringe and analyzed the estradiol concentrations using enzyme-linked immunosorbent assay (ELISA). The follicles were grouped into 3 categories based on the diameter (\emptyset) of follicles: small follicles (\emptyset 1 - <5 mm), medium follicles (\emptyset 5 - <8 mm), and large follicles (\emptyset \geq 8 mm). The morphological characteristic of ovaries varied between right and left ovaries in which right ovaries showed bigger size and weight compared to the left ovaries ($P < 0.05$), whereas the number of follicles and follicular fluid did not significantly different ($P > 0.05$). The concentrations of estradiol in follicular fluid of large and medium follicles were significantly higher compared to small follicles ($P < 0.05$), whereas the concentration of estradiol between large and medium follicles, did not significant different ($P > 0.05$). In conclusion, the follicles from abattoir can be used as potential oocytes resources to support IVF development for Aceh cattle in the future. The follicular fluid provided from these follicles can be an alternative for in vitro maturation media of oocytes due to containing high estradiol concentrations.

Key words: Aceh cattle, estradiol, follicular fluid, ovaries

ABSTRAK

Tujuan dari penelitian ini adalah untuk mengkarakterisasi morfologi ovarium sapi aceh dari Rumah Potong Hewan (RPH) dan mengukur konsentrasi estradiol dalam cairan folikuler untuk menguji potensi pemanfaatannya untuk pengembangan fertilisasi in-vitro (IVF) pada sapi aceh. Sebanyak 30 pasang ovarium dikumpulkan dari 30 sapi aceh yang disembelih di RPH, Banda Aceh. Karakteristik morfologis ovarium yang diamati yaitu, ukuran, berat, jumlah folikel, diameter folikel, corpus luteal (CL), dan volume cairan folikel. Cairan folikel diaspirasi menggunakan jarum suntik dan selanjutnya konsentrasi estradiol diukur menggunakan metode enzyme-linked immunosorbent assay (ELISA). Folikel dikelompokkan menjadi 3 kategori berdasarkan diameter (\emptyset) folikel yaitu: folikel kecil (\emptyset 1 - <5 mm), folikel sedang (\emptyset 5 - <8,5 mm), dan folikel besar (\emptyset 8 mm). Karakteristik morfologi ovarium bervariasi antara ovarium kanan dan ovarium kiri yang mana ovarium kanan menunjukkan ukuran, dan berat ovarium kanan lebih besar secara signifikan dibandingkan dengan ovarium kiri ($P < 0,05$), tetapi jumlah folikel dan volume cairan folikuler antara ovarium kanan dan kiri tidak berbeda ($P > 0,05$). Konsentrasi estradiol pada cairan folikel besar dan folikel sedang secara signifikan lebih tinggi dibandingkan dengan folikel kecil ($P < 0,05$), sedangkan konsentrasi estradiol antara folikel besar dan folikel sedang tidak berbeda ($P > 0,05$). Berdasarkan hasil yang diperoleh maka dapat disimpulkan bahwa folikel dari RPH dapat digunakan sebagai sumber daya oosit potensial untuk mendukung pengembangan IVF untuk sapi Aceh di masa depan. Selain itu, cairan folikel yang disediakan dari folikel-folikel ini dapat menjadi alternatif untuk media pematangan in vitro oosit karena mengandung estradiol yang tinggi.

Kata kunci: sapi aceh, estradiol, cairan folikel, ovarium

INTRODUCTION

Aceh cattle are local-breed cattle from Aceh Province. According to the official report from Kementerian Pertanian (2011) number 2907/kpts/ot.140/6/2011, the characteristics of Aceh cattle: the fur color of cows is brown-reddish and dark red for bulls; the fur color at the back-body posterior is dark brown; the mass of bulls is approximately 253 \pm 65 kg and 148 \pm 37 kg for cows; the height of "gumba" for bulls and cows is 116 \pm 24 cm, and 102 \pm 21 cm, respectively (Abdullah *et al.*, 2012; Sari *et al.*, 2016) The Aceh cattle have a smaller posture, but they have a good meat production with the carcass proportion of approximately 49%, relatively smoother and confined of meat structure that is better compared to the Brahman and the Ongoles cattle (Rizal, 2013). Moreover, it also adequately contributes to the fulfillment of meat product for the people of Aceh (Dinas Kesehatan Hewan dan Peternakan Aceh, 2011).

For the last three years (2010-2013), the escalating demand for annual meat products has resulted in the number of cattle cow slaughtering (in average 3,046 cows per year) including Aceh cattle (bulls and cows) and other cattle (Badan Perencanaan dan Pembangunan Daerah Kota Banda Aceh, 2014). Along with the growing of slaughtering numbers, the volume of waste products produced by the slaughtering house was also increased namely solid and liquid wastes such as ovary waste. The fact that the presence of different sized follicles with the liquid inside in ovary can be useful for several purposes such as oocyte sources, maturation media, and others). However, the benefit from the ovary waste of Aceh cattle has not fully considered. Therefore, it is necessary to characterize the ovarium waste such as number of type of follicles, number of follicular fluid, and the composition of the liquid follicles to support the possibility of in-vitro fertilization (IVF) development in Aceh cattle using these waste (Nagai *et al.*, 2016).

Previous studies stated that the composition of the liquid follicles consists of insulin-like growth factor I (IGF-I), IGF-binding protein (IGF-BP), follicle stimulating hormone (FSH), luteinizing hormone (LH), estrogen and progesterone (Hafez, 2000; Lamy *et al.*, 2016). One of the valuable components of the follicle liquid is the estrogen (E2). E2 is formed in the follicle of granulosa cells through several steps of enzyme reaction conversions. Measurement of estrogen concentration in the follicular fluid can be used to determine the doses when it used for IVF technology and predict the presence and the quality of oocyte. One of the main functions of E2 estrogen as the reproduction hormone in the female is to control the estrus cycle (Binelli *et al.*, 2018). Additionally, E2 also contribute to the central nervous system regarding the induction of female cattle's behavior, although a small concentration of progesterone is also needed in this mechanism (Wiltbank *et al.*, 2014). In the body metabolism, estrogen increases the growth hormone so that it can stimulate the growth of cells inside the body, raise the body weight, and trigger the adrenal cortex to increase the protein metabolism. In the mammary gland, estrogen acts as the hormone which highly affects the growth of mammary gland system (Yart *et al.*, 2013). So far, a study of estrogen measurement from the waste ovarium from Aceh cattle is still absent. The objective of the present study therefore to a) characterize the morphology of ovary from the slaughtered Aceh cattle, and b) measure the concentration of estrogen in follicular fluid in order to support further study of IVF development in the Aceh cattle.

MATERIALS AND METHODS

Collection and Characterization of Ovaries

During two months study, 30 pairs of ovaries were collected from 30 Aceh cattle slaughtered at Banda Aceh abattoir. The collected ovaries were put into a clean tube containing 0.9% NaCl and stored in a cool box and then transported to the laboratory. Afterwards, the ovaries were cleaned from the fatty tissue. Finally, the morphological characteristic of the ovaries was observed. The ovaries were examined for size, weight, number of follicles, the diameter of follicles, corpus luteum (CL), and amount of follicular fluid (FF).

Aspiration of the Follicular Fluid

After observation of the morphological characteristic of ovaries, the follicular fluid was aspirated using a disposable syringe. The follicles were grouped into 3 categories based on the diameter (\emptyset) of follicles namely: small follicles ($\emptyset 1 - < 5$ mm: SF), medium follicles ($\emptyset 5 - < 8.5$ mm: MF), and large follicle ($\emptyset > 8.5$ mm: LF). This classification is based on the functional status of the follicles as described by Murasawa *et al.* (2005). The obtained FF pool from each category was then centrifuged at 1200 x g for 10 minutes at 4° C. The supernatant was placed into 2 ml microtube and stored at -20° C until estradiol measurements.

Estradiol Measurements

The concentrations of estradiol were measured using a commercial estradiol ELISA kits (DGR EIA 2693, DRG Instruments GmbH, Germany). The cross-reactivities of this assay are as follows: 100% with estradiol-17, 6.86% estrone, 2.27% estriol, 0.033% with testosterone, 0.003% with 17-hydroxyprogesterone, and <0.0001% with all other steroid tested. Hormone analysis was performed following the instruction from the manufacturer. Prior to assay, FF was diluted in assay buffer (dilution 1:20). Duplicate 25 μ L aliquots of diluted FF were assayed along with 25 μ L aliquots standard (dose range 25-2000 pg/mL), low control, and high control on microtitre plates coated with a polyclonal (rabbit) antibody directed towards an antigenic site of the estradiol molecule. Afterwards, 100 μ L enzyme conjugate was added to each well and the mixture solution incubated for 90 minutes at room temperature. Following incubation, the plates were washed four times with washing solution and blotted dry. After that, 100 μ L substrate solution (tetramethylbenzidine) was then added to each well. The plates re-incubated for 30 minutes at room temperature. The enzyme reaction was stopped with 500 μ L 0.5 M H₂SO₄ in each well. Finally, absorbance was measured at 450 nm on an automatic plate reader (ELISA reader). The concentration of estradiol was calculated using the MPM6 program.

The analytical sensitivity of the assay was 10.6 pg/mL. Intra-assay coefficients of variation (CVs) of low and high controls were 3.6% and 4.5%, respectively (n= 6). Inter-assay CVs of low and high controls were 5.2% and 8.3%, respectively (n= 3).

Data Analysis

Data of morphological characteristic of ovaries were analyzed using independent samples T-test to determine whether there was a statistically significant difference between left and right ovaries in size, weight, number of follicles, and amount of FF. A two-way analysis of variance (ANOVA) was used to examine whether the diameter of follicles (three different categories of follicles) and female status (present or absent of CL in ovaries) influence the concentrations of estradiol. All statistical tests were two-tailed and statistical significance was set to = 0.05.

RESULTS AND DISCUSSION

Characteristic of Ovarian Morphology of Aceh Cattle

The results of morphological observation of ovarian revealed that the right and left ovarian of Aceh cattle showed a different characteristic. The mean of ovarian diameter from right and left ovary was 17.84 \pm 0.77 mm, and 15.86 \pm 0.51 mm, respectively which showed a significantly different (t= 2.144, p= 0.037, Figure 1a). Moreover, the right ovary has also a bigger weight compared to the left ovary: 3.67 \pm 0.42 g and 2.62 \pm 1.56 g, respectively and it was statistically different

($t= 2.080$, $p= 0.043$, Figure 1b). The mean of follicles number and amount of follicular fluid did not show significantly different between right and left ovary ($P>0.05$). The mean of follicles number from right and left ovary was 13.73 ± 1.73 follicles and 10.10 ± 1.34 follicles, respectively (Figure 1c), whereas the mean of follicular fluid from the right and left ovary was 0.41 ± 0.06 mL, and 0.31 ± 0.04 mL, respectively (Figure 1d). In total 715 follicles observed from 30 pairs ovaries, 94.82% was a small follicle ($\varnothing < 5$ mm), whereas 2.57% and 2.61% were medium ($5 \leq \varnothing < 8$ mm), and large ($\varnothing \geq 8$ mm) follicles, respectively (Figure 1e). From 30 cattle, 11 (36.67%) of the cattle revealed a CL, while 19 (63.33%) did not show a CL (Figure 1f).

The difference of several morphological parameters between right and left ovary (Figure 1) suggested that the right ovaries be more active than the left ovaries. It

can be occurred due to the right ovaries get more amount of blood than left ovaries (Ali *et al.*, 2001). Moreover, it can be inferred that the medium and large follicles were not always found in the female ovaries slaughtered at the abattoir. However, small follicles were always found. These follicles can be used as potential oocytes resources to support IVF development for Aceh cattle in the future. In addition, the follicular fluid provided from these follicles can be an alternative for in vitro maturation media of oocytes.

Rodgers and Irving-Rodgers (2010) reported that during estrus cycle cow in which the concentration of FSH is high, there would be approximately 17-18 small follicles, 5-7 medium follicles, and 1-4 large follicles. The diameter of antrum at the beginning its formation is around 0.25 mm then developed to be more than 14 mm which is termed as preovulation follicle or follicle

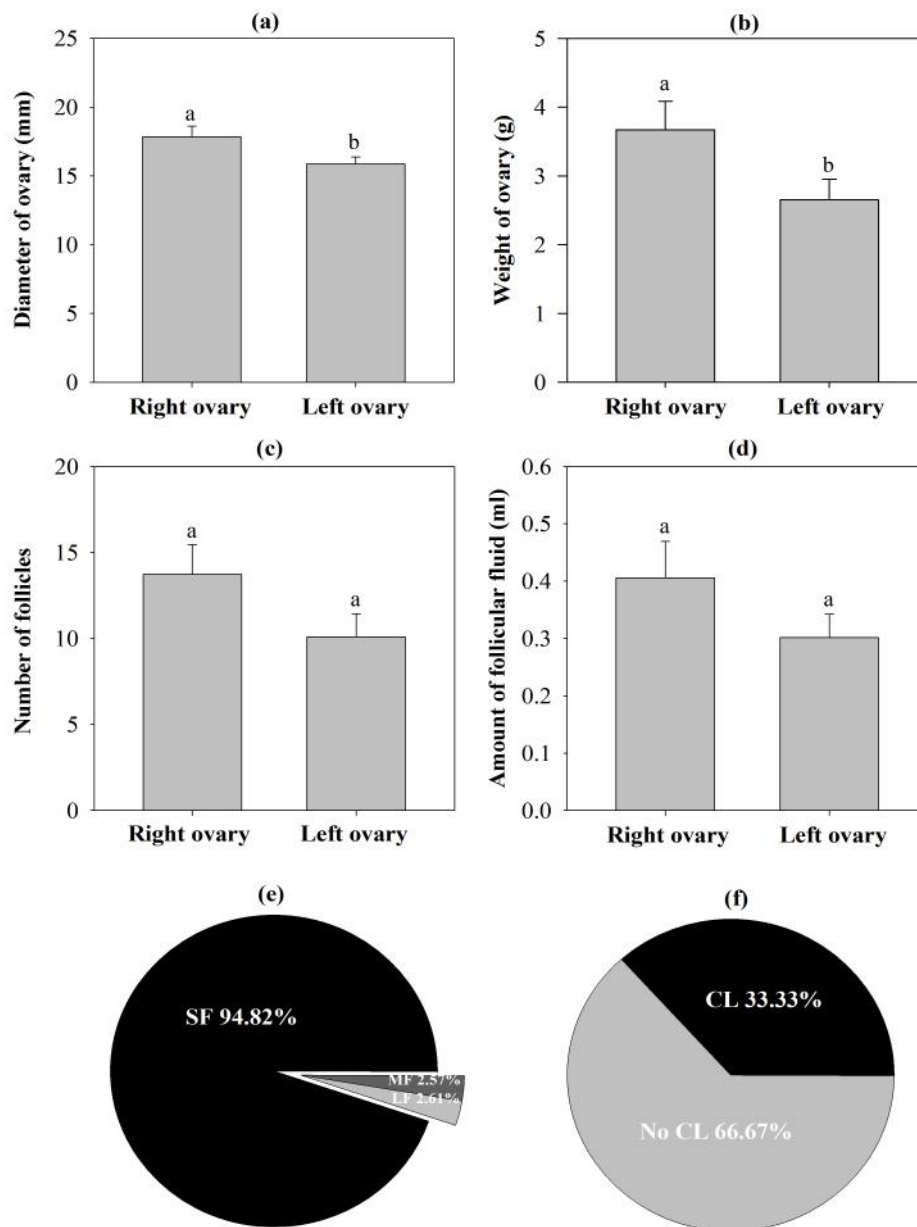


Figure 1. Characteristic of ovarian morphological features in Aceh cattle slaughtered at Banda Aceh abattoir. A= Diameter of ovaries, b= Weight of ovaries, c= A number of follicles, d= Amount of follicular fluid, e= Different category of follicles, and f= The existence of corpus luteum. SF= Small follicles, MF= Medium follicles, LF= Large follicles, CL= Corpus luteum. Different superscript above histogram showed a significantly different ($P<0.05$), $N=30$

Table 1. Mean (\pm SE) of estradiol concentration from different size of follicles in Aceh cattle

Follicle categories	Concentration of estradiol (ng/mL)
Small	24.88 \pm 3.26 ^a
Medium	70.76 \pm 8.68 ^b
Large	70.51 \pm 2.54 ^b

^{a, b}Different superscripts within the same column indicate significantly different

de Graaf (Zangirolamo *et al.*, 2018). In Thianzu cows, small follicles are categorized in having a diameter of less than 4 mm, medium follicles of 4-6 mm, and large follicles of more than 6 mm (Tao *et al.*, 2014). In dairy cows, the diameter of small, medium, and large follicles reported 3-5 mm, 6-9 mm, and 10-20 mm, respectively (Kor, 2014). Cushman *et al.* (2009) stated that in normal cows, the size of small, medium, and large follicles are 3-5 mm, 6-10 mm, and more than 10 mm, respectively.

Concentration of Estradiol in Follicular Fluid of Aceh Cattle

Despite providing the oocytes, the follicles obtained follicular fluid that contains several hormones such as estradiol. The concentration of estradiol obtained from Aceh cows was presented in Table 1. The results of statistical analysis showed that different size of follicles has a significant difference in the concentration of estradiol [F(2,46)= 11.322, p= 0.000]. The concentrations of estradiol from small follicles were significantly smaller compared to medium follicles (p= 0.000), and large follicles (p= 0.012). However, the concentration of estradiol between medium and large follicles did not show significant different (p= 0.990).

According to Perry *et al.* (2014), there is a positive correlation between the follicle diameters with the estradiol concentration in the cow. The concentration of estradiol achieves its highest ratio at the time of estrus. This phase is called the peak of the estradiol phase. During this stage, the ovarian follicles experience an increase in size mainly due to the rise of the liquid follicle which contains estrogenic liquid (Vassena *et al.*, 2003). Several previous studies were reported regarding the estradiol concentration in follicular fluid in cattle. For example, in Zebu cows, the estradiol concentrations in the follicular fluid and serum were 1.76 ng/mL and 0.08 ng/mL, respectively (Opara *et al.*, 2006). In Bos Taurus cows, the estradiol concentrations were in a range of 300-500 ng/mL, while in Bos Indicus cows were around 2 ng/mL (Opera *et al.*, 2006). These results indicated that estradiol concentration in follicular fluid differed between cattle. Therefore, it is necessary to measure it before using it.

The concentration of estradiol obtained from small follicles between right and left ovaries did not show a significantly different (t= -0.362, p= 0.719). The mean of estradiol concentrations between right and left ovaries I small follicles were 25.34 \pm 5.59 ng/mL, 28.03 \pm 4.73 ng/mL, respectively. Moreover, the concentrations of estradiol from small follicles with or without CL did not show significant differences (t= -0.210, p= 0.835). The data show that the concentrations of estradiol from small follicles in Aceh cattle were higher compared to the results reported from several previous studies (Opera *et al.*, 2006). It seems that the follicular fluid from

small follicles is a good candidate to be used for estradiol resources.

The concentrations of estradiol in follicular fluid is different between phases of estrus cycles which it usually increases during the follicular phase and decreases drastically after the ovulation. According to Senger (2005), there are 4 processes of the follicle development: recruitment, selection, dominant, and atresia. In particular, Torres *et al.* (2012) stated that the recruitment stage corresponds to the initialization of follicle development which is caused by the high concentration of FSH hormone. Each of the occurred follicle waves started when the FSH hormone concentration reaches its highest state within 1-2 days which will trigger the follicles to develop. The well-developed follicle is then entering the next phase and in fact having the enzyme activity of P450-SCC and P450-aromatase, which acts as the catalyst in the formation of estradiol. After the recruitment phase, a group of follicles which is not experiencing the atresia stage will be entering the selection phase. According to Torres *et al.* (2012), the ability of a follicle to produce a good estradiol and gonadotropin receptor determines the development of follicle for entering the next phase. This will result in the production of LH secretion to induce ovulation.

Dominant phase is one or more follicles start to develop exponentially in terms of its size and secretion. In dogs and cats, the selected follicle experiences more than one dominant phase. However, in cows, horses, and human, there is only one selected follicle and experience the dominant phase (Senger, 2005). Dominant phase in cows occurs when the follicle diameter has reached to more than 8 mm. This will enable the production of high concentration estradiol in addition to the production of inhibin for FSH hormone. This inhibin is one type of sulfide bonded glycoprotein which is categorized to superfamily TGF- β . Inhibin is produced by granulosa cells inside the follicles (Torres *et al.*, 2012). Therefore, the small follicle contains less estradiol than the medium follicle, and the large follicle contains the highest concentration of estradiol.

CONCLUSION

The follicles can be used as a potential oocytes resources to support IVF development for Aceh cattle in the future. In addition, the follicular fluid provided from these follicles can be an alternative for in vitro maturation media of oocytes.

REFERENCES

- Abdullah, M., H. Martojo, R.R. Noor, and D.D. Solihin. 2012. Genetic characterization of the Aceh cattle using phenotypic, mitochondrial DNA of D-loop region and microsatellite DNA analyses. *Reprod. Dom. Anim.* 47 (Suppl. 1):15-17.
- Ali, A., A. Lange, M. Gilles, and P.S. Glatzel. Morphological and functional characteristics of the dominant follicle and corpus

- luteum in cattle and their influence on ovarian function. **Theriogenology**. 56:569-576.
- Badan Perencanaan dan Pembangunan Daerah Kota Banda Aceh. 2014. **Statistik Banda Aceh 2014**. BAPPEDA Kota Banda Aceh. Banda Aceh.
- Binelli, M., A.M. Gonella-Diaza, F.S. Mesquita, and C.M.B. Membrive. 2018. Sex steroid-mediated control of oviductal function in cattle. **Biology** (review). 7(15):1-24.
- Cushman, R.A., M.F. Allan, L.A. Kuehn, W.M. Snelling, A.S. Cupp, and H.C. Freetly. 2009. Evaluation of antral follicle count and ovarian morphology in crossbred beef cows: Investigation of influence of stage of the estrous cycle, age, and birth weights. **J. Anim. Sci.** 87:1971-1980.
- Dinas Kesehatan Hewan dan Peternakan Aceh. 2011. **Profil Sapi Aceh**. DINKESWANNAK Aceh, Banda Aceh.
- Hafez, E.S.E. 2000. **Reproduction in Farm Animals**. 7th ed. Baltimore (US): Lippincott Williams & Wilkins, Philadelphia.
- Kementrian Pertanian. 2011. **Penetapan Rumpun Sapi Aceh**. Keputusan Menteri Pertanian Nomor: 2907/kpts/ot.140/6/2011. Jakarta.
- Kor, N.M. 2014. The effect of corpus luteum on homonal composition of follicular fluid from different size follicles and their relationship to serum concentration in dairy cows. **Asian Pac. J. Trop. Med.** 7:S282-S288.
- Lamy, J., P. Liere, A. Pianos, F. Aprahamian, P. Mermillod, and M. Saint-Dizier. 2016. **Theriogenology**. 86:1409-1420.
- Murasawa, M., T. Takahashi, H. Nishimoto, S. Yamamoto, S. Hamano, and M. Tetsuka. 2005. Relationship between ovarian weight and follicular population in heifer. **J. Reprod. Dev.** 51(5):689-693.
- Nagai, K., Y. Yanagawa, S. Katagiri, and M. Nagano. 2016. The relationship between antral follicle count in a bovine ovary and developmental competence of in vitro-grown oocytes derived from early antral follicles. **Biomedical Research** (Tokyo). 37(1):61-71.
- Opara, M.N., C.I. Okoli, U. Herbert, and O. Adeyemo. 2006. Ovarian morphology and estradiol-17 β concentrations in serum and follicular fluid of slaughtered zebu cattle in Ibadan, Nigeria. **Veterinarski Arhiv**. 76(5):403-441.
- Perry, G.A., O.I. Swanson, E.I. Larimore, B.I. Perry, and D.G. Dijkstra. 2014. Relationship of follicle size and concentrations of estradiol among cows exhibiting or not exhibiting estrus during a fixed-time AI protokol. **Dom. Anim. Endocrinol.** 48:15-20.
- Rodgers, R.J. and H.F. Irving-Rodgers. 2010. Morphological classification of bovine ovarian follicles. **Reproduction** (review). 139:309-318.
- Sari, E.M., H. Jianlin, R.R. Noor, C. Sumantri, and E.T. Margawati. 2016. Phylogenetic analysis of Aceh cattle breed of Indonesia through mitochondrial D-Loop region. **J. Genet. Eng. Biotechnol.** 14:227-231.
- Senger, P.L. 2005. **Pathways to Pregnancy and Parturition**. Washington State University, Pullman. 2nd ed. Washington State University, Pullman.
- Tao, J., G. Zhao, X. Zhao, F. Li, X. Wu, J. Hu, and Y. Zhang. 2014. Proteomic analysis of the follicular fluid of tianzhu white yak during diestrus. **Int. J. Mol. Sci.** 15:4481-4491.
- Torres, A.M.R., A.G. Sanches, and C.G. Agullar. 2012. Follicular development in domestic ruminants. **Trop. Subtrop. Agroecosyst.** 15(1): S147-S160.
- Vassena, R., R.J. Mapletoft, S. Allodi, J. Singh, and G.P. Adams. 2003. Morphology and developmental competence of bovine oocytes relative to follicular status. **Theriogenology**. 60:923-932.
- Wiltbank, M.C., A.H. Souza, P.D. Carvalho, A.P. Cunha, J.O. Giordano, P.M. Fricke, G.M. Baez, and G. Diskin. 2014. Physiological and practical effects of progesterone on reproduction in dairy cattle. **Animal**. 8:70-81.
- Yart, L., V. Lollivier, P.G. Marnet, and F. Dessauge. 2014. Role of ovarian secretions in mammary gland development and function in ruminants. **Animal**. 8(1):72-85.
- Zangirolamo, A.F., F. Morotti, C.N. da Silva, T.K. Sanches, and M.M. Seneda. 2018. Ovarian antral follicle populations and embryo production in cattle. **Proceeding of the 34th Meeting of the Association of Embryo Transfer in Europe (AETE)**: Nantes, France.