

THE ANTI-OXIDANT ACTIVITIES OF ETHANOL EXTRACT OF MAHOGANY (*Sweitenia mahagoni* Jacq.) SEEDS IN THE LIVER TISSUES OF DIABETIC EXPERIMENTAL RATS

Eka Prasetiawan¹, I Ketut Mudite Adnyane¹, and Tutik Wresdiyati^{1*}

¹Department of Anatomy, Physiology and Pharmacology, Bogor Agricultural University, Bogor, Indonesia

*Corresponding author: tutikwr@gmail.com

ABSTRACT

The aim of this research was to analyze the anti-oxidant activities of ethanol extract of mahogany seeds on the liver tissues of diabetic experimental rats to overcome oxidative stress condition. This study used male *Rattus norvegicus* strain Sprague Dawley which were divided into 5 groups: (i) negative control group (K-), (ii) positive control group/diabetes mellitus (DM) (K+), (iii) DM group treated with 500 mg/kg BW ethanol extract of mahogany seeds (EM), (iv) DM group treated with acarbose (KO), and (v) non-DM group treated with 500 mg/kg BW ethanol extract of mahogany seed (KE). Alloxan with dose of 110 mg/kg BW was used to induce diabetes in rats. The treatments were conducted for 28 days. At the end of treatment, the liver tissues were collected and analyzed for malondialdehyde (MDA) content using thiobarbituric acid reactive substance (TBARS) method and anti-oxidant copper zinc superoxide dismutase (Cu,Zn-SOD) content using immunohistochemical technique. The result showed that level of MDA were significantly different ($P < 0.05$) in K-; K+; EM; KO; and KE with values were 0.81 ± 0.17 ; 1.19 ± 0.26 ; 1.10 ± 0.04 ; 0.95 ± 0.13 ; and 0.92 ± 0.01 $\mu\text{mol/gram}$, respectively. The anti-oxidant content (Cu, Zn-SOD) of rat liver tissue in K+ lower than in K-, while anti-oxidant content in EM and KE were higher compared to K+. The study concluded that ethanol mahogany seeds extract decreased blood glucose levels and increased the anti-oxidant status in the liver tissues of diabetic rats.

Key words: anti-oxidant, diabetic, superoxide dismutase, *Sweitenia mahagoni*

ABSTRAK

Penelitian ini bertujuan menganalisis aktivitas anti-oksidan ekstrak etanol biji mahoni pada jaringan hati tikus model diabetes melitus (DM) dalam upaya menanggulangi kondisi stres oksidatif. Dalam penelitian ini digunakan tikus jantan *Rattus norvegicus* galur Sprague Dawley. Tikus dibagi dalam lima kelompok, yaitu kontrol negatif (K-), kontrol positif/DM (K+), kelompok DM yang diberi ekstrak etanol biji mahoni 500 mg/kg bobot badan (EM), kelompok DM yang diberi acarbose (KO), dan kelompok non-DM yang diberi ekstrak etanol biji mahoni 500 mg/kg bobot badan (KE). Kondisi DM dilakukan melalui induksi aloksan (110 mg/kg bobot badan). Perlakuan diberikan selama 28 hari. Pada akhir perlakuan, jaringan hati tikus diambil dan dilakukan analisis terhadap jumlah malondialdehyde (MDA) dengan metode thiobarbiturate acid reactive substance (TBARS) dan jumlah kandungan anti-oksidan kuprum zink superoksida dismutase (Cu, Zn-SOD) dengan teknik imunohistokimia. Kadar MDA ($\mu\text{mol/gram}$) pada K-; K+; EM; KO; dan KE masing-masing adalah $0,81 \pm 0,17$; $1,19 \pm 0,26$; $1,10 \pm 0,04$; $0,95 \pm 0,13$; dan $0,92 \pm 0,01$ ($P < 0,05$). Hasil analisis uji kualitatif terhadap kandungan anti-oksidan menunjukkan bahwa kandungan antioksidan Cu, Zn-SOD pada jaringan hati tikus kelompok K+ lebih rendah dibandingkan pada tikus kelompok K-. Kandungan anti-oksidan pada tikus kelompok EM dan KE juga terlihat lebih tinggi dibandingkan kelompok K+. Dari hasil penelitian disimpulkan bahwa ekstrak etanol biji mahoni dapat menurunkan kadar gula darah dan meningkatkan status anti-oksidan pada jaringan hati tikus diabetes.

Kata kunci: antioksidan, diabetes, superoksida dismutase, *Sweitenia mahagoni*

INTRODUCTION

International Diabetes Federation (IDF, 2013) reported that the number of people with diabetes mellitus (DM) in 2013 reached 382 million people globally and was estimated to increase to 592 million people by 2035. Nowadays, the number of people with DM in Indonesia reached 8.5 million people, demanding a serious consideration and handling in order to decrease the number which rising in each year. Diabetes Mellitus is a metabolic disorder marked with high glucose levels in blood. The decreasing metabolism of glucose, fat, and protein in diabetics occurred because of insulin deficiency and resistance (Gardner and Shoback, 2007). In diabetic sufferers, the production of reactive oxygen and free radicals increased, leading to an oxidative stress condition (Giacco and Brownlee, 2010), a condition which the amount of anti-oxidant is lower than the number of free radicals.

In a case of diabetes mellitus, Wresdiyati *et al.* (2008); Wresdiyati *et al.* (2014); Wresdiyati *et al.* (2015) reported a decreasing concentration of Cu, Zn-SOD in pancreatic tissue in diabetic experimental rat.

As an alternative handling of oxidative stress condition, diabetics may consume high anti-oxidant plants in order to prevent complication caused by diabetes and help lower glucose level in blood.

Several studies showed that the ethanol extract of mahogany stem (*Mahonia oiwakensis* Hayata) that commonly grow in Taiwan have an anti-oxidant, analgesic, anti-inflammation, and hepatoprotector properties (Chao *et al.*, 2013). Debasis *et al.* (2011) and Suryani (2013) reported that methanol extract of Mahogany seed (*Sweitenia mahagoni* Jacq.) are hypoglycemic, able to increase insulin levels and decrease TNF- α expression on diabetic rats that was induced with streptozotocin (STZ). Another study reported that ethanol extract of mahogany seed is able to inhibit the activity of α -glucosidase enzyme in alloxan-induced diabetic rats (Hasan *et al.*, 2011) and in sucrose-induced hyperglycemia rats (Wresdiyati *et al.*, 2015). Mahogany seed extract has phytochemical compounds such as flavonoids, saponins, and triterpenoids (Wresdiyati *et al.*, 2015). It is known that flavonoid acts as a natural anti-oxidant compounds, but the effect of ethanol extract of mahogany seed in the

liver of diabetic rats has never been reported. Therefore, this study aimed to analyze anti-oxidant activity of ethanol extract of mahogany seed in liver tissue of diabetic rats model in order to prevent oxidative stress condition.

MATERIALS AND METHODS

This study used 25 rats (*Rattus norvegicus*) strain Sprague Dawley obtained from Laboratory Animal Management Unit of Faculty of Veterinary Medicine, Bogor Agricultural University. The rats were divided into 5 groups: negative control group (K-), positive control group/diabetes mellitus (DM) (K+), DM group treated with 500 mg/kg BW of the ethanol extract of mahogany seeds (EM), DM group treated with 10 mg/kg of acarbose (KO), and non-DM group treated with 500 mg/kg BW of the ethanol extract of mahogany seed (KE). The alloxan (110 mg/kg BW) was injected intraperitoneally to induce diabetes in all rats except rat in group K- and KE. The experiment was conducted for 28 days. Feed ration was weighed every day, while blood glucose levels and rat body weight were measured once in four days. On day 29 rats were anesthetized using a combination of ketamine (75 mg/kg BW) and silacin (8 mg/kg BW). Rat liver was taken in order to analyze the level of malondialdehyde (MDA) and concentration of anti-oxidant Cu, Zn-SOD through immunohistochemistry technique.

MDA Levels Analysis

MDA levels were analyzed by thiobarbiturate acid reactive substance (TBARS) method (Suarsana *et al.*, 2013). Liver organ crushed in phosphate buffer saline (PBS) and centrifuged (3500 rpm, 20 minutes, with temperature 25° C). Then the supernatant was taken and added with 4 ml cold HCl contained 15% trichloroacetic acid (TCA), 0.38% thiobarbituric acid (TBA), and 0.5% butylated hydroxytoluene (BHT). The mixture then heated at 80° C for 1 hour, followed with centrifuge (3500 rpm, 15 minutes, 25° C temperature). After that we used spectrophotometer to measured, the absorbance with wavelength (532 nm) and standard solution 1,1,3,3-tetraethoxypropane (TEP).

Liver Tissue Processing

Prior to the process of analyzing the content of anti-oxidant Cu, Zn-SOD with immunohistochemistry techniques, the liver tissue has been sampled fixed in Bouin fixation solution for 24 hours. After that the next process was dehydrating the tissue using alcohol with stratified concentration (70%, 80%, 90%, 95% until absolute alcohol I, II, III) and continued with tissue clearing stage with xylene solution (xylene I, II, III). Next, the tissue was infiltrated with paraffin (paraffin I, II, III) carried out in the oven and followed by embedding the tissue in paraffin mold. Then, the tissue block was cut (sectioning) thickness 4 µm using microtome. The pieces of tissue in the form of ribbons were attached to a glass object that had been given glue

(0.2% neofren® in toluene). Furthermore, the immunohistochemistry staining stage was performed.

The Analysis of Cu, Zn-SOD Concentration with Immunohistochemistry Technique

Anti-oxidant Cu, Zn-SOD profile was detected by using Immunohistochemistry technique with the method previously used by Wresdiyati *et al.* (2014). Liver tissue that had been deparaffinized was soaked in H₂O₂ in order to block endogen peroxidase for 15 minutes before washed with PBS. Then, the tissue was incubated in a 10% normal serum to block non-specific protein for 30-60 minutes, before washed with PBS. After that, the tissues was re-incubated in background sniper for 15 minutes, incubated in antibody Cu, Zn-SOD for 48 hours and washed with PBS. After that, the tissue incubated in Trekkie Universal Link for 20 minutes, washed with PBS, re-incubated with Trekkie Avidin-HRP for 10 minutes, and washed with PBS. The reaction result between antigen and antibody then visualized using diaminobenzidine (DAB) and counterstain with hematoxylin. The tissue then dehydrated with alcohol and cleansed with xylene. After the process, the tissue was mounted with entellan®. The existence of Cu, Zn-SOD marked with the appearance of brown color on the nucleus and cell cytoplasm. Qualitative observation were based on the intensity of a brown color in nucleus and cell cytoplasm, in which the more equal color distribution refer to the more content of Cu, Zn-SOD, while cell that did not contain Cu, Zn-SOD will not reacted marked with the appearance of blue color (hematoxylin) from counterstain. Quantitative observation were performed by counting the amount of hepatocytes that both positively and negatively reacted with Cu, Zn-SOD in the observed tissue. The number of hepatocytes was measured using a McMaster Biophotonics Image J. software program.

RESULTS AND DISCUSSION

Body Weight and Total Ration of Rat Experiment Consumption

The change of rat body weight after 28 days trial can be seen in Figure 1. With the exception of group K+ (had a tendency with stable body weight), the rats body weight from all groups were increased. The lower body weight of K+ rats as compared to other groups possibly caused by low production of insulin, which caused the glucose unable to enter into cell. This condition made glucose unable transformed to be energy, so it could not be restored in glycogen form which in turn caused weight loss in diabetic rats. Total consumption of experimental rat can be seen at Table 1.

Table 1 showed that total ration consumed by K+ groups significantly higher (P<0.05) than K- and KE groups, but the amount of ration consumed in K+ did not followed by weight gain (Figure 1). Probably a low insulin production in K+ group caused by DM was responsible for inability of the glucose in blood to enter to cell. This

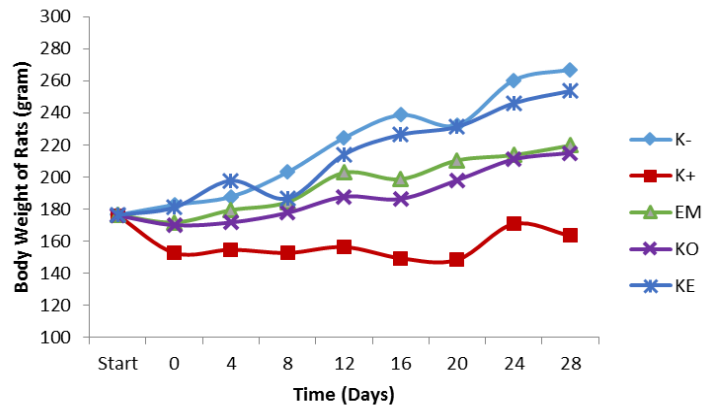


Figure 1. Body weight of experimental rats. K-= Negative control; K+= DM; EM= DM + ethanol extract of mahogany seeds; KO= DM

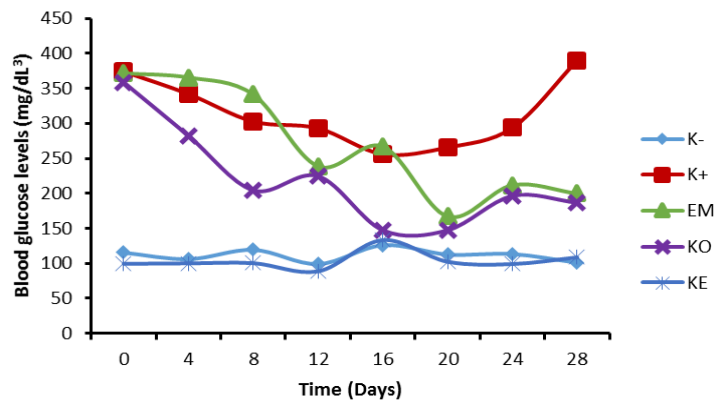


Figure 2. Blood glucose level in experimental rats. K-= Negative control; K += DM; EM= DM + ethanol extract of mahogany seeds; KO= DM + acarbose; KE= Non DM + ethanol extract of mahogany seeds

Table 1. The amount of ration consumption in rat treatment for 28 days

Treatment	Amount of ration consumption (g)
K- (Negative control)	634.67±96.19 ^b
K+ (DM)	861.33±80.01 ^a
EM (DM + ethanol extract of mahogany seeds)	727.33±31.08 ^{ab}
KO (DM + acarbose)	722.33±76.64 ^{ab}
KE (non DM + ethanol extract of mahogany seeds)	650.00±74.35 ^b

^{a,ab,b} Different letters in the same columns show significantly different (P<0.05)

Table 2. MDA content and anti-oxidant profile Cu, Zn-SOD on rats liver tissue

Group	MDA level (µmol/gram)	Number of hepatocyte cells containing Cu, Zn-SOD anti-oxidant with different color intensity			
		(+++)	(++)	(+)	(-)
K- (Negative control)	0.81±0.17 ^b	50.2±5.56 ^a	132.2±41.54 ^a	151.7±16.91 ^a	63.7±20.83 ^c
K+ (DM)	1.19±0.26 ^a	18.5±3.78 ^c	101.7±7.67 ^a	103.2±13.76 ^b	138.7±11.47 ^a
EM (DM + ethanol extract of mahogany seeds)	1.10±0.04 ^{ab}	31.5±6.45 ^b	99.2±18.99 ^a	164.5±33.7 ^a	76±13.39 ^c
KO (DM + acarbose)	0.95±0.13 ^{ab}	25.5±3.10 ^{bc}	101.5±24.56 ^a	135.2±33.65 ^{ab}	100±8.75 ^b
KE (non DM + ethanol extract of mahogany seeds)	0.92±0.01 ^{ab}	29.2±5.37 ^b	106.7±13.42 ^a	172.5±28.45 ^a	57.7±14.75 ^c

^{a,ab,b,bc,c} Different letters in the same column show significantly different (P<0.05)

condition leads to the decrease in energy of the body that influence hunger and increase rat total ration consumption.

In the group of diabetic rats that given ethanol extract of mahogany seed (EM) and acarbose (KO) had no significant difference in total ration consumption (P>0.05) with K- group. This result also showed that rat in EM and KO groups (Figure 1) had similar body weight with rat in of K- group.

Similarly, the difference of ration intake of KE and K- groups was not significant (P>0.05), but the KE group had less weight gain, as seen in the K- group

(Figure 1). This is related to the presence of flavonoid compounds in mahogany seed extracts that have the potential to inhibit the activity of α-glucosidase (Wresdiyati *et al.*, 2011), in the process of carbohydrates breakdown and glucose absorption in the intestine (Wu *et al.*, 2012). This will inhibit the breakdown of carbohydrate compounds into glucose and delay the absorption of glucose by the small intestine (Adisakwattana and Chanathong, 2011), thus will affect the weight loss. Therefore, the use of ethanol mahogany seed extract in non-DM conditions has the

potential to be utilized as a natural medicine for weight loss.

The Hypoglycemic Effect of Ethanol Mahogany Seeds Extract

The changes in blood glucose levels of experimental rat for 28 days are presented in Figure 2. It showed that the blood glucose levels in the group of DM rats given ethanol extract of mahogany seeds (EM) and acarbose (KO) was decreased, while in the K+ group was increased. The similar finding has been reported by Hasan *et al.* (2011) that the ethanol extract of mahogany seed (*Swietenia mahagoni*) has hypoglycemic effect, so it can lower blood glucose levels in DM rat. The decrease of blood glucose level is possibly caused by the active compounds contained in the ethanol mahogany seed extract such as flavonoids and saponin that have hypoglycemic activity (Wresdiyati *et al.*, 2015). Flavonoid compounds also have potential as anti-oxidant by scavenging free radical compounds (Lukacinova *et al.*, 2008) and repairing damage to pancreatic tissue caused by free radical activity (Wresdiyati *et al.*, 2008; Suryani *et al.*, 2013). Because of this healing process, the β cells in Islets of Langerhans of pancreatic tissue will increase its insulin secretion. This causes glucose to be absorbed into cells and indirectly decreases the blood glucose levels in the body's circulation.

In the KO group also showed a decrease in blood glucose levels. Acarbose has been widely used as a drug for the treatment of diabetes because it acts as an α -glucosidase inhibitor (Sivakumar *et al.*, 2012). Inhibition of this enzyme causes inhibition of carbohydrate breakdown into glucose and delayed the absorption of glucose by the small intestine (Adisakwattana and Chanathong 2011; Wu *et al.*, 2012), so blood glucose levels of rats with DM will be restored in normal value.

MDA and Anti-oxidant Cu, Zn-SOD Levels in Liver tissue

The results of MDA level and anti-oxidant content of Cu, Zn-SOD analysis on rat liver tissue with DM were presented in Table 2. This table shows that MDA levels in the K+ group were higher than in the K- group ($P < 0.05$). This indicates that the condition of DM can cause the occurrence of oxidative stress conditions, because in a state of hyperglycemia in DM condition may stimulate increased production of free radicals (Tiwari *et al.*, 2013). This increased production can occur through various mechanisms, such as through the mechanism of glycation-oxidation of proteins and fats, increase production of advanced glycation end product (AGEs), activation of protein kinase C (PKC), polyol-sorbitol pathways, and glucose auto-oxydation (Giacco and Brownlee, 2010).

The EM, KO, and KE groups had MDA levels not significantly difference than in the K+ group ($P > 0.05$). In all these three groups (EM, KO, and KE), there was also damage to lipid peroxidation through free radical activity that is naturally generated by the body through the body's metabolic processes. Nevertheless, through

the administration of ethanol mahogany seed extract in the EM and KE groups, MDA levels in these group can be suppressed so as not to differ significantly compared with K-group ($P > 0.05$). These results are suspected to be related to the compounds contained in the ethanol mahogany seed extract, namely flavonoids (Wresdiyati *et al.*, 2015). Flavonoids are potential anti-oxidant by eliminating excess free radical compounds (Matos *et al.*, 2015), so that MDA production as lipid peroxidation products can be suppressed. MDA levels have been widely used as an indicator of the occurrence of oxidative damage, because MDA is the final product of lipid peroxidation produced by oxidation by free radicals (Tiwari *et al.*, 2013).

The results of qualitative analysis on the anti-oxidant content of Cu, Zn-SOD on liver tissue showed that the anti-oxidant content of Cu, Zn-SOD in liver tissue of K+ group was lower than in K-group. Anti-oxidant content in EM and KE group rats also appeared to be higher than in the K+ group (Figure 3).

Quantitative analysis of the anti-oxidant content of Cu, Zn-SOD on liver tissue was performed by counting the number of liver cell nuclei at various levels of Cu, Zn-SOD with the results are presented in Table 2. The results showed that the anti-oxidant content of Cu, Zn-SOD in the K+ group was lower than that of K-, EM, and KE. This is indicated by the number of liver cells which positively reacted (+++) was lower in the K+ group than in the K-, EM, and KE group ($P < 0.05$), and the number of liver cells that negatively reacted (-) was higher than that of K-, EM, KO, and KE groups ($P < 0.05$).

The anti-oxidant content of Cu, Zn-SOD in the rats group given the ethanol extract of mahogany seeds (EM and KE) was higher than in the K+ group. This was demonstrated by the number of liver cell reacted positivey (+++) in the mahogany seeds extract groups (EM and KE) was higher than in the K+ group ($P < 0.05$), while the number of cells that negatively reacted (-) was significantly ($P < 0.05$) lower in the EM and KE groups than in the K+ groups.

Anti-oxidant Cu, Zn-SOD is one of the endogenous anti-oxidant present in cells that act as a defense mechanism by inhibiting oxidation reactions of free radical activity by converting them into more stable compounds (Valko *et al.*, 2006). The high content of anti-oxidant Cu, Zn-SOD in groups of rats given ethanol extract of mahogany seed (EM and KE) probably due to by flavonoid compound contained in mahogany seed (Wresdiyati *et al.*, 2015). Flavonoids can act as anti-oxidant through various mechanisms, such as through scavenging or quenching free radical compounds by donating hydrogen atoms from hydroxyl groups when reacting with free radicals, metal ionizing, or by enzymatically inhibiting the formation of new free radical compounds (Lukacinova *et al.*, 2008; Han *et al.*, 2012). Flavonoids in mahogany seed extract will work synergistically with anti-oxidant Cu, endogenous Zn-SOD in neutralizing the activity of free radical compounds, so that the anti-oxidant content of Cu, Zn-SOD in rat liver tissue can be improved in DM condition.

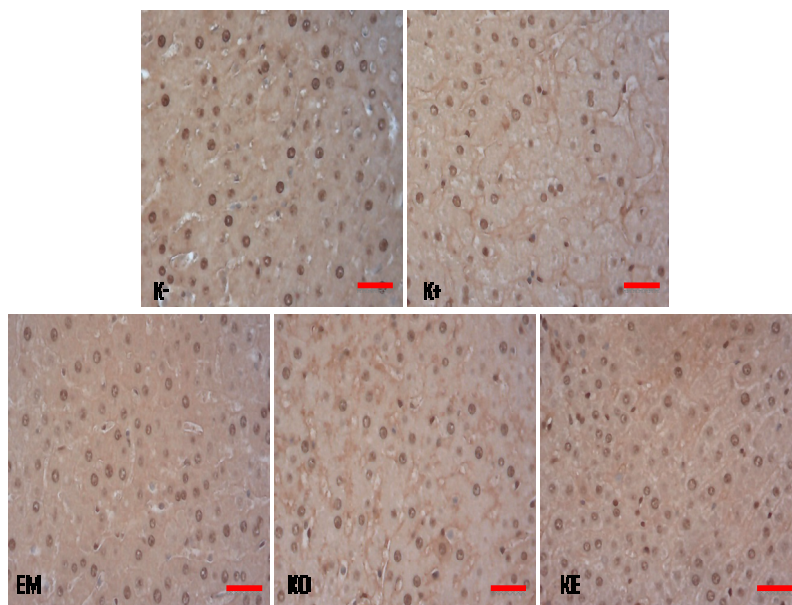


Figure 3. Photomicrograph of rat tissue treated with immunohistochemistry to Cu, Zn-SOD. K- = Non DM; K + = DM; EM = DM + extract of mahogany seed, KO = DM + acarbose; KE = Non DM + extract of mahogany seeds. The content of anti-oxidant Cu, Zn-SOD in liver of rats with DM given ethanol extract of mahogany seed (EM) showed higher than in group of DM (K +). 50 μ m Scale

CONCLUSION

This study concluded that the ethanol extract of mahogany seed has effect on lowering blood glucose levels and improve anti-oxidant status in liver tissue of diabetic rats.

ACKNOWLEDGEMENTS

Thanks to the Directorate General of Higher Education who funded this research through Excellent Research Higher Education on Primary Research for Section Year 2014 on behalf of Prof. Drh Tutik Wresdiyati, Ph.D, PAVet.

REFERENCES

- Adisakwattana, S. and B. Chanathong. 2011. α -glucosidase inhibitory activity and lipid-lowering mechanisms of *Moringa oleifera* leaf extract. **Eur. Rev. Med. Pharmacol. Sci.** 15:803-808.
- Chao, J., J. Liao, W. Peng, M. Lee, L. Pao, and H. Cheng. 2013. Antioxidant, analgesic, anti-inflammatory and hepatoprotective effect of the ethanol extract of *Mahonia oiwakensis* stem. **Int. J. Mol. Sci.** 14:2928-2945.
- Debasis, De., K. Chatterjee, K.M. Ali, T.K. Bera, and D. Ghosh. 2011. Antidiabetic potentiality of the aqueous methanolic extract of seed of *Swietenia mahagoni* [L.] Jacq. in streptozotocin-induced diabetic male albino rat: a correlative and antihyperlipidemic activities. **Evid. Based Complement Alternat. Med.** DOI: 10.1155/2011/892807.
- Gardner, D.G. and D. Shoback. 2007. **Greenspan's Basic and Clinical Endocrinology**. The McGraw-Hill Companies, USA.
- Giacco, F. and M. Brownlee. 2010. Oxidative stress and diabetic complications. **Circ. Res.** 107:1058-1070.
- Han, R., J. Zhang, and L.H. Skibsted. 2012. Review: Reaction dynamics of flavonoids and carotenoids as antioxidant. **Molecules.** 17:2140-2160.
- Hasan, M., M.I. Khan, and B.U. Umar. 2011. Effect of ethanolic extract of *Swietenia mahagoni* seeds on experimentally induced diabetes mellitus rats. **Faridpur. Med. Coll. J.** 6(2):70-73.
- IDF. International Diabetes Federation. 2013. IDF Diabetes Atlas. 6th ed. www.idf.org/diabetesatlas.
- Lukacinova, A., J. Mojzis, R. Benacka, J. Keller, T. Maguth, P. Kurila, L. Vasko, O. Racz, and F. Nistiar. 2008. Preventive effects of flavonoids on alloxan-induced diabetes mellitus in rats. **Acta Vet. Brno.** 77:175-182.
- Matos, M.J., F. Mura, S. Vasquez-Rodriguez, F. Borges, L. Santana, E. Uriarte, and C. Olea-Azar. 2015. Review: Study of coumarin-resveratrol hybrids as potent antioxidant compounds. **Molecules.** 20:3290-3308.
- Sivakumar, T., S. Sivakumar, L. Chaychi, and R.J. Comi. 2012. A review of the use of acarbose for the treatment of post-prandial syndrome (reactive hypoglycemia). **Endocrinol. Metabol. Syndrome.** DOI: 10.4172/2161-1017.S1-010.
- Suarsana, I.N., T. Wresdiyati, and A. Suprayogi A. 2013. Respon stres oksidatif dan pemberian isoflavon terhadap aktivitas enzim superoksida dismutase dan peroksidasi lipid pada hati tikus. **JITV.** 18(2):146-152.
- Suryani, N., T. Endang, and Aulanni'am. 2013. Pengaruh ekstrak metanol biji mahoni terhadap peningkatan kadar insulin, penurunan ekspresi TNF- α dan perbaikan jaringan pankreas tikus diabetes. **JKB.** 27(3):137-145.
- Tiwari, B.K., K.B. Pandey, A.B. Abidi, and S.I. Rizvi. 2013. Markers of oxidative stress during diabetes mellitus. **J. Biomarkers.** <http://dx.doi.org/10.1155/2013/378790>.
- Valko, M., C.J. Rhodes, J. Moncol, M. Izakovic, and M. Mazur. 2006. Free radicals, metals and antioxidant in oxidative stress-induced cancer. **Chem. Biol. Interact.** 160(1):1-40.
- Wresdiyati, T., M. Astawan, R. Kesenja, and P.A. Lestari. 2008. Pengaruh pemberian tepung buah pare (*Momordica charantia* L) pada sel beta dan SOD pankreas tikus diabetes melitus. **JBAI.** 6(5):193-200.
- Wresdiyati, T., A. Karmila, M. Astawan, and R. Karmila. 2014. Teripang pasir meningkatkan kandungan antioksidan superoksida dismutase pada pankreas tikus diabetes. **J. Vet.** 16(1):145-151.
- Wresdiyati, T., A. Winarto, S. Sa'diah, and V. Febriyani. 2015. Alpha-glucosidase inhibition and hypoglycemic activities of *Swietenia mahagoni* seed extract. **Hayati.** 22(2):73-78.
- Wu, C., J. Shen, P. He, Y. Chen, L. Li, L. Zhang, Y. Li, Y. Fu, R. Dai, W. Meng, and Y. Deng. 2012. The α -glucosidase inhibiting isoflavones isolated from Belamcanda chinesis leaf extract. **Rec. Nat. Prod.** 6(2):110-120.