

# HISTOMORPHOMETRY OF SEMINIFEROUS TUBULES OF LOCAL GOATS FIXED WITH DIFFERENT FIXATIVES

Fitriani<sup>1</sup>, Sri Wahyuni<sup>2</sup>, Muslim Akmal<sup>1</sup>, Dasrul<sup>3</sup>, and Cut Dahlia Iskandar<sup>1</sup>

<sup>1</sup>Histology Laboratorium, Faculty of Veterinary Medicine, Universitas Syiah Kuala, Banda Aceh, Indonesia

<sup>2</sup>Anatomy Laboratorium, Faculty of Veterinary Medicine, Universitas Syiah Kuala, Banda Aceh, Indonesia

<sup>3</sup>Reproduction Laboratorium, Faculty of Veterinary Medicine, Universitas Syiah Kuala, Banda Aceh, Indonesia

\*Corresponding author: [akmal\\_kh@unsyiah.ac.id](mailto:akmal_kh@unsyiah.ac.id)

## ABSTRACT

The aim of this study was to further understand the histomorphometry of seminiferous tubules from local goat testicles that were fixed with different fixatives. Nine testicles were randomly chosen, each fixed with 10% formalin, 10% neutral buffered formalin (NBF), and 4% paraformaldehyde (PFA) solutions. The sample was then proceeded to histology preparation and stained with haematoxylin eosin (HE). Observation of the tissue was carried out using microscope and the data obtained was analyzed statistically. The results showed that there was a significant difference ( $P > 0.05$ ) on each fixative in tubular diameter and membrane, and very significant difference ( $P < 0.01$ ) on germinal cell and staining absorbability. Duncan test result on tubular diameter showed that the use of PFA fixative was significantly different ( $P < 0.05$ ) compared to formalin fixative while the use of NBF fixative had no significant difference ( $P < 0.05$ ) compared to PFA fixative. In addition, the measurement of interstitial membrane of seminiferous tubules showed no significant difference ( $P < 0.05$ ) among three fixatives. To conclude, formalin, NBF, and PFA fixatives affect seminiferous tubules, basal membrane structure, and germinal cell appearance inside tubular lumen. Type of tissues and fixative must be considered in selecting the suitable fixative.

Key words: fixative, goat testicles, histomorphometry

## ABSTRAK

Penelitian ini bertujuan mengetahui histomorfometri tubulus seminiferus testis kambing lokal yang difiksasi dengan fiksatif berbeda. Dalam penelitian digunakan 9 testis yang diambil secara acak dan masing-masing difiksasi dalam fiksatif formalin 10%, neutral buffered formalin (NBF) 10%, dan paraformaldehid (PFA) 4%. Selanjutnya dilakukan pembuatan preparat histologi testis dengan metode parafin dan diwarnai dengan hematoksilin eosin (HE). Pengamatan jaringan tubulus seminiferus testis dilakukan secara mikroskopis dan hasil pengamatan dianalisis secara statistik. Hasil penelitian menunjukkan terdapat pengaruh yang signifikan ( $P > 0,05$ ) antara fiksatif dengan diameter tubulus dan membran tubulus, dan berpengaruh sangat signifikan ( $P < 0,01$ ) terhadap germinal sel dan daya serap warna. Hasil uji Duncan diameter tubulus menunjukkan bahwa penggunaan fiksatif PFA berbeda nyata ( $P < 0,05$ ) dengan fiksatif formalin, sedangkan penggunaan fiksatif NBF tidak berbeda nyata ( $P > 0,05$ ) dengan PFA, dan keadaan membran tubulus seminiferus pada fiksatif NBF berbeda nyata ( $P < 0,05$ ) dibanding fiksatif PFA. Berbeda halnya pada pengukuran ruang antar membran tubulus seminiferus yang tidak memperlihatkan perbedaan nyata ( $P > 0,05$ ) antara fiksasi formalin, NBF, dan PFA. Dapat disimpulkan bahwa penggunaan fiksatif formalin, NBF, dan PFA berpengaruh terhadap tubulus seminiferus, struktur membran basal, serta gambaran sel germinal di dalam lumen tubulus. Penggunaan fiksatif dipengaruhi oleh jenis jaringan yang akan difiksasi dan jenis fiksatif.

Kata kunci: bahan fiksatif, testis kambing, histomorfometri

## INTRODUCTION

Testis is a part of active male reproductive organ that produce the male germ cell called spermatozoa. Nearly 90% of testis consists of long small tubes called seminiferous tubules while the other 10% is connective tissues (Feradis, 2010). Testis main function is to produce male reproductive hormone and spermatozoa. The quality and quantity of spermatozoa produced in the seminiferous tubules are important in understanding fertility problems that determine the survival of living organisms and their genetic diversity (Sarwono, 2002). Assessment of the quality and quantity of spermatozoa produced by spermatogenesis in seminiferous tubules can be observed microscopically from testicular preparations using histo-technique.

Histo-technique tissue preparations for an organ requires fixated tissue utilizing fixative substance which aims to preserve and maintain tissue morphology in physiological conditions (Essen *et al.*, 2010; Hewitson *et al.*, 2010; Miranti, 2010). Generally, fixative materials are capable to shift the refractive index of cell parts (such as cell integrity and cytoplasm) so that the cells internal organelles can be easily observed under microscope (Hewitson *et al.*, 2010; Ahmed and Mohammed, 2011;

Zanini *et al.*, 2012). In addition, according to Suntoro (1983), fixative materials can cause tissues to easily absorb staining and be able to maintain the shape and structure of the cells or tissues (Gatta *et al.*, 2012).

Researches on microscopic examination of testis sample are plenty, but according to Mohammadzadeh *et al.* (2013), informations about testicular histomorphometry are still few. Based on the observation of testicular studies at the Histology Laboratory, Faculty of Veterinary Medicine, Universitas Syiah Kuala, testicular histology results was non-optimal, especially in the non-uniformity of seminiferous tubules structure. Others reported shrinkage of seminiferous tubule walls with separation of spermatogenic cells in the tubule. The difference in the histological structure of testicular tissue compared to its original structure is thought to be related to the fixation process of testicular tissue and the type of fixative material used.

The inaccuracy of fixation process will certainly reduce the quality of the testicular tissue preparations, for both research and diagnosis of fertility disorders in male animals. This is supported by Jusuf (2012) who stated that the quality of histological preparations is necessary for researchers to provide precise and accurate

information, especially in diagnostics (Moelans *et al.*, 2011; Gatta *et al.*, 2012).

Hewitson *et al.* (2010) stated that each fixative material has its advantages and disadvantages in penetrating testicular tissue which contains a lot of tunica albuginea. In addition, the selection of fixative materials must also be appropriate to the type of staining used. Selection of staining type in the same animal species can also provide a different picture and significantly influence the result of microscopic observations (Suntoro, 1983; Hess and Moore, 1993; Kiernan, 2000). According to Hewitson *et al.* (2010), formalin, formaldehyde, and paraformaldehyde fixative materials have different tissues penetration characteristics.

Studies on the use of formaldehyde fixation, neutral buffered formalin (NBF), and paraformaldehyde (PFA) in paraffin embedding on testicular tissue of local goat histotechnically has not been reported to date. Based on these problems, it is necessary to conduct studies related to the fixation process of local goat testicular tissue using several fixative materials to produce a quality microscopic image. The choice of fixative material is based on the routine practice in the Histology Laboratory of the Faculty of Veterinary Medicine, Universitas Syiah Kuala, those are 10% formalin, 10% NBF, and 4% PFA.

## MATERIALS AND METHODS

### Testicular Tissues

Samples used were testicular tissues of local male goats aged 1-1.5 years. Age selection was based on Sarwono (2002) who stated that male goats reach sexual maturity approximately at 5-15 months old. Goats were obtained from *qurban* animal slaughter. Nine testes were obtained (left or right testicles was not differentiated) from local male goats.

### Testicular Tissues Fixation

Testicular tissues were immersed in 10% formalin, 10% neutral buffered formalin (NBF), and 4% paraformaldehyde for fixation. Prior to immersion, testicular albugenia was incised horizontally and vertically then punctured at 20 random spots using 20 ml cannula needles (modified Hess method). During the first 6 hours of the immersion process, the testicular organs were cut into two parts and the next 6 hours were cut into four parts. Immersion was continued according to the treatment. After fixation, testicular tissues were transferred into 70% alcohol as a stopping point until the next step was performed.

### Tissues Processing

The testicular tissue in 70% alcohol was cut to a size of 0.5x0.5 cm<sup>2</sup> and inserted into tissue cassette, then dehydrated in a multilevel alcohol concentration (80%, 90%, 95%, and absolute) for 2 hours each (Wahyuni *et al.*, 2012; Kiernan, 1990), followed by a clearing process with xylol for 30 minutes with three repetitions. We performed paraffin infiltration inside an oven with temperature of 58-60° C for three times repetitions (Muntiha, 2001; Jusuf, 2009). Tissues were then embedded in liquid paraffin and

then made into paraffin blocks. Afterwards, the tissue block was sectioned to a thickness of about 3 µm. Slides of testicular tissues were then stained using hematoxylin-eosin (HE) (Kiernan, 2000).

### Haematoxylin-Eosin (HE) Staining

HE stains refers to Kiernan (1990) method. The staining process began with deparaffinization using xylol solution in 3 repetitions of 2 minutes each and continued with tissue rehydration with multilevel alcohol (absolute, 96%, 90%, 80%) for 2 minutes per concentration. Samples were rinsed with running water for 5 minutes and stained with hematoxylin for 1 minute (controlled under a microscope) and rinsed again using running water, and then stained with eosin for 5 minutes (controlled under a microscope) and followed by dehydration with alcohol. Xylol was used for purification and ended with tissue mounting using Entellan® adhesive. Tissues were then observed under microscope and photographed using an Olympus CX41 microscope with a DP12 digital photo instrument.

### Histomorphometry of Testicular Tissues

Qualitative scoring observation was based on Moelans (2011) in nominal forms 1, 2, 3, and 4, for quantification. The three items observed were tubular membrane state (score 1= very contracted, score 2= contracted, score 3= slightly contracted, and score 4= not contracted), germ cells structure (score 1= irregular, score 2= slightly organized, score 3= organized, and score 4= very organized) and staining absorption (score 1= no contrast, score 2= slight contrast, score 3= contrast, and score 4= stark contrast). Criteria of observations on seminiferous tubules are intact lumen and round tubules.

### Diameter of Seminiferous Tubules (DT)

Parameters values were measured by creating one point on histological preparations, then magnified 100 times in ten diameters of seminiferous tubules adjacent to it. Mean diameter of seminiferous tubules was obtained by measuring the longest and shortest diameter of tubules divided by two. Diameter was calculated using ToupView program with microscope equipped with HDMI camera of SIGMA full HD brand.

### Intermembrane Space (RAM)

Biocular microscope with 10 times magnification was used to measure intermembrane space on 10 cross sections of intact tubules. The area of inter membrane space was measured by 4 different latitudes taken at the space between the membrane and germinal cells in the seminiferous tubules.

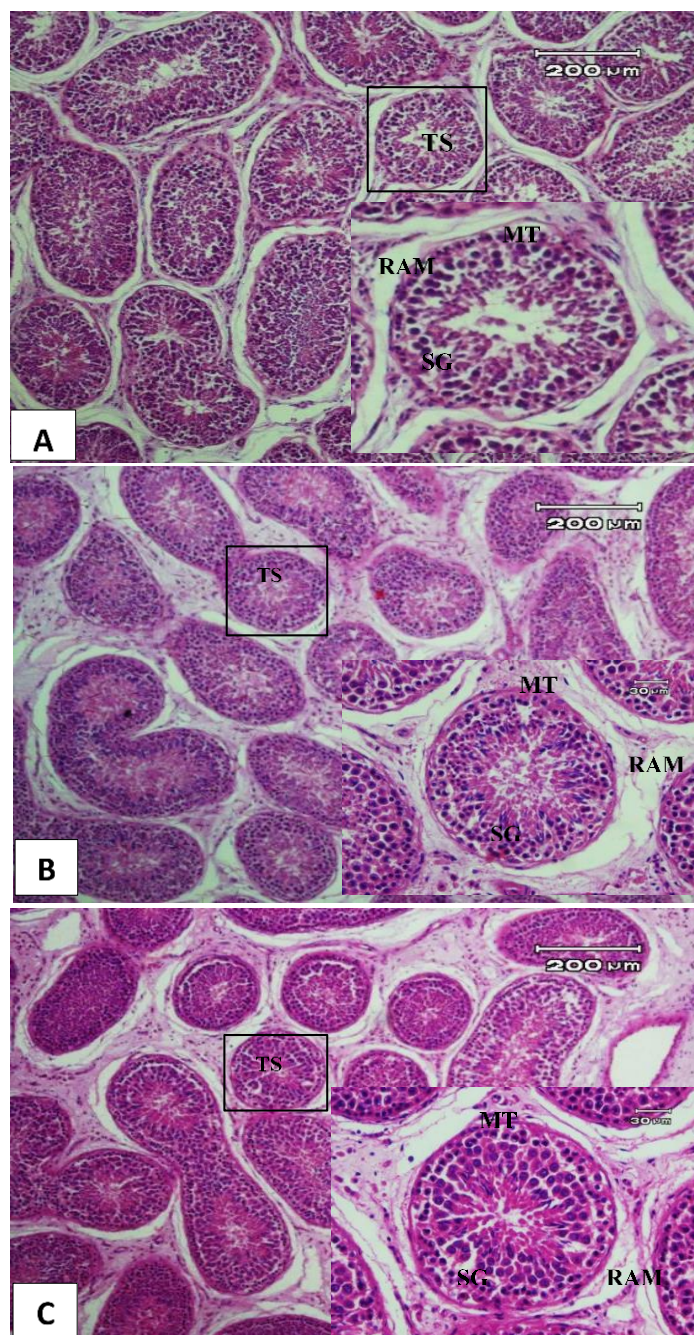
### Data Analysis

Qualitative data of histological structure on local goat testes were converted to number by scoring and measuring. Data was analyzed using analysis of variance (ANOVA), and to determine the significance of different fixative materials on testicular histology Duncan test was used.

**Table 1.** Average  $\pm$  SD of histomorphometry figure of local goat testis histology fixated with different fixatives

Parameters	Formalin	NBF	PFA
Tubular membrane (MT)	2.37 $\pm$ 0.80 <sup>ab</sup>	2.22 $\pm$ 0.38 <sup>a</sup>	2.98 $\pm$ 0.59 <sup>b</sup>
Germinal cell (SG)	3.06 $\pm$ 0.44 <sup>a</sup>	3.47 $\pm$ 0.37 <sup>b</sup>	3.68 $\pm$ 0.20 <sup>b</sup>
Color absorbance (DSW)	3.08 $\pm$ 0.23 <sup>a</sup>	3.76 $\pm$ 0.36 <sup>b</sup>	3.66 $\pm$ 0.27 <sup>b</sup>
Tubular diameter (DT)	236.44 $\pm$ 22.02 <sup>a</sup>	224.30 $\pm$ 43.63 <sup>ab</sup>	212.76 $\pm$ 29.18 <sup>b</sup>
Intermembrane space (RAM)	12.50 $\pm$ 4.25 <sup>a</sup>	9.19 $\pm$ 3.57 <sup>a</sup>	9.60 $\pm$ 3.17 <sup>a</sup>

<sup>a, b, ab</sup>Different superscripts within the same row indicate significant difference ( $P < 0.05$ )



**Figure 1.** Microscopic image of local goat testis. A= Formalin fixative, B= NBF fixative, and C= PFA fixative. TS= Seminiferous tubules, MT= Tubular membrane, PS= Germinal cells, RAM= Intermembrane space. H&E 100x and 400x

## RESULTS AND DISCUSSION

### Histomorphometry of Testicular Tissues

Histology of testicular tissues using 10% formalin fixation, 10% neutral formalin (NBF), and 4% paraformaldehyde (PFA) showed different microscopic

results (Figure 1) and statistically shown in Table 1. Microscopically, the seminiferous tubules were intact in all three fixative materials and can be diagnosed properly. Microscopic differences in tubular membranes (MT), germinal cells (SG), intermembrane spaces (RAM), and staining absorption (DSW) were observed.

The use of 10% formalin fixative showed contracted of MT, irregular SG, and looser RAM compared to NBF and PFA. Statistically, the effect of fixative on tubule diameter (DT), MT, SG, and DSW showed a significant difference ( $P < 0.05$ ). This means that there was a significant influence between different fixatives on the measured parameters.

The results of ANOVA with Duncan test on DT showed that the use of formalin fixative have significant difference ( $P < 0.05$ ) compared to PFA fixative and NBF fixative, whereas NBF fixative did not show significant difference ( $P > 0.05$ ) compared to formalin fixative and PFA. MT with formalin fixative showed significant difference ( $P < 0.05$ ) compared to PFA fixative, while NBF fixative did not show significant difference compared to formalin. SG and DSW in formalin fixative showed significant difference ( $P < 0.05$ ) compared to NBF and PFA fixative, while NBF and PFA fixative did not show any significant difference ( $P > 0.05$ ). Additionally, the measurement of inter-membranes space of seminiferous tubules showed no significant difference ( $P > 0.05$ ) between the use of formalin, NBF, and PFA fixatives.

Formalin fixatives are still widely used, in addition of its affordability, formalin can be used after a long time. However, in this study, statistically formalin fixation did not give any significant effect ( $P > 0.05$ ) compare to NBF and PFA. Similarly, there is also no difference in microscopic morphologic of goat testis (Figure 1) in fixation of NBF and PFA. As expressed by Kap *et al.* (2011) and Jusuf (2012), formalin fixation has greater tissue penetration capability and do not cause much tissues contraction. This may be caused by fixative's capability to diffuse well in testicular tissues (Ahmed and Mohammad, 2011; Trianto *et al.*, 2015).

In histomorphometry, each measured parameter of seminiferous tubules was influenced by its fixative material. The results showed that fixative substantially affected tubular diameter and membrane ( $P < 0.05$ ), especially when using PFA fixative, however, for SG and DSW, the usage of NBF fixative had similar effect. This is in accordance to Hess and Moore (1993) who stated that the use of PFA is equal to NBF. However, PFA is still superior for fixation of local goat testis because of its ability in minimizing damage to tubular membrane.

The use of fixative, especially NBF and PFA in paraffin embedding can maintain seminiferous tubule tissue and do not cause lumen reduction. However, the use of NBF fixation can cause cytoplasmic contraction, the formation of intercellular vacuoles, and damage to the seminiferous epithelium. However, this can be minimized by combining NBF and Bouin (Hess and Moore, 1993). Moelans *et al.* (2011) argued that NBF can maintain good histological morphology, asides from being inexpensive and can be stored for a long time, NBF can provide good and reliable histological staining for immunohistochemistry. This is supported by several researchers such as Abba *et al.* (2016) who used NBF fixative to see aspermatogenesis and hypospematogenesis in goat testis by immunehisto-

chemistry and Ferasyi *et al.* (2014) who observed the histopathology of local goat seminiferous tubules.

The use of the 4% PFA fixative has also been mentioned by Noviana *et al.* (2000) in observation of morphology and histomorphometry of local goat testicles with good histological features. Wahyuni *et al.* (2012) also used 4% PPF fixative to view histology and histomorphometry of testicles and epididymis of *muncak* (*Muntiacus muntjak muntjak*), and Faucette *et al.* (2014) in etiopathology and gene expression in goat testes. Although formaldehyde is an effective fixation for antigen preservation (Wang *et al.*, 2016), there are drawbacks such as artefacts between seminiferous tubules and germinal cell (Figure 1).

The use of various fixative materials showed different result on each parameter of testicular histology of local goat. However, the suitable fixative material for local goat testicular tissue is 4% PFA since it had better effect in maintaining the integrity of the seminiferous tubules and its adjacent tissues.

## CONCLUSION

The use of formalin, NBF, and PFA fixative affect seminiferous tubules, basement membrane structure, and cellular appearance in the tubular lumen. Fixative usage is influenced by the type of tissue and fixative.

## REFERENCES

- Abba, Y. and I.O. Igbokwe. 2016. Postmortem diagnosis of aspermatogenesis and hypospermatogenesis in the Nigerian Sahel goat by testicular and epididymal sperm cytometry. **J. Small Rum. Res.** 144:35-40.
- Ahmed, H.G. and A.I.I. Mohammed. 2011. A comparison study of histochemical staining of various tissue after Carnoy's versus after formalin fixation. **J. Cancer Sci. Ther.** 3(4):84-87.
- Essen, H.F.V., M.A.M. Verdaasdonk, S.M. Elshof, R.A. de Weger, and P.J. van Diest. 2010. Alcohol based tissue fixation as an alternative for formaldehyde: Influence on immunohistochemistry. **J. Clin. Pathol.** 63: 1090-1094.
- Faucette, A.N., V.A. Maher, M.A. Gutierrez, J.M. Jucker, D.C. Yates, T.H. Welsh Jr., M. Amstalden, G.R. Newton, L.C. Nuti, D.W. Forrest, and N.H. Ing. 2014. Temporal changes in histomorphology and gene expression in goat testes during postnatal development. **J. Anim. Sci.** 92:4440-4448.
- Feradis. 2010. **Reproduksi Ternak**. Alfabeta, Bandung.
- Ferasyi, T.R., H. Budiman, M. Akmal, J. Melia, Razali, A. Novita, R.A. Barus, and A. Suprayogi. 2014. Histological findings in the seminiferous tubule of male local Kacang goats after supplementation. **J. Ked. Hewan.** 8(1):57-60.
- Gatta, L.B., M. Cadei, P. Balzarini, S. Castriciano, R. Paroni, A. Verzeletti, V. Cortellini, F.D. Ferrari, and P. Grigolato. 2012. Application of the alternative fixatives to formalin in diagnostic pathology. **EJH.** 56(e12):63-70.
- Hess, R.A. and B.J. Moore. 1993. Histological Methods for Evaluation of the Testis. In **Male Reproductive Toxicology**. Chapin, R.E. and J.J. Heindel. Volume 3 Part A. Academic Press, Inc., California.
- Hewitson, T.D., B. Wigg, and G.J. Becker. 2010. Tissue Preparation for Histochemistry: Fixation, Embedding, and Antigen Retrieval for Light Microscopy. In **Histology Protocols**. Hewitson, T.D. and I.A. Darby, Jr. (Eds.). Chapter 1. Human Press, Australia.
- Jusuf, A.A. 2009. **Histoteknik Dasar**. Bagian Histologi Fakultas Kedokteran. Universitas Indonesia, Jakarta.
- Jusuf, A.A. 2012. **Teknik Histologi I**. Bagian Histologi Fakultas Kedokteran Universitas Indonesia, Jakarta.
- Kap, M., F. Smedts, W. Oosterhuis, R. Winther, N. Christensen, B. Reischauer, C. Viertler, D. Groelz, K.F. Becker, K. Zatloukal, R. Langer, J. Slotta-Huspenina, K. Bodo, B. de Jong, U. Oelmuller,

- and P. Riegman. 2011. Histological assesment of paxgene tissue fixation and stabilization reagent. **Plos One**. 6(11):1-10.
- Kiernan, J.A. 1990. Histological and Histochemical Methods: Theory and Practice. 2<sup>nd</sup> ed. Pergamon Pr., England.
- Kiernan, J.A. 2000. **Formaldehyde, Formalin, Paraformaldehyde and Glutaraldehyde: What They Are and What They Do. Microscopy Today**. Cambridge.
- Miranti, I.P. 2010. Pengolahan jaringan untuk penelitian hewan coba. **Media Medika Muda**. 4:1-4.
- Mohammadzadeh, S., M. Abasi, M. Tavafi, and A. Kiani. 2013. Reproductive efficiency of indigenous Irianian goat (*Capra hircus*). **ARI**. 10(2):1723-1729.
- Moelans, C.B., N.T. Hoeve, J.W.V. Ginkel, F.J.T. Kate, and P.J.V. Diest. 2011. Formaldehyde substitute fixatives. Analisis of macroscopy, morphologic analysis, and imunohistochemical analysis. **Am. J. Clin. Pathol**. 136:548-556.
- Muntiha, M. 2001. Teknik Pembuatan Preparat dengan Pewarnaan Hematoksilin dan Eosin. Balai Penelitian Veteriner Bogor. Bogor
- Noviana, C., A. Boediono, and T. Wresdiyati. 2000. Morphology and histomorphometry of testis and epididymis of kacang Goat (*Capra Sp.*) and local sheep (*Ovis sp.*). **Med. Vet**. 7(2):12-16.
- Sarwono, B. 2002. **Beternak Kambing Unggul**. Penerbit Penebar Swadaya, Jakarta.
- Suntoro, H. 1983. **Metode Pewarnaan: Histologi dan Histokimia**. Bagian Anatomi dan Mikrotehnik Hewan Fakultas Biologi UGM. Bhiratar Karya Aksara, Jakarta.
- Trianto, H.F., M.I. Ilmiawan, S.E. Pratiwi, and Asuprianto. 2015. Perbandingan kualitas pewarnaan histologi jaringan testis dan hepar menggunakan fiksasi formalin metode intravital dan konvensional: Sebuah studi eksperimental pada tikus. **J. Mahasiswa PSPD**. 3(1):1-13.
- Wahyuni S., S. Agungpriyono, M. Agil, and T.L. Yusuf. 2012. Histologi dan histomorfometri testis dan epididimis Muncak (*Muntiacus muntjak muntjak*) pada periode ranggah keras. **J. Ked. Hewan** 13(3):211-219.
- Wang, H., L.L. Yang, Y.L. Ji, Y.H. Chen, J. Hu, C. Zhang, J. Zhang, and D.X. Xu. 2016. Different fixative methods influence histological morphology and TUNEL staining in mouse testes. **J. Reprotox**. 60:53-61.
- Zanini, C., E. Gerbaudo, E. Ercole, A. Vendramin, and M. Forni. 2012. Evaluation of two commercial and three home-made fixatives for the substitution of formalin: A formaldehyde-free laboratory is possible. Environmental Health. **Bio. Med. Central**. 11(59):1-14.