

# THE EFFECTIVENESS OF THE COMBINATIONS OF CALCITRIOL AND ETHYNIL ETHYL ESTRADIOL TO DECREASE OSTEOPOROSIS AND ENDOMETRIAL CANCER RISKS IN OVARIECTOMIZED RATS

Hartiningsih<sup>1\*</sup> and Devita Anggraeni<sup>1</sup>

<sup>1</sup>Department of Surgery and Radiology Faculty of Veterinary, Gadjah Mada University, Yogyakarta, Indonesia

\*Corresponding author: [hartiningsih56@yahoo.com](mailto:hartiningsih56@yahoo.com)

## ABSTRACT

The objective of this research was to study the effectiveness of calcitriol and ethynil ethyl estradiol combinations to decrease osteoporosis and endometrial cancer risks in ovariectomized Wistar rats. Twenty five 8-week old female Wistar rats were randomly divided into five groups (normal controlled rats/NK, ovariectomized rats/OVK, ovariectomized rats + calcitriol supplementation/OVD, ovariectomized rats + ethynil ethyl estradiol supplementation/OVE, and ovariectomized rats + calcitriol + ethynil ethyl estradiol supplementation/OVDE). At the end of the study, all rats were weighed and euthanized with 10% ketamine and 2% xylazine. Uterus and left femur were taken and fixed in 10% formaldehyde solution for histopathological examination using hematoxylin and eosin stain. Uterus was weighed before the fixation. The results showed that the percentage of uterus weight in OVK was significantly decreased compared to NK. Meanwhile, the percentage of uterus weight in OVDE was significantly increased compared to OVK. Histopathological features of the uterus in OVK were atrophy, reduction of myometrial and endometrial layers thickness, and formation of cuboidal epithelium in the endometrial lumen. However, the thickness of myometrial and endometrial layers in OVDE were increased, and its endometrial lumen was lined with metaplastic and hyperplastic squamous cell. Histopathological features of distal femur epiphysis in OVK rats showed fewer trabecular spiculus and more adipocyte in the bone marrow compared to NK. However, OVDE had more trabecular bone spiculus and less adipocyte in the bone marrow compared to OVK. In conclusion, the combination of calcitriol and ethynil ethyl estradiol supplementation could reduce osteoporosis, but increased the endometrial cancer risk in ovariectomized Wistar rats.

Key words: calcitriol, endometrium, estradiol, osteoporosis, ovariectomized

## ABSTRAK

Penelitian ini dilakukan untuk mengetahui efektivitas kombinasi kalsitriol dan etinil etil estradiol dalam menurunkan risiko osteoporosis dan kanker endometrium tikus ovariektomi. Dua puluh lima tikus Wistar betina umur delapan minggu, dibagi ke dalam lima kelompok (kontrol normal/NK, kontrol ovariektomi/OVK, ovariektomi+kalsitriol/OVD, ovariektomi+etinil etil estradiol/OVE, dan ovariektomi+ kombinasi kalsitriol dan etinil etil estradiol/OVDE) yang diberi perlakuan selama delapan minggu. Pada akhir perlakuan, tikus dieutanasia menggunakan campuran ketamin 10% dengan xylaxine 2%. Uterus dan femur kiri diambil, uterus ditimbang, kemudian uterus dan tulang femur kiri difiksasi dalam formalin 10% untuk pemeriksaan histopatologis. Hasil analisis menunjukkan prosentase berat uterus tikus OVK lebih rendah signifikan dibanding tikus NK, sedangkan prosentase berat uterus tikus OVDE lebih tinggi signifikan dibanding tikus OVK. Gambaran histopatologis uterus tikus OVK terlihat atrofi, penurunan tebal lapisan endometrium dan miometrium, sel epitel lumen endometrium berbentuk kuboid, sedangkan tikus ovariektomi OVDE terlihat penebalan lapisan endometrium dan miometrium, sebagian lumen endometrium dilapisi sel epitel squamus metaplasia dan sel epitel squamus hiperplasia. Gambaran histopatologis epifisis tulang femur distalis pada tikus OVK terlihat lebih sedikit spikulum trabekula dan dominasi jaringan adiposit dalam rongga sumsum tulang dibanding tikus NK, sedangkan pada tikus OVDE terlihat mempunyai lebih banyak spikulum trabekula dan lebih sedikit adiposit dalam rongga sumsum tulang dibanding tikus OVK. Dari hasil penelitian dapat disimpulkan bahwa kombinasi kalsitriol dengan etinil etil estradiol pada tikus ovariektomi efektif menurunkan risiko osteoporosis namun meningkatkan risiko kanker endometrium.

Kata kunci: kalsitriol, endometrium, estradiol, osteoporosis, ovariektomi

## INTRODUCTION

Low level of estrogen causes osteoporosis either in animals or humans. There is a relationship between low circulating estrogen concentrations in menopausal period with osteoporotic fracture in post-menopausal women (Doherty *et al.*, 2001). Estrogen plays a role in the suppression of bone remodeling (Manolagas, 2002) by suppressing bone resorption, decreasing osteoclast production (Hughes *et al.*, 1996; Teitelbaum, 2000), and inducing bone formation by increasing osteoblast production, despite the variation depends on its animal model (Qu *et al.*, 1998). Estrogen also activates the kidney to convert vitamin D into its active form (Notelovitz, 1997). The decreased estrogen level causes the reduction of 1,25-dihydroxyvitamin D<sub>3</sub> (Notelovitz, 1997). Hormone replacement therapy using estradiol can inhibit bone resorption, increase bone density, and reduce the risk of bone fracture (Rossouw *et al.*, 2002;

Anderson *et al.*, 2004). However, it may cause stroke, pulmonary embolism, breast cancer, and endometrial cancer (Rodan and Martin, 2000; Rossouw *et al.*, 2002). Estradiol supplementation causes hypertrophy and hyperplasia of all uterus structure (Gallo *et al.*, 2008; Pan *et al.*, 2010). According to Amant *et al.* (2005) and Kong *et al.* (1997), endometrial hyperplasia was the precursor of endometrial cancer. Several study showed that 1,25-dihydroxyvitamin D<sub>3</sub> increased bone formation (Hendy *et al.*, 2006) and decreased the risk of endometrial cancer (Salazar-Martinez *et al.*, 2005; Mohr *et al.*, 2007). Supplementation of 8 ng calcitriol for six weeks in ovariectomized rats reduced the estrogen concentration and cause osteoporosis, which was marked by reduced trabecular bone spiculus, increased bone marrow cavity, and domination of adipocyte tissue of the distal femur (Hartiningsih *et al.*, 2012). The effect of combined calcitriol and ethynil ethyl estradiol in reducing osteoporosis and its safety for uterus in ovariectomized

rats had never been reported. The effectiveness of combined calcitriol and ethynil ethyl estradiol was analyzed using histopathological examination of the distal femur and the uterus. Combined estrogen and ethynil ethyl estradiol are expected to reduce osteoporosis, which is marked by increased trabecular bone spiculum and reduced adipocyte tissue in bone marrow cavity. They are also expected to be safe for the uterus, with no effect of inducing hypertrophy and hyperplasia on the uterus structure.

## MATERIALS AND METHOD

In this research, twenty five female Wistar rats with 8 weeks of age were used and placed in individual cages with 25° C room temperature. The rats were given standard feeding which contained 20% protein, 0.6% calcium, and 0.4% phosphate. The standard feeding, for each g/100 g, consist of 78% corn, 20% anchovy, 0.3% CaCO<sub>3</sub>, 0.7% molase, 1.0% mineral-vitamin, and sufficient distilled water.

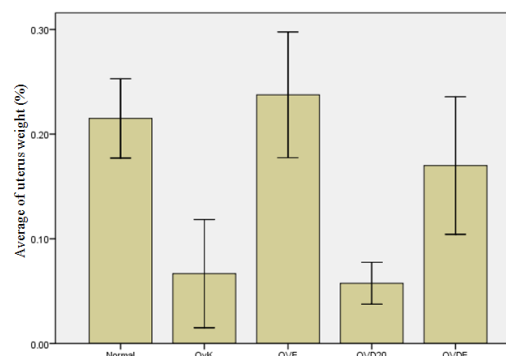
The rats were divided into five groups (normal control/NK, ovariectomized control/OVK, ovariectomized + 20 ng/day/rat oral calcitriol/OVD, ovariectomized + 25 µg/day/rat oral ethynil ethyl estradiol/OVE, and ovariectomized + combined 20 ng/day/rat oral calcitriol and 25 µg/day/rat oral ethynil ethyl estradiol/OVDE). One week after environmental adaptation, ovariectomy was performed using incision in the caudal midline. Combination of 10% ketamine (50 mg/kg) and 2% xylazine (5 mg/kg) was injected intramuscularly for anesthesia. The same procedure was performed in the controlled Wistar rats without ovariectomy. One week after surgery, all Wistar rats were started to be given the treatment for eight weeks.

At the end of treatment period, rats were weighed and euthanized using combination of ketamine 10% and xylazine 2% intramuscularly. Left femoral bone was taken and fixated in formalin 10% for histopathological examination. Before the fixation in formalin 10%, the uterus was weighed and the result was analyzed using one way Anova and Duncan's test, while the result of histopathological examination was analyzed descriptively.

## RESULTS AND DISCUSSION

Ovariectomy caused a significant decrease in uterus weight percentage of OVK rats (0.068±0.02%) compared to that of the NK rats (0.22±0.02%). Supplementation of ethynil ethyl estradiol caused uterus weight percentage of OVE rats (0.24±0.04%) increased 3.5 folds more than that of OVK rats (0.068±0.02%). Supplementation of combined calcitriol and ethynil ethyl estradiol caused uterus weight percentage of OVDE rats (0.17±0.03%) to increased 2.5 folds greater than OVK rats. Supplementation of calcitriol caused uterus weight percentage of OVD rats (0.058±0.01%) decreased 0.85 fold than OVK rats (Figure 1). Saruhan *et al.* (2006) reported that the ovariectomy reduced the uterus

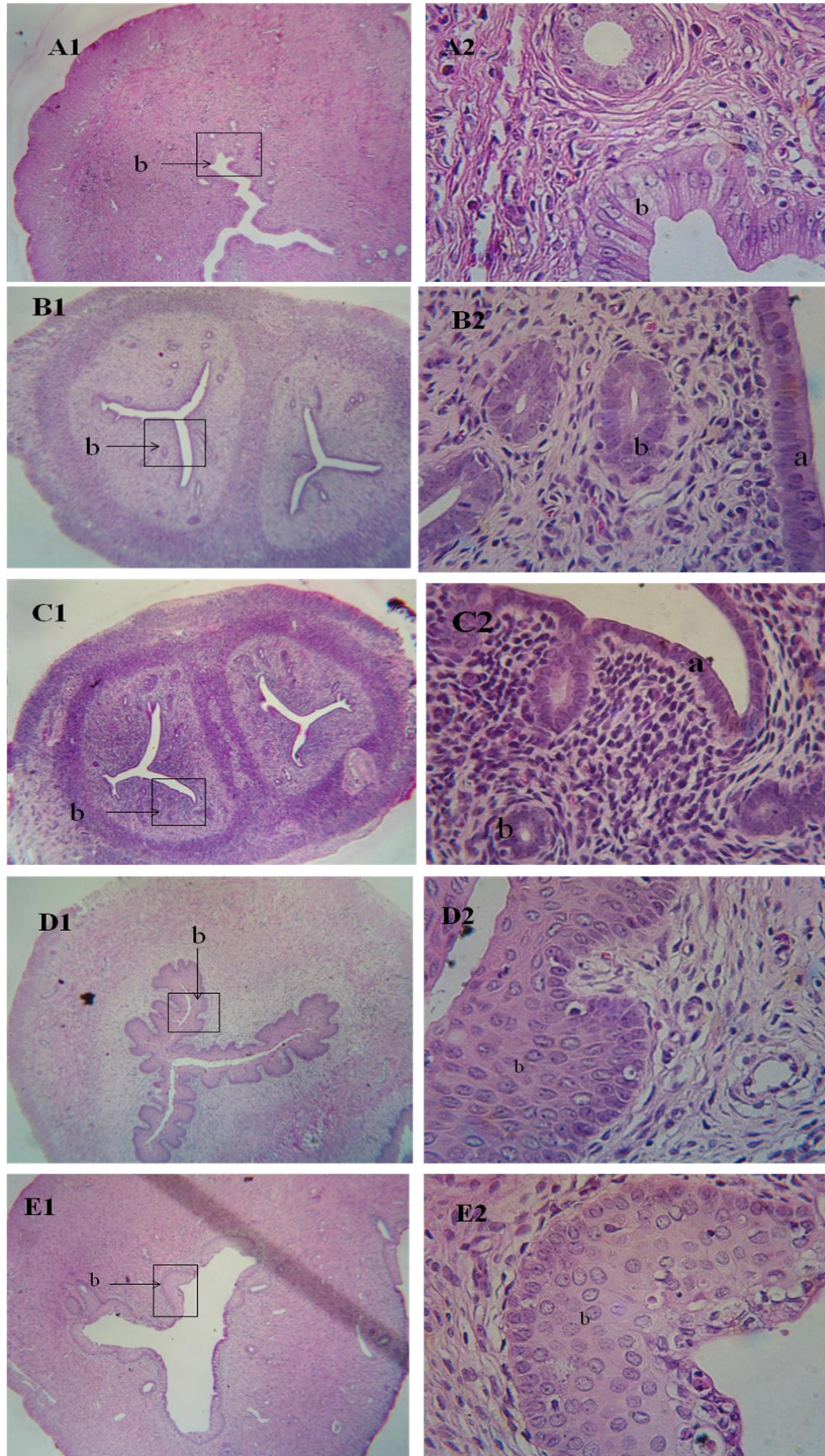
weight. Reduction of uterus weight percentage in OVK rats was reciprocal to the study by Li *et al.* (2003), Pan *et al.* (2010), and Gallo *et al.* (2008), which reported that ovariectomy in rats reduced serum estradiol concentration and uterus weight.



**Figure 1.** Percentage of uterus weight (g/body weight) after 8 weeks of treatment

The higher percentage of uterus weight of OVE rats compared to OVK rats, and OVDE rats compared to OVD rats were also consistent to the study done by Li *et al.* (2003), Pan *et al.* (2010), and Gallo *et al.* (2008), which reported that ethynil ethyl estradiol in ovariectomized rats increased serum estradiol concentration and increased uterus weight. Uterus weight percentage of OVD rats, which was less than OVK rats, in spite of its non-significant result, was caused by the lower estrogen concentration in OVD rats compared to OVK rats. Hartiningsih *et al.* (2006) reported that supplementation of calcitriol for 3 months after ovariectomy reduced estrogen. OVDE rats had a lower uterus weight percentage compared to OVE rats, despite its non-significant result, and was caused by its lower estrogen concentration compared to OVE rats.

Histopathological figure of uterus in NK rats showed columnar endometrial epithelium, which was reciprocal to Saruhan *et al.* (2006). Histopathological figure of uterus in OVK and OVD rats showed atrophy, reduction in diameter, reduction in endometrial-myometrial layer, and cuboidal epithelium of the uterus (Figure 2). Several researches showed atrophic and cuboidal epithelium of uterus, two months after ovariectomy (Sonmez *et al.*, 2000; Saruhan *et al.*, 2006; Pan *et al.*, 2010). Histopathological figure of uterus in OVE and OVDE rats uterus showed an increase of luminal diameter and endometrial-myometrial layer. However, in OVE rats, endometrial lumen was lined by complex and hyperplastic squamous epithelium, while in OVDE rats, the uterus was lined by metaplastic, complex, and hyperplastic squamous epithelium. According to Pan *et al.* (2010) and Gallo *et al.* (2008), the supplementation of estradiol caused epithelial hyperplasia of the uterus, and hypertrophy in all of its structure. Amant *et al.* (2005) and Kong *et al.* (1997) reported the hyperplasia of endometrium was a precursor of type I endometrial cancer. Eighty percent of all endometrial carcinoma or type I endometrial can-



**Figure 2.** Histopathological figure of normal rat uterus. A1 and A2= Lumen was lined by columnar endometrial epithelium (b), B1 and B2= OVK rat uterus showed reduced uterus diameter, cuboidal epithelium (a), and loose stromal, C1 and C2= OVD rat uterus showed reduced uterus diameter, endometrial cuboidal epithelium (a), and loose stromal, D1 and D2= OVDE rat uterus, E1 and E2= Showed endometrial epithelium hyperplasia (b) (HE 100x)

cer was reported to be caused by hormone replacement therapy or estrogen. Histopathological figure of uterus in OVE and OVDE rats showed an increased risk of endometrial cancer.

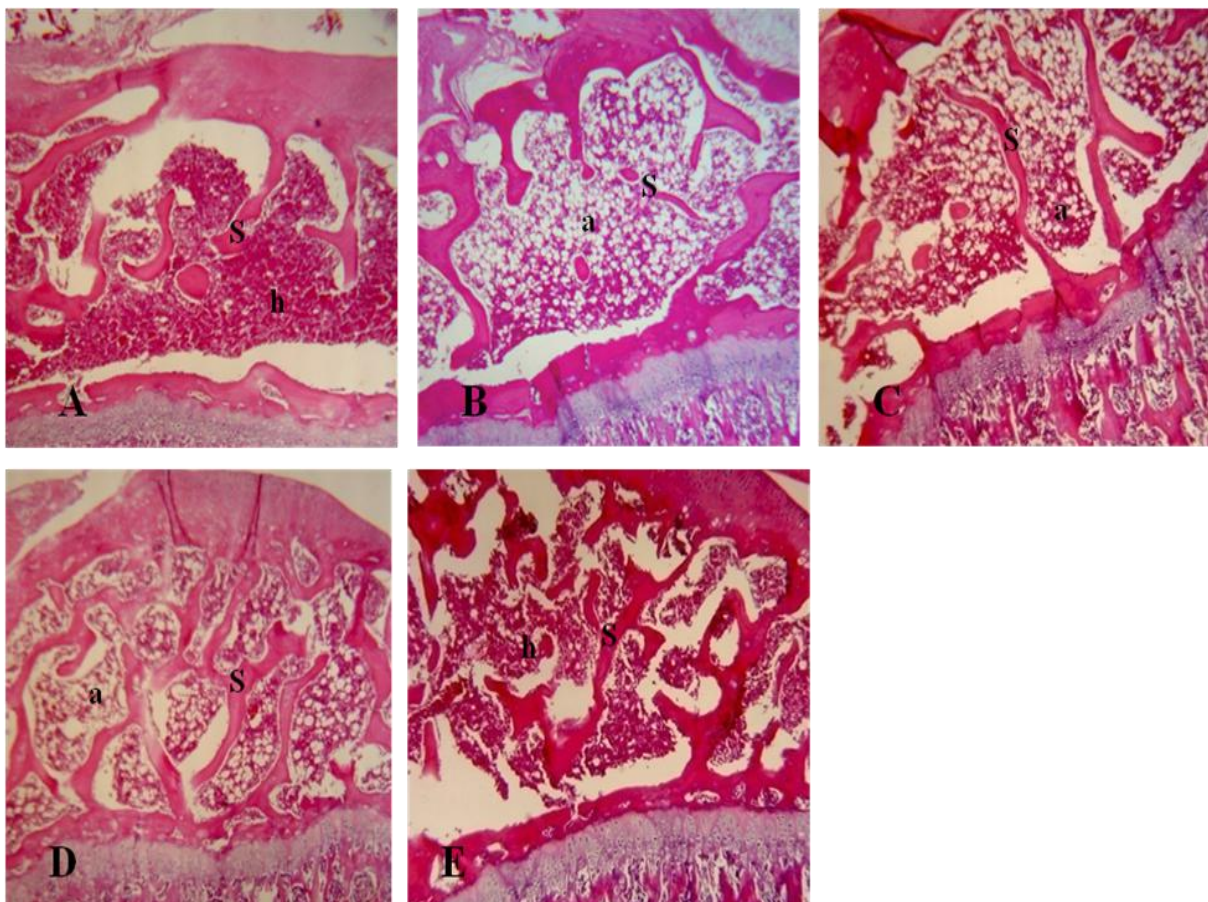
### Histopathological Analysis of Distal Femoral Epiphysis

Histopathological analysis of distal femoral epiphysis of normal control rats NK showed a normal shape (Figure 3A), in agreement to what Jee (1983) and Bullock and Rosendahl (1984) have explained, that proximal epiphysis and distal part of long bones consisted of the trabeculae and the cleft that connects trabeculae are filled with bone marrow. The use of trabeculae spicules to mark the presence of osteoblast is in accordance with a report by Shiraishi *et al.* (2000) which stated that recruitment, osteoblast differentiation, and bone formation by osteoblast were marked by the thickening of trabeculae spicules. The use of adipose tissue to mark the presence of osteoclast in bone marrow cavity is in accordance with Rosen *et al.* (2009) whose report stated that bone marrow cavity was filled with hematopoietic tissue, bone tissue, and adipose tissue. It has been reported by Dazzi *et al.*

(2006) and Minguell *et al.* (2001) that the balance of microenvironment in bone marrow is an important factor for hematopoietic process, osteogenesis process, and other processes.

Histopathologic analysis of distal femoral epiphysis of OVK rats (Figure 3B) and OVD rats (Figure 3C) showed a little amount of trabeculae spicules and the bone marrow cavity was dominated by adipose tissue. On OVDE rats (Figure 3D) and OVE rats (Figure 3E) showed more trabeculae spicules, and bone marrow cavity of OVE rats was dominated by hematopoietic tissue, while bone marrow cavity of OVDE rats was dominated by adipose tissue.

Domination of adipose tissue in bone marrow cavity of OVK rats femoral epiphysis marked osteoporosis. It had been reported by Syed *et al.* (2008) and Benayahu *et al.* (2000) that estrogen deficiency caused an increase in the accumulation, number, and size of adipose cells in bone marrow of post-menopausal women that suffer from osteoporosis and ovariectomized mice. Domination of adipose tissue in bone marrow cavity of OVK rats femoral epiphysis marked the increasing osteoclast activity in bone resorption which was thought to be related to the



**Figure 3.** Histopathological figure of distal epiphyseal femoral bone of NK rats (A) showed no change in trabecular spicules (s) and hematopoietic cells predominance in bone marrow cavity (h); OVK rats (B) and OVD rats (C) were showed few trabecular spicules (s), and adipocytes predominance in bone marrow (a); OVDE rats (D) and OVE rats (E) were showed more trabecular spicules (s), adipocytes predominance in bone marrow of OVDE rats (a), and hematopoietic cells predominance in bone marrow cavity of OVE rats (h) (HE 100x)

decreasing level of estrogen. According to Cooke and Naaz (2004) and Riggs *et al.* (2002), estrogen had a fundamental role in control of osteoblast and adipose cells. It had also been reported by Verma *et al.* (2002), Justesen *et al.* (2001) and Rodriguez *et al.* (1999) that the decrease of estrogen concentration affects proliferation and estrogenic activities in bone marrow and will cause a higher conversion of stromal cells into adipose cells rather than into osteoblasts. According to Weisberg *et al.* (2003) not only did the presence of adipose cells in bone marrow cavity suppress bone formation and inhibit osteoblastogenesis, but it also increase bone resorption. Some researchers reported that the decrease of estrogen concentration increase bone resorption until it exceeds bone formation (Manolagas *et al.*, 2000; Khosla *et al.*, 2002; Riggs *et al.*, 2002) which causes wider resorption of trabeculae bone, loss of trabeculae connectivity (Manolagas *et al.*, 2000; Khosla *et al.*, 2002; Riggs *et al.*, 2002), and the absence of trabeculae structure (Rosen and Bouxsein, 2006; Syed *et al.*, 2008). The decrease of distal femoral bone trabecular spicules in OVK rats also marked bone formation. Cigiela *et al.* (2012) reported that ovariectomy decreases trabeculae spicules and causes bone marrow cavity to become wider. According to Nakamura *et al.* (2003) and Notelovitz (1997), in normal condition, bone will maintain normal blood calcium level through the balance between bone resorption by osteoclast and formation of new bone by osteoblast. According to some researchers, bone resorption and formation imbalance (Goltzman, 2002; Teitelbaum and Ross, 2003; Martin and Sims, 2005; Seeman *et al.*, 2006; Karsdal *et al.*, 2007), higher rate of bone resorption rate than that of bone formation (Doige, 1988; Palmer, 1993), increasing bone resorption and decreasing bone formation or both (Banks, 1981; Bullock and Rosendahl, 1984; Jubb *et al.*, 1985) might cause osteoporosis. Therefore, it could be said that ovariectomy on OVK rats cause osteoporosis.

Calcitriol supplementation on OVD rats caused more adipose tissue to form in bone marrow cavity and trabeculae spicules of the distal epiphyseal plate of the femur were decreased compared to that of the NK rats, but appeared to have fewer amount of adipose tissue and more trabeculae spicules than OVK rats (Figure 3). The amount of adipose tissue in the bone marrow of femur distal epiphyseal plate of OVD rats, which was lesser than that of OVK rats but greater than NK rats, revealed that calcitriol supplementation decrease adipose tissue even in OVD rats that have lower concentration of estrogen. It was reported by Duque *et al.* (2004) that calcitriol inhibits adipogenesis in bone marrow cavity by lowering the expression of peroxisome proliferator-activated receptor gamma (PPAR $\gamma$ ) (Duque *et al.*, 2004). Zhou *et al.* (2006), Kong and Li (2006), and Sun and Zemel (2004), also reported that 1,25-dihydroxyvitamin D<sub>3</sub> induced apoptosis adipogenesis and inhibited adipogenesis in cells. Adipose tissue in the bone marrow cavity of femur the distal epiphyseal plate in OVD rats, which was lesser than that of the

OVK rats but greater than the NK rats revealed that calcitriol supplementation caused OVD rats's bone resorption activities become lower than that of OVK rats, but higher than that of NK rats.

Trabecular spicules of femur distal epiphyseal plate in OVD rats, which was greater in OVK rats but lesser in NK rats, thought to be related with a higher level of calcitriol. Chang *et al.* (2013) and Anderson *et al.* (2006) reported that supplementation of 1,25-dihydroxyvitamin D<sub>3</sub> increased preosteoblast proliferation to be osteoblast. Chang *et al.* (2013) also reported that supplementation of 1,25-dihydroxyvitamin D<sub>3</sub> caused higher marker of osteoclastin formation and alkaline phosphatase as well as caused higher mineral density of femoral and trabeculae femoral volume although still lower than rats that had been treated with estradiol. According to Zhou *et al.* (2006) 1,25-dihydroxyvitamin D<sub>3</sub> works directly on osteoblast to increase bone formation. Therefore, in this study, calcitriol supplementation causes bone formation activity on OVD rats to become higher than that of OVK rats, even though it's still lower than that of the NK rats.

Ethynil ethyl estradiol supplementation on OVE rats and OVDE rats were thought to cause estrogen concentration of OVE rats raised above that of OVK rats, and estrogen concentration of OVDE rats to become higher than that of OVD rats. Histopathological analysis of OVE rats showed fewer adipose tissues in bone marrow cavity and more spiculum trabeculae in the distal epiphyseal plate of the femur than that of OVK rats. The same thing was occurred in OVDE rats when compared to OVD rats (Figure 3). The fewer number of adipose tissue in bone marrow cavity of OVE rats and OVDE rats marked a lowered activity of bone resorption that was thought to have a relationship with the higher level of estrogen. Parikka *et al.* (2001) and Kameda *et al.* (1997) reported that estradiol lowers osteoclast activity for bone resorption. The more number of trabecular spicules that found in femur distal epiphyseal plate of OVE rats and OVDE rats were considered related with the higher level of estrogen in OVE rats and OVDE rats. Some researchers reported that estrogen could increase bone formation by increasing osteoblast formation, differentiation, proliferation, and osteoblast function, although it depends on the animal used (Chow *et al.*, 1992; Majeska *et al.*, 1994; Qu *et al.*, 1998). Chang *et al.* (2013) reported that estrogen has direct impact on osteoblast by increasing the number of osteoblast and hasten osteoblast in forming new bones. In conclusion, estradiol supplementation lowers bone resorption activity and increase bone formation activity.

The combination of calcitriol ethynil ethyl estradiol supplementation on OVDE rats caused rats OVDE to have higher amount of adipose tissue within their bone marrow cavity and higher number of trabeculae spicules than OVK rats (Figure 3). The lesser amount of adipose tissue in the bone marrow cavity of OVDE rats compared to that of OVK rats but greater than NK rats revealed that the combination of calcitriol and ethynil

ethyl estradiol supplementation caused the bone resorption activity of OVDE rats to become lower than OVK rats, but higher than NK rats. The higher number of trabecular spicules on femur distal epiphyseal plate of OVDE rats than in OVK rats and NK rats were showed an increment of bone formation process of OVDE rats than in OVK rats and NK rats. Adipose tissue in bone marrow cavity of OVDE rats was looked abundant than in NK rats, meanwhile, adipose tissue in OVDE rats looked fewer than OVK rats. These differences might be due to the higher number of estrogen found in OVDE rats than OVK rats. The more number of trabecular spicules in distal femoral epiphysis of OVDE rats than OVK rats was assumed related with the higher number of 1,25-dihydroxyvitamin D<sub>3</sub> and estrogen of OVDE rats than OVK rats. Furthermore, the more number of trabecular spicules in distalis femoral epiphysis of OVDE rats than NK rats is assumed related with higher number of 1,25-dihydroxyvitamin D<sub>3</sub> and estrogen of OVDE rats than NK rats. According to the result, it showed that the combination of calcitriol and ethynil ethyl estradiol in OVDE rats causes bone resorption activity of OVDE rats lower than OVK rats, but higher than NK rats, and causes bone formation activities of OVDE rats higher than OVK rats and NK rats.

## CONCLUSION

It can be concluded that the combination of calcitriol 20 g/day/rat and ethynil ethyl estradiol 25 µg/day/rat administered orally for 8 weeks in ovariectomized rats lower osteoporosis risk but increase endometrium cancer risk.

## REFERENCES

- Amant, F., P. Moerman, P. Neven, D. Timmerman, E. Van Limbergen, and I. Vergote. 2005. Endometrial cancer. **Lancet**, 366:491-505.
- Anderson, G.L., R.T. Chlebowski, and J.E. Rossouw. 2006. Prior hormone therapy and breast cancer risk in the women's health initiative randomized trial of estrogen plus progestin. **Maturitas**, 55:103-115.
- Anderson, G.L., M. Limacher, and A.R. Assaf. 2004. Effects of conjugated equine estrogen in postmenopausal women with hysterectomy: The women's health initiative randomized controlled trial. **JAMA**, 291:1701-1712.
- Banks, W.J. 1981. **Applied Veterinary Histology**. Williams & Wilkins, Baltimore/London.
- Benayahu, D., I. Shur, and S. Ben-Eliyahu. 2000. Hormonal changes affect the bone and bone marrow cells in a rat model. **J Cell Biochem**, 79:407-415.
- Bullock, B.L. and P.P. Rosendahl. 1984. **Pathophysiology Adaptations and Alterations in Function**. Little Brown and Company, Boston, Toronto.
- Chang, K.L., Y.C. Hu, B.S. Hsieh, H.L. Cheng, H.W. Hsu, L.W. Huang, and S.J. Su. 2013. Combined effect of soy isoflavones and vitamin D<sub>3</sub> on bone loss in ovariectomized rats. **Nutrition**, 29:250-257.
- Chow, J., J.H. Tobias, K.W. Colston, and T.J. Chambers. 1992. Estrogen maintains trabecular bone volume in rats not only by suppression of bone resorption but also by stimulation of bone formation. **J. Clin. Invest.** 89:74-78.
- Cigiela, U., J. Folwarczna, M. Pytlik, and G. Zgorka. 2012. Effect of extracts from *Trifolium medium L* and *Trifolium pratense L*. on development of estrogen deficiency-induced osteoporosis in rats. Hindawi Publishing Corporation. **Based Complementary and Alternative Medicine**. Article ID 921684.
- Cooke, P.S. and A. Naaz. 2004. Role of estrogens in adipocyte development and function. **Exp. Biol. Med.** 229:1127-1135.
- Dazzi, F., R. Ramasamy, S. Glennie, S.P. Jones, and I. Roberts. 2006. The role of mesenchymal stem cells in haemopoiesis. **Blood Rev.** 20:161-171.
- Doherty, D.A., K.M. Sanders, M.A. Kotowicz, and R.L. Prince. 2001. Lifetime and five-year age-specific risks of first and subsequent osteoporotic fractures in postmenopausal women. **Osteoporos. Int.** 12:16-23.
- Doige, C. 1988. Skeletal System. In **Special Veterinary Pathology**. Thompson, B.C. (Ed.). Decker Inc., Toronto.
- Duque, G., M. Maconno, and R. Kremer. 2004. 1,25(OH)<sub>2</sub>D<sub>3</sub> Inhibits bone marrow adipogenesis in senescence accelerated mice (SAM-P/6) by decreasing the expression of peroxisome proliferator-activated receptor gamma 2 (PPARgamma2). **Exp. Gerontol.** 39:333-336.
- Gallo, D., G.F. Zannoni, M. Fabrizi, I. De Stefano, E. Mantuano, and G. Scambia. 2008. Comparative effects of 17beta-estradiol and phytoestrogens in the regulation of endometrial functions in the rodent uterus. **J. Endocrinol. Invest.** 31(1):48-56.
- Goltzman, D. 2002. Discoveries, drugs and skeletal disorders. **Nat. Rev. Drug Discov.** 1:784-796.
- Hartiningsih, I. Widiyono, and D. Anggraeni. 2006. Peranan Ikan Teri Tawar dan 1,25-Dihidroksivitamin D<sub>3</sub> Dalam Kesehatan Tulang dan Ginjal: Studi Penanggulangan Osteoporosis. **Laporan Penelitian**. Universitas Gadjah Mada, Yogyakarta.
- Hartiningsih, D. Anggraeni, and D. Dhirgo Aji. 2012. Respon metafisis tulang femur distalis tikus ovariektomi yang mengkonsumsi kalsitriol. **J. Ked. Hewan**, 6:92-98.
- Hendy, G.N., K.A. Hruska, S. Mathew, and D. Goltzman. 2006. New insights into mineral and skeletal regulation by active forms of vitamin D. **Kidney Int.** 69:218-223.
- Hughes, D.E., A. Dai, J.C. Tiffée, H.H. Li, G.R. Mundy, and B.F. Boyce. 1996. Estrogen promotes apoptosis of murine osteoclasts mediated by TGF-beta. **Nat. Med.** 2:1132-1136.
- Jee, W.S.S. 1983. The Skeletal Tissues. In **Histology Cell and Tissue Biology**. Weiss, L. (Ed.). 5<sup>th</sup> ed. Elsevier Biomedical, New York.
- Jubb, K.V.F., P.C. Kenneddy, and N. Palmer. 1985. **Pathophysiology of Domestic Animals**. 3<sup>rd</sup> ed. Academic Press. Inc., Orlando Sandigo.
- Justesen, J., K. Stenderus, E.N. Ebbesen, L. Mosekilde, T. Steinche, and M. Kassem. 2001. Adipocyte tissue volume in bone marrow is increased with aging and in patients with osteoporosis. **Biogerontology**, 2(3):165-171.
- Kameda, T., H. Mano, T. Yuasa, Y. Mori, K. Miyazawa, M. Shiokawa, Y. Nakamaru, E. Hiroi, K. Hiura, A. Kameda, N.N. Yang, Y. Hakeda, and M. Kumegawa. 1997. Estrogen inhibit resorption by directly inducing apoptosis of bone-resorbing osteoclast. **J. Exp. Med.** 186(4):489-495.
- Karsdal, M.A., T.J. Martin, J. Bollerslev, C. Christiansen, and K. Henriksen. 2007. Are nonresorbing osteoclast sources of bone anabolic activity? **J. Bone Miner. Res.** 22:487-494.
- Khosla, S., L.J. Melton, and B.L. Riggs. 2002. Estrogen and the male skeleton. **J. Clin. Endocrinol. Metab.** 87:1443-1450.
- Kong, J. and Y.C. Li. 2006. Molecular mechanism of 1,25-dihydroxyvitamin D<sub>3</sub> inhibition of adipogenesis in 3T3-L1 cells. **Am. J. Physiol. Endocrinol. Metab.** 290:916-924.
- Kong, D., A. Suzuki, T.T. Zou, A. Sakurada, L.W. Kemp, and S. Wakatsuki. 1997. PTEN1 is frequently mutated in primary endometrial carcinomas. **Nat. Genet.** 17:143-144.
- Li, F., Y. Yang, C. Guo, C. Zhang, Z. Yang, and P. Li. 2013. Antiosteoporotic activity of echinacoside in ovariectomized rats. **Phytomedicine**, 20(6):549-557.
- Majeska, R.J., J.T. Ryaby, and T.A. Einhorn. 1994. Direct modulation of osteoblastic activity with estrogen. **J. Bone Joint. Surg. Am.** 76A:713-721.
- Manolagas, S.C. 2000. Birth and death of bone cells: Basic regulatory mechanisms and implications for the pathogenesis and treatment of osteoporosis. **Endocr. Rev.** 21:115-137.
- Manolagas, S.C., S. Kousteni, and R.L. Jilka. 2002. Sex steroids and bone. **Recent Prog. Horm. Res.** 57:385-409.
- Martin, T.J. and N.A. Sims. 2005. Osteoclast derived activity in the coupling of bone formation to resorption. **Trend. Mol. Med.** 11:76-81.

- Minguell J.J., A. Erices, and P. Conget. 2001. Mesenchymal stem cell. **Exp. Biol. Med.** 226:507-520.
- Mohr, S.B., C.F. Garland, E.D. Gorham, W.D. Grant, and F.C. Garland. 2007. Is ultraviolet B irradiance inversely associated with incidence rates of endometrial cancer: An ecological study of 107 countries. **Prev. Med.** 45:327-331.
- Nakamura, M., N. Udagawa, S. Matsuura, M. Mogi, H. Nakamura, H. Horiuchi, N. Saito, B.Y. Hiraoka, Y. Kobayashi, K. Takaoka, H. Ozawa, H. Miyazawa, and N. Takahashi. 2003. Osteoprotegerin regulates bone formation through a coupling mechanism with bone resorption. **Endocrinology.** 144:5441-5449.
- Notelovitz, M. 1997. Estrogen therapy and osteoporosis: Principles & practice. **Am. J. Med. Sci.** 313(1):2-12.
- Palmer, N. 1993. Bones and Joints. In **Pathology of Domestic Animals**. Jubb, K.V.F., P.C. Kennedy, and N. Palmer (Eds.). Academic Press, Inc., Harcourt Brace Jovanovich Publishers, San Diego.
- Pan, M., Z. Li, V. Yeung, and R.J. Xu. 2010. Dietary supplementation of soy germ phytoestrogens or estradiol improves spatial memory performance and increases gene expression of BDNF, TrkB receptor and synaptic factors in ovariectomized rats. **Nutrition and Metabolism.** 7:75.
- Parikka, V., P. Lehenkari, M.L. Sassi, J. Halleen, J. Risteli, P. Harkonen, and K. Vaananen. 1997. Estrogen inhibit resorption by directly inducing apoptosis of bone-resorbing osteoclast. **Endocrinology.** 142(2):5371-5378.
- Qu, Q., M. Perala-Heape, A. Kapanen, J. Dahllund, J. Salo, H.K. Vaananen, P. Harkonen. 1998. Estrogen enhances differentiation of osteoblasts in mouse bone marrow culture. **Bone.** 22:201-209.
- Riggs, B.L., S. Khosla, and L.J. Melton. 2002. Sex steroids and the construction and conservation of the adult skeleton. **Endocrinol. Rev.** 23:279-302.
- Rodan, G.A. and T.J. Martin. 2000. Therapeutic approaches to bone disease. **Science.** 289:1508-1514.
- Rodriguez, J.P., S. Garat, H. Gajardo, A.M. Pino, and G. Seitz. 1999. Abnormal osteogenesis in osteoporotic patients is reflected by altered mesenchymal stem cells dynamics. **J. Cell Biochem.** 75:414-423.
- Rosen, C.J., C. Ackert-Bicknell, J.P. Rodriguez, and A.M. Pino. 2009. Marrow fat and the bone microenvironment: Developmental, functional, and pathological implications. **Crit. Rev. Eukaryot. Gene Expr.** 19(2):109-124.
- Rosen, C.J. and M.L. Bouxsein. 2006. Mechanisms of disease: Is osteoporosis he obesity of bone? **Nature Clinical Practice Rheumatol.** 2:35-43.
- Rossouw, J.E., G.L. Anderson, R.L. Prentilce, A.Z. LaCroix, C. Kooperberg, M.L. Stefanick, R.D. Jackson, S.A. Beresford, B.V. Howard, K.C. Johnson, J.M. Kotchen, and J. Ockene. 2002. Risk and benefits of estrogen plus progestin in healthy postmenopausal women: Principal results from the women's health initiative randomized controlled trial. **JAMA.** 288:321-333.
- Salazar-Martinez, E., E. Lazcano-Ponce, L.M. Sanchez-Zamorano, G. Gonzales-Lira, R.P. Escudero-DE Los, and M. Hernandez-Avila. 2005. Dietary factors and endometrial cancer risk. Results of a case-control study in Mexico. **Int. J. Gynecol. Cancer.** 15:938-945.
- Saruhan, B.G., D. Ozbag, N. Ozdemir, and Y. Gumusalan. 2006. Comparative effects of ovariectomy and flutamid on body-uterus weight and uterine histology in the ovariectomized rat model. **Inonu Universitesi Tip Fakultesi Dergisi.** 13:221-226.
- Seeman, E., B. Vellas, C. Benhamou, J.P. Aquino, J. Semler, J.M. Kaufman, K. Hoszowski, A.R. Varela, C. Fiore, K. Brixen, J.Y. Reginster, and S. Boonen. 2006. Strontium ranelate reduce the risk of vertebral and nonvertebral fractures in women eighty years of age and older. **J. Bone Miner. Res.** 21:1113-1120.
- Shiraishi, A., S. Takeda, T. Masaki, Y. Higuchi, Y. Uchiyama, N. Kubodera, K. Sato, K. Ikeda, T. Nakamura, T. Matsumoto, and E. Ogata. 2000. Alfacalcidol inhibits bone resorption and stimulates formation in an ovariectomized rat model of osteoporosis: Distinct actions from estrogen. **J. Bone Miner. Res.** 15:235-244.
- Sonmez, A.S., M. Birincioglu, A. Aydin, E. Kilic, and N. Sahin. 2000. Effects of misoprostol on the endometrium of ovariectomized rats. **Turk. J. Med. Sci.** 30:115-118.
- Sun, X. and M.B. Zemel. 2004. Role of uncoupling protein 2 (UCP2) expression and 1alpha, 25-dihydroxyvitamin D3 in modulating adipocyte apoptosis. **Faseb. J.** 18:1430-1432.
- Syed, F.A., M.J. Oursler, T.E. Hefferan, J.M. Peterson, B.L. Riggs, and S. Khosla. 2008. Effects of estrogen therapy on bone marrow adipocytes in postmenopausal osteoporotic women. **Osteoporosis Int.** 19(9):1323-1330.
- Teitelbaum, S.L. and F.P. Ross. 2003. Genetic regulation of osteoclast development and function. **Nat. Rev. Genet.** 4:638-649.
- Teitelbaum, S.L. 2000. Bone resorption by osteoclasts. **Science.** 289:1504-1508.
- Verma, S., J.H. Rajaratnam, J. Denton, J.A. Hoyland, and R.J. Byers. 2002. Adipocytic proportion of bone marrow is inversely related to bone formation in osteoporosis. **J. Clin. Pathol.** 55:693-698.
- Weisberg, S.P., D. McCann, M. Desai, M. Rosenbaum, R.L. Leibel, and A.W. Jr. Ferrante. 2003. Obesity is associated with macrophage accumulation in adipose tissue. **J. Clin. Invest.** 112(12):1785-1808.
- Zhou, Y.S., Y.S. Liu, and J.G. Tan. 2006. Is 1, 25-dihydroxyvitamin D3 an ideal substitute for dexamethasone for inducing osteogenic differentiation of human adipose tissue-derived stromal cells *in vitro*? **Chin. Med. J.** 119:1278-1286.