

# HISTOLOGICAL FINDINGS IN THE SEMINIFEROUS TUBULE OF MALE LOCAL KACANG GOATS AFTER SUPPLEMENTATION OF KATUK LEAVES

## *Gambaran Histologis Tubulus Seminiferus Kambing Kacang Jantan Lokal Pascapemberian Suplemen Daun Katuk*

Teuku Reza Ferasyi<sup>1</sup>, Hamdani Budiman<sup>2</sup>, Muslim Akmal<sup>3</sup>, Juli Melia<sup>4</sup>, Razali<sup>1</sup>,  
Andi Novita<sup>1</sup>, Rina Aulia Barus<sup>5</sup>, and Agik Suprayogi<sup>6</sup>

<sup>1</sup>Laboratory of Veterinary Public Health, Faculty of Veterinary Medicine Syiah Kuala University, Banda Aceh

<sup>2</sup>Laboratory of Pathology, Faculty of Veterinary Medicine Syiah Kuala University, Banda Aceh

<sup>3</sup>Laboratory of Histology, Faculty of Veterinary Medicine Syiah Kuala University, Banda Aceh

<sup>4</sup>Laboratory of Animal Reproduction, Faculty of Veterinary Medicine Syiah Kuala University, Banda Aceh

<sup>5</sup>Centre for Aceh's Cattle Development, Indrapuri, Aceh Besar

<sup>6</sup>Department of Anatomy, Physiology, and Pharmacology of Animal Reproduction, Faculty of Veterinary Medicine of Bogor Agricultural Institute, Bogor

E-mail: teuku\_rezaferasyi@unsyiah.ac.id

### ABSTRACT

This study tested whether administration of powder or alcohol extract of katuk leaves affected the histology of seminiferous tubule of testis of male local kacang goats. We used 15 animals that were about 1.5 years old. They were acclimatized for 2 weeks to the experimental environment and allocated among three groups of 5. Group P0 (Control) was given distilled water. Group P1 was given powdered katuk leaf and Group P2 was given alcohol extract of katuk leaf. All treatments were administered orally twice per day (at morning and afternoon) for 35 consecutive days. All animals were fed with leaves and grasses, and had access to water *ad libitum*. At the end of the treatment period, animals were castrated, and the seminiferous tubule from testes was processed for histology evaluation. There was a qualitative indication of a high production of spermatids and spermatocytes in P1 and P2. Most production was observed in P1 as compared to P2. We conclude that the administration of katuk leaf increases the production of spermatids and spermatocytes in kacang Goats, with a greater effect when the goats fed with powder than with alcohol extract.

Key words: spermatids, spermatocytes, testis, katuk leaf, kacang goats

### ABSTRAK

Penelitian ini mengetahui pengaruh pemberian tepung atau ekstrak alkohol daun katuk terhadap perubahan histologis testis kambing kacang lokal jantan. Dalam penelitian ini digunakan 15 ekor kambing dengan umur sekitar 1,5 tahun. Semua hewan penelitian terlebih dahulu diaklimatisasi selama 2 minggu terhadap lingkungan penelitian. Hewan-hewan tersebut dibagi menjadi 3 kelompok yang masing-masing terdiri atas 5 ekor kambing. Kelompok P0 (kontrol) telah hanya diberikan air distilasi. Pada kelompok P1, diberikan perlakuan berupa suplementasi tepung daun katuk dan untuk kelompok P2 diberikan ekstrak alkohol daun katuk. Semua perlakuan diberikan secara oral sebanyak dua kali per hari (pada pagi dan sore hari) selama 35 hari berturut-turut. Setiap kambing percobaan diberikan pakan yang terdiri atas daun-daunan dan rumput, serta disediakan akses untuk memperoleh air minum secara *ad libitum*. Pada akhir waktu penelitian, seluruh hewan dikastrasi dan bagian tubulus seminiferus dari testis diambil dan diproses lebih lanjut untuk evaluasi secara histologis. Hasil yang diperoleh menunjukkan bahwa terdapat indikasi peningkatan produksi spermatid dan spermatoosit pada Kelompok P1 dan P2. Dengan demikian disimpulkan bahwa pemberian suplemen daun katuk dapat meningkatkan produksi spermatid dan spermatoosit kambing kacang lokal jantan.

Kata kunci: spermatid, spermatoosit, testis, daun katuk, kambing kacang

### INTRODUCTION

In small ruminants, such as sheep and goats, have been reported that their reproductive performances mainly depend on nutrition, including its supplement. In particular, to increase the activity of testis in producing testosterone and sperms (Lindsay et al., 1976; Oldham et al., 1978; Masters and Fels, 1984; Thwaites and Hannan, 1989; Murray et al., 1990). For example, Australian Merino sheep fed with a high amount of lupin has resulted in an increased the activity of testis twice as compared to the group fed with a lower amount of lupin (Oldham et al., 1978; Masters and Fels, 1984; Murray et al., 1990). On the other hand, feeding the animals with a low amount of nutrition resulted in a smaller size (Oldham et al., 1978;

Thwaites and Hannan, 1989) and a lower weight of testis (Howland and Skinner, 1973; Campbell et al., 1977; Howland, 1979). These condition can be improved after increased the diet (Campbell et al., 1977; Howland, 1979).

Possibly, the effect in the small ruminants reproductive system as mentioned above is resulted from an increase of metabolic substances, which produced post-feeding. Among metabolic substance produced in the small ruminants and play a vital role in increasing the activity of reproductive system is volatile fatty acids (VFA) (Martin and Walkden-Brown, 1995). Boukhliq et al. (1993) reported that feeding rams with VFA supplement has increased the activity of reproductive endocrinology axis, they are hypothalamus, pituitary gland, and testis similar

to the effect when the animals fed with lupin. However, although several studies have been conducted, a sufficient applicable method or substance to stimulate the production of VFA is not yet available.

Interestingly, a study showed that administration of powder or alcohol extract of katuk leaves (*Sauropus androgynus*, L. Merr.), as a herbal supplement, to the sheep could increase their VFA production (Suprayogi and Meulen, 2000). Therefore, we assumed that the administration of powder or alcohol extract of katuk leaves, in turn, would also affect the activity of testis. We have tested this hypothesis in our preliminary study and the results are described below.

## MATERIALS AND METHODS

### Preparation of Powder and Alcohol Extract of Katuk Leaves

#### Production of powder of katuk leaves

The production of powder of katuk leaves was conducted by modified the processing method of Suprayogi (2005). Firstly, fresh katuk leaves that obtained from a cultivation plot in Aceh Besar District of Aceh Province, were withered for 24 h. Then, it was dried at a temperature of 30° C for 12 h. Finally, the dried leaves were processed to be powder using a blender machine (Panasonic®).

#### Production of alcohol extract of katuk leaves

The production of alcohol extract of katuk leaves was conducted using the following maceration technique (Suprayogi, 2005): 88 g of powder of katuk leaves was mixed with 1 liter of 70% alcohol. It was stirred for up to 9 h and, then, stored for 24 h. The mixed substance was filtered. Then, it was evaporated using a rotary-evaporator at 50° C for 36 h to obtain a viscous extract.

#### Animal Treatment

A total of 15 male local *kacang* goats at  $\pm 1.5$  years old were used in this study. Initially, all animals were acclimatized for 14 days. Every day, they were fed native pasture and grass as well as access to water ad libitum. Then, after passed acclimatization period, by using a complete random design (CRD) approach, all 15 goats were placed randomly in individual cage, and divided into 3 different treatment groups (Each group comprised of 5 goats). The groups were one control group (P0) and two different treatment groups (P1 and P2), as follow: P0, control group, which was given distilled water; P1, which was administered with powder of katuk leaves at 7.44 g/day per goat; and, which was given with alcohol extract of katuk leaves (P1) at 1.89 g/day per goat. All animals were given treatments by oral administration twice a day in the morning (at 07:30 hours) and in the afternoon (at 16:30 hours), for 35 days, consecutively.

### Sample Collection

On the day of 36<sup>th</sup> the sample of testis were collected from all animals. All 15 goats were castrated using a sterile surgical method at the surgery room of Animal Clinic of the Faculty of Veterinary Medicine of Syiah Kuala University, Darussalam, Banda Aceh.

### Histological Preparation and Evaluation

After castrated, all testis samples were rapidly isolated and fixed in 10% neutral-buffered formalin (pH 7.0) solution for 24 h at the Laboratory of Histology of the Faculty of Veterinary Medicine of Syiah Kuala University, Darussalam, Banda Aceh. Then, the seminiferous tubules were separated from the testis. The tissue was dehydrated using a series of graded ethanol in ascending concentrations (80%-95%-95%-100%-100%-100%). Next, immersed in xylene for clearing, infiltrated in paraffin wax, and finally embedded in paraffin wax. The tissue sections were then cut at 5-6  $\mu$ m thickness by using rotary microtome Leica RM 2235 (Leica Biosystem GmbH, Germany) and stained by hematoxylin and eosin (H&E). The specimens were examined and photographed under microscope Olympus, BX.41 40x (Olympus America, Melville, NY, USA).

### Data Analysis

Data obtained from this study were analyzed descriptively based on histological evaluation.

## RESULTS AND DISCUSSION

This is the first report, as far as we know, of the effect of supplementation of katuk leaves powder and alcohol extract on the male reproductive organ of small ruminant. Previously, most studies have tested the effect of supplementation of powder and alcohol extract of katuk leaves on the reproductive system of poultry (Subekti, 2007; Wiramadja et al., 2007; Putranto, 2011).

The results from our preliminary study showed that there were dissimilar histological findings in the seminiferous tubule of the testis, qualitatively, between different treatment groups of male local *kacang* goat (Figure 1). In particular, there was a qualitative indication of a high production of spermatids and spermatocytes in a group given with powder (Figure 1B) and alcohol extract (Figure 1C) of katuk leaf as compared to control group (Figure 1A).

Based on further histological evaluation, it was found that most production of spermatids and spermatocytes observed in a group administered with powder of katuk leaf as compared to the group given alcohol extract of katuk leaf. The results we obtained in our study are in agreement with the effect of supplementation of katuk leaf to poultry animals. Subekti (2007) have conducted a research to study the effect of katuk leaves on Japanese Quail Reproduction System. They suggested that the addition of 9% of powder of katuk leaf into the feed ration led to

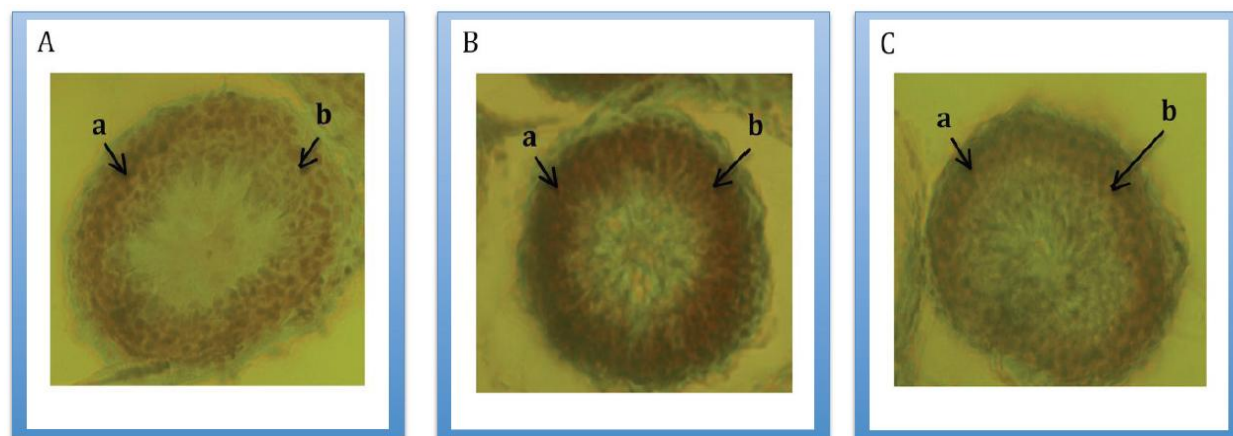


Figure 1. Histological findings in the seminiferous tubule of the testis between different treatment groups of male local *kacang* goat. A (control group), B (administration of powder of katuk leaf), C (alcohol extract of katuk leaf). a: spermatocytes, b: spermatids. H&E 40X

stimulate the production of oestradiol hormone and reached puberty faster as compared to control group and the group given alcohol extract of katuk leaf. However, a different result is obtained when the quail given a higher percentage of powder of katuk leaf (Wiramadja, 2007). In addition, Putranto (2011) reported that the supplementation of water extract of katuk leaf has increased the weight of ovarium of Burgo (Bengkulu native chicken) hens. It is caused by the increased activity of this organ after given the extract, and resulted in a higher production of ovum. Importantly, our result indicated that the effect on the testis organ not only in the group of male local *kacang* goat administered with powder of katuk leaf, but also in the group received alcohol extract of katuk leaf. Although, most production of spermatids and spermatocytes is found in a group administered with powder of katuk leaf. Overall, these results indicated that katuk leaf supplement is very potential to be used in animal industry, especially for improving poultry and small ruminant reproductive performance.

The effect of nutrition supplement to the activity of small ruminants reproductive system perhaps conducted through a direct action to gonadotropin releasing hormone (GnRH)-pulse neurons or to gonad (Martin et al., 1994). For example, the improvement of nutrition in male sheep could increase the frequency of luteinizing hormone (LH) pulses, as a reflection of GnRH pulses activity in the hypothalamus, and the amount of follicle stimulating hormone (FSH) secreted. The increase of production of these gonadotropin hormones, then affected to the increase of testosterone secretion and testicular size.

In the case of the effect of katuk leaf on the animal reproductive system, perhaps conducted through its stimulation to the activity of substance of 17-ketosteroids, androstan-17-one,3-ethyl-3-hydroxy-5 $\alpha$ , which can be converted to oestradiol (Suprayogi et al., 2001). This substance is play an important role as a precursor or mediator in steroid hormone biosynthesis in gonad, thyroid gland and cortex

adrenal (Miller et al., 1984). In particular, the addition of powder of katuk leaf into the animal fodder could reduce the level of cholesterol in several parts, such as liver and carcass, which in turn will affect the reproductive performance of animals (Wiramadja et al., 2007). In this case, the VFA, which is increased post supplemented with katuk leaves powder may also play an important role in increasing the activity of reproductive system in small ruminant (Martin and Walkden-Brown, 1995; Suprayogi and Meulen, 2000). However, a further study is needed to proof this hypothesis.

Furthermore, another interesting aspect for future study of the internal effects of katuk leaves supplementation on the testis is to look at molecular changes in the intracellular of testis. The intermolecular process of spermatogenesis is suggested involving the mechanism of cAMP-dependent signaling pathway. In this mechanism, there is also involves the modulation of multigene family of transcription factor, which consists of basic transactivation and basic region-leucine zipper (bZIP), such as CREB, CREM, and activating transcription factor-1 (ATF-1) (Scobey et al., 2001).

## CONCLUSION

We concluded that the administration of katuk leaves increased the production of spermatids and spermatocytes in *kacang* goats, with a greater effect when the goats fed with powder than with alcohol extract.

## ACKNOWLEDGEMENTS

The authors would like to grateful to the DP2M of Directorate of Higher Education of The Ministry of Education and Culture of Republic Indonesia and Research Institute of Syiah Kuala University for supporting our research funding through “*Hibah Bersaing*” scheme.

## REFERENCES

- Boukhliq, R., D.W. Miller, and G.B. Martin. 1993. Dietary fatty acids stimulate gonadotrophin secretion in the ram. **Proceedings of Annual Conference of the Australian Society for Reproductive Biology**. Dunedin:25. (Abstract).
- Campbell, G.A., M. Kurz, S. Marshall, and J. Meites. 1977. Effects of starvation in rats on serum levels of follicle-stimulating hormone, luteinizing hormone, thyrotropin, growth hormone and prolactin; response to LH-releasing hormone and thyrotropin-releasing hormone. **Endocrinol.** 100:580-587.
- Howland, B.E. 1979. Effect of underfeeding on the inhibition of gonadotrophin secretion by testosterone propionate in rats. **J. Reprod. Fertil.** 55:335-338.
- Howland, B.E. and K.R. Skinner. 1973. Effect of starvation on LH levels in male and female hamsters. **J. Reprod. Fertil.** 32:505-507.
- Martin, G.B. and S.W. Walkden-Brown. 1995. Nutritional influences on reproduction in mature male sheep and goats. **J. Reprod. Fertil (Supl.)**. 49:437-449.
- Martin, G.B., S. Tjondronegoro, and M.A. Blackberry. 1994. Effects of nutrition on testicular size and the concentrations of gonadotrophins, testosterone and inhibin in plasma of nature male sheep. **J. Reprod. Fertil.** 101:121-128.
- Masters, D.G. and H.E. Fels. 1984. Seasonal changes in the testicular size of grazing rams. **Proc. Aust. Soc. Anim. Prod.** 15:444-447.
- Miller, R.J., D.R. Brown, E.B. Chang, and J.F. Kachur. 1984. **Effect of Opiates and Opioid Peptides in the Intestinal Mucosa**. Elsevier Science Publishers, USA.
- Murray, P.J., J.B. Rowe, D.W. Pethick, and N.R. Adams. 1990. The effect of nutrition on testicular growth in the Merino ram. **Aust. J. Ag. Res.** 41:185-195.
- Oldham, C.M., N.R. Adams, P.B. Gherardi, D.R. Lindsay, and J.B. Mackintosh. 1978. The influence of level of feed intake on sperm producing capacity of testicular tissue in the ram. **Aust. J. Ag. Res.** 29:173-179.
- Putranto, H.D. 2011. Pengaruh suplementasi daun katuk terhadap ukuran ovarium dan oviduk serta tampilan produksi telur ayam Burgo. **J. Sain Peternakan Indonesia.** 6(2):103-114.
- Scobey, M.J., S. Bertera., J.P. Somers., S.C. Watkins., A.J. Zeleznik and W.H. Walker. 2001. Delivery of a cyclic adenosine 3', 5'-monophosphate response element binding protein (CREB) to seminiferous tubules result in impaired spermatogenesis. **Endocrinol.** 142:948-954.
- Subekti S. 2007. Komponen Sterol dalam Ekstrak Daun Katuk (*Sauropus androgynus* L. Merr) dan Hubungannya dengan Sistem Reproduksi Puyuh. **Disertasi**. Sekolah Pascasarjana, Institut Pertanian Bogor. Bogor.
- Suprayogi A. 2005. Blood serum volatile fatty acids (VFAs) in lactating sheep and VFAs production under *in-vitro* conditions using *Sauropus androgynus* (L.) Merr. Leaves. **Gakuryoku XI(3):57-60**.
- Suprayogi, A. and .U. ter. Meulen. 2000. The Influence of *Sauropus androgynus* Leaves on The Production of Volatile Fatty Acids Using Rumen Liquor Under In-Vitro Conditions. **Expo 2000-Workshop. Lanbouforschung Volkenrode-Sonderheft. Bunderforschungsanstalt fur Landwirtschaft**. Braunschweig: 398-401.
- Suprayogi, A., U. ter Meulen, T. Ungerer, and W. Manalu. 2001. Population of secretory cells and synthetic activities in mammary gland of lactating sheep after consuming *Sauropus androgynus* (L.) Merr. leaves. **Indon. J. Trop. Agric.** 10(1):1-3.
- Thwaites, C.J. and G.D. Hannan. 1989. The effects of frequency of ejaculation and undernutrition on the size and tone of the ram's testes. **Anim. Reprod. Sci.** 19:29-35.
- Wiradimadja, R., W.G. Piliang, M.T. Suhartono, and W. Manalu. 2007. Umur dewasa kelamin puyuh jepang betina yang diberi tepung daun katuk (*Sauropus androgynus*, L. Merr.). **Anim. Product.** 9(2):67-72.