



REFERENCE ONLY

UNIVERSITY OF LONDON THESIS

Degree PhD

Year 2005

Name of Author EL. GOHARY MA
ALU

COPYRIGHT

This is a thesis accepted for a Higher Degree of the University of London. It is an unpublished typescript and the copyright is held by the author. All persons consulting the thesis must read and abide by the Copyright Declaration below.

COPYRIGHT DECLARATION

I recognise that the copyright of the above-described thesis rests with the author and that no quotation from it or information derived from it may be published without the prior written consent of the author.

LOANS

Theses may not be lent to individuals, but the Senate House Library may lend a copy to approved libraries within the United Kingdom, for consultation solely on the premises of those libraries. Application should be made to: Inter-Library Loans, Senate House Library, Senate House, Malet Street, London WC1E 7HU.

REPRODUCTION

University of London theses may not be reproduced without explicit written permission from the Senate House Library. Enquiries should be addressed to the Theses Section of the Library. Regulations concerning reproduction vary according to the date of acceptance of the thesis and are listed below as guidelines.

- A. Before 1962. Permission granted only upon the prior written consent of the author. (The Senate House Library will provide addresses where possible).
- B. 1962 - 1974. In many cases the author has agreed to permit copying upon completion of a Copyright Declaration.
- C. 1975 - 1988. Most theses may be copied upon completion of a Copyright Declaration.
- D. 1989 onwards. Most theses may be copied.

This thesis comes within category D.

This copy has been deposited in the Library of UCL

This copy has been deposited in the Senate House Library, Senate House, Malet Street, London WC1E 7HU.

POSTERIOR CAPSULAR OPACIFICATION

**Incidence and Factors Influencing the Rate of
Nd:YAG Capsulotomy in Diabetic and Uveitic Patients
and after Multifocal Intraocular Lens Implantation**

Submission to the University of London

By

Mostafa A. Elgohary

for the degree of Doctorate in Medicine (M.D.)

2005

UMI Number: U592026

All rights reserved

INFORMATION TO ALL USERS

The quality of this reproduction is dependent upon the quality of the copy submitted.

In the unlikely event that the author did not send a complete manuscript and there are missing pages, these will be noted. Also, if material had to be removed, a note will indicate the deletion.



UMI U592026

Published by ProQuest LLC 2013. Copyright in the Dissertation held by the Author.
Microform Edition © ProQuest LLC.

All rights reserved. This work is protected against
unauthorized copying under Title 17, United States Code.



ProQuest LLC
789 East Eisenhower Parkway
P.O. Box 1346
Ann Arbor, MI 48106-1346

I dedicate this work to *my parents* and *my brother Ahmad*, for their unrelenting support and unconditional love.

ABSTRACT

This thesis examined the incidence and factors affecting the rate of posterior capsular opacification (PCO), the most common complication of cataract surgery, in diabetic and uveitic patients and in patients with multifocal intraocular lenses (IOLs). These patients are particularly sensitive to PCO development because of the risks associated with Nd:YAG capsulotomy in the former two groups and the potential effect on visual function in the latter group. PCO rate was estimated both retrospectively, using Nd:YAG capsulotomy as a surrogate measure of clinically significant PCO, as well as prospectively using clinical and imaging methods.

Diabetic patients were found to have a lower incidence and risk of Nd:YAG capsulotomy than non-diabetic patients within 4 years after surgery. Young age, postoperative inflammation, pars plana vitrectomy and, in comparison to 3-piece silicone IOL, polymethylmethacrylate (PMMA) and plate-haptic silicone IOLs were associated with increased risk of Nd:YAG capsulotomy. In subgroup analysis, male gender was found to be a risk factor in the non-diabetic group and the duration and type of diabetes and diabetic retinopathy grade were not risk factors. In a prospective randomised trial, hydrophobic acrylic IOLs, while associated with a higher flare value within the early postoperative period, had a significantly lower rate of PCO development than plate-haptic silicone IOLs after 6 months and 1 year in diabetic patients. Optical coherence tomography revealed the development of a characteristic mid-peripheral apposition between the optic and the posterior capsule with hydrophobic acrylic IOLs both early and late after surgery, and the lack thereof with plate-haptic silicone IOLs, which is consistent with and explains the difference in PCO rate between the two IOLs.

In uveitic patients, the incidence of Nd:YAG capsulotomy was higher within the first two years after surgery than in non-uveitic patients, although the presence of uveitis was not an independent risk factor for an increased rate of Nd:YAG capsulotomy. The use of preoperative systemic steroids reduced the risk of Nd:YAG capsulotomy and, in comparison to PMMA IOLs, silicone IOLs reduced the risk of Nd:YAG capsulotomy while hydrophilic acrylic IOLs and young age increased it.

In patients with multifocal IOLs, within 4 years of follow-up the incidence of PCO and Nd:YAG capsulotomy were similar to those reported with monofocal implants

and young age was a risk factor for the development of PCO. Patients with multifocal IOLs present for Nd:YAG capsulotomy with earlier loss of high and low-contrast acuity, which could increase the rate of Nd:YAG capsulotomy in these patients.

TABLE OF CONTENTS

Abstract	3
Abbreviations	17
Abbreviations	17
Acknowledgement.....	19
Chapter 1	21
1 Introduction and review of the literature.....	22
1.1 Introduction	22
1.1.1 Cataract surgery and posterior capsular opacification: perspective and aims of the thesis	22
1.1.2 Embryology, anatomy and histology of the lens and its capsule	25
1.1.3 Cataract extraction techniques	27
1.1.4 Intraocular lenses used after cataract extraction: physical properties and clinical features.....	32
1.1.5 Anterior segment changes after cataract extraction	44
1.1.6 Changes in the capsular bag	45
1.2 Review of the literature	68
1.2.1 Incidence of PCO	68
1.2.2 Factors affecting the incidence of PCO.....	69
Chapter 2	79
2 Posterior capsular opacification in diabetic patients	80
2.1 Study of the incidence and risk factors of Nd:YAG capsulotomy in non-diabetic and diabetic patients	80
2.1.1 Introduction	80
2.1.2 Aims	81
2.1.3 Patients and methods.....	81

2.1.4	Results	83
2.1.5	Discussion	92
2.1.6	Limitations	96
2.1.7	Conclusion.....	97
2.2	Posterior Capsular Opacification after implantation of Plate Haptic Silicone and Hydrophobic Acrylic IntraOcular Lenses in Diabetic Patients: A Pilot random ised clinical trial	98
2.2.1	Introduction	98
2.2.2	Aims	99
2.2.3	Patients and methods.....	99
2.2.4	Results	102
2.2.5	Discussion	110
2.2.6	Conclusion.....	115
Chapter 3	116
3	Using the optical coherence tomography to compare the relationship of a plate haptic silicone and a hydrophobic acrylic intraocular lens to the posterior capsule: a pilot randomised clinical trial.....	117
3.1	Introduction	117
3.1.1	Optical coherence tomography.....	117
3.1.2	Light source in OCT.....	117
3.1.3	The beam splitter.....	119
3.1.4	Scanning and scan images.....	119
3.1.5	Use of the Optical conherence tomography for anterior segment examination	120
3.2	Aims	120
3.3	Patients and methods.....	121
3.3.1	Inclusion & exclusion criteria	121

3.3.2	Surgical technique	121
3.3.3	OCT image acquisition.....	121
3.3.4	Outcome measures and statistical analysis.....	125
3.4	Results	125
3.4.1	Patient characteristics	125
3.4.2	Delineation of IOLs on the OCT scans	126
3.4.3	Appositional relationship between the intraocular lenses and the posterior capsule.....	127
3.4.4	Follow-up scans.....	127
3.4.5	Posterior capsular opacification and IOL outline.....	127
3.5	Discussion	128
3.5.1	Delineation of the IOLs.....	128
3.5.2	Appositional relationship of the posterior capsule to the IOLs.....	131
3.6	Limitations	137
3.7	Conclusion.....	137
Chapter 4	138
4	Incidence and risk factors of posterior capsular opacification in uveitis patients following phacoemulsification and extracapsular cataract extraction	139
4.1	Introduction	139
4.2	Aims	139
4.3	Study of the incidence and risk factors of Nd:YAG capsulotomy after phacoemulsification in patients with uveitis	140
4.3.1	Material and Methods.....	140
4.3.2	Results	145
4.3.3	Discussion	156
4.3.4	Limitations	160
4.3.5	Conclusion.....	160

4.4	Study of the incidence and risk factors of Nd:YAG capsulotomy in uveitis patients: phacoemulsification versus extracapsular cataract extraction	161
4.4.1	Patients and methods.....	161
4.4.2	Results.....	161
4.4.3	Discussion	170
4.4.4	Limitations	171
4.4.5	Conclusion.....	171
Chapter 5	172
5	Posterior capsular opacification after multifocal intraocular lens implantation	173
5.1	Study of the incidence of posterior capsular opacification and Nd:YAG capsulotomy after implantation of multifocal Intraocular lens implantation	173
5.1.1	Introduction	173
5.1.2	Aims	174
5.1.3	Patients and methods.....	174
5.1.4	Results.....	176
5.1.5	Discussion	180
5.1.6	Limitations	181
5.1.7	Conclusion.....	182
5.2	Study of the effect of posterior capsular opacification on visual function in patients with monofocal and multifocal intraocular lenses	183
5.2.1	Introduction	183
5.2.2	Aim.....	183
5.2.3	Patients and method	184
5.2.4	Results	188
5.2.5	Discussion	195
5.2.6	Limitations	196

5.2.7	Conclusion.....	196
6	Summary and future directions	198
7	Publications and presentations generated from this thesis	204
7.1	Publications	204
7.2	Oral Presentations	205
7.3	Poster Presentations.....	205
8	References	206

LIST OF FIGURES

Figure 1-1. A schematic diagram of the steps of extracapsular cataract extraction. Partial-thickness corneal section (a & b) of about 10-mm chord; can-opener capsulotomy (c) or continuous curvilinear capsulorhexis (d) performed through a small incision; hydrodissection and nuclear maneuvering to separate it from the cortex (e); enlargement of the corneal section (f); nuclear delivery by pressing on the superior edge of the wound by a vectis and counter-pressing at the opposite limbal area by a hook (g); irrigation-aspiration of the cortical matter (h); insertion of the IOL in the sulcus or capsular bag (i); closure of the wound with 10/0 nylon (j) (Lawrence, 2000) (with permission from Saunders Company). 28

Figure 1-2. A schematic diagram of the steps of phacoemulsification. Designing the incision: uniplanar, biplanar or triplanar (a), continuous curvilinear capsulorhexis by shearing (b) or traction using forceps (c), hydrodissection (d), initial grooving of the nucleus (e), dividing the nucleus into halves (f), dividing the nucleus into quadrants and removal of each quadrant in sequence (g), chopping (an alternate way of dividing the nucleus) (h), irrigation-aspiration of the cortical lens matter (i), insertion of a foldable IOL implants (Azar & Rumelt, 2000) (with permission from Saunders Company). 31

Figure 1-3. Design of Diffractive IOL 35

Figure 1-4. Plate-haptic IOL (C11UB, Bausch & Lomb) 38

Figure 1-5. STAAR toric one-piece silicone IOL. The mark on the optic shows the axis of additional power. (http://www.stlukeseye.com/news/items/toric_lens.jpg) 38

Figure 1-6. SA40N AMO Array©: the five zonal progressive multifocal IOL in situ 40

Figure 1-7. Diagrammatic representation of the different zones of AMO array multifocal IOL (Courtesy of Advanced Medical Optics, Inc.). 40

Figure 1-8. Ray diagram of the refractive multifocal IOL (Courtesy of Advanced Medical Optics, Inc.). 41

Figure 1-9. Opacification of the anterior capsule (top left). Severe contraction of the anterior capsule (top, right). Closure of the capsular opening as a result of severe phimosis (bottom, left). PMMA IOL subluxation within a fibrotic capsular bag (bottom, left). 46

Figure 1-10. Clinical types of PCO: fibrotic type showing posterior capsule wrinkles (a) and grayish haze (b); and cellular type showing LEC pearls (c). 52

Figure 1-11. An example of the collateral damage in a silicone IOL (SI30NB; Advanced Medical Optic, Inc., AMO). It shows marks of laser strikes (pitting) and radial extensions of the marks presumably cuts (arrows) within the optic. 62

Figure 1-12. A schematic diagram of the twin-capsulorhexis and the IOL with the two perpendicularly orientated haptics (1 & 3). The side view shows the characteristic groove (2) that embraces the two capsular leaflets (Courtesy of Prof. Tassignon (Tassignon *et al*, 2002)) 65

Figure 1-13. A schematic diagram illustrating a comparison between the conventional in-the-bag IOL with the LECs covering the posterior capsule and the bag-in-the lens with the two flanges of the haptics embracing the capsular leaflets that in turn captures the LECs in between them. (Courtesy of Prof. Tassignon (Tassignon *et al*, 2002)) 65

Figure 2-1. Kaplan-Meier curves of the factors affecting the rate of Nd:YAG capsulotomy. An increased Nd:YAG capsulotomy rates is demonstrated in patients of 65 year or younger (a), in non-diabetic patients (b), in patients with plate-haptic silicone and PMMA implants compared to 3-piece silicone IOLs (c), in patients who developed postoperative inflammation (d) and in patients who underwent vitrectomy (e). 91

Figure 2-2. Anterior chamber flare (a) and cells (b) in the two groups of patients. Both flare and cells decreased significantly as the time went by, but there was only a borderline significant increase of flare in the Acrylic group in the early postoperative period. 107

Figure 2-3. The mask size (a) and the percentage of the area of opacified posterior capsule (b) in the two groups of patients. There was a decrease of the mask size in the plate-haptic silicone group and an increase in the area of PCO in the plate-haptic silicone IOL group. Only the latter was statistically significant. . 108

Figure 2-4. Visual acuity (a) and contrast sensitivity (b) in the two groups of patients. Although both function showed some deterioration over time, the differences were not statistically significant..... 109

Figure 2-5. An example of a patient with plate-haptic silicone IOL. The left panel show the contrast-enhanced images with the outlines of the masks and their sizes (in pixels). The right panel shows the software-processed images and the percentages of the area of PCO. MGO=the photo's ID 112

Figure 2-6 (A & B). Examples of patients with hydrophobic acrylic IOLs. The left panels show the contrast-enhanced images with the outline of the masks and their sizes (in pixels). The right panels show the software-processed images and the percentages of the area of PCO. They show relatively smaller increase in the area of PCO over the follow-up period (A) and even regression and reduction of the area of PCO that occurred in some cases (B). NCI & JHA=the Ids of the photos. 114

Figure 3-1. Optical coherence tomography: principle and components (Reproduced from Schmitt J. 1999 & Huang D. et al 1991) 118

Figure 3-2. Diagram showing the positions of the long scans across the pupillary area (interrupted lines) and short scans astride the pupillary margin (continuous lines)..... 122

Figure 3-3. An example of the video photographs and OCT scan images of a patient with a hydrophobic acrylic IOL. Top 2 panels: horizontal and vertical long scans, bottom 2 panels: short scans at 12 and 3 o'clock positions. Top panel OCT scan shows: pupillary margin (thin horizontal arrow), anterior capsule (thick horizontal arrows), anterior lens surface (thin vertical arrow), posterior lens surface (thick vertical arrow) and posterior capsule (curved arrow). 123

Figure 3-4. Video photograph and OCT scan of a patient with plate-haptic silicone IOL. Top 2 panels: vertical and horizontal long scans; bottom 2 panels: short scans at 6 and 9 o'clock positions. Top panel OCT scan shows: pupillary margin (thin horizontal arrow), anterior capsule (thick horizontal arrows), posterior lens surface (thin vertical arrow) and posterior capsule (thick vertical arrows)..... 124

Figure 3-5. Video photographs and OCT scan of two patients with hydrophobic acrylic IOLs within 2 days (top panel) and 9 months after surgery (bottom

panel). Note the clear delineation of the IOL outline. The OCT scans show the anterior capsular leaflet (thin vertical arrows), the haptic (thin horizontal arrows) and the posterior capsule (thick vertical arrow). The mid-peripheral part of the latter (thick horizontal arrows) is in close apposition to the optic..... 129

Figure 3-6. . Video photographs and OCT scans of two patients with plate-haptic silicone IOLs within 2days (top panel) and 14 months after surgery (bottom panel). The OCT scan shows that the implant surfaces are poorly delineated in both panels. The peripheral part of the optics are visible though (horizontal arrows) and there is absence of the close apposition pattern demonstrated in 3-a. Instead there is an optically empty space between the optic (horizontal arrows) and the posterior capsule (vertical arrows) 130

Figure 3-7. Video photographs and OCT scans of a patient with a hydrophobic acrylic IOL. It shows a close mid-peripheral apposition between the posterior capsule and the optic 2 days (top panel: thin arrows) and total apposition 4 weeks after surgery (Bottom panel: thick arrow)..... 133

Figure 3-8. Video photographs and OCT scan of 2 patients with plate-haptic IOLs 2 years after surgery. There is lack of apposition between the implant and the mid-peripheral part of the capsule (thin arrows). A high-reflectance material is present between the capsule and the posterior lens surface (vertical arrows)(presumably of LECs and extracellular substance) and an optically similar substance underneath the anterior capsular leaflet (thick arrows), corresponding to the anterior capsular fibrosis showing in the video photograph 134

Figure 3-9. A colour photograph and OCT scan of a patient with plate-haptic silicone IOL and PCO. The colour photograph shows abundant LECs forming Elshnig's pearls on the posterior capsule. The OCT scans shows better definition of the posterior surface of the optic (top panel: thin arrow), the central part of which became indiscernible after Nd:YAG capsulotomy (bottom panel: thick arrow), indicating that the reflections were predominantly from the posterior capsule rather than the optic of the implant 135

Figure 3-10. A diagram of the proposed appositional patterns that develop between hydrophobic acrylic and plate-haptic silicone implants, and the posterior

capsule. Once in the capsule bag, early close apposition of the edge of the hydrophobic acrylic IOL optic to the posterior capsule occurs due to the posterior vaulting that result from their larger overall diameter (13mm vs. 10 mm) and the angulation between the optic and the haptic (10°) that supposedly increases as the capsular bag contracts. The square edge and the acrylic material create a tighter adherence force between the capsule and the IOL optic. This close apposition with the posterior capsule helps prevent LEC migration (straight arrows), whereas the lack of similar apposition with the plate-haptic silicone IOLs allows early migration and proliferation of the LECs on the posterior capsule (curved arrows) 136

Figure 4-1. Kaplan Meier curves of Nd:YAG capsulotomy. It shows that increased rate was associated with age of 55 or younger (a) and decreased rate with the use of prophylactic steroids (b). In comparison with PMMA IOL, plate-haptic and 3-piece silicone had lower capsulotomy rates whereas Hydrogel had higher capsulotomy rate (c). Censored data are that of patients whose follow-up ended before they need Nd:YAG capsulotomy 151

Figure 4-2. Kaplan Meier curves of Nd:YAG capsulotomy. It shows no significant difference in the rate of Nd:YAG capsulotomy between non-uveitic and uveitic patients. Censored data are that of patients whose follow-up ended before they need Nd:YAG capsulotomy 155

Figure 4-3. Kaplan-Meier curve of Nd:YAG capsulotomy rate of phacoemulsification and ECCE groups..... 169

Figure 5-1. Kaplan-Meier survival curve of PCO (a) and Nd:YAG capsulotomy (b) over the follow-up period. It shows that the majority of cases occurred between 2 to 4 years after surgery 178

Figure 6-1. Summary of the incidences of Nd:YAG laser capsulotomy in non-diabetic/non-uveitic patients, diabetic and uveitic. The incidences increased gradually over the 4 years (including in those with multifocal IOL). A drop in the incidence occurs after the third year in both diabetic and uveitic patients. 200

LIST OF TABLES

Table 1-1. General physical properties of the currently available generic types of IOLs (Seward, 1997;Cunanan <i>et al</i> , 1998;Doan <i>et al</i> , 2002;Tehrani <i>et al</i> , 2004)	33
Table 1-2. Published incidence of Nd:YAG capsulotomy after ECCE and implantation of IOLs with different materials and designs and a follow-up of at least one year (modified and updated with permission from Linnola) (Linnola R., 2001).....	73
Table 1-3. Published incidence of Nd:YAG capsulotomy after phacoemulsification and implantation of IOLs with different materials and designs and a follow-up of at least one year (modified and updated with permission from Linnola) (Linnola R., 2001).	74
Table 2-1. Patient characteristics	84
Table 2-2. Incidences of Nd:YAG capsulotomy in diabetic and non-diabetic patients	85
Table 2-3. Multivariate Cox regression analysis of the factors associated with Nd:YAG Capsulotomy.....	87
Table 2-4. Multivariate Cox regression analysis of the factors associated with Nd:YAG capsulotomy in the two subgroups	88
Table 2-5. Clinical features of patients in the non-diabetic and diabetic groups	103
Table 2-6. Anterior chamber reaction and percentage of PCO at the different postoperative periods.....	105
Table 3-1. Patient characteristics	126
Table 4-1. Patient characteristics in the uveitis group	146
Table 4-2. Incidences of Nd:YAG capsulotomy in the uveitic group.....	148
Table 4-3. Cox regression analysis of the factors affecting the rate of Nd:YAG capsulotomy	149
Table 4-4. Patient characteristic in the Non-uveitic and Uveitic group	153

Table 4-5. The incidence of Nd:YAG capsulotomy in the non-uveitic and uveitic group.....	154
Table 4-6. Demographic features and prevalence of PCO after phacoemulsification in uveitis patients in recent studies of similar follow-up.....	157
Table 4-7. Comparison of the incidences of Nd:YAG capsulotomy in previous studies of non-uveitic and uveitic patients	158
Table 4-8. Demographic and clinical features of patients in the phacoemulsification and ECCE groups	162
Table 4-9. Incidences of Nd:YAG capsulotomy in phacoemulsification and ECCE groups.....	164
Table 4-10. Cox regression analysis of the factors affecting the rate of Nd:YAG capsulotomy	166
Table 5-1. Incidence of PCO and Nd:YAG capsulotomy.....	177
Table 5-2. Clinical features of patients who developed PCO and those who underwent Nd:YAG capsulotomy.....	179
Table 5-3. PCO grades	186
Table 5-4. The questionnaires administered before and after Nd:YAG capsulotomy	187
Table 5-5. Clinical features of patients in the two groups	189
Table 5-6. Visual function in the two groups of patients	190
Table 6-1. Risk factors for PCO/Nd:YAG capsulotomy identified in the different studies.....	202

ABBREVIATIONS

ACC	Anterior capsular contraction
ACO	Anterior capsular opacification
AMO	Advanced Medical Optics
BAB	Blood-aqueous barrier
CCC	Continuous curvilinear capsulorhexis
CMO	Cystoid macular oedema
ECCE	Extracapsular cataract extraction
EPCO	Evaluation of Posterior Capsule Opacification
FDA	Food and Drug Administration
HEMA	Hydroxyethylmethacrylate
HLA-B27	Human leukocyte antigen-B27
HPMC	Hydroxypropylmethylcellulose
IDDM	Insulin-dependent diabetes mellitus
IOL	Intraocular lens
IOP	Intraocular pressure
IQR	Interquartile range
LEC	Lens epithelial cell
logMAR	logarithm of the minimum angle of resolution
mm	millimeter
Nd:YAG	Neodymium:Yttrium-Aluminium-Garnet
NHS	National Health Service
NIDDM	Non-insulin-dependent diabetes mellitus
NPDR	Non-proliferative diabetic retinopathy
ns	Nanosecond
OCT	Optical coherence tomography

PDR	Proliferative diabetic retinopathy
PCCC	Posterior continuous curvilinear capsulorhexis
PCO	Posterior capsular opacification
PE	Phacoemulsification
PH	Plate haptic
PMMA	Polymethylmethacrylate
ps	Picosecond
SD	Standard deviation
TGF- β	Transforming growth factor β
WESDR	Wisconsin Epidemiologic Study of Diabetic Retinopathy

ACKNOWLEDGEMENT

My ultimate praise and gratitude is to Allah SWT for enabling me to finish this physically and mentally demanding work.

I was fortunate to have worked with and received help from several people to whom I will ever owe my sincere gratitude. First of all, I would like to thank my supervisor Professor Susan Lightman, Moorfields Eye Hospital, London, who has been a magnificent supervisor continuously motivating and encouraging me during the time I worked on this thesis. I learned tremendously from her comments and without her guidance, support and patience this work would have never been completed. I also would like to thank Mr. Jonathan Dowler, Consultant Ophthalmologist, Moorfields Eye Hospital, London, who taught me a great deal about research methods and statistics as well as about diabetes and diabetic retinopathy. He also helped me a great deal with the design, analysis and writing up of the diabetic studies. I also would like to thank Mr. Adrian Beckingsale, Consultant Ophthalmologist, Essex County Hospital, Colchester, who is one of the pioneers in using multifocal implants in the UK. He, in addition to teaching me all about these implants and their use, was an extremely supportive and inspiring mentor. I also would like to thank Miss Michelle Bradley, Department of Public Health and Primary Care, Cambridge University, for her help in reviewing the statistics of the diabetic, uveitis and multifocal intraocular lens studies. I also would like to thank Dr. Reijo Linnola, University of Oulu, Finland, Professor Tassignon, University Hospital Antwerp, Belgium, Karen Mills, Advanced Medical Optics (AMO), Dr Daniel Albert and Nicole McIntyre, Elsevier, and Tony Adams for the courtesy of the copyright permission. I also would like to thank my professors at Tanta Faculty of Medicine, Tanta University, Tanta, Egypt: Prof. Said Shalaby, Prof. Bothina Bondok and Prof. Samia El Ghobashi, for their support when I was applying to the University of Tanta for the scholarship grant, which was used to sponsor three projects of this thesis. I also would like to thank Alcon Inc. for providing the AcrySof lenses for the diabetic randomised trial and the limited grant for the patient transport expenses.

I also would like to thank the secretaries, nurses and the Medical Record staff at Moorfields Eye Hospital, London, and at Essex County Hospital, Colchester, for their help with the administrative work and patient recruitment.

Finally, my parents and all my family and my friends deserve my sincere and heartfelt gratitude and appreciation for their emotional support and for putting up with my extreme unsociability while working on this thesis.

CHAPTER 1

INTRODUCTION AND REVIEW OF THE LITERATURE

1 INTRODUCTION AND REVIEW OF THE LITERATURE

1.1 INTRODUCTION

1.1.1 Cataract surgery and posterior capsular opacification: perspective and aims of the thesis

Cataract, the leading cause of blindness all over the world, poses a significant challenge to the medical profession and health authorities. The increase in the population age and the modern enhancement of surgical techniques have led to lower threshold for surgical intervention and hence an increase in the cataract workload. Approximately 156,500 cataract operations were carried out under the National Health Service in England and Wales in 1995/6 (Minassian *et al*, 2000). This is now estimated to have risen to 270,000 in 2002/3, making it one of the most commonly performed elective procedures in the UK (Royal College of Ophthalmologists, 2004). Moreover, the number of cataract extraction procedures performed all over the world is predicted to increase under the auspices of Vision 2020 Global Initiative from the current annual rate of 8 millions to about 35 millions by 2020 (Taylor, 1999).

In diabetic and uveitic patients, cataract is more prevalent. In a review of two case-control studies, Harding *et al*, 1993 (Harding *et al*, 1993), found that diabetes was a highly significant risk factor for cataract development with a relative risk of 5.04. In the Wisconsin Epidemiological Study of Diabetic Retinopathy (WESDR) (Klein *et al*, 1984), cataract was the most common cause of decreased vision in older-onset and the second commonest cause after proliferative retinopathy in younger-onset diabetics. The relative scarcity of uveitis patients led to the lack of epidemiological data on the prevalence of cataract in them. However, the incidence has been estimated to be between 10%, in HLA-B27 negative patients (Power *et al*, 1998), and 77.8%, in Fuchs' heterochromic cyclitis patients (Velilla *et al*, 2001).

Posterior capsular opacification (PCO) remains the most common complication of modern extracapsular cataract extraction and intraocular lens (IOL) implantation. It impairs the visual function (Magno *et al*, 1997; Hayashi *et al*, 2003) and obstructs the

fundus view and, therefore, can interfere with early recognition and timely treatment of posterior segment diseases such as diabetic retinopathy in diabetic patients and macular oedema in diabetic and uveitic patients. In patients with multifocal IOLs, PCO can compromise visual function, in particular contrast sensitivity that is already compromised by the multifocal design of the implant optic.

Nd:YAG laser capsulotomy, the procedure of choice in treating patients with PCO, is a simple outpatient procedure that takes few minutes to perform and leads to significant improvement of visual function in the majority of patients (Magno *et al*, 1997; Hayashi *et al*, 2003). The procedure, however, is not without complications that include damage to the IOL, rise of intraocular pressure, anterior uveitis and potentially sight-threatening complications such as cystoid macular oedema and retinal breaks or detachment (Keates *et al*, 1984; Javitt *et al*, 1992; Johnson *et al*, 1984; Jahn *et al*, 2003; Ranta *et al*, 2004). Moreover, Nd:YAG capsulotomy incurs considerable costs and exhausts the resources of healthcare systems. In the United States, Nd:YAG capsulotomy is the second most commonly reimbursed procedure after cataract extraction and has been estimated to cost the Medicare program \$250 million a year (Steinberg *et al*, 1993). The prohibitive cost of laser machines limits the availability of Nd:YAG capsulotomy to patients in the developing countries.

PCO has been estimated to occur in up to a third of the patients in 5 years (Schaumberg *et al*, 1998). While several studies have investigated PCO development in non-diabetic and non-uveitis patients and after monofocal IOL implantation, information about the incidence and factors affecting PCO rate in diabetic and uveitic patients and after multifocal IOL implantation are either conflicting or lacking.

Recent PCO studies often relied on the quantitative measurement of the density or extent of PCO using several imaging techniques for reporting PCO development and its incidence. While invaluable for research purposes, these imaging techniques and the reported PCO rates very often merely reflected early postoperative LEC activities and do not necessarily reflect what might be a clinically significant PCO i.e. one that reduces visual function or visibility of the posterior segment and thus requires treatment. Lens epithelial cell growth onto the posterior capsule can be variable in the short-term (Findl *et al*, 2004) and even show regression on the long-term (Hollick *et al*, 1998; Meacock *et al*, 2001; Findl *et al*, 2004).

On the other hand, Nd:YAG capsulotomy, which has been used before as a surrogate measure of clinically significant PCO (Knorz *et al*, 1991; Apple *et al*, 2001; Baratz *et al*, 2001; Ando *et al*, 2003), is a perfectly acceptable surrogate measure of PCO if our goal is to reduce the additional clinical and financial burdens the procedure imposes on patients as well as on the already exhausted health care resources, in addition to improving the overall outcome of cataract surgery. Although, it has been contended that the indications for Nd:YAG capsulotomy can be subject to variations in patients' tolerance of PCO-induced symptoms and to clinician's threshold for intervention, these indications are generally uniform within the same unit and universally fall into either of two main categories: (1) to improve the visual function or eliminate other PCO-induced symptoms e.g. glare or double vision, or (2) to improve the fundus visualisation.

In this thesis, the main aims were:

1. To estimate the incidence of PCO, using Nd:YAG capsulotomy as a surrogate measure of clinically significant PCO, in diabetic and uveitic patients and after multifocal intraocular lens implantation.
2. To examine the factors influencing Nd:YAG capsulotomy rates in the three patient groups with emphasis on the effect of different IOLs in diabetic and uveitic patients and functional changes in patients with multifocal IOLs.

Estimating the incidence and identifying the factors influencing the development of PCO and the need for Nd:YAG capsulotomy will help in peri-operative counselling of patients as well as in developing strategies to reduce or even prevent the development of PCO and the need for Nd:YAG capsulotomy in the above patient groups. That should help to reduce the demands on the healthcare system resources and improve the overall outcome of cataract surgery.

1.1.2 Embryology, anatomy and histology of the lens and its capsule

Crystalline lens development (Saha *et al*, 1989;Henry & Grainger, 1990;Kuszak *et al*, 2000) begins at the first month of gestation from the surface ectoderm overlying the optic vesicle. The ectodermal cells thicken to form the lens placode, which subsequently invaginates and eventually separates forming the lens vesicle. The basement membrane of the epithelial cells, lying now on the exterior of the lens vesicle, forms the lens capsule. The cuboidal epithelium lining the posterior half of the vesicle then begins to elongate and extend anteriorly, forming the primary lens fibres and obliterating the cavity of the lens vesicle. The anterior cuboidal cells, known later as the lens epithelial cells (LECs), also proliferate at the equator, forming the secondary lens fibres.

The lens (Saxby, 1999) is located behind the iris and pupil, held in place by means of zonular fibres that attach it the ciliary body processes, with its anterior surface in contact with the aqueous humour and its posterior surface in contact with the vitreous. It has an asymmetric oblate spheroid shape and its equatorial axis lies perpendicular to the sagittal plane and its polar axis lies parallel to the sagittal plane. The anterior lens surface is 3.5mm behind the cornea. The dimensions of the lens increase steadily throughout life, with the highest rate occurring during the early years. The equatorial diameter is about 5mm at birth and steadily increases to reach 9 to 10mm at the age of 20 years. The central thickness is about 3.5 to 4mm at birth and can reach up to 4.75 to 5 mm.

The lens capsule (Saha *et al*, 1989;Henry & Grainger, 1990;Saxby, 1999;Kuszak *et al*, 2000) is a PAS-positive structure that is produced by the LECs. The anterior capsule is 14-21 μm while the posterior is 4 μm . The capsule increases in thickness until approximately 35 years of age when the equator and the posterior pole thin slightly while the anterior capsule remains stable (Kuszak, 1997;Kuszak *et al*, 2000). Immunohistochemical studies showed that the anterior capsule contains collagen types IV, V & VI, while the posterior capsule laminin and collagen type IV (Saika *et al*, 1998).

Two distinct types of LECs were described (Vargas *et al*, 2001;Kuszek *et al*, 2000). The first type is A-cells. These cells are located in the anterior central zone (corresponding to the zone of the anterior lens capsule) and have minimal mitotic activity. When disturbed, the primary type of response of A-cells is to proliferate in situ and form fibrous tissue by undergoing fibrous metaplasia (Font & Brownstein, 1974;Fagerholm, 1982). The anterior subcapsular plaques that form in a variety of disorders (e.g., inflammation, trauma or with certain types of posterior chamber or phakic IOLs) are typical examples of A-cell response. The second type is E-cells. These cells are the germinal cells located at the equator of the lens and normally contribute to the formation of the nucleus, epi-nucleus and cortex of the crystalline lens. They normally show mitotic activities, and continuously produce new lens fibres, accounting for a constant growth in size and weight of the lens throughout life. They are also rich in enzymes and have extensive protein metabolism. In pathological states, the E-cells tend to migrate posteriorly along the posterior capsule, forming large, balloon-like bladder cells (Wedl cells). E-cells are the primary source of classic secondary cataract, especially LEC pearls (Kappelhof *et al*, 1986;Fagerholm, 1982). They are also responsible for the formation of Soemmering's ring, an amalgam lesion composed of retained or regenerated cortex and LECs and is considered the basic prototype of classic PCO (Kappelhof *et al*, 1985).

The lens fibres (Kuszek, 1997;Saxby, 1999;Kuszek *et al*, 2000) form three distinct layers: the elongating fibres, the cortical fibres and the nuclear fibres. The elongating fibres consist of newly forming lens fibres that mature by losing their intracellular organelles, namely the nuclei, the Golgi apparatus and endoplasmic reticulum. The cortex is comprised of all mature secondary fibres. The nucleus consists also of mature secondary fibres but is divided according to developmental and growth criteria into: a) the embryonic nucleus consisting solely of primary lens fibres, b) the foetal nucleus consisting of the embryonic nucleus and all the added secondary fibres until parturition, d) the infantile nucleus consisting of the foetal nucleus and all the secondary fibres that are formed within the first 4 years of life, e) the juvenile nucleus consisting of the secondary fibres formed until sexual maturation and f) the adult nucleus, consisting of the juvenile nucleus and all the fibres added onto it until middle age.

1.1.3 Cataract extraction techniques

Couching is the first surgical procedure known to treat cataract surgically and is only of historic interest. Intracapsular cataract extraction is now obsolete. The most common techniques used nowadays for cataract extraction in adults are extracapsular cataract extraction (ECCE) and phacoemulsification, both are described below. The universal tendency is towards expanding the use of phacoemulsification as the primary technique of cataract extraction for the advantages that are discussed later (1.1.3.2.2). In the United States, phacoemulsification is now used in more than 90% of cataract surgeries (Masket *et al*, 2001; Leaming, 2002) and in the UK's 1997/8 National Cataract Survey (Desai *et al*, 1999), phacoemulsification was performed on 77% of cases in the National Health Service (NHS), with proportions between 10% and 99%.

1.1.3.1 Extracapsular cataract extraction (Figure 1-1)

The technique of ECCE is shown in Figure 1-1. It involves a corneal or corneoscleral incision of about 10-mm chord (between 2 and 10 o'clock at the superior limbus). This is followed by the injection of a viscoelastic substance in the anterior chamber and the performance of a can-opener capsulotomy. The nucleus is then hydrodissected, to separate it from the cortex, and delivered through the wound using a vectis to apply gentle pressure at the superior limbal area, and a hook to assist that by counter-pressing at the inferior limbal area. The cortical lens matter is then removed using either a manual or an automated irrigation-aspiration system. Filling the anterior chamber with a viscoelastic substance precedes the implantation of an IOL and closure of the wound with 10/0 nylon sutures after washing out of the excess viscoelastic substance, which concludes the procedure.

Several modifications have been made to the above technique. The most important of these was the 'endocapsular' or 'intercapsular cataract extraction'. In this technique, an incomplete capsulotomy is made by creating a semicircular flap of the anterior capsule. The nucleus and cortical matter are then removed as before, the IOL placed inside the capsular bag and the capsulotomy completed. The rest of the procedure is as above. The advantages were protection of corneal endothelial cells in addition to those advantages of in-the-bag placement of the IOL i.e. reduced incidence of IOL decentration and posterior synechiae (Naylor *et al*, 1989).

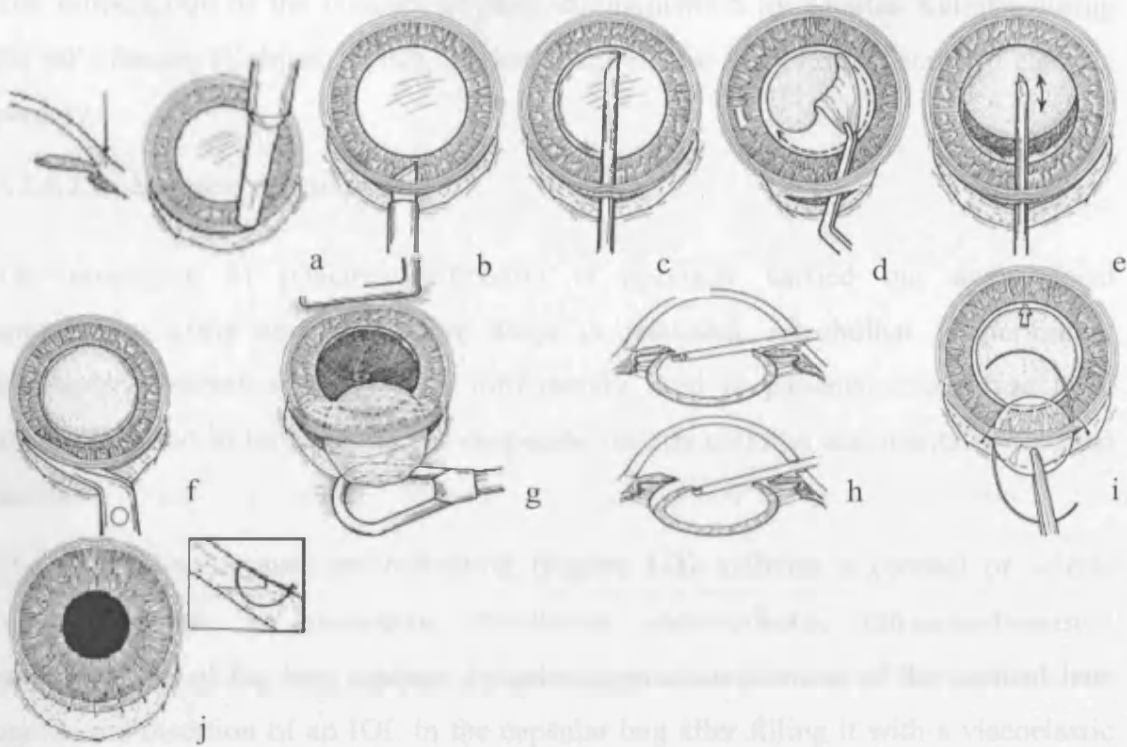


Figure 1-1. A schematic diagram of the steps of extracapsular cataract extraction. Partial-thickness corneal section (a & b) of about 10-mm chord; canopener capsulotomy (c) or continuous curvilinear capsulorhexis (d) performed through a small incision; hydrodissection and nuclear maneuvering to separate it from the cortex (e); enlargement of the corneal section (f); nuclear delivery by pressing on the superior edge of the wound by a vectis and counter-pressing at the opposite limbal area by a hook (g); irrigation-aspiration of the cortical matter (h); insertion of the IOL in the sulcus or capsular bag (i); closure of the wound with 10/0 nylon (j) (Lawrence, 2000) (with permission from Saunders Company).

1.1.3.2 Phacoemulsification cataract extraction (Figure 1-2)

The introduction of the concept of phacoemulsification by Charles Kelman during the 60's decade (Kelman, 1967), marked a significant evolutionary stage of cataract surgery.

1.1.3.2.1 Surgical technique

The procedure of phacoemulsification is normally carried out under local anaesthesia, using anaesthetic eye drops or subtenon, retrobulbar or peribulbar injections. General anaesthesia is infrequently used in patients who refuse local anaesthesia and in those unable to cooperate such as children and mentally disabled adults.

The technique of phacoemulsification (Figure 1-2) includes a corneal or scleral tunnel incision, a continuous curvilinear capsulorhexis, ultrasound-assisted emulsification of the lens nucleus, irrigation-aspiration removal of the cortical lens matter and insertion of an IOL in the capsular bag after filling it with a viscoelastic substance. The development of foldable intraocular lenses, , accompanied the increasing use of phacoemulsification and enabled the use of smaller incisions of 2.8 to 3.2mm.

1.1.3.2.2 Advantages of phacoemulsification

The technique of phacoemulsification has several advantages over ECCE. The smaller corneal incision used in phacoemulsification minimises postoperative surgically-induced astigmatism (el Maghraby *et al*, 1993;Zheng *et al*, 1997;Naus *et al*, 1995;Neumann *et al*, 1989). The tight seal of the small incision around the hand-piece allows better maintenance of the anterior chamber and intraocular pressure during the procedure and reduces the likelihood of vitreous prolapse in case of posterior capsular tear and suprachoroidal haemorrhage in predisposed patients. Also, phacoemulsification of the nucleus induces minimal trauma to the iris and results in less damage to the blood-aqueous barrier than after ECCE and hence less postoperative inflammation (Oshika *et al*, 1992). The latter contributes to reducing the incidence of postoperative cystoid macular oedema (Ursell *et al*, 1999;Mentes *et al*, 2003). These attributes have resulted in speedy postoperative functional recovery of the patients (Watson & Sunderraj, 1992;Naus *et al*, 1995). Also, when required,

posterior segment surgery such as vitrectomy or scleral buckling can be safely performed because of the small and more secure wound.

1.1.3.2.3 Disadvantages of phacoemulsification

Reliance on technology, the need for a longer period of training than with ECCE in addition to the excessive cost of the equipment and their maintenance are obvious disadvantages of phacoemulsification, with costs being the main limiting factor for its widespread use in the developing countries.

On balance, however, it is believed that the peri-operative complication rate during the learning period of phacoemulsification is comparable to that of ECCE (Seward *et al*, 1993; Thomas *et al*, 1997) and that overall the advantages outweigh the disadvantages.

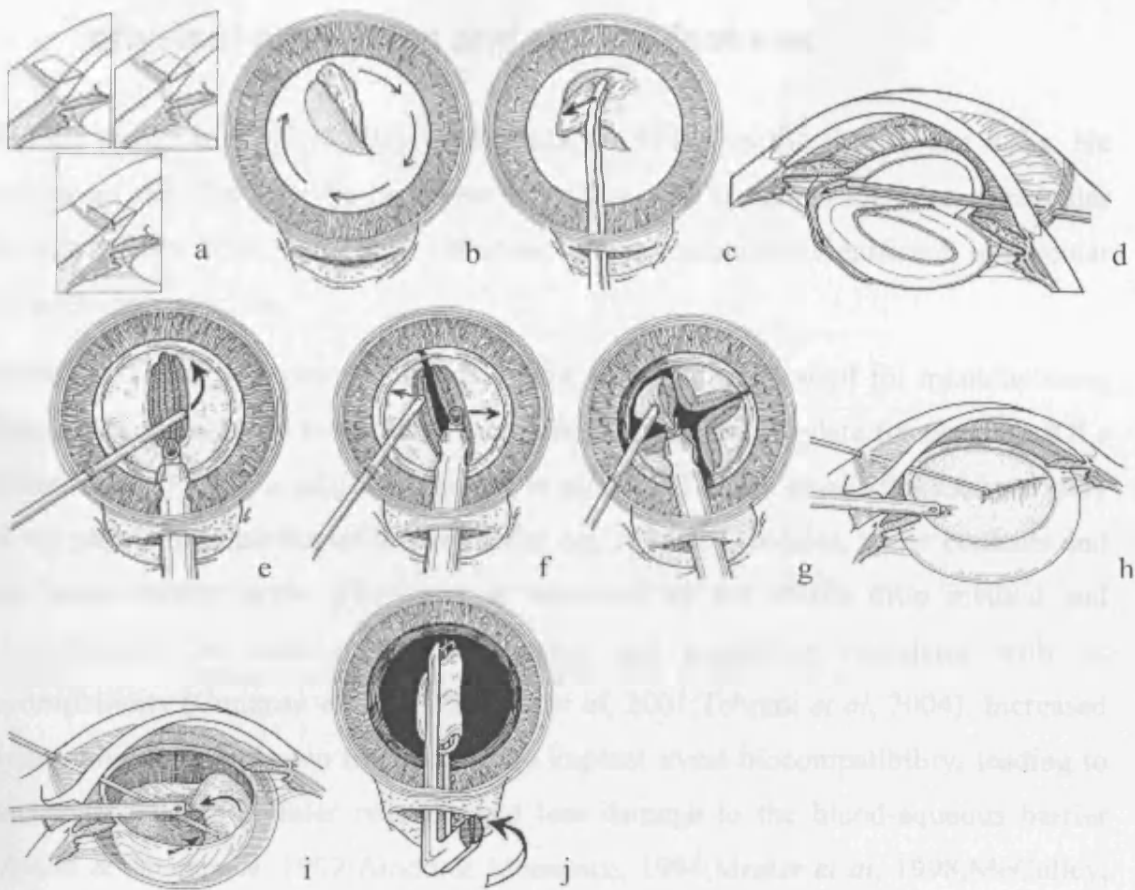


Figure 1-2. A schematic diagram of the steps of phacoemulsification. Designing the incision: uniplanar, biplanar or triplanar (a), continuous curvilinear capsulorhexis by shearing (b) or traction using forceps (c), hydrodissection (d), initial grooving of the nucleus (e), dividing the nucleus into halves (f), dividing the nucleus into quadrants and removal of each quadrant in sequence (g), chopping (an alternate way of dividing the nucleus) (h), irrigation-aspiration of the cortical lens matter (i), insertion of a foldable IOL implants (Azar & Rumelt, 2000) (with permission from Saunders Company).

1.1.4 Intraocular lenses used after cataract extraction: physical properties and clinical features

Harold Ridley in 1949 (Ridley, 1952;Ridley, 1954) was the first to use IOLs. He conceived the idea after he observed that pilots who sustained Plexglas intraocular foreign bodies from aeroplane canopies, did not manifest significant intraocular inflammatory reaction.

Table 1-1 shows the general features of the three materials used for manufacturing IOL optics, namely polymethylmethacrylate, silicone and acrylate (or acrylic). IOLs (Seward, 1997;Dick *et al*, 2001;Daynes *et al*, 2002;Tehrani *et al*, 2004) vary widely in the physical properties of their material e.g. refractive indices, water contents and the water-contact angle. The latter is measured by the sessile drop method and characterises the material surface tension and negatively correlates with its hydrophilicity (Cunanan *et al*, 1998;Dick *et al*, 2001;Tehrani *et al*, 2004). Increased hydrophilicity was shown to enhance the implant uveal biocompatibility, leading to decreased surface cellular reaction and less damage to the blood-aqueous barrier (Amon & Menapace, 1992;Amon & Menapace, 1994;Mester *et al*, 1998;McCulley, 2003). Increased IOL hydrophilicity, however, was also shown to increase LECs proliferation and PCO development i.e. reduced capsular biocompatibility (Hollick *et al*, 1999b;Mullner-Eidenbock *et al*, 2001;Abela-Formanek *et al*, 2002c;Abela-Formanek *et al*, 2002b). IOLs also vary in their overall diameter, the optic size and shape, the haptic shape, angulation and material. Functionally, IOLs are classified depending on whether their design allows for a single focus (monofocal) or multiple foci (multifocal) formation on the retina.

1.1.4.1 Polymethylmethacrylate (PMMA) IOLs

PMMA IOLs are still considered the reference to which other IOLs are compared. The main features of PMMA IOLs are detailed in Table 1-1. These lenses are rigid, inert, light and relatively inexpensive. They has <1% water content. Because of their rigidity, they are introduced through large incisions (usually >5mm), which often require suturing.

Table 1-1. General physical properties of the currently available generic types of IOLs (Seward, 1997; Cunanan *et al*, 1998; Doan *et al*, 2002; Tehrani *et al*, 2004)

	PMMA	Silicone	Hydrophobic Acrylic	Hydrophilic Acrylic (hydrogel)
Material	Polymethyl-methacrylate	Elastomer of polydimethylsiloxane	Copolymers of acrylate and methacrylate	Copolymer of methacrylate
Rigidity	Rigid	Foldable	Foldable	Foldable
Contact angle	68.1-75.5	106-119	87.6-72.7	59.2-69.1
Water contents	<1 %	<1 %	<2 %	18%-30%
Refractive index	1.49	1.41-1.47	1.44-1.55	1.47

PCO was found to occur at a higher rate with PMMA IOLs than with silicone and acrylic IOLs (Ursell *et al*, 1998;Hayashi *et al*, 1998c;Hollick *et al*, 1999c;Apple, 2000). Heaprin-coating of the PMMA IOL surface has led to reduced cellular reaction on their anterior surfaces (Amon *et al*, 1996) and less postoperative inflammatory reaction (Borgioli *et al*, 1992;Shah & Spalton, 1995a). Recently, 'snowflake opacification' of PMMA IOLs has been described by Apple *et al* (Apple *et al*, 2002). It was suggested to be due to direct destruction or molecular breakdown of the PMMA polymer by ultraviolet radiation and found to cause visual disturbance ranging from glare to severe blurring of vision.

1.1.4.1.1 Monofocal and diffractive multifocal PMMA IOLs (Figure 1-3)

Monofocal PMMA IOLs are the most commonly used type of PMMA implants. Diffractive multifocal PMMA IOLs (Davison, 2001) function by using the phenomenon of 'constructive and destructive interference'. As a result most of these implants are in effect bifocal. The lens has a spherical anterior surface and a grooved posterior surface (Figure 1-3) that splits the light and creates ripples of wave fronts 'interference patterns or fringes'. These wave fronts cross each other and create either 'constructive interference' if in-phase or 'destructive interference' if out-of-phase. Combining the spherical power of the anterior surface with the constructive or destructive interference patterns results in the formation of either a near or distance focus, respectively. Because the diffractive patterns are created throughout the optic of the implant, it is less dependent on the pupillary size than refractive IOLs (Discussed in 1.1.4.2.4). However, almost 18% of the incident light is lost because of interference. This is believed to explain the more profound reduction in contrast sensitivity that patients with these implants were shown to suffer from in comparison to patients with refractive implants (Pieh *et al*, 1998).

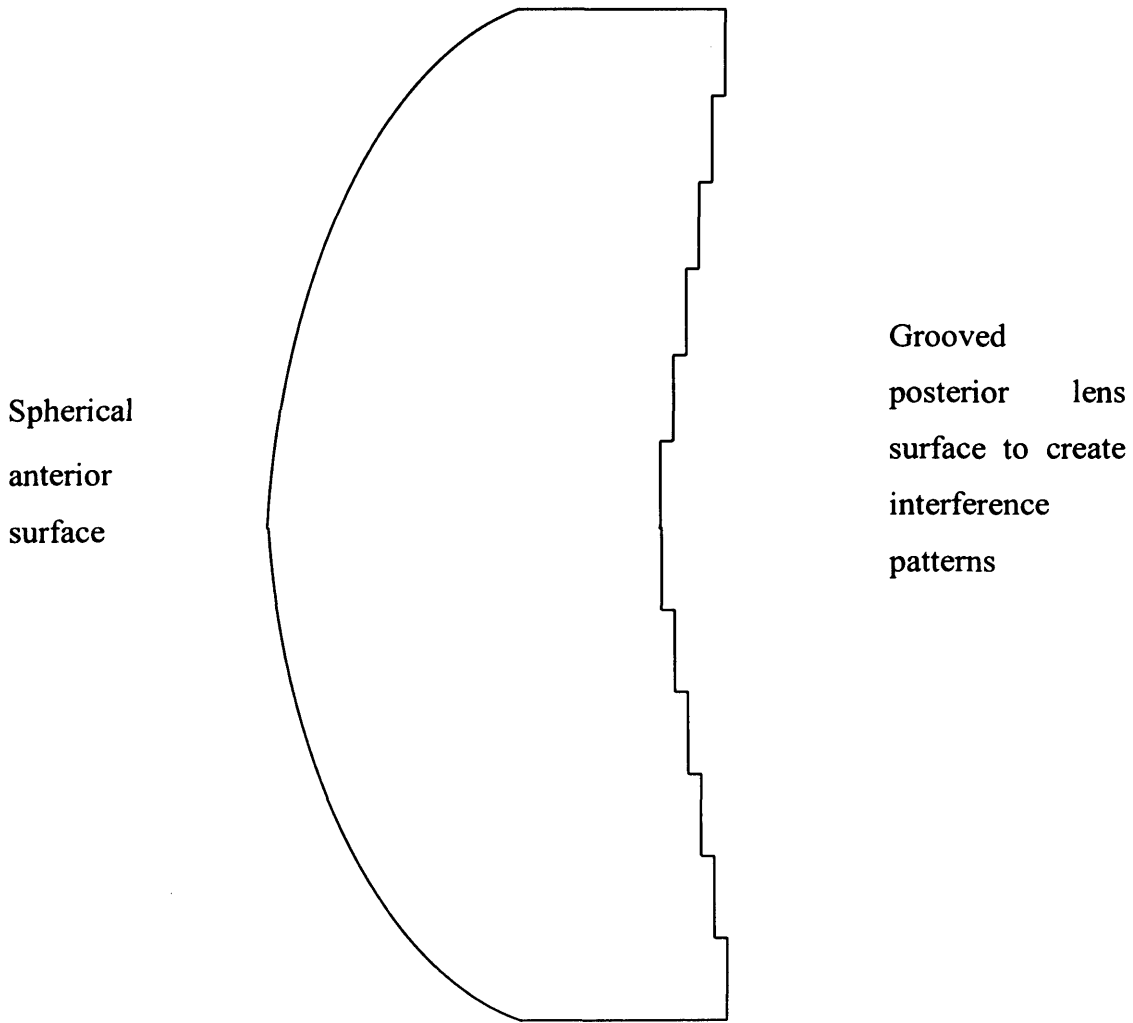


Figure 1-3. Design of Diffractive IOL

1.1.4.2 Silicone IOLs

The physical properties of the silicone IOLs are detailed in Table 1-1. These lenses were approved by the Food and Drug Administration (FDA) in 1990. The lenses are made of polymers of silicone and oxygen. The most common silicone IOLs are elastomers of polydiethylsiloxane backbone.

Silicone IOLs are inert, non-adherent to tissue and stable at a range of temperatures. They are also hydrophobic and difficult to handle when wet as they become slippery. The newer generation of silicone IOLs have higher refractive indices (1.46-1.47), and thus have thinner optics over a range of dioptric power, which enables implantation through a small wound size. One important feature of these lenses is their rapid unfolding action that can be hazardous especially in a patient with posterior capsular tear or zonular dialysis. After implantation, the rate of giant cell deposition was shown to be lower than with PMMA (Ravalico *et al*, 1997) and comparable to that with hydrophobic acrylic IOLs (Samuelson *et al*, 2000). The lenses also exhibit a lower threshold for Nd:YAG laser damage (Newland *et al*, 1999;Trinavarat *et al*, 2001) and were shown to adhere to silicone oil in patients who undergo vitrectomy and silicone oil tamponade (Apple *et al*, 1996;Dick *et al*, 1997;Apple *et al*, 1997). Senn, in an experimental study, showed that this could potentially affect its optical qualities (Senn *et al*, 1997). Recently case reports have been published of greyish to brownish opacification of some of these lenses including SI30NB (Parkin & Pitts-Crick, 2000), SI40NB (Hilgert *et al*, 2004;Tanaka *et al*, 2004b) and SA40N Array (Elgohary *et al*, 2005). The origin of this opacification is not clearly understood but was proposed to be the result of impurities, water incorporation into the IOL material or interaction with instruments or medications.

1.1.4.2.1 One-piece plate-haptic silicone IOLs (Figure 1-4)

These implants have a broad haptic and can be inserted through a small incision using an injector (Coombes *et al*, 2001). Hwang *et al* (Hwang *et al*, 1998) showed greater amount of decentration with 3-piece silicone IOLs than with plate-haptic silicone IOLs. Increasing the size of the positioning holes was suggested to have increased the stability of these implants in the capsular bag (Mamalis *et al*,

1996a; Kent *et al*, 1997; Whiteside *et al*, 1998) and several other studies have shown its favourable long-term outcome (Cumming, 1993; Maar *et al*, 2002).

The lenses, however, were shown to be associated with increased opacification and contraction of the anterior capsule (Werner *et al*, 2000b; Apple, 2000), which is attributed to the larger area of contact between the haptic and the anterior capsule and the hydrophobic nature of its material. The plate-haptic IOL design is also believed to be susceptible to forces of capsular contraction. There are reports of early decentration (Subramaniam & Tuft, 2001; Mackool, 1996), late subluxation and even posterior dislocation of the lens, either spontaneously (Agustin & Miller, 2000) or after Nd:YAG capsulotomy (Tuft & Talks, 1998; Petersen *et al*, 2000). Faucher and Rootman (Faucher & Rootman, 2001) reported anterior dislocation of the lens into the anterior chamber 4 months after an uneventful surgery.

1.1.4.2.2 Toric one-piece plate-haptic silicone IOLs

These lenses have a spherocylindrical anterior surface that is designed to correct corneal astigmatism of 1.5 to 3.5 dioptres. This is achieved by aligning the axis markings of the implant to the steep corneal meridian.

Although the lenses were found to effectively and stably correct the astigmatism in the majority of patients (Ruhswurm *et al*, 2000; Leyland *et al*, 2001), they are susceptible to the same postoperative positional changes as their spherical counterparts, namely decentration or dislocation, which can have a more dramatic effect on the visual function. Leyland *et al* (Leyland *et al*, 2001) reported 9% of the lenses undergoing rotation of more than 30 degrees both in the early and late postoperative periods.

1.1.4.2.3. Three-piece silicone IOLs

These are the most commonly used type of silicone IOLs. All the lenses have beveled edges except that of the STAAR Array IOL (Atlanta, GA, USA) and the C11UB IOL (Bausch & Lomb, Tampa, FL, USA) which have square edges. The first generation of the three-piece silicone IOLs and higher than 2140, a second generation of hydrophobic acrylic IOLs and square-edged silicone IOLs. Development similar to the STAAR Array IOL (Erlentz *et al.*, 2000; Schuck *et al.*, 2000; Schuck & Grawmeyer, 2000). M... found that



Figure 1-4. Plate-haptic IOL (C11UB, Bausch & Lomb)

(From: Foldable Lens Range: European Edition, Bausch & Lomb product manual)

1.1.4.2.4. Multifocal silicone IOL (Refraction up) (Figure 1-5)

The silicone multifocal accommodative lens... enabling focusing and... STAAR Array (AMOR) IOL... this design are: the...



Figure 1-5. STAAR toric one-piece silicone IOL. The mark on the optic shows the axis of additional power.

(http://www.stlukeseye.com/news/items/toric_lens.jpg)

The Array IOL: It... 3-piece silicone IOL... and two PMMA... has 5 concentric... of the optic... distance-dependent, as are the third and fifth zones. The second and fourth zones are near-constant, each with 3.5 dioptres and 1.75 D, for each of the distance-dependent zones, the distance power is fixed centrally and power gradually increases toward the periphery of the zone (2000-progressive) to provide intermediate vision

1.1.4.2.3 Three-piece silicone IOLs

These are the most commonly used type of silicone IOLs. All the lenses have rounded edges except that of CeeOn-Edge 911 (Pharmacia Atlanta, GA, USA) and Clariflex (AMO, Irvine, CA, USA), which have sharp posterior edges.

The first generation of these lenses had a PCO rate similar to that associated with PMMA IOLs and higher than that with hydrophobic acrylic IOLs. That has improved remarkably with the second generation of implants. Daynes et al, 2002, found that SI40, a second generation 3-piece silicone IOL, had a PCO rate similar to hydrophobic acrylic IOLs (Daynes *et al*, 2002). Several studies also found that square-edged silicone IOLs had a preventative effect on LEC migration and PCO development similar to that of hydrophobic acrylic IOLs (Nishi *et al*, 2000; Schmack & Gerstmeyer, 2000). Mullner-Eidenbock et al (Mullner-Eidenbock *et al*, 2001) found that CeeOn Edge IOL had a low incidence of LEC growth and reduced non-specific foreign-body reactions in comparison to hydrophilic and hydrophobic acrylic IOLs.

1.1.4.2.4 Multifocal silicone IOL (Refractive type) (Figure 1-6)

The silicone multifocal design was developed in order to help patients overcome the accommodative loss associated with pseudophakia while enabling folding and implanting the IOL through a small incision. SA40N AMO Array (AMO) IOL (Figure 1-6) will be discussed in detail as it is the one studied in this thesis and is the most commonly used refractive multifocal implant.

1.1.4.2.4.1 Design and optics (Figures 1-6 to 1-8)

The Array IOL (Featherstone *et al*, 1999; Davison, 2001) is a 3-piece silicone IOL that has an overall diameter of 13mm, an optic diameter of 6mm and two PMMA haptics that make an angle of 10° with the optic. The optic has a biconvex surface, a spherical refractive posterior surface and an anterior surface that has 5 concentric refractive zones that give it a wavy-shape (Figure 1-6). The central zone of the optic is distance-dominant, as are the third and fifth zones. The second and fourth zones are near-dominant, each with 3.5 dioptres add (Figure 1-7). In each of the distance-dominant zones, the distance power is placed centrally and power gradually increases toward the periphery of the zone (zonal-progressive) to provide intermediate vision

(Figure 1-8). The concentric zones are meant to make the IOL less sensitive to variation in pupil size and to provide stable vision under a variety of luminance conditions. At a pupillary size of 4mm, approximately 50% of available light is allocated to the distance focus, 37% to the near focus and 13% to the intermediate focus.




Figure 1-6. SA40N AMO Array©: the five zonal progressive multifocal IOL in situ



Figure 1-7. Diagrammatic representation of the different zones of AMO array multifocal IOL (Courtesy of Advanced Medical Optics, Inc.).




Figure 1-8. Ray diagram of the refractive multifocal IOL (Courtesy of Advanced Medical Optics, Inc.).

1.1.4.2.4.2 Functional outcome

Multifocal intraocular lenses have proved to provide reasonably useful near and intermediate vision without spectacles and without adversely affecting distance vision (Brydon *et al*, 2000;Javitt *et al*, 2000;Steinert, 2000;Vaquero-Ruano *et al*, 1998;Leyland *et al*, 2002). These implants, however, are known to reduce contrast sensitivity, especially under low contrast (Steinert *et al*, 1999;Schmitz *et al*, 2000) and mesopic conditions (Williamson *et al*, 1994). They also cause dysphotopic phenomena such as glare and haloes with bright light (Steinert *et al*, 1999).

Increasing age, variation of pupil size and the degree of corneal astigmatism were found to affect the degree of contrast sensitivity loss as well as patients' satisfaction with these lenses. Schmitz *et al*, 2000 (Schmitz *et al*, 2000), found that, with and without glare disability, patients over 70 years have reduced contrast sensitivity. In a study by Hayashi *et al* (Hayashi *et al*, 2001), a pupil size of less than 4.5mm was found to reduce near vision ability. Using an experimental optical model consisting of a helium-neon laser, a triangular optical bench with a precision collimator, a micropositionable immersion stage to support the IOL and a digital image-processing system, Ravalico *et al* (Ravalico *et al*, 1999) found that correcting astigmatism of more than 1 dioptre reduces light intensity by about 20%. Also, Hayashi *et al* (Hayashi *et al*, 2000) found that up to 1.5 dioptres, astigmatism reduced distance and

intermediate vision but that all degrees of astigmatism up to 2.5 dioptres favoured near vision. On the other hand, Schmitz et al (Schmitz *et al*, 2000) found that there was no clinically significant difference between monofocal and multifocal IOL groups with and without > 1 dioptre of astigmatism.

1.1.4.3 Hydrophobic acrylic IOLs

Hydrophobic acrylic IOLs are relatively new lenses, with FDA approval obtained only in December 1994. Three-piece with PMMA haptics or one-piece design are available and in common use. These lenses are made of copolymers of acrylate and methacrylate. They have a contact angle of 73° and are thinner, because of their higher refractive index, and lighter than silicone IOLs (Table 1-1). They have lower elasticity and increased stiffness and thus require larger incisions to be introduced into the eye. The implant feels like PMMA at low temperature and it needs to be warmed to facilitate its folding. These features, however, make its unfolding in the capsular bag slower and more controlled but also make it fragile and more liable to scratches and dents.

Hydrophobic acrylic IOLs are less likely to cause problems of adherence when silicone oil tamponade is used than silicone IOLs (Apple *et al*, 1997). The square-edged design of some of these implants creates a capsular bend preventing migration of LECs onto the posterior capsule and PCO formation (Nishi *et al*, 1998c; Nishi & Nishi, 1999; Nishi *et al*, 2000). The square edge, however, causes internal reflection of the incident light leading to positive dysphotopic complaints such as glare, streaks or flashes of lights; or negative dysphotopic symptoms such as dark shadows (Farbowitz *et al*, 2000; Davison, 2000). New implant designs with a frosted edge (SA60, Alcon) or rounded anterior edge (Sensar, Allergan) have been developed to minimise these symptoms. These lenses are also more resistant to damage by Nd:YAG laser than PMMA and silicone IOLs (Newland *et al*, 1999; Trinavarat *et al*, 2001).

Several reports have shown the development of 'glistenings' within hydrophobic acrylic (Alcon) IOLs (Gunenc *et al*, 2001; Christiansen *et al*, 2001; Tognetto *et al*, 2002). These were proved to be water vacuoles and the phenomenon was related to a change in the equilibrium of water content caused by temperature changes (Miyata & Yaguchi, 2004; Shiba *et al*, 2003; Tognetto *et al*, 2002). Recent reports have shown no

effect (Gunenc *et al*, 2001) or only a mild effect (Christiansen *et al*, 2001) on visual acuity in cases with severe 'glistenings'.

1.1.4.4 Hydrophilic acrylic (hydrogel) IOLs

Hydrophilic acrylic (hydrogel) IOLs are composed of a mixture of a hydroxyethylmethacrylate (poly-HEMA) backbone and a hydrophilic acrylic monomer. The water content varies between 18-30%. Because of their water content, they must be kept hydrated until implantation. The lenses are soft and resist scratches and surface damage from folding because of their high water content and flexible surfaces. They fold and unfold faster than hydrophobic acrylic but still are more controllable than silicone IOLs. They are also resistant to damage by Nd:YAG laser and have minimal adherence to silicone oil.

Several studies reported an excellent uveal biocompatibility profile for these implants i.e. less flare in the early postoperative period and a low incidence of non-specific foreign body reaction, i.e. less deposition of small and giant cells on its surface, than with silicone and hydrophobic acrylic IOLs (Schauersberger *et al*, 1999; Hollick *et al*, 1999b; Mullner-Eidenbock *et al*, 2001; Abela-Formanek *et al*, 2002c). However, the lens was found to be associated with a high rate of LEC proliferation and high PCO and Nd:YAG capsulotomy rates i.e. it has a low capsular biocompatibility (Hollick *et al*, 1999b; Abela-Formanek *et al*, 2002c; Abela-Formanek *et al*, 2002d; McCulley, 2003).

MemoryLens (Ciba Vision) is a pre-rolled 3-piece implant hydrophilic acrylic implant. It slowly unfolds within the eye in a controlled fashion. This lens was reported to be associated with a late-onset of toxic anterior segment syndrome (Jehan *et al*, 2000), which was attributed by the manufacturer to residual polishing compounds in the lens.

Hydroview (Bausch & Lomb) is a three-piece IOL that lens has been reported to develop late opacification due to calcium phosphate deposition within the optic (Werner *et al*, 2000a), a phenomenon which is still under investigation. These proved to be visually significant and required IOL explantation in many patients (Fernando & Crayford, 2000; Mamalis *et al*, 2004). The origin of this phenomenon was blamed on the silicone packaging of the IOL (Dorey *et al*, 2003).

1.1.5 Anterior segment changes after cataract extraction

1.1.5.1 Breakdown of the blood-aqueous barrier

Surgical trauma, the presence of an IOL, which attracts a foreign body reaction, and the release of inflammatory mediators synthesized by LECs are the main factors responsible for the breakdown of the blood-aqueous barrier (BAB) after cataract extraction (Miyake *et al*, 1996;Nishi *et al*, 1995b;Nishi *et al*, 1996c). This is mediated by prostaglandin E₂ and various other cytokines, such as interleukin-1 and interleukin-6 that can be produced by LECs. Clinically this gives rise to flare (protein) and cells in the anterior chamber, which can be quantified by laser flare-cell photometry (Shah & Spalton, 1994).

Several factors seem to affect the degree of breakdown of the BAB and hence the anterior chamber flare value or cell count. Increased BAB breakdown was found to be associated with larger corneal incisions such as those used for ECCE as compared to small incisions used in phacoemulsification (Oshika *et al*, 1992;Pande *et al*, 1996b;Chee *et al*, 1999), sclero-corneal as compared to pure corneal incisions (Dick *et al*, 2000), sulcus as compared to in-the-bag placement of the IOL (Alio *et al*, 1997), torn capsulorhexis as compared to intact ones (Pande *et al*, 1996a) and hydrophobic as compared to hydrophilic IOLs (Miyake *et al*, 1996;Schauersberger *et al*, 1999).

1.1.5.2 Cellular reaction on IOL surface

Immunohistochemical staining has been used to study the cellular deposits on the surface of IOLs (Saika *et al*, 1998). Specular microscopy, using high magnification and intense illumination on the slit lamp, enables us to clinically identify these cellular elements in vivo (Wenzel M *et al*, 1988;Shah *et al*, 1993;Shah & Spalton, 1995b). These include blood-derived monocytes, which give rise to histiocytes and its different forms including macrophages, spindle-shaped or fibroblast-like cells, epitheloid and giant cells (Wolter & Kunkel, 1983a;Wolter, 1985;Wolter & Kleberger, 1985), capsule-derived LECs (Wolter, 1993;Ibaraki *et al*, 1995;Saika *et al*, 1998;Hollick *et al*, 1999b) and iris-derived melanocytes (Tanner *et al*, 1998).

These cellular deposits can produce a clear membrane on the IOL composed of a film of extracellular matrix (Wolter & Kunkel, 1983c;Wolter *et al*, 1985;Saika *et al*,

1998). Experimental and postmortem studies have shown this membrane to be produced in the early postoperative period (within few hours to few days) (Wolter & Kunkel, 1983b; Wolter & Kleberger, 1985). They also showed that it contained proteins such as fibronectin (Kanagawa *et al*, 1990; Saika *et al*, 1992; Saika *et al*, 1995), collagen types I, III and IV (Saika *et al*, 1995; Saika *et al*, 1997), vitronectin and laminin (Linnola *et al*, 1999b; Linnola *et al*, 2000a; Linnola *et al*, 2000b).

The IOL material has an effect on the number of cells attached to the IOL surface. Fewer epitheloid and giant cells were found attached to hydrophilic IOLs: HSM-PMMA in comparison to PMMA IOLs (Larsson *et al*, 1989; Amon *et al*, 1996; Fagerholm *et al*, 1989; Shah & Spalton, 1995a), and hydrophilic acrylic (Hydroview) in comparison to hydrophobic acrylic (AcrySof) and silicone IOLs (CeeOn 920) (Mullner-Eidenbock *et al*, 2001).

1.1.6 Changes in the capsular bag

The changes in the capsular bag after IOL implantation are the most important changes as they lead to more lasting and clinically significant effects.

1.1.6.1.1 Anterior capsular opacification and contraction (Figure 1-9)

Anterior capsular opacification (ACO) is probably the earliest and most common pathological development in the capsular bag. It may occur as soon as one month and variably in almost all the patients. A clinically more important change is anterior capsular contraction (ACC) or phimosis, which is usually associated with and often consequential upon ACO. Davison (Davison, 1993) suggested that ACC occurs as a result of an imbalance between centrifugal and centripetal forces of the contracting fibrous tissue on the capsular bag. ACC was shown to occur maximally within the first 3 months after surgery (Hayashi *et al*, 1997; Zambarakji *et al*, 1997) and, on average, amounts to about 22% of the original CCC size (Sugimoto *et al*, 1998). Both ACO and ACC have common pathological features and have similar predisposing factors.

1.1.1.1.1 Pathology of ACO and ACC

The pathological changes leading to the development of ACO occur mainly underneath the capsule. Macky *et al.* (Macky *et al.*, 2001) indicated that a more

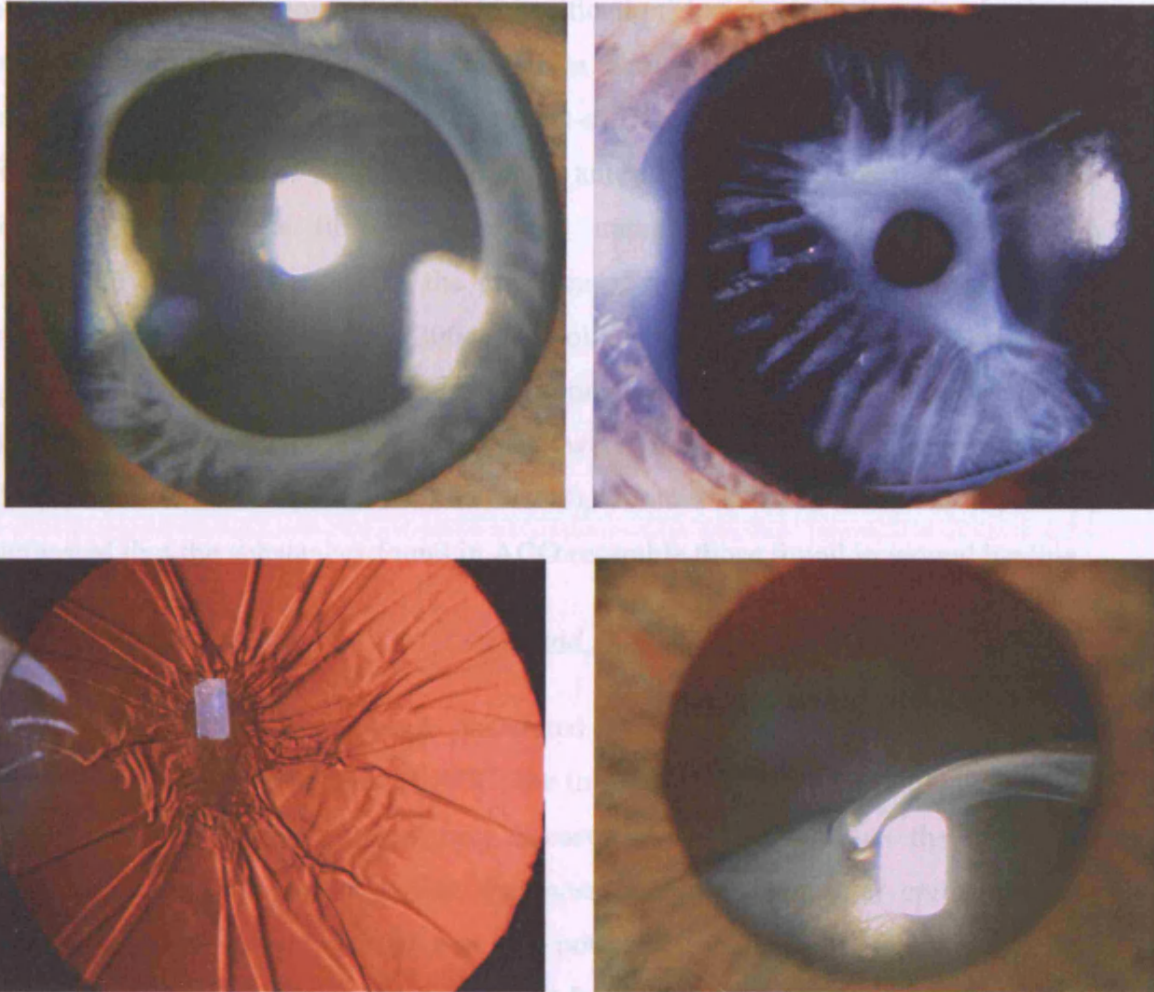


Figure 1-9. Opacification of the anterior capsule (top left). Severe contraction of the anterior capsule (top, right). Closure of the capsular opening as a result of severe phimosis (bottom, left). PMMA IOL subluxation within a fibrotic capsular bag (bottom, left).

1.1.6.1.1.1 Pathology of ACO and ACC

The pathological changes leading to the development of ACO occur mainly underneath the capsule. Macky et al (Macky *et al*, 2001) indicated that a more accurate term is 'anterior subcapsular opacification' but the term is maintained as it is well established in the literature and in clinical practice. These pathological changes include LEC proliferation and trans-differentiation, and extracellular matrix formation (Ishibashi *et al*, 1993). Human anterior capsule fibrosis samples were found to have dense fibrous tissue and numerous activated fibroblasts with contractile capacity, because of the presence of α -smooth muscle actin in the cell cytoplasm (Tanaka *et al*, 2004a). Collagen, fibronectin, osteopontin and glycosaminoglycans such as chondroitin, keratan, and dermatan sulphate, are among the extracellular matrix substances that were found in histological specimens (Ishibashi *et al*, 1993; Azuma *et al*, 1998). Azuma et al (Azuma *et al*, 1998) suggested that the substances found in ACO resemble those found in wound healing.

1.1.6.1.1.2 Factors associated with ACO and ACC and clinical features

Three major factors have been postulated to affect the degree of ACO and consequently the development of ACC: the initial size of the capsulorhexis, the IOL material and design and pre-existing diseases. It is proposed that the larger the remaining anterior capsular leaflet, the more anterior subcapsular epithelial cells there are and, therefore, the greater the potential for capsular opacification and contraction (Davison, 1993; Arshinoff, 1994; Packard, 1998). Miyake et al (Miyake *et al*, 1996) found a negative correlation between the hydrophilicity of an IOL and the severity of postoperative inflammation and the speed of ACO, with hydrophobic silicone of 99° water contact angle having greater postoperative inflammation and anterior capsular opacification. On the other hand, Werner et al (Werner *et al*, 2001) found that 3-piece, hydrophobic acrylic optic, PMMA-haptic IOLs (AcrySof) had a lower ACO score than small- and large-hole, single-piece, plate-haptic silicone IOLs. This was also confirmed in several other histopathological studies (Apple, 2000; Werner *et al*, 2000b; Werner *et al*, 2001; Werner *et al*, 2000b) that showed plate-haptic silicone IOLs to be associated with a higher rate of ACO than PMMA and acrylic IOLs.

The amount of ACC was shown to be significantly greater with silicone than with PMMA IOLs (Zambarakji *et al*, 1997;Cochener *et al*, 1999;Hayashi *et al*, 1997) and acrylic IOLs (Ursell *et al*, 1997). The haptic material (polypropylene versus polymethylmethacrylate in two otherwise similar silicone IOLs) did not affect the amount of ACC (Gallagher & Pavilack, 1999). Dahlhauser *et al* (Dahlhauser *et al*, 1998) reported that 14% of patients who had plate-haptic silicone IOLs developed clinically significant ACC and needed Nd:YAG anterior capsulotomy. Other factors found to be associated with increased ACC are increased anterior chamber flare, older age (Sugimoto *et al*, 1998;Kato *et al*, 2002), smaller capsulorhexis (Sugimoto *et al*, 1998), diabetes mellitus and the presence of diabetic retinopathy (Hayashi *et al*, 1998b;Kato *et al*, 2001). The risk of anterior capsular contraction was found to be greater in eyes with zonular weakness such as those with pseudoexfoliation syndrome (Davison, 1993;Gallagher & Pavilack, 1999;Moreno-Montanes *et al*, 2002). Also, patients with retinitis pigmentosa (Nishi & Nishi, 1993;Jackson *et al*, 2001;Lee *et al*, 2004), uveitis (Davison, 1993), and myotonic dystrophy (Newman, 1998;Hansen *et al*, 1993) were found to have a greater tendency to develop ACC.

1.1.6.1.1.3 Treatment

Polishing the anterior capsule to remove the subcapsular lens epithelium is a useful technique to reduce the incidence of ACO (Davison, 1993;Nishi, 1987), using large CCC (>5.5mm diameter) and implantation of large PMMA IOLs or intracapsular PMMA rings should be considered in high risk patients (Spang *et al*, 1999;Hayashi *et al*, 1998a).

As soon as ACC is noted in high-risk patients or those who have already had ACC-related problems in the other eye, relaxing radial anterior capsular incisions can be performed using Nd:YAG laser (Davison, 1993;Scorolli *et al*, 1996;Chawla & Shaikh, 1999). These incisions will help to reduce traction on the equator of the capsular bag and hence pre-empt the development of complications such as lens decentration, subluxation and dislocation. Surgical anterior capsulotomy may be required in patients with severe degrees of ACC that can not be treated with laser (Yeh *et al*, 2002).

1.1.6.1.2 Posterior capsular opacification (PCO)

1.1.6.1.2.1 Pathology of PCO

Schmidbauer et al (Schmidbauer *et al*, 2001b) and Aslam et al, 2003 (Aslam *et al*, 2003b), pointed out that the term ‘posterior capsular opacification’ is a misnomer as the changes are sub-capsular. However, similar to ‘anterior capsular opacification’, the term is maintained because it is commonly accepted and widely used.

1.1.6.1.2.1.1 Methods of studying PCO development

Several methods have been used to study PCO (Wormstone, 2002). These include cell culture, in vivo animal studies, capsular bag models, in vivo clinical studies and analysis of post-mortem material. Cell culture studies have provided information on certain aspects of LECs such as factors affecting their growth. Capsular bag cultures and in vivo animal studies have been used to establish the effect of surgical techniques and IOLs design and material on the development of PCO. Different posterior capsule imaging and image analysis systems have enabled in vivo monitoring of PCO development and progression. Post-mortem examination, using electron microscopy, immunohistochemistry and ELISA techniques has provided information about the different molecules that exist in the capsular bag and the possible effect they have on PCO development and progression.

1.1.6.1.2.1.2 Anatomical considerations

As discussed before (in 1.1.2), there are two anatomical classes of LECs: A-cells and E-cells. While A and E-cells are capable of contributing to all forms of capsular opacification, A-cells are primarily responsible for the development of anterior capsular opacification and the fibrotic changes of PCO and E-cells for the cellular element of PCO and inter-lenticular opacification in patients with piggyback IOLs (Schmidbauer *et al*, 2001b).

E-cell proliferation and migration onto the posterior capsule lead to the formation of large, balloon-like bladder cells (Wedl cells) or Elshnig’s pearls. Metaplastic transformation (transdifferentiation) of LECs into spindle-shaped or myofibroblast-like cells and residual lens fibres lead to fibrotic changes, including greyish

discolouration and wrinkling of the posterior capsule, and Sommering's ring formation at the equator.

1.1.6.1.2.1.3 Pathogenesis of PCO

McDonnell et al (McDonnell *et al*, 1983;McDonnell *et al*, 1984;McDonnell *et al*, 1985;Green & McDonnell, 1985) have shown that LECs in both rabbits and humans initially undergo hyperplasia and transdifferentiation into myofibroblast-like cells within 4 days of surgery. The proliferation of LECs has been shown to be under control of paracrine and autocrine pathways (Wormstone *et al*, 2002). Paracrine control is related to increased aqueous protein content, including serum growth factors, induced by the breakdown of the BAB and the inflammatory response to surgery (Wallentin *et al*, 1998;Pande *et al*, 1996b). These were shown to increase LEC proliferation and collagen formation (Nishi *et al*, 1996a). The autocrine mechanism is conceivable in patients who develop PCO several years after surgery when the aqueous protein levels would have subsided to preoperative levels. This is evidenced by the ability of LECs to survive under minimal cultural conditions and to produce de novo proteins (Wormstone *et al*, 1997;Wormstone *et al*, 2001).

Both the autocrine and paracrine mechanisms were found to be influenced by several cytokines. Nishi O et al (Nishi *et al*, 1996a) found that cytokines such as interleukin (IL)1 and basic fibroblast growth factor (b-FGF) increased LECs mitosis and collagen synthesis. Wallentin et al (Wallentin *et al*, 1998) found that LEC proliferation positively correlated with protein concentration and with leukocyte count but negatively with TGF- β concentration. The latter finding was consistent with the findings by Kurosaka et al (Kurosaka & Nagamoto, 1994;Kurosaka *et al*, 1995).

Myofibroblastic transdifferentiation of LECs leads clinically to the formation of wrinkles and contraction of the capsule. Kurosaka et al (Kurosaka *et al*, 1996) showed the presence of alpha smooth muscle actin in LECs after experimental cataract extraction. They also showed that adding TGF- β 2 to a culture of LECs on a collagen gel increased the shrinkage of the collagen gel as well as the expression of alpha smooth muscle actin from these cells in a dose dependent manner (Kurosaka *et al*, 2000).

LEC migration onto the posterior capsule was shown to be facilitated by the presence of collagen type IV, laminin and fibronectin (Olivero & Furcht, 1993). Also, metalloproteinases (gelatinases), which are proteolytic enzymes that were found to be stimulated by sham cataract surgery (Tamiya *et al*, 2000), were suggested to play an important role in the regulation of LEC migration onto the posterior capsule (Kawashima *et al*, 2000; Wong *et al*, 2004).

Extracellular matrix (ECM) formation by LECs is the result of capsular bag wound-healing response after extracapsular cataract surgery. The cells become surrounded by multiple layers of ECM consisting predominantly of dermatan, chondroitin and heparan sulphates, and collagen types I, III, IV, V, VI (Ishibashi *et al*, 1994; Azuma *et al*, 1998; Nishi *et al*, 1995c), XII and XIV (Saika *et al*, 2001). Other substances found are laminin (Zhang *et al*, 2001) and osteopontin (Saika *et al*, 2003).

1.1.6.1.2.2 Clinical types of PCO (Figure 1-10)

Clinically there are two main morphological types of PCO: fibrotic and cellular. The fibrotic type is the result of collagen deposition and myofibroblastic transdifferentiation of LECs. This type leads to greyish-white discolouration and often wrinkling of the posterior capsule. The cellular type is associated with the formation of lens epithelial cell clumps (Elshnig's pearls) as a result of growth factor and cytokine stimulation of LEC proliferation. In the majority of cases, the two forms normally coexist, although a predominant feature can often be identified.

In a series of patients who had a square-edged hydrophobic acrylic IOLs (AcrySof), Wolken and Oetting (Wolken & Oetting, 2001) described a linear form of PCO that developed along the posterior capsular striae. These striae, which are often seen both during surgery and in the early postoperative period with these implants as well as with other 3-piece IOLs, were believed to have provided tunnels for the LECs to migrate through and onto the posterior capsule.

Following Nd:YAG capsulotomy, LEC pearls were found to form around the margin of the capsular opening (Kato *et al*, 1997a; Kurosaka *et al*, 2002). The cumulative probability of that occurrence was estimated to be 70% in 2 years, but according to Kurosaka *et al* (Kurosaka *et al*, 2002) only 20% of these pearls were progressive and required a second capsulotomy procedure.

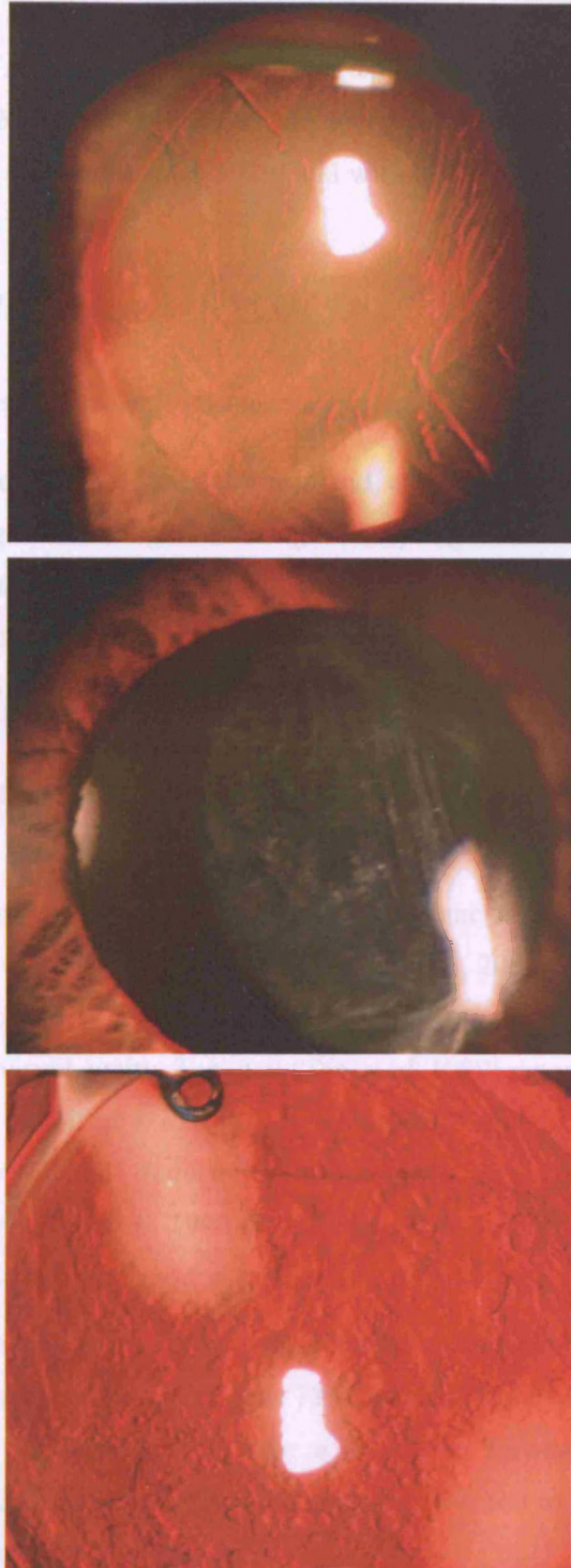


Figure 1-10. Clinical types of PCO: fibrotic type showing posterior capsule wrinkles (a) and grayish haze (b); and cellular type showing LEC pearls (c).

Posterior capsular and anterior hyaloid opacification or closure of the capsular opening after Nd:YAG capsulotomy was reported before in patients younger than 50 years (McPherson & Govan, 1995) and was found to be significantly more frequent in diabetic patients (Kumagai *et al*, 1999) and with hydrogel IOLs (Georgopoulos *et al*, 2003).

1.1.6.1.2.3 Methods of assessment of PCO

1.1.6.1.2.3.1 Subjective methods: visual function tests

Centripetal migration of the LECs, fibrosis and wrinkling of the posterior capsule leads to scattering of the light entering the eye (forward scatter) and hence compromises visual function. The two main visual functions that are commonly tested and that were shown to be compromised by PCO are visual acuity and contrast sensitivity (Hayashi *et al*, 2003; Tan *et al*, 1998; Aslam & Patton, 2004; Meacock *et al*, 2003). In addition, glare disability (Hayashi *et al*, 2003; Tan *et al*, 1998; Aslam & Patton, 2004) and forward light scatter (Meacock *et al*, 2003) have been linked to PCO development.

Using Scheimpflug videophotography and measurements of visual acuity and contrast sensitivity with and without glare, Hayashi *et al*, 2003 (Hayashi *et al*, 2003), found that the degree of PCO correlated with both these visual functions, although most strongly with visual acuity. Tan *et al* (Tan *et al*, 1999) reported that high spatial frequency contrast sensitivity loss (3 cycles/degree) provided a more sensitive measure than other spatial frequencies in the early stages of PCO formation. Sunderraj *et al* (Sunderraj *et al*, 1992) found that glare disability is more prominent in some patients who still had good visual acuity.

Meacock *et al* (Meacock *et al*, 2003) estimated that the percentage of PCO required for a decline in visual acuity to occur was 78% but was 38% to 46% for a decline in contrast sensitivity and less than 1% for a decline in forward light-scatter. The authors thus concluded that the latter is the most sensitive test to assess the influence of PCO on visual function.

1.1.6.1.2.3.2 Objective methods

1.1.6.1.2.3.2.1 *Slit lamp grading*

Many authors have used different systems that rely on slit lamp grading of PCO. Kruger et al (Kruger *et al*, 2000) used a system that graded capsular opacification within the central 3mm into: 0=absent, 1=very mild, 2=moderate, and 3=dense white. Sellman and Lindstrom (Sellman & Lindstrom, 1988) graded fibrosis and Elshnig's pearls on a similar four-point scale, which was used by other studies (Oner *et al*, 2000; Winther-Nielson *et al*, 1998). They used diagrams to illustrate the various grades of both fibrosis and cell pearls: 1= no or slight PCO without reduced red reflex and no pearls to the IOL edge; 2 = mild PCO reducing the red reflex, Elshnig's pearls to the IOL edge; 3 = moderate fibrosis or Elshnig pearls inside IOL edge but with a clear visual axis; 4 = severe fibrosis or Elshnig's pearls covering the visual axis and severely reducing red reflex. Legler et al (Legler *et al*, 1993) used ease of visibility of posterior segment structures, including the optic nerve head, retinal blood vessels and retinal nerve fibre layer, with the indirect ophthalmoscope. Prajna et al (Prajna *et al*, 2000) combined this method with the slit lamp grading system. According to Prajna's system, in grades II and III the capsular opacity is visible through an undilated pupil and grade II is characterised by clearly seen optic nerve head but hazy retinal nerve fibre layer and blood vessels, whereas in grade III, even the optic nerve head is not visible.

These methods are easy to apply clinically and their reproducibility is expected to be high for an experienced observer but they are still subject to inherent interobserver variability. Also, although they can be considered to be semi-quantitative, they lack precise quantification.

1.1.6.1.2.3.2.2 *Imaging systems*

1.1.6.1.2.3.2.2.1 *Scheimpflug system*

Scheimpflug system was introduced by Lasa et al in 1995 (Lasa *et al*, 1995) then further developed by Hayashi in 1998 (Hayashi *et al*, 1998d; Hayashi *et al*, 1998e) to enable quantification of the density of the PCO. The system is called Anterior Eye Segment Analysis (EAS-1000; Nidek, Japan) and has been used in several studies

(Klos *et al*, 1999;Zaczek & Zetterstrom, 1999;Hayashi *et al*, 2001;Hayashi *et al*, 2002;Tsuchiya *et al*, 2003;Hayashi *et al*, 2003;Hayashi & Hayashi, 2004;Hayashi *et al*, 2004). The central 3-mm position of the posterior capsule is quantified by means of area densitometry that measures the scattering light intensity. Slit images of the implanted IOL are taken at 0, 45, 90 and 135 meridians after full pupillary dilatation. The highest quality image of each meridian is selected and then transferred to a computer. The axial densitometry is used to calculate the scattered light density of the central 3-mm area of the posterior capsule. The density value of one section is determined by subtracting the scatter light density value of the IOL from that of the posterior capsule. The averaged density of the 4 meridians then determines the PCO density value. Hayashi *et al* (Hayashi *et al*, 1998e) found intraobserver and interobserver correlation coefficient of 0.95 and 0.976, respectively, that indicated high reproducibility. However, in a recent study by Tantaka *et al* (Tanaka *et al*, 2004c), IOL material was found to significantly influence the scattered light density measurements of Scheimpflug system, and thus the density of PCO quantified by this system cannot be directly compared with different optic materials.

1.1.6.1.2.3.2.2.2 Digital photography

Digital photography or digital image acquisition of the posterior capsule (Aslam *et al*, 2002) includes a group of computer-based systems, each adopts a specific principle to quantify PCO.

Brightness-based analysis system relies on the image pixel grey value (light intensity of the pixel) to classify it into either PCO area or not according to a given light intensity threshold. The percentage of classified pixels is then calculated by a computer to give the percentage of PCO. Wang *et al* (Wang & Woung, 2000) used digital images with the EAS anterior segment analysis system and graded brightness within the central and peripheral zones of the optic area from 0 to 255. A predefined threshold of transparency is 167 and the percentage level of transparency is estimated by mean of a computer program. Because the system requires that each pixel be defined individually as opaque or clear, problems of image analysis and interpretation arise due to the inherently variable background illumination intensity. This can be due to variations in patient fixation, head posture, pupillary size, fundus

pigmentation and IOL centration or refractive index (Pande *et al*, 1997; Barman *et al*, 2000).

Density map system is another imaging system that was developed by Friedman *et al* (Friedman *et al*, 1999). In that method, a polarised light is incorporated in the illumination and viewing systems of the camera to suppress much of the corneal reflex. The image illumination is evened out by an image analysis technique that produces an illumination-compensated image. The grading of PCO assesses both average area density (grey level of opacification), which is converted to a scale (0 to 4), and percentage coverage of PCO. Validation studies showed that the image analysis system identifies the percentage coverage and the density of PCO similar to subjective assessment by an ophthalmologist. The system, however, seems to lack ability to identify progression of PCO. Because the system uses the average density, when more area is covered with less dense PCO the overall average decreases. Therefore, it was suggested that using the standard deviation (rather than the mean) of the density for the specified area, regionalising areas of different opacities and assessing texture of the capsule would improve the assessment scheme.

Evaluation of the Posterior Capsule Opacification (EPCO) system was developed by Heidelberg and uses retro-illumination colour photographs taken with a Zeiss photo slit lamp to score PCO. This system was first described by Tetz *et al* in 1997 (Tetz *et al*, 1997). The area of opacification of the posterior capsule is encircled and graded 0-4 according to perceived density. The overall opacity is then calculated by multiplying the density of the opacification by the fraction of the area behind the IOL optic that is involved. The system is cheap and is claimed to be one of the best systems for evaluating PCO. Inter-observer and intra-observer variability were assessed by estimating the standard deviation of the PCO grade and was found to be low. The system, however, was not assessed for its ability to identify progression and is limited by not being fully objective as it relies on the observer to define the PCO level in different areas.

Texture segmentation system has been described by Pande *et al* (Pande *et al*, 1997) and recently by Barman *et al* (Barman *et al*, 2000). It has been used in several studies by the research group at St Thomas Hospital, London since 1997. It depends on specialised photographic equipment that produces a high-resolution, evenly illuminated image of the posterior capsule. The image analysis software is based on

TRACEE, an image analysis computer program that is enhanced with dedicated modules written for the purpose of PCO analysis. The system analyses the area behind the optic of the IOL and not obscured by the anterior capsule 'the mask'. All images undergo processing steps including removal of Purkinje images, contrast-enhancement, filtering to enhance the texture of areas of opacity that look like clear capsule and texture segmentation to classify the mask area into areas of opacity and transparency. This binary classification is dependent on the texture (structural details), with increased texture indicating opacity. The final result is calculated in percentage area of opacification based on the number of opaque pixels in the mask area compared with the total number of pixels within the mask. A colour-coded form of the software has been developed with the intention of simplifying interpretation.

The system has been validated by comparing the computer-derived percentages of PCO to clinical assessment of PCO percentage on the slit lamp by experienced clinicians and intra-observer variability was found to be less than 10% (Barman *et al*, 2000).

1.1.6.1.2.4 Treatment of PCO

1.1.6.1.2.4.1 Nd:YAG capsulotomy

Nd:YAG laser capsulotomy was introduced as a method of treating PCO in the 1980s by Aron-Rosa (Aron-Rosa *et al*, 1980) and Fankhauser (Fankhauser *et al*, 1981) and proved to be both effective and safe.

1.1.6.1.2.4.1.1 Principles of Nd:YAG laser

Nd:YAG laser (Murrill *et al*, 1995;Thall, 1999) is a CO₂ infrared laser of 1,064nm wavelength that works on the principle of photodisruption. When amplified, focused and applied to tissues, Nd:YAG laser light strips the electrons away from their nuclei and produces plasma. The reuniting of the electrons and nuclei creates an acoustic shock wave that damages the tissues.

Commonly used Nd:YAG lasers are either Q-switched or mode-locked or both. In Q-switching, a shutter in front of one of the mirrors prevents any significant laser emission until a large population inversion of electrons has been achieved. The shutter is then opened and the energy exits in a very short pulse (~10-20ns). In mode-

locking, an interferometer inside the cavity of the laser tube synchronises the modes of the emitted light in a train of 7 to 10 shorter pulses than that of a Q-switched pulse (~30ps). Q-switched lasers are more commonly used since they are less expensive.

1.1.6.1.2.4.1.2 Technique of Nd:YAG capsulotomy

Since Nd:YAG laser is an invisible infrared light, an ancillary helium-neon (He-Ne) aiming system is used. A slight discrepancy of the foci of both lasers results from chromatic aberration, with the shorter wavelength of the He-Ne focusing in front of the infrared light of the Nd:YAG (Thall, 1999). Also, although photodisruption occurs at the focus of the laser, impurities of the laser or lens material may produce damage to the lens implant before the focusing point (Thall, 1999). Slightly defocusing the laser behind the point of intended delivery helps avoid damaging the implants. Also, using a contact lens to converge the light at a steeper angle makes the impact at an area remote from the focus point less likely (Downing & Alberhasky, 1990).

Capsular opening made with the laser should be at least 1.5mm. Hu et al (Hu *et al*, 2001) found that the size of the opening tended to increase in size up to 1 month and then stabilises. Decentration of the capsular opening by up to 1mm was not found to affect visual function as long as the opening was clear (Aslam & Dhillon, 2002).

1.1.6.1.2.4.1.3 Complications of Nd:YAG capsulotomy

Nd:YAG capsulotomy can lead to several complications, some of which can be sight threatening.

1.1.6.1.2.4.1.3.1 Rise of IOP

The incidence of this complication varies between 25% and 90%. An increase of IOP up to 30mmHg was found to occur in 5.7% (Keates *et al*, 1984) to 28.6% in the early reports of the procedure (Terry *et al*, 1983; Stark *et al*, 1985). The maximal increase in IOP occurs within 3-4 hours after capsulotomy (Richter *et al*, 1985). Keates *et al* (Keates *et al*, 1984) found that the increase in IOP returned to its pre-treatment level in 89% of patients after 1 week. A persistent elevation of IOP was reported to occur in about 1% of patients (Stark *et al*, 1985). The authors also found the ratio of the IOP in the treated eye to that in the other eye to be significantly higher than in the group with intact capsule. A late-onset elevation of IOP after a mean follow-up of

2.7 years was found in 5.9% of patients (Fourman & Apisson, 1991). Recently Hu et al (Hu *et al*, 2000) and Ge et al (Ge *et al*, 2000) reported conflicting evidence on the effect of Nd:YAG capsulotomy on the IOP. Hu's study showed no significant rise in IOP up to 3 months after Nd:YAG capsulotomy. Ge's study, on the other hand, showed a long-term rise of IOP in patients who developed an increase of IOP within an hour of the procedure and in patients with glaucoma.

The mechanisms of this complication include obstruction of the trabecular meshwork by inflammatory cells, capsular (Stark *et al*, 1985; Lynch *et al*, 1986) and dialyzable proteins of a small molecular weight from the disrupted anterior vitreous face (Schubert *et al*, 1985). Shock-wave damage to the trabecular endothelial cells (Lynch *et al*, 1986), and release of inflammatory mediators (Stjernschantz *et al*, 1986) have also been suggested to be involved in producing IOP rise following Nd:YAG capsulotomy.

Risk factors for IOP rise following Nd:YAG capsulotomy include larger size of the capsular opening (Channell & Beckman, 1984) aphakia (Richter *et al*, 1985; Javitt *et al*, 1992), glaucoma (Ge *et al*, 2000) and myopia (Schubert, 1987). Similarly, although some authors found that increased total laser energy was associated with increased IOP (Channell & Beckman, 1984; Richter *et al*, 1985), Slomovic et al (Slomovic & Parrish, 1985) was unable to find a significant correlation between them.

Apraclonidine 1% or Timolol 0.5% drops and oral acetazolamide are among the most commonly used medications to prevent and control IOP spikes following Nd:YAG capsulotomy. To date, there is no evidence for a long-lasting visual damage as a result of IOP rise following Nd:YAG capsulotomy.

1.1.6.1.2.4.1.3.2 Retinal breaks and detachment

In patients who underwent ECCE, the incidence of retinal detachment following Nd:YAG capsulotomy has been estimated to be between 0.4% (Keates *et al*, 1984) and 3.6% (Rickman-Barger *et al*, 1989). More recently, Jahn et al (Jahn *et al*, 2003) found the incidence of retinal detachment to be 0.5% within 24 months after phacoemulsification and subsequent Nd:YAG capsulotomy.

Javitt et al (Javitt *et al*, 1992) found almost fourfold increase in the incidence of retinal tears or detachment following Nd:YAG capsulotomy. Also, Nd:YAG

capsulotomy was identified as an independent risk factor for the development of retinal detachment in a case-control study (Tielsch *et al*, 1996). Powell et al (Powell & Olson, 1995), however, found no significant difference in the incidence of retinal detachment between patients who underwent phacoemulsification alone and those who underwent Nd:YAG capsulotomy following phacoemulsification.

The risk factors of developing retinal detachment after Nd:YAG capsulotomy include high myopia, lattice degeneration with associated holes, greater laser energy and larger capsulotomy size (Koch *et al*, 1989; MacEwen & Baines, 1989). Dardenne et al (Dardenne *et al*, 1989) and Steinert et al (Steinert *et al*, 1991), however, were unable to establish a relationship between the laser parameters and the incidence of retinal detachment.

1.1.6.1.2.4.1.3.3 Cystoid macular oedema (CMO)

The incidence of CMO following Nd:YAG capsulotomy ranges between 0.68 to 1.23% (Shah *et al*, 1986; Steinert *et al*, 1991). The exact mechanism leading to the development of CMO is not known. However, it is postulated to be a non-specific response to any intraocular surgical procedures. The disruption of the anterior hyaloid face, movement of the vitreous and possibly vitreoretinal traction are believed to contribute to its development. It was also postulated to be the result of an inflammatory response to the release of capsular fragments that involves the release of prostaglandins and leukotrienes (Murrill *et al*, 1995).

The majority of cases of CMO following Nd:YAG capsulotomy are asymptomatic and in only a small percentage is there a drop in vision. Fluorescein angiography can demonstrate the leakage from the peri-foveal capillaries. The low incidence and difficulty in quantifying CMO rendered the assessment of the effectiveness of its treatment difficult. A common therapeutic regimen includes applying either non-steroidal antiinflammatory or steroidal eye drops 4 times a day for 4 weeks (Murrill *et al*, 1995). The use of the non-invasive technique of optical coherence tomography to measure the changes in macular thickness after cataract surgery (Sourdille & Santiago, 1999; Grewing & Becker, 2000) offers an effective and safe means to further investigate this complication and its treatment following Nd:YAG capsulotomy.

1.1.6.1.2.4.1.3.4 IOL damage

The most common occurrence during Nd:YAG capsulotomy is 'striking' or 'pitting' of the IOL by the laser, with rates between 4% to 40% (Stark *et al*, 1985; Weiblinger, 1986). Silicone IOLs were found to have a lower threshold of damage by the laser in comparison to acrylic and PMMA IOLs (Trinavarat *et al*, 2001). The threshold for damage of these implants was estimated to be 0.37mJ, 0.52 to 0.66mJ and 0.68mJ, respectively. Mainster *et al* (Mainster *et al*, 1983) indicated that the threshold of damage to an implant decreases with repeated striking by the laser.

The Nd:YAG laser optical breakdown was shown to occur up to 2mm anterior to its focal plane (Clayman & Jaffe, 1988). Fallor *et al* (Fallor & Hoft, 1985) showed that an IOL with a theoretical separation of 0.25mm or more between the lens and the posterior capsule sustains no damage. Also using a contact lens to focus the laser beam just behind the posterior capsule minimises the damage to the IOL (Downing & Alberhasky, 1990).

Newland *et al* (Newland *et al*, 1999) showed that silicone implants, in addition to having the lowest threshold for laser-induced damage, exhibit collateral damage in the form of a greater linear extension of damage (Figure 1-11) than PMMA and acrylic implants. They also showed that PMMA and silicone polymers could eject particulate matters adjacent to the entry site. One study showed cytotoxicity to cultured choroidal and retinal pigment epithelial cells by compounds released from experimentally damaged PMMA IOLs at energy levels of 10mJ or higher but not at 2-5mJ (Terry *et al*, 1985). There is, however, no clinical evidence of any toxic effect to the corneal endothelium or other intraocular tissues from striking the IOLs.

Generally, IOL 'strikes' or 'pits', unless excessive, are of no clinical significance (Keates *et al*, 1984). Rarely, however, they may cause glare, blurring or even distortion of vision (Gardner *et al*, 1985; Nirankari & Richards, 1985; Mamalis *et al*, 1990) that might at times require removal of the IOL (Mamalis *et al*, 1990).



Figure 1-11. An example of the collateral damage in a silicone IOL (SI30NB; Advanced Medical Optic, Inc., AMO). It shows marks of laser strikes (pitting) and radial extensions of the marks presumably cuts (arrows) within the optic.

1.1.6.1.2.4.1.3.5 IOL displacement

Findl et al (Findl *et al*, 1999), using dual beam partial coherence interferometry, showed that a small but measurable backward movement of the IOL occurs after Nd:YAG capsulotomy. The backward movement was more pronounced in patients with plate-haptic IOLs than with one-piece PMMA or 3-piece foldable IOLs and its magnitude was related to the size of the capsular opening.

Several case reports have been published of spontaneously dislocated IOLs following Nd:YAG capsulotomy that included hydrogel (Levy *et al*, 1990), PMMA (Framme *et al*, 1998) and plate-haptic silicone IOLs (Tuft & Talks, 1998; Dick *et al*, 1998; Akerele *et al*, 1999; Petersen *et al*, 2000). In one of the patients, this led to pupillary block glaucoma (Shankar & Halliwell, 2003).

1.1.6.1.2.4.1.3.6 Other rare complications

Anterior uveitis (0.4%-1.4%) (Keates *et al*, 1984;Chambless, 1985), persistent vitritis after 6 months (0.6%) (Keates *et al*, 1984), spread of low-grade infective endophthalmitis (Carlson & Koch, 1988;Neuteboom & Vries-Knoppert, 1988;Hollander *et al*, 2004), iris haemorrhage (Gardner *et al*, 1985), secondary closure of capsular aperture (Oshika *et al*, 2001) and corneal oedema (Wasserman *et al*, 1985) were rarely reported following Nd:YAG capsulotomy.

1.1.6.1.2.4.2 Surgical discision

Surgical discision (Murrill *et al*, 1995) either at the time of surgery or later on was the treatment of choice of PCO before the development of Nd:YAG laser capsulotomy. The procedure was associated with numerous serious complications such as corneal endothelial damage, IOL dislocation, vitreous loss, endophthalmitis and retinal detachment (Weiblinger, 1986;Flohr *et al*, 1985).

1.1.6.1.2.5 Prevention of PCO

1.1.6.1.2.5.1 Surgical technique

In a review by Apple *et al* (Apple *et al*, 1992), two major principles have been proposed to apply to the prevention of PCO. These included minimising the number of residual LECs, especially the equatorial cells, and creating a secondary barrier to block migration of LECs from the equatorial region toward the visual axis. They identified six factors, three of them are surgery-related and three are IOL-related, that play crucial roles in preventing or delaying the development of this complication (Ram *et al*, 1999;Apple *et al*, 2000;Peng *et al*, 2000;Apple *et al*, 2001). The surgery-related factors are hydrodissection-enhanced cortical removal, a smaller continuous capsulorhexis than the optic and in the bag placement of the IOL. The IOL-related factors are the biocompatibility of the IOL material to reduce stimulation of cellular proliferation, square-optic geometry of the IOL and maximal optic-capsule contact.

A PMMA square-edged capsular bag tension ring was used by Hara (Hara *et al*, 1995), Hashizoe (Hashizoe *et al*, 1998), and Nishi (Nishi *et al*, 1998b;Nishi *et al*, 1998a), who showed a significant reduction in PCO development. Nishi *et al* (Nishi *et al*, 1998a) concluded that a discontinuous bend in the capsule significantly inhibits LEC migration. The subsequent development of the square-edged IOLs and the establishment of their beneficial effect have made this technique redundant, however.

Posterior continuous curvilinear capsulorhexis (PCCC) and the optic capture technique with or without vitrectomy is another method that was primarily used in children and was reported by many authors to successfully prevent posterior capsular opacification (Gimbel, 1996;Vasavada *et al*, 2001;Raina *et al*, 2002). The procedure, however, did not prevent the growth of LECs on the anterior hyaloid face and Vasavada *et al* (Vasavada *et al*, 2004) reported up to almost 40% of anterior hyaloid opacification. Secondary surgical procedure was required after a mean follow-up of 2.3 years in 13.6% to clear the visual axis.

Tassignon *et al* (Tassignon *et al*, 2002) recently described the ‘bag-in-the-lens’ technique (Figure 1-12 & 1-13), where two identical continuous curvilinear capsulorhexes are created in both the anterior and posterior capsules and the capsular leaflets are inserted between the flanges of an IOL especially designed for that technique ‘twin-capsulorhexis IOL’. The authors reported no PCO or rather any similar retro-lenticular opacification in adults (Tassignon *et al*, 2002);(Tassignon, 2004b) and children (Tassignon, 2004a). They advocated the technique as the most effective surgical technique to prevent the development of PCO in high-risk patients such as children, uveitic patients and following vitrectomy. The procedure, however, is technically demanding but the authors report no increased risk of vitreous loss or increased incidence of cystoid macular oedema.

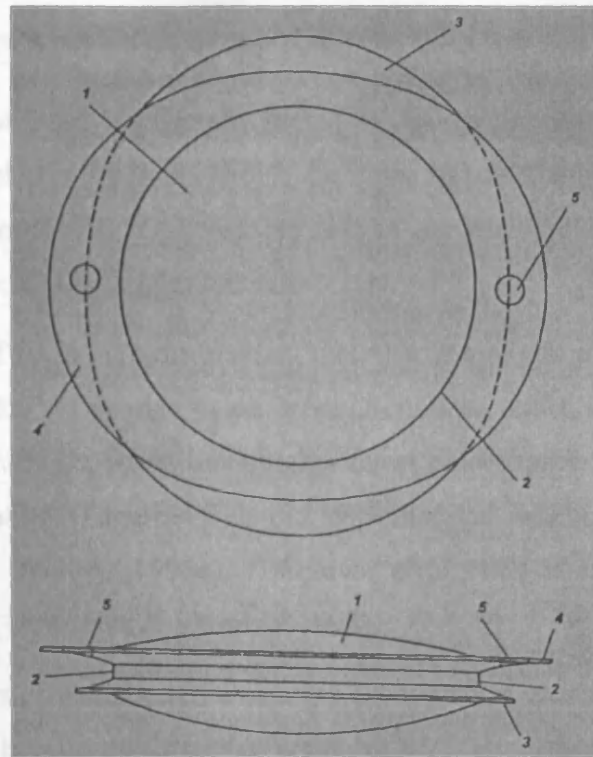


Figure 1-12. A schematic diagram of the twin-capsulorhexis and the IOL with the two perpendicularly orientated haptics (1 & 3). The side view shows the characteristic groove (2) that embraces the two capsular leaflets (Courtesy of Prof. Tassignon (Tassignon *et al*, 2002))

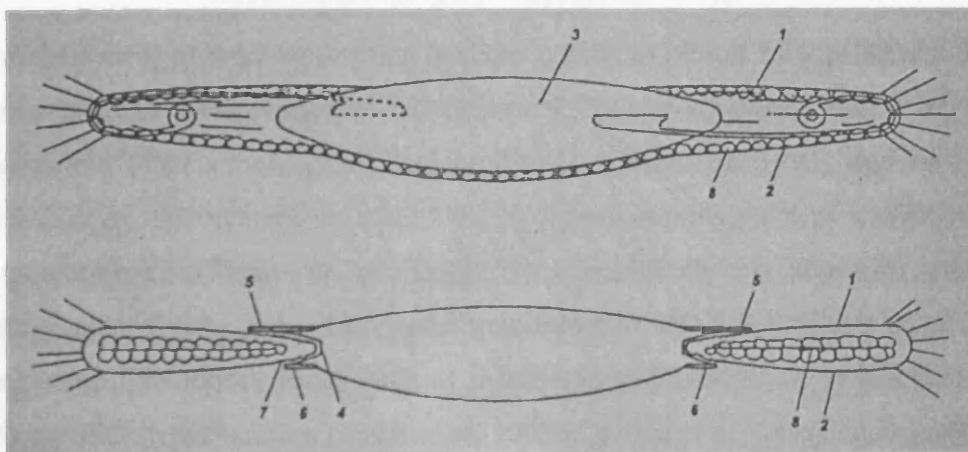


Figure 1-13. A schematic diagram illustrating a comparison between the conventional in-the-bag IOL with the LECs covering the posterior capsule and the bag-in-the-lens with the two flanges of the haptics embracing the capsular leaflets that in turn captures the LECs in between them. (Courtesy of Prof. Tassignon (Tassignon *et al*, 2002))

1.1.6.1.2.5.2 Surface modification of IOLs

Coating the IOL surfaces is generally meant to change their surface tension, which determines their relative hydrophilicity. The latter affects the attraction of the cells and their growth onto the IOL surfaces and is inversely related to their surface tension and to their contact angles (section 1.1.4).

Heparin-coating of PMMA IOLs renders their surfaces hydrophilic, with a contact angle of 33° to 56.5° (Cunanan *et al*, 1998; Dick *et al*, 2001; Tehrani *et al*, 2004). Although the lens was shown to have higher uveal biocompatibility i.e. less anterior chamber inflammation (Fagerholm *et al*, 1989; Percival & Pai, 1993) and cellular deposits (Shah & Spalton, 1995a), Umezawa *et al* showed that it increased the incidence of PCO (Umezawa & Shimizu, 1993).

Surface-passivation of PMMA IOLs changes their surface energy and hence renders them more hydrophobic with a contact angle of 90° (Umezawa & Shimizu, 1993). Kochounia *et al* (Kochounian *et al*, 1991) found that surface-passivated PMMA IOLs activated complement to the same degree of regular PMMA and no significant effect was found on lowering the incidence of PCO (Umezawa & Shimizu, 1993).

1.1.6.1.2.5.3 Inhibiting lens epithelial cell proliferation

The main classes of medications that have been used to inhibit LEC proliferation are: a) Antiproliferative drugs such as 5-fluorouracil (Ruiz *et al*, 1990; Ismail *et al*, 1996), daunorubicin (Tetz *et al*, 1996), colchicines (Legler *et al*, 1993) and mitomicin C (Ismail *et al*, 1996; Chung *et al*, 2000); b) Immunotoxins such as 4197X-ricin A immunoconjugate (Tarsio *et al*, 1997), lens epithelial cell adhesion molecule blocking agent (Nishi *et al*, 1997) and immunotoxin MDX-RA (Clark *et al*, 1998) and c) Antiinflammatory drugs such as indomethacin (Nishi *et al*, 1996b; Tetz *et al*, 1996) and diclofenac sodium (Nishi *et al*, 1995a; Cortina *et al*, 1997) and cyclosporin A (Cortina *et al*, 1997). These medications are applied either intraoperatively, through a long-acting delivery system or postoperatively. None of these medications, however, have been proved clinically useful yet.

1.1.6.1.2.5.4 Other methods

Experimental use of heparin-mixed anterior chamber irrigating solution during cataract extraction (Zaturinsky *et al*, 1990) and implantation of an anterior chamber heparin drug-delivery system (Xie *et al*, 2003) were found to be useful in reducing the postoperative inflammatory reaction and the incidence of PCO. Also, in a case-controlled trial, heparin eye drops have been shown to reduce the incidence of PCO after 4 years (Mastropasqua *et al*, 1997). The long-term effectiveness of these methods has not been yet established.

1.2 REVIEW OF THE LITERATURE

1.2.1 Incidence of PCO

PCO is the most common postoperative complication after modern cataract extraction surgery. Published estimates that are based on the need for Nd:YAG capsulotomy have shown a gradually increasing incidence of PCO after surgery. Within the first postoperative year, the incidence was found to be up to 12% (Sudhakar *et al*, 1989; Schaumberg *et al*, 1998; Baratz *et al*, 2001; Ando *et al*, 2003) and that increases to about 50% in 5 years (Moisseiev *et al*, 1989; Apple *et al*, 1992; Baratz *et al*, 2001; Ando *et al*, 2003). Sundelin (Sundelin & Sjostrand, 1999) found that, 5 years after surgery, there was a 'hidden' untreated group of approximately 9% of patients that had clinically significant PCO and would benefit from Nd:YAG capsulotomy.

Table 1-2 and 1-3 details the incidence rate of PCO, as indicated by the need for Nd:YAG capsulotomy, reported in the most recent studies with a follow-up of at least 1 year after ECCE and phacoemulsification. Incidence of Nd:YAG capsulotomy has mainly been used in retrospective (Mamalis *et al*, 1996b; Ninn-Pedersen & Bauer, 1997; Dana *et al*, 1997; Baratz *et al*, 2001; Beltrame *et al*, 2002; Ando *et al*, 2003; Abhilakh Missier *et al*, 2003) and post-mortem studies (Apple *et al*, 2001; Schmidbauer *et al*, 2001a). The method is criticised for its subjectivity as it relies on patients' complaints and surgeons' threshold for intervention. However, the method derives validity from the fact that it reflects 'clinically significant' PCO i.e. PCO that affects visual function or obscures the fundus view.

Several factors related either to the patient or the surgical technique have been suggested to affect the incidence and rate of PCO.

1.2.2 Factors affecting the incidence of PCO

1.2.2.1 Surgery related factors

1.2.2.1.1 Surgical technique

Although, a meta-analysis by Powe et al (Powe *et al*, 1994) was unable to show a significant difference between ECCE and phacoemulsification techniques in the incidence of PCO, a decline in PCO and Nd:YAG capsulotomy rates has recently been documented in a large post-mortem study of Nd:YAG capsulotomy rate (Apple *et al*, 2001). Reports of the 5-year incidence following ECCE indicated that PCO occurred in up to 50% (Moisseiev *et al*, 1989; Apple *et al*, 1992), while after phacoemulsification the incidence was only up to 33% (Baratz *et al*, 2001; Ando *et al*, 2003). In a study by Ram et al (Ram *et al*, 2001) ECCE was found to have a higher rate of visually significant PCO than phacoemulsification (42.5% vs. 19.2%). The lower incidence with phacoemulsification is believed to be related to the improvement in the surgical techniques, the use of smaller incisions, better cortical clean-up and the use of modern foldable intraocular lenses with better design profiles. Also, the reduced postoperative inflammatory reaction shown to occur after phacoemulsification (Oshika *et al*, 1992; Ursell *et al*, 1999; Montes *et al*, 2003) seem to have a role in lowering the incidence of PCO.

The type and size of capsulorhexis affects the incidence of PCO. The performance of continuous curvilinear capsulorhexis was found to be associated with less PCO than 'envelope' capsulectomy (Birinci *et al*, 1999). Hollick et al, 1999 (Hollick *et al*, 1999a), and Aykan et al, 2003 (Aykan *et al*, 2003), reported an increase in the percentage of area of opacified posterior capsule after phacoemulsification and implantation of PMMA IOLs in patients with larger capsulorhexis (6-7mm in comparison to 4.5-5mm). Also, Wejde et al (Wejde *et al*, 2004) found that a small central CCC that totally covers the optic edge was associated with significantly less PCO than that that lies partially or completely off-the-optic.

1.2.2.1.2 *Intraocular lens*

1.2.2.1.2.1 *IOL and its position*

Implantation of an IOL following cataract surgery was shown to decrease the incidence of PCO and Nd:YAG capsulotomy in comparison to aphakia (Nishi, 1986;Badr *et al*, 1995). Also, bag-fixated IOLs were found to decrease the incidence of PCO (Laurell *et al*, 1998) and Nd:YAG capsulotomy (Ram *et al*, 1999;Ram *et al*, 2001).

1.2.2.1.2.2 *Design of the IOL*

Angulation of the haptic and the overall size of an implant or its optic can have an effect on the rate of PCO. Patients implanted with PMMA IOLs with angled haptics were found to have a lower capsular discission rate than uniplanar PMMA IOLs (7.9% vs. 15%) (Downing, 1986). In a later study by Shmidbauer *et al* (Schmidbauer *et al*, 2002) this was not found to be the case, however. Mamalis *et al* (Mamalis *et al*, 1995) found less PCO requiring Nd:YAG capsulotomies in a PMMA IOL group with an overall lens diameter less than 13.5 mm, than in a PMMA IOL group with an overall diameter of 13.5mm or larger. Nishi and Nishi (Nishi & Nishi, 2003) found that acrylic IOLs with larger optics (7 mm) had a higher rate of PCO development than those with smaller optics (5.5 mm).

Similarly, the configuration of the posterior surface of the IOL has been found to affect the rate of PCO as well as the type of opacification that develops. Intraocular lenses with a convex posterior surface were found to have a lower capsulotomy rate (up to 17.6%) than those with a plane posterior surface (up to 29.3%) (Sterling & Wood, 1986). Following a continuous capsulorhexis and phacoemulsification, Yamada *et al* (Yamada *et al*, 1995) found that Nd:YAG capsulotomy rates were 5.9% and 32.5% after plano-convex and biconvex IOL implantation, respectively.

A laser-created ridge on the posterior surface of the implant was found in earlier studies to lower the PCO rate (Maltzman *et al*, 1989). Born *et al* (Born & Ryan, 1990) found that implants of biconvex or plano-convex design that had broader posterior surface contact with the posterior capsule had a lower cumulative

capsulotomy rates than implants with a convex-plano optic or those with laser ridges (5.9% versus 40%).

Plate-haptic silicone IOLs was shown to have less PCO requiring Nd:YAG capsulotomy in comparison to 3-piece silicone IOLs (Cumming, 1993). Mamalis et al (Mamalis *et al*, 1996b) found the same results but the difference between the capsulotomy rates in their study was not statistically significant (30.2% and 39.1%). In a recent study by Abhilakh Missier (Abhilakh Missier *et al*, 2003), plate-haptic silicone IOL had more PCO and Nd:YAG capsulotomy rate than hydrophobic acrylic IOLs.

A square-edge profile of an IOL has been shown to reduce or even prevent migration of LECs onto the posterior capsule and hence the development of PCO through either a contact inhibition mechanism (Nishi *et al*, 1998c) or a mechanical barrier effect (Boyce *et al*, 2002). Nishi et al has shown that to be the case in experimental and clinical settings (Nishi *et al*, 1998a;Nishi *et al*, 1998c;Nishi & Nishi, 1999;Nishi *et al*, 2000). Peng et al (Peng *et al*, 2000), in a study of 150 autopsy eyes with 3 types of IOLs: PMMA, silicone and hydrophobic acrylic, noticed that there was an abrupt termination of cells at the peripheral edge of the truncated or square-edged optic. In a study by Kruger et al (Kruger *et al*, 2000), after 2 years of follow-up, silicone implants with square edges had less PCO and Nd:YAG capsulotomy rates than those with rounded edges.

The optic edge profile was shown to be more relevant in preventing PCO development than the optic material. Nishi et al (Nishi *et al*, 2000;Nishi & Nishi, 2002) found the speed of capsular bend-formation at the optic edge was comparable and that there was no difference in PCO between two square-edged 3 piece IOLs made of silicone and hydrophobic acrylic material. Nishi also found that hydrophobic acrylic implants with rounded edge lost their PCO preventative effect (Nishi *et al*, 2001).

1.2.2.1.2.3 IOL material

Several studies have shown that PMMA IOLs have a higher Nd:YAG capsulotomy rate than silicone and acrylic implants. Hollick et al (Hollick *et al*, 1999c) reported

26%, 14% and 0% Nd:YAG capsulotomy after 3 years for PMMA, silicone and hydrophobic acrylic IOLs, respectively.

Nagata et al and Oshika et al found that the adhesion force of a type I collagen sheet and of the posterior capsule to intraocular lenses made of acrylate was greater than with PMMA (Nagata *et al*, 1998;Oshika *et al*, 1998b) or silicone IOLs (Oshika *et al*, 1998b). Linnola et al (Linnola *et al*, 1999a) suggested that acrylate is a bioactive material that adheres to the biological tissues better than silicone and PMMA. They suggested that this is due to better adhesion of fibronectin to acrylate than to silicone and PMMA IOLs. This was postulated to explain the stronger adhesion between the posterior capsule and acrylic IOLs than PMMA and silicone IOLs and hence the preventative effect on LEC migration and PCO development (Linnola *et al*, 1999b;Linnola *et al*, 2000a;Linnola *et al*, 2000b). They also proposed that a single layer of lens epithelial cell binds both to the IOL and to the posterior capsule, which produces a sandwich-like structure, including the IOL, the cell monolayer, and the posterior capsule; and that this sealed sandwich-like structure prevents further epithelial ingrowth and PCO development (The sandwich theory) (Linnola, 1997;Linnola *et al*, 1999b;Linnola *et al*, 2000b;Linnola *et al*, 2000a).

Table 1-2. Published incidence of Nd:YAG capsulotomy after ECCE and implantation of IOLs with different materials and designs and a follow-up of at least one year (modified and updated with permission from Linnola) (Linnola R., 2001).

Study & Year	IOL model	Haptic material	No.	Follow-up (months)	Nd:YAG %
PMMA					
(Winther-Nielson <i>et al</i> , 1998)	Pharmacia 725b	PMMA	60	36	43
(Winther-Nielson <i>et al</i> , 1998)	Pharmacia 700b	PMMA	62	36	43.5
(Khan & Percival, 1999)	Cilco JF1LRU	PMMA	40	144	50
(Hollick <i>et al</i> , 1999c)	Alcon MC60BM	PMMA	23	36	26
Hydrophilic acrylic (HSM-PMMA)					
(Winther-Nielson <i>et al</i> , 1998)	Pharmacia HSM-725b	PMMA	70	36	44
(Winther-Nielson <i>et al</i> , 1998)	Pharmacia HSM-700b	PMMA	58	36	67
(Khan & Percival, 1999)	logel PC12	Single-piece	35	144	20
Silicone					
(Hollick <i>et al</i> , 1999c)	Iolab LI41U	PMMA	22	36	14
Hydrophobic Acrylic					
(Oshika <i>et al</i> , 1996)	Alcon AcrySof MA60BM	PMMA	64	24	11.1
(Hollick <i>et al</i> , 1999c)	Alcon AcrySof MA60BM	PMMA	19	36	0

Table 1-3. Published incidence of Nd:YAG capsulotomy after phacoemulsification and implantation of IOLs with different materials and designs and a follow-up of at least one year (modified and updated with permission from Linnola) (Linnola R., 2001).

Study & Year	IOL model	Haptic material	No.	Follow-up (months)	Nd:YAG %
PMMA					
(Hayashi <i>et al.</i> , 1998c)	Alcon MZ60BD	PMMA	69	24	30.4
(Olson & Crandall, 1998)	*	PMMA	59	36	33
(Erie <i>et al.</i> , 1998)	Pharmacia 720/Storz 650 CUV	PMMA	198	41	26.5
(Erie <i>et al.</i> , 1998)	Pharmacia 805/Storz 359	PMMA	171	41	23.5
(Oner <i>et al.</i> , 2000)	Opsia-Agena 550	PMMA	77	17.8+1.7	26.3
Silicone					
(Cumming, 1993)	*	Plate-haptic	503	30	2.3
(Mamalis <i>et al.</i> , 1996b)	Staar AA-4203	Plate-haptic	139	21	30.2
(Mamalis <i>et al.</i> , 1996b)	AMO S118NB/SI30NB	Polypropylene	349	23.3	39.1
(Hayashi <i>et al.</i> , 1998c)	AMO SI30NB	Polypropylene	70	24	5.7
(Linnola & Holst, 1998)	Pharmacia CeeOn 920	PMMA	45	12	11
(Olson & Crandall, 1998)	AMO SI30NB	Polypropylene	60	36	24
(Abhilakh Missier <i>et al.</i> , 2003)	Staar AA4-203	Plate-haptic	107	36	23.1
Hydrophilic acrylic					
(Brown <i>et al.</i> , 1998)	Staar Collamer	Plate-haptic	125	65	4.7
(Stordahl & Drolsum, 2003)	Ioltech Stabibag	Hydroge	370	23.7 (3.1)	7.6
Hydrophobic Acrylic					
(Hayashi <i>et al.</i> , 1998c)	Alcon AcrySof MA60BM	PMMA	73	24	2.7
(Oner <i>et al.</i> , 2000)	Alcon AcrySof MA30BA	PMMA	80	17.8+1.7	14.34
(Abhilakh Missier <i>et al.</i> , 2003)	Alcon AcrySof MA30BA/60BM	PMMA	107	9 (2-23)/ 5.5(5-6)	0.34/ 0.64
(Stordahl & Drolsum, 2003)	Alcon AcrySof MA30BA	PMMA	335	23.3(3.3)	2.7

ECCE=Extracapsular cataract extraction; AMO= Advanced Medical Optics. * = data not available.

1.2.2.2 Patient-related factors

1.2.2.2.1 Ocular factors

1.2.2.2.1.1 Uveitis

Several studies have reported the incidence or prevalence of PCO in uveitis patients after ECCE or phacoemulsification cataract extraction. After extracapsular cataract extraction, Krishna et al (Krishna *et al*, 1998) reported a prevalence of 58% after a mean follow-up period of 81.4 months. In a case-controlled retrospective study of patients who underwent either ECCE or phacoemulsification, Dana et al (Dana *et al*, 1997) reported 45% of PCO rate after a mean follow-up of 4.3 years. In that study, the rate was compared to a contemporary group of non-uveitic patients who had a mean follow-up of 3.9 years and a PCO rate of 40%. Although the difference was statistically significant, the difference became no longer significant after adjusting for the younger age of the uveitis patients.

After phacoemulsification in uveitis patients, Estafanous et al (Estafanous *et al*, 2001) reported PCO in 62% of patients after a mean follow-up of 20 months. Also, Suresh et al (Suresh & Jones, 2001), reported 42% of PCO and 21 % of Nd:YAG capsulotomy among their patients after a mean follow-up of 2 years.

Berker et al (Berker *et al*, 2004) indicated that PCO was the most frequent complication, occurring in 37.5% of 40 eyes of patients with uveitis and Behçet's disease after phacoemulsification and IOL implantation. In a recent study by Rahman et al (Rahman & Jones, 2004), the long-term incidence of PCO in uveitis patients (after a mean follow-up of 7.5 years) was 96%.

1.2.2.2.1.2 Myopia

After phacoemulsification, patients with myopia and increased axial length were found to have an increased incidence of PCO. In a series of 109 highly myopic eyes (axial length over 26 mm) with a mean postoperative follow-up of 27 months, Lyle et al (Lyle & Jin, 1996), found an incidence of 50% of PCO, 95% of whom needed Nd:YAG capsulotomy. In another retrospective study of 32 eyes of 27 highly myopic patients (axial length=31mm to more than 35 mm) who had cataract surgery and

negative power_posterior chamber IOL implantation (-1.0 to -8.0 dioptries), PCO occurred in 44% after a follow-up of 6 to 36 months (Kohnen & Brauweiler, 1996).

1.2.2.2.1.3 Retinitis pigmentosa

Auffarth et al (Auffarth *et al*, 1996) found that, after phacoemulsification, patients with retinitis pigmentosa had an incidence of PCO of about 70.7% after 1 to 4 years. That was found to be significantly higher than an age and follow-up matched control group. Ando et al found that retinitis pigmentosa was an independent risk factor for the development of PCO (Ando *et al*, 2003).

1.2.2.2.1.4 Pseudoexfoliation

In a retrospective study of 197 patients, 99 of whom had pseudoexfoliation syndrome, Kuchle et al (Kuchle *et al*, 1997) reported an incidence of 45% of PCO in comparison to 9% in the control group.

1.2.2.2.1.5 Glaucoma and phaco-trabeculectomy

The relationship between glaucoma and the incidence of PCO appears to be related mainly to the surgical technique performed or to coexistent diseases. Phaco-trabeculectomy was found to have a decreased incidence of early PCO than combined ECCE and trabeculectomy (Anand *et al*, 1997). Shin et al (Shin *et al*, 2002) found that the incidence of PCO did not particularly increase after phaco-trabeculectomy when compared to phacoemulsification. They found, however, that the use of mitomycin C and the presence of diabetes mellitus significantly decreased the rate of PCO. An increased rate of PCO, on the other hand, was reported in eyes having a combined procedure and a limbal-based conjunctival flap when compared to those with a combined procedure and a fornix-based flap (Tezel *et al*, 1997). Ober et al (Ober *et al*, 2000) found no difference between silicone and acrylic IOLs in the incidence of PCO after phaco-trabeculectomy.

1.2.2.2.2 Systemic factors

1.2.2.2.2.1 Age

Both experimental and clinical studies have shown the effect of age on the development of PCO. Wormstone and coauthors (Wormstone *et al*, 1997) found that lens epithelial cell growth rate was age-dependent. They found that LEC count was significantly higher in the capsular bags of children in comparison to adults with senile cataract. Majima (Majima, 1995) showed a higher growth potential of LECs in patients with congenital cataract compared to those with senile cataract. Also, Jamal (Jamal & Solomon, 1993) found that an increased risk of developing epithelial pearls onto the posterior capsular associated with younger age and Stager (Stager, Jr. *et al*, 2002) reported an incidence of PCO up to 100 % in children under 4 years after 2.75 years of follow-up.

1.2.2.2.2.2 Sex

In an epidemiological study, Ninn-Pedersen *et al* (Ninn-Pedersen & Bauer, 1997) showed that after about 4 to 5 years, the percentage of patients not having had a Nd:YAG capsulotomy was reduced to around 50% for women and 60% for men. Also, Ando, *et al* (Ando *et al*, 2003) found that female sex was an independent risk factor for increased rate of Nd:YAG capsulotomy.

1.2.2.2.2.3 Diabetes mellitus

Conflicting reports exist regarding the effect of diabetes mellitus on PCO. A lower PCO rate in diabetic patients was reported by Knorz *et al* (Knorz *et al*, 1991) in a retrospective study of 939 eyes with an average follow-up of 26.3 months following ECCE and in a prospective study by Zaczek and Zetterstrom (Zaczek & Zetterstrom, 1999) following phacoemulsification and implantation of heparin-coated intraocular lenses. A lower incidence in diabetics was also reported in other studies of PCO in glaucoma (Shin *et al*, 1998; Shin *et al*, 2002) and pseudoexfoliation syndrome patients (Kuchle *et al*, 1997). In a recent prospective randomised clinical trial, Hayashi *et al*, 2002 (Hayashi *et al*, 2002), found that both PCO density and the incidence of Nd:YAG capsulotomy were significantly higher in diabetic patients up

to 3 years after surgery. The differences in these studies design, patient populations and method of PCO assessment could explain the differences in their conclusions.

CHAPTER 2

POSTERIOR CAPSULAR OPACIFICATION IN DIABETIC PATIENTS

2 POSTERIOR CAPSULAR OPACIFICATION IN DIABETIC PATIENTS

2.1 STUDY OF THE INCIDENCE AND RISK FACTORS OF ND:YAG CAPSULOTOMY IN NON-DIABETIC AND DIABETIC PATIENTS

2.1.1 Introduction

Posterior capsular opacification, in addition to impairing vision, can obscure fundus visualisation and potentially compromise the surveillance and timely treatment of posterior segment pathology such as diabetic retinopathy and macular oedema. Nd:YAG laser capsulotomy, the treatment of choice, is not without complications, some of which can be sight-threatening such as retinal oedema and detachment (Keates *et al*, 1984), which are particularly important in diabetic patients.

The long-term incidence of PCO in diabetic patients after phacoemulsification has not been separately examined before. Also, although factors such as young age, female gender, extra-capsular cataract extraction (ECCE), retinitis pigmentosa, better preoperative acuity and polymethylmethacrylate (PMMA) IOLs have been identified as risk factors for increased rate of PCO development and/or Nd:YAG capsulotomy (Baratz *et al*, 2001; Ando *et al*, 2003), the effect of diabetes mellitus remains uncertain. Some studies have shown an increased (Ionides *et al*, 1994; Hayashi *et al*, 2002), and others a decreased risk of PCO development and Nd:YAG capsulotomy in diabetic patients (Zaczek & Zetterstrom, 1999; Knorz *et al*, 1991). Moreover, none of the studies have investigated the influence of factors such as ethnic origin, postoperative inflammation and diabetes type and duration.

Many recent studies of PCO relied on the quantitative measurement of the density or extent of capsular opacification. While invaluable as an indicator of early lens epithelial cell (LEC) proliferative activity, the reported PCO rates in these studies do not necessarily reflect what might be a clinically significant opacification i.e. one that reduces visual functions or visibility of the posterior segment and thus requires treatment. Moreover, LEC proliferation and migration onto the posterior capsule can

be variable and even show regression at the short- and long-terms (Hollick *et al*, 1998;Meacock *et al*, 2001;Findl *et al*, 2004).

2.1.2 Aims

We undertook this retrospective study to examine the incidence and factors that affect Nd:YAG capsulotomy rate, which was used as a surrogate measure of PCO rate, in a cohort of non-diabetic and diabetic patients in a single medical retina unit at a tertiary referral hospital.

2.1.3 Patients and methods

2.1.3.1 Inclusion& exclusion criteria

After obtaining ethical approval for the study, we reviewed 1223 medical records of a continuous series of patients who underwent phacoemulsification cataract extraction in the medical retina service at Moorfields Eye Hospital between 1994 and 2000. Only one eye was randomly included for patients who had bilateral surgery (n=216). Patients who underwent other anterior segment surgery (e.g. trabeculectomy or keratoplasty) (n=156) and those with unavailable records at the time of the study (n=45) were excluded. Four patients (0.5%) were included who had diagnoses of uveitis (Behcet's, multifocal choroiditis, sympathetic ophthalmia and Eales disease). The number of included patients was 806, 327 (40.6%) of whom were diabetic.

2.1.3.2 Surgery

The number of included patients was 806, 327 (40.6%) of whom were diabetic. All patients underwent a standard phacoemulsification and implantation of an IOL. Surgery was performed by a consultant or a fellow (306; 38%); or a senior resident (420, 52.1%) attached to the medical retina service. In 80 patients (9.9%), it was not possible to identify the surgeon's grade at the time of surgery. A corneal incision of 2.8 to 3.2mm was performed on all patients except those who were given PMMA implants where a 5.5mm to 6mm incision and corneal sutures were needed. A circular continuous capsulorhexis was fashioned, the size of which was aimed to just overlap the optic edge. This was typically 5 to 5.5mm, although details of the exact size and position of the lens in relation to the capsule was not routinely recorded.

Hydrodissection was then performed followed by phacoemulsification of the nucleus and manual irrigation-aspiration of cortical lens matter. Intraocular lenses used were either polymethylmethacrylate (PMMA)(n=114, 14.2%) (MC550, Iolab, n=82 or 6840U, Chiron Vision-Iolab, n=32), plate-haptic silicone (n=647, 80.3%) (Chiron C10UB, n=100; or Chiron Vision C11UB, n=547) or 3-piece-silicone (LI41U, Iolab) (n=45, 5.6%). All IOLs were implanted inside the capsular bag except in 9 patients (1%), in whom posterior capsular tear necessitated sulcus-fixation.

At the conclusion of the procedure, subconjunctival Betamethasone (4mg) and Cefuroxime (125mg) or Gentamicin were given. After surgery, patients were prescribed Guttae Dexamethasone 0.1% and Guttae Chloramphenicol 0.5% QDS for 2 weeks followed by Guttae Dexamethasone 0.1% BID for 2 weeks. Postoperative evaluation was performed immediately after surgery, within two weeks and at regular intervals thereafter depending on the clinical need.

2.1.3.3 Outcome measure and data collection

The principal outcome variable was the performance of Nd:YAG capsulotomy, taken as a surrogate measure for clinically significant PCO. Indications for this procedure were the presence of significant PCO that is: (1) causing visual symptoms such as reduced acuity or glare; or (2) interfering with the visualisation of the posterior segment.

A database file was used for entering all the relevant data including age at surgery, ethnic origin, the medical and surgical history, operative and postoperative details, the surgeon's grade (resident or fellow/ consultant), the duration between surgery and the performance of Nd:YAG capsulotomy and the follow-up time. Information about diabetes mellitus included diabetes type: non-insulin dependent or insulin-dependent, duration (in years) and grade of retinopathy: none, non-proliferative or proliferative. Also, the presence of uveitis and the occurrence of clinically significant postoperative inflammation, i.e. documented inflammatory signs that required additional topical or systemic steroid treatment within 3 months of surgery, was recorded.

2.1.3.4 Statistical analysis

The Statistical Package for Social Science (SPSS, v.9; Chicago, Ill.) for Windows software was used for statistical analysis. The median and inter-quartile range were

used for description of continuous data. Survival tables and Kaplan-Meier curves, which accounts for censored data i.e. patients that did not have Nd:YAG laser treatment by the end of their follow-up, were used to derive the cumulative incidence and compare rates of Nd:YAG capsulotomy between patient subgroups. The cumulative incidence was calculated as the number of events (i.e. Nd:YAG capsulotomy) divided by the number of patients at risk at each of the time intervals (No. of patients entering the period less 50% of those lost to follow-up). Confidence intervals for the incidences were calculated using the Wilson score method.

A log rank test was used for bivariate analysis and a backward step-wise Cox-proportional hazard regression for multivariate analysis. A variable qualified for inclusion in the Cox-proportional hazard model if they had a p value of 0.2 or less or if believed from previous studies to affect the rate of PCO. Post hoc assessment showed that the study sample size had a power of 90% to detect a hazard ratio of 10% to 30% between the two subgroups for variables such as diabetes mellitus, postoperative inflammation, IOL type and vitrectomy over an accrual period of 48 months. The sample size allowed for up to 95% censored data (loss of follow-up or no capsulotomy by the time patients were discharged) in either of the two subgroups and 10% conversion rate (from non-diabetic to diabetic) during the follow-up period. A p value of <0.05 was considered statistically significant.

2.1.4 Results

2.1.4.1 Patient characteristics

The demographic and clinical features of the patients are listed in Table 2-1. The median age of the patients was 69.7 years (range=20.2 to 99.3) and the median length of follow-up was 16.6 months (range=1.8 to 74).

2.1.4.2 Incidences of PCO

Survival table analysis (Table 2-2) revealed that the incidences of Nd:YAG capsulotomy were 9.9%, 12.3%, 18% and 15.4% after 1,2,3 and 4 years respectively. In non-diabetic patients the incidences were 10.6%, 14.8%, 21.2% and 28.6% and in diabetic patients they were 9%, 9.4%, 15.3% and 5.4% after the same follow-up periods.

Table 2-1. Patient characteristics

	Total	Non-diabetic	Diabetic	<i>P</i>
No.	806	479(59.4%)	327(40.6%)	
Gender				
Male	337(41.8%)	189(39.5%)	148(45.3%)	0.12
Female	469(58.2%)	290(61.8%)	179(54.7%)	
Ethnic origin				
Caucasian	311(38.6%)	229(47.8%)	82(25.1%)	<0.001
Asian	99(12.3%)	38(7.9%)	61(18.7%)	
Afro-Caribbean	59(7.3%)	19(4%)	40(12.2%)	
Other	72(8.9%)	41(8.6%)	31(9.5%)	
Unknown	265(32.9%)	152(31.7%)	113(34.6%)	
Age				
Median	70	72	67	<0.001
IQR	63-77	64-79	61-74	
<= 65 years	283(35.1%)	144(30.1%)	139(42.5%)	<0.001
> 65 years	523(64.9%)	335(69.9%)	188(57.5%)	
Follow-up (months)				
Median	13.8	12.9	14.97	0.001
IQR	7.3-22.8	6.77-20.07	7.83-26.43	
Diabetes type				
IDDM	-	-	37(11.3%)	
NIDDM	-	-	290(88.7%)	
Diabetic retinopathy				
None	-	-	104(31.8%)	
NPDR	-	-	137(41.9%)	
PDR	-	-	86(26.3%)	
Retinitis pigmentosa	12(1.5%)	11(2.3%)	1(0.3%)	0.02
Surgeon's grade				
Resident	420(52.1%)	262(54.7%)	158(48.3%)	0.04
Fellow/Consultant	306(38%)	179(37.4%)	127(38.8%)	
Unknown grade	80(9.9%)	38(7.9%)	42(12.8%)	
IOL				
PMMA	114(14.1%)	62(12.9%)	52(15.9%)	0.04
PH silicone	647(80.3%)	397(82.9%)	250(76.5%)	
3-piece silicone	45(5.6%)	20(4.2%)	25(7.6%)	
Postop inflammation	62(7.7%)	43(9%)	19(5.8%)	0.10
Vitrectomy	114(14.1%)	82(17.1%)	32(9.8%)	0.003

IDDM=insulin-dependent diabetes mellitus; NIDDM=non-insulin dependent diabetes mellitus, NPDR=non-proliferative diabetic retinopathy; PDR=proliferative diabetic retinopathy, PMMA=polymethylmethacrylate; PH=plate-haptic

Table 2-2. Incidences of Nd:YAG capsulotomy in diabetic and non-diabetic patients

	Non-Diabetic (n=479)				Diabetic (n=327)			
	No. of patients : No. lost to follow-up	No of capsulotomy	% incidence	95% Confidence interval	No. of patients : No. lost to follow-up	No. of capsulotomy	% incidence	95% Confidence interval
Up to 1 year	479:200	40	10.6	7.9, 14.1	327:118	24	9	6.1, 13
>1 year-2 years	239:140	25	14.8	10.2, 20.9	185:92	13	9.4	5.6, 15.3
>2 years-3 years	74:44	11	21.2	12.2, 34	80:42	9	15.3	8.2, 26.5
>3 years-4 years	19:10	4	28.6	11.7, 54.7	29:21	1	5.4	1, 25.2
>4 years-5 years	5:4	0	0	0, 56.2	7:4	0	0	0, 43.5

2.1.4.3 Risk factors for Nd:YAG capsulotomy

We constructed a Cox proportional hazard regression model (Table 2-3) that included gender, age (<65 or \geq 65), ethnic origin, diabetes mellitus, pars plana vitrectomy, surgeon's grade, IOL type, postoperative inflammation and retinitis pigmentosa as potential risk factors. The model revealed that a decreased risk of Nd:YAG capsulotomy was associated with diabetes mellitus, [HR= 0.69; 95% CI (0.47, 0.99)] and with the use of 3-piece silicone IOLs [HR= 0.25; 95% CI (0.10, 0.63)] while an increased risk was associated with patient age of 65 years or younger [HR=1.58; 95% CI (1.09, 2.27)], postoperative inflammation [HR=2.63; 95% CI (1.56, 4.42)] and vitrectomy surgery [HR=1.85; 95% CI (1.20, 2.83)] (Figures 2-1 a to e).

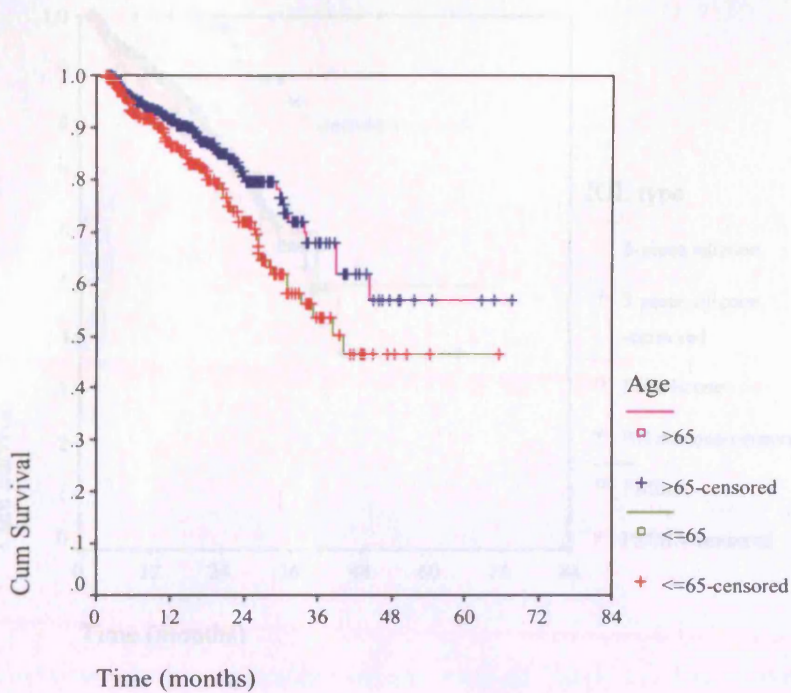
In the non-diabetic subgroup (Table 2-4), a Cox proportional hazard model that included the same variables (except diabetes mellitus) showed that male gender [HR=1.63; 95% CI (1.04, 2.57); $p=0.03$], vitrectomy [HR=1.90; 95% CI (1.09, 3.33); $p=0.02$], postoperative inflammation [HR=2.78; 95% CI (1.51, 5.12); $p=0.001$] were associated with an increased risk while 3-piece silicone IOL with a reduced risk for Nd:YAG capsulotomy [HR=0.18; 95% CI (0.04, 0.82); $p=0.03$]. In the diabetic subgroup (Table 2-4), a model that included, instead of diabetes mellitus, diabetes type (IDDM vs. NIDDM), duration, and diabetic retinopathy grade (None, NPDR and PDR), only vitrectomy was significantly associated with an increased risk of Nd:YAG capsulotomy [HR=2.47; 95% CI (1.26, 4.83); $p=0.008$].

Table 2-3. Multivariate Cox regression analysis of the factors associated with Nd:YAG Capsulotomy

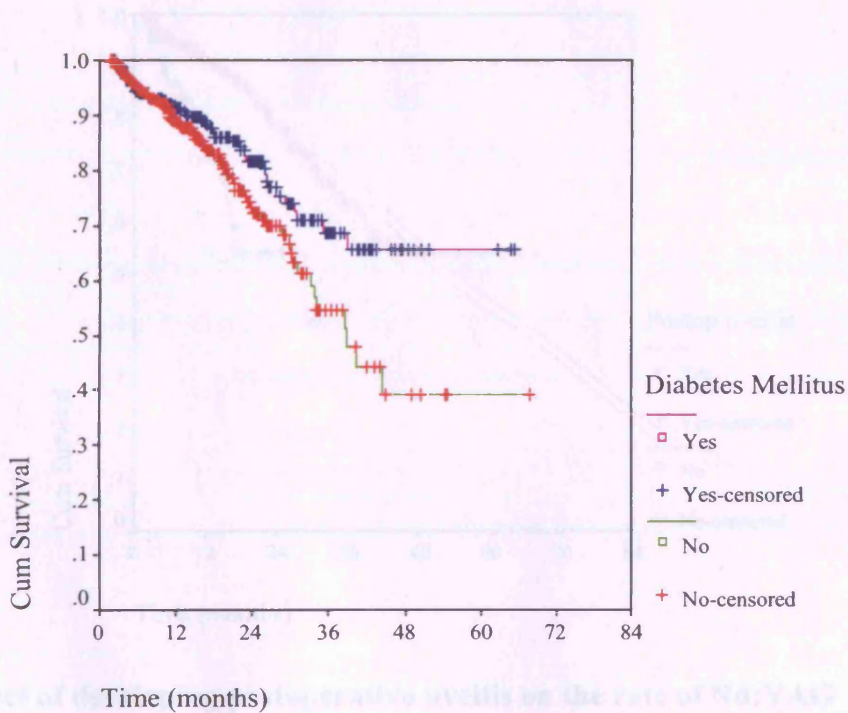
	Hazard ratio	95% Confidence interval	<i>p</i>
Diabetes mellitus			
No	Reference		
Yes	0.69	0.47, 0.99	0.047
Age			
>65	Reference		
<=65	1.58	1.09, 2.27	0.01
Postop inflammation (within 3 months)			
No	Reference		
Yes	2.63	1.56, 4.42	0.0003
IOL type			
PMMA	Reference		
PH silicone	0.94	0.59, 1.49	0.79
3-piece silicone	0.25	0.10, 0.63	0.003
Vitrectomy			
No	Reference		
Yes	1.85	1.20, 2.83	0.005

Table 2-4. Multivariate Cox regression analysis of the factors associated with Nd:YAG capsulotomy in the two subgroups

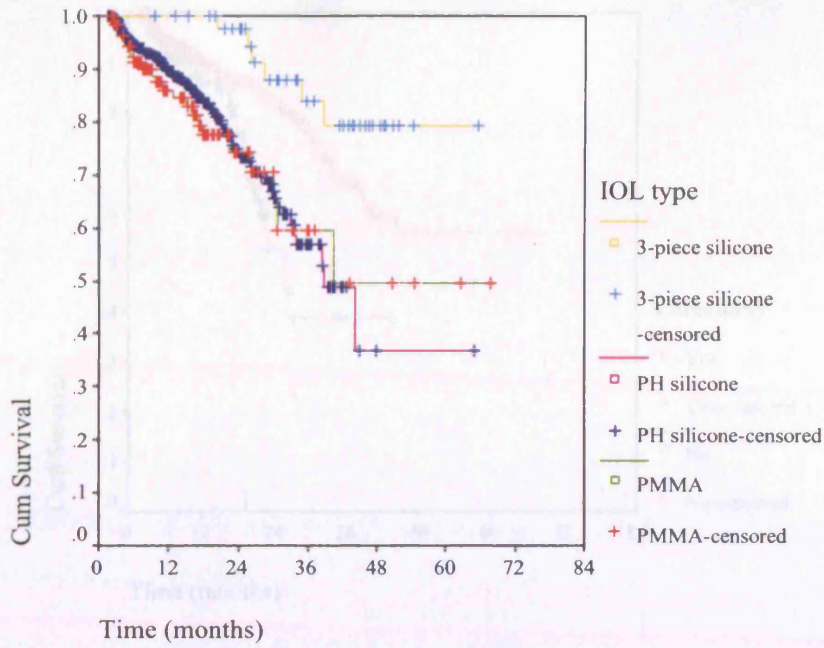
	Non-diabetic subgroup			Diabetic subgroup		
	Hazard ratio	95% Confidence interval	<i>p</i>	Hazard ratio	95% Confidence interval	<i>p</i>
Surgeon grade						
Resident				Reference		
Consultant				0.86	0.45,2.10	0.74
Unknown				1.98	0.85,4.57	0.11
Gender						
Female	Reference					
Male	1.63	1.04,2.57	0.03			
Age						
>65	Reference			-	-	-
<=65	1.49	0.94, 2.36	0.09			
IOL type						
3-piece silicone	Reference					
PH silicone	6.98	1.65, 29.46	0.008	-	-	-
PMMA	5.48	1.22, 24.68	0.03			
Postop inflammation						
No	Reference			-	-	-
Yes	2.78	1.51, 5.12	0.001			
Vitrectomy						
No	Reference			Reference		
Yes	1.90	1.09, 3.33	0.03	2.47	1.26,4.83	0.008



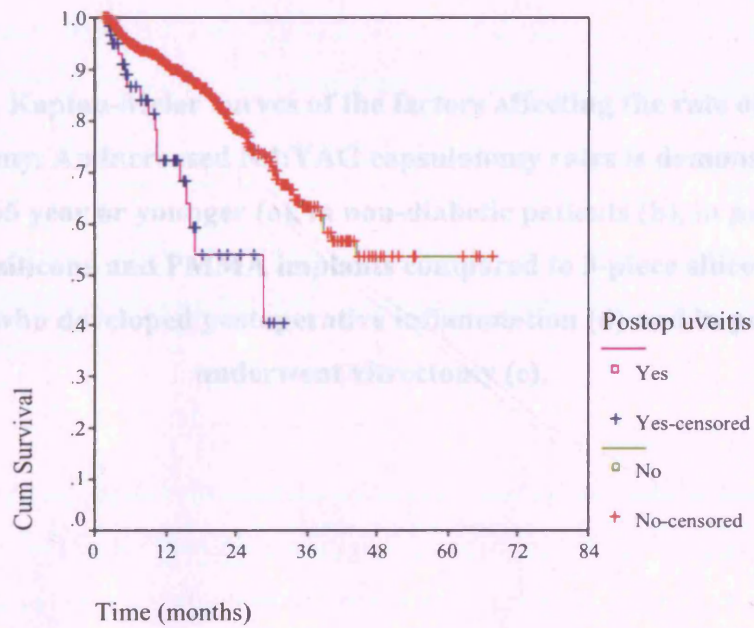
a. The effect of age on the rate of Nd:YAG capsulotomy



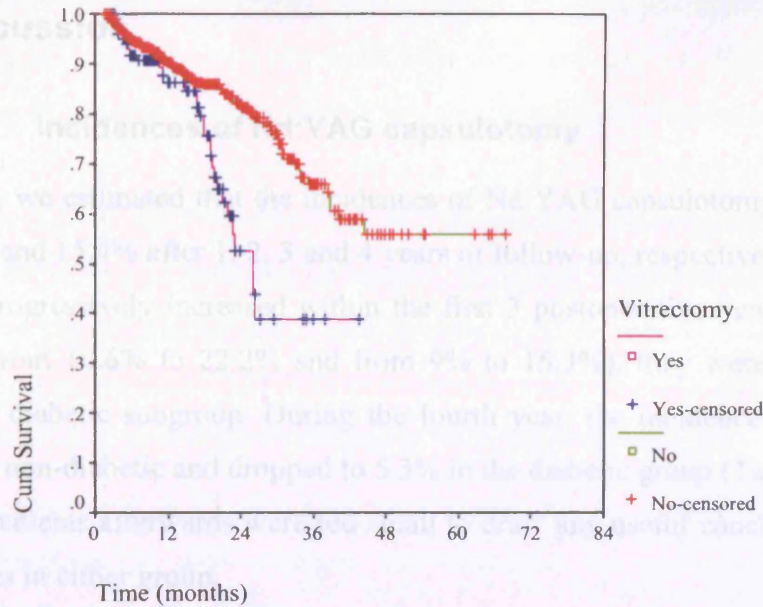
b. The effect of diabetes mellitus on the rate of Nd:YAG capsulotomy



c. The effect of IOL type on the rate of Nd:YAG capsulotomy



d. The effect of developing postoperative uveitis on the rate of Nd:YAG capsulotomy



e. The effect of vitrectomy operation on the rate of Nd:YAG capsulotomy

Figure 2-1. Kaplan-Meier curves of the factors affecting the rate of Nd:YAG capsulotomy. An increased Nd:YAG capsulotomy rates is demonstrated in patients of 65 year or younger (a), in non-diabetic patients (b), in patients with plate-haptic silicone and PMMA implants compared to 3-piece silicone IOLs (c), in patients who developed postoperative inflammation (d) and in patients who underwent vitrectomy (e).

2.1.5.2. Effect of GR on the rate of PCO

We noticed, as suggested by Baratz study (Baratz et al, 2001), that the steady increase of capsulotomy rate did not agree to our data. While this can be attributed to the improvement in the surgical technique, especially with the use of small-incision and foldable IOLs, or even to a possible natural decline in LHC surgical aggressiveness (retrospective study (Kane et al, 1997; Sarda et al, 2002), our findings (the lower rate of Nd:YAG capsulotomy, the sharp drop after the third year and the lower rate of Nd:YAG capsulotomy in diabetic patients) suggest a role for the presence of diabetes mellitus in lowering the long-term incidence of Nd:YAG capsulotomy and possibly PCO.

2.1.5 Discussion

2.1.5.1 Incidences of Nd:YAG capsulotomy

In this study, we estimated that the incidences of Nd:YAG capsulotomy were 9.9%, 12.3%, 18% and 15.4% after 1, 2, 3 and 4 years of follow-up, respectively. While the incidences progressively increased within the first 3 postoperative years in the two subgroups (from 10.6% to 22.2% and from 9% to 15.3%), they were consistently lower in the diabetic subgroup. During the fourth year, the incidence increased to 28.6% in the non-diabetic and dropped to 5.3% in the diabetic group (Table 2-3). The numbers of patients afterwards were too small to draw any useful conclusions about the incidences in either group.

These incidences are generally similar to those reported by Baratz et al (Baratz *et al*, 2001) and Ando et al (Ando *et al*, 2003). They estimated cumulative probabilities of 15 to 18.5% and 32.7 to 33% after 3 and 5 years of follow-up, respectively. Both studies, however, reported lower probabilities within one year of follow-up (6% & 1.95%). This could be related to the inclusion in their studies of patients who had hydrophobic acrylic implants (1.2% and 12.6%). These implants were proved to have a lower PCO rate than PMMA and silicone implants (Ingram *et al*, 1980; Ursell *et al*, 1998; Hollick *et al*, 1999c) and the patients must have been entered late in their studies and hence perhaps comprised a significant proportion of those followed up within the first year.

2.1.5.2 Effect of DM on the rate of PCO

We noticed, as suggested by Baratz study (Baratz *et al*, 2001), that the steady increase of capsulotomy rate did not appear to continue. While this can be attributed to the improvement in the surgical technique, especially with the use of small incisions and foldable IOLs, or even to a possible natural decline in LEC survival suggested in experimental studies (Kato *et al*, 1997b; Saika *et al*, 2002), our findings (the lower incidence of Nd:YAG capsulotomy, the sharp drop after the third year and the lower risk of Nd:YAG capsulotomy in diabetic patients) suggest a role for the presence of diabetes mellitus in lowering the long-term incidence of Nd:YAG capsulotomy and possibly PCO.

While neither of the above studies found a difference between diabetic and non-diabetic patients, conflicting reports exist regarding the rate of PCO in the two groups. Lower PCO rates in diabetic patients were reported by Knorz and coauthor (Knorz *et al*, 1991) in a retrospective study of 939 eyes following ECCE and an average follow-up of 26.3 months and by Zaczek and Zetterstrom (Zaczek & Zetterstrom, 1999) in a prospective study following phacoemulsification and implantation of heparin-coated IOLs. In a prospective randomised trial, Hayashi *et al* (Hayashi *et al*, 2002) found that both PCO density and Nd:YAG capsulotomy rate were significantly higher in diabetic patients after 3 years of follow-up.

The conflict of reported PCO rates between studies could be related to variation in the clinical features of their patients, the threshold for performing Nd:YAG capsulotomy or the duration of follow-up. The progression of retinopathy reported to occur after cataract extraction (Liao & Ku, 2003; Hauser *et al*, 2004) could increase the clinician's threshold to perform Nd:YAG capsulotomy for fear of inducing macular oedema or because the decline in visual acuity could be attributed to the retinopathy when in fact PCO could, at least partly, be contributory to causing the poor vision. However, a plausible biological explanation for the lower PCO rate in diabetics can be related to the detrimental effect of accumulating intracellular sorbitol (Kinoshita, 1974; Lin *et al*, 1991; Takamura *et al*, 2003; Ramana *et al*, 2003) and that of free radicals and oxidative stress (Hothersall *et al*, 1988; Kubo *et al*, 2004) on proliferation and survival of LECs and their decreased density in the diabetic capsular bag (Saitoh *et al*, 1990; Struck *et al*, 2000). These effects, presumably reinforced by the longer postoperative duration, perhaps explain the drop in PCO rate in diabetics that manifested after the third year in our series (Table 2-2).

2.1.5.3 Other risk factors of PCO in non-diabetic and diabetic patients

We also found that Nd:YAG capsulotomy was more likely in patients who were 65 years or younger, those who underwent pars plana vitrectomy or developed postoperative inflammation within 3 months and with implantation of PMMA or plate-haptic silicone IOLs (Figures 2-1 a to e). While, in addition, male sex increased the risk of Nd:YAG capsulotomy and age had a non-significant effect in non-diabetic patients, only vitrectomy increased the risk in diabetic patients. The disturbance of LEC metabolism induced by the presence of diabetes or, perhaps, the relatively

smaller sample sizes might have effaced the effect of some of the risk factors in the subgroups.

2.1.5.3.1 Age

The increased Nd:YAG capsulotomy rate in younger individuals has been attributed to the increased proliferative capacity of the LECs in younger patients demonstrated in experimental studies (Liu *et al*, 1996; Wormstone *et al*, 1997). This can also conceivably be due to the increased visual demands in younger patients.

2.1.5.3.2 Pars plana vitrectomy

The increased Nd:YAG capsulotomy rate in patients who underwent pars plana vitrectomy concurs with the findings by Helbig *et al* (Helbig *et al*, 1996), and Pinter and Sugar (Pinter & Sugar, 1999). This could be related to increased LEC proliferation or collagen formation as a result of surgical trauma. The development of posterior capsular plaques commonly described during cataract extraction after pars plana vitrectomy indirectly supports this hypothesis (Grusha *et al*, 1998; Pinter & Sugar, 1999; Chang *et al*, 2002). Another explanation is the possible increased exposure to retina-derived growth factors that could stimulate LEC proliferation (Jacob *et al*, 1988). This was suggested by Jones *et al* (Jones *et al*, 1995), who described massive LEC proliferation at the edge of the capsulotomy in 6 of 8 eyes, all of which had posterior segment pathology.

2.1.5.3.3 Diabetic retinopathy

In our study, as in the study by Hayashi *et al*, 2002 (Hayashi *et al*, 2002), although retinopathy had no significant effect on Nd:YAG capsulotomy rate, a possible effect could not be completely ruled out. The forward diffusion of retina-derived growth factors into the anterior segment (Aiello *et al*, 1994), which can be enhanced by vitrectomy (Noma *et al*, 2002), could provide a stimulatory drive for LEC proliferation. This was also suggested in Jones' study (Jones *et al*, 1995) as 4 of their patients had proliferative diabetic retinopathy.

2.1.5.3.4 IOLs: Polymethylmethacrylate (PMMA) and plate-haptic silicone versus 3-piece silicone

PMMA and plate-haptic silicone IOLs were associated with a higher risk for Nd:YAG capsulotomy in comparison with 3-piece-silicone IOLs. This is in agreement with other studies that have shown a higher PCO rate with PMMA when compared to 3-piece silicone IOLs (Hayashi *et al*, 1998c; Olson & Crandall, 1998). In earlier studies by Mamalis *et al* (Mamalis *et al*, 1996b) and Cumming *et al* (Cumming, 1993) a lower rate of PCO with plate-haptic silicone IOLs than with 3-piece silicone IOLs was reported. In a postmortem analysis of the Nd:YAG rates with different IOLs, Apple *et al* (Apple *et al*, 2001) found that foldable IOLs had a lower rate than rigid PMMA IOLs (14.1% vs. 31.1%). Schmidbauer *et al* (Schmidbauer *et al*, 2001b) later reported that 3-piece silicone IOLs had Nd:YAG capsulotomy rates between 14.5% to 23.3% and plate-haptic silicone 15.3% to 25%. The rates vary between small-hole and large-hole implants (possibly due to of the advances in surgical technique rather than to the hole size).

2.1.5.3.5 Postoperative inflammation

Our study also suggests an independent risk associated with the occurrence of postoperative inflammation for the development of PCO. This relationship, which is consistent with the clinical impression of many surgeons, has not been suggested in a clinical study before. The interaction between the presence of residual LECs, their proliferation and the development of postoperative inflammation seem to pose a clinical conundrum, similar to the evolutionary ones, of ‘which came first?’ Clinical and experimental studies have demonstrated that cytokine release from residual LECs after cataract extraction can excite postoperative inflammation (Nishi & Nishi, 1992; Nishi *et al*, 1992; Nishi *et al*, 1999). On the other hand, the rate of LEC proliferation has been shown to increase in a protein rich environment (Quinlan *et al*, 1997; Davidson *et al*, 2000; Wallentin *et al*, 1998; Wormstone *et al*, 1997), which would be similar to that resulting from inflammation due to the influx of growth factors through the damaged blood-aqueous barrier and the consequent decreased concentration of aqueous transforming growth factor-beta (TGF- β) that would normally inhibit LEC proliferation (Wormstone *et al*, 2002; de Boer *et al*, 1994). It is most likely that these two mechanisms, as intimately consequential as they may look,

are independent of each other as several other factors are associated with postoperative inflammation, such as incision size (Oshika *et al*, 1994; Oshika *et al*, 1998a) and surgical technique (Pande *et al*, 1996b). In addition LECs can grow independently of external growth factors (Wormstone *et al*, 1997).

This finding raises the question of whether prophylactic or more aggressive treatment of postoperative inflammation would be a worthwhile strategy in patients at risk of developing postoperative inflammation and in the presence of other risk factors e.g. young age. The inhibitory effect of steroids and other antiinflammatory medications on the LECs proliferation and extracellular matrix formation has been suggested in experimental studies (Mansfield *et al*, 2004; Cortina *et al*, 1997) but remains to be established clinically.

2.1.5.3.6 Gender

The relationship between gender and Nd:YAG capsulotomy is not clear and is difficult to explain. In this study we found that, in contrast to that by Ando *et al* (Ando *et al*, 2003), in the non-diabetic group, men were more likely to have Nd:YAG capsulotomy than women. Ando *et al* explained the excess of PCO in the female patients by the gender difference in attitude towards health problems, with more women seeking medical advice and reporting symptoms more readily than men. This, however, varies across different cultures and the presence of more ethnically diverse population in our study might have reversed that effect. Moreover, in women, the protective effect of oestrogen against TGF- β (Hales *et al*, 1997; Chen *et al*, 2004), implicated in cellular trans-differentiation and extracellular matrix formation for PCO (Davidson *et al*, 2000; Wormstone *et al*, 2002), provides a possible hormonal explanation in favour of our finding.

2.1.6 Limitations

The retrospective nature is an apparent limitation of this study because of the inability to account for all potential confounders. Attempts to avoid bias because of the retrospective design of this study included: the large sample size, the continuous nature of the series, drawing the sample from a single service in the hospital to ensure as much as possible homogeneity of the indications for Nd:YAG capsulotomy and the random inclusion of one eye in patients with bilateral surgeries. Also, we

used multivariate analysis to identify the independent risk factors after accounting for all possible clinical and surgery-related confounders.

2.1.7 Conclusion

Despite its limitations, this study is an addition to other large-scale studies that aimed to identify the potential risk factors of developing clinically significant PCO, which is the preliminary step towards developing strategies of preventing its development and planning for the review and treatment of predisposed patients. It suggests that diabetic patients have a lower long-term incidence and risk of PCO and an increased risk of PCO in association with younger age, postoperative inflammation, vitrectomy surgery and PMMA or plate-haptic silicone implants in comparison to 3-piece silicone implants. Future studies should perhaps aim at further exploring the long-term effect of diabetes and of prophylactic control of postoperative inflammation in predisposed patients on the incidence and risk of developing PCO.

2.2 POSTERIOR CAPSULAR OPACIFICATION AFTER IMPLANTATION OF PLATE HAPTIC SILICONE AND HYDROPHOBIC ACRYLIC INTRAOCULAR LENSES IN DIABETIC PATIENTS: A PILOT RANDOM ISED CLINICAL TRIAL

2.2.1 Introduction

The IOL physical properties, including the optic material and design were shown to be important determinants of the rate of PCO development (Ursell *et al*, 1998;Hollick *et al*, 1999c). Also, postoperative breakdown of the blood-aqueous barrier was related to the type of IOL (Abela-Formanek *et al*, 2002c;Miyake *et al*, 1996;Schauersberger *et al*, 1999) and could potentially affect the rate of PCO development.

Chiron C11UB (Bausch & Lomb) and AcrySof MA 60 BM (Alcon Inc.) are two of the commonly used implants that are made of different materials and have different designs. The former is a single-piece second-generation silicone implant that has a 6-mm biconvex optic, plate-haptics and an overall diameter of 10.5mm (Figure 1-4). The latter is a 3-piece hydrophobic acrylic implant that has a 6-mm biconvex optic and a polymethylmethacrylate haptics that make 10° angles with the optic and an overall diameter of 12.5 mm. Chiron C11UB IOL is normally implanted using an injector, which allows introduction of the IOL through a relatively small corneal incision (3.2 to 3.5 mm). Acrysof hydrophobic acrylic IOL, on the other hand, is inserted using lens forceps and needs corneal incision enlargement. This, in addition to increasing the incidence of wound-related complications (Kumar *et al*, 2001), was found to increase blood-aqueous barrier breakdown and postoperative inflammatory reaction (Oshika *et al*, 1992;Pande *et al*, 1996b;Chee *et al*, 1999). Moreover, some studies have established a greater inflammatory response and blood-aqueous barrier breakdown after hydrophobic acrylic IOL implantation (Abela-Formanek *et al*, 2002c;Miyake *et al*, 1996). In the meantime, previous studies of plate-haptic silicone IOLs have established favourable results (Maar *et al*, 2002;Kent *et al*, 1997) and

suggested a lower PCO rate than with 3-piece silicone IOLs (Cumming, 1993; Mamalis *et al*, 1996b).

In diabetic patients, posterior capsular opacification obstructs the posterior segment view and can interfere with timely diagnosis and treatment of sight-threatening retinopathy and postoperative inflammation was shown to occur more frequently in diabetic patients, especially those with diabetic retinopathy (Zaczek & Zetterstrom, 1998). Comparison of the above two implants in diabetic patients has not been previously published.

2.2.2 Aims

In this pilot randomised clinical trial, we aimed to compare the magnitude of inflammation and extent of PCO up to one year after surgery in a group of diabetic patients who were randomised to be given one the above two IOLs.

2.2.3 Patients and methods

After approval of the study protocol by Moorfields ethical committee, patients were recruited consecutively from those who had diabetes mellitus and were listed for phacoemulsification cataract extraction. The study was performed in accordance with the tenets of Helsinki treaty.

2.2.3.1 Inclusion and exclusion criteria

Recruitment was carried out between March 2001 and February 2002. Patients were considered eligible for inclusion if they were diagnosed with diabetes mellitus (according to the World Health Organization and American Diabetic Association criteria), had cataract sufficient to either cause visual disturbance or impair the fundus view and gave consent to be included in the study. Both type I and type II diabetic patients were eligible.

Exclusion criteria included patients on oral steroids or medications for glaucoma, coexistent ocular disease unrelated to diabetes that were likely to reduce visual acuity, e.g. age-related macular degeneration, amblyopia or retinal venous occlusion. Also, patients with iris neovascularisation or those who had had prior intraocular

surgery, e.g. trabeculectomy or vitrectomy, were excluded. Also, capsular complication lead to the patient being excluded and replaced.

2.2.3.2 Randomisation

Patients were randomised when in the operating theatre using a computer-generated random number to have either an injectable plate-haptic silicone (Chiron, C11UB, Bausch and Lomb) or a hydrophobic acrylic (AcrySof, MA60BM, Alcon) IOL. The C11UB plate-haptic silicone IOL has a 6-mm biconvex surface optic and an overall diameter of 10.5mm (Figure 1-4). The hydrophobic acrylic IOL, also, has a 6-mm biconvex optic but polymethylmethacrylate haptics that make an angle of 10° and an overall diameter of 12.5 mm.

2.2.3.3 Preoperative management

Before surgery, mydriasis was achieved using G. Phenylephrine 5 % and G. Cyclopentolate 1 % six times within an hour and a half prior to surgery. Topical anaesthesia was used on all patients using G. Amethocaine and that was coupled with a single quadrant subtenon injection of 3 ml of Lignocaine in 2 patients. Preoperative assessment included measuring the best-corrected visual acuity (BCVA) using the logarithm of the minimum angle of resolution (logMAR) chart at 4 meters in addition to routine anterior and posterior segment examination.

2.2.3.4 Surgery

A standard phacoemulsification was carried out by a single surgeon (JGD) through a 3.2mm self-sealing clear corneal section. Hydroxypropylmethylcellulose (HPMC) viscoelastic was used to fill the anterior chamber and a continuous curvilinear capsulorhexis was performed followed by hydrodissection of the nucleus and divide-and-conquer removal of the nucleus. Manual aspiration of cortical lens matter was conducted using a Simcoe irrigation-aspiration cannula and a balanced salt solution containing 1 ml of 1:1000 adrenaline per 500 ml. No attempt was made to remove the subcapsular LECs. The viscoelastic was then used to fill in the capsular bag before placement of the IOL. The occurrence of a posterior capsular tear or radial extension of the capsulorhexis edge led to the patient being excluded.

2.2.3.5 Postoperative management

Patients were routinely examined immediately after surgery and prescribed G. Dexamethasone 0.1% four times a day for two weeks then twice a day for two weeks, and G. Chloramphenicol four times a day for two weeks. Acetazolamide (Diamox) 250mg QDS for 2 days was prescribed for any elevation of intraocular pressure above 21 mmHg. For the purpose of the study, patients were reviewed at 2-3 weeks, 6 months and 12 months and additional visits were arranged, if needed, for assessment and treatment of postoperative inflammation and/or diabetic retinopathy (Dowler *et al*, 1999;Dowler & Hykin, 2001).

At each of the postoperative visit, assessment was made of anterior capsular opening and posterior capsular opacification as well as of the anterior chamber flare and cells using Kowa FC 1000 laser flare-cell meter. Seven consecutive readings were taken and after discarding the highest and lowest values, the average of the remaining readings was taken. The flare was expressed as photons/millisecond and the cells as number/0.075 mm³. Also, logMAR BCVA at 4 meters and Pelli-Robson contrast sensitivity at 1 meter were measured at each visit.

2.2.3.6 Posterior capsule imaging system

Standardized retro-illumination photographs were taken at each of the 3 visits using St Thomas' digital retro-illumination camera system, described in more details elsewhere (1.1.5.2.2.3.2.3.2. Digital photography). The system is based on a Zeiss 120 slit lamp frame with specially adapted optics to provide axial illumination to the camera light path from a flash pack through a fibre-optic cable and the images are acquired through a 420 digital camera (Eastman-Kodak, Rochester, NY). The system produces high definition, evenly illuminated images of the posterior capsule that are accessed directly by computer. The reproducibility of the system was assessed before and its short-term variability was estimated to be less than 10% (Hollick *et al*, 1999c).

Only one observer carried out the analysis for the PCO pictures. Because of the distinctive shapes of the IOLs, the observer could not be masked to the IOL type. The area of the posterior capsule assessed was that not obscured by the anterior capsular rim (the mask). That area, which corresponds to that of the anterior capsular opening, was measured in pixels after being defined manually on a 21-inch monitor

screen using a mouse. Dedicated software was used to calculate the area of opacity using a technique known as image segmentation. The software allows separation of the pixels into binary classes of opaque and clear areas. The areas of opacified posterior capsule are characterized by having an increased texture of the corresponding area of the image, whereas clear areas have little or no texture. From the binary values the area of PCO is calculated and expressed as percentage of the mask area.

2.2.3.7 Statistical analysis

The primary outcome of interest was the percentage of the area of opacified posterior capsule. Other outcome measures were anterior chamber flare value and cell count, anterior capsular opening size, logMAR BCVA and Pelli-Robson contrast sensitivity.

For the purpose of description, the mean and standard deviation (SD) were used. Categorical data were compared using the Chi-squared test. Between-group comparison of the percentage of the area of PCO, flare value, cell count and the size of the anterior capsular opening (in pixels) at the different visits between the two groups was carried out using either independent Student-t or Mann-Whitney test after checking the data for normality of distribution. Within-group analysis of the changes in the above measurements over the follow-up period in each group was carried out using Friedman within-group analysis. A *p* value of <0.05 was considered statistically significant. A post hoc analysis showed that the study had between 97.9% and 99% power for 2-sided and 1-sided tests, respectively, to detect the difference in the area of PCO.

2.2.4 Results

2.2.4.1 Patient characteristics

We recruited 43 patients between March 2001 and February 2002, three of whom opted out. Four patients were excluded because two of those randomised to acrylic and one randomised to plate-haptic silicone IOL had posterior capsular tears. Another patient, who was randomised to a plate-haptic silicone IOL, had a radial extension of the capsulorhexis and was excluded, which left 35 patients. During the study 2 patients died and the overall follow-up rate was 60% after 1 year. The

recruitment was terminated in February 2002 after the results suggested increased PCO in patients with plate-haptic silicone IOLs.

Demographic data of the two groups of patients are detailed in Table 2-5. There was no significant difference in the mean age, preoperative logMAR BCVA, the gender distribution or grade of diabetic retinopathy between the two groups.

Table 2-5. Clinical features of patients in the non-diabetic and diabetic groups

	PH Silicone (N=15)	Hydrophobic Acrylic (No=20)
Age (years)		
Mean (SD)	72.5(9.6)	68.6(12.1)
Median	71	69.3
IQR	65.2-80.3	62.2-75.8
M:F	8:7	9:11
IDDM: NIDDM	2:13	2:18
Diabetic retinopathy		
No	8	10
NPDR	2	6
PDR	5	4
Preop logMAR BCVA		
Mean	0.66(0.8)	0.62(0.7)
Median	.38	0.51
IQR	0.38 to 0.80	0.51 to 0.96

SD=standard deviation; IQR=interquartile range, PH=plate-haptic; SD=standard deviation; M=male; F=female; IDDM= insulin- dependent diabetes mellitus; NIDDM=non-insulin-dependent diabetes mellitus

2.2.4.2 Between-group analysis: inflammatory indices, ACO and PCO difference between the two groups

Between-group analysis (Table 2-6 & Figures 2-2, 2-3 & 2-4) showed that at 2-3 weeks, there was a higher flare value in the hydrophobic acrylic than in the PH silicone group but the difference was only of borderline significance ($p=0.08$). No significant difference was found in cell count, size of the anterior capsular opening (the mask size) or the percentage of PCO between the two groups. Within the first month, 5 patients developed clinically significant inflammation that required additional topical steroid treatment, 3 in the PH silicone IOL group (20%) and 2 in the hydrophobic acrylic group (10%). This difference was not statistically significant.

At 6 and 12 months, there was no significant difference in flare value or cell count between the two groups. At 6 months, the anterior capsular opening size was significantly smaller in the PH silicone group ($p=0.04$) but the difference was not statistically significant at 12 months ($p=0.08$). The average percentage area of PCO was significantly greater in patients with PH silicone than in those with hydrophobic acrylic IOLs ($p=0.002$ & $p=0.002$; at 6 and 12 months, respectively). LogMAR visual acuity and Pelli-Robson contrast sensitivity scores were not significantly different between the two groups at any postoperative visit.

Table 2-6. Anterior chamber reaction and percentage of PCO at the different postoperative periods

	PH silicone Mean (SD)	Hydrophobic acrylic Mean (SD)	<i>p</i> *
2-3 weeks			
AC Flare	15.3 (7.3)	26.9 (18.1)	0.08
AC cells	2.9 (2.5)	6.3 (7.9)	0.2
Mask size in pixels†	431941.3 (82675.9)	411965.5 (77615.9)	0.5
% of PCO	10 (13.2)	10.3 (8.3)	0.9
6 months			
AC Flare	11.1 (4.3)	11.2 (5.4)	0.9
AC cells	0.03 (0.08)	0.10 (0.2)	0.5‡
Mask size in pixels	371652.1 (93355.7)	440504.2 (56537.8)	0.04
% of PCO	27.2 (13.9)	10.9 (8.7)	0.002
12 months			
AC Flare	9.5 (3.2)	11.5 (7.5)	0.5
AC cells	0 (0)	0 (0)	0.9
Mask size in pixels	383974.1 (104230.7)	443102.3 (61838.5)	0.08
% of PCO	57.7 (41.1)	13.9 (11.1)	0.002‡

PH=plate-haptic, SD=standard deviation; AC= anterior chamber

* Between-group analysis.

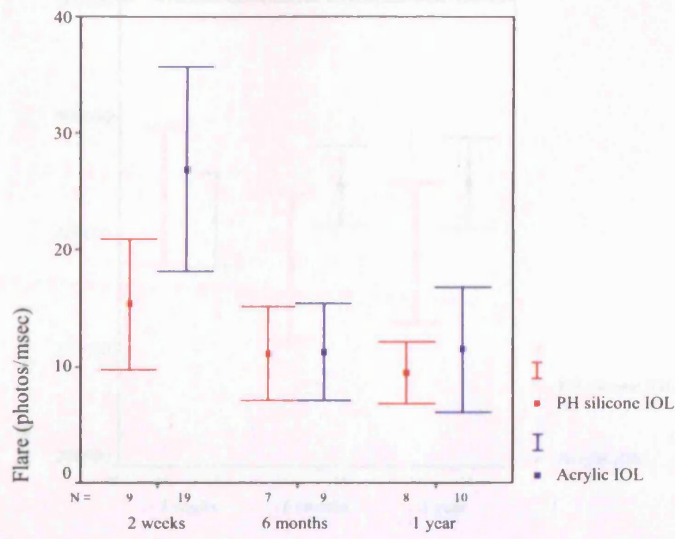
† Corresponds to the size of the anterior capsular opening.

‡Mann-Whitney test used for comparison

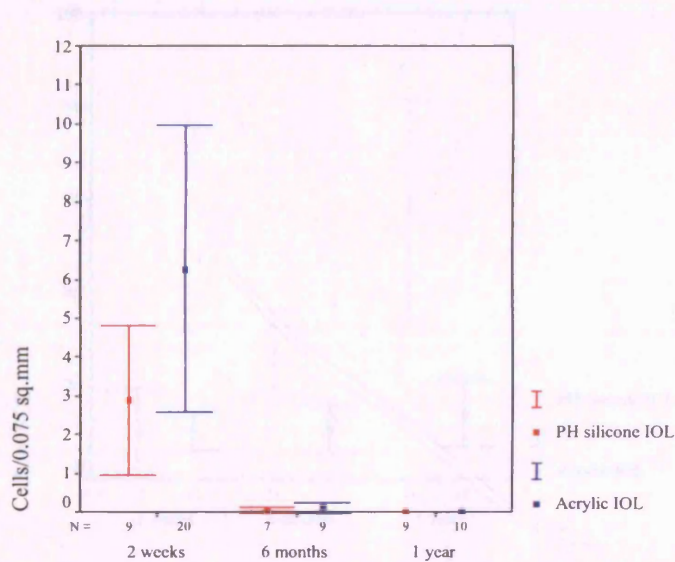
2.2.4.3 Within-group analysis: the inflammatory indices, ACO and PCO in each group over the follow-up period

Within group analysis (Figures 2-2, 2-3 & 2-4) showed a significant reduction in anterior chamber flare value in the hydrophobic acrylic group ($p=0.01$) but not in the PH silicone group ($p=0.47$). Cell count did not change significantly in the two groups over the period of follow-up. The mask size decreased over the follow-up period in both groups but the difference was of borderline significance only in the PH silicone group ($p=0.09$ & 0.9). There was a statistically significant increase in the area of opacified posterior capsule in the PH group ($p=0.003$) but the difference was not significant in the hydrophobic acrylic group ($p=0.4$) (Figure 2-5).

One of the patients in the PH silicone IOL group required Nd:YAG capsulotomy after one year and 4 patients in the hydrophobic acrylic group had less area of PCO at 1 year than at 6 months (Figure 2-6). There was no significant difference in logMAR BCVA or Pelli-Robson CS scores between the three visits in either of the two groups.

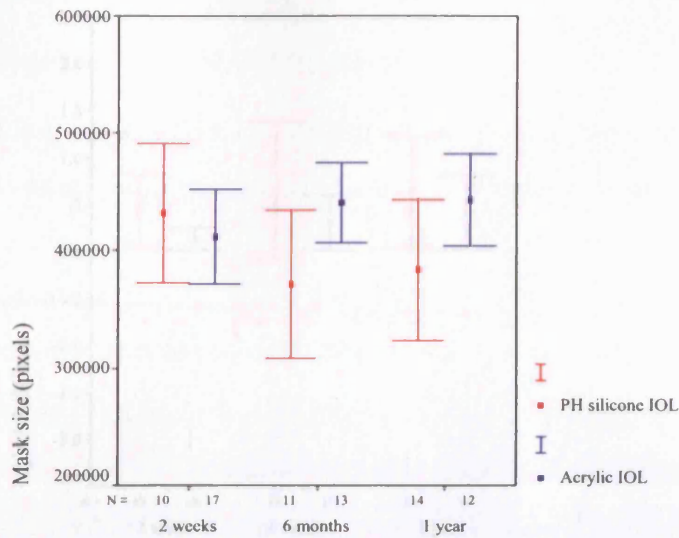


a.

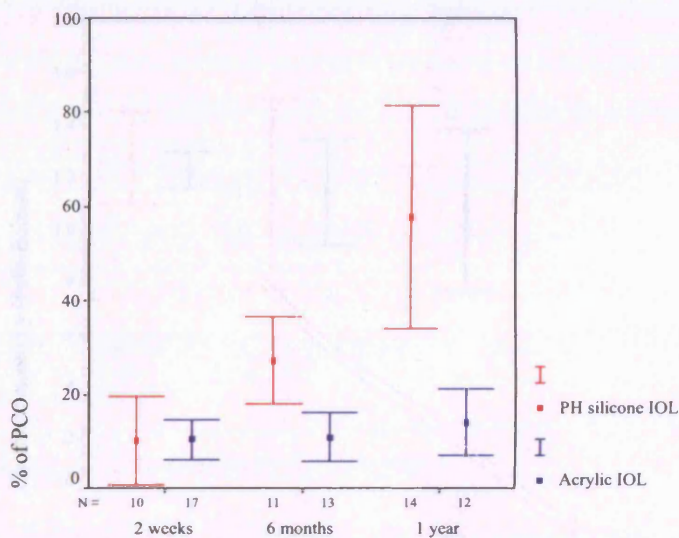


b.

Figure 2-2. Anterior chamber flare (a) and cells (b) in the two groups of patients. Both flare and cells decreased significantly as the time went by, but there was only a borderline significant increase of flare in the Acrylic group in the early postoperative period.



a.



b.

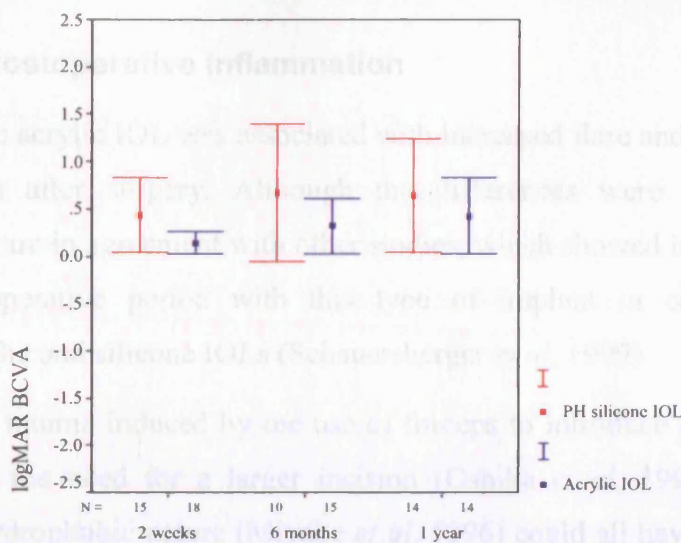
Figure 2-3. The mask size (a) and the percentage of the area of opacified posterior capsule (b) in the two groups of patients. There was a decrease of the mask size in the plate-haptic silicone group and an increase in the area of PCO in the plate-haptic silicone IOL group. Only the latter was statistically significant.

2.2.5 Discussion

2.2.5.1 Postoperative inflammation

The hydrophobic acrylic IOL was associated with increased flare and cells within the first 2-3 weeks after surgery. Although these differences were not statistically significant, they were consistent with those reported in other studies. The early postoperative period with this type of implant or comparison with hydrophobic acrylic IOLs (Schwartz et al., 1997). The mechanical stimuli induced by the use of forceps to insert the hydrophobic acrylic implant, the use of a larger incision (Chakrabarti et al., 1998a) or the hydrophobic acrylic IOLs (Schwartz et al., 1997) could all have contributed to

a.



increasing the flare intensity and cell count in these patients. Notably, however, these changes were not clinically significant as there was no difference between the two groups in the incidence of clinically significant postoperative inflammation (i.e. requiring additional treatment) at any time in the postoperative period. In a study by Zeynalov et al. (2007), the mean flare intensity was significantly higher with the hydrophobic acrylic IOL than with the hydrophobic acrylic IOL. Although the mean cell count was significantly higher with the hydrophobic acrylic IOL than with the hydrophobic acrylic IOL, the relatively small sample size would influence the statistical significance of the results.

2.2.5.2 Posterior capsular contraction

We found that at 6 months postoperatively, the mean PCO was significantly higher in the PH silicone group but there was no

b.

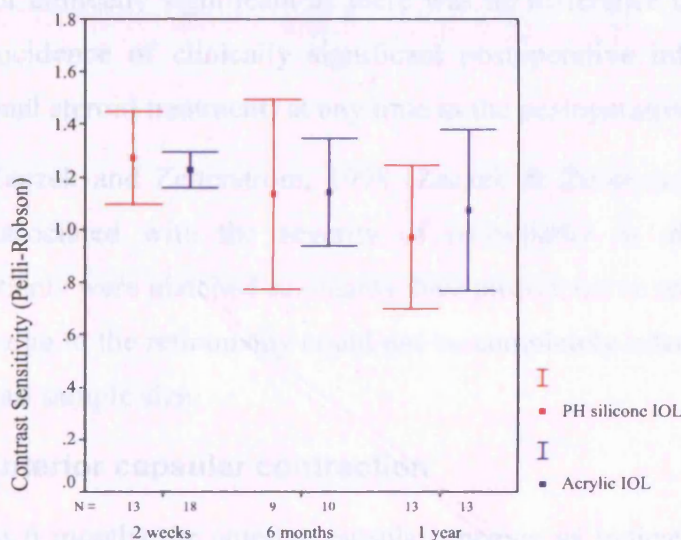


Figure 2-4. Visual acuity (a) and contrast sensitivity (b) in the two groups of patients. Although both function showed some deterioration over time, the differences were not statistically significant.

This finding is consistent with that by Wang et al. (2004) (Wang et al., 2004), who, in an elderly series, found that phacoemulsification with silicone IOLs were associated with higher anterior capsular opacification scores as opposed to increase in incidence of anterior capsular phimosis in comparison with hydrophobic acrylic IOLs.

2.2.5 Discussion

2.2.5.1 Postoperative inflammation

The hydrophobic acrylic IOL was associated with increased flare and cells within the first 2-3 weeks after surgery. Although the differences were not statistically significant, they are in agreement with other studies, which showed increased flare in the early postoperative period with this type of implant in comparison with hydrophilic acrylic and silicone IOLs (Schauersberger *et al*, 1999).

The mechanical trauma induced by the use of forceps to introduce the hydrophobic acrylic implant, the need for a larger incision (Oshika *et al*, 1994; Oshika *et al*, 1998a) or the hydrophobic nature (Miyake *et al*, 1996) could all have contributed to increasing the flare intensity and cell count in these patients. Notably, however, these changes were not clinically significant as there was no difference between the two groups in the incidence of clinically significant postoperative inflammation (i.e. requiring additional steroid treatment) at any time in the postoperative period.

In a study by Zaczek and Zetterstrom, 1998 (Zaczek & Zetterstrom, 1998), flare intensity was associated with the severity of retinopathy in diabetic patients. Although our patients were matched as regards their postoperative retinopathy grade, a mild influence due to the retinopathy could not be completely ruled out because of the relatively small sample size.

2.2.5.2 Anterior capsular contraction

We found that at 6 months the anterior capsular opening as indicated by the mask size was significantly smaller in the plate-haptic silicone group but there was no significant difference at 1 year. Also the mask size got significantly smaller over the follow-up period in the plate-haptic silicone group. Hayashi *et al* (Hayashi *et al*, 1997) and Zambrakji *et al* (Zambrakji *et al*, 1997) found that anterior capsular opacification occurs mostly within the first 3 months after surgery.

This finding is consistent with that by Werner *et al*, 2001 (Werner *et al*, 2001), who, in an autopsy series, found that plate-haptic silicone IOLs were associated with higher anterior capsular opacification scoring in addition to increased incidence of anterior capsular phimosis in comparison with hydrophobic acrylic IOL.

The relatively smaller overall diameter of the IOL as well as its ability to easily yield under pressure from the contracting capsule make this complication more likely with these implants.

2.2.5.3 Posterior capsular opacification

Recent research seems to underscore the role of IOLs as the most important factor in preventing its development of PCO. This role is further emphasised in diabetic patients, where prevention of PCO development is essential for maintenance of clear fundus view. Our findings established a significantly increased rate of PCO development with plate-haptic silicone IOLs after 6 months and 1 year when compared to hydrophobic acrylic IOLs in diabetic patients, which is in agreement with the findings of a recent study that compared the two lenses in non-diabetic patients (Abhilakh Missier *et al*, 2003).

Figures 2-5 and 2-6 (A & B) show examples of the changes in PCO over the follow-up time with the two implants. Four cases in the hydrophobic acrylic group showed reduction of the PCO area at 1 year in comparison with 6 months. Although the number was too small to be statistically tested, the finding is consistent with that of Hollick *et al* (Hollick *et al*, 1998; Meacock *et al*, 2001; Findl *et al*, 2004), who found regression of LEC in 83% of patients with that implant after 2 years of follow-up.

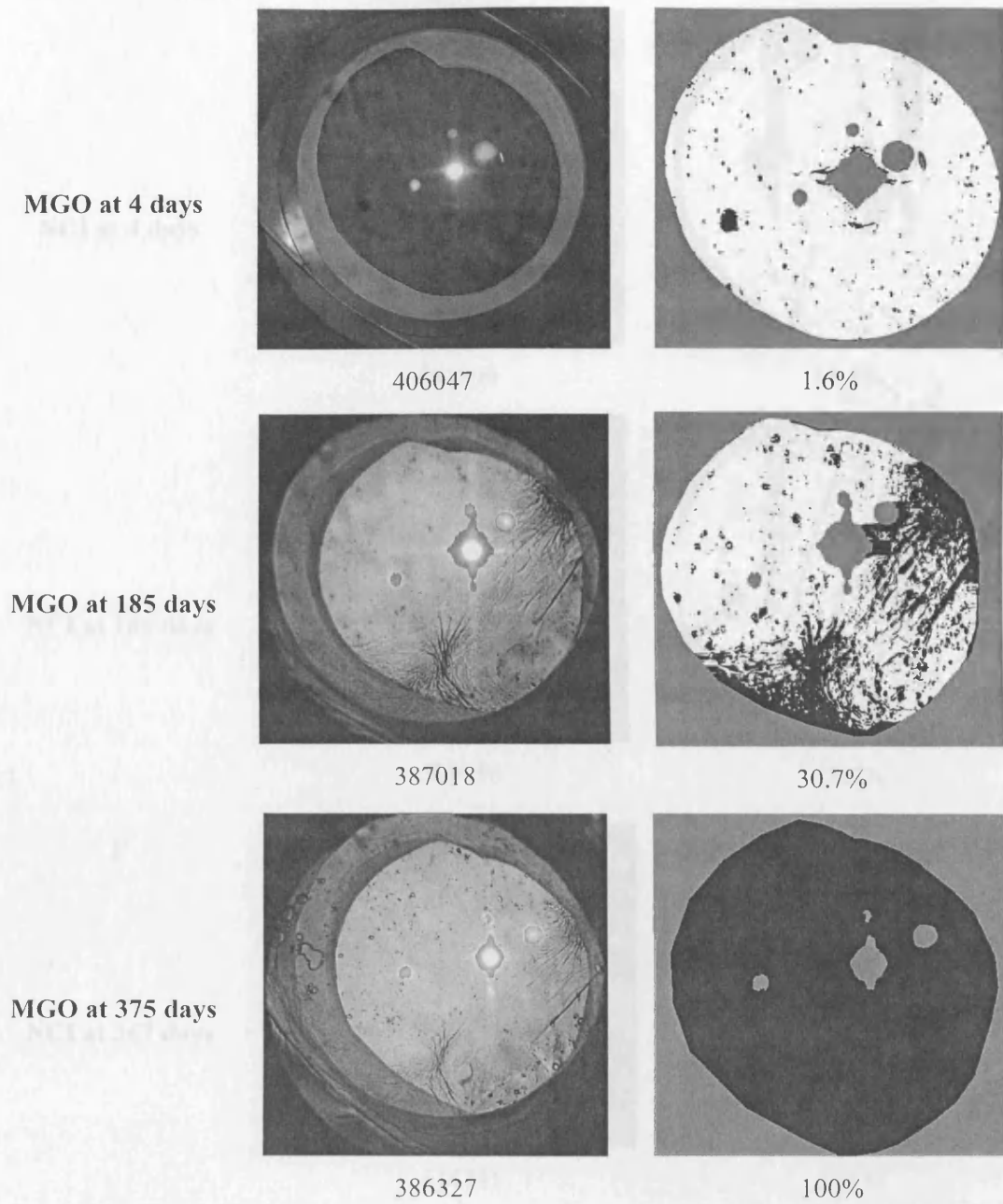
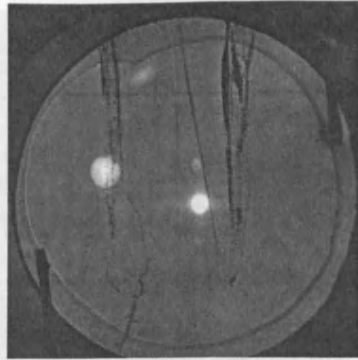
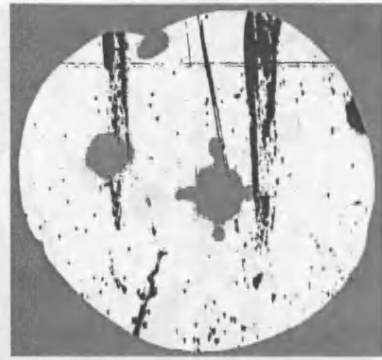


Figure 2-5. An example of a patient with plate-haptic silicone IOL. The left panel show the contrast-enhanced images with the outlines of the masks and their sizes (in pixels). The right panel shows the software-processed images and the percentages of the area of PCO. MGO=the photo's ID

NCI at 4 days

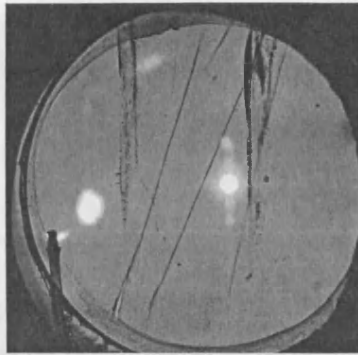


591899

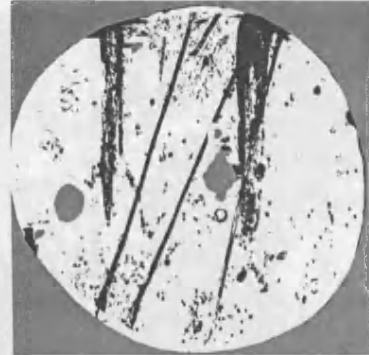


11.3%

NCI at 185 days

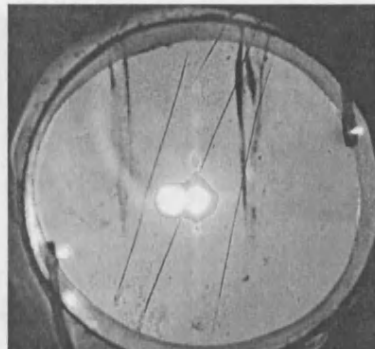


589056




18.7%

NCI at 367 days



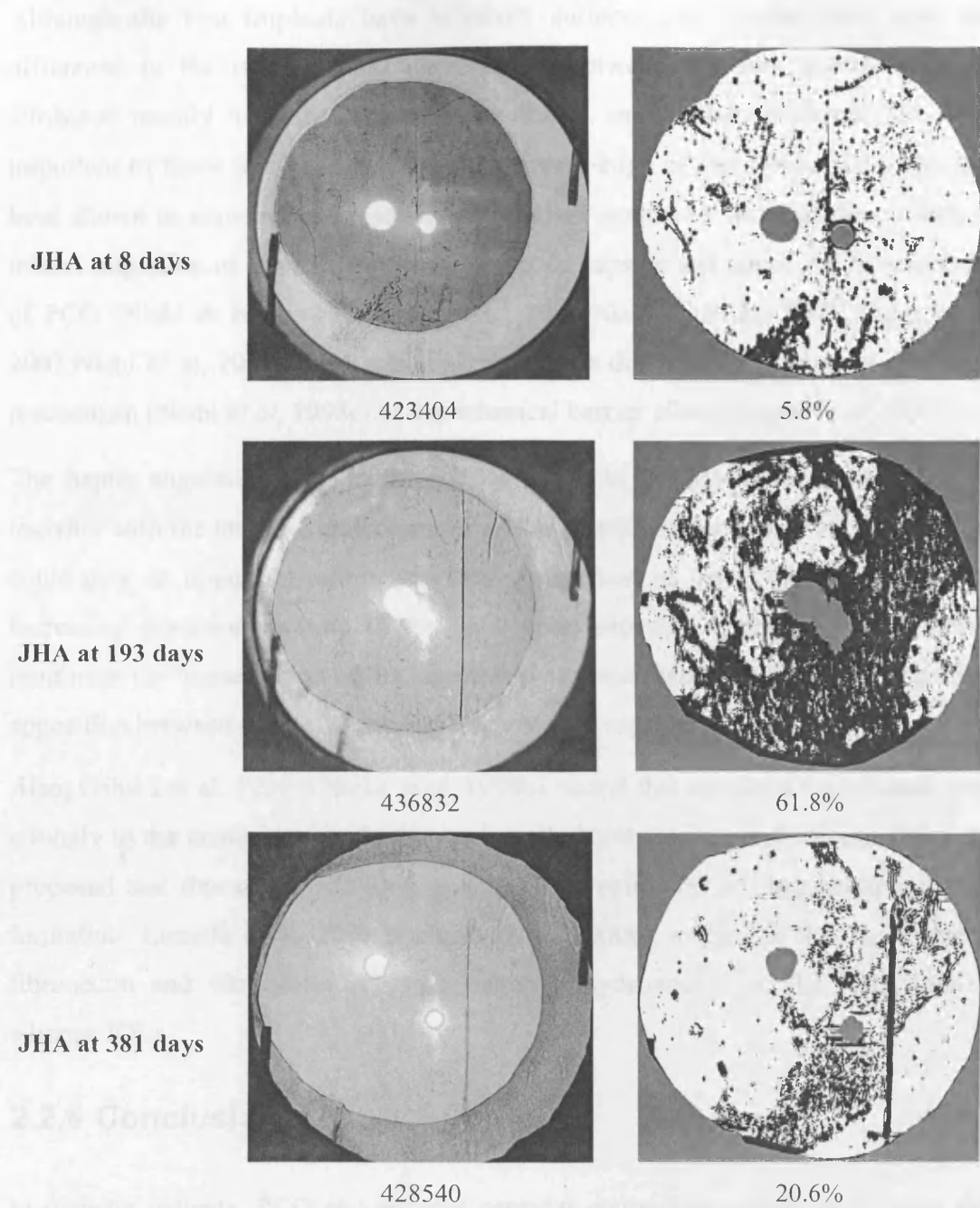
614731



24.1%

(A)

Figure 2-6 (A) is the example of patients who have had surgery. The left panels show the original fundus images with the image of the retina and the lens (the pupil). The right panels show the image of the retina and the lens (the pupil) with the percentage of the area of PCO. They show the increase in the area of PCO over the follow-up period (A) and the corresponding increase in the area of PCO that occurred in patients (B). The images are shown in the photos.



(B)

Figure 2-6 (A & B). Examples of patients with hydrophobic acrylic IOLs. The left panels show the contrast-enhanced images with the outline of the masks and their sizes (in pixels). The right panels show the software-processed images and the percentages of the area of PCO. They show relatively smaller increase in the area of PCO over the follow-up period (A) and even regression and reduction of the area of PCO that occurred in some cases (B). NCI & JHA=the Ids of the photos.

Although the two implants have biconvex surfaces and similar optic size, the difference in the rate of PCO development between the two implants can be attributed mainly to other differences in design and to their material. The most important of these features seem to be the square-edge of the acrylic IOLs. This has been shown in experimental research and clinical studies of non-diabetic patients to inhibit migration of the LECs onto the posterior capsule and hence the development of PCO (Nishi & Nishi, 1999; Nishi *et al*, 2000; Nishi & Nishi, 2002; Wejde *et al*, 2003; Nishi *et al*, 2002). This was suggested to be due to either a contact inhibition mechanism (Nishi *et al*, 1998c) or a mechanical barrier effect (Boyce *et al*, 2002).

The haptic angulation (10° in the acrylic and 0 in the plate-haptic silicone IOL) together with the larger overall diameter of the acrylic implant are other features that could play an important role in preventing migration of the LECs by creating and increasing posterior vaulting of the optic upon capsular contraction. This further reinforces the barrier effect of the square edge by increasing the force of mechanical apposition between the IOL optic and the posterior capsule.

Also, Oshika *et al*, 1998 (Oshika *et al*, 1998b), found that acrylic IOLs adhered more strongly to the posterior capsule than polymethylmethacrylate and silicone IOLs and proposed that this strong adhesion prevents lens epithelial cell migration and PCO formation. Linnola *et al*, 2000 (Linnola *et al*, 2000b), suggested that to be due to fibronectin and vitronectin adhering better to hydrophobic acrylic IOLs than to silicone IOLs.

2.2.6 Conclusion

In diabetic patients, PCO and anterior capsular contraction occurs at a higher rate with plate-haptic silicone than with hydrophobic acrylic IOLs. Although the latter may cause more early postoperative flare, this was not associated with increased clinically significant postoperative inflammation. This suggests that hydrophobic acrylic implants are more favourable than plate-haptic silicone implants in these patients.

CHAPTER 3

IN VIVO ASSESSMENT OF THE RELATIONSHIP BETWEEN THE INTRAOCULAR LENS AND THE POSTERIOR CAPSULE

3 USING THE OPTICAL COHERENCE TOMOGRAPHY TO COMPARE THE RELATIONSHIP OF A PLATE HAPTIC SILICONE AND A HYDROPHOBIC ACRYLIC INTRAOCULAR LENS TO THE POSTERIOR CAPSULE: A PILOT RANDOMISED CLINICAL TRIAL

3.1 INTRODUCTION

3.1.1 Optical coherence tomography

Optical coherence tomography (OCT)(Huang *et al*, 1991;Fujimoto *et al*, 2004;Schmitt J.M., 1999) (Figure 3-1) is an imaging technology that is based on modification of the Michelson's interferometer. The latter has been used to measure distances accurately by using a split light beam; a reference and a sample beam, each traverses a different path and then are recombined at a photo-detector that captures all the light to form an interference fringe. Depending on the length of the two paths, constructive or destructive fringes are formed and hence the centre of the fringe can be bright or less so by an amount proportional to the path difference.

3.1.2 Light source in OCT

In optical coherence tomography (Huang *et al*, 1991;Fujimoto *et al*, 2004), the light source is a super-luminant diode laser, which has a wave-length of 800 to 1300 nm and an emission power of 1-10 mW. This has low coherence (15-30 μ m), which helps produce interference patterns of short temporal and spatial extent.

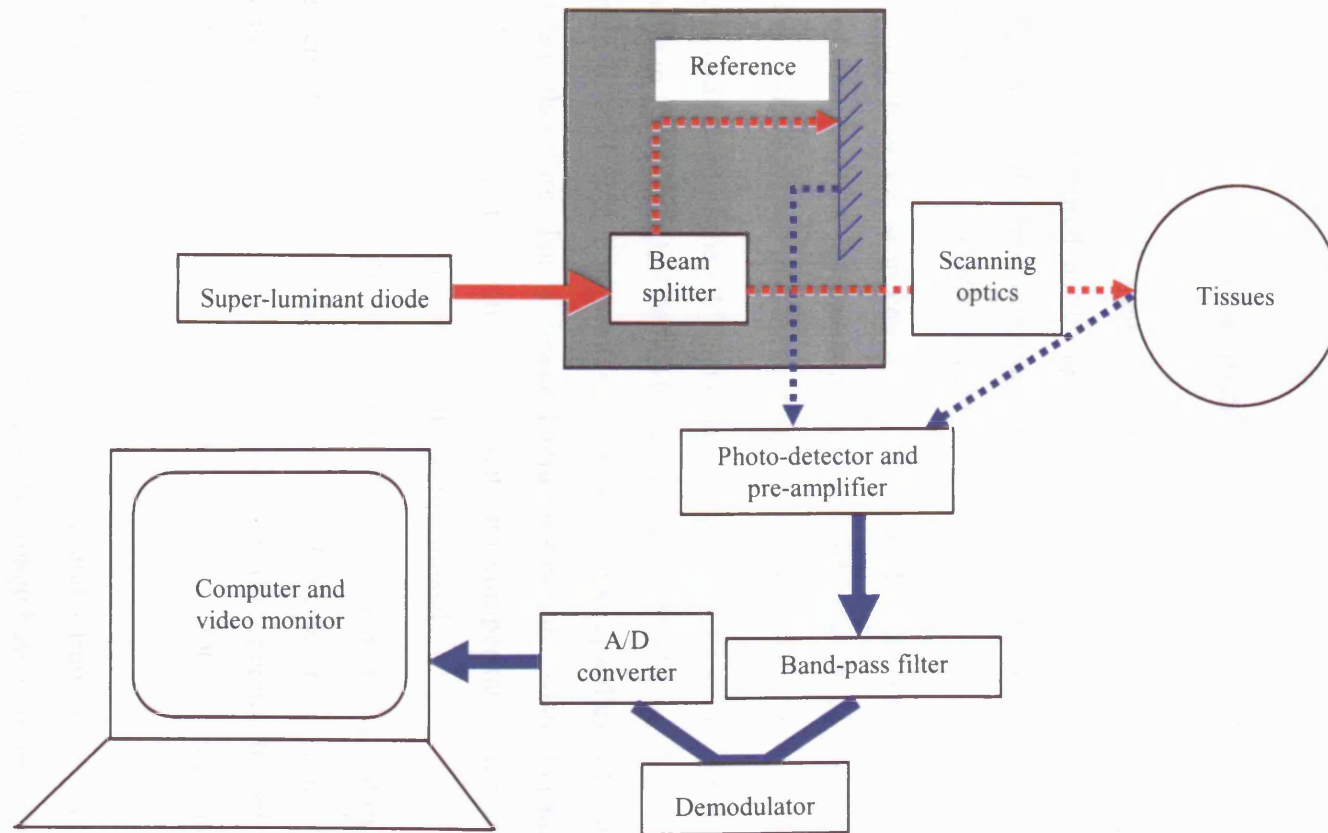


Figure 3-1. Optical coherence tomography: principle and components (Reproduced from Schmitt J. 1999 & Huang D. et al 1991)

3.1.3 The beam splitter

The beam of light is split into two separate, mutually coherent beams by means of two isosceles prisms with their bases apposed with an intervening layer of partial silvering.

3.1.4 Scanning and scan images

The OCT relies on mechanical scanning mechanisms based on translation of a reference mirror mounted on a stage driven by a motor. A constant excursion of about 2.72 mm/s and a repetition rate of 55 Hz are maintained in the middle of the scan range by means of a feedback control.

The X-Y length of the scan can be varied from 2.5 to 19mm in air at a working distance of 43 mm. This represents a scan angle of between 3° and 25°. The angular orientation of the scan can also be changed within X-Y plane within 360°.

The lateral resolution of the OCT image is limited by diffraction to a maximum of 25 µm (Chauhan & Marshall, 1999). However, lateral resolution depends also on the scan length as each image is composed of 100 scans regardless of scan length. The longer scan, therefore, has a lower lateral resolution. Also, because the image acquisition time is approximately 1 sec with no compensation for drifts in patient fixation, the lateral resolution can also be compromised.

The device has an internal fixation light visible to the patient but not on the operators viewing screen. A second light, generated by HeNe laser, is seen on the viewing screen and could be moved under the control of the operator to fall on any given tissues. The acquisition time for each composite OCT image is about 0.9s, independent of scan length and orientation.

The light reflected from the tissues is processed and a transducer is used to convert the light signal into pseudochromatic real-time image based on the reflectance of the light from the different tissues. The arbitrary pseudo-colour scale is logarithmic and had the effect of grouping a range of signal intensity into one colour. The image is displayed on a computer screen and the setting for each scan is stored on the computer for repeated measurement.

3.1.5 Use of the Optical coherence tomography for anterior segment examination

The OCT has been used before to examine the anterior segment structures. Because of the transparency of these structures, the only parts that are likely to result in significant OCT signals are the interfaces between different media. Hoerauf H (Hoerauf *et al*, 2000) used a slit-lamp adapted OCT and Radhakrishnan S *et al* (Radhakrishnan *et al*, 2001) used a high speed OCT (at 1310 nm wavelength) for *in vivo* imaging of the anterior segment structures, including the cornea, the chamber angle, the iris and the crystalline lens. Also, Hirano *et al* (Hirano *et al*, 2001) used the OCT 2000 (Zeiss-Humphrey) to study the different pathologies of the cornea. They demonstrated that the OCT was able to obtain reflection signals at the interface of the different corneal layers. Also, in a non-published *in vitro* and *in vivo* studies by Chauhan *et al* (Chauhan DS *et al*, 2000), the intraocular lens surfaces and posterior capsule opacification were clearly identified and characterised using the OCT.

It is known that IOL material and design influence the rate of PCO development. Acrylic implants have been found to be associated with lower rates than silicone implants (Hollick *et al*, 1999c), plano-convex (Nagamoto & Eguchi, 1997), and square edged implants (Nishi *et al*, 2000) with lower rates than other IOL profiles. In 1992, Apple and coauthors (Apple *et al*, 1992) proposed that the absence of space between the IOL and posterior capsule prevents LECs from migrating centripetally onto the posterior capsule and producing PCO: the ‘no space, no cells’ theory, which has not, hitherto, been demonstrated *in vivo*.

3.2 AIMS

In the previous study, it was shown that the plate-haptic silicone IOL (Chiron C11 UB; Bausch & Lomb) had a higher PCO rate than the hydrophobic acrylic IOL (Acrysof; Alcon Inc.). The aims of this study were to demonstrate the ability of the OCT scan to obtain *in vivo* images of the two IOLs; and to describe the characteristic relationships of their optics to the posterior capsule that can be related to the known difference in their PCO rates.

3.3 PATIENTS AND METHODS

3.3.1 Inclusion & exclusion criteria

Twenty-six patients were recruited consecutively between September 2001 and March 2002 from those who had uneventful phacoemulsification and IOL implantation of either plate-haptic silicone (Chiron C11UB) or hydrophobic acrylic (AcrySof) IOLs and gave consent to be included in the study. Twelve of the patients (46%) were recruited prospectively after they had been randomised to be given either of the above two implants. The rest of the patients (n=14, 54%) were recruited retrospectively.

Exclusion criteria were history of uveitis or other intraocular surgery, systemic steroids or other immunosuppressive therapy, the presence of corneal opacity, the development of postoperative uveitis that required additional steroid treatment, poor mydriasis, or refusal to be included in the study.

3.3.2 Surgical technique

One surgeon performed 81% of operations, including all those in the randomised group. All patients underwent a standard phacoemulsification through a supero-temporal corneal incision. Subconjunctival antibiotic (Cefuroxime) and steroids (Betamethasone) were injected at the conclusion of the procedure. Patients were reviewed within 24 hours after surgery and prescribed G Chloramphenicol 0.1% to be used QDS for 2 weeks and Dexamethasone 0.1% QDS for 2 weeks than BID for 2 weeks.

3.3.3 OCT image acquisition

OCT scan was performed within 48 hours and 4 to 6 weeks later in the randomised group but only once in the retrospective group, except in one of the patients who needed Nd:YAG capsulotomy that had a follow-up scan after the laser. The scans were performed following pupillary dilatation with G. tropicamide 1% and G. phenylephrine 2.5% using a Humphrey OCT scanner (Humphrey Inst., San Leonardo, CA). Patients were asked to fixate straight ahead with the other eye on the

instrument's external target because the internal fixation light was not visible when scanning the anterior segment. Linear scans, which take approximately 0.9s to acquire regardless of their length and angular orientation, were obtained. A vertical and a horizontal scans of 4-6mm across the pupillary area were taken for all the patients. Because short scans provided better resolution, 4 scans of 1.5-3mm were added, when necessary, astride the pupillary margin at 12, 3, 6 & 9 o'clock positions for detailed study of the peripheral part of the optic. (Figures 3-2, 3-3 & 3-4).

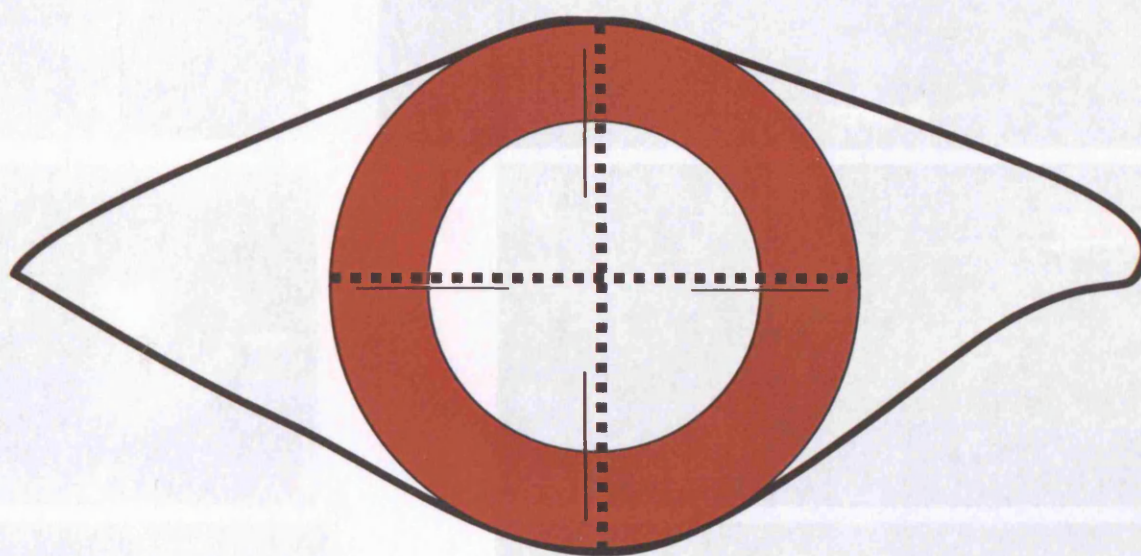


Figure 3-2. Diagram showing the positions of the long scans across the pupillary area (interruption lines) and short scans astride the pupillary margin (continuous lines)

Figure 3-3. An example of the two photographs and OCT scans images of a patient with a Nd:YAG laser capsulotomy. Top 1 panel: horizontal and vertical long scans, bottom 2 panels: short scans at 12 and 3 o'clock positions. Top panel OCT scan shows: pupillary margin (thin horizontal arrow), anterior capsule (thick horizontal arrows), anterior lens surface (thin vertical arrow), posterior lens surface (thick vertical arrow), and posterior capsule (curved arrow).

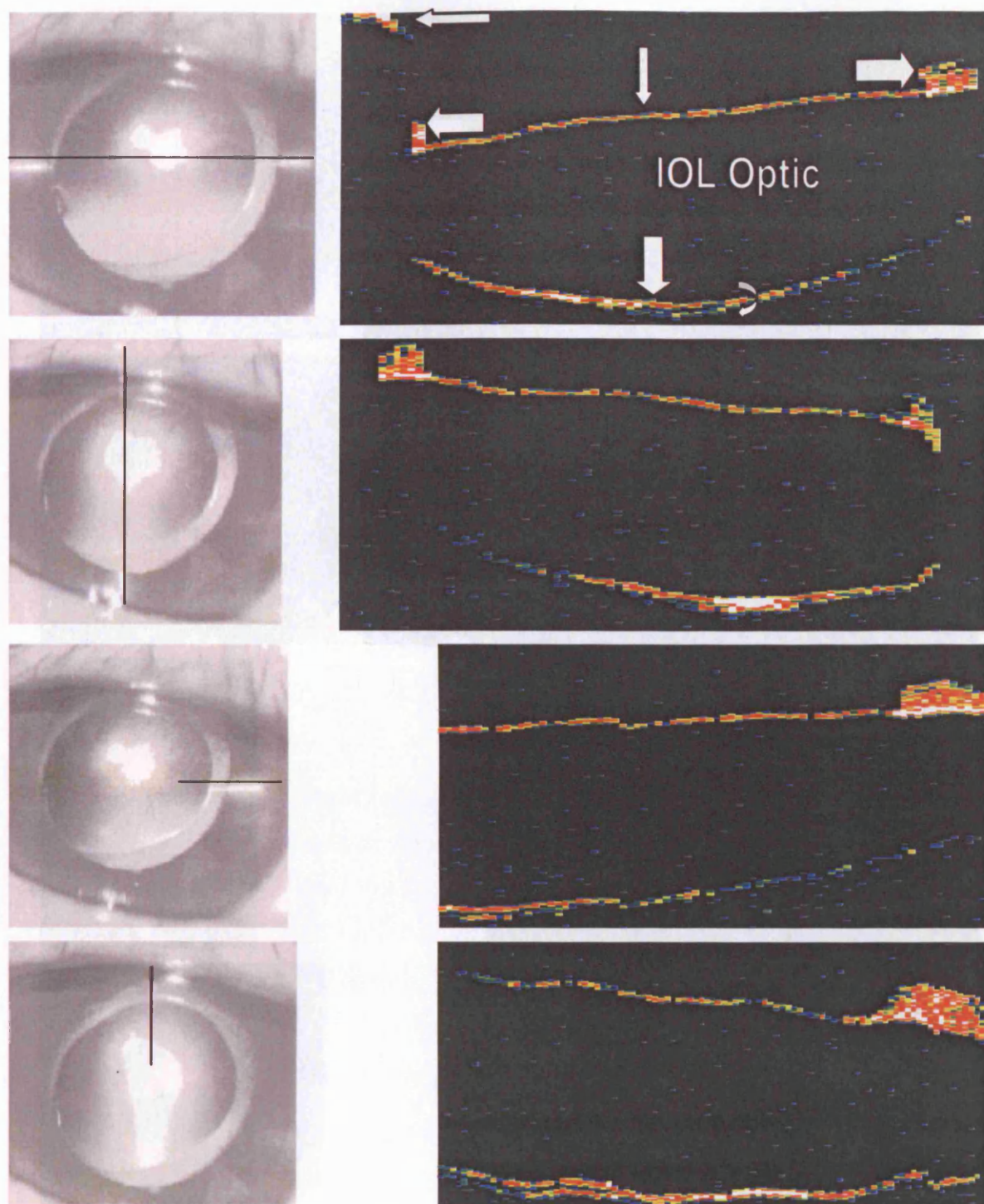


Figure 3-3. An example of the video photographs and OCT scan images of a patient with a hydrophobic acrylic IOL. Top 2 panels: horizontal and vertical long scans, bottom 2 panels: short scans at 12 and 3 o'clock positions. Top panel OCT scan shows: pupillary margin (thin horizontal arrow), anterior capsule (thick horizontal arrows), anterior lens surface (thin vertical arrow), posterior lens surface (thick vertical arrow) and posterior capsule (curved arrow).

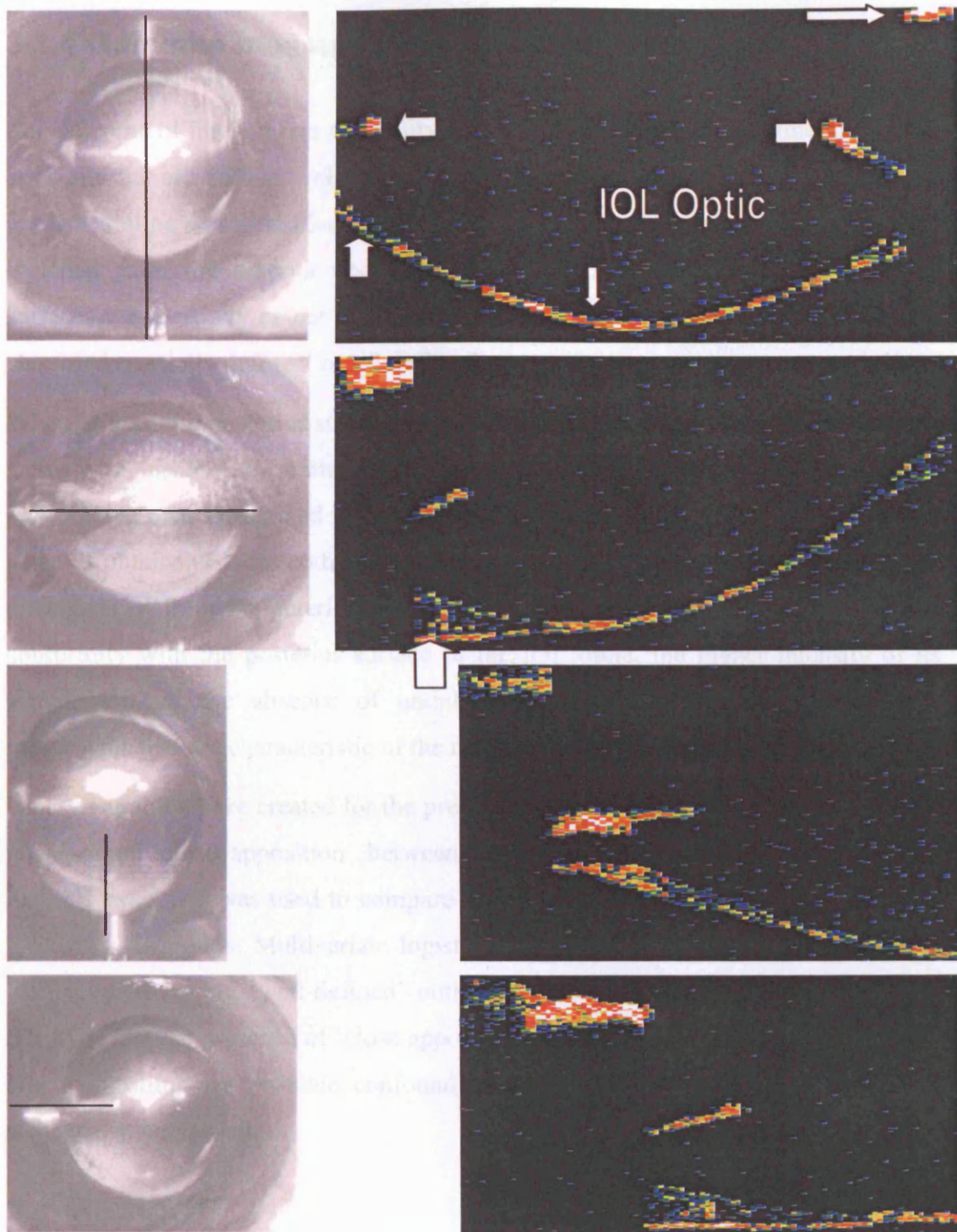


Figure 3-4. Video photograph and OCT scan of a patient with plate-haptic silicone IOL. Top 2 panels: vertical and horizontal long scans; bottom 2 panels: short scans at 6 and 9 o'clock positions. Top panel OCT scan shows: pupillary margin (thin horizontal arrow), anterior capsule (thick horizontal arrows), posterior lens surface (thin vertical arrow) and posterior capsule (thick vertical arrows).

3.3.4 Outcome measures and statistical analysis

The outcome of interest was the ability of the OCT to capture the outline of the IOL optic and the appositional relationship of the lens optic to the posterior capsule. An implant outline was classified 'well-defined' if clearly distinguishable signals were obtained from the anterior and posterior surfaces. Conversely, if either of the surfaces was partially or not at all distinguishable on all the scans, the outline was classified 'partially defined' or 'ill-defined'.

When at least the posterior surface of the optic of the IOL and the posterior capsule were distinguishable, the pattern of apposition between them was examined. A 'close apposition' pattern described the absence of any discernible optical space i.e. a single signal is obtainable from both of them (Figure 3-3 & 3-4). The posterior capsule was distinguished from the anterior hyaloid, if visible, by its relative proximity to and conformity with the posterior surface of the IOL optic, the higher intensity of its signal, and by the absence of undulating movements with the saccadic eye movements that are characteristic of the anterior hyaloid face (Chauhan *et al*, 2000).

Binary variables were created for the presence of a 'well-defined' outline and for the presence of 'close apposition' between the IOL optic and the posterior capsule. Fisher's exact test was used to compare the proportions of these binary variables in the two IOL groups. Multivariate logistic regression analysis was used to test the likelihood of having 'well-defined' outline as well as the association between the IOL type and the presence of 'close apposition' of its posterior surface to the capsule after controlling for possible confounders. A p value of < 0.05 was considered statistically significant.

3.4 RESULTS

3.4.1 Patient characteristics

Twenty-six patients were examined, 16 (63%) had plate-haptic silicone and 10 (37%) acrylic IOLs. The demographic data of the two groups of patients are shown in Table 3-1. The patients' age ranged between 44 and 84 (median=67). Fifteen (57.7%) of the patients were male and 15 (57.7%) were diabetics, 10 of them were in the plate-

haptic silicone group. There was no significant difference in age, sex distribution or the proportion of diabetic patients between the two groups.

Table 3-1. Patient characteristics

	PH silicone (N=16)	Hydrophobic acrylic (N=10)
Age (Years)		
Median	66	67
IQR	59.8-76.3	58.3-73.5
Gender		
M:F	9:7	7:3
Ethnic origin		
Caucasian: Asian	8:8	4:6
Follow-up		
Median	10.5	0.5
IQR	3.8 days to 22.2 months	1 day to 5.5 months

PH=plate-haptic; IQR=interquartile range

3.4.2 Delineation of IOLs on the OCT scans

In the randomised group, all the acrylic implants (n=6) had a ‘well-defined’ outline whereas all the plate-haptic silicone implants (n=6) had either of their surfaces ‘ill-defined’ or ‘partially defined’.

In the whole group, significantly more patients in the acrylic group had a ‘well-defined’ outline than in the plate-haptic silicone group (9/10 vs. 1/15) ($p<0.001$). There was no significant difference between diabetic and non-diabetic patients in the proportions with ‘well-defined’ IOL outline. After controlling for the length of follow-up and the presence of diabetes mellitus, the hydrophobic acrylic IOL was found to be more likely to have a ‘well-defined’ outline on the OCT scan [Odds Ratio=134.9; 95% Confidence Interval (7.5; 2433.2); $p=0.0009$].

3.4.3 Appositional relationship between the intraocular lenses and the posterior capsule

In the randomised group, 9 patients had distinguishable signals from the peripheral part of the optic i.e. the part subjacent to the pupillary margin and the posterior capsule. All the acrylic IOLs (n=5) showed ‘close apposition’ between the optic and the mid-peripheral part of the posterior capsule and an optically empty space centrally (Figure 3-5), whereas all the plate-haptic silicone implants (n=4) showed a distinct optically empty space between the peripheral parts of their optics and the capsule (Figure 3-6) but their central parts of the optics were difficult to discern from the capsule.

In the whole group, 20 IOLs (76.9%) had ‘well-defined’ posterior surfaces. The appositional pattern between the IOL and the posterior capsule varied. A ‘close apposition’ pattern existed in 7/8 (88%) of the patients with acrylic IOLs and in 1/12 (8%) of those with plate-haptic silicone IOLs ($p<0.001$). No significant difference was found between non-diabetic and diabetic patients in the presence of IOL-capsular apposition (4/9 vs. 4/11). After controlling for the length of follow-up and the presence of diabetes mellitus, the optics of acrylic IOLs were more likely to have ‘close apposition’ with the posterior capsule on OCT [Odds Ratio=480.3; 95% Confidence Interval (1.62, 142460.8); $p=0.03$].

3.4.4 Follow-up scans

In 8 patients in the randomised group (4 in each group), where the first and follow-up scan showed distinguishable signals from both the optic and the capsule, the central part of the optic was distinguishable only on all the patients with acrylic implants. In these patients, a central optically empty space was identified on their first scans (Figures 3-a & 4-a top panels). This was either shallow or completely obliterated on the follow-up scans at 4 to 6 weeks (Figure 3-7).

3.4.5 Posterior capsular opacification and IOL outline

Four patients had PCO and 3, all with plate-haptic silicone IOLs (16%), underwent Nd:YAG laser capsulotomy. The reflective substances on the posterior capsule on

the scan corresponded to the lens epithelial pearls seen in the colour photograph, which enhanced the outline of the posterior surface of the optic (Figure 3-8 & 3-9). Notably, however, the posterior optic surface outline was no longer discernible after Nd:YAG laser capsulotomy.

3.5 DISCUSSION

In this pilot study, OCT enabled us to examine *in vivo* features of two IOLs that are different in material and design and were shown to be different in their PCO rate in our previous study as well as in a recent study by Abhilakh Missier et al (Abhilakh Missier *et al*, 2003).

3.5.1 Delineation of the IOLs

The first feature studied here was the difference in the ability of the OCT to delineate the outline of the two IOLs. The outlines of the hydrophobic acrylic IOLs were better defined than those of the plate-haptic silicone IOLs (Figures 3-3 & 3-4). In latter group of patients, the outline of the peripheral part of the posterior surface of the optic was the only discernible part rather than their central part. This could be related to accumulation of extracellular substance and LECs on that part because of its proximity to the highly proliferative equatorial LECs. In patients with PCO, the posterior surface outline was enhanced by the presence of LECs and extracellular substance on the posterior capsule (Figure 3-7 & 3-8). This feature was lost following Nd:YAG posterior capsulotomy.

The ability of the OCT to delineate the outline of the hydrophobic acrylic IOLs better than that of the plate-haptic silicone IOLs can be related to the principle of the OCT and the reflective characteristics of the IOLs. The definition of tissues on the OCT relies on the formation of constructive interference fringes from the interaction between the reference light and that reflected from the target tissue, with more reflections leading to enhancement of the interference fringe signal. In an experimental study by Erie et al, 2003 (Erie *et al*, 2001) more external reflections were found with hydrophobic acrylic IOLs (AcrySof MA60) than with silicone IOLs (LI61U). They attributed that to the higher refractive index of the acrylic IOLs (1.55 vs. 1.43) and their optic design (an unequal biconvex vs. equiconvex). The latter features are similar to those of the plate-haptic silicone IOL's, which has a refractive

index of 1.413 and an equiconvex optic. The deposition of a biofilm of extracellular substances such as fibronectin and vitronectin that was shown to occur more on the acrylic than on the silicone IOL surfaces (Kochounian *et al*, 1994) might perhaps have a role in rendering the surfaces of these implants more reflective or light-scattering.

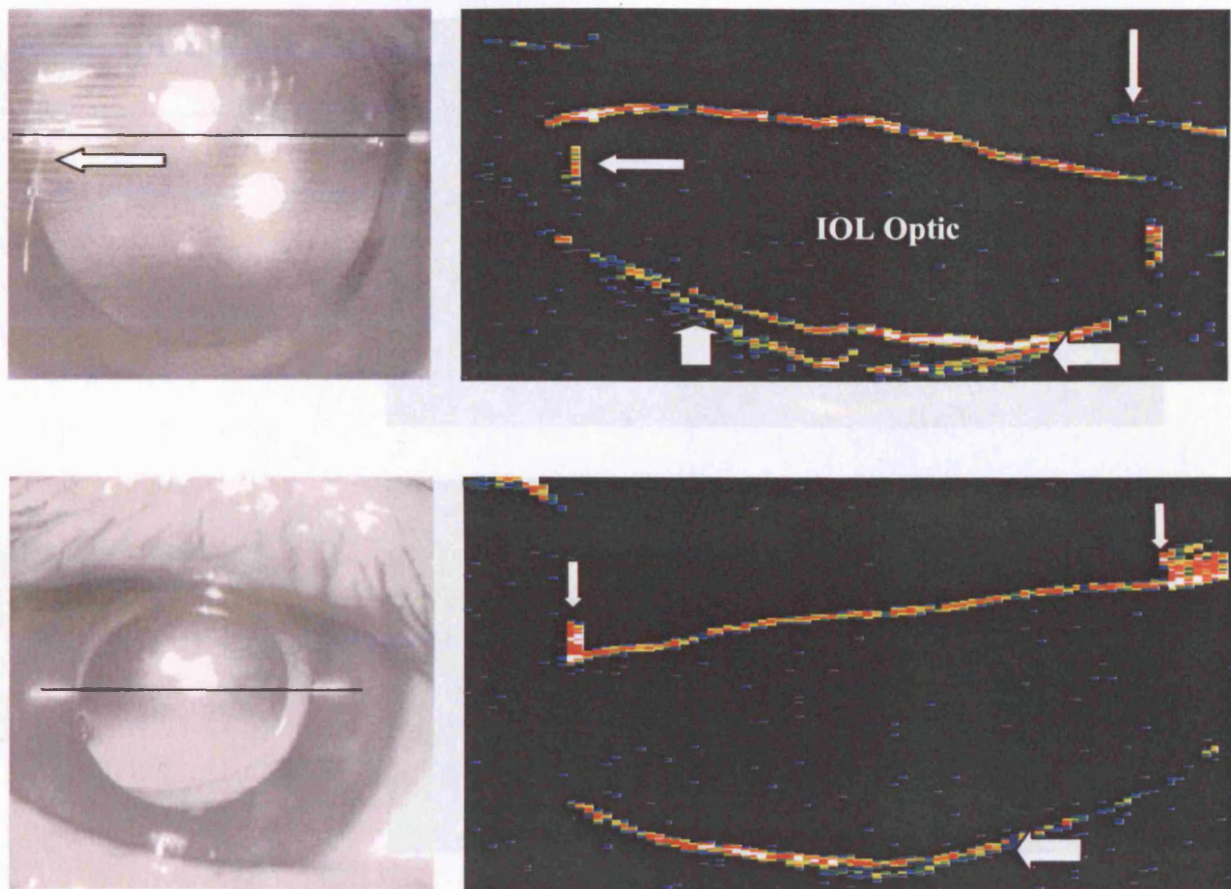


Figure 3-5. Video photographs and OCT scans of two patients with plan-haptic

Figure 3-5. Video photographs and OCT scan of two patients with hydrophobic acrylic IOLs within 2 days (top panel) and 9 months after surgery (bottom panel). Note the clear delineation of the IOL outline. The OCT scans show the anterior capsular leaflet (thin vertical arrows), the haptic (thin horizontal arrows) and the posterior capsule (thick vertical arrow). The mid-peripheral part of the latter (thick horizontal arrows) is in close apposition to the optic

3.5.2 Appraisal of the relationship of the posterior capsule to the IOLs

In the 20 patients whose posterior lens surface was inspected and the distance between the IOL optic and the posterior capsule was measured, the presence of a close apposition was

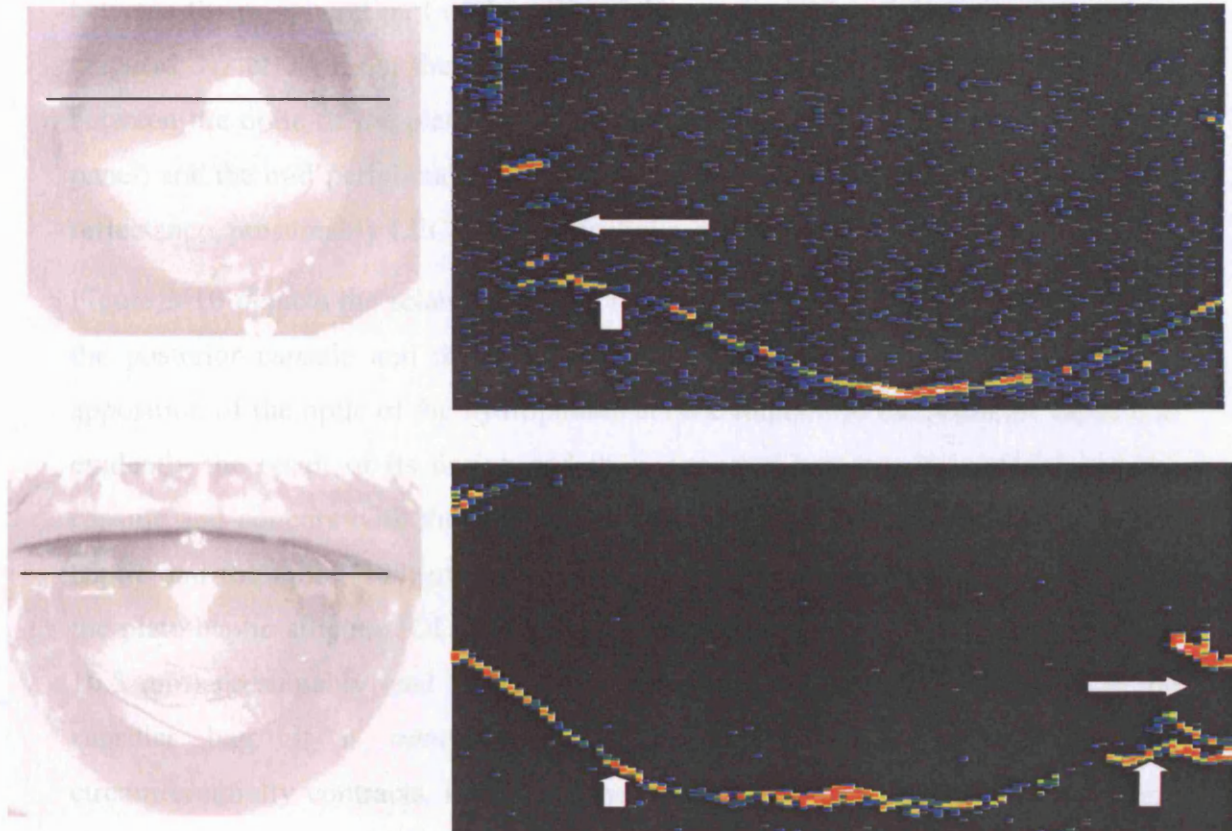


Figure 3-6. Video photographs and OCT scans of two patients with plate-haptic silicone IOLs within 2days (top panel) and 14 months after surgery (bottom panel). The OCT scan shows that the implant surfaces are poorly delineated in both panels. The peripheral part of the optics are visible though (horizontal arrows) and there is absence of the close apposition pattern demonstrated in 3-*a*. Instead there is an optically empty space between the optic (horizontal arrows) and the posterior capsule (vertical arrows)

3.5.2 Appositional relationship of the posterior capsule to the IOLs

In the 20 patients where the posterior surface of the optic and the posterior capsule were identifiable, the most distinctive feature was the presence of ‘close apposition’ between the peripheral part of the optic of the acrylic IOL and the posterior capsule (Figures 3-7 & 3-8). On the other hand, an optically empty space was identifiable between the optic of the plate-haptic silicone IOLs (Figures 3-3, 3-6 and 3-8 upper panel) and the mid-peripheral part of the capsule that was filled with material of high reflectance, presumably LECs and extracellular substance, (Figures 3-6, 3-8 & 3-9).

Figure 3-10 depicts the relationship and the proposed appositional patterns between the posterior capsule and the two implants once in the capsular bag. The close apposition of the optic of the hydrophobic acrylic implant to the posterior capsule is evidently the result of its design and the interaction between its material and the capsule and concurs with the findings of other studies. The angulation between the haptic and the optic (10°) of the hydrophobic acrylic implants, which is lacking in the plate-haptic silicone IOL design, as well as their larger overall diameter (13 vs. 10.5 mm) presumably lead to posterior vaulting of the optic once they are in the capsular bag. It is conceivable that this increases as the capsular bag circumferentially contracts, increasing the appositional force between the optic and the posterior capsule. This could explain the disappearance of the central space in patients examined later after surgery (Figures 3-4 & 3-7). The sharp square edge of the lens optic is another attribute of the acrylic lens and perhaps the most important in producing this characteristic appositional relationship. Nishi and coauthors (Nishi *et al*, 2002) showed that capsular bend formation around the IOL implant occurs earlier with hydrophobic acrylic IOL than with silicone and PMMA IOL. Boyce *et al*, using a mathematical model, found that square-edged optic profiles exert a higher pressure on the posterior capsule than IOLs with round-edged optic profiles (Boyce *et al*, 2002). Also, in the study by Nagata *et al*, 1998 (Nagata *et al*, 1998), and another by Oshika *et al*, 1998 (Oshika *et al*, 1998b), the adherence force between the IOL and the capsule, attributable to integrins and cadherin adhesion molecules expressed by the LECs (Birk *et al*, 1994), was found to be greater with acrylic than

with silicone IOLs. This adherence was found to occur even faster with the acrylic than with silicone and PMMA IOLs (Nishi *et al*, 2002).

In a study by Hollick *et al* (Hollick *et al*, 1998), LECs that migrated behind hydrophobic acrylic IOL optic were found to disappear. Our finding that the central optically empty space between the hydrophobic acrylic implant and the posterior capsule disappeared within few weeks after surgery corroborates the authors' hypothesis that related the disappearance of cells to their demise as a result of posterior vaulting and mechanical compression of the cells by the optic.

The demonstrable appositional differences between the two implants are in keeping with experimental (Nishi *et al*, 1998c;Nishi *et al*, 2000) and clinical studies (Beltrame *et al*, 2002;Hayashi *et al*, 1998c;Hollick *et al*, 1999c) that have shown that square-edged acrylic implants prevent lens epithelial cell migration onto the posterior capsule and hence had lower PCO rate. All, also, is consistent with the time-honoured concept of 'no space, no cells, no PCO' (Apple *et al*, 1992).

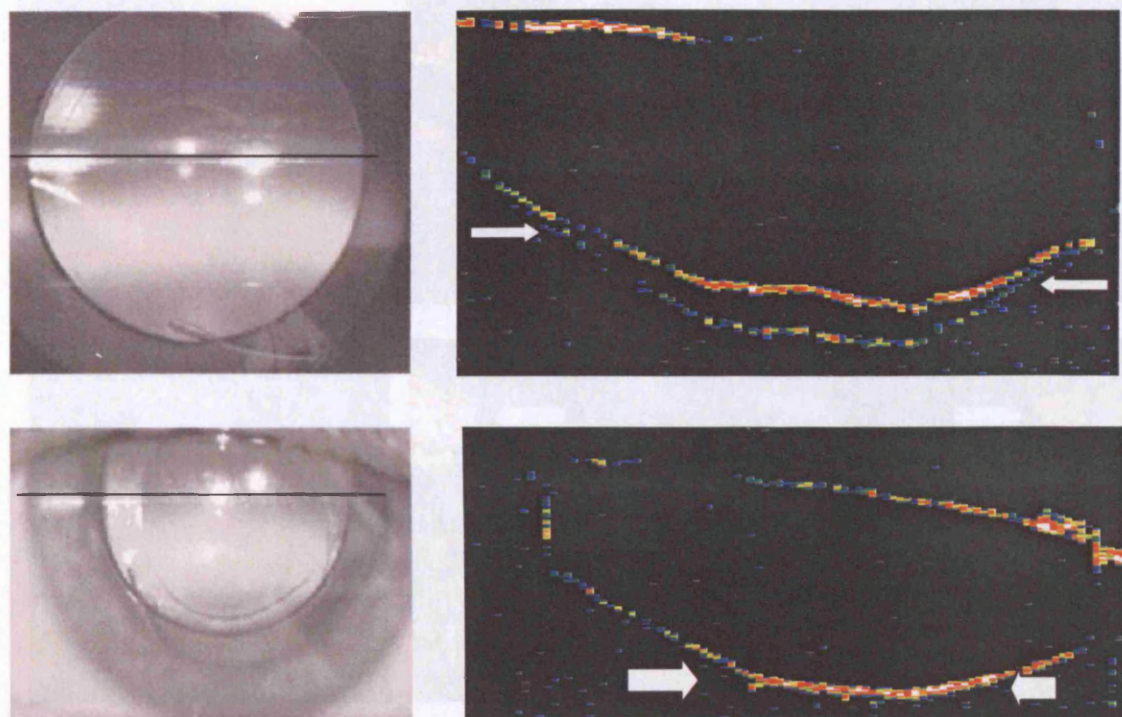


Figure 3-7. Video photographs and OCT scans of a patient with a hydrophobic acrylic IOL. It shows a close mid-peripheral apposition between the posterior capsule and the optic 2 days (top panel: thin arrows) and total apposition 4 weeks after surgery (Bottom panel: thick arrow)

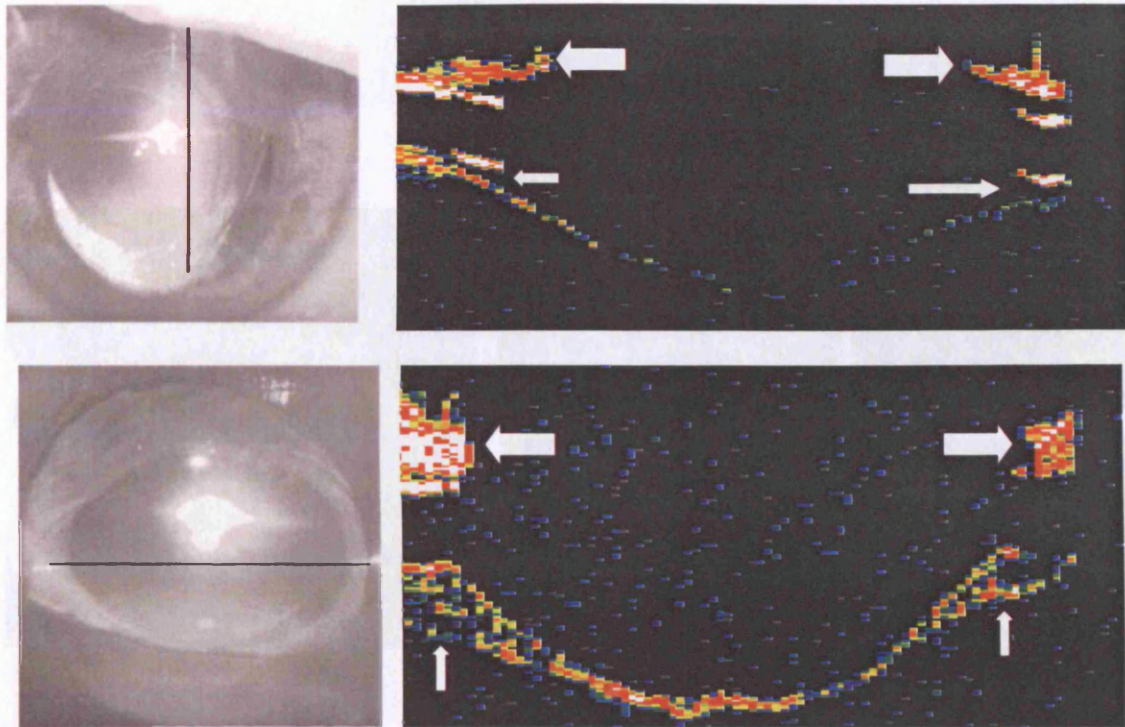


Figure 3-8. Video photographs and OCT scan of 2 patients with plate-haptic IOLs 2 years after surgery. There is lack of apposition between the implant and the mid-peripheral part of the capsule (thin arrows). A high-reflectance material is present between the capsule and the posterior lens surface (vertical arrows)(presumably of LECs and extracellular substance) and an optically similar substance underneath the anterior capsular leaflet (thick arrows), corresponding to the anterior capsular fibrosis showing in the video photograph

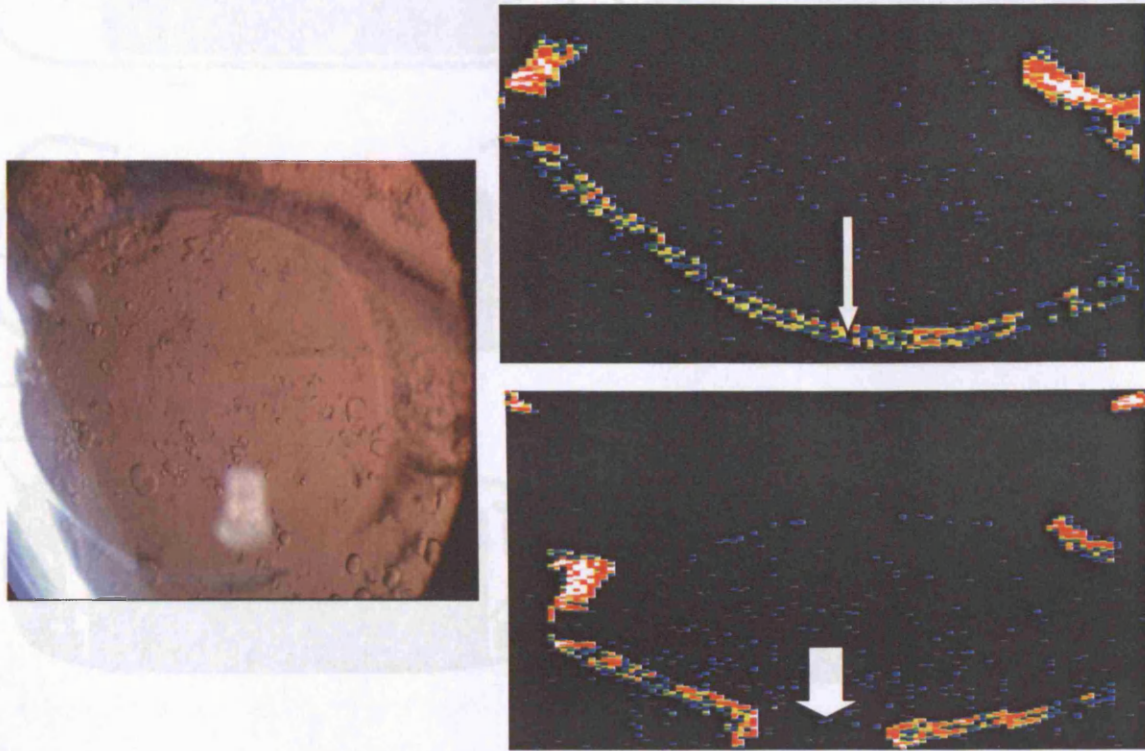


Figure 3-9. A colour photograph and OCT scan of a patient with plate-haptic silicone IOL and PCO. The colour photograph shows abundant LECs forming Elshnig's pearls on the posterior capsule. The OCT scans shows better definition of the posterior surface of the optic (top panel: thin arrow), the central part of which became indiscernible after Nd:YAG capsulotomy (bottom panel: thick arrow), indicating that the reflections were predominantly from the posterior capsule rather than the optic of the implant

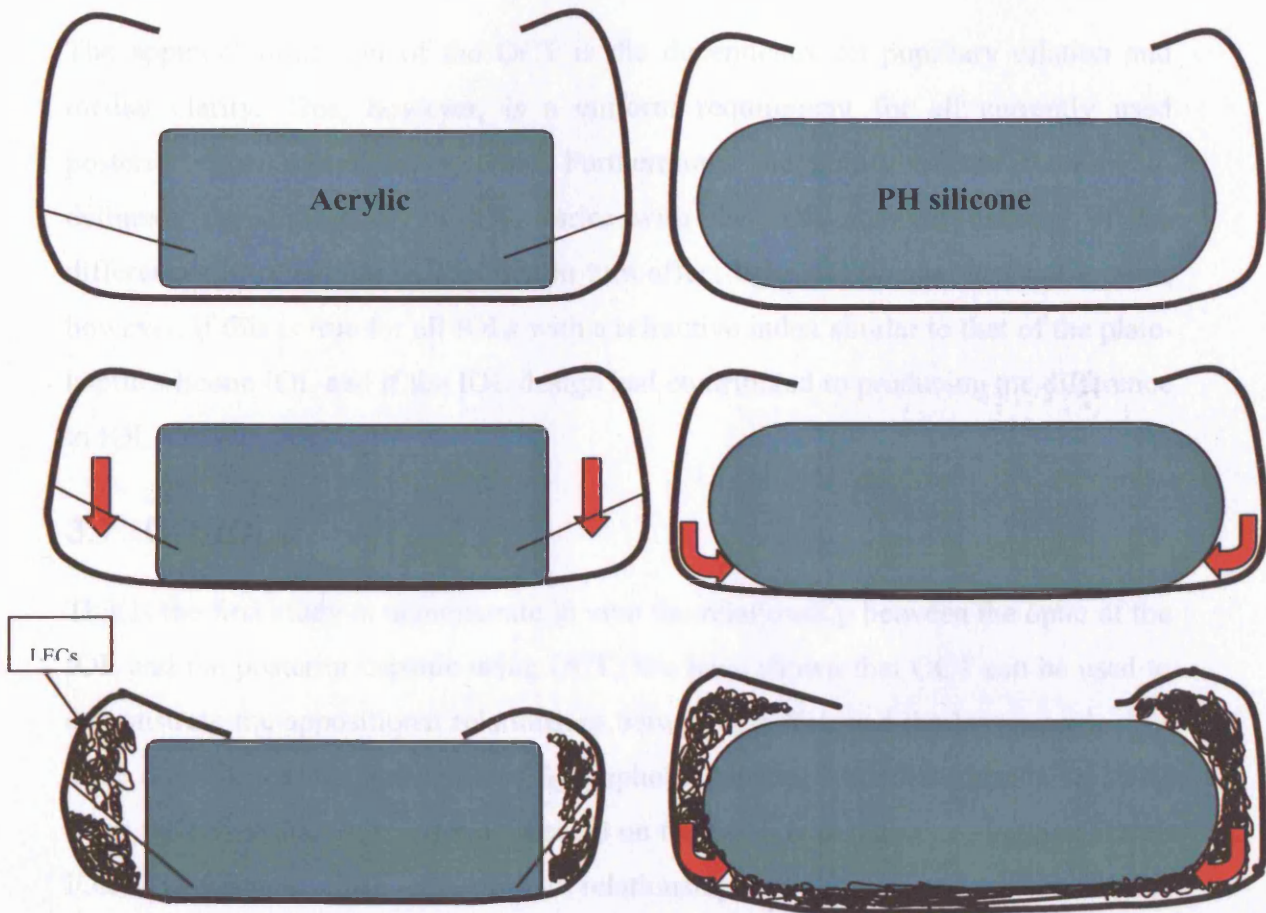


Figure 3-10. A diagram of the proposed appositional patterns that develop between hydrophobic acrylic and plate-haptic silicone implants, and the posterior capsule. Once in the capsule bag, early close apposition of the edge of the hydrophobic acrylic IOL optic to the posterior capsule occurs due to the posterior vaulting that result from their larger overall diameter (13mm vs. 10 mm) and the angulation between the optic and the haptic (10°) that supposedly increases as the capsular bag contracts. The square edge and the acrylic material create a tighter adherence force between the capsule and the IOL optic. This close apposition with the posterior capsule helps prevent LEC migration (straight arrows), whereas the lack of similar apposition with the plate-haptic silicone IOLs allows early migration and proliferation of the LECs on the posterior capsule (curved arrows)

3.6 LIMITATIONS

The apparent limitation of the OCT is the dependency on pupillary dilation and media clarity. This, however, is a uniform requirement for all currently used posterior capsule-imaging systems. Furthermore, the ability of the machine to delineate the outline of an IOL varies with the IOL material because of the differences in refractive indices that in turn affect light reflectance. It is not known, however, if this is true for all IOLs with a refractive index similar to that of the plate-haptic silicone IOL and if the IOL design had contributed to producing the difference in IOL surface reflectivity.

3.7 CONCLUSION

This is the first study to demonstrate in vivo the relationship between the optic of the IOL and the posterior capsule using OCT. We have shown that OCT can be used to demonstrate the appositional relationship between the IOL and the lens capsule. We have also shown that the optic of hydrophobic acrylic IOLs, in addition to being more reflective and thus better delineated on the OCT scan than plate-haptic silicone IOL, maintains a close appositional relationship with the posterior capsule that appears lacking with the plate-haptic silicone. These features are consistent with the ‘no-space; no-cell; no PCO’ concept.

The recent generations of OCT and their higher resolution may be able to overcome the above limitations and provide a potentially useful tool for in vivo examination of the IOL-capsule relationship. This should help to identify important design features in preventing PCO development.

CHAPTER 4

POSTERIOR CAPSULAR OPACIFICATION IN PATIENTS WITH UVEITIS

4 INCIDENCE AND RISK FACTORS OF POSTERIOR CAPSULAR OPACIFICATION IN UVEITIS PATIENTS FOLLOWING PHACOEMULSIFICATION AND EXTRACAPSULAR CATARACT EXTRACTION

4.1 INTRODUCTION

Similar to diabetic patients, posterior capsule opacification in uveitis patients carries the risk of obscuring the fundus view and hence the timely diagnosis and treatment of posterior segment complications such as macular oedema. Moreover, performing Nd:YAG capsulotomy can potentially excite the dormant uveal inflammation and can itself cause macular oedema or other posterior segment complications such as retinal detachment. According to Dana et al, 1997 (Dana *et al*, 1997), the incidence of PCO in uveitis patients can be higher than in patients without uveitis and has been estimated to be 38.5% at 1 year and 56% at 3 years. In that study, the relatively young age of the patients was considered the most important risk factor that led to increased PCO in uveitis patients.

Dana's study, however, included patients who underwent phacoemulsification as well as ECCE. Also, no study to date has investigated other factors that can potentially affect the rate of PCO in uveitis patients, including the surgical technique, prophylactic steroids, the development of postoperative inflammation, gender, type of IOL and ethnic origin.

4.2 AIMS

In the following two studies, we aimed at:

1. Estimating the incidence and identifying the factors that could potentially affect the rate of PCO in patients with uveitis.
2. Estimating and comparing the incidence of PCO in uveitis patients after phacoemulsification and ECCE

4.3 STUDY OF THE INCIDENCE AND RISK FACTORS OF ND:YAG CAPSULOTOMY AFTER PHACOEMULSIFICATION IN PATIENTS WITH UVEITIS

For the purpose of this study two groups of patients were examined. The 'Uveitis group' refers to a consecutive series of patients that were recruited from 3 tertiary referral centres. The 'Non-uveitic and uveitic group' refers to a comparative series that was derived from the same centre.

4.3.1 Material and Methods

4.3.1.1 Uveitis group

4.3.1.1.1 *Design and study population*

This is a retrospective case-note review of a consecutive series of 156 uveitis patients who underwent phacoemulsification and intraocular lens implantation between 1996 and 2001 under the care of 3 consultants at Moorfields Eye Hospital and Whipps' Cross University Hospital, London, UK; and at the Royal Prince Alfred Hospital and St Vincent's Hospital, Sydney, Australia.

There were 57 patients with anterior uveitis (56%), comprising three subgroups: recurrent acute anterior uveitis (RAAU)(n=25,43.9%), chronic anterior uveitis (CAU)(n=22, 38.6%), and Fuchs' heterochromic cyclitis (FHC)(n=10,17.5%). The posterior uveitis group comprised 44 patients (44%) consisting of intermediate uveitis (IU)(n=17,39%) and posterior uveitis, retinal vasculitis and panuveitis (PU)(n=27,61%).

A systemic disease associated with the uveitis was found in 25 (25%) of the patients. These included sarcoidosis (n=6, 24%), toxoplasmosis (n=5, 20%), Vogt-Koyanagi-Harada disease (n=3, 12%), ankylosing spondylitis (n=3, 12%), Crohn's disease (n=2, 8%), ulcerative colitis (n=1, 4%), Reiter's disease (n=2, 8%), Behçet's disease (n=2, 8%) and tuberculosis (n=1, 4%). Eight patients had diabetes mellitus but none of them had clinically significant retinopathy requiring treatment. One of the patients had undergone a trabeculectomy operation for chronic glaucoma 5 years preoperatively and another pars plana vitrectomy for rhegmatogenous retinal

detachment 18 months preoperatively.

4.3.1.1.2 Inclusion & exclusion criteria

We included patients with a minimum postoperative follow-up of 3 months (n=151 eyes) and only the first eye of patients who had bilateral surgeries (n=36). Patients with juvenile idiopathic arthritis (n=2), herpetic kerato-uveitis (n=4) and lymphoma-associated uveitis (n=2) and patients who underwent phaco-trabeculectomy (n=6) were excluded. This left 101 patients whose details are shown in Table 1.

4.3.1.1.3 Data collection

The collected data, included age at surgery, gender, type of uveitis, the presence of systemic disease, the occurrence of uveitis episodes within the preoperative year and preoperative ocular findings, preoperative best-corrected visual acuity (BCVA), operative details, postoperative and final BCVA and postoperative complication, including early rise of intraocular pressure, uveitis or macular oedema requiring additional treatment.

4.3.1.1.4 Preoperative management

According to the uveitis service protocol in the 3 hospitals, all the patients had to have good control of ocular inflammation for a minimum of 3 months preoperatively, except in patients with chronic anterior uveitis or pan-uveitis, in whom the surgery had to be undertaken when the AC activity had been reduced to the lowest possible level.

Patients with disease activity within 3 months prior to surgery and those with previously documented posterior uveitis or macular oedema were given prophylactic systemic steroids (58, 57%). These were given either orally (50, 86%) as 40mg of prednisolone for 2 weeks prior to surgery or intravenously (4, 7%) as methylprednisolone 500mg on the day of surgery.

4.3.1.1.5 Surgery

Phacoemulsification was performed via a corneal or scleral tunnel incision using a standard technique. Pupillary dilation using iris hooks was carried out in 6 patients and iris sphincterotomy in another patient for poor dilation due to posterior synechiae.

One of 5 types of IOL was implanted in the capsular bag: silicone either plate-haptic (C10/11UB; Chiron, Bausch& Lomb) (32, 31.7%) or 3-piece (SI30 or SA40; Allergan Medical Optics or LI41U; Iolab) (15, 14.8%), hydrophobic acrylic (AcrySof MA60U, Alcon Lab Inc.) (24, 23.8%), polymethylmethacrylate (MC550, Bausch & Lomb Surgical) (21, 20.8%) or hydrogel (Hydroview, H60M) (Bausch & Lomb Surgical) (9, 9%)*.

Twenty-three patients (23%) required corneal sutures, 2 of them for poorly sealing wounds and the rest for larger incision size in those who had PMMA implants.

There were no major operative complications. Three patients with FHC and one who required sphincterotomy developed intraoperative hyphema. In one patient with chronic anterior uveitis, posterior capsular rupture occurred requiring anterior vitrectomy but an acrylic IOL was successfully placed in the bag. Corneal suturing was needed for the patients who had PMMA IOLs (21, 20.8%) in addition to 2 other patients who had leaky wounds at the end of the operation. Subconjunctival injection of antibiotics and steroids was performed in all patients at the conclusion of the procedure.

Two of the patients with sarcoidosis-related posterior uveitis required vitrectomy for persistent floaters and retinal detachment almost 1 and 4 years after surgery.

4.3.1.1.6 Postoperative management

Patients were discharged on the day of surgery and all but two, were reviewed within 48 hours. The frequency of subsequent clinic visits were determined by the treating clinician according to clinical findings and patients were advised to present to casualty should they have symptoms of uveal inflammation.

* The percentages do not add up to 100% because of the rounding.

4.3.1.2 Non-uveitic and uveitic group

4.3.1.2.1 Design and study population

We reviewed the case-notes of 251 patients, 53 had established diagnoses of uveitis (10 (18.9%) recurrent acute anterior uveitis, 6 (11.3%) chronic anterior uveitis, 14 (26.4%) intermediate uveitis, 6 (11.3%) posterior uveitis and 17 (32.1%) pan-uveitis) and 198 contemporary random controls. Both groups underwent uneventful phacoemulsification cataract surgery and in-the-bag IOL implantation at Moorfields Eye Hospital between 1995 and 2001.

4.3.1.2.2 Inclusion and exclusion criteria

Only the first eye of those who underwent bilateral surgery was randomly included. Also, only non-diabetic patients and patients who had not undergone other intraocular surgery (e.g. penetrating keratoplasty, vitrectomy and trabeculectomy) were included. Also, in the uveitic group, patients with juvenile idiopathic arthritis, herpetic kerato-uveitis, lymphoma-associated uveitis and patients who underwent phaco-trabeculectomy were excluded.

The relevant preoperative, operative and postoperative data were collected, including gender, age at surgery, type of IOL, surgeon's grade, the development of postoperative inflammation (within 3 months), the performance of Nd:YAG capsulotomy and best-corrected visual acuity at the final visit.

4.3.1.2.3 Preoperative management

Preoperatively, in the uveitis group the inflammation had to be controlled for a minimum of 3 months, except in patients with chronic anterior uveitis and 3 of those with posterior uveitis. In these patients, the surgery was undertaken when AC activity had been reduced to the lowest possible level. Patients with previously documented macular edema, disease activity within 3 months preoperatively or those with a poor outcome in the first eye due to macular edema or postoperative uveitis had been given prophylactic systemic corticosteroid treatment.

4.3.1.2.4 Postoperative management

After surgery, patients were reviewed within 48 hours and subsequent visits were determined according to clinical findings. Oral corticosteroids were withdrawn

gradually over 8 weeks. Routine phacoemulsification was performed and subconjunctival injection of antibiotics and corticosteroids was given to all the patients at the conclusion of the procedure.

4.3.1.2.5 Outcome measures and statistical analysis

In the two study groups, the primary outcome of interest was the performance of Nd:YAG capsulotomy, which was used as a surrogate measure of clinically significant PCO. The indications for Nd:YAG capsulotomy in the two groups were the presence of an opacified capsule that caused reduction in visual acuity in comparison to that achieved in the immediate postoperative period especially in the presence of visual symptoms or that compromised posterior segment visualisation even in the absence of visual symptoms.

Statistical analysis was undertaken using version 9 of Statistical Package for Social Science (SPSS) for Windows software. The distribution of continuous variables was expressed as the mean, standard deviation and inter-quartile range (IQR). Survival table analysis was used to derive the cumulative incidences as previously described (in 2.1.3.4) and Wilson's method to calculate their 95% confidence intervals (CI). Univariate and Cox multivariate survival analysis were used to identify risk factors associated with Nd:YAG capsulotomy. All variables that could possibly affect the development of PCO were included in the regression model especially if it had been shown to be associated with PCO in previous studies or if it had a *p* value of less than 0.2 in the univariate analysis. The backward stepwise method was used and the strength of association as a hazard ratio (HR) and the 95% confidence interval (CI) was calculated for both ratios. A *p* value of < 0.05 was considered significant. Post-hoc assessment showed that the study had more than 90% power to detect the difference in median survival time and to identify a 10% difference in the hazard ratio between the different study groups.

4.3.2 Results

4.3.2.1 Uveitis group

4.3.2.1.1 Patient characteristics

Table 4-1 shows the demographic and different clinical features of the patients. One hundred and one eyes of 101 patients were included, 43 (43%) of them were male. The mean age was 52.8 years (range= 14.1 to 88.2 years) and the mean follow-up time was 23.3 years (range= 3 to 79.5 months).

Postoperatively, 76 patients (75%) had one or more Snellen's lines of visual improvement (median=3 lines), with 65 (64%) having 2 or more lines. Fifty-eight (57%) of the patients had 6/12 or better and 32 (32%) 6/9 or better. At the final visit, 82 (81%) had 1 to 9 lines of visual improvement (median=4), with 72 (71%) having 2 or more lines. Seventy-eight (77%) had 6/12 or better and 57 (56%) 6/9 or better.

4.3.2.1.2 Postoperative complications

Raised intraocular pressure (IOP) requiring treatment occurred within the first 2 days in 6 patients (6%). During the postoperative follow-up, recurrence of uveitis occurred in 22 patients (22%) and macular oedema in 21 patients (21%).

Clinically significant deposits on the anterior lens surface were formed in 3 patients with plate-haptic silicone IOLs. They were dispersed using low-energy Nd:YAG laser applications. The procedures were uneventful and resulted in visual improvement in 2 of them.

Table 4-1. Patient characteristics in the uveitis group

No	101
Age at surgery (in years)	
Mean (SD)	52.8(15.6)
Median	51.5
IQR	42.7-65.2
Sex	
Male: Female	43: 58
Ethnic Origin	
Caucasian	67(66%)
Asian	13(13%)
Afro-Caribbean	10(10%)
Others	11(11%)
Uveitis type	
Anterior	57(56%)
Posterior uveitis	44(44%)
Systemic diseases associated with uveitis	
	25(25%)
IOL types	
PH silicone	32(32%)
3-piece silicone	15(15%)
Acrylic	24(24%)
Hydrogel	9(9%)
PMMA	21(21%)
Surgeon's grade	
Resident	20 (20%)
Fellow or consultant	81(80%)
Follow-up (in months)	
Mean (SD)	23.3(18)
Median	18.1
IQR	8.5-31.4

SD=standard deviation, IQR=interquartile range, BCVA=best-corrected visual acuity (Snellen's), CF=count fingers, PL=perception of light, PH=plate-haptic, PMMA=poly-methylmethacrylate

4.3.2.1.3 PCO and Nd:YAG Capsulotomy

4.3.2.1.3.1 Incidence

The crude incidences of PCO and Nd:YAG capsulotomy were 39 (39%) and 33 (33%), respectively, over the follow-up period. As such, PCO was the most common postoperative complication. The median time to Nd:YAG capsulotomy was 10.8 months (range=1.5 to 42.3 months).

Survival table analysis showed that the incidences of Nd:YAG capsulotomy were 19.2% [95% CI (12.4, 28.6)], 19% [95% CI (10.3, 32.2)], 27.9% [95% CI (13.5, 49)] and 15.4% [95% CI (2.8, 53.7)] after 1, 2, 3 and 4 years, respectively (Table 4-2).

Table 4-2. Incidences of Nd:YAG capsulotomy in the uveitic group

	No. of Patients Entering the Period:	No. of Nd:YAG Capsulotomy	% Incidence	95% Confidence Interval
	No. lost to follow-up			
Up to 1 year	101:25	17	19.2	12.4, 28.6
>1 year-2 years	59:23	9	19	10.3, 32.2
>2 years-3 years	27:11	6	27.9	13.5, 49
>3 years-4 years	10:7	1	15.4	2.8, 53.7
>4 years-5 years	2:0	0	0	0, 65.8

PCO=posterior capsular opacification

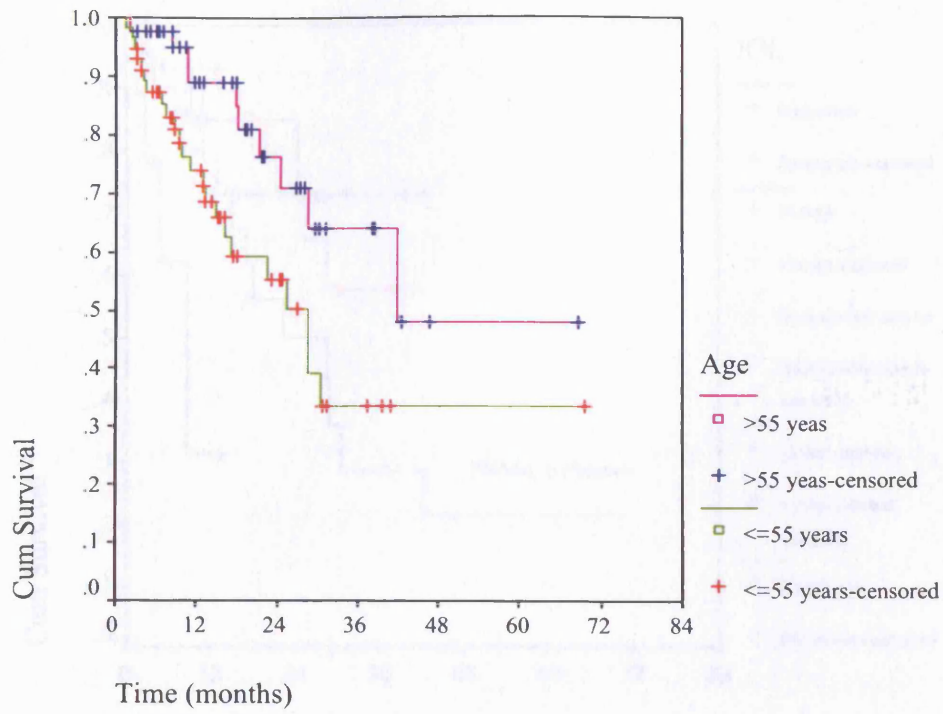
4.3.2.1.3.2 *Risk factors*

In order to identify the independent risk factors for Nd:YAG capsulotomy, a Cox regression model was constructed and included the patient’s age (>55 years vs. ≤55 years), gender, ethnic origin, the uveitis type (anterior vs. posterior), the use of prophylactic steroids, the presence of a uveitis-associated systemic disease, the surgeon’s grade, the presence of significant posterior synechiae and the type of the IOL as covariates. The model revealed that Nd:YAG capsulotomy was more likely in patients of 55 years or younger and with the use of hydrogel IOLs [HR=3.74; 95% CI (1.05, 13.33)] and was lower with the use of plate-haptic silicone [HR=0.23; 95% CI (0.08, 0.62)] and 3-piece silicone [HR=0.18; 95% CI (0.05, 0.71)] in comparison with PMMA IOL and in patients who had prophylactic steroids [HR=0.24; 95% CI (0.11, 0.60)] (Table 4-3 & Figure 4-1).

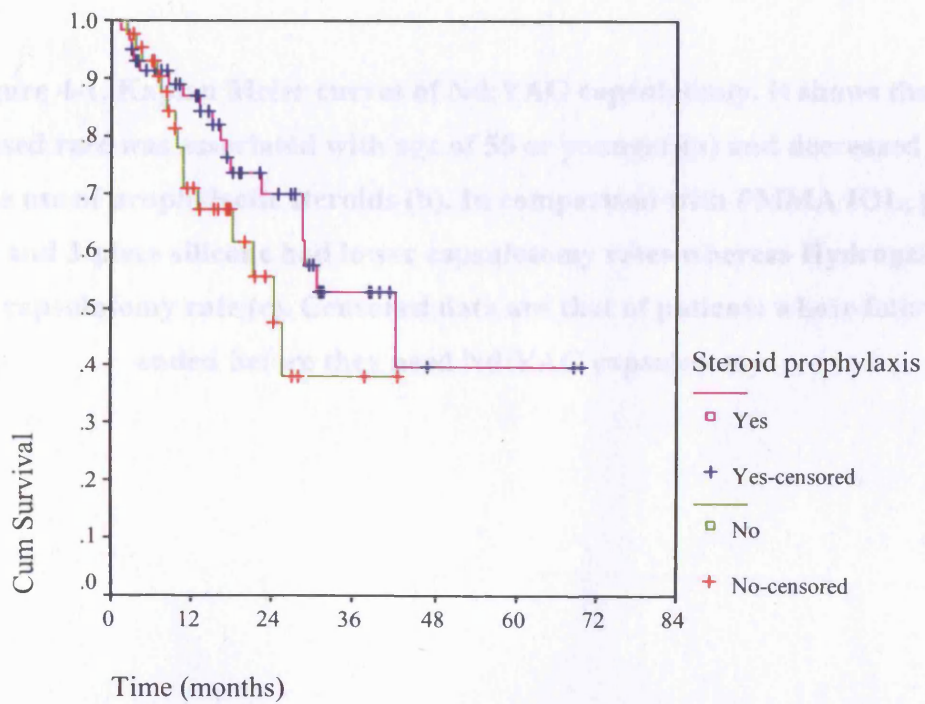
Table 4-3. Cox regression analysis of the factors affecting the rate of Nd:YAG capsulotomy

	HR	95% CI	p
Age			
>55 years	Reference		
≤55 years	2.28	1.06, 4.93	0.04
Prophylactic steroids			
No	Reference		
Yes	0.25	0.11, 0.59	0.002
IOL			
PMMA	Reference		
PH silicone	0.23	0.08, 0.64	0.005
3-piece silicone	0.19	0.05, 0.74	0.02
Hydrophobic acrylic	0.74	0.25, 2.23	0.60
Hydrogel	3.71	1.04, 13.20	0.04

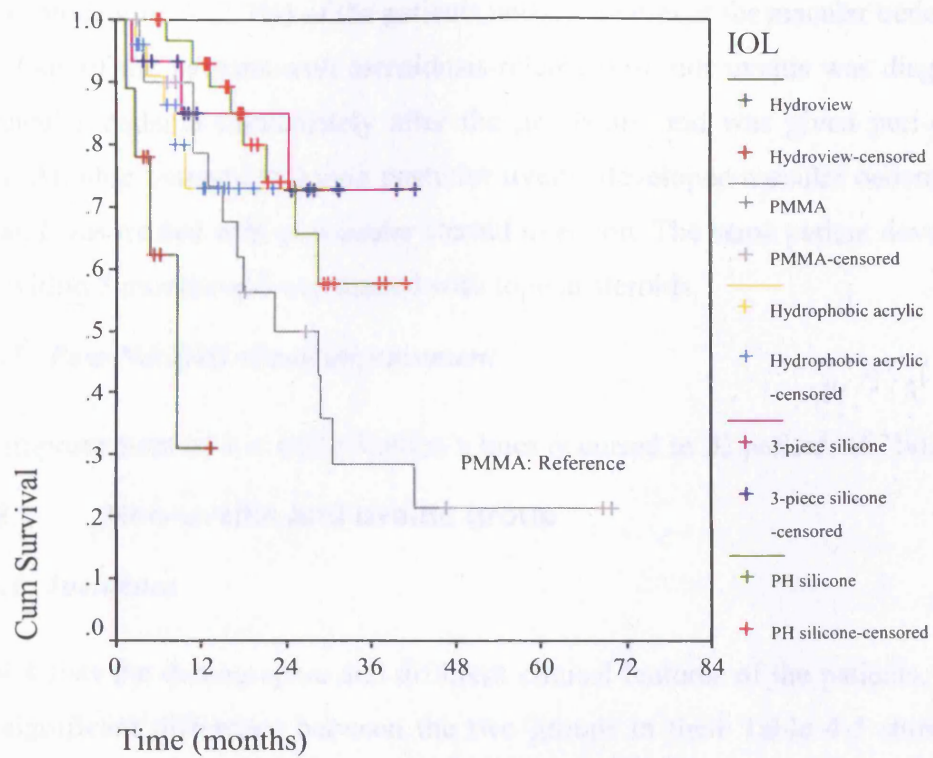
HR=Hazard ratio ; CI=confidence interval, IOP=intraocular pressure, PH=plate-haptic



a



b



c

Figure 4-1. Kaplan Meier curves of Nd:YAG capsulotomy. It shows that increased rate was associated with age of 55 or younger (a) and decreased rate with the use of prophylactic steroids (b). In comparison with PMMA IOL, plate-haptic and 3-piece silicone had lower capsulotomy rates whereas Hydrogel had higher capsulotomy rate (c). Censored data are that of patients whose follow-up ended before they need Nd:YAG capsulotomy

4.3.2.1.4 *Post-Nd:YAG uveitis or macular oedema*

After the procedure, 3 (7.7%) of the patients needed treatment for macular oedema or uveitis. One of the patients with sarcoidosis-related posterior uveitis was diagnosed with macular oedema immediately after the procedure and was given peri-ocular steroids. Another patient (3%) with posterior uveitis developed macular oedema at 8 weeks and was treated with peri-ocular steroid injection. The same patient developed uveitis within 3 months and was treated with topical steroids.

4.3.2.1.5 *Post-Nd:YAG visual improvement*

Visual improvement of 1 or more Snellen's lines occurred in 22 patients (67%).

4.3.2.2 Non-uveitic and uveitic group

4.3.2.2.1 *Incidence*

Table 4-4 lists the demographic and different clinical features of the patients. There was a significant difference between the two groups in their Table 4-5 shows the incidence of PCO that required Nd:YAG capsulotomy in the two patient groups over the follow-up period.

4.3.2.2.2 *Risk factors*

Survival analysis showed that there was no statistically significant difference between the rate of Nd:YAG capsulotomy between the two groups (Figure . On Cox multivariate regression analysis, no significant association was found between the presence of uveitis, type of IOL, surgeon's grade, young age, the devotement of postoperative inflammation and the need for Nd:YAG capsulotomy.

Table 4-4. Patient characteristic in the Non-uveitic and Uveitic group

	Non-uveitis (n=198)	Uveitis (n=53)	<i>P</i>
Male:Female	76:122	27:26	
Age (years)			
Median	73.5	55.5	<0.001
IQR	65-80	45.3-69	
<=55	22 (11.1%)	26 (49.1%)	<0.001
>55	176 (88.9%)	27 (50.9%)	
Ethnic origin			
Caucasian	90 (45.5%)	27 (50.9%)	<0.001
Asian	20 (10.1%)	12 (22.6%)	
Afro-Caribbean	8 (4%)	6 (11.3%)	
Other	17 (8.6%)	8 (15.1%)	
Unknown	63 (31.8%)	0 (0%)	
Surgeon's grade			
Resident	118 (59.6%)	4 (7.5%)	<0.001
Fellow/consultant	64 (32.3%)	10 (18.9%)	
Unknown	16 (8.1%)	39 (73.9%)	
IOL			
PMMA	28 (14.1%)	0 (0%)	<0.001
Plate-haptic silicone	158 (79.8%)	31 (58.5%)	
3-piece silicone	12 (6.1%)	7(13.2%)	
Hydrophobic acrylic	0 (0%)	15 (28.3%)	
Postop. Inflammation	20 (10.1%)	15 (28.3%)	0.001
Nd:YAG	30 (15.2%)	12 (22.6%)	
Follow-up (months)			
Median	13	18.9	<0.001
IQR	6.4-18.6	11.7-29.5	

Table 4-5. The incidence of Nd:YAG capsulotomy in the non-uveitic and uveitic group

	Non-uveitic (n=198)				Uveitic (n=53)			
	No. of Patients : No. lost to follow-up	No of YAG capsulotomy	% Incidence	95% Confidence Interval	No. of Patients : No. lost to follow-up	No. of YAG Capsulotomy	% Incidence	95% Confidence Interval
Up to 6 moths	198:40	12	7.6	4.4:12.8	53:2	0	0	0
>6 months-12 months	146:38	5	4.6	2:10.4	51:10	5	12.2	5.3:25.5
>12 months-18 months	103:49	3	5.6	1.9:15.1	36:13	2	8.7	2.4:26.8
>18 months-24 months	51:20	3	9.7	3.4:24.9	21:5	2	12.5	3.5:36
>24 months-30 months	28:11	0	0	0	14:4	3	30	10.8:60.3
>30 months-36 months	17:5	5	41.7	19.3:68.1	7:1	0	0	0
>36 months-42 months	7:2	1	20	3.6:62.5	6:5	0	0	0
>42months-48months	4:0	0	0	0	1:1	0	0	0

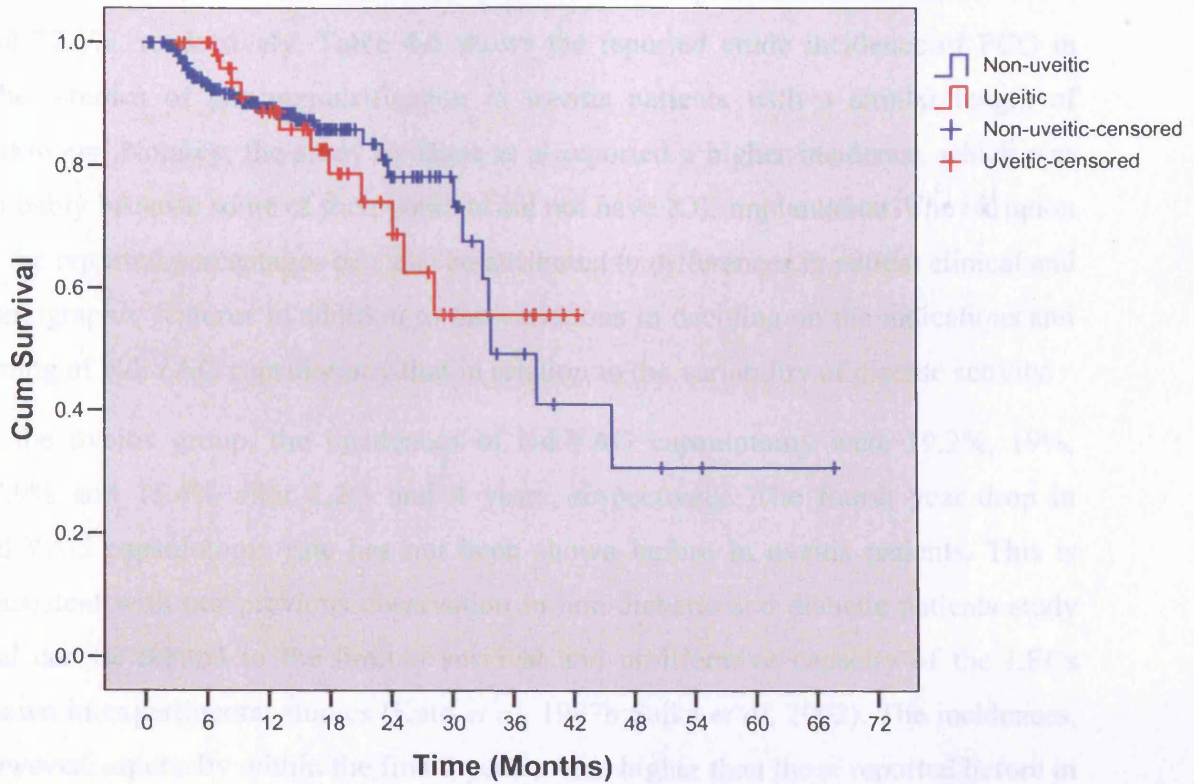


Figure 4-2. Kaplan Meier curves of Nd:YAG capsulotomy. It shows no significant difference in the rate of Nd:YAG capsulotomy between non-uveitic and uveitic patients. Censored data are that of patients whose follow-up ended before they need Nd:YAG capsulotomy

4.3.3 Discussion

4.3.3.1 Incidences of Nd:YAG capsulotomy

In the uveitis group, PCO occurred in 39%, and Nd:YAG capsulotomy was performed on 33%. In the non-uveitic and uveitic group, the incidences were 15.2% and 22.6%, respectively. Table 4-6 shows the reported crude incidence of PCO in other studies of phacoemulsification in uveitis patients with a similar length of follow-up. Notably, the study by Dana et al reported a higher incidence, which was probably because some of their patients did not have IOL implantation. The variation in the reported percentages can also be attributed to differences in patient clinical and demographic features in addition to the variations in deciding on the indications and timing of Nd:YAG capsulotomy that in relation to the variability of disease activity.

In the uveitis group, the incidences of Nd:YAG capsulotomy were 19.2%, 19%, 27.9% and 15.4% after 1,2,3 and 4 years, respectively. The fourth year drop in Nd:YAG capsulotomy rate has not been shown before in uveitis patients. This is consistent with our previous observation in non-diabetic and diabetic patients study and can be related to the limited survival and proliferative capacity of the LECs shown in experimental studies (Kato *et al*, 1997b; Saika *et al*, 2002). The incidences, however, especially within the first 2 years, were higher than those reported before in patient without uveitis (Table 4-5). This was also the case in the non-uveitic and uveitic group, where the incidences were consistently higher in patients with uveitis over the first 2 years.

Although, we could not establish an independent risk associated with the presence of uveitis for an overall increase in the rate of Nd:YAG capsulotomy, the increased incidence within the first 2 years after surgery is in agreement with other studies. Abela Formanek et al (Abela-Formanek *et al*, 2002d) found that uveitis patients had a denser PCO at 6 months after surgery. Also, Dana et al suggested an increased incidence of PCO in patients with uveitis that is related to their younger age at the time of surgery (Dana *et al*, 1997).

Table 4-6. Demographic features and prevalence of PCO after phacoemulsification in uveitis patients in recent studies of similar follow-up

	Dana et al, 1997 N=78 (108 eyes)*	Rauz et al, 2000 N=49 (60 eyes)	Estefanous et al, 2001 N=32 (39 eyes)	Suresh et al, 2001 N=75 (86 eyes)	This study N=101 (101 eyes)
Study type	Retrospective	Prospective	Retrospective	Retrospective	Retrospective
M:F		26:23	10:22	35:40	43:58
Age (years)					
Range	6-81	9-83	21-73	19-89	14.1-88.2
Mean	68.5†	48.2	50	43.8	52.8
Follow-up (months)					
Range	-	1-33	3-63	4-63	3-79.5
Mean	51.6	17.03	20	24.1	23.3
PCO	-	49(81.7%)	24(62%)	36(42%)	39(38.6%)
Nd:YAG capsulotomy	58(54%)	5(8.3%)	12(31%)	18(21%)	33(32.7%)
IOL deposits	-	19(31.7%)	-	17(19.7%)	3(3%)
Treatment of deposits (Nd:YAG or steroids)		No		Yes	Yes

†Median, *80% had a posterior chamber IOL.

Table 4-7. Comparison of the incidences of Nd:YAG capsulotomy in previous studies of non-uveitic and uveitic patients

	Non-uveitic			Uveitic	
	Dana et al, 1997*	Baratz et al, 2001	Ando et al, 2003	Dana et al, 1997**	This study
Type of study	Retrospective	Retrospective	Retrospective	Retrospective	Retrospective
No.	106(122 eyes)	2718	3997	78(108 eyes)	101
M:F (%)	-	33:67	34.8:65.2	-	43:57
Average age in years (Range)	68.5†(27-96)	74‡(1-103)	-	44.5†(6-81)	52.8(14.1-88.2)
Average follow-up in months (Range or SD)	46.8	44.4‡(0-116.4)	17.8‡(17.1 SD)	51.6	23.4(3-79.5)
% Incidence (95% confidence interval)					
Up to 1 year	11.5 (6.2, 16.8)	6 (5, 7)	1.95 (1.43, 2.47)	38.5 (28.9, 48.2)	19.2 (12.4, 28.6)
>1 year-2 years	-	15 (14, 17)	-	-	19 (10.3, 32.2)
>2 years-3 years	38.4 (29, 47.8)	23 (20, 25)	18.5 (16.1, 20.9)	56 (45.8, 66.3)	27.9 (13.5, 49)
>3 years-4 years	-	-	-	-	15.4 (2.8, 53.7)
>4 years-5 years	-	33 (31, 35)	32.7 (28.7, 36.7)	-	-
>5 years-6 years	-	38 (35, 40)	-	-	-

SD=Standard deviation, † Median, ‡ Mean, * 98% had a posterior chamber IOL, **80% had a posterior chamber IOL.

4.3.3.2 Risk factors for Nd:YAG capsulotomy

In the uveitis group, an increased Nd:YAG capsulotomy rate was associated with hydrogel IOLs, while a decreased rate was associated with plate-haptic and 3-piece silicone IOLs, in comparison to PMMA IOLs, and with the use of prophylactic steroids. There was no significant difference in the rate of Nd:YAG capsulotomy between patients with anterior and posterior uveitis nor between those who developed postoperative inflammation and those who did not. Also, neither ethnic origin nor gender affected the rate of Nd:YAG capsulotomy. In the non-uveitic and uveitic group, there was no association between increased risk of Nd:YAG capsulotomy over the follow-up period and the presence of uveitis, gender, ethnic origin, younger age, surgeon's grade or the type of IOL. In the study by Dana *et al*, 1997 (Dana *et al*, 1997), increased PCO rate in uveitis patients and was attributed mainly to the patients' younger age at surgery rather than to the presence of uveitis. Increased PCO rate with hydrogel implants has been shown before in uveitis (Abela-Formanek *et al*, 2002a) and non-uveitis patients (Abela-Formanek *et al*, 2002a; Hollick *et al*, 2000) and was ascribed to its increased water content in comparison with other implants, which encourages the proliferation of LECs.

To our knowledge, the effect of prophylactic steroids on lowering PCO rate in these patients has not been shown previously and may be related to inhibition of the lens epithelial cell proliferation as has been demonstrated in vitro studies with dexamethasone (McDonnell *et al*, 1988) and cyclosporin (Cortina *et al*, 1997). A possible indirect effect through inhibition of uveal inflammatory response cannot be excluded, however.

In the majority of patients, Nd:YAG capsulotomy was a relatively safe procedure and resulted in improvement of visual acuity in the majority of patients. The development of postoperative inflammation and CMO in 3 patients of those who needed the procedure (7.7%) seemed to be related to the natural course of the uveitis rather than to the procedure and its treatment was satisfactory.

There is lack of consensus regarding the most suitable type of IOLs to use in patients with uveitis (Raouf *et al*, 2000). In the current study, 3 patients with plate-haptic silicone IOLs developed clinically significant deposits on the anterior lens surface that required Nd:YAG laser treatment. Also, an increased rate of Nd:YAG laser

capsulotomy was found with the hydrogel implants. Both findings suggest that these two lenses should be better avoided in patients with uveitis.

4.3.4 Limitations

One caveat of this study seems to be its retrospective nature. We have tried to avoid bias in patient selection by including a continuous series. We also collected data about the possible surgery and uveitis-related potential confounders and used Cox multivariate analysis to account for differences in patient follow-up and to isolate independent factors associated with Nd:YAG capsulotomy. The lack of information on factors such as uveitis duration and the biochemical profile for all the patients, however, precluded their use in the multivariate analysis and their possible influence could not be ruled out.

4.3.5 Conclusion

Posterior capsular opacification is the most frequent complication after phacoemulsification in uveitis patients. The incidence appears to be higher within the first two postoperative years than those reported in non-uveitic patients, although the presence of uveitis does not seem to be independently associated with an overall increased risk of PCO. Hydrophilic acrylic IOLs (in comparison to PMMA IOLs) and an age of 55 years or younger can be associated with an increased risk, while the use of prophylactic steroids and silicone IOLs (in comparison to PMMA IOLs) with a decreased risk of PCO. Nd:YAG capsulotomy is a relatively safe procedure and results in improvement of visual acuity in the majority of uveitis patients.

4.4 STUDY OF THE INCIDENCE AND RISK FACTORS OF ND:YAG CAPSULOTOMY IN UVEITIS PATIENTS: PHACOEMULSIFICATION VERSUS EXTRACAPSULAR CATARACT EXTRACTION

4.4.1 Patients and methods

4.4.1.1 Design

This is a retrospective study. The dataset of a previous study of ECCE in uveitis that was conducted at one of the study centres (Okhravi *et al*, 1999) was retrieved and added to dataset of the previous study. The variables common to both datasets were collated and a new dataset was created.

4.4.1.2 Inclusion and exclusion criteria

In order to match the two groups of patients, only patients who were followed up for at least 3 months and who had preoperative visual acuity of <6/18 were included. Both subgroups were managed using the same preoperative and postoperative protocols. The exclusion criteria were similar to those in the previous study.

4.4.2 Results

4.4.2.1 Patient Characteristics

Table 4-8 details the demographic and clinical features of the two groups of patients. There were 71 patients in the phacoemulsification group, 41 with anterior uveitis (57.7%) and 30 with posterior uveitis (42.3%) and 63 in the ECCE group, 38 (60.3%) with anterior uveitis and 25 (39.7%) with posterior uveitis. Prophylactic systemic steroids were used in 29(41%) of phacoemulsification group and in 27 (43%) in the ECCE group.

Table 4-8. Demographic and clinical features of patients in the phacoemulsification and ECCE groups

	Phacoemulsification (N=71)	ECCE (N=63)	<i>p</i>
Age (years) *			
Mean (SD)	52.4(15.4)	52(16.3)	0.92
Median	51.9	52.9	
IQR	41.9-64.5	37.8-66	
Male: Female	30:41	30:33	0.53
Ethnic origin (%)			
Caucasian	46(65%)	40(64%)	0.88
Asian	7(10%)	7(11%)	0.03
Afro-Caribbean	8(11%)	16(25%)	0.81
Uveitis diagnosis			
Anterior: posterior	30:41	38:25	0.76
Systemic disease associated with the uveitis (%)	16(23%)	13(21%)	0.84
Preoperative Steroids	42(59%)	36(57%)	0.81
IOL†			
PMMA	19(26.8)	63(100)	<0.001
PH silicone	18(25.4)	0	
3-piece silicone	12(16.9)	0	
Hydrophobic acrylic	14(19.7)	0	
Hydrophilic acrylic	8(11.3)	0	
Time to Nd:YAG			
Mean	13	12.6	0.9
Median	10.8	11.9	
IQR	4.2-19.1	6.7-19.1	
Follow-up‡			
Mean (SD)	23.1(19.4)	11.5(5.2)	<0.001
Median	15.9	11.3	
IQR	8.4-29.5	7.3-14.1	

ECCE=extracapsular cataract extraction, IQR=interquartile range; PH=plate-haptic

*Independent t-test

† Chi-squared

‡ Mann-Whitney test

The two groups had similar age, gender distribution, uveitis diagnoses and preoperative acuity. No significant difference was found in the proportion who had systemic diseases in association with uveitis or those who had preoperative prophylactic corticosteroids. The number of Asians in the ECCE group was significantly larger (16/63 vs. 8/71; $p=0.03$) and the phacoemulsification group had a significantly longer follow-up (median=16.9 vs. 11.3, $p<0.001$).

4.4.2.2 Postoperative findings

Postoperative visual improvement occurred in 66 (93%) and 64 (90%) of the phacoemulsification group and in 61 (96.8%) and 59 (93.7%) of the ECCE subgroup. Immediate postoperative BCVA was significantly better in the phacoemulsification group than in the ECCE group ($p=0.015$).

Postoperative uveitis occurred in 14 patients (19.7%) in the phacoemulsification group and 19 patients (30.2%) in the ECCE subgroup. Macular oedema occurred in 14 (19.7%) and 13 (20.6%) in the phacoemulsification and ECCE subgroups, respectively.

4.4.2.3 Incidence of Nd:YAG capsulotomy

Nd:YAG capsulotomy was carried out on 22 patients in the phacoemulsification group and on 21 in the ECCE subgroup. The median time to Nd:YAG capsulotomy was 10.8 months in the phacoemulsification group (range=1.5-30.5 months) and 11.9 (range=3.3-26.9 months) in the ECCE subgroup. No postoperative complications were noted after Nd:YAG capsulotomy in either of the two subgroups.

Table 4-9 shows the incidences of Nd:YAG capsulotomy in the phacoemulsification and ECCE subgroups at each of the 6 monthly intervals following surgery. The incidences increased in the phacoemulsification group from 9% within the first 6 months to 20.2% within first half of the third year. In the ECCE subgroup, the incidences were 8.3% and 100% within the same periods. Notably, the incidences were consistently higher in the ECCE group after the first 6 months.

Table 4-9. Incidences of Nd:YAG capsulotomy in phacoemulsification and ECCE groups

	PE (n=71)				ECCE (n=63)			
	No. of Patients	No of		95%	No. of Patients	No. of		95%
	Entering the Period: No. lost to follow-up	Nd:YAG capsulotomy	% incidence	Confidence Interval	Entering the Period: No. lost to follow-up	Nd:YAG Capsulotomy	% incidence	Confidence Interval
Up to 6 months	71:8	6	9	4.2, 18.2	63:6	5	8.3	3.6, 18.1
>6 months-12 months	57:11	6	11.7	5.5, 23.2	52:18	6	14	6.6, 27.3
>12 months-18 months	40:12	4	11.8	4.7, 26.6	28:16	4	20	8.1, 41.6
>18 months-24 months	24:5	2	9.3	2.6, 28.4	8:2	5	71.4	35.9, 91.8
>24 months-30 months	17:7	3	22.2	7.9, 48.9	1:0	1	100	20.7, 100
>30 months-36 months	7:0	1	14.3	2.6, 51.3	0	0	0	0

PCO=posterior capsular opacification

4.4.2.4 Factors affecting the rate of Nd:YAG capsulotomy

A Cox regression hazard model including the type of surgery in addition to the patients' age (≤ 55 years or > 55 years), gender, ethnic origin, uveitis type (anterior vs. posterior) the use of prophylactic steroids, the presence of a uveitis-associated systemic disease and the development of postoperative uveitis showed that ECCE was an independent risk factors for increased Nd:YAG capsulotomy rate (HR=2.02; 95% Confidence Interval (CI)=1.05, 3.89; $p=0.03$) in comparison with PE, and so was age of 55 years or younger (HR=2.69; 95% CI=1.36, 5.30; $p=0.004$) in comparison with those of older age. The use of prophylactic steroids reduced the risk for Nd:YAG capsulotomy (HR=0.52; 95% CI=0.27, 0.98; $p=0.04$), Figures 4-2. The development of postoperative uveitis mildly increased the risk (HR=1.88; 95% CI=0.98, 3.58; $p=0.06$).

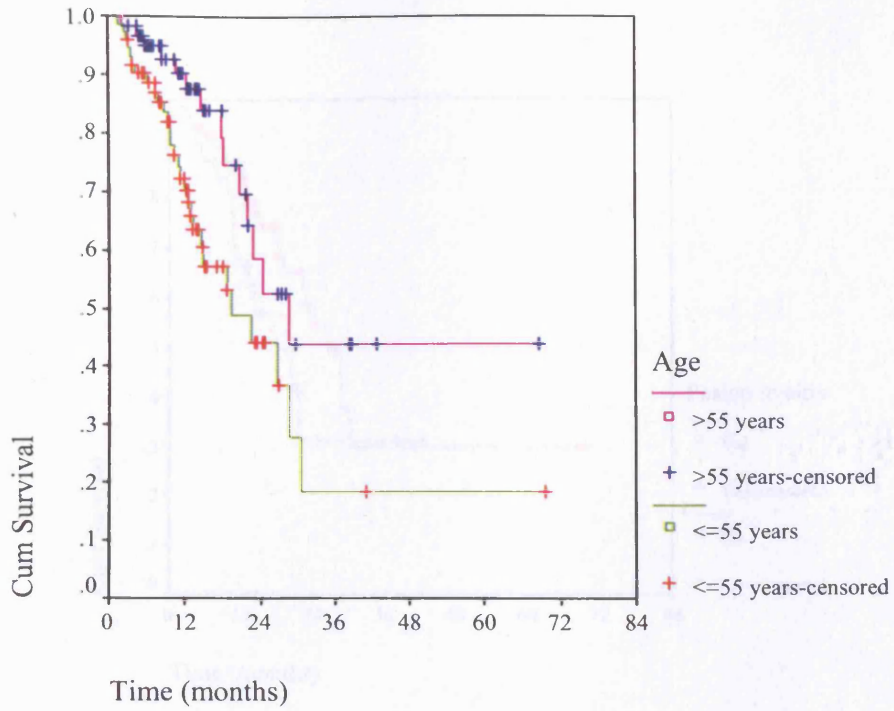
Including the type of IOL in the regression model (Table 4-8) showed that surgery had no significant effect while age of 55 years or younger, the use of prophylactic steroid and the development of postoperative uveitis were associated with increased risk of Nd:YAG capsulotomy. On the other hand, in comparison with PMMA IOL, plate-haptic silicone and 3-piece silicone IOLs were associated with a decreased while hydrophilic acrylic IOL with an increased risk.

Nd:YAG capsulotomy was generally a safe procedure and none of the patients developed a clinically significant complication that required treatment.

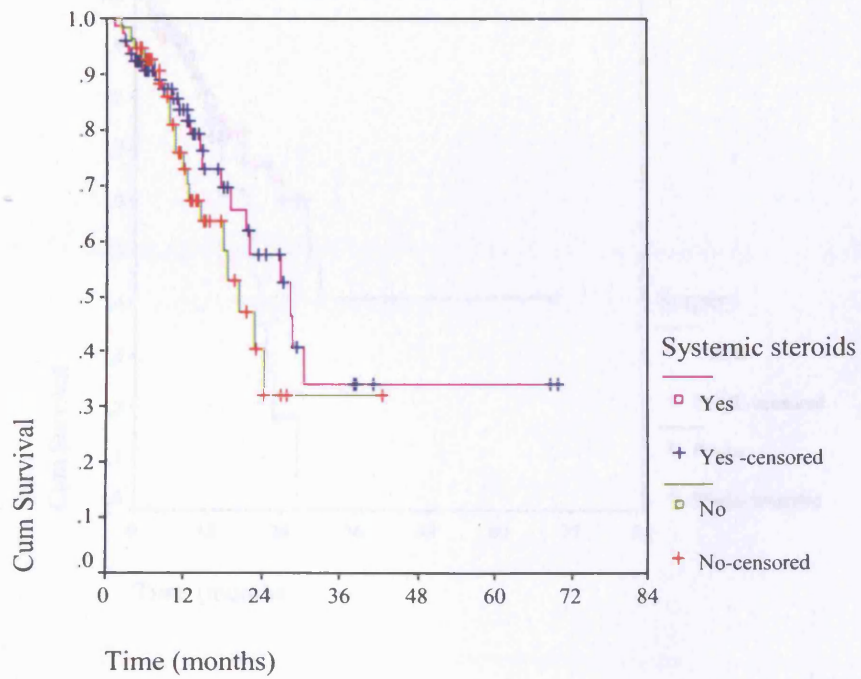
Table 4-10. Cox regression analysis of the factors affecting the rate of Nd:YAG capsulotomy

	HR	95% CI	<i>p</i>
Age			
>55 years	Reference		
≤55 years	2.62	1.30, 5.30	0.007
Prophylactic steroids			
No	Reference		
Yes	0.27	0.13, 0.56	0.0005
IOL			
PMMA	Reference		
PH silicone	0.09	0.02, 0.40	0.001
3-piece silicone	0.18	0.05, 0.68	0.01
Hydrophobic acrylic	0.93	0.28, 3.10	0.91
Hydrogel	5.81	1.57, 21.49	0.008
Postop uveitis	2.65	1.36, 5.18	0.004

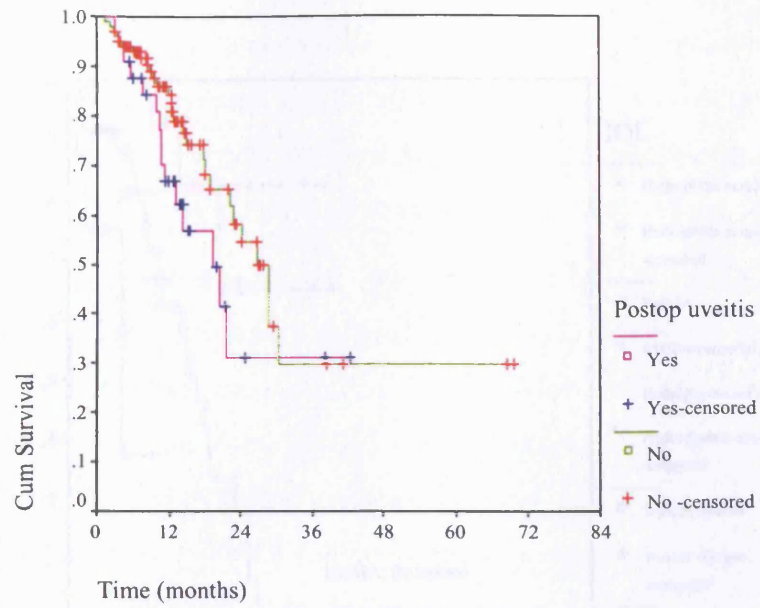
HR=Hazard ratio; CI=confidence interval, IOP=intraocular pressure, PH=plate-haptic



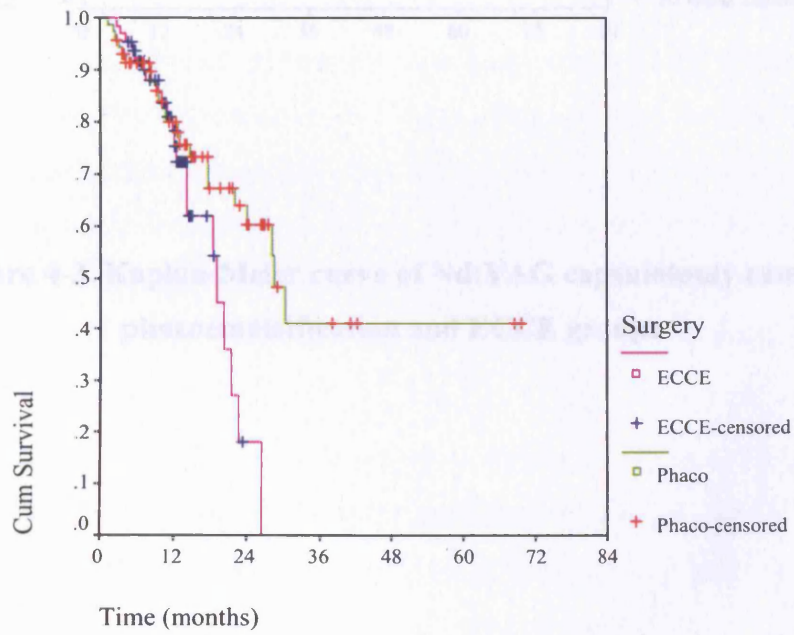
a



b

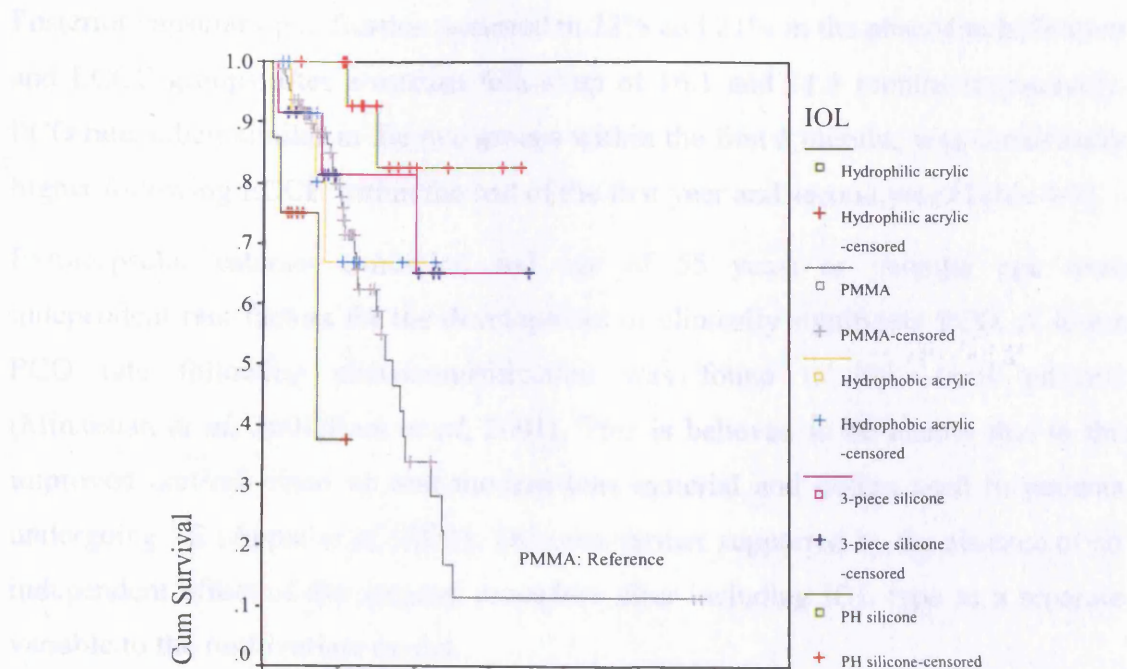


c



d

4.4.3 Discussion



e

Figure 4-3. Kaplan-Meier curve of Nd:YAG capsulotomy rate of phacoemulsification and ECCE groups

The development of postoperative inflammation, the rate of prophylactic steroids and IOL type independently affected the rate of PCO development. The rate of PCO in QOL patients was 14.3% (95% CI 7.8-21.0%), which is significantly higher than the rate of PCO in phacoemulsification patients (1.5%, 95% CI 0.5-2.5%). The rate of PCO in phacoemulsification patients was significantly lower than the rate of PCO in ECCE patients (14.3%, 95% CI 7.8-21.0%). The rate of PCO in phacoemulsification patients was significantly lower than the rate of PCO in ECCE patients (1.5%, 95% CI 0.5-2.5%). The rate of PCO in phacoemulsification patients was significantly lower than the rate of PCO in ECCE patients (1.5%, 95% CI 0.5-2.5%).

4.4.3 Discussion

Posterior capsular opacification occurred in 22% and 21% in the phacoemulsification and ECCE groups after a median follow-up of 16.1 and 11.3 months respectively. PCO rate, albeit similar in the two groups within the first 6 months, was consistently higher following ECCE within the rest of the first year and second year (Table 4-7).

Extracapsular cataract extraction and age of 55 years or younger age were independent risk factors for the development of clinically significant PCO. A lower PCO rate following phacoemulsification was found in non-uveitis patients (Minassian *et al*, 2001; Ram *et al*, 2001). This is believed to be mainly due to the improved cortical clean up and modern lens material and design used in patients undergoing PE (Apple *et al*, 2001). This was further supported by the absence of an independent effect of the surgical procedure after including IOL type as a separate variable to the multivariate model.

Also, the relationship between younger age and increased PCO rate has been established before (Wormstone *et al*, 1997) and was explained in view of the better survival and proliferative capacity of the LECs (Oharazawa *et al*, 2001; Balaram *et al*, 2000). Less traumatic removal of the lens nucleus by and hence the lower magnitude of blood-aqueous barrier damage (Pande *et al*, 1996b; Chee *et al*, 1999) and inflammatory response (Oshika *et al*, 1992) could be contributory to lowering the PCO rate after PE.

The development of postoperative inflammation, the use of prophylactic steroids and IOL type independently affected the rate of PCO development. Increased PCO in uveitis patients and in patients who develop postoperative inflammation can be related to the stimulatory effect of the plasma-derived growth factors in the aqueous of these patients, as a result of blood-aqueous barrier breakdown, on LEC proliferation (The paracrine mechanism in 1.1.6.1.2.1.3). In a study by Wormstone *et al*, 1997 (Wormstone *et al*, 1997), the addition of serum to the growing LECs increased the rate of lens epithelial cell proliferation via increasing the amount of stimulating growth factors in the aqueous humour. The effect of prophylactic steroids and intraocular lenses has been discussed in the previous study.

4.4.4 Limitations

The comparability of the two subgroups in the known major sources of bias, such as age, preoperative acuity, use of prophylactic steroids and type of uveitis in addition to the standard protocol of management used in both groups must have limited that and yielded fairly reliable comparisons. It was not possible to include factors such as the preoperative course or severity of the disease because of the different length of time after the onset of the disease when the patients were referred to us and because of the lack of standardised system for clinically grading the severity of uveitis.

4.4.5 Conclusion

This study has shown that in patients with uveitis, the surgical technique affect the rate of Nd:YAG capsulotomy over the follow-up period. This appears to be related mainly to the type of the IOL rather than to the surgical technique per se. Other risk factors include younger age, the development of postoperative uveitis and hydrophilic acrylic IOL, in comparison to PMMA IOLs while the use of prophylactic steroid seems to have a protective effect against the development of PCO.

CHAPTER 5

POSTERIOR CAPSULAR OPACIFICATION AFTER MULTIFOCAL INTRAOCULAR LENS IMPLANTATION

5 POSTERIOR CAPSULAR OPACIFICATION AFTER MULTIFOCAL INTRAOCULAR LENS IMPLANTATION

5.1 STUDY OF THE INCIDENCE OF POSTERIOR CAPSULAR OPACIFICATION AND ND:YAG CAPSULOTOMY AFTER IMPLANTATION OF MULTIFOCAL INTRAOCULAR LENS IMPLANTATION

5.1.1 Introduction

SA40N Array intraocular lens (Advanced Medical Optics, Inc. (AMO)) (Fine & Hoffman, 2000; Steinert, 2000; Avitabile & Marano, 2001) is a second-generation silicone refractive multifocal IOL that enables focusing for near as well as for intermediate and distant objects. The lens design was discussed in detail in 1.1.4.2.4. It has five aspheric concentric zones that incorporate an additional refractive power of 3.5 diopters (Figures 1-7 & 1-8). The design allows 50% of the light entering the eye to be dedicated to distance focusing, 13 % to intermediate focusing and 37% to near focusing. Because of these features, the Array IOL is known to cause dysphotopic symptoms such as glare (Haring *et al*, 2001; Javitt & Steinert, 2000; Leyland *et al*, 2002; Leyland & Zinicola, 2003; Steinert *et al*, 1999) and to reduce contrast sensitivity (Gimbel *et al*, 1991; Leyland & Zinicola, 2003; Steinert *et al*, 1999).

Dysphotopic symptoms and reduced contrast sensitivity can be exacerbated by opacification of the posterior capsule, which often gives rise to similar symptoms (Magno *et al*, 1997; Tan *et al*, 1998; Meacock *et al*, 2003; Hayashi *et al*, 2003), and, therefore, could potentially increase Nd:YAG capsulotomy rate among patients with this implant. Also, it is not known if factors such increasing age (Schmitz *et al*, 2000) and the degree of corneal astigmatism, which were found to affect the degree of contrast sensitivity loss as well as patients' satisfaction with these lenses (Ravalico *et al*, 1999) (Hayashi *et al*, 2000), can similarly affect the rate of Nd:YAG capsulotomy.

Several reports have been published of the incidence of PCO with monofocal silicone IOLs, which ranged between 24% to 39% up to 3 years after surgery (Mamalis *et al*, 1996b; Milazzo *et al*, 1996). One previous study reported an incidence of 32.5% PCO within one year in patients with diffractive multifocal IOLs (Voigt & Strobel, 1999). No study to date, however, has reported the long-term incidence and potential risk factors of PCO development and Nd:YAG capsulotomy following implantation of refractive multifocal IOLs.

5.1.2 Aims

The purpose of this study was to report the incidence of PCO and Nd:YAG capsulotomy after implantation of multifocal AMO Array IOL. We also aimed to examine the potential risk factors associated with the development of PCO and the symptoms most frequently prompting Nd:YAG capsulotomy.

5.1.3 Patients and methods

5.1.3.1 Inclusion and exclusion criteria

All available clinical notes of consecutive patients who underwent phacoemulsification and implantation of AMO Array IOLs between January 1996 and September 2002 (n=181) were retrieved and reviewed. All those who had uneventful surgery were eligible for inclusion. Exclusion criteria included amblyopia (n=1), concurrent ocular pathology such as significant macular scars of age-related maculopathy (n=3), uveitis (n=2) and glaucoma (n=3), a systemic disease that could affect PCO development such as diabetes mellitus (n=3) and long-term use of systemic steroids or cytotoxic agents (n=8). One eye only was randomly chosen for those who had bilateral surgery (n=11), which left 150 eyes of 150 patients.

5.1.3.2 Surgical technique

All the patients were operated on by a single surgeon using a standard phacoemulsification technique involving a temporal corneal section, capsulorhexis, hydrodissection, washout of the cortical matter, and insertion of the IOL using an unfolders (Advanced Medical Optics, Inc.). This was followed by subconjunctival injection of Cefuroxime 100mg and methylprednisolone acetate 40mg (Depo-Medrone, Pharmacia & Upjohn) at the conclusion of the procedure. Postoperative

treatment included G. Maxitrol (Alcon) QDS for 2 weeks then BID for 2 weeks or G Chloramphenicol and Dexamethosone.1% in patient allergic to the preparation. Patients were reviewed at 1 day, 6 weeks and 3 months then discharged or further follow-up arranged should there be a clinical indication.

5.1.3.3 Data collection

A spreadsheet was used for entering all the relevant data including age at surgery (<75 years & \geq 75 years), the medical and ocular history, Snellen's best-corrected visual acuity (BCVA) preoperatively, postoperatively as well as pre and post Nd:YAG capsulotomy, the time to Nd:YAG capsulotomy and follow-up time. The occurrence of uveal inflammation that required steroid treatment within 3 months after surgery, the dioptric power of the IOL, postoperative refraction and visual symptoms that prompted capsulotomy were recorded. The spherical equivalent was categorised into: emmetropic, myopic or hyperopic, and the presence of astigmatism into <1 dioptre or \geq 1dioptre.

5.1.3.4 Outcome measure and statistical analysis

Two outcome measures were examined: the presence of PCO and the need for Nd:YAG capsulotomy. Patients were either self-referred or referred by a primary care unit if they had developed visual symptoms attributable to PCO i.e. blurred or double vision or increased glare or halos. Patients were offered Nd:YAG capsulotomy if they were found to have PCO in the presence of the above symptoms or impaired fundus visualization. Slitlamp grading of PCO was carried out by a single observer into: mild (faint opacity, clear fundus view, with or without minimal symptoms of reduced acuity or glare symptoms), moderate (moderate opacity, slightly hazy fundus view, and symptoms of glare or reduced acuity) or severe (severe opacity, blurred fundus view and symptoms of reduced acuity).

The Statistical Package for Social Science software for Windows (Release 9, SPSS Inc., Chicago, Illinois, USA) was used for statistical analysis. Survival tables were used to derive the incidences of PCO and Nd:YAG capsulotomy. The incidence was calculated as the number of events (i.e. PCO or Nd:YAG) divided by the number of patients at risk at each of the time intervals (No. of patients entering the period-50% of those lost to follow-up). Confidence intervals for incidences were calculated using the Wilson score method. Log rank and the Median tests were used for comparisons

and a p value of <0.05 was considered significant. The study had more than 90% power to detect a 10% difference in hazard ratio for the examined risk factors of PCO (age, refractive outcome, degree of astigmatism and postoperative inflammation).

5.1.4 Results

5.1.4.1 Patient characteristics

We included 150 patients, of whom 87 (58%) were female. The median age was 78 years (range=47-100) and the median follow-up 23.4 months (range=1.4-73.2).

Twenty-three patients (15.3%) were referred with PCO, 14 of whom (60.1%) were of grade 1 and 9 (39.1%) of grade 2. Nd:YAG capsulotomy was performed in 14 (9.3%) and the median time to Nd:YAG capsulotomy was 25.2 months (range=8.6 to 47.7 months).

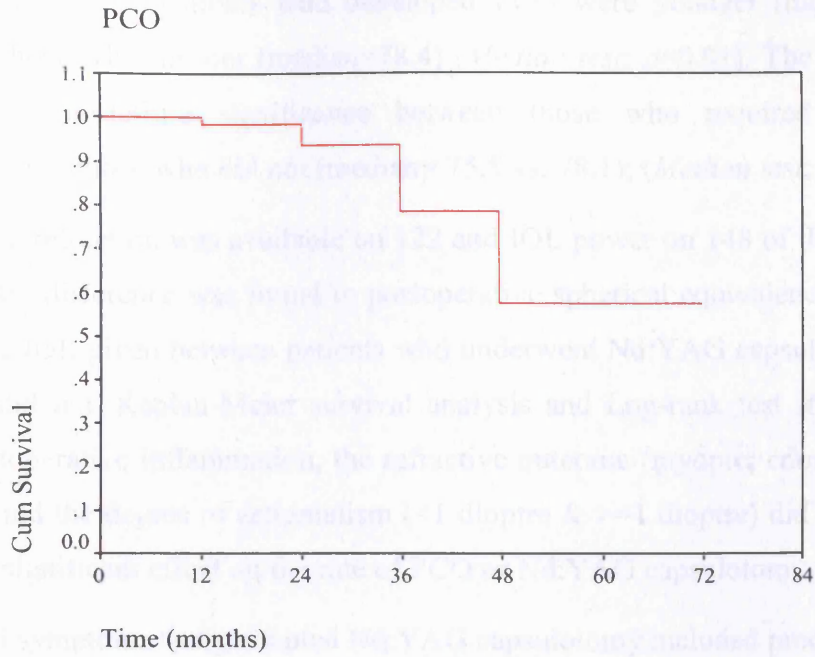
5.1.4.2 Incidence of PCO and Nd:YAG capsulotomy

Survival tables (Table 5-1) and the survival curves (Figure 5-1) show the incidences of PCO and Nd:YAG capsulotomy within 6 years of follow-up. Both show that the majority of PCO and Nd:YAG capsulotomy occurred between two and four years after surgery and that no new cases of PCO or Nd:YAG capsulotomy were noted after the fourth year.

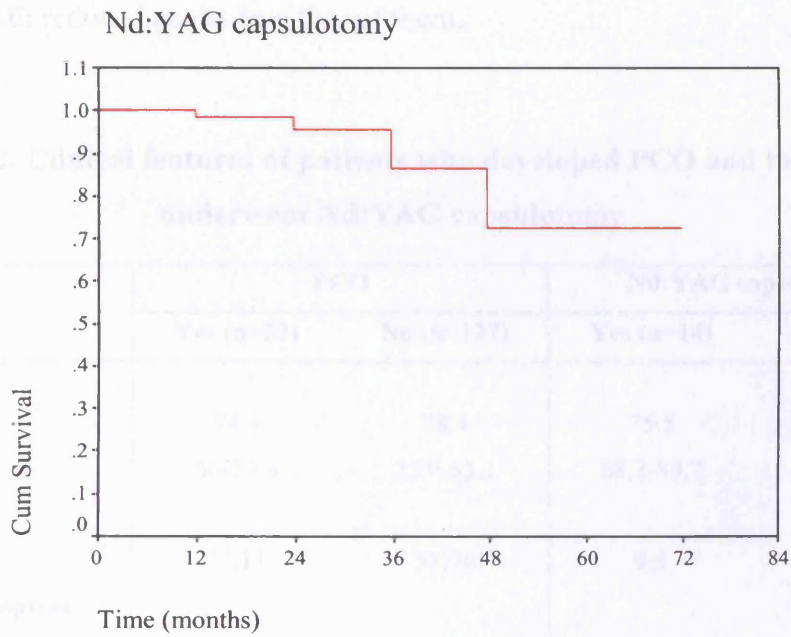
Table 5-1. Incidence of PCO and Nd:YAG capsulotomy

	PCO (n=23)				Nd:YAG capsulotomy (n=14)			
	No. of Patients		95% Confidence		No. of Patients		95% Confidence	
	Entering the Period: No. lost to follow-up	No of PCO	% Incidence	Interval	Entering the Period: No. lost to follow-up	No. of Nd:YAG Capsulotomy	% Incidence	Interval
Up to 1 year	150:27	2	1.5	0.4, 5.2	150:27	2	1.5	0.4, 5.2
>1 year-2 years	121: 47	5	5.1	2.2, 11.5	121:49	3	3.1	1.1, 8.8
>2 years-3 years	69: 26	9	16.1	8.7, 27.8	69:30	5	9.2	4, 19.9
>3 years-4 years	34: 16	7	26.9	13.7, 46	34:19	4	16.7	6.7, 35.9
>4 years-5 years	11: 8	0	0	0-35.4	11:8	0	0	0-35.4
>5years-6years	3:3	0	0	0-56.2	3:3	0	0	0-56.2

PCO=posterior capsular opacification



a



b

Figure 5-1. Kaplan-Meier survival curve of PCO (a) and Nd:YAG capsulotomy (b) over the follow-up period. It shows that the majority of cases occurred between 2 to 4 years after surgery

Table 5-2 shows that patients who developed PCO were younger (median=74.4 years) than those who did not (median=78.4) (*Median test; p=0.01*). The difference was only of borderline significance between those who required Nd:YAG capsulotomy and those who did not (median= 75.5 vs. 78.1); (*Median test; p=0.09*).

Postoperative refraction was available on 122 and IOL power on 148 of the patients. No significant difference was found in postoperative spherical equivalence or in the power of the IOL given between patients who underwent Nd:YAG capsulotomy and those who did not. Kaplan-Meier survival analysis and Log-rank test showed that gender, postoperative inflammation, the refractive outcome (myopic, emmetropic & hyperopic) and the degree of astigmatism (<1 dioptre & >=1 dioptre) did not have a statistically significant effect on the rate of PCO or Nd:YAG capsulotomy.

PCO-related symptoms that prompted Nd:YAG capsulotomy included predominantly reduction of BCVA, which ranged between 1 to 5 Snellen's lines (median=2.5 lines) (n=12; 85.7%) and, less frequently, glare or halos (n=2, 14.3%), which was not associated with reduced acuity in either of them.

Table 5-2. Clinical features of patients who developed PCO and those who underwent Nd:YAG capsulotomy

	PCO		Nd:YAG capsulotomy	
	Yes (n=23)	No (n=127)	Yes (n=14)	No (n=136)
Age (years)				
Median	74.4	78.4	75.5	78.1
IQR	66-79.6	72.9-83.1	68.2-80.7	72.3-82.9
Sex				
M:F	12:11	51:76	9:5	54:82
IOL power (dioptries)				
Median	21.5	21	21.3	21.
IQR	19.5-22.5	20-22.5	19.4-22.6	19.9-22.5
Postop sph. equivalent				
Median	-0.25	0.13	-0.25	0.13
IQR	-0.50 to 0.50	-0.50 to 0.50	-0.88 to 0.43	-0.5to 0.50
Postop inflammation				
Yes/No	4/19	8/119	2/12	10/126

PCO=posterior capsular opacification, M=male, F=female, IQR=interquartile range

5.1.5 Discussion

5.1.5.1 Incidences of PCO and Nd:YAG capsulotomy

This study is the first to report the long-term incidence of PCO with AMO ARRAY multifocal implants. The estimated annual incidences were based on the number of patients who were self-referred or were referred by primary care units for PCO-related symptoms. The assumption of the study was that the rest of the patients either had clinically insignificant PCO or did not require Nd:YAG capsulotomy for their vision was reduced because of other concomitant ocular pathology. As such, our estimated incidences should reflect those in the majority of secondary ophthalmic units. Sundelin and Sjostrand (Sundelin & Sjostrand, 1999) estimated that a 'hidden' group of patients that would have clinically significant PCO and benefit from Nd:YAG capsulotomy represents only 9% of patients within 5 years following cataract extraction.

In this study, the incidences of PCO were 1.5% (0.4, 5.2), 5.1% (2.2, 11.5), 16.1% (8.7, 27.8) and 26.9% (13.7, 46) and that of Nd:YAG capsulotomy were 1.5% (0.4, 5.2), 3.1% (1.1, 8.8), 9.2% (4, 19.9) and 16.7% (6.7, 35.9) after 1, 2, 3 and 4 years of follow-up. These progressively increasing incidences concur with the study by Ando et al, (Ando *et al*, 2003) who reported a cumulative probability of capsulotomy of 1.95%, 18.5% and 32.7% after 1, 3, and 5 years, respectively. The relatively higher percentage in their study could possibly be related to the variety of IOLs used, which included PMMA (43.6%), silicone (41.5%) and acrylic (12.6%) types, in addition to the inclusion in their series of patients with other systemic and ocular comorbidity such as diabetes mellitus (14%), diabetic retinopathy (5.2%) and retinitis pigmentosa (0.8%).

In our study, no cases were noted after the fourth year possibly because of the relatively small number of patients that were followed up more than 4 years. Baratz et al (Baratz *et al*, 2001) in a large retrospective series, reported a cumulative incidence of 23 % at 3 years that increased to 33% at 5 years and only to 38% at 9 years. They suggested that the increase in PCO rate that occurs within the first 5 years might not continue after the sixth year. This could be related to a plausible temporal decline in the survival of LECs and their proliferative capacity.

The PCO incidence in this study is less than that reported after other multifocal IOLs. Negishi and associates (Negishi *et al*, 1996) reported 4.2% incidence of PCO after 6 months of follow-up of patients who had a five-zone refractive multifocal IOL made of PMMA. The incidences in our study are, however, comparable to those reported after other modern silicone and acrylic IOLs. Beltrame *et al* (Beltrame *et al*, 2002) found that two years after surgery 27.6% of patients with the SI-40 monofocal silicone lens had PCO and 9.7% had Nd:YAG laser capsulotomy. Oner *et al* (Oner *et al*, 2000) and Abhilakh *et al* (Abhilakh Missier *et al*, 2003) reported incidences of 14.3% and 8.5% of PCO after 18 months and 3 years of implantation of acrylic IOLs, respectively.

5.1.5.2 Risk factors for PCO and Nd:YAG capsulotomy

We found that patients who developed PCO were younger, but there was no significant age difference between those who had Nd:YAG capsulotomy and those who did not. The explanation could be that the need for Nd:YAG capsulotomy is perhaps more related to the magnitude of influence of PCO on visual function and visual demands dictated by patients' life style than their age. On the other hand, our sample size could have limited the ability to detect a difference in the age between patients who needed Nd:YAG capsulotomy and those who did not.

5.1.5.3 Symptoms associated with Nd:YAG capsulotomy

Patients required Nd:YAG capsulotomy predominantly for reduced vision (85.7%) rather than for glare symptoms (14.3%). This concurs with the findings by Hayashi *et al* (Hayashi *et al*, 2003) that PCO value in patients with monofocal IOLs correlates more strongly with visual acuity than with contrast sensitivity and glare sensitivity. Notably, however, none of our patients had PCO of more than grade 2 and it is not known if that is due to a tendency of these patients to present earlier due to the effect of PCO on other visual functions such as near acuity or contrast sensitivity.

5.1.6 Limitations

The limitation of this study is related to the retrospective design. Future prospective studies that will include a contemporary group of patients with monofocal implants will be able to avoid some of the inherent potential bias of the retrospective design and will help to directly compare the incidences as well as the differential effect of

PCO on the different aspects of visual function between the two groups. It will also help to establish if that effect will rather vary the length of time to presentation and to requiring Nd:YAG capsulotomy than its incidence.

5.1.7 Conclusion

After phacoemulsification and AMO ARRAY IOL implantation, PCO and Nd:YAG capsulotomy incidences are similar to those reported after other modern foldable monofocal implants. The incidences steadily increase till the fourth year, with the majority of cases occurring after the first year. PCO tends to develop in younger patients and Nd:YAG capsulotomy, similar to the case with monofocal implants, appears to be largely prompted by reduced vision rather than glare symptoms.

5.2 STUDY OF THE EFFECT OF POSTERIOR CAPSULAR OPACIFICATION ON VISUAL FUNCTION IN PATIENTS WITH MONOFOCAL AND MULTIFOCAL INTRAOCULAR LENSES

5.2.1 Introduction

Posterior capsular opacification (PCO), by causing forward and backward light scattering, reduces visual acuity and contrast sensitivity (Cheng *et al*, 2001; Meacock *et al*, 2003; Hayashi *et al*, 2003; Magno *et al*, 1997; Tan *et al*, 1999). The magnitude of the effect of PCO on visual function was found to be related mainly to its location, density and type, with epithelial pearls having a more pronounced effect on visual acuity and contrast sensitivity (Cheng *et al*, 2001; Aslam *et al*, 2003a; Aslam & Patton, 2004).

All published studies of the effect of PCO on visual function have been conducted on patients with monofocal IOLs. Because multifocal intraocular lens design reduces contrast sensitivity (Haring *et al*, 2001; Leyland & Zinicola, 2003), it is not known if this can be exacerbated by the development of PCO, which could lead to an increased rate of Nd:YAG capsulotomy. We hypothesised that the magnitude of PCO-induced impairment of visual function when presenting for Nd:YAG capsulotomy might be different between patients with monofocal and multifocal IOLs.

5.2.2 Aim

The aim of this study was to compare the functional impairment in patients with monofocal and multifocal IOLs who presented for Nd:YAG capsulotomy. The results will help in understanding the relative effect of this complication on visual function in the two groups of patients and to assess whether functional loss can potentially be a risk factor for increased Nd:YAG capsulotomy rate.

5.2.3 Patients and method

This is a prospective non-randomised case-control study. The appropriate ethical approval was obtained for the study and all eligible patients were informed of the study design and its aims before they gave consent to be included.

5.2.3.1 Eligibility and inclusion criteria

Fifty-four patients were recruited consecutively from the outpatient clinic at Essex County Hospital, Colchester between April and November 2004. Only the first eye to develop the symptoms for patients who needed bilateral Nd:YAG capsulotomy was included. Patients were considered eligible for inclusion if they had undergone cataract extraction and implantation of either monofocal or multifocal IOLs and were referred because of visual symptoms attributable to PCO and had lost at least one line of Snellen's visual acuity.

5.2.3.2 Exclusion criteria

Patients with a history suggestive of amblyopia (n=1) or colour blindness (n=1) and those who had glaucoma (n=6), diabetic retinopathy (n=4), neo-vascular or atrophic age-related maculopathy (n=6) or pupillary abnormality (n=3) were excluded, which left 33 patients.

5.2.3.3 Examination

5.2.3.3.1 Visual acuity

High-contrast (90%) distance and near best-corrected visual acuities (BCVA) were measured using logMAR charts at 3 meters and 40cm, respectively. The charts were externally illuminated and illumination levels at the charts were 400 lux. The patients were encouraged to read as far down the charts as they can. The acuity was recorded as a logMAR score of the total number of letters that were identified correctly.

5.2.3.3.2 Contrast sensitivity

Pelli-Robson and low-contrast (10%) logMAR acuity charts were used to examine contrast sensitivity. Pelli-Robson chart has 8 lines of Sloan letters that subtend a visual angle of 3 degrees at a test distance of 1 meter. The letters are arranged in triplets, each progressively decrease in contrast from 96% to 1%. The 10% logMAR

acuity chart was tested at 3 meters. Both charts were externally illuminated and the illumination levels at their surfaces were approximately 400 and 300 lux, respectively.

5.2.3.3.3 Colour vision

All the patients underwent Ishihara test to identify those with congenital colour blindness. Colour vision was then tested using Lanthony desaturated D15 test that was conducted under an additional external illumination of 1000 lux produced by a fluorescent lamp placed at 35 cm from the colour chips. The Colour Vision Recorder software (v. 2.3; Optical Diagnostics, The Netherlands) was used to record the results and to calculate the colour confusion index (CCI). (Bowman, 1982) The latter indicates how much the patient's arrangement of the colour chips deviates from the perfect arrangement: an index of 1 indicates a perfect arrangement and a value larger than 1 indicates some colour confusion or error.

5.2.3.3.4 Slit lamp examination

This included anterior segment and fundus examination in addition to intraocular pressure measurement.

5.2.3.3.5 Determining type and grading of PCO

A single examiner determined the PCO type and grade. PCO was classified clinically into 'fibrotic' or 'cellular' according to the predominant feature (> 50%) within the retro-optic part of the posterior capsule. PCO grading was carried out after pupillary dilatation and was determined based on the visibility of the posterior segment structures on the slit lamp. A modification of the grading system used by several other authors (Aslam & Dhillon, 2002; Kucuksumer *et al*, 2000; Kruger *et al*, 2000; Sellman & Lindstrom, 1988) was adopted (Table 5-3).

Table 5-3. PCO grades

Grade I (Mild)	The outlines of the optic nerve head and main retinal vessels (\pm retinal striations) are clearly distinguishable.
Grade II (Moderate PCO)	The outlines of the optic nerve head or of the main retinal blood vessels are blurred
Grade III (Severe or Dense)	The optic nerve head and blood vessels are barely visible.

5.2.3.4 Questionnaire

A questionnaire (Table 5-4) was administered by the examiner during the consultation before and 2 to 6 weeks after capsulotomy. It included questions about different PCO-related visual symptoms, including blurred distance and near vision, colour vision, dysphotopic symptoms or diplopia. Patients were asked to rate the symptoms as mild, moderate or severe, depending on how much it affected their day-to-day activities. After capsulotomy, the questions were whether the symptoms have disappeared, improved or got worse and if new symptoms had developed.

5.2.3.5 Nd:YAG capsulotomy

Before capsulotomy, G. Tropicamide 1% was instilled in the eye to achieve 4 to 6mm of pupillary dilation. Also, G. Apraclonidine 0.1% (Iopidine) was used before and after the procedure to prevent rise of intraocular pressure. The procedure was performed using Cooper Vision 2500 (Alcon) machine and 2 to 4mJ of energy per pulse that were increased as needed. The laser beam was posteriorly defocused in order to avoid pitting the lens.

5.2.3.6 After care

After capsulotomy, G. Dexamethasone 0.1% (Maxidex; Alcon Inc.) was prescribed QDS for 1 week and BID for one week. All the patients were reviewed 2 to 6 weeks when the same visual tests were carried out and a questionnaire regarding the change in visual symptoms was administered. Visual acuity, contrast sensitivity and colour vision were assessed as before and under the same conditions. The anterior and posterior segments were assessed for adequacy of the capsular opening, IOL position, clarity of the visual axis, signs of inflammation and macular oedema.

Table 5-4. The questionnaires administered before and after Nd:YAG capsulotomy

<p><i>Before capsulotomy</i></p> <p>What is the main problem with the eye that needs laser treatment?</p> <p>Mild (can manage)/ Moderate (manage with difficulty)/ Severe (unable to manage)*</p> <ul style="list-style-type: none">▪ Blurred distance vision (e.g. TV/reading signs or bus numbers)▪ Blurred near vision (e.g. reading/needle work)▪ Disturbed colour vision▪ Glare▪ Halos▪ Streaks/stars/flare▪ Double vision▪ Other (please mention) <p><i>After capsulotomy</i></p> <p>How has the laser affected the symptoms you had?</p> <p>Disappeared, No change, Worse*</p> <ul style="list-style-type: none">▪ Blurred distance vision (e.g. TV/reading signs or bus numbers)▪ Blurred near vision (e.g. reading/needle work)▪ Disturbed colour vision▪ Glare▪ Halo▪ Streak/stars/flare▪ Double vision▪ Other (please mention)

* These were the choices for each of the questions.

5.2.3.7 Statistical Analysis

The primary outcome of the study was the difference in the presenting visual functions (distance and near visual acuity, contrast sensitivity and colour confusion index) at presentation between the two groups of patients. The secondary outcome was the difference in the proportion of patients with different PCO-related symptoms in the two groups.

We used the independent t-test or Mann-Whitney test (when the data were not normally distributed) for comparison of continuous data. Fisher's exact test was used for comparing proportions of patients with different PCO-related symptoms. The study had 90% power to detect a 0.2 log units (2 lines on the high and low contrast log MAR chart) in the mean preoperative acuity (SD 0.1), of 0.3 of log units of Pelli-Robson contrast sensitivity (1 line) and 0.25 in the mean colour confusion index (with a standard deviation of 0.15) at an alpha level of 0.05.

5.2.4 Results

5.2.4.1 Clinical features

Thirty-three patients were included in the study, 13 of them were males and the median age was 76.2 years (range 18 to 91). Thirty-two of the patients had undergone phacoemulsification and one extracapsular cataract extraction. Twenty-four patients (72.7%) had monofocal IOL, including PMMA: 95UV, Storz (Refractive index (RI)=1.49) (n=3, 12.6%); Silicone: SI30NB, SI40NB or Clariflex; Advanced Medical Optics, Inc. (RI=1.46) (n=15, 62.6%), Lenstec LH3000, Lenstec Inc. (RI=1.4585) (n=5, 25%) or Hydrogel: Li61U Soflex, Bausch & Lomb (RI=1.427) (n=1, 4.2%). Nine patients (27.3%) had silicone refractive multifocal IOL, Array SA40N, Advanced Medical Optics, Inc. (RI=1.46, n=9, 100%).

There was no significant difference in age, gender distribution, PCO type or grade, the time to presentation for capsulotomy or the spherical equivalent between the two groups (Table 5-5).

Table 5-5. Clinical features of patients in the two groups

	Monofocal	Multifocal	<i>P</i>
M:F	12:12	1:8	0.06
Age			
Mean (SD)	75.1 (9.5)	67.01 (22.6)	0.48
Median	76.2	75.9	
IQR	71.4 to 82.6	54.4 to 83.1	
PCO type			
Cellular	10(41.7%)	3 (33.3%)	0.25
Fibrotic	14(58.3%)	6(66.7%)	
PCO grade			
Mild	5(20.8%)	5(55.6%)	0.15
Moderate	13(54.2%)	3(33.3%)	
Severe	6(25%)	1(11.1%)	
Time to Nd:YAG			
Mean (SD)	36.5 (34.6)	24.8 (18.3)	0.54
Median	28.9	16.5	
IQR	11.1 to 49.1	8.1 to 40.7	
Spherical equivalent			
Mean (SD)	-0.31 (1.31)	-0.33 (0.56)	0.54
Median	0	-0.38	
IQR	-1.19 to 0.75	-0.69 to 0.06	

M=male; F=female; SD=standard deviation; IQR=interquartile range

5.2.4.2 Visual function

At presentation, high- and low-contrast logMAR acuity were significantly better (smaller values) in the multifocal group (0.40 vs. 0.20; $p=0.04$ & 0.34 vs. 0.98; $p=0.006$) (Table 5-6). On the other hand, near acuity, Pelli-Robson contrast sensitivity and CCI were not significantly different between the two groups. After capsulotomy, high- and low contrast distance and near visual acuity, Pelli-Robson contrast sensitivity and CCI were not significantly different between the two groups (Table 5-6).

Table 5-6. Visual function in the two groups of patients

	Monofocal (n=24; 72.7%)			Multifocal (n=9; 27.3%)		
	Pre-Nd:YAG	Post-Nd:YAG	Difference	Pre-Nd:YAG	Post-Nd:YAG	Difference
Distance BCVA (logMAR)						
Mean (SD)	0.40 (0.58)*	-0.13(0.17)	0.54(0.64)	0.20 (0.69)*	-0.13(0.15)	0.33(0.77)
Near BCVA (logMAR)						
Mean (SD)	0.68 (0.36)	0.19(0.17)	0.47(0.39)	0.42 (0.41)	0.10(0.11)	0.3(0.37)
CS (Pelli-Robson)						
Mean (SD)	1.15 (0.39)	1.66(0.08)	0.48(0.39)	1.34 (0.44)	1.64(0.13)	0.24(0.42)
CS (10% log MAR)						
Mean (SD)	0.98 (0.76)*	0.07(0.19)	0.88(0.79)†	0.34 (0.32)*	0.16(0.22)	0.12(0.33)†
CCI						
Mean (SD)	1.31 (0.34)	1.23(0.41)	0.07(0.36) *	1.36 (0.48)	1.31(0.33)	0.09(0.36) *

BCVA=best-corrected visual acuity; logMAR=logarithm of minimum angle of resolution; SD=standard deviation;

IQR=interquartile range; CS=contrast sensitivity; CCI=colour confusion index

*Mann-Whitney test

5.2.4.3 Questionnaire results

The presenting symptoms (Table 5-7 & Figure 5-2) in the majority of patients in the two groups were blurred distance or near vision (95.8% & 100% in the monofocal group and 88.9% and 66.7% in the multifocal group). Glare and halos affected 45.8% and 25% of patients in the monofocal group and each affected 44.4% of patients in the multifocal group. Other dysphotopic symptoms such as seeing stars/ streaks/ flare; and other symptoms such as double vision and floaters affected a smaller proportion of patients in the two groups. A significantly greater proportion of patients in the monofocal group had blurred near vision (24/24 vs. 6/9; Fisher's exact; $p=0.01$). There was no statistically significant difference between the proportions of patients affected by the other symptoms in the two groups. While the symptoms in the majority of patients in the monofocal group were moderate to severe, in the majority of patients in the multifocal group they were mild to moderate (Table 5-7).

After capsulotomy, Table 5-8 shows that all patients in the monofocal group experienced improvement or complete disappearance of their symptoms. One of the patients in the multifocal group (1/8, 12.5%) had persistent symptoms of blurred distance and near vision and another (1/8, 12.5%) had persistent glare and halos. Also, 19% and 25% of the monofocal and multifocal group, respectively, reported seeing floaters that was graded as mild by all the patients.

Table 5-7. Questionnaire result before Nd:YAG capsulotomy

	Monofocal (n=24); n (%)				Multifocal (n=9); n (%)			
	No	Mild	Moderate	Severe	No	Mild	Moderate	Severe
Blurred distance vision	1(4.2)	5(20.8)	9(37.5)	9(37.5)	1(11.1)	5(55.6)	2(22.2)	1(11.1)
Blurred near vision*	0	4(16.7)	10(41.7)	10(41.7)	3(33.3)	3(33.3)	2(22.2)	1(11.1)
Disturbed colour vision	24(100)	0	0	0	8(88.9)	1(11.1)	0	0
Glare	13(54.2)	2(8.3)	6(25)	3(12.5)	5(55.6)	2(22.2)	2(22.2)	0
Halos	18(75)	2(8.3)	3(12.5)	1(4.2)	5(55.6)	0	3(33.3)	1(11.1)
Streaks/stars/flare	20(83.3)	2(8.3)	1(4.2)	1(4.2)	9(100)	0	0	0
Double vision	22(91.7)	2(8.3)	0	0	8(88.9)	1(11.1)	0	0
Floaters	21(87.5)	3(12.5)	0	0	9(100)	0	0	0

* $p=0.01$

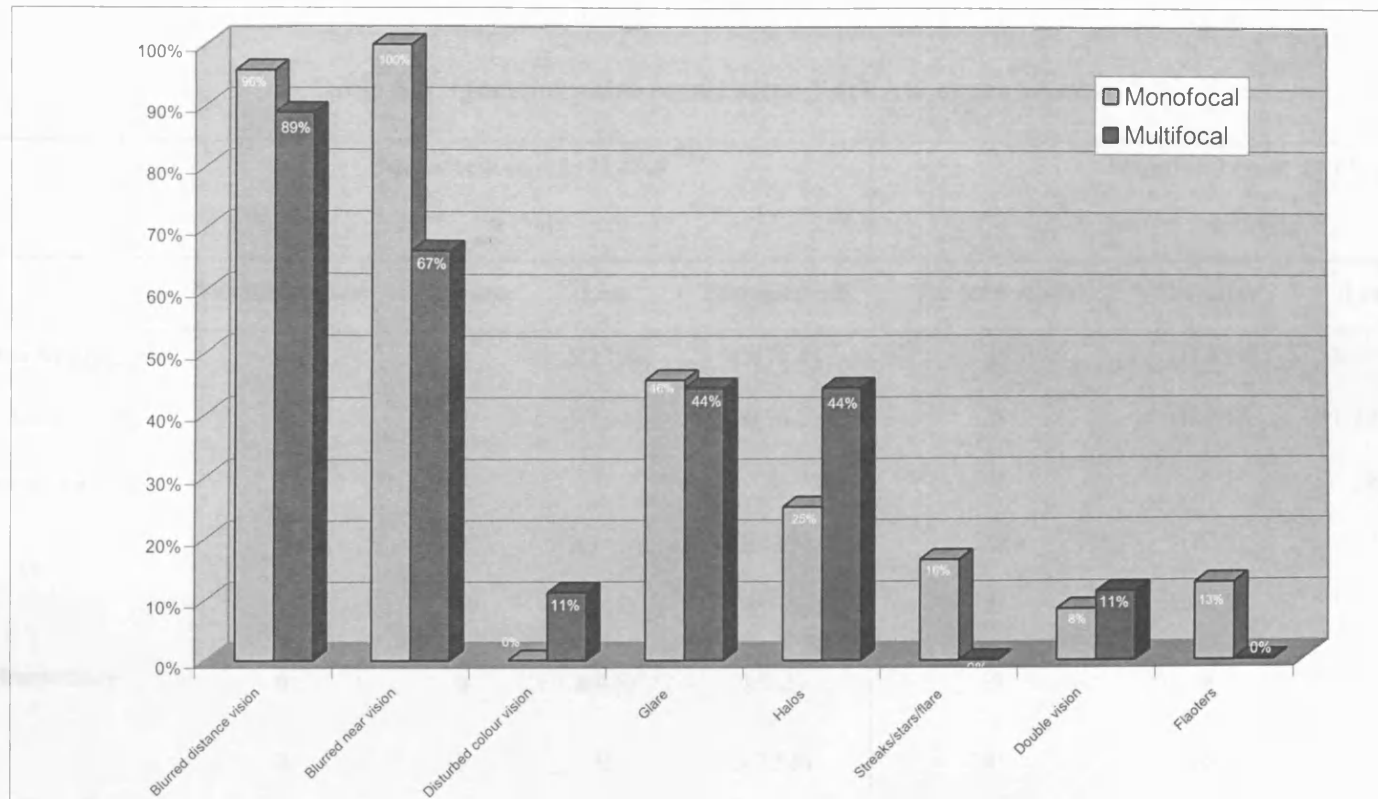


Figure 5-2. Bar chart of the different presenting symptoms of PCO in the monofocal and multifocal IOL patients

Table 5-8. Questionnaire result after Nd:YAG capsulotomy

	Monofocal (n=21; 72.4%)				Multifocal (n=8; 27.6%)			
	n (%)				n (%)			
	Yes (new cases)	The same	Less	Disappeared	Yes (new cases)	The same	Less	Disappeared
Blurring of distance vision	0	0	5(23.8)	15(71.4)	0	1(12.5)	3(37.5)	3(37.5)
Blurring of near vision	0	0	5(23.8)	16(76.2)	0	1(12.5)	1(12.5)	3(37.5)
Disturbance of colour vision	0	0	0	0	0	0	0	1(12.5)
Glare	0	0	3(14.3)	7(33.3)	0	1(12.5)	0	2(25)
Halos	0	0	2(9.5)	4(19)	0	1(12.5)	1(12.5)	1(12.5)
Streaks/stars/sunburst/flare	0	0	2(9.5)	2(9.5)	0	0	0	0
Double vision	0	0	0	5(23.8)	0	0	0	1(12.5)
Floaters	4(19)	3(14.3)	0	0	2(25)	0	0	0

5.2.5 Discussion

Several studies have shown that patients with monofocal and multifocal IOL have comparable visual functions and that the effect of the multifocal lens design on visual function is limited and clinically insignificant (Steinert *et al*, 1999;Vaquero *et al*, 1996;Arens *et al*, 1999;Elgohary & Beckingsale, 2004). In this study, we compared the presenting visual functions between two groups of patients who had either monofocal or multifocal IOLs and presented with PCO and needed Nd:YAG capsulotomy with view to relating that to a possible effect on Nd:YAG capsulotomy rate. We showed that while near BCVA, Pelli-Robson contrast sensitivity and colour confusion index were not significantly different at presentation in the two groups, high- and low-contrast acuity values were significantly greater in the multifocal group. After Nd:YAG capsulotomy, all visual functions were comparable in the two groups.

Hayashi *et al* (Hayashi *et al*, 2003) showed that visual acuity reflects most relevantly the degree of PCO. Other studies of the effect of PCO on contrast sensitivity (Meacock *et al*, 2003;Tan *et al*, 1999) have shown that patients suffer a predominantly global loss over all spatial frequencies and Cheng *et al* (Cheng *et al*, 2001) showed a preferential loss at low- to intermediate spatial frequency (6 cpd). Our finding suggest that logMAR acuity charts, perhaps by displaying a wide range of spatial frequencies (Adams, 1993) (Figure 5.3), are probably more sensitive in detecting PCO-related differences between the two groups than other charts.

There are two explanations for the difference between two groups: either that patients with multifocal IOLs were referred earlier for Nd:YAG capsulotomy or that these patients were less tolerant to PCO-induced functional loss. Against the first proposition is the fact that the two groups had comparable pre-capsulotomy features, including their PCO type (cellular or fibrotic) and grade. In support of the second proposition, is that in our multifocal group, the difference between pre-YAG and post-YAG mean functional loss was 0.33 log units for high contrast acuity, 0.24 log units for Pelli-Robson contrast sensitivity and 0.12 log units for low-contrast acuity. The respective values in the monofocal group were 0.54, 0.48 and 0.88 (Table 5-6). Moreover, the presenting symptoms in the multifocal group were predominantly mild or moderate while in the monofocal group moderate or severe. Also, although

symptoms in the two groups were generally comparable, more patients in the monofocal group had difficulty with reading than those in multifocal group. This, in addition to further confirming the earlier presentation of patients with multifocal IOLs, can be related to the enhancement of near vision performance achieved by the power incorporated within the multifocal IOL design.

Colour confusion index showed the least change of all the visual functions, indicating that colour vision is perhaps more resistant to PCO-induced blur. This is consistent with the evidence suggesting that colour vision is resistant to different forms of blur, including optical blur (Mantjarvi & Tuppurainen, 1995; Degen *et al*, 1983) and that resulting from medial opacities such as cataract (Pinckers, 1980).

After capsulotomy, the majority of patients in the two groups experienced improvement or disappearance of their symptoms after capsulotomy. On the other hand, one patient (12.5%) with multifocal IOL experienced persistent glare or halos. In the other patient there was no explanation for the persistent blurring of vision. A small percentage in each group, (19% & 25%, respectively) developed floaters, but all patient reported that to be mild and not affecting their vision.

5.2.6 Limitations

It was not possible to compare the survival time between the two groups of patients nor between those in the subgroups with different PCO type and grade because of the small sample size and the absence of control groups who did not have PCO or require Nd:YAG capsulotomy. A similarly designed study with a larger sample size and a contemporary control group will enable further assessment of the incidences in patients with different types of PCO.

5.2.7 Conclusion

This study suggests that patients with multifocal IOLs present for Nd:YAG capsulotomy with a lesser magnitude of functional impairment, that mainly affects high- and low-contrast acuity. This perhaps reflects more vision-consciousness or sensitivity to early functional loss and could lead to a higher rate of Nd:YAG capsulotomy in these patients.

REVIEW AND FUTURE DIRECTIONS

The relationship between contrast sensitivity and visual acuity is a key concept in understanding the impact of PCO. Visual acuity is the ability to resolve fine detail, while contrast sensitivity is the ability to detect differences in light and dark levels. PCO can affect both, but its impact on contrast sensitivity is often more significant than on visual acuity.

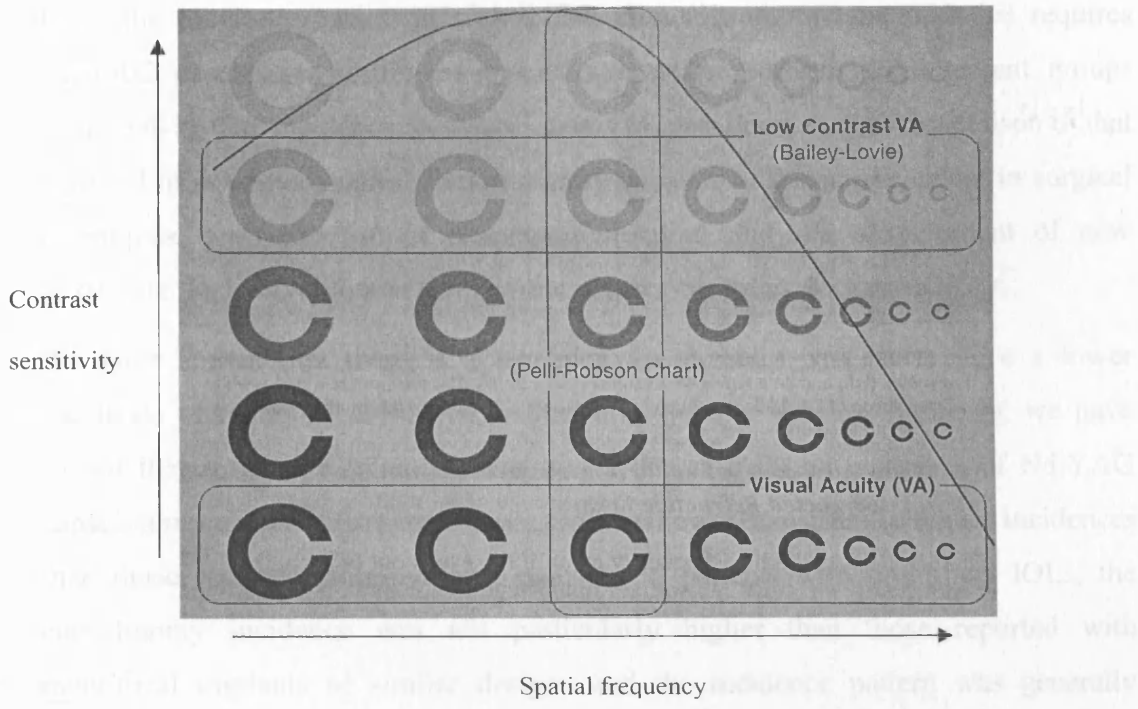


Figure 5-3. The relationship between different letter-based test charts and contrast sensitivity. (Courtesy of T. Adams) (Adams, 1993).

6 SUMMARY AND FUTURE DIRECTIONS

The ever-increasing drive to perfect the outcome of cataract extraction is a lasting motivation for researchers to explore the means by which the incidence of PCO can be reduced or even prevented. The latter, perhaps, would be the next revolutionary step in cataract surgery development.

From the previous studies, it is clear that clinically significant PCO-that requires Nd:YAG capsulotomy-still develops in a large proportion of all patient groups (Figure 6-1). The incidence, however, seems to have decreased in comparison to that reported in previous studies. This is mainly because of the improvement in surgical techniques, with the use of phacoemulsification and the development of new intraocular lenses with better designs and greater capsular biocompatibility.

We have shown that there is a tendency for diabetic patients to have a lower incidence of Nd:YAG capsulotomy than non-diabetic patients. Similarly, we have shown that in uveitic patients, there was a decrease in the incidence of Nd:YAG capsulotomy after the first three years, which showed consistently higher incidences than those reported in non-uveitic patients. In patients with multifocal IOLs, the capsulotomy incidence was not particularly higher than those reported with monofocal implants of similar designs and the incidence pattern was generally similar to the non-diabetic/non-uveitic group of patients (Figure 6-1), with gradual increase in incidence over the 4 postoperative years.

Several factors were found to affect the rate of Nd:YAG capsulotomy and PCO development (Table 6-1). The presence of diabetes mellitus was found to be associated with a lower risk of Nd:YAG capsulotomy over a 4-year postoperative period. Factors associated with increased risk of Nd:YAG capsulotomy included young age, postoperative inflammation, pars plana vitrectomy and polymethylmethacrylate and plate-haptic silicone IOL, as compared to 3-piece silicone IOLs. Also, in diabetic patients, plate-haptic silicone (Chiron C11UB) were associated with a higher PCO rate than hydrophobic acrylic IOLs (AcrySof) within 1 year after surgery. Optical coherence tomography showed that decreased PCO and Nd:YAG capsulotomy rates in patients with hydrophobic acrylic IOLs could be related to the development of a peripheral appositional contact between the IOL optic and the posterior capsule. This is consistent with the previously demonstrated

beneficial effect of the square-edge of these IOL optic, its stronger adherence to the capsule and the 'no-space, no cell, no PCO theory'.

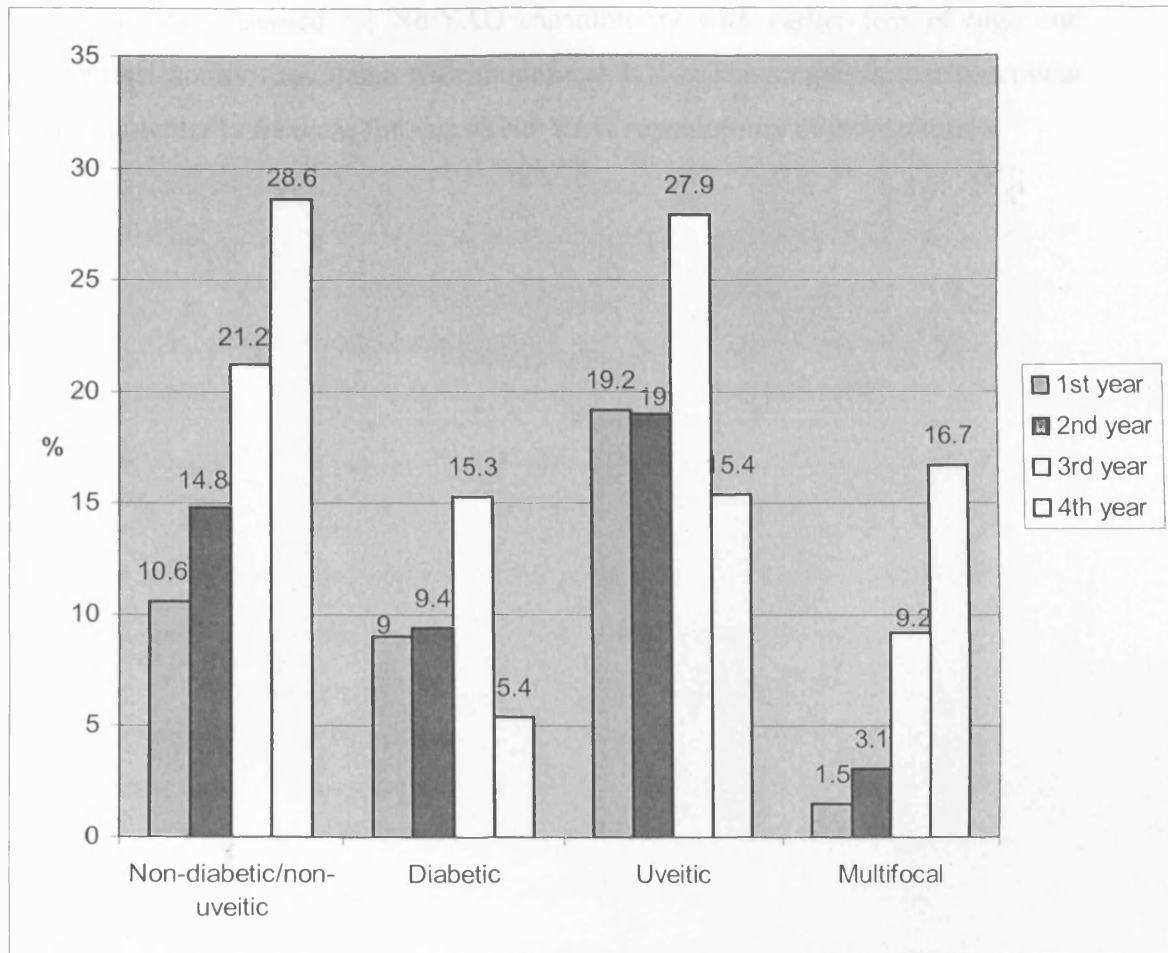


Figure 6-1. Summary of the incidences of Nd:YAG laser capsulotomy in non-diabetic/non-uveitic patients, diabetic and uveitic. The incidences increased gradually over the 4 years (including in those with multifocal IOL). A drop in the incidence occurs after the third year in both diabetic and uveitic patients.

In uveitis patients, in addition to young age, postoperative uveitis and the use of hydrophilic acrylic implants were associated with a higher Nd:YAG capsulotomy rates over the follow-up period. The use of silicone IOLs and prophylactic systemic steroids were associated with a lower risk.

Young age was a risk factor for developing PCO in patients with multifocal IOLs. These patients presented for Nd:YAG capsulotomy with earlier loss of high and low-contrast acuity than those with monofocal IOLs. This suggests that functional loss can potentially increase the rate of Nd:YAG capsulotomy in these patients.

Table 6-1. Risk factors for PCO/Nd:YAG capsulotomy identified in the different studies

	Non-diabetic/Diabetic Studies	Uveitis Study	Multifocal IOL Study
Increased risk	Young age	Young age	Young age
	PH silicone IOL*	Hydrophilic acrylic IOL†	
	PMMA IOL**		
	Postoperative uveitis (within 3 months)	Postoperative uveitis (within 3 months)	
	Pars plana vitrectomy		
Decreased risk	Diabetes mellitus	Prophylactic steroids	
	Hydrophobic acrylic IOL (AcrySof)‡	3-piece silicone IOL†	
		PH silicone IOL†	

PH=plate-haptic, PMMA=polymethylmethacrylate

* Reference IOL was 3-piece silicone IOL & hydrophobic acrylic IOL

** Reference IOL was 3-piece silicone

†Reference IOL was polymethylmethacrylate (PMMA) IOL

‡The rate of PCO formation after 6 months and 1 year was compared to that of PH silicone IOL

From the previous studies, there are clearly still unresolved issues that should be addressed in future studies. Although we found a tendency for diabetic patients to have a lower incidence of Nd:YAG capsulotomy, the bias of the retrospective design have limited our conclusion from that finding. A prospective long-term case-control study of a single-surgeon, using a single-implant will be a pre-requisite to validly establish the relative incidences of this complication in diabetic and non-diabetic patients. Objective photographic assessment as well as functional and subjective assessment of PCO will perhaps be more clinically relevant than using either of them alone in such a study.

The development of postoperative inflammation is one of the modifiable risk factors that was identified in our studies to increase the risk for requiring Nd:YAG capsulotomy in diabetic and uveitic patient groups. Futhermore, in the latter group we found that the use of prophylactic systemic steroids preoperatively was associated with a lower risk for requiring Nd:YAG capsulotomy. Investigations are required of the possible causa-effect relationship between postoperative inflammation and PCO development. Also, the proposed beneficial effect of using peri-operative steroids in patients predisposed to postoperative inflammation or to increased rate of PCO such as those of a relatively young age and those who underwent vitrectomy will need further studies.

The use of the high-resolution OCT should enable us to study the relationship between the posterior capsule and the different IOL optics in vivo. This should help to establish the required enhancement and modification of the IOL designs to lower or prevent the PCO development. Correlating the different capsular features to the clinical and functional features may help to establish OCT as an additional beneficial PCO imaging technique.

Studies involving comparison of contemporary groups of patients with monofocal and multifocal IOLs will determine whether the latter group have a higher rate of Nd:YAG capsulotomy that could be attributed to IOL multifocal design alone and its effect on visual function. The purpose-designed questionnaire that was used in assessing the subjective effect of PCO on visual function of patients with multifocal IOLs will need validation by comparing it to other currently used and more established visual function questionnaires i.e. VF-14 in order to enable its use in future studies of PCO assessment.

7 PUBLICATIONS AND PRESENTATIONS GENERATED FROM THIS THESIS

7.1 PUBLICATIONS

Elgohary MA, Chauhan DS, Dowler JFG. Optical Coherence tomography of the relationship between the posterior capsule and plate-haptic silicone and acrylic IOLs after phacoemulsification. Accepted by *Ophthalmic Research*

Elgohary MA, Hollick EJ, Dowler JFG, Bender L, Heatly C, Wren S, Spalton D: Posterior capsular opacification after plate-haptic silicone and acrylic IOLs in diabetic patients. Accepted by *Journal of Cataract and Refractive Surgery*

Elgohary MA, Dowler JF. Incidence and risk factors of posterior capsular opacification in non-diabetic and diabetic patients. Accepted by *Journal of Clinical and Experimental Ophthalmology*

Elgohary MA, Beckingsale AB. Effect of illumination on visual function in patients with monofocal and multifocal intraocular lenses. Accepted by *Eye*

Elgohary MA, Ahmad N.(2004) Spontaneous late subluxation of polymethylmethacrylate intraocular lens. *Ref. Eye News*, 3, 22.

Elgohary MA, McCluskey PJ, Towler HM, Okhravi N, Singh RP, Obikpo R, Lightman SS. Outcome of phacoemulsification in patients with uveitis. Submitted to *Clinical and Experimental Ophthalmology*

Elgohary MA, Saleh G, Beckingsale AA. Incidence of PCO after multifocal intraocular lens implantation. Submitted to *Ophthalmic Surgery, Laser and Imaging*

Elgohary MA, Beckingsale AB. Effect of posterior capsular opacification on visual function in patients with monofocal and multifocal intraocular lenses. Submitted to *Eye*

7.2 ORAL PRESENTATIONS

Outcome of phacoemulsification in patients with uveitis. European society of Vision and Eye Research (EVER), Sept 2004

Anterior segment changes after cataract extraction in patients with diabetes mellitus. Presented as part of 'Management of Cataract in Diabetes' course', American Academy of Ophthalmology (AAO) Annual Meeting, New Orleans, Oct 2002

7.3 POSTER PRESENTATIONS

Effect of posterior capsular opacification on visual function of patients with monofocal and multifocal intraocular lenses. Elgohary MA, Beckingsale AB. Royal College of Ophthalmologists Annual Congress, Birmingham, May 2005

Incidence of posterior capsular opacification after multifocal IOL implantation. Saleh G, Elgohary MA, Beckingsale AA, European Society of Cataract and Refractive Surgery (ESCRS) Meeting, Munich, Germany, Sept 2003

Comparison of posterior capsular opacification in diabetic eyes with either a silicone plate or acrylic lens. Wren SM, Heatley CJ, Bender L, Elgohary M, Hollick E, Dowler J, Spalton DJ. Royal College of Ophthalmologists Congress, Birmingham, UK, May 2003

Factors influencing posterior capsular opacification in diabetic and non-diabetic patients. Elgohary MA, Dowler JF. Royal college of Ophthalmologists Annual Congress, May 2002

Evaluation of the lens capsule with the optical coherence tomography. Elgohary MA, Chauhan DS, Dowler JF, International Congress of Ophthalmology (ICO) Sydney, Australia, Apr 2002

Effect of diabetes, diabetic retinopathy and surgical technique on the incidence of Posterior capsular opacification. Elgohary MA, Dowler JGF, AMP Hamilton. Association for Research in Vision and Ophthalmology (ARVO) Meeting, May 2001

8 REFERENCES

- Abela-Formanek,C., Amon,M., Schauersberger,J., Kruger,A., Nepp,J., & Schild,G. (2002a) Results of hydrophilic acrylic, hydrophobic acrylic, and silicone intraocular lenses in uveitic eyes with cataract: comparison to a control group. *J Cataract Refract Surg*, **28**, 1141-1152.
- Abela-Formanek,C., Amon,M., Schauersberger,J., Schild,G., Kolodjaschna,J., Barisani-Asenbauer,T., & Kruger,A. (2002b) Uveal and capsular biocompatibility of 2 foldable acrylic intraocular lenses in patients with uveitis or pseudoexfoliation syndrome: comparison to a control group. *J Cataract Refract Surg*, **28**, 1160-1172.
- Abela-Formanek,C., Amon,M., Schild,G., Schauersberger,J., Heinze,G., & Kruger,A. (2002c) Uveal and capsular biocompatibility of hydrophilic acrylic, hydrophobic acrylic, and silicone intraocular lenses. *J.Cataract Refract.Surg.*, **28**, 50-61.
- Abela-Formanek,C., Amon,M., Schild,G., Schauersberger,J., Kolodjaschna,J., Barisani-Asenbaum,T., & Kruger,A. (2002d) Inflammation after implantation of hydrophilic acrylic, hydrophobic acrylic, or silicone intraocular lenses in eyes with cataract and uveitis: comparison to a control group. *J Cataract Refract Surg*, **28**, 1153-1159.
- Abhilakh Missier,K.A., Nuijts,R.M., & Tjia,K.F. (2003) Posterior capsule opacification: silicone plate-haptic versus AcrySof intraocular lenses. *J Cataract Refract.Surg.*, **29**, 1569-1574.
- Adams,A.J. (1993) Impact of new and emerging instrumentation in optometry. *Optom.Vis.Sci.*, **70**, 272-278.

- Agustin,A.L. & Miller,K.M. (2000) Posterior dislocation of a plate-haptic silicone intraocular lens with large fixation holes. *J Cataract Refract.Surg.*, **26**, 1428-1429.
- Aiello,L.P., Avery,R.L., Arrigg,P.G., Keyt,B.A., Jampel,H.D., Shah,S.T., Pasquale,L.R., Thieme,H., Iwamoto,M.A., Park,J.E., & . (1994) Vascular endothelial growth factor in ocular fluid of patients with diabetic retinopathy and other retinal disorders. *N.Engl.J Med.*, **331**, 1480-1487.
- Akerele,T., Minasian,M., Little,B., & Jagger,J. (1999) Posterior dislocation of Staar plate haptic silicone lenses following Nd:YAG capsulotomy. *Eye*, **13 (Pt 5)**, 700-702.
- Alio,J.L., Sayans,J.A., & Chipont,E. (1997) Flare-cell meter measurement of inflammation after uneventful cataract surgery with intraocular lens implantation. *J.Cataract Refract.Surg.*, **23**, 935-939.
- Amon,M. & Menapace,R. (1992) In vivo observation of surface precipitates of 200 consecutive hydrogel intraocular lenses. *Ophthalmologica*, **204**, 13-18.
- Amon,M. & Menapace,R. (1994) In vivo documentation of cellular reactions on lens surfaces. for assessing the biocompatibility of different intraocular implants. *Eye*, **8 (Pt 6)**, 649-656.
- Amon,M., Menapace,R., Radax,U., & Freyler,H. (1996) In vivo study of cell reactions on poly(methyl methacrylate) intraocular lenses with different surface properties. *J.Cataract Refract.Surg.*, **22 Suppl 1**, 825-829.
- Anand,N., Menage,M.J., & Bailey,C. (1997) Phacoemulsification trabeculectomy compared to other methods of combined cataract and glaucoma surgery. *Acta Ophthalmol.Scand.*, **75**, 705-710.
- Ando,H., Ando,N., & Oshika,T. (2003) Cumulative probability of neodymium: YAG laser posterior capsulotomy after phacoemulsification. *J Cataract Refract.Surg.*, **29**, 2148-2154.

- Apple,D.J. (2000) Influence of intraocular lens material and design on postoperative intracapsular cellular reactivity. *Trans.Am.Ophthalmol.Soc.*, **98**, 257-283.
- Apple,D.J., Federman,J.L., Krolicki,T.J., Sims,J.C., Kent,D.G., Hamburger,H.A., Smiddy,W.E., Cox,M.S., Jr., Hassan,T.S., Compton,S.M., & Thomas,S.G. (1996) Irreversible silicone oil adhesion to silicone intraocular lenses. A clinicopathologic analysis. *Ophthalmology*, **103**, 1555-1561.
- Apple,D.J., Isaacs,R.T., Kent,D.G., Martinez,L.M., Kim,S., Thomas,S.G., Basti,S., Barker,D., & Peng,Q. (1997) Silicone oil adhesion to intraocular lenses: an experimental study comparing various biomaterials. *J Cataract Refract.Surg.*, **23**, 536-544.
- Apple,D.J., Peng,Q., Arthur,S.N., Werner,L., Merritt,J.H., Vargas,L.G., Hoddinott,D.S., Escobar-Gomez,M., & Schmidbauer,J.M. (2002) Snowflake degeneration of polymethyl methacrylate posterior chamber intraocular lens optic material: a newly described clinical condition caused by unexpected late opacification of polymethyl methacrylate. *Ophthalmology*, **109**, 1666-1675.
- Apple,D.J., Peng,Q., Visessook,N., Werner,L., Pandey,S.K., Escobar-Gomez,M., Ram,J., & Auffarth,G.U. (2001) Eradication of posterior capsule opacification: documentation of a marked decrease in Nd:YAG laser posterior capsulotomy rates noted in an analysis of 5416 pseudophakic human eyes obtained postmortem. *Ophthalmology*, **108**, 505-518.
- Apple,D.J., Peng,Q., Visessook,N., Werner,L., Pandey,S.K., Escobar-Gomez,M., Ram,J., Whiteside,S.B., Schoderbeck,R., Ready,E.L., & Guindi,A. (2000) Surgical prevention of posterior capsule opacification. Part 1: Progress in eliminating this complication of cataract surgery. *J.Cataract Refract.Surg.*, **26**, 180-187.
- Apple,D.J., Solomon,K.D., Tetz,M.R., Assia,E.I., Holland,E.Y., Legler,U.F., Tsai,J.C., Castaneda,V.E., Hoggatt,J.P., & Kostick,A.M. (1992) Posterior capsule opacification. *Surv Ophthalmol*, **37**, 73-116.

- Arens,B., Freudenthaler,N., & Quentin,C.D. (1999) Binocular function after bilateral implantation of monofocal and refractive multifocal intraocular lenses. *J Cataract Refract Surg*, **25**, 399-404.
- Aron-Rosa,D., Aron,J.J., Griesemann,M., & Thyzel,R. (1980) Use of the neodymium-YAG laser to open the posterior capsule after lens implant surgery: a preliminary report. *J.Am.Intraocul.Implant.Soc.*, **6**, 352-354.
- Arshinoff,S. (1994) Classifying capsulorhexis complications. *J.Cataract Refract.Surg.*, **20**, 475.
- Aslam,T.M., Aspinall,P., & Dhillon,B. (2003a) Posterior capsule morphology determinants of visual function. *Graefes Arch.Clin.Exp.Ophthalmol.*, **241**, 208-212.
- Aslam,T.M., Devlin,H., & Dhillon,B. (2003b) Use of Nd:YAG laser capsulotomy. *Surv.Ophthalmol.*, **48**, 594-612.
- Aslam,T.M. & Dhillon,B. (2002) Neodymium:YAG laser capsulotomy: a clinical morphological analysis. *Graefes Arch.Clin.Exp.Ophthalmol.*, **240**, 972-976.
- Aslam,T.M., Dhillon,B., Werghi,N., Taguri,A., & Wadood,A. (2002) Systems of analysis of posterior capsule opacification. *British Journal of Ophthalmology*, **86**, 1181-1186.
- Aslam,T.M. & Patton,N. (2004) Methods of assessment of patients for Nd:YAG laser capsulotomy that correlate with final visual improvement. *BMC.Ophthalmol.*, **4**, 13.
- Auffarth,G.U., Tetz,M.R., Krastel,H., Blankenagel,A., & Volcker,H.E. (1996) Indications and prognosis of cataract surgery in patients with retinitis pigmentosa. (Abstract). *Ophthalmologe*, **93**, 168-176.
- Avitabile,T. & Marano,F. (2001) Multifocal intra-ocular lenses. *Curr.Opin.Ophthalmol*, **12**, 12-16.

- Aykan,U., Bilge,A.H., Karadayi,K., & Akin,T. (2003) The effect of capsulorhexis size on development of posterior capsule opacification: small (4.5 to 5.0 mm) versus large (6.0 to 7.0 mm). *Eur.J Ophthalmol.*, **13**, 541-545.
- Azar,D.t. & Rumelt,S. (2000) Phacoemulsification. Principles and Practice of Ophthalmology (ed. by D. M. Albert & F. A. Jacobiec) W.B. Saunders Company, Philadelphia.
- Azuma,N., Hara,T., & Hara,T. (1998) Extracellular matrix of opacified anterior capsule after endocapsular cataract surgery. *Graefes Arch.Clin.Exp.Ophthalmol.*, **236**, 531-536.
- Badr,I.A., Hussain,H.M., Jabak,M., & Wagoner,M.D. (1995) Extracapsular cataract extraction with or without posterior chamber intraocular lenses in eyes with cataract and high myopia. *Ophthalmology*, **102**, 1139-1143.
- Balaram,M., Tung,W.H., Kuszak,J.R., Ayaki,M., Shinohara,T., & Chylack,L.T., Jr. (2000) Noncontact specular microscopy of human lens epithelium. *Invest Ophthalmol.Vis.Sci.*, **41**, 474-481.
- Baratz,K.H., Cook,B.E., & Hodge,D.O. (2001) Probability of Nd:YAG laser capsulotomy after cataract surgery in Olmsted County, Minnesota. *Am.J.Ophthalmol.*, **131**, 161-166.
- Barman,S.A., Hollick,E.J., Boyce,J.F., Spalton,D.J., Uyyanonvara,B., Sanguinetti,G., & Meacock,W. (2000) Quantification of posterior capsular opacification in digital images after cataract surgery. *Invest Ophthalmol.Vis.Sci.*, **41**, 3882-3892.
- Beltrame,G., Salvetat,M.L., Chizzolini,M., Driussi,G.B., Busatto,P., Di Giorgio,G., & Barosco,F. (2002) Posterior capsule opacification and Nd:YAG capsulotomy rates after implantation of silicone, hydrogel and soft acrylic intraocular lenses: a two-year follow-up study. *Eur.J Ophthalmol*, **12**, 388-394.

- Berker,N., Soykan,E., Elgin,U., & Ozkan,S.S. (2004) Phacoemulsification cataract extraction and intraocular lens implantation in patients with Behcet's disease. *Ophthalmic Surg.Lasers Imaging*, **35**, 215-218.
- Birinci,H., Kuruoglu,S., Oge,I., Oge,F., & Acar,E. (1999) Effect of intraocular lens and anterior capsule opening type on posterior capsule opacification. *J.Cataract Refract.Surg.*, **25**, 1140-1146.
- Birk,D., Cochen,R., & Geiger,B. (1994) Cell junctions, cell adhesion, and extracellular matrix. *Molecular biology of the cell* (ed. by ALBERTS B, BRAG D, LEWIS J, & et al), pp. 969-970. Garland Publishing, New York.
- Borgioli,M., Coster,D.J., Fan,R.F., Henderson,J., Jacobi,K.W., Kirkby,G.R., Lai,Y.K., Menezo,J.L., Montard,M., Strobel,J., & . (1992) Effect of heparin surface modification of polymethylmethacrylate intraocular lenses on signs of postoperative inflammation after extracapsular cataract extraction. One-year results of a double-masked multicenter study. *Ophthalmology*, **99**, 1248-1254.
- Born,C.P. & Ryan,D.K. (1990) Effect of intraocular lens optic design on posterior capsular opacification. *J.Cataract Refract.Surg.*, **16**, 188-192.
- Bowman,K.J. (1982) A method for quantitative scoring of the Farnsworth Panel D-15. *Acta Ophthalmol.(Copenh)*, **60**, 907-916.
- Boyce,J.F., Bhermi,G.S., Spalton,D.J., & El Osta,A.R. (2002) Mathematical modeling of the forces between an intraocular lens and the capsule. *J Cataract Refract.Surg.*, **28**, 1853-1859.
- Brown,D.C., Grabow,H.B., Martin,R.G., Rowen,S.L., Shepherd,J.R., Williamson,C.H., & Ziemba,S.L. (1998) Staar Collamer intraocular lens: clinical results from the phase I FDA core study. *J Cataract Refract Surg*, **24**, 1032-1038.

- Brydon, K.W., Tokarewicz, A.C., & Nichols, B.D. (2000) AMO array multifocal lens versus monofocal correction in cataract surgery. *J Cataract Refract Surg*, **26**, 96-100.
- Carlson, A.N. & Koch, D.D. (1988) Endophthalmitis following Nd:YAG laser posterior capsulotomy. *Ophthalmic Surg.*, **19**, 168-170.
- Chambless, W.S. (1985) Neodymium:YAG laser posterior capsulotomy results and complications. *J.Am.Intraocul.Implant.Soc.*, **11**, 31-32.
- Chang, M.A., Parides, M.K., Chang, S., & Braunstein, R.E. (2002) Outcome of phacoemulsification after pars plana vitrectomy. *Ophthalmology*, **109**, 948-954.
- Channell, M.M. & Beckman, H. (1984) Intraocular pressure changes after neodymium-YAG laser posterior capsulotomy. *Arch.Ophthalmol.*, **102**, 1024-1026.
- Chauhan DS, Hollick EJ, El-Osta AR, Spalton DJ, & Marshal J. OCT of PCO. 28-12-2000. *Personal Communication*
- Chauhan, D.S., Antcliff, R.J., Rai, P.A., Williamson, T.H., & Marshall, J. (2000) Papillofoveal traction in macular hole formation: the role of optical coherence tomography. *Arch.Ophthalmol.*, **118**, 32-38.
- Chauhan, D.S. & Marshall, J. (1999) The interpretation of optical coherence tomography images of the retina. *Invest Ophthalmol. Vis.Sci.*, **40**, 2332-2342.
- Chawla, J.S. & Shaikh, M.H. (1999) Neodymium: YAG laser parabolic anterior capsulotomy in extreme capsule contraction syndrome. *J.Cataract Refract.Surg.*, **25**, 1415-1417.
- Chee, S.P., Ti, S.E., Sivakumar, M., & Tan, D.T. (1999) Postoperative inflammation: extracapsular cataract extraction versus phacoemulsification. *J.Cataract Refract.Surg.*, **25**, 1280-1285.

- Chen,Z., John,M., Subramanian,S., Chen,H., & Carper,D. (2004) 17Beta-estradiol confers a protective effect against transforming growth factor-beta2-induced cataracts in female but not male lenses. *Exp.Eye Res.*, **78**, 67-74.
- Cheng,C.Y., Yen,M.Y., Chen,S.J., Kao,S.C., Hsu,W.M., & Liu,J.H. (2001) Visual acuity and contrast sensitivity in different types of posterior capsule opacification. *J.Cataract Refract.Surg.*, **27**, 1055-1060.
- Christiansen,G., Durcan,F.J., Olson,R.J., & Christiansen,K. (2001) Glistenings in the AcrySof intraocular lens: pilot study. *J Cataract Refract Surg*, **27**, 728-733.
- Chung,H.S., Lim,S.J., & Kim,H.B. (2000) Effect of mitomycin-C on posterior capsule opacification in rabbit eyes. *J.Cataract Refract.Surg.*, **26**, 1537-1542.
- Clark,D.S., Emery,J.M., & Munsell,M.F. (1998) Inhibition of posterior capsule opacification with an immunotoxin specific for lens epithelial cells: 24 month clinical results. *J.Cataract Refract.Surg.*, **24**, 1614-1620.
- Clayman,H.M. & Jaffe,N.S. (1988) Spontaneous enlargement of neodymium:YAG posterior capsulotomy in aphakic and pseudophakic patients. *J.Cataract Refract.Surg.*, **14**, 667-669.
- Cochener,B., Jacq,P.L., & Colin,J. (1999) Capsule contraction after continuous curvilinear capsulorhexis: poly(methyl methacrylate) versus silicone intraocular lenses. *J Cataract Refract.Surg.*, **25**, 1362-1369.
- Coombes,A.G., Sheard,R., Gartry,D.S., & Allan,B.D. (2001) Silicone plate-haptic lens injection without prior incision enlargement. *J Cataract Refract.Surg.*, **27**, 1542-1544.
- Cortina,P., Gomez-Lechon,M.J., Navea,A., Menezo,J.L., Terencio,M.C., & Diaz-Llopis,M. (1997) Diclofenac sodium and cyclosporin A inhibit human lens epithelial cell proliferation in culture. *Graefes Arch.Clin.Exp.Ophthalmol*, **235**, 180-185.

- Cumming, J.S. (1993) Postoperative complications and uncorrected acuities after implantation of plate haptic silicone and three-piece silicone intraocular lenses. *J. Cataract Refract. Surg.*, **19**, 263-274.
- Cunanan, C.M., Ghazizadeh, M., Buchen, S.Y., & Knight, P.M. (1998) Contact-angle analysis of intraocular lenses. *J. Cataract Refract. Surg.*, **24**, 341-351.
- Dahlhauser, K.F., Wroblewski, K.J., & Mader, T.H. (1998) Anterior capsule contraction with foldable silicone intraocular lenses. *J. Cataract Refract. Surg.*, **24**, 1216-1219.
- Dana, M.R., Chatzistefanou, K., Schaumberg, D.A., & Foster, C.S. (1997) Posterior capsule opacification after cataract surgery in patients with uveitis. *Ophthalmology*, **104**, 1387-1393.
- Dardenne, M.U., Gerten, G.J., Kokkas, K., & Kermani, O. (1989) Retrospective study of retinal detachment following neodymium:YAG laser posterior capsulotomy. *J. Cataract Refract. Surg.*, **15**, 676-680.
- Davidson, M.G., Wormstone, M., Morgan, D., Malakof, R., Allen, J., & McGahan, M.C. (2000) Ex vivo canine lens capsular sac explants. *Graefes Arch. Clin. Exp. Ophthalmol.*, **238**, 708-714.
- Davison, J.A. (1993) Capsule contraction syndrome. *J. Cataract Refract. Surg.*, **19**, 582-589.
- Davison, J.A. (2000) Positive and negative dysphotopsia in patients with acrylic intraocular lenses. *J. Cataract Refract Surg*, **26**, 1346-1355.
- Davison, J.A. (2001) Overview of intraocular lenses. *Cataract Surgery and Intraocular Lenses: A 21st-century Perspective* (ed. by J. G. Ford & C. L. Karp), pp. 94-119. American Academy of Ophthalmology, San Francisco.

- Daynes,T., Spencer,T.S., Doan,K., Mamalis,N., & Olson,R.J. (2002) Three-year clinical comparison of 3-piece AcrySof and SI-40 silicone intraocular lenses. *J Cataract Refract Surg*, **28**, 1124-1129.
- de Boer,J.H., Limpens,J., Orengo-Nania,S., de Jong,P.T., La Heij,E., & Kijlstra,A. (1994) Low mature TGF-beta 2 levels in aqueous humor during uveitis. *Invest Ophthalmol. Vis.Sci.*, **35**, 3702-3710.
- Degen,R.L., Mullane,S.D., & Richards,O.W. (1983) Variation of the green-red ratio with refractive error. *Am.J.Optom.Physiol Opt.*, **60**, 151-152.
- Desai,P., Minassian,D.C., & Reidy,A. (1999) National cataract surgery survey 1997-8: a report of the results of the clinical outcomes. *Br.J.Ophthalmol.*, **83**, 1336-1340.
- Dick,B., Schwenn,O., Stoffelns,B., & Pfeiffer,N. (1998) Late dislocation of a plate haptic silicone lens into the vitreous body after Nd:YAG capsulotomy. A case report. (Abstract). *Ophthalmologe*, **95**, 181-185.
- Dick,B., Stoffelns,B., Pavlovic,S., Schwenn,O., & Pfeiffer,N. (1997) Interaction of silicone oil with various intraocular lenses. A light and scanning electron microscopy study. (Abstract). *Klin.Monatsbl.Augenheilkd.*, **211**, 192-206.
- Dick,H.B., Frohn,A., Augustin,A.J., Wolters,B., Pakula,T., & Pfeiffer,N. (2001) Physicochemical surface properties of various intraocular lenses. *Ophthalmic Res.*, **33**, 303-309.
- Dick,H.B., Schwenn,O., Krummenauer,F., Krist,R., & Pfeiffer,N. (2000) Inflammation after sclerocorneal versus clear corneal tunnel phacoemulsification. *Ophthalmology*, **107**, 241-247.
- Doan,K.T., Olson,R.J., & Mamalis,N. (2002) Survey of intraocular lens material and design. *Curr.Opin.Ophthalmol.*, **13**, 24-29.

- Dorey, M.W., Brownstein, S., Hill, V.E., Mathew, B., Botton, G., Kertes, P.J., & El Defrawy, S. (2003) Proposed pathogenesis for the delayed postoperative opacification of the hydroview hydrogel intraocular lens. *Am.J.Ophthalmol.*, **135**, 591-598.
- Dowler, J. & Hykin, P.G. (2001) Cataract surgery in diabetes. *Curr.Opin.Ophthalmol*, **12**, 175-178.
- Dowler, J.G., Sehmi, K.S., Hykin, P.G., & Hamilton, A.M. (1999) The natural history of macular edema after cataract surgery in diabetes. *Ophthalmology*, **106**, 663-668.
- Downing, J.E. (1986) Long-term discission rate after placing posterior chamber lenses with the convex surface posterior. *J.Cataract Refract.Surg.*, **12**, 651-654.
- Downing, J.E. & Alberhasky, M.T. (1990) Biconvex intraocular lenses and Nd:YAG capsulotomy: experimental comparison of surface damage with different poly(methyl methacrylate) formulations. *J.Cataract Refract.Surg.*, **16**, 732-736.
- el Maghraby, A., Anwar, M., el Sayyad, F., Matheen, M., Marzouky, A., Gazayerli, E., Salah, T., & Ballew, C. (1993) Effect of incision size on early postoperative visual rehabilitation after cataract surgery and intraocular lens implantation. *J.Cataract Refract.Surg.*, **19**, 494-498.
- Elgohary, M.A. & Beckingsale, A.B. (2004) Effect of illumination on visual function of multifocal and monofocal IOLs. *Eye*, in press.
- Elgohary, M.A., Werner, L., Zaheer, A., Sheldrick, J., & Ahmad, N. (2005) Opacification of SA40N silicone multifocal intraocular lens. *J. Cataract Refract. Surg.*, in press.
- Erie, J.C., Bandhauer, M.H., & McLaren, J.W. (2001) Analysis of postoperative glare and intraocular lens design. *J Cataract Refract.Surg.*, **27**, 614-621.

- Erie, J.C., Hardwig, P.W., & Hodge, D.O. (1998) Effect of intraocular lens design on neodymium:YAG laser capsulotomy rates. *J. Cataract Refract. Surg.*, **24**, 1239-1242.
- Estafanous, M.F., Lowder, C.Y., Meisler, D.M., & Chauhan, R. (2001) Phacoemulsification cataract extraction and posterior chamber lens implantation in patients with uveitis. *Am. J. Ophthalmol.*, **131**, 620-625.
- Fagerholm, P., Bjorklund, H., Holmberg, A., Larsson, R., Lydahl, E., Philipson, B., & Selen, G. (1989) Heparin surface modified intraocular lenses implanted in the monkey eye. *J. Cataract Refract. Surg.*, **15**, 485-490.
- Fagerholm, P.P. (1982) The response of the lens to trauma. *Trans. Ophthalmol. Soc. U.K.*, **102 Pt 3**, 369-374.
- Fallor, M.K. & Hoft, R.H. (1985) Intraocular lens damage associated with posterior capsulotomy: a comparison of intraocular lens designs and four different Nd:YAG laser instruments. *J. Am. Intraocul. Implant. Soc.*, **11**, 564-567.
- Fankhauser, F., Roussel, P., Steffen, J., van der, Z.E., & Chrenkova, A. (1981) Clinical studies on the efficiency of high power laser radiation upon some structures of the anterior segment of the eye. First experiences of the treatment of some pathological conditions of the anterior segment of the human eye by means of a Q-switched laser system. *Int. Ophthalmol.*, **3**, 129-139.
- Farbowitz, M.A., Zabriskie, N.A., Crandall, A.S., Olson, R.J., & Miller, K.M. (2000) Visual complaints associated with the AcrySof acrylic intraocular lens(1). *J. Cataract Refract. Surg.*, **26**, 1339-1345.
- Faucher, A. & Rootman, D.S. (2001) Dislocation of a plate-haptic silicone intraocular lens into the anterior chamber. *J. Cataract Refract. Surg.*, **27**, 169-171.
- Featherstone, K.A., Bloomfield, J.R., Lang, A.J., Miller-Meeks, M.J., Woodworth, G., & Steinert, R.F. (1999) Driving simulation study: bilateral array multifocal

- versus bilateral AMO monofocal intraocular lenses. *J Cataract Refract Surg*, **25**, 1254-1262.
- Fernando,G.T. & Crayford,B.B. (2000) Visually significant calcification of hydrogel intraocular lenses necessitating explantation. *Clin.Experiment.Ophthalmol.*, **28**, 280-286.
- Findl,O., Drexler,W., Menapace,R., Georgopoulos,M., Rainer,G., Hitzemberger,C.K., & Fercher,A.F. (1999) Changes in intraocular lens position after neodymium: YAG capsulotomy. *J Cataract Refract.Surg.*, **25**, 659-662.
- Findl,O., Neumayer T., Buehl W., & Sacu S. (2004) Short-term changes in the morphology of posterior capsule opacification. (Abstract). *Book of Abstracts: XXII Congress of the ESCRS*, 29.
- Fine,I.H. & Hoffman,R.S. (2000) The AMO array foldable silicone multifocal intraocular lens. *Int.Ophthalmol Clin.*, **40**, 245-252.
- Flohr,M.J., Robin,A.L., & Kelley,J.S. (1985) Early complications following Q-switched neodymium: YAG laser posterior capsulotomy. *Ophthalmology*, **92**, 360-363.
- Font,R.L. & Brownstein,S. (1974) A light and electron microscopic study of anterior subcapsular cataracts. *Am.J.Ophthalmol.*, **78**, 972-984.
- Fourman,S. & Apisson,J. (1991) Late-onset elevation in intraocular pressure after neodymium-YAG laser posterior capsulotomy. *Arch.Ophthalmol.*, **109**, 511-513.
- Framme,C., Hoerauf,H., Roider,J., & Laqua,H. (1998) Delayed intraocular lens dislocation after neodymium:YAG capsulotomy. *J.Cataract Refract.Surg.*, **24**, 1541-1543.

- Friedman,D.S., Duncan,D.D., Munoz,B., West,S.K., & Schein,O.D. (1999) Digital image capture and automated analysis of posterior capsular opacification. *Invest Ophthalmol. Vis.Sci.*, **40**, 1715-1726.
- Fujimoto,J.G., Hee,M.R., Huang,D., Schuman,J.S., Puliafito,C., & Swanson,E. (2004) Principles of optical coherence tomography. *Optical Coherence Tomography of Ocular Diseases* (ed. by J. S. Schuman, C. Puliafito, & J. G. Fujimoto), pp. 3-19. Slack Incorporated, Thorofare.
- Gallagher,S.P. & Pavilack,M.A. (1999) Risk factors for anterior capsule contraction syndrome with polypropylene or poly(methyl methacrylate) haptics. *J Cataract Refract.Surg.*, **25**, 1356-1361.
- Gardner,K.M., Straatsma,B.R., & Pettit,T.H. (1985) Neodymium: YAG laser posterior capsulotomy: the first 100 cases at UCLA. *Ophthalmic Surg.*, **16**, 24-28.
- Ge,J., Wand,M., Chiang,R., Paranhos,A., & Shields,M.B. (2000) Long-term effect of Nd:YAG laser posterior capsulotomy on intraocular pressure. *Arch.Ophthalmol.*, **118**, 1334-1337.
- Georgopoulos,M., Findl,O., Menapace,R., Buehl,W., Wirtitsch,M., & Rainer,G. (2003) Influence of intraocular lens material on regenerative posterior capsule opacification after neodymium:YAG laser capsulotomy. *J Cataract Refract.Surg.*, **29**, 1560-1565.
- Gimbel,H.V. (1996) Posterior capsulorhexis with optic capture in pediatric cataract and intraocular lens surgery. *Ophthalmology*, **103**, 1871-1875.
- Gimbel,H.V., Sanders,D.R., & Raanan,M.G. (1991) Visual and refractive results of multifocal intraocular lenses. *Ophthalmology*, **98**, 881-887.
- Green,W.R. & McDonnell,P.J. (1985) Opacification of the posterior capsule. *Trans.Ophthalmol.Soc.U.K.*, **104 (Pt 7)**, 727-739.

- Grewing,R. & Becker,H. (2000) Retinal thickness immediately after cataract surgery measured by optical coherence tomography. *Ophthalmic Surg Lasers*, **31**, 215-217.
- Grusha,Y.O., Masket,S., & Miller,K.M. (1998) Phacoemulsification and lens implantation after pars plana vitrectomy. *Ophthalmology*, **105**, 287-294.
- Gunenc,U., Oner,F.H., Tongal,S., & Ferliel,M. (2001) Effects on visual function of glistening and folding marks in AcrySof intraocular lenses. *J Cataract Refract Surg*, **27**, 1611-1614.
- Hales,A.M., Chamberlain,C.G., Murphy,C.R., & McAvoy,J.W. (1997) Estrogen protects lenses against cataract induced by transforming growth factor-beta (TGFbeta). *J Exp.Med.*, **185**, 273-280.
- Hansen,S.O., Crandall,A.S., & Olson,R.J. (1993) Progressive constriction of the anterior capsular opening following intact capsulorhexis. *J.Cataract Refract.Surg.*, **19**, 77-82.
- Hara,T., Hara,T., Sakanishi,K., & Yamada,Y. (1995) Efficacy of equator rings in an experimental rabbit study. *Arch.Ophthalmol.*, **113**, 1060-1065.
- Harding,J.J., Egerton,M., van Heyningen,R., & Harding,R.S. (1993) Diabetes, glaucoma, sex, and cataract: analysis of combined data from two case control studies. *Br.J Ophthalmol.*, **77**, 2-6.
- Haring,G., Dick,H.B., Krummenauer,F., Weissmantel,U., & Kroncke,W. (2001) Subjective photic phenomena with refractive multifocal and monofocal intraocular lenses. results of a multicenter questionnaire. *J Cataract Refract Surg*, **27**, 245-249.
- Hashizoe,M., Hara,T., Ogura,Y., Sakanishi,K., Honda,T., & Hara,T. (1998) Equator ring efficacy in maintaining capsular bag integrity and transparency after cataract removal in monkey eyes. *Graefes Arch.Clin.Exp.Ophthalmol.*, **236**, 375-379.

- Hauser,D., Katz,H., Pokroy,R., Bukelman,A., Shechtman,E., & Pollack,A. (2004) Occurrence and progression of diabetic retinopathy after phacoemulsification cataract surgery. *J Cataract Refract.Surg.*, **30**, 428-432.
- Hayashi,H., Hayashi,K., Nakao,F., & Hayashi,F. (1998a) Anterior capsule contraction and intraocular lens dislocation in eyes with pseudoexfoliation syndrome. *Br.J.Ophthalmol.*, **82**, 1429-1432.
- Hayashi,H., Hayashi,K., Nakao,F., & Hayashi,F. (1998b) Area reduction in the anterior capsule opening in eyes of diabetes mellitus patients. *J.Cataract Refract.Surg.*, **24**, 1105-1110.
- Hayashi,H., Hayashi,K., Nakao,F., & Hayashi,F. (1998c) Quantitative comparison of posterior capsule opacification after polymethylmethacrylate, silicone, and soft acrylic intraocular lens implantation. *Arch.Ophthalmol.*, **116**, 1579-1582.
- Hayashi,K. & Hayashi,H. (2004) Posterior capsule opacification after implantation of a hydrogel intraocular lens. *Br.J Ophthalmol.*, **88**, 182-185.
- Hayashi,K., Hayashi,H., Nakao,F., & Hayashi,F. (1997) Reduction in the area of the anterior capsule opening after polymethylmethacrylate, silicone, and soft acrylic intraocular lens implantation. *Am.J Ophthalmol.*, **123**, 441-447.
- Hayashi,K., Hayashi,H., Nakao,F., & Hayashi,F. (1998d) In vivo quantitative measurement of posterior capsule opacification after extracapsular cataract surgery. *Am.J.Ophthalmol.*, **125**, 837-843.
- Hayashi,K., Hayashi,H., Nakao,F., & Hayashi,F. (1998e) Reproducibility of posterior capsule opacification measurement using Scheimpflug videophotography. *J.Cataract Refract.Surg.*, **24**, 1632-1635.
- Hayashi,K., Hayashi,H., Nakao,F., & Hayashi,F. (2000) Influence of astigmatism on multifocal and monofocal intraocular lenses. *Am.J Ophthalmol*, **130**, 477-482.

- Hayashi,K., Hayashi,H., Nakao,F., & Hayashi,F. (2001) Correlation between pupillary size and intraocular lens decentration and visual acuity of a zonal-progressive multifocal lens and a monofocal lens. *Ophthalmology*, **108**, 2011-2017.
- Hayashi,K., Hayashi,H., Nakao,F., & Hayashi,F. (2002) Posterior capsule opacification after cataract surgery in patients with diabetes mellitus. *Am.J Ophthalmol.*, **134**, 10-16.
- Hayashi,K., Hayashi,H., Nakao,F., & Hayashi,F. (2003) Correlation between posterior capsule opacification and visual function before and after Neodymium: YAG laser posterior capsulotomy. *Am.J Ophthalmol*, **136**, 720-726.
- Hayashi,Y., Kato,S., Fukushima,H., Numaga,J., Kaiya,T., Tamaki,Y., & Oshika,T. (2004) Relationship between anterior capsule contraction and posterior capsule opacification after cataract surgery in patients with diabetes mellitus. *J.Cataract Refract.Surg.*, **30**, 1517-1520.
- Helbig,H., Kellner,U., Bornfeld,N., & Foerster,M.H. (1996) Cataract surgery and YAG-laser capsulotomy following vitrectomy for diabetic retinopathy. *Ger J.Ophthalmol.*, **5**, 408-414.
- Henry,J.J. & Grainger,R.M. (1990) Early tissue interactions leading to embryonic lens formation in *Xenopus laevis*. *Dev.Biol.*, **141**, 149-163.
- Hilgert,C.R., Hilgert,A., Hofling-Lima,A.L., Farah,M.E., & Werner,L. (2004) Early opacification of SI-40NB silicone intraocular lenses. *J.Cataract Refract.Surg.*, **30**, 2225-2229.
- Hirano,K., Ito,Y., Suzuki,T., Kojima,T., Kachi,S., & Miyake,Y. (2001) Optical coherence tomography for the noninvasive evaluation of the cornea. *Cornea*, **20**, 281-289.

- Hoerauf,H., Wirbelauer,C., Scholz,C., Engelhardt,R., Koch,P., Laqua,H., & Birngruber,R. (2000) Slit-lamp-adapted optical coherence tomography of the anterior segment. *Graefes Arch.Clin.Exp.Ophthalmol*, **238**, 8-18.
- Hollander,D.A., Stewart,J.M., Seiff,S.R., Poothullil,A.M., & Jeng,B.H. (2004) Late-onset Corynebacterium endophthalmitis following laser posterior capsulotomy. *Ophthalmic Surg.Lasers Imaging*, **35**, 159-161.
- Hollick,E.J., Spalton,D.J., & Meacock,W.R. (1999a) The effect of capsulorhexis size on posterior capsular opacification: one-year results of a randomized prospective trial. *Am.J.Ophthalmol.*, **128**, 271-279.
- Hollick,E.J., Spalton,D.J., & Ursell,P.G. (1999b) Surface cytologic features on intraocular lenses: can increased biocompatibility have disadvantages? *Arch.Ophthalmol.*, **117**, 872-878.
- Hollick,E.J., Spalton,D.J., Ursell,P.G., Meacock,W.R., Barman,S.A., & Boyce,J.F. (2000) Posterior capsular opacification with hydrogel, polymethylmethacrylate, and silicone intraocular lenses: two-year results of a randomized prospective trial. *Am.J Ophthalmol*, **129**, 577-584.
- Hollick,E.J., Spalton,D.J., Ursell,P.G., & Pande,M.V. (1998) Lens epithelial cell regression on the posterior capsule with different intraocular lens materials. *Br.J.Ophthalmol.*, **82**, 1182-1188.
- Hollick,E.J., Spalton,D.J., Ursell,P.G., Pande,M.V., Barman,S.A., Boyce,J.F., & Tilling,K. (1999c) The effect of polymethylmethacrylate, silicone, and polyacrylic intraocular lenses on posterior capsular opacification 3 years after cataract surgery. *Ophthalmology*, **106**, 49-54.
- Hothersall,J.S., Taylaur,C.E., & McLean,P. (1988) Antioxidant status in an in vitro model for hyperglycemic lens cataract formation: effect of aldose reductase inhibitor statil. *Biochem.Med.Metab Biol.*, **40**, 109-117.

- Hu,C.Y., Woung,L.C., & Wang,M.C. (2001) Change in the area of laser posterior capsulotomy: 3 month follow-up. *J.Cataract Refract.Surg.*, **27**, 537-542.
- Hu,C.Y., Woung,L.C., Wang,M.C., & Jian,J.H. (2000) Influence of laser posterior capsulotomy on anterior chamber depth, refraction, and intraocular pressure. *J Cataract Refract.Surg.*, **26**, 1183-1189.
- Huang,D., Swanson,E.A., Lin,C.P., Schuman,J.S., Stinson,W.G., Chang,W., Hee,M.R., Flotte,T., Gregory,K., Puliafito,C.A., & . (1991) Optical coherence tomography. *Science*, **254**, 1178-1181.
- Hwang,I.P., Clinch,T.E., Moshifar,M., Malmquist,L., Cason,M., & Crandall,A.S. (1998) Decentration of 3-piece versus plate-haptic silicone intraocular lenses. *J Cataract Refract.Surg.*, **24**, 1505-1508.
- Ibaraki,N., Ohara,K., & Miyamoto,T. (1995) Membranous outgrowth suggesting lens epithelial cell proliferation in pseudophakic eyes. *Am.J.Ophthalmol.*, **119**, 706-711.
- Ingram,R.M., Banerjee,D., Traynar,M.J., & Thompson,R.K. (1980) Day-case cataract surgery. *Trans.Ophthalmol.Soc.U.K.*, **100**, 205-209.
- Ionides,A., Dowler,J.G., Hykin,P.G., Rosen,P.H., & Hamilton,A.M. (1994) Posterior capsule opacification following diabetic extracapsular cataract extraction. *Eye*, **8 (Pt 5)**, 535-537.
- Ishibashi,T., Araki,H., Sugai,S., Tawara,A., Ohnishi,Y., & Inomata,H. (1993) Anterior capsule opacification in monkey eyes with posterior chamber intraocular lenses. *Arch.Ophthalmol.*, **111**, 1685-1690.
- Ishibashi,T., Hatae,T., & Inomata,H. (1994) Collagen types in human posterior capsule opacification. *J.Cataract Refract.Surg.*, **20**, 643-646.
- Ismail,M.M., Alio,J.L., & Ruiz Moreno,J.M. (1996) Prevention of secondary cataract by antimetabolic drugs: experimental study. *Ophthalmic Res.*, **28**, 64-69.

- Jackson,H., Garway-Heath,D., Rosen,P., Bird,A.C., & Tuft,S.J. (2001) Outcome of cataract surgery in patients with retinitis pigmentosa. *Br.J.Ophthalmol.*, **85**, 936-938.
- Jacob,T.J., Humphry,R.C., Davies,E.G., & Thompson,G.M. (1988) Human retinal extract stimulates the proliferation of human lens epithelial cells. *Eye*, **2 (Pt 3)**, 304-308.
- Jahn,C.E., Richter,J., Jahn,A.H., Kremer,G., & Kron,M. (2003) Pseudophakic retinal detachment after uneventful phacoemulsification and subsequent neodymium: YAG capsulotomy for capsule opacification. *J Cataract Refract.Surg.*, **29**, 925-929.
- Jamal,S.A. & Solomon,L.D. (1993) Risk factors for posterior capsular pearly after uncomplicated extracapsular cataract extraction and plano-convex posterior chamber lens implantation. *J.Cataract Refract.Surg.*, **19**, 333-338.
- Javitt,J., Brauweiler,H.P., Jacobi,K.W., Klemen,U., Kohnen,S., Quentin,C.D., Teping,C., Pham,T., Knorz,M.C., & Poetzsch,D. (2000) Cataract extraction with multifocal intraocular lens implantation: clinical, functional, and quality-of-life outcomes. Multicenter clinical trial in Germany and Austria. *J Cataract Refract Surg*, **26**, 1356-1366.
- Javitt,J.C. & Steinert,R.F. (2000) Cataract extraction with multifocal intraocular lens implantation: a multinational clinical trial evaluating clinical, functional, and quality-of-life outcomes. *Ophthalmology*, **107**, 2040-2048.
- Javitt,J.C., Tielsch,J.M., Canner,J.K., Kolb,M.M., Sommer,A., & Steinberg,E.P. (1992) National outcomes of cataract extraction. Increased risk of retinal complications associated with Nd:YAG laser capsulotomy. The Cataract Patient Outcomes Research Team. *Ophthalmology*, **99**, 1487-1497.
- Jehan,F.S., Mamalis,N., Spencer,T.S., Fry,L.L., Kerstine,R.S., & Olson,R.J. (2000) Postoperative sterile endophthalmitis (TASS) associated with the memorylens. *J.Cataract Refract.Surg.*, **26**, 1773-1777.

- Johnson,S.H., Kratz,R.P., & Olson,P.F. (1984) Clinical experience with the Nd:YAG laser. *J Am.Intraocul.Implant Soc.*, **10**, 452-460.
- Jones,N.P., McLeod,D., & Boulton,M.E. (1995) Massive proliferation of lens epithelial remnants after Nd-YAG laser capsulotomy. *Br.J.Ophthalmol.*, **79**, 261-263.
- Kanagawa,R., Saika,S., Ohmi,S., Tamura,M., & Nakao,T. (1990) Presence and distribution of fibronectin on the surface of implanted intraocular lenses in rabbits. *Graefes Arch.Clin.Exp.Ophthalmol.*, **228**, 398-400.
- Kappelhof,J.P., Vrensen,G.F., de Jong,P.T., Pameyer,J., & Willekens,B. (1986) An ultrastructural study of Elschnig's pearls in the pseudophakic eye. *Am.J.Ophthalmol.*, **101**, 58-69.
- Kappelhof,J.P., Vrensen,G.F., Vester,C.A., Pameyer,J.H., de Jong,P.T., & Willekens,B.L. (1985) The ring of Soemmerring in the rabbit: A scanning electron microscopic study. *Graefes Arch.Clin.Exp.Ophthalmol.*, **223**, 111-120.
- Kato,K., Kurosaka,D., Bissen-Miyajima,H., Negishi,K., Hara,E., & Nagamoto,T. (1997a) Elschnig pearl formation along the posterior capsulotomy margin after neodymium:YAG capsulotomy. *J Cataract Refract.Surg.*, **23**, 1556-1560.
- Kato,K., Kurosaka,D., & Nagamoto,T. (1997b) Apoptotic cell death in rabbit lens after lens extraction. *Invest Ophthalmol.Vis.Sci.*, **38**, 2322-2330.
- Kato,S., Oshika,T., Numaga,J., Hayashi,Y., Oshiro,M., Yuguchi,T., & Kaiya,T. (2001) Anterior capsular contraction after cataract surgery in eyes of diabetic patients. *Br.J.Ophthalmol.*, **85**, 21-23.
- Kato,S., Suzuki,T., Hayashi,Y., Numaga,J., Hattori,T., Yuguchi,T., Kaiya,T., & Oshika,T. (2002) Risk factors for contraction of the anterior capsule opening after cataract surgery. *J Cataract Refract Surg*, **28**, 109-112.

- Kawashima,Y., Saika,S., Miyamoto,T., Yamanaka,O., Okada,Y., Tanaka,S., & Ohnishi,Y. (2000) Matrix metalloproteinases and tissue inhibitors of metalloproteinases of fibrous humans lens capsules with intraocular lenses. *Curr.Eye Res.*, **21**, 962-967.
- Keates,R.H., Steinert,R.F., Puliafito,C.A., & Maxwell,S.K. (1984) Long-term follow-up of Nd:YAG laser posterior capsulotomy. *J Am.Intraocul.Implant Soc.*, **10**, 164-168.
- Kelman,C.D. (1967) Phaco-emulsification and aspiration. A new technique of cataract removal. A preliminary report. *Am.J.Ophthalmol.*, **64**, 23-35.
- Kent,D.G., Peng,Q., Isaacs,R.T., Whiteside,S.B., Barker,D.L., & Apple,D.J. (1997) Security of capsular fixation: small-versus large-hole plate-hepatic lenses. *J Cataract Refract.Surg.*, **23**, 1371-1375.
- Khan,A.J. & Percival,S.P. (1999) 12 year results of a prospective trial comparing poly(methyl methacrylate) and poly(hydroxyethyl methacrylate) intraocular lenses. *J Cataract Refract Surg*, **25**, 1404-1407.
- Kinoshita,J.H. (1974) Mechanisms initiating cataract formation. Proctor Lecture. *Invest Ophthalmol.*, **13**, 713-724.
- Klein,R., Klein,B.E., & Moss,S.E. (1984) Visual impairment in diabetes. *Ophthalmology*, **91**, 1-9.
- Klos,K.M., Richter,R., Schnaudigel,O., & Ohrloff,C. (1999) Image analysis of implanted rigid and foldable intraocular lenses in human eyes using Scheimpflug photography. *Ophthalmic Res.*, **31**, 130-133.
- Knorz,M.C., Soltau,J.B., Seiberth,V., & Lorgner,C. (1991) Incidence of posterior capsule opacification after extracapsular cataract extraction in diabetic patients. *Metab Pediatr.Syst.Ophthalmol.*, **14**, 57-58.

- Koch,D.D., Liu,J.F., Gill,E.P., & Parke,D.W. (1989) Axial myopia increases the risk of retinal complications after neodymium-YAG laser posterior capsulotomy. *Arch.Ophthalmol.*, **107**, 986-990.
- Kochounian,H.H., Kovacs,S.A., Sy,J., Grubbs,D.E., & Maxwell,W.A. (1994) Identification of intraocular lens-adsorbed proteins in mammalian in vitro and in vivo systems. *Arch.Ophthalmol.*, **112**, 395-401.
- Kochounian,H.H., Maxwell,W.A., & Gupta,A. (1991) Complement activation by surface modified poly(methyl methacrylate) intraocular lenses. *J.Cataract Refract.Surg.*, **17**, 139-142.
- Kohnen,S. & Brauweiler,P. (1996) First results of cataract surgery and implantation of negative power intraocular lenses in highly myopic eyes. *J.Cataract Refract.Surg.*, **22**, 416-420.
- Krishna,R., Meisler,D.M., Lowder,C.Y., Estafanous,M., & Foster,R.E. (1998) Long-term follow-up of extracapsular cataract extraction and posterior chamber intraocular lens implantation in patients with uveitis. *Ophthalmology*, **105**, 1765-1769.
- Kruger,A.J., Schauersberger,J., Abela,C., Schild,G., & Amon,M. (2000) Two year results: sharp versus rounded optic edges on silicone lenses. *J.Cataract Refract.Surg.*, **26**, 566-570.
- Kubo,E., Urakami,T., Fatma,N., Akagi,Y., & Singh,D.P. (2004) Polyol pathway-dependent osmotic and oxidative stresses in aldose reductase-mediated apoptosis in human lens epithelial cells: role of AOP2. *Biochem.Biophys.Res.Commun.*, **314**, 1050-1056.
- Kuchle,M., Amberg,A., Martus,P., Nguyen,N.X., & Naumann,G.O. (1997) Pseudoexfoliation syndrome and secondary cataract. *Br.J.Ophthalmol.*, **81**, 862-866.

- Kucuksumer,Y., Bayraktar,S., Sahin,S., & Yilmaz,O.F. (2000) Posterior capsule opacification 3 years after implantation of an AcrySof and a MemoryLens in fellow eyes. *J.Cataract Refract.Surg.*, **26**, 1176-1182.
- Kumagai,K., Ogino,N., Shinjo,U., Demizu,S., Shioya,M., & Ueda,K. (1999) Vitreous opacification after neodymium:YAG posterior capsulotomy. *J.Cataract Refract.Surg.*, **25**, 981-984.
- Kumar,R., Reeves,D.L., & Olson,R.J. (2001) Wound complications associated with incision enlargement for foldable intraocular lens implantation during cataract surgery. *J Cataract Refract.Surg.*, **27**, 224-226.
- Kurosaka,D., Kato,K., Kurosaka,H., Yoshino,M., Nakamura,K., & Negishi,K. (2002) Elschmig pearl formation along the neodymium:YAG laser posterior capsulotomy margin. Long-term follow-up. *J Cataract Refract.Surg.*, **28**, 1809-1813.
- Kurosaka,D., Kato,K., & Nagamoto,T. (1996) Presence of alpha smooth muscle actin in lens epithelial cells of aphakic rabbit eyes. *British Journal of Ophthalmology*, **80**, 906-910.
- Kurosaka,D., Kato,K., Nagamoto,T., & Negishi,K. (1995) Growth factors influence contractility and alpha-smooth muscle actin expression in bovine lens epithelial cells. *Invest Ophthalmol. Vis.Sci.*, **36**, 1701-1708.
- Kurosaka,D., Kato,K., Oshima,T., Kurosaka,H., Yoshino,M., & Nagamoto,T. (2000) Effect of rabbit aqueous humor obtained after cataract surgery on collagen gel contraction induced by bovine lens epithelial cells. *Ophthalmic Res.*, **32**, 94-99.
- Kurosaka,D. & Nagamoto,T. (1994) Inhibitory effect of TGF-beta 2 in human aqueous humor on bovine lens epithelial cell proliferation. *Invest Ophthalmol. Vis.Sci.*, **35**, 3408-3412.

- Kuszak,J.R. (1997) Anatomy and embryology of the lens. Duane's Clinical Ophthalmology (ed. by W. Tasman & Jaeger E.A.) Lippincott-Raven, Philadelphia.
- Kuszak,J.R., Clark,J.I., Cooper,K.E., & Rae,J. (2000) Biology of the lens: lens transparency as a function of embryology, anatomy and physiology. Principles and Practice of Ophthalmology (ed. by Albert D.M. & Jacobiec F.A.) W.B. Saunders Company, Philadelphia.
- Larsson,R., Selen,G., Bjordklund,H., & Fagerholm,P. (1989) Intraocular PMMA lenses modified with surface-immobilized heparin: evaluation of biocompatibility in vitro and in vivo. *Biomaterials*, **10**, 511-516.
- Lasa,M.S., Datiles,M.B., III, Magno,B.V., & Mahurkar,A. (1995) Scheimpflug photography and postcataract surgery posterior capsule opacification. *Ophthalmic Surg.*, **26**, 110-113.
- Laurell,C.G., Zetterstrom,C., & Lundgren,B. (1998) Phacoemulsification and lens implantation in rabbit eyes: capsular bag versus ciliary sulcus implantation and 4.0 versus 7.0 mm capsulorhexis. *J.Cataract Refract.Surg.*, **24**, 230-236.
- Lawrence,M.G. (2000) Extracapsular cataract extraction. Principles and Practice of Ophthalmology (ed. by D. M. Albert & F. A. Jacobiec) W.B. Saunders Company, Philadelphia.
- Leaming,D.V. (2002) Practice styles and preferences of ASCRS members--2001 survey. *J Cataract Refract.Surg.*, **28**, 1681-1688.
- Lee,H.J., Min,S.H., & Kim,T.Y. (2004) Bilateral spontaneous dislocation of intraocular lenses within the capsular bag in a retinitis pigmentosa patient. *Korean J.Ophthalmol.*, **18**, 52-57.
- Legler,U.F., Apple,D.J., Assia,E.I., Bluestein,E.C., Castaneda,V.E., & Mowbray,S.L. (1993) Inhibition of posterior capsule opacification: the effect of colchicine in a sustained drug delivery system. *J.Cataract Refract.Surg.*, **19**, 462-470.

- Levy, J.H., Pisacano, A.M., & Anello, R.D. (1990) Displacement of bag-placed hydrogel lenses into the vitreous following neodymium: YAG laser capsulotomy. *J. Cataract Refract. Surg.*, **16**, 563-566.
- Leyland, M. & Zinicola, E. (2003) Multifocal versus monofocal intraocular lenses in cataract surgery: a systematic review. *Ophthalmology*, **110**, 1789-1798.
- Leyland, M., Zinicola, E., Bloom, P., & Lee, N. (2001) Prospective evaluation of a plate haptic toric intraocular lens. *Eye*, **15**, 202-205.
- Leyland, M.D., Langan, L., Goolfee, F., Lee, N., & Bloom, P.A. (2002) Prospective randomised double-masked trial of bilateral multifocal, bifocal or monofocal intraocular lenses. *Eye*, **16**, 481-490.
- Liao, S.B. & Ku, W.C. (2003) Progression of diabetic retinopathy after phacoemulsification in diabetic patients: a three-year analysis. *Chang Gung Med. J.*, **26**, 829-834.
- Lin, L.R., Reddy, V.N., Giblin, F.J., Kador, P.F., & Kinoshita, J.H. (1991) Polyol accumulation in cultured human lens epithelial cells. *Exp. Eye Res.*, **52**, 93-100.
- Linnola R. (2001) The sandwich theory: a bioactivity based explanation for posterior capsule opacification after cataract surgery with intraocular lens implantation. M.D., Department of Ophthalmology & Department of Medical Biochemistry, University of Oulu.
- Linnola, R.J. (1997) Sandwich theory: bioactivity-based explanation for posterior capsule opacification. *J. Cataract Refract. Surg.*, **23**, 1539-1542.
- Linnola, R.J. & Holst, A. (1998) Evaluation of a 3-piece silicone intraocular lens with poly(methyl methacrylate) haptics. *J. Cataract Refract Surg*, **24**, 1509-1514.

- Linnola,R.J., Salonen,J.I., & Happonen,R.P. (1999a) Intraocular lens bioactivity tested using rabbit corneal tissue cultures. *J.Cataract Refract.Surg.*, **25**, 1480-1485.
- Linnola,R.J., Sund,M., Ylonen,R., & Pihlajaniemi,T. (1999b) Adhesion of soluble fibronectin, laminin, and collagen type IV to intraocular lens materials. *J.Cataract Refract.Surg.*, **25**, 1486-1491.
- Linnola,R.J., Werner,L., Pandey,S.K., Escobar-Gomez,M., Znoiko,S.L., & Apple,D.J. (2000a) Adhesion of fibronectin, vitronectin, laminin, and collagen type IV to intraocular lens materials in pseudophakic human autopsy eyes. Part 1: histological sections. *J Cataract Refract Surg*, **26**, 1792-1806.
- Linnola,R.J., Werner,L., Pandey,S.K., Escobar-Gomez,M., Znoiko,S.L., & Apple,D.J. (2000b) Adhesion of fibronectin, vitronectin, laminin, and collagen type IV to intraocular lens materials in pseudophakic human autopsy eyes. Part 2: explanted intraocular lenses. *J.Cataract Refract.Surg.*, **26**, 1807-1818.
- Liu,C.S., Wormstone,I.M., Duncan,G., Marcantonio,J.M., Webb,S.F., & Davies,P.D. (1996) A study of human lens cell growth in vitro. A model for posterior capsule opacification. *Invest Ophthalmol.Vis.Sci.*, **37**, 906-914.
- Lyle,W.A. & Jin,G.J. (1996) Phacoemulsification with intraocular lens implantation in high myopia. *J.Cataract Refract.Surg.*, **22**, 238-242.
- Lynch,M.G., Quigley,H.A., Green,W.R., Pollack,I.P., & Robin,A.L. (1986) The effect of neodymium: YAG laser capsulotomy on aqueous humor dynamics in the monkey eye. *Ophthalmology*, **93**, 1270-1275.
- Maar,N., Dejacó-Ruhsurm,I., Zehetmayer,M., & Skorpik,C. (2002) Plate-haptic silicone intraocular lens implantation: long-term results. *J Cataract Refract Surg*, **28**, 992-997.

- MacEwen,C.J. & Baines,P.S. (1989) Retinal detachment following YAG laser capsulotomy. *Eye*, **3** (Pt 6), 759-763.
- Mackool,R.J. (1996) Decentration of plate-haptic lenses. *J.Cataract Refract.Surg.*, **22**, 396.
- Macky,T.A., Pandey,S.K., Werner,L., Trivedi,R.H., Izak,A.M., & Apple,D.J. (2001) Anterior capsule opacification. *Int.Ophthalmol.Clin.*, **41**, 17-31.
- Magno,B.V., Datiles,M.B., Lasa,M.S., Fajardo,M.R., Caruso,R.C., & Kaiser-Kupfer,M.I. (1997) Evaluation of visual function following neodymium:YAG laser posterior capsulotomy. *Ophthalmology*, **104**, 1287-1293.
- Mainster,M.A., Sliney,D.H., Belcher,C.D., III, & Buzney,S.M. (1983) Laser photodisruptors. Damage mechanisms, instrument design and safety. *Ophthalmology*, **90**, 973-991.
- Majima,K. (1995) Cell biological analysis of the human cataractous lens: implication of lens epithelial cells in the development of aftercataract. *Ophthalmic Res.*, **27**, 202-207.
- Maltzman,B.A., Haupt,E., & Cucci,P. (1989) Effect of the laser ridge on posterior capsule opacification. *J.Cataract Refract.Surg.*, **15**, 644-646.
- Mamalis,N., Craig,M.T., & Price,F.W. (1990) Spectrum of Nd:YAG laser-induced intraocular lens damage in explanted lenses. *J.Cataract Refract.Surg.*, **16**, 495-500.
- Mamalis,N., Crandall,A.S., Linebarger,E., Sheffield,W.K., & Leidenix,M.J. (1995) Effect of intraocular lens size on posterior capsule opacification after phacoemulsification. *J.Cataract Refract.Surg.*, **21**, 99-102.
- Mamalis,N., Davis,B., Nilson,C.D., Hickman,M.S., & Leboyer,R.M. (2004) Complications of foldable intraocular lenses requiring explantation or

- secondary intervention-2003 survey update. *J. Cataract Refract.Surg.*, **30**, 2209-2218.
- Mamalis,N., Omar,O., Veiga,J., Tanner,D., Pirayesh,A., & Fernquist,D.S. (1996a) Comparison of two plate-haptic intraocular lenses in a rabbit model. *J. Cataract Refract.Surg.*, **22 Suppl 2**, 1291-1295.
- Mamalis,N., Phillips,B., Kopp,C.H., Crandall,A.S., & Olson,R.J. (1996b) Neodymium: YAG capsulotomy rates after phacoemulsification with silicone posterior chamber intraocular lenses. *J.Cataract Refract.Surg.*, **22 Suppl 2**, 1296-1302.
- Mansfield,K.J., Cerra,A., & Chamberlain,C.G. (2004) Effects of dexamethasone on posterior capsule opacification-like changes in a rat lens explant model. *Mol.Vis.*, **10**, 728-737.
- Mantjarvi,M. & Tuppurainen,K. (1995) Colour vision and dark adaptation in high myopia without central retinal degeneration. *Br.J.Ophthalmol.*, **79**, 105-108.
- Masket,S., Fine,I.H., Kidwell,T.P., Koch,D.D., Lane,S.S., Miller,K.M., Steinert,R.F., Mangione,C.C., & Boyce,V. Cataract in the adult eye. (2001) *American Academy of Ophthalmology. Preferred Practice Pattern*. Serial, Monograph.
- Mastropasqua,L., Lobefalo,L., Ciancaglini,M., Ballone,E., & Gallenga,P.E. (1997) Heparin eyedrops to prevent posterior capsule opacification. *J.Cataract Refract.Surg.*, **23**, 440-446.
- McCulley,J.P. (2003) Biocompatibility of intraocular lenses. *Eye Contact Lens*, **29**, 155-163.
- McDonnell,P.J., Krause,W., & Glaser,B.M. (1988) In vitro inhibition of lens epithelial cell proliferation and migration. *Ophthalmic Surg.*, **19**, 25-30.
- McDonnell,P.J., Rowen,S.L., Glaser,B.M., & Sato,M. (1985) Posterior capsule opacification. An in vitro model. *Arch.Ophthalmol.*, **103**, 1378-1381.

- McDonnell,P.J., Stark,W.J., & Green,W.R. (1984) Posterior capsule opacification: a specular microscopic study. *Ophthalmology*, **91**, 853-856.
- McDonnell,P.J., Zarbin,M.A., & Green,W.R. (1983) Posterior capsule opacification in pseudophakic eyes. *Ophthalmology*, **90**, 1548-1553.
- McPherson,R.J. & Govan,J.A. (1995) Posterior capsule reopacification after neodymium:YAG laser capsulotomy. *J.Cataract Refract.Surg.*, **21**, 351-352.
- Meacock,W.R., Spalton,D.J., Boyce,J., & Marshall,J. (2003) The effect of posterior capsule opacification on visual function. *Invest Ophthalmol Vis.Sci.*, **44**, 4665-4669.
- Meacock,W.R., Spalton,D.J., Hollick,E.J., Barman,S., & Boyce,J.F. (2001) The effect of polymethylmethacrylate and acrysof intraocular lenses on the posterior capsule in patients with a large capsulorrhexis. *Jpn.J.Ophthalmol.*, **45**, 348-354.
- Mentes,J., Erakgun,T., Afrashi,F., & Kerci,G. (2003) Incidence of cystoid macular edema after uncomplicated phacoemulsification. *Ophthalmologica*, **217**, 408-412.
- Mester,U., Strauss,M., & Grewing,R. (1998) Biocompatibility and blood-aqueous barrier impairment in at-risk eyes with heparin-surface-modified or unmodified lenses. *J.Cataract Refract.Surg.*, **24**, 380-384.
- Milazzo,S., Turut,P., Artin,B., & Charlin,J.F. (1996) Long-term follow-up of three-piece, looped, silicone intraocular lenses. *J Cataract Refract.Surg.*, **22 Suppl 2**, 1259-1262.
- Minassian,D.C., Reidy,A., Desai,P., Farrow,S., Vafidis,G., & Minassian,A. (2000) The deficit in cataract surgery in England and Wales and the escalating problem of visual impairment: epidemiological modelling of the population dynamics of cataract. *British Journal of Ophthalmology*, **84**, 4-8.

- Minassian,D.C., Rosen,P., Dart,J.K.G., Reidy,A., Desai,P., & Sidhu,M. (2001) Extracapsular cataract extraction compared with small incision surgery by phacoemulsification: a randomised trial. *British Journal of Ophthalmology*, **85**, 822-829.
- Miyake,K., Ota,I., Miyake,S., & Maekubo,K. (1996) Correlation between intraocular lens hydrophilicity and anterior capsule opacification and aqueous flare. *J Cataract Refract.Surg.*, **22 Suppl 1**, 764-769.
- Miyata,A. & Yaguchi,S. (2004) Equilibrium water content and glistenings in acrylic intraocular lenses. *J.Cataract Refract.Surg.*, **30**, 1768-1772.
- Moisseiev,J., Bartov,E., Schochat,A., & Blumenthal,M. (1989) Long-term study of the prevalence of capsular opacification following extracapsular cataract extraction. *J.Cataract Refract.Surg.*, **15**, 531-533.
- Moreno-Montanes,J., Sanchez-Tocino,H., & Rodriguez-Conde,R. (2002) Complete anterior capsule contraction after phacoemulsification with acrylic intraocular lens and endocapsular ring implantation. *J.Cataract Refract.Surg.*, **28**, 717-719.
- Mullner-Eidenbock,A., Amon,M., Schauersberger,J., Kruger,A., Abela,C., Petternel,V., & Zidek,T. (2001) Cellular reaction on the anterior surface of 4 types of intraocular lenses. *J.Cataract Refract.Surg.*, **27**, 734-740.
- Murrill,C.A., Stanfield,D.L., & Van Brocklin,M.D. (1995) Capsulotomy. *Optom.Clin.*, **4**, 69-83.
- Nagamoto,T. & Eguchi,G. (1997) Effect of intraocular lens design on migration of lens epithelial cells onto the posterior capsule. *J Cataract Refract Surg*, **23**, 866-872.
- Nagata,T., Minakata,A., & Watanabe,I. (1998) Adhesiveness of AcrySof to a collagen film. *J Cataract Refract Surg*, **24**, 367-370.

- Naus,N.C., Luyten,G.P., Stijnen,T., & de Jong,P.T. (1995) Astigmatism and visual recovery after phacoemulsification and conventional extracapsular cataract extraction. *Doc.Ophthalmol.*, **90**, 53-59.
- Naylor,G., Sutton,G.A., Morrell,A.J., & Pearce,J.L. (1989) Intercapsular versus extracapsular cataract extraction. *Ophthalmic Surg.*, **20**, 766-768.
- Negishi,K., Nagamoto,T., Hara,E., Kurosaka,D., & Bissen-Miyajima,H. (1996) Clinical evaluation of a five-zone refractive multifocal intraocular lens. *J Cataract Refract Surg*, **22**, 110-115.
- Neumann,A.C., McCarty,G.R., Sanders,D.R., & Raanan,M.G. (1989) Small incisions to control astigmatism during cataract surgery. *J.Cataract Refract.Surg.*, **15**, 78-84.
- Neuteboom,G.H. & Vries-Knoppert,W.A. (1988) Endophthalmitis after Nd:YAG laser capsulotomy. *Doc.Ophthalmol.*, **70**, 175-178.
- Newland,T.J., McDermott,M.L., Elliott,D., Hazlett,L.D., Apple,D.J., Lambert,R.J., & Barrett,R.P. (1999) Experimental neodymium:YAG laser damage to acrylic, poly(methyl methacrylate), and silicone intraocular lens materials. *J Cataract Refract.Surg.*, **25**, 72-76.
- Newman,D.K. (1998) Severe capsulorhexis contracture after cataract surgery in myotonic dystrophy. *J.Cataract Refract.Surg.*, **24**, 1410-1412.
- Ninn-Pedersen,K. & Bauer,B. (1997) Cataract patients in a defined Swedish population 1986-1990. VI. YAG laser capsulotomies in relation to preoperative and surgical conditions. *Acta Ophthalmol.Scand.*, **75**, 551-557.
- Nirankari,V.S. & Richards,R.D. (1985) Complications associated with the use of the neodymium:YAG laser. *Ophthalmology*, **92**, 1371-1375.
- Nishi,O. (1986) Incidence of posterior capsule opacification in eyes with and without posterior chamber intraocular lenses. *J.Cataract Refract.Surg.*, **12**, 519-522.

- Nishi,O. (1987) Removal of lens epithelial cells by ultrasound in endocapsular cataract surgery. *Ophthalmic Surg.*, **18**, 577-580.
- Nishi,O. & Nishi,K. (1992) Disruption of the blood-aqueous barrier by residual lens epithelial cells after intraocular lens implantation. *Ophthalmic Surg.*, **23**, 325-329.
- Nishi,O. & Nishi,K. (1993) Intraocular lens encapsulation by shrinkage of the capsulorhexis opening. *J.Cataract Refract.Surg.*, **19**, 544-545.
- Nishi,O. & Nishi,K. (1999) Preventing posterior capsule opacification by creating a discontinuous sharp bend in the capsule. *J.Cataract Refract.Surg.*, **25**, 521-526.
- Nishi,O. & Nishi,K. (2002) Preventive effect of a second-generation silicone intraocular lens on posterior capsule opacification. *J Cataract Refract.Surg.*, **28**, 1236-1240.
- Nishi,O. & Nishi,K. (2003) Effect of the optic size of a single-piece acrylic intraocular lens on posterior capsule opacification. *J Cataract Refract.Surg.*, **29**, 348-353.
- Nishi,O., Nishi,K., & Akura,J. (2002) Speed of capsular bend formation at the optic edge of acrylic, silicone, and poly(methyl methacrylate) lenses. *J Cataract Refract Surg*, **28**, 431-437.
- Nishi,O., Nishi,K., Akura,J., & Nagata,T. (2001) Effect of round-edged acrylic intraocular lenses on preventing posterior capsule opacification. *J Cataract Refract.Surg.*, **27**, 608-613.
- Nishi,O., Nishi,K., Fujiwara,T., & Shirasawa,E. (1995a) Effects of diclofenac sodium and indomethacin on proliferation and collagen synthesis of lens epithelial cells in vitro. *J.Cataract Refract.Surg.*, **21**, 461-465.

- Nishi,O., Nishi,K., Fujiwara,T., Shirasawa,E., & Ohmoto,Y. (1996a) Effects of the cytokines on the proliferation of and collagen synthesis by human cataract lens epithelial cells. *Br.J.Ophthalmol.*, **80**, 63-68.
- Nishi,O., Nishi,K., & Imanishi,M. (1992) Synthesis of interleukin-1 and prostaglandin E2 by lens epithelial cells of human cataracts. *Br.J.Ophthalmol.*, **76**, 338-341.
- Nishi,O., Nishi,K., Imanishi,M., Tada,Y., & Shirasawa,E. (1995b) Effect of the cytokines on the prostaglandin E2 synthesis by lens epithelial cells of human cataracts. *Br.J.Ophthalmol.*, **79**, 934-938.
- Nishi,O., Nishi,K., Mano,C., Ichihara,M., & Honda,T. (1998a) The inhibition of lens epithelial cell migration by a discontinuous capsular bend created by a band-shaped circular loop or a capsule-bending ring. *Ophthalmic Surg Lasers*, **29**, 119-125.
- Nishi,O., Nishi,K., Mano,C., Ichihara,M., Honda,T., & Saitoh,I. (1997) Inhibition of migrating lens epithelial cells by blocking the adhesion molecule integrin: a preliminary report. *J.Cataract Refract.Surg.*, **23**, 860-865.
- Nishi,O., Nishi,K., & Menapace,R. (1998b) Capsule-bending ring for the prevention of capsular opacification: a preliminary report. *Ophthalmic Surg.Lasers*, **29**, 749-753.
- Nishi,O., Nishi,K., Morita,T., Tada,Y., Shirasawa,E., & Sakanishi,K. (1996b) Effect of intraocular sustained release of indomethacin on postoperative inflammation and posterior capsule opacification. *J.Cataract Refract.Surg.*, **22 Suppl 1**, 806-810.
- Nishi,O., Nishi,K., & Ohmoto,Y. (1996c) Synthesis of interleukin-1, interleukin-6, and basic fibroblast growth factor by human cataract lens epithelial cells. *J Cataract Refract.Surg.*, **22 Suppl 1**, 852-858.

- Nishi,O., Nishi,K., & Sakanishi,K. (1998c) Inhibition of migrating lens epithelial cells at the capsular bend created by the rectangular optic edge of a posterior chamber intraocular lens. *Ophthalmic Surg.Lasers*, **29**, 587-594.
- Nishi,O., Nishi,K., Wada,K., & Ohmoto,Y. (1999) Expression of transforming growth factor (TGF)-alpha, TGF-beta(2) and interleukin 8 messenger RNA in postsurgical and cultured lens epithelial cells obtained from patients with senile cataracts. *Graefes Arch.Clin.Exp.Ophthalmol.*, **237**, 806-811.
- Nishi,O., Nishi,K., & Wickstrom,K. (2000) Preventing lens epithelial cell migration using intraocular lenses with sharp rectangular edges. *J.Cataract Refract.Surg.*, **26**, 1543-1549.
- Nishi,O., Nishi,K., Yamada,Y., & Mizumoto,Y. (1995c) Effect of indomethacin-coated posterior chamber intraocular lenses on postoperative inflammation and posterior capsule opacification. *J Cataract Refract.Surg.*, **21**, 574-578.
- Noma,H., Funatsu,H., Yamashita,H., Kitano,S., Mishima,H.K., & Hori,S. (2002) Regulation of angiogenesis in diabetic retinopathy: possible balance between vascular endothelial growth factor and endostatin. *Arch.Ophthalmol.*, **120**, 1075-1080.
- Ober,M.D., Lemon,L.C., Shin,D.H., Nootheti,P., Cha,S.C., & Kim,P.H. (2000) Posterior capsular opacification in phacotrabeculectomy : a long-term comparative study of silicone versus acrylic intraocular lens. *Ophthalmology*, **107**, 1868-1873.
- Oharazawa,H., Ibaraki,N., Matsui,H., & Ohara,K. (2001) Age-related changes of human lens epithelial cells in vivo. *Ophthalmic Res.*, **33**, 363-366.
- Okhravi,N., Lightman,S.L., & Towler,H.M. (1999) Assessment of visual outcome after cataract surgery in patients with uveitis. *Ophthalmology*, **106**, 710-722.

- Olivero,D.K. & Furcht,L.T. (1993) Type IV collagen, laminin, and fibronectin promote the adhesion and migration of rabbit lens epithelial cells in vitro. *Invest Ophthalmol.Vis.Sci.*, **34**, 2825-2834.
- Olson,R.J. & Crandall,A.S. (1998) Silicone versus polymethylmethacrylate intraocular lenses with regard to capsular opacification. *Ophthalmic Surg.Lasers*, **29**, 55-58.
- Oner,F.H., Gunenc,U., & Ferliel,S.T. (2000) Posterior capsule opacification after phacoemulsification: foldable acrylic versus poly(methyl methacrylate) intraocular lenses. *J.Cataract Refract.Surg.*, **26**, 722-726.
- Oshika,T., Nagahara,K., Yaguchi,S., Emi,K., Takenaka,H., Tsuboi,S., Yoshitomi,F., Nagamoto,T., & Kurosaka,D. (1998a) Three year prospective, randomized evaluation of intraocular lens implantation through 3.2 and 5.5 mm incisions. *J Cataract Refract.Surg.*, **24**, 509-514.
- Oshika,T., Nagata,T., & Ishii,Y. (1998b) Adhesion of lens capsule to intraocular lenses of polymethylmethacrylate, silicone, and acrylic foldable materials: an experimental study. *Br.J Ophthalmol.*, **82**, 549-553.
- Oshika,T., Santou,S., Kato,S., & Amano,S. (2001) Secondary closure of neodymium:YAG laser posterior capsulotomy. *J Cataract Refract.Surg.*, **27**, 1695-1697.
- Oshika,T., Suzuki,Y., Kizaki,H., & Yaguchi,S. (1996) Two year clinical study of a soft acrylic intraocular lens. *J Cataract Refract Surg*, **22**, 104-109.
- Oshika,T., Tsuboi,S., Yaguchi,S., Yoshitomi,F., Nagamoto,T., Nagahara,K., & Emi,K. (1994) Comparative study of intraocular lens implantation through 3.2- and 5.5-mm incisions. *Ophthalmology*, **101**, 1183-1190.
- Oshika,T., Yoshimura,K., & Miyata,N. (1992) Postsurgical inflammation after phacoemulsification and extracapsular extraction with soft or conventional intraocular lens implantation. *J.Cataract Refract.Surg.*, **18**, 356-361.

- Packard,R. (1998) Revisiting the anterior capsulotomy. *J.Cataract Refract.Surg.*, **24**, 1016-1017.
- Pande,M., Spalton,D.J., & Marshall,J. (1996a) Continuous curvilinear capsulorhexis and intraocular lens biocompatibility. *J.Cataract Refract.Surg.*, **22**, 89-97.
- Pande,M.V., Spalton,D.J., Kerr-Muir,M.G., & Marshall,J. (1996b) Postoperative inflammatory response to phacoemulsification and extracapsular cataract surgery: aqueous flare and cells. *J.Cataract Refract.Surg.*, **22 Suppl 1**, 770-774.
- Pande,M.V., Ursell,P.G., Spalton,D.J., Heath,G., & Kundaiker,S. (1997) High-resolution digital retroillumination imaging of the posterior -004 capsule after cataract surgery. *J.Cataract Refract.Surg.*, **23**, 1521-1527.
- Parkin,B. & Pitts-Crick,M. (2000) Opacification of silicone intraocular implant requiring lens exchange. *Eye*, **14 Pt 5**, 794-795.
- Peng,Q., Visessook,N., Apple,D.J., Pandey,S.K., Werner,L., Escobar-Gomez,M., Schoderbek,R., Solomon,K.D., & Guindi,A. (2000) Surgical prevention of posterior capsule opacification. Part 3: Intraocular lens optic barrier effect as a second line of defense. *J Cataract Refract.Surg.*, **26**, 198-213.
- Percival,S.P. & Pai,V. (1993) Heparin-modified lenses for eyes at risk for breakdown of the blood-aqueous barrier during cataract surgery. *J.Cataract Refract.Surg.*, **19**, 760-765.
- Petersen,A.M., Bluth,L.L., & Campion,M. (2000) Delayed posterior dislocation of silicone plate-haptic lenses after neodymium:yag capsulotomy. *J Cataract Refract.Surg.*, **26**, 1827-1829.
- Pieh,S., Weghaupt,H., & Skorpik,C. (1998) Contrast sensitivity and glare disability with diffractive and refractive multifocal intraocular lenses. *J Cataract Refract Surg*, **24**, 659-662.

- Pinckers,A. (1980) Color vision and age. *Ophthalmologica*, **181**, 23-30.
- Pinter,S.M. & Sugar,A. (1999) Phacoemulsification in eyes with past pars plana vitrectomy: case-control study. *J.Cataract Refract.Surg.*, **25**, 556-561.
- Powe,N.R., Schein,O.D., Gieser,S.C., Tielsch,J.M., Luthra,R., Javitt,J., & Steinberg,E.P. (1994) Synthesis of the literature on visual acuity and complications following cataract extraction with intraocular lens implantation. Cataract Patient Outcome Research Team. *Arch.Ophthalmol.*, **112**, 239-252.
- Powell,S.K. & Olson,R.J. (1995) Incidence of retinal detachment after cataract surgery and neodymium: YAG laser capsulotomy. *J.Cataract Refract.Surg.*, **21**, 132-135.
- Power,W.J., Rodriguez,A., Pedroza-Seres,M., & Foster,C.S. (1998) Outcomes in anterior uveitis associated with the HLA-B27 haplotype. *Ophthalmology*, **105**, 1646-1651.
- Prajna,N.V., Ellwein,L.B., Selvaraj,S., Manjula,K., & Kupfer,C. (2000) The madurai intraocular lens study IV: posterior capsule opacification. *Am.J.Ophthalmol.*, **130**, 304-309.
- Quinlan,M., Wormstone,I.M., Duncan,G., & Davies,P.D. (1997) Phacoemulsification versus extracapsular cataract extraction: a comparative study of cell survival and growth on the human capsular bag in vitro. *Br.J.Ophthalmol.*, **81**, 907-910.
- Radhakrishnan,S., Rollins,A.M., Roth,J.E., Yazdanfar,S., Westphal,V., Bardenstein,D.S., & Izatt,J.A. (2001) Real-time optical coherence tomography of the anterior segment at 1310 nm. *Arch.Ophthalmol*, **119**, 1179-1185.
- Rahman,I. & Jones,N.P. (2004) Long-term results of cataract extraction with intraocular lens implantation in patients with uveitis. *Eye*, (in press).

- Raina,U.K., Gupta,V., Arora,R., & Mehta,D.K. (2002) Posterior continuous curvilinear capsulorhexis with and without optic capture of the posterior chamber intraocular lens in the absence of vitrectomy. *J.Pediatr.Ophthalmol.Strabismus*, **39**, 278-287.
- Ram,J., Apple,D.J., Peng,Q., Visessook,N., Auffarth,G.U., Schoderbek,R.J., Jr., & Ready,E.L. (1999) Update on fixation of rigid and foldable posterior chamber intraocular lenses. Part II: Choosing the correct haptic fixation and intraocular lens design to help eradicate posterior capsule opacification. *Ophthalmology*, **106**, 891-900.
- Ram,J., Pandey,S.K., Apple,D.J., Werner,L., Brar,G.S., Singh,R., Chaudhary,K.P., & Gupta,A. (2001) Effect of in-the-bag intraocular lens fixation on the prevention of posterior capsule opacification. *J.Cataract Refract.Surg.*, **27**, 1039-1046.
- Ramana,K.V., Friedrich,B., Bhatnagar,A., & Srivastava,S.K. (2003) Aldose reductase mediates cytotoxic signals of hyperglycemia and TNF-alpha in human lens epithelial cells. *FASEB J*, **17**, 315-317.
- Ranta,P., Tommila,P., & Kivela,T. (2004) Retinal breaks and detachment after neodymium: YAG laser posterior capsulotomy: five-year incidence in a prospective cohort. *J Cataract Refract.Surg.*, **30**, 58-66.
- Rauz,S., Stavrou,P., & Murray,P.I. (2000) Evaluation of foldable intraocular lenses in patients with uveitis. *Ophthalmology*, **107**, 909-919.
- Ravalico,G., Baccara,F., Lovisato,A., & Tognetto,D. (1997) Postoperative cellular reaction on various intraocular lens materials. *Ophthalmology*, **104**, 1084-1091.
- Ravalico,G., Parentin,F., & Baccara,F. (1999) Effect of astigmatism on multifocal intraocular lenses. *J Cataract Refract Surg*, **25**, 804-807.

- Richter,C.U., Arzeno,G., Pappas,H.R., Steinert,R.F., Puliafito,C., & Epstein,D.L. (1985) Intraocular pressure elevation following Nd:YAG laser posterior capsulotomy. *Ophthalmology*, **92**, 636-640.
- Rickman-Barger,L., Florine,C.W., Larson,R.S., & Lindstrom,R.L. (1989) Retinal detachment after neodymium:YAG laser posterior capsulotomy. *Am.J Ophthalmol*, **107**, 531-536.
- Ridley,H. (1952) Intra-ocular acrylic lenses after cataract extraction. *The Lancet*, **1**, 758-761.
- Ridley,H. (1954) Further experiences of intra-ocular acrylic lens surgery; with a report of more than 100 cases. *Br.J.Ophthalmol.*, **38**, 156-162.
- Royal College of Ophthalmologists. (2004) Cataract surgery guidelines. *Report*
- Ruhswurm,I., Scholz,U., Zehetmayer,M., Hanselmayer,G., Vass,C., & Skorpik,C. (2000) Astigmatism correction with a foldable toric intraocular lens in cataract patients. *J.Cataract Refract.Surg.*, **26**, 1022-1027.
- Ruiz,J.M., Medrano,M., & Alio,J.L. (1990) Inhibition of posterior capsule opacification by 5-fluorouracil in rabbits. *Ophthalmic Res.*, **22**, 201-208.
- Saha,M.S., Spann,C.L., & Grainger,R.M. (1989) Embryonic lens induction: more than meets the optic vesicle. *Cell Differ.Dev.*, **28**, 153-171.
- Saika,S., Miyamoto,T., Ishida,I., Ohnishi,Y., & Ooshima,A. (2002) Lens epithelial cell death after cataract surgery. *J Cataract Refract.Surg.*, **28**, 1452-1456.
- Saika,S., Miyamoto,T., Ishida,I., Ohnishi,Y., & Ooshima,A. (2003) Osteopontin: a component of matrix in capsular opacification and subcapsular cataract. *Invest Ophthalmol.Vis.Sci.*, **44**, 1622-1628.

- Saika,S., Miyamoto,T., Tanaka,T., Ishida,I., Ohnishi,Y., & Ooshima,A. (2001)
Collagens XII and XIV (FACITs) in capsular opacification and in cultured
lens epithelial cells. *Curr.Eye Res.*, **23**, 463-468.
- Saika,S., Miyamoto,T., Yamanaka,A., Kawashima,Y., Okada,Y., Tanaka,S.,
Yamanaka,O., Ohmi,S., Ohnishi,Y., & Ooshima,A. (1998)
Immunohistochemical evaluation of cellular deposits on posterior chamber
intraocular lenses. *Graefes Arch.Clin.Exp.Ophthalmol*, **236**, 758-765.
- Saika,S., Ohmi,S., Ooshima,A., Kimura,M., Tanaka,S., Okada,Y., Ohnishi,Y., &
Yamanaka,A. (1997) Deposition of extracellular matrix on silicone
intraocular lens implants in rabbits. *Graefes Arch.Clin.Exp.Ophthalmol*, **235**,
517-522.
- Saika,S., Uenoyama,S., Kanagawa,R., Tamura,M., & Uenoyama,K. (1992)
Phagocytosis and fibronectin of cells observed on intraocular lenses.
Jpn.J.Ophthalmol., **36**, 184-191.
- Saika,S., Yamanaka,A., Tanaka,S., Ohmi,S., Ohnishi,Y., & Ooshima,A. (1995)
Extracellular matrix on intraocular lenses. *Exp.Eye Res.*, **61**, 713-721.
- Saitoh,J., Nishi,O., & Hitani,H. (1990) Cell density and hexagonality of lens
epithelium in human cataracts. (Abstract). *Nippon Ganka Gakkai Zasshi*, **94**,
176-180.
- Samuelson,T.W., Chu,Y.R., & Kreiger,R.A. (2000) Evaluation of giant-cell deposits
on foldable intraocular lenses after combined cataract and glaucoma surgery.
J Cataract Refract.Surg., **26**, 817-823.
- Saxby,L.A. (1999) Basic science of the lens: Anatomy. Ophthalmology (ed. by M.
Yanoff & J. S. Duker) Mosby, London.
- Schauersberger,J., Kruger,A., Abela,C., Mullner-Eidenbock,A., Petternel,V.,
Svolba,G., & Amon,M. (1999) Course of postoperative inflammation after

- implantation of 4 types of foldable intraocular lenses. *J.Cataract Refract.Surg.*, **25**, 1116-1120.
- Schaumberg,D.A., Dana,M.R., Christen,W.G., & Glynn,R.J. (1998) A systematic overview of the incidence of posterior capsule opacification. *Ophthalmology*, **105**, 1213-1221.
- Schmack,W.H. & Gerstmeyer,K. (2000) Long-term results of the foldable CeeOn Edge intraocular lens. *J.Cataract Refract.Surg.*, **26**, 1172-1175.
- Schmidbauer,J.M., Escobar-Gomez,M., Apple,D.J., Peng,Q., Arthur,S.N., & Vargas,L.G. (2002) Effect of haptic angulation on posterior capsule opacification in modern foldable lenses with a square, truncated optic edge. *J Cataract Refract.Surg.*, **28**, 1251-1255.
- Schmidbauer,J.M., Vargas,L.G., Apple,D.J., Peng,Q., Arthur,S.N., Escobar-Gomez,M., & Izak,A. (2001a) Influence of surgery-related factors on the Nd:YAG laser capsulotomy rates of 3-piece silicone IOLs - analysis of 457 pseudophakic human globes obtained post mortem. (Abstract). *Klin.Monatsbl.Augenheilkd.*, **218**, 523-527.
- Schmidbauer,J.M., Vargas,L.G., Peng,Q., Escobar-Gomez,M., Werner,L., Arthur,S.N., & Apple,D.J. (2001b) Posterior capsule opacification. *Int.Ophthalmol.Clin.*, **41**, 109-131.
- Schmitt J.M. (1999) Optical coherence tomography: a review. *IEEE J.Select.Topics Quantum Electronics*, **5**, 1205-1215.
- Schmitz,S., Dick,H.B., Krummenauer,F., Schwenn,O., & Krist,R. (2000) Contrast sensitivity and glare disability by halogen light after monofocal and multifocal lens implantation. *British Journal of Ophthalmology*, **84**, 1109-1112.
- Schubert,H.D. (1987) Vitreoretinal changes associated with rise in intraocular pressure after Nd:YAG capsulotomy. *Ophthalmic Surg.*, **18**, 19-22.

- Schubert,H.D., Morris,W.J., Trokel,S.L., & Balazs,E.A. (1985) The role of the vitreous in the intraocular pressure rise after neodymium-YAG laser capsulotomy. *Arch.Ophthalmol.*, **103**, 1538-1542.
- Scorolli,L., Martini,E., Scalinci,S.Z., Scorolli,L.G., & Meduri,R. (1996) Capsule contraction after continuous curvilinear capsulorhexis. *J.Cataract Refract.Surg.*, **22**, 1245-1246.
- Sellman,T.R. & Lindstrom,R.L. (1988) Effect of a plano-convex posterior chamber lens on capsular opacification from Elschnig pearl formation. *J.Cataract Refract.Surg.*, **14**, 68-72.
- Senn,P., Schmid,M.K., Schipper,I., & Hendrickson,P. (1997) Interaction between silicone oil and silicone intraocular lenses: an in vitro study. *Ophthalmic Surg.Lasers*, **28**, 776-779.
- Seward,H.C. (1997) Folding intraocular lenses: materials and methods. *Br.J.Ophthalmol.*, **81**, 340-341.
- Seward,H.C., Dalton,R., & Davis,A. (1993) Phacoemulsification during the learning curve: risk/benefit analysis. *Eye*, **7 (Pt 1)**, 164-168.
- Shah,G.R., Gills,J.P., Durham,D.G., & Ausmus,W.H. (1986) Three thousand YAG lasers in posterior capsulotomies: an analysis of complications and comparison to polishing and surgical discission. *Ophthalmic Surg.*, **17**, 473-477.
- Shah,S.M. & Spalton,D.J. (1994) Changes in anterior chamber flare and cells following cataract surgery. *Br.J.Ophthalmol.*, **78**, 91-94.
- Shah,S.M. & Spalton,D.J. (1995a) Comparison of the postoperative inflammatory response in the normal eye with heparin-surface-modified and poly(methyl methacrylate) intraocular lenses. *J.Cataract Refract.Surg.*, **21**, 579-585.

- Shah,S.M. & Spalton,D.J. (1995b) Natural history of cellular deposits on the anterior intraocular lens surface. *J.Cataract Refract.Surg.*, **21**, 466-471.
- Shah,S.M., Spalton,D.J., & Muir,M.K. (1993) Specular microscopy of the anterior intraocular lens surface. *Eye*, **7 (Pt 5)**, 707-710.
- Shankar,J. & Halliwell,M. (2003) Spontaneous posterior dislocation of an intraocular lens presenting as pupillary block glaucoma. *J.Cataract Refract.Surg.*, **29**, 410-411.
- Shiba,T., Mitooka,K., & Tsuneoka,H. (2003) In vitro analysis of AcrySof intraocular lens glistening. *Eur.J.Ophthalmol.*, **13**, 759-763.
- Shin,D.H., Kim,Y.Y., Ren,J., Weatherwax,A.L., Pearlman,R.B., Kim,C., Glover,K.B., & Muenk,S.B. (1998) Decrease of capsular opacification with adjunctive mitomycin C in combined glaucoma and cataract surgery. *Ophthalmology*, **105**, 1222-1226.
- Shin,D.H., Vandenbelt,S.M., Kim,P.H., Gross,J.P., Keole,N.S., Lee,S.H., Birt,C.M., & Reed,S.Y. (2002) Comparison of long-term incidence of posterior capsular opacification between phacoemulsification and phacotrabeulectomy. *Am.J Ophthalmol.*, **133**, 40-47.
- Slomovic,A.R. & Parrish,R.K. (1985) Neodymium: YAG laser posterior capsulotomy: visual acuity outcome and intraocular pressure elevation. *Can.J Ophthalmol*, **20**, 101-104.
- Sourdille,P. & Santiago,P.Y. (1999) Optical coherence tomography of macular thickness after cataract surgery. *J.Cataract Refract.Surg.*, **25**, 256-261.
- Spang,K.M., Rohrbach,J.M., & Weidle,E.G. (1999) Complete occlusion of the anterior capsular opening after intact capsulorhexis: clinicopathologic correlation. *Am.J.Ophthalmol.*, **127**, 343-345.

- Stager,D.R., Jr., Weakley,D.R., Jr., & Hunter,J.S. (2002) Long-term rates of PCO following small incision foldable acrylic intraocular lens implantation in children. *J Pediatr.Ophthalmol.Strabismus*, **39**, 73-76.
- Stark,W.J., Worthen,D., Holladay,J.T., & Murray,G. (1985) Neodymium: YAG lasers. An FDA report. *Ophthalmology*, **92**, 209-212.
- Steinberg,E.P., Javitt,J.C., Sharkey,P.D., Zuckerman,A., Legro,M.W., Anderson,G.F., Bass,E.B., & O'Day,D. (1993) The content and cost of cataract surgery. *Arch.Ophthalmol*, **111**, 1041-1049.
- Steinert,R.F. (2000) Visual outcomes with multifocal intraocular lenses. *Curr.Opin.Ophthalmol*, **11**, 12-21.
- Steinert,R.F., Aker,B.L., Trentacost,D.J., Smith,P.J., & Tarantino,N. (1999) A prospective comparative study of the AMO ARRAY zonal-progressive multifocal silicone intraocular lens and a monofocal intraocular lens. *Ophthalmology*, **106**, 1243-1255.
- Steinert,R.F., Puliafito,C.A., Kumar,S.R., Dudak,S.D., & Patel,S. (1991) Cystoid macular edema, retinal detachment, and glaucoma after Nd:YAG laser posterior capsulotomy. *Am.J Ophthalmol*, **112**, 373-380.
- Sterling,S. & Wood,T.O. (1986) Effect of intraocular lens convexity on posterior capsule opacification. *J.Cataract Refract.Surg.*, **12**, 655-657.
- Stjernschantz,J., von Dickhoff,K., Oksala,O., & Seppa,H. (1986) A study of the mechanism of ocular irritation following YAG laser capsulotomy in rabbits. *Exp.Eye Res.*, **43**, 641-651.
- Stordahl,P.B. & Drolsum,L. (2003) A comparison of Nd:YAG capsulotomy rate in two different intraocular lenses: AcrySof and Stabibag. *Acta Ophthalmol.Scand.*, **81**, 326-330.

- Struck,H.G., Heider,C., & Lautenschlager,C. (2000) Changes in the lens epithelium of diabetic and non-diabetic patients with various forms of opacities in senile cataract. (Abstract). *Klin.Monatsbl.Augenheilkd.*, **216**, 204-209.
- Subramaniam,S. & Tuft,S.J. (2001) Early decentration of plate-haptic silicone intraocular lenses. *J.Cataract Refract.Surg.*, **27**, 330-332.
- Sudhakar,J., Ravindran,R.D., & Natchiar,G. (1989) Analysis of complications in 1000 cases of posterior chamber intra ocular lens implantation. *Indian J.Ophthalmol.*, **37**, 78-79.
- Sugimoto,Y., Takayanagi,K., Tsuzuki,S., Takahashi,Y., & Akagi,Y. (1998) Postoperative changes over time in size of anterior capsulorrhexis in phacoemulsification/aspiration. *Jpn.J.Ophthalmol.*, **42**, 495-498.
- Sundelin,K. & Sjostrand,J. (1999) Posterior capsule opacification 5 years after extracapsular cataract extraction. *J.Cataract Refract.Surg.*, **25**, 246-250.
- Sunderraj,P., Villada,J.R., Joyce,P.W., & Watson,A. (1992) Glare testing in pseudophakes with posterior capsule opacification. *Eye*, **6 (Pt 4)**, 411-413.
- Suresh,P.S. & Jones,N.P. (2001) Phacoemulsification with intraocular lens implantation in patients with uveitis. *Eye*, **15**, 621-628.
- Takamura,Y., Kubo,E., Tsuzuki,S., & Akagi,Y. (2003) Apoptotic cell death in the lens epithelium of rat sugar cataract. *Exp.Eye Res.*, **77**, 51-57.
- Tamiya,S., Wormstone,I.M., Marcantonio,J.M., Gavrilovic,J., & Duncan,G. (2000) Induction of matrix metalloproteinases 2 and 9 following stress to the lens. *Exp.Eye Res.*, **71**, 591-597.
- Tan,J.C., Spalton,D.J., & Arden,G.B. (1998) Comparison of methods to assess visual impairment from glare and light scattering with posterior capsule opacification. *J.Cataract Refract.Surg.*, **24**, 1626-1631.

- Tan, J.C., Spalton, D.J., & Arden, G.B. (1999) The effect of neodymium: YAG capsulotomy on contrast sensitivity and the evaluation of methods for its assessment. *Ophthalmology*, **106**, 703-709.
- Tanaka, S., Saika, S., Tamura, M., & Ohnishi, Y. (2004a) Histological observation of complete closure of anterior capsulotomy in 2 cases. *J. Cataract Refract. Surg.*, **30**, 1374-1377.
- Tanaka, T., Saika, S., Hashizume, N., & Ohnishi, Y. (2004b) Brown haze in an Allergan SI-40NB silicone intraocular lens. *J. Cataract Refract Surg*, **30**, 250-252.
- Tanaka, Y., Kato, S., Miyata, K., Honbo, M., Nejima, R., Kitano, S., Amano, S., & Oshika, T. (2004c) Limitation of Scheimpflug videophotography system in quantifying posterior capsule opacification after intraocular lens implantation. *Am. J. Ophthalmol.*, **137**, 732-735.
- Tanner, V., Kanski, J.J., & Frith, P.A. (1998) Posterior sub-Tenon's triamcinolone injections in the treatment of uveitis. *Eye*, **12 (Pt 4)**, 679-685.
- Tarsio, J.F., Kelleher, P.J., Tarsio, M., Emery, J.M., & Lam, D.M. (1997) Inhibition of cell proliferation on lens capsules by 4197X-ricin A immunoconjugate. *J. Cataract Refract. Surg.*, **23**, 260-266.
- Tassignon, M.J. (2004a) Bag-in-the-lens in the child eye. (Abstract). *Book of Abstracts: XXII Congress of the ESCRS*, 108.
- Tassignon, M.J. (2004b) Bag-in-the-lens: 4-year results. *Personal Communication*
- Tassignon, M.J., De, G., V, & Vrensen, G.F. (2002) Bag-in-the-lens implantation of intraocular lenses. *J. Cataract Refract Surg*, **28**, 1182-1188.
- Taylor, H.R. (1999) Epidemiology of age-related cataract. *Eye*, **13 (Pt 3b)**, 445-448.

- Tehrani,M., Dick,H.B., Wolters,B., Pakula,T., & Wolf,E. (2004) Material properties of various intraocular lenses in an experimental study. *Ophthalmologica*, **218**, 57-63.
- Terry,A.C., Stark,W.J., Maumenee,A.E., & Fagadau,W. (1983) Neodymium-YAG laser for posterior capsulotomy. *Am.J.Ophthalmol.*, **96**, 716-720.
- Terry,A.C., Stark,W.J., Newsome,D.A., Maumenee,A.E., & Pina,E. (1985) Tissue toxicity of laser-damaged intraocular lens implants. *Ophthalmology*, **92**, 414-418.
- Tetz,M.R., Auffarth,G.U., Sperker,M., Blum,M., & Volcker,H.E. (1997) Photographic image analysis system of posterior capsule opacification. *J.Cataract Refract.Surg.*, **23**, 1515-1520.
- Tetz,M.R., Ries,M.W., Lucas,C., Stricker,H., & Volcker,H.E. (1996) Inhibition of posterior capsule opacification by an intraocular-lens-bound sustained drug delivery system: an experimental animal study and literature review. *J.Cataract Refract.Surg.*, **22**, 1070-1078.
- Tezel,G., Kolker,A.E., Kass,M.A., & Wax,M.B. (1997) Comparative results of combined procedures for glaucoma and cataract: II. Limbus-based versus fornix-based conjunctival flaps. *Ophthalmic Surg.Lasers*, **28**, 551-557.
- Thall,E.H. (1999) Principles of lasers. *Ophthalmology* (ed. by M. Yanoff & J. S. Duker) Mosby International Ltd, London.
- Thomas,R., Naveen,S., Jacob,A., & Braganza,A. (1997) Visual outcome and complications of residents learning phacoemulsification. *Indian J.Ophthalmol.*, **45**, 215-219.
- Tielsch,J.M., Legro,M.W., Cassard,S.D., Schein,O.D., Javitt,J.C., Singer,A.E., Bass,E.B., & Steinberg,E.P. (1996) Risk factors for retinal detachment after cataract surgery. A population-based case-control study. *Ophthalmology*, **103**, 1537-1545.

- Tognetto,D., Toto,L., Sanguinetti,G., & Ravalico,G. (2002) Glistenings in foldable intraocular lenses. *J Cataract Refract Surg*, **28**, 1211-1216.
- Trinavarat,A., Atchaneeyasakul,L., & Udompunturak,S. (2001) Neodymium:YAG laser damage threshold of foldable intraocular lenses. *J Cataract Refract.Surg.*, **27**, 775-780.
- Tsuchiya,T., Ayaki,M., Onishi,T., Kageyama,T., & Yaguchi,S. (2003) Three-year prospective randomized study of incidence of posterior capsule opacification in eyes treated with topical diclofenac and betamethasone. *Ophthalmic Res.*, **35**, 67-70.
- Tuft,S.J. & Talks,S.J. (1998) Delayed dislocation of foldable plate-haptic silicone lenses after Nd:YAG laser anterior capsulotomy. *Am.J Ophthalmol.*, **126**, 586-588.
- Umezawa,S. & Shimizu,K. (1993) Biocompatibility of surface-modified intraocular lenses. *J.Cataract Refract.Surg.*, **19**, 371-374.
- Ursell,P.G., Spalton,D.J., & Pande,M.V. (1997) Anterior capsule stability in eyes with intraocular lenses made of poly(methyl methacrylate), silicone, and AcrySof. *J Cataract Refract.Surg.*, **23**, 1532-1538.
- Ursell,P.G., Spalton,D.J., Pande,M.V., Hollick,E.J., Barman,S., Boyce,J., & Tilling,K. (1998) Relationship between intraocular lens biomaterials and posterior capsule opacification. *J.Cataract Refract.Surg.*, **24**, 352-360.
- Ursell,P.G., Spalton,D.J., Whitcup,S.M., & Nussenblatt,R.B. (1999) Cystoid macular edema after phacoemulsification: relationship to blood-aqueous barrier damage and visual acuity. *J.Cataract Refract.Surg.*, **25**, 1492-1497.
- Vaquero,M., Encinas,J.L., & Jimenez,F. (1996) Visual function with monofocal versus multifocal IOLs. *J Cataract Refract Surg*, **22**, 1222-1225.

- Vaquero-Ruano,M., Encinas,J.L., Millan,I., Hijos,M., & Cajigal,C. (1998) AMO array multifocal versus monofocal intraocular lenses: long-term follow-up. *J Cataract Refract Surg*, **24**, 118-123.
- Vargas,L.G., Peng,Q., Escobar-Gomez,M., Schmidbauer,J.M., & Apple,D.J. (2001) Overview of modern foldable intraocular lenses and clinically relevant anatomy and histology of the crystalline lens. Complications of Aphakic and Refractive Intraocular Lenses (ed. by L. Werner & D. J. Apple), pp. 1-15. Lippincott Williams & Wilkins, Philadelphia.
- Vasavada,A.R., Trivedi,R.H., & Nath,V.C. (2004) Visual axis opacification after AcrySof intraocular lens implantation in children. *J.Cataract Refract.Surg.*, **30**, 1073-1081.
- Vasavada,A.R., Trivedi,R.H., & Singh,R. (2001) Necessity of vitrectomy when optic capture is performed in children older than 5 years. *J.Cataract Refract.Surg.*, **27**, 1185-1193.
- Velilla,S., Dios,E., Herreras,J.M., & Calonge,M. (2001) Fuchs' heterochromic iridocyclitis: a review of 26 cases. *Ocul.Immunol.Inflamm.*, **9**, 169-175.
- Voigt,U. & Strobel,J. (1999) YAG laser capsulotomy in multifocal intraocular lenses. (Abstract). *Ophthalmologe*, **96**, 578-582.
- Wallentin,N., Wickstrom,K., & Lundberg,C. (1998) Effect of cataract surgery on aqueous TGF-beta and lens epithelial cell proliferation. *Invest Ophthalmol.Vis.Sci.*, **39**, 1410-1418.
- Wang,M.C. & Woung,L.C. (2000) Digital retroilluminated photography to analyze posterior capsule opacification in eyes with intraocular lenses. *J.Cataract Refract.Surg.*, **26**, 56-61.
- Wasserman,E.L., Axt,J.C., & Sheets,J.H. (1985) Neodymium: YAG laser posterior capsulotomy. *J Am.Intraocul.Implant Soc.*, **11**, 245-248.

- Watson,A. & Sunderraj,P. (1992) Comparison of small-incision phacoemulsification with standard extracapsular cataract surgery: post-operative astigmatism and visual recovery. *Eye*, **6 (Pt 6)**, 626-629.
- Weiblinger,R.P. (1986) Review of the clinical literature on the use of the Nd:YAG laser for posterior capsulotomy. *J.Cataract Refract.Surg.*, **12**, 162-170.
- Wejde,G., Kugelberg,M., & Zetterstrom,C. (2003) Posterior capsule opacification: comparison of 3 intraocular lenses of different materials and design. *J Cataract Refract.Surg.*, **29**, 1556-1559.
- Wejde,G., Kugelberg,M., & Zetterstrom,C. (2004) Position of anterior capsulorhexis and posterior capsule opacification. *Acta Ophthalmol.Scand.*, **82**, 531-534.
- Wenzel M, Reim M, Heinze M, & Boecking A (1988) Cellular invasion on the surface of intraocaulr lenses. In vivo cytological observations. *Graefes Arch.Clin.Exp.Ophthalmol.*, 449-454.
- Werner,L., Apple,D.J., Escobar-Gomez,M., Ohrstrom,A., Crayford,B.B., Bianchi,R., & Pandey,S.K. (2000a) Postoperative deposition of calcium on the surfaces of a hydrogel intraocular lens. *Ophthalmology*, **107**, 2179-2185.
- Werner,L., Pandey,S.K., Apple,D.J., Escobar-Gomez,M., McLendon,L., & Macky,T.A. (2001) Anterior capsule opacification: correlation of pathologic findings with clinical sequelae. *Ophthalmology*, **108**, 1675-1681.
- Werner,L., Pandey,S.K., Escobar-Gomez,M., Visessook,N., Peng,Q., & Apple,D.J. (2000b) Anterior capsule opacification: a histopathological study comparing different IOL styles. *Ophthalmology*, **107**, 463-471.
- Whiteside,S.B., Apple,D.J., Peng,Q., Isaacs,R.T., Guindi,A., & Draughn,R.A. (1998) Fixation elements on plate intraocular lens: large positioning holes to improve security of capsular fixation. *Ophthalmology*, **105**, 837-842.

- Williamson,W., Poirier,L., Coulon,P., & Verin,P. (1994) Compared optical performances of multifocal and monofocal intraocular lenses (contrast sensitivity and dynamic visual acuity). *British Journal of Ophthalmology*, **78**, 249-251.
- Winther-Nielson,A., Johansen,J., Pedersen,G.K., & Corydon,L. (1998) Posterior capsule opacification and neodymium: YAG capsulotomy with heparin-surface-modified intraocular lenses. *J.Cataract Refract.Surg.*, **24**, 940-944.
- Wolken,M.A. & Oetting,T.A. (2001) Linear posterior capsule opacification with the AcrySof intraocular lens. *J.Cataract Refract.Surg.*, **27**, 1889-1891.
- Wolter,J.R. (1985) Cytopathology of intraocular lens implantation. *Ophthalmology*, **92**, 135-142.
- Wolter,J.R. (1993) Continuous sheet of lens epithelium on an intraocular lens: pathological confirmation of specular microscopy. *J.Cataract Refract.Surg.*, **19**, 789-792.
- Wolter,J.R. & Kleberger,E. (1985) Surface reaction on a posterior chamber lens seven days after implantation. *J.Am.Intraocul.Implant.Soc.*, **11**, 599-602.
- Wolter,J.R. & Kunkel,S.L. (1983a) Adherence of mouse macrophages to plastic lens implants--resulting in the formation of a cellular membrane. *Ophthalmic Surg.*, **14**, 823-827.
- Wolter,J.R. & Kunkel,S.L. (1983b) Cellular membranes on glass lens implants--formed in tissue culture by mouse macrophages. *Ophthalmic Surg.*, **14**, 834-838.
- Wolter,J.R. & Kunkel,S.L. (1983c) Formation of proteinaceous capsules on plastic lens implants--by mouse macrophages under tissue culture conditions. *Ophthalmic Surg.*, **14**, 828-833.

- Wolter, J.R., Sugar, A., & Meyer, R.F. (1985) Reactive membranes on posterior chamber lens implants. *Ophthalmic Surg.*, **16**, 699-702.
- Wong, T.T., Daniels, J.T., Crowston, J.G., & Khaw, P.T. (2004) MMP inhibition prevents human lens epithelial cell migration and contraction of the lens capsule. *Br.J.Ophthalmol.*, **88**, 868-872.
- Wormstone, I.M. (2002) Posterior capsule opacification: a cell biological perspective. *Exp.Eye Res.*, **74**, 337-347.
- Wormstone, I.M., Liu, C.S., Rakic, J.M., Marcantonio, J.M., Vrensen, G.F., & Duncan, G. (1997) Human lens epithelial cell proliferation in a protein-free medium. *Invest Ophthalmol. Vis.Sci.*, **38**, 396-404.
- Wormstone, I.M., Rio-Tsonis, K., McMahon, G., Tamiya, S., Davies, P.D., Marcantonio, J.M., & Duncan, G. (2001) FGF: an autocrine regulator of human lens cell growth independent of added stimuli. *Invest Ophthalmol. Vis.Sci.*, **42**, 1305-1311.
- Wormstone, I.M., Tamiya, S., Anderson, I., & Duncan, G. (2002) TGF-beta2-induced matrix modification and cell transdifferentiation in the human lens capsular bag. *Invest Ophthalmol. Vis.Sci.*, **43**, 2301-2308.
- Xie, L., Sun, J., & Yao, Z. (2003) Heparin drug delivery system for prevention of posterior capsular opacification in rabbit eyes. *Graefes Arch. Clin. Exp. Ophthalmol.*, **241**, 309-313.
- Yamada, K., Nagamoto, T., Yozawa, H., Kato, K., Kurosaka, D., Miyajima, H.B., & Kimura, C. (1995) Effect of intraocular lens design on posterior capsule opacification after continuous curvilinear capsulorhexis. *J.Cataract Refract.Surg.*, **21**, 697-700.
- Yeh, P.C., Goins, K.M., & Lai, W.W. (2002) Managing anterior capsule contraction by mechanical widening with vitrector-cut capsulotomy. *J.Cataract Refract.Surg.*, **28**, 217-220.

- Zaczek,A. & Zetterstrom,C. (1998) Aqueous flare intensity after phacoemulsification in patients with diabetes mellitus. *J Cataract Refract Surg*, **24**, 1099-1104.
- Zaczek,A. & Zetterstrom,C. (1999) Posterior capsule opacification after phacoemulsification in patients with diabetes mellitus. *J.Cataract Refract.Surg.*, **25**, 233-237.
- Zambarakji,H.J., Rauz,S., Reynolds,A., Joshi,N., Simcock,P.R., & Kinnear,P.E. (1997) Capsulorhexis phymosis following uncomplicated phacoemulsification surgery. *Eye*, **11 (Pt 5)**, 635-638.
- Zaturinsky,B., Naveh,N., Saks,D., & Solomon,A.S. (1990) Prevention of posterior capsular opacification by cryolysis and the use of heparinized irrigating solution during extracapsular lens extraction in rabbits. *Ophthalmic Surg.*, **21**, 431-434.
- Zhang,X.H., Sun,H.M., & Yuan,J.Q. (2001) Extracellular matrix production of lens epithelial cells. *J.Cataract Refract.Surg.*, **27**, 1303-1309.
- Zheng,L., Merriam,J.C., & Zaider,M. (1997) Astigmatism and visual recovery after 'large incision' extracapsular cataract surgery and 'small' incisions for phakoemulsification. *Trans.Am.Ophthalmol Soc.*, **95**, 387-410.

