Reversible Sclerosing Cholangitis with Ulcerative Colitis

Keisuke Kakisaka [1)]

Kazuyuki Ishida [2)]

Kojiro Kataoka [1)]

Yuji Suzuki [1)]

Shunichi Yanai [3)]

Hidekatsu Kuroda [1)]

Tamotsu Sugai [2)]

Takayuki Matsumoto [3)]

Yasuhiro Takikawa [1)]

1) Division of Hepatology, Department of Internal Medicine,
Iwate Medical University,
Morioka, Japan

2) Department of Molecular Diagnostic Pathology,
Iwate Medical University,
Morioka, Japan

3) Division of Gastroenterology, Department of Internal Medicine,
Iwate Medical University,
Morioka, Japan

Address for correspondence: Keisuke Kakisaka, M.D., Ph.D.
School of Medicine
Iwate Medical University
19-1 Uchimaru Morioka
Iwate, JAPAN 0208505
Tel.: +81-19-651-5111
Fax: +81-19-652-6664
E-mail: keikaki@iwate-med.ac.jp

Running title: GEL positive sclerosing cholangitis

Number of:

Figures - 4

Table -1

References - 14

Word counts: 1286

Abstract

Sclerosing cholangitis (SC) with granulocytic epithelial lesion (GEL) responds well to immunosuppression therapy. We treated a 42-year-old Japanese female with ulcerative colitis, who was admitted for further evaluation of both an elevated alkaline phosphatase level and dilated intrahepatic bile ducts. A liver biopsy on the fourth hospital day revealed the infiltration of neutrophils into the bile duct epithelium, which was diagnosed as GEL. Because her ulcerative colitis was in an active stage, prednisolone (PSL) therapy was started. After the administration of PSL, laboratory data dramatically decreased.. A liver biopsy was performed on the 66th hospital day to confirm the lesion around bile ducts in the portal tract. The infiltration of neutrophils into the bile duct epithelium were disappearedafter PSL administration, and IgG4-positive plasma cells were not found in the liver. Herein, we report a rare case of GEL-positive SC. The present case provides early evidence of treatment-induced histological changes as well as serial changes in biochemical data during the course of immunosuppression therapy.

Key words: granulocytic epithelial lesion, GEL, PR3-ANCA, sclerosing cholangitis

Introduction:

Sclerosing cholangitis (SC) has several etiologies, such as bile duct stones, refractory infections, ischemia, and idiopathic cholangitis [1-3]. Idiopathic cholangitis is generally referred to as primary sclerosing cholangitis (PSC), a chronic, progressive disorder that is associated with a poor prognosis [2]. The recurrence rate of PSC after liver transplantation is highly related to the use of first-degree-relative donors, thus PSC is considered to be associated with autoimmune-associated disease as well as idiopathic disease [1, 2, 4, 5].

Recently, granulocytic epithelial lesion (GEL)-positive SC was reported to have similar histological findings to type 2 autoimmune pancreatitis (AIP) in the bile duct and an excellent response to steroid therapy [6]. GEL-positive cholangitis and type 2 AIP have rarely been reported in Japan [7]. Herein, we present the case of a 42-year-old Japanese female who was diagnosed with GEL-positive cholangitis and concomitant ulcerative colitis (UC).

Clinical summary:

A 42-year-old Japanese female was referred to our institute for evaluation of high serum alkaline phosphatase (ALP) level (2,280 IU/L) and slight increases in serum transaminases, including alanine aminotransferase (ALT) (Table 1). Abdominal CT, magnetic resonance cholangiopancreatography (MRCP), and ultrasound revealed beading of the intrahepatic bile duct without evidence of bile duct stones or pancreatitis (Figure 1A). Since the patient had been suffering from mild diarrhea during the preceding two months, we next performed a colonoscopy and found that the patient had

UC of the total colitis type. Activity of UC in the present case was evaluated by the Mayo scoring system, which resulted in a score of 4. Because these clinical findings strongly suggested SC, a liver biopsy was performed. The liver specimen suggested SC, although the patient did not have any evidence of PSC, IgG4-related disease, or other autoimmune diseases. We first treated the patient by oral 5-aminosalicylic acid. However, her diarrhea remained either unchanged or worsened over the course of treatment. We thus chose to treat the patient by oral prednisolone (PSL; 1 mg/kg/day), which resulted in the prompt resolution of symptoms. Furthermore, her serum ALP and ALT levels returned to their normal ranges within 10 days (Figure 2). MRCP on the 62nd hospital day revealed improved bile duct stenosis (Figure 1B). However, colonoscopy at that time revealed that the patient had mildly active UC. There was no evidence of severe bile duct stenosis in MRCP on the 600th day post-admission, although colonoscopy at that time revealed that the patient had active UC. Sustained normalization of both ALT and ALP levels was observed 2 years after admission.

Pathological findings:

To further evaluate the irregularly dilated intrahepatic bile duct, a liver biopsy was performed on the fourth hospital day. Histologically, the portal tracts expanded progressively with fibrosis and had mild to moderate inflammatory cell infiltration (Figure 3A, 3B, and 3C). Interface hepatitis was focal. The interlobular bile ducts showed an irregular configuration with partly attenuated epithelium and intra-epithelial neutrophils, which is consistent with GEL. The affected bile ducts were surrounded by loose connective tissue. The background infiltrate contained many lymphocytes, plasma

cells, and scattered neutrophils and eosinophils (Figure 3D and 3E). Immunohistochemically, numerous CD38-positive plasma cells were observed in the portal area, but there were few IgG4-positive cells (Figure 3F and 3G). Steatosis was observed in hepatocytes, however, lobular inflammation was mild. Based on these results, we diagnosed the patient as having GEL-positive SC with complicating UC. For confirmation about regarding response to PSL administration in the liver, a liver biopsy was performed on the 66th hospital day. Repeated liver biopsy revealed that portal fibrosis and inflammation had improved; furthermore, GELs had completely disappeared (Figure 4A, 4B, and 4C). The observation of steatosis was unchanged.

Discussion:

PSC is associated with an elevation of ALP and signature imaging findings, such as segmental dilatation of the bile ducts alternating with stenotic or obliterated segments[2]. Because PSC in most patients is complicated by inflammatory bowel disease, the differential diagnosis of the present case was PSC [2, 8]. However, both ALP levels and infiltration of neutrophils into the bile duct epithelium improved after PSL administration for the treatment of UC. Furthermore, the histological findings in the liver, which showed GEL, were not typical findings of PSC. We therefore hypothesized that the patient had GEL-positive SC.

The infiltration of neutrophils in the pancreatic duct that define GEL has frequently been reported in patients with type 2 AIP [7, 9-11]. Recently, Grammatikopoulos et al. reported a pediatric case of steroid-responsive autoimmune sclerosing cholangitis

(ASC) with GELs at the bile ducts, which suggested the existence of autoimmune cholangitis with GEL [6]. Based on this hypothesis, Portmann et al. retrospectively analyzed a large number of patients with ASC or PSC, and found that 4 of 103 children with ASC and 1 of 142 adults with PSC had GELs in the bile ducts [12]. According to these results, the prevalence of GEL-positive cholangitis in adults was 0.7%. The present case is also considered an adult case of GEL-positive SC. Although it is difficult to define "autoimmune" regarding our diagnosis, positive results for both ANA and PR3-ANCA in this case suggests that an autoimmune mechanism might be implicated in the cholangitis along with type 2 AIP [1, 13, 14]. All of the patients with GEL-positive SC in the previous reports were male. In contrast, the present case was a female, however, whether gender differences exist in this disease remains unclear. Importantly, liver tissue samples from these patients did not show increased IgG4-positive plasma cells, and all patients went into remission following treatment using PSL and/or ursodeoxycholic acid [12]. Based on these histological findings and responses to therapy, this disease should be distinguished from IgG4-related ASC and PSC to ensure that patients receive the proper treatment.

GEL-positive SC was improved by PSL therapy. In contrast, the efficacy of PSL has not been demonstrated in patients with PSC. As mentioned above, both diseases present similar clinical findings, such as complication with UC, an elevation of bile tract enzymes, and an irregular bile duct in imaging examinations. The histological finding of GELs is the only distinction between the diseases. Although the prevalence of GEL-positive SC is thought to be quite low, an awareness and accurate diagnosis of this

disease is important for the prognosis of PSL therapy. Here, we report the case of a patient with UC who presented with GEL-positive SC, where PSL administration drastically improved both abnormal levels of ALP and the presence of GELs. To ensure that patients receive proper treatment and improve patient care, the disease concept of SC with GEL should be widely adapted and recognized by clinicians.

Acknowledgements:

None of the authors who took part in this study have any conflicts of interest to declare regarding funding from any industry. This study was supported by KAKENHI Grant Number 16K21307 to KK and 16K08655 to KI. We thank Koko Motodate for providing excellent secretarial support and Shuhei Oana and Sho Shibata for the patient's care.

Authors' contribution:

The first two authors, KK and KI, contributed equally to this work.

Abbreviations: autoimmune sclerosing cholangitis (ASC), Anti-nucleus antibody (ANA), autoimmune pancreatitis (AIP), alkaline phosphatase (ALP), computed tomography (CT), granulocytic epithelial lesion (GEL), magnetic resonance cholangiopancreatography (MRCP), proteinase 3 anti-neutrophil cytoplasmic antibody (PR3-ANCA), primary sclerosing cholangitis (PSC),prednisolone (PSL), sclerosing cholangitis (SC), ulcerative colitis (UC).

CONSENT

Written informed consent was obtained from the patient for the publication of this case report and any accompanying images. A copy of the written consent form is available for review from the Editor of this journal.

Conflict of interest

The authors declare that they have no competing interests.

Reference

1 Hov JR, Boberg KM, Karlsen TH. Autoantibodies in primary sclerosing cholangitis. *World J Gastroenterol*. 2008; **14**: 3781-91.

2 Eaton JE, Talwalkar JA, Lazaridis KN, Gores GJ, Lindor KD. Pathogenesis of primary sclerosing cholangitis and advances in diagnosis and management. *Gastroenterology*. 2013; **145**: 521-36.

3 Imam MH, Talwalkar JA, Lindor KD. Secondary sclerosing cholangitis: pathogenesis, diagnosis, and management. *Clin Liver Dis*. 2013; **17**: 269-77.

4 Egawa H, Ueda Y, Ichida T, *et al.* Risk factors for recurrence of primary sclerosing cholangitis after living donor liver transplantation in Japanese registry. *Am J Transplant*. 2011; **11**: 518-27.

5 Fosby B, Karlsen TH, Melum E. Recurrence and rejection in liver transplantation for primary sclerosing cholangitis. *World J Gastroenterol*. 2012; **18**: 1-15.

6 Grammatikopoulos T, Zen Y, Portmann B, *et al.* Steroid-responsive autoimmune sclerosing cholangitis with liver granulocytic epithelial lesions. *J Pediatr Gastroenterol Nutr*. 2013; **56**: e3-4.

7 Okazaki K, Uchida K, Koyabu M, Miyoshi H, Takaoka M. Recent advances in the concept and diagnosis of autoimmune pancreatitis and IgG4-related disease. *J Gastroenterol*. 2011; **46**: 277-88.

8 Rojas-Feria M, Castro M, Suarez E, Ampuero J, Romero-Gomez M. Hepatobiliary manifestations in inflammatory bowel disease: the gut, the drugs and the liver. *World J Gastroenterol*. 2013; **19**: 7327-40.

9 Nishino T, Oyama H, Hashimoto E, *et al.* Clinicopathological differentiation between sclerosing cholangitis with autoimmune pancreatitis and primary sclerosing cholangitis. *J Gastroenterol*. 2007; **42**: 550-9.

10 Zen Y, Nakanuma Y, Portmann B. Immunoglobulin G4-related sclerosing cholangitis: pathologic features and histologic mimics. *Semin Diagn Pathol*. 2012; **29**: 205-11.

11 Buijs J, Maillette de Buy Wenniger L, van Leenders G, *et al.* Immunoglobulin G4-related prostatitis: a case-control study focusing on clinical and pathologic characteristics. *Urology*. 2014; **83**: 521-6.

12 Zen Y, Grammatikopoulos T, Heneghan MA, Vergani D, Mieli-Vergani G, Portmann BC. Sclerosing cholangitis with granulocytic epithelial lesion: a benign form of sclerosing cholangiopathy. *Am J Surg Pathol*. 2012; **36**: 1555-61.

13 Terjung B, Sohne J, Lechtenberg B, *et al.* p-ANCAs in autoimmune liver disorders recognise human beta-tubulin isotype 5 and cross-react with microbial protein FtsZ. *Gut*. 2010; **59**: 808-16.

14 Harada K, Nakanuma Y. Innate immunity in the pathogenesis of cholangiopathy: a recent update. *Inflamm Allergy Drug Targets*. 2012; **11**: 478-83.

Table 1. The laboratory data of the present patient in the admission.

Blood chemistry			Virus markers			ALP isoenzyme		
TP	6.5	g/dL	HBsAg	(-)		ALP1	24	%
Albumin	2.1	g/dL	HCVAb	(-)		ALP2	73	%
T-Bil	0.5	mg/dL	IgM HA	(-)		ALP3	3	%
AST	36	IU/L	HSV IgM	(-)		ALP2+3	(-)	
ALT	28	IU/L	HSV IgG	(+)		ALP3+4	(-)	
ALP	2280	IU/L	CMV IgM	(-)		ALP5	(-)	
g-GTP	378	IU/L	CMV IgG	(+)				
BUN	8.9	mg/dL	EBVCA IgA	(-)		IgG Subclass		
Cre	0.39	mg/dL	EBVCA IgM	(-)		IgG1	1690	mg/dL
IgG	2726	mg/dL	EBNA Ab	(+)		IgG2	638	mg/dL
IgM	127	mg/dL				IgG3	80.7	mg/dL
CRP	2.56	mg/dL	Autoantibodies			IgG4	55.2	mg/dL
			ANA	x40				
Hematology			AMA	(-)		HLA		
WBC	6.72	10^3/mL	PR3-ANCA	29.8	EU	A	A11	A26
Neutro	66.9	%	MPO-ANCA	<1.0	EU	B	B51	B56
Lympho	17.4	%				DR	DR12	DR15
Mono	9.1	%	Tumor markers					
Eosino	4.6	%	CEA	2.1	ng/mL			
RBC	291	10^6/mL	AFP	0.9	ng/mL			
Hb	6.7	g/dL	PIVKA-2	20	mAU/mL			
Plt	814	10^3/mL						
			FBS	81	mg/dL			
Blood coagulation			HbA1c	4.2	%			
PT-INR	1.37							
APTT-R	1.08							
Fib	427	mg/dL						
DD	1.8	mg/mL						

WBC, white blood cells; RBC, red blood cells; Hb, hemoglobin; Plt, platelets; TP, total protein; T-Bil., total bilirubin; AST, aspartate aminotransferase; ALT, alanine aminotransferase; ALP, alkaline phosphatase; γ-GTP, γ-glutamyl transpeptidase; ChE,

choline esterase; BUN, blood urea nitrogen; Cre, creatinine; AMY, amylase; CRP, C-reactive protein; PT, prothrombin time; HPT, hepaplastin test; Fib, fibrinogen; FDP, fibrin degradation products; Ig, immunoglobulin; Ab, antibody; Ag, antigen; HB, hepatitis B virus; HCV, hepatitis C virus; HA, hepatitis A virus; HSV, herpes simplex virus; CMV, cytomegalovirus; EB, Epstein–Barr virus; ANA, anti-nuclear antibody; AMA, anti-mitochondrial antibody; CEA, carcinoembryonic antigen; CA19-9, carbohydrate antigen 19-9; AFP, α-fetoprotein; PIVKA-II, protein induced by vitamin K absence/antagonist-II.

FIGURE LEGENDS

Figure 1. Magnetic resonance cholangiopancreatography (MRCP) findings on the 7th and 62nd hospital days. A: MRCP performed on the 7th hospital day found diffuse stenosis of intrahepatic bile ducts. B: MRCP performed on the 62nd hospital day found that the beading of the bile ducts that was observed on the 7th hospital day had disappeared.

Figure 2. **Time course of the patient's laboratory data.** The line chart presents the change in alanine aminotransferase (ALT) and alkaline phosphatase (ALP) levels. The triangles at the top of the line chart indicate the time point of each examination, such as colonoscopy (CS), liver biopsy (Liver Bx), magnetic resonance cholangiopancreatography (MRCP), and computed tomography (CT). The bar chart indicates the duration of each medication.

Figure 3. Histological findings of the liver on the 4th hospital day (A and C to E, hematoxylin and eosin-stained section; B, elastica Masson-stained section; F, CD38; G, IgG4; A and B, 40x; C, F, and G, 200x; D and E, 400x). The portal tracts expanded progressively with fibrosis (A and B) and had mild to moderate inflammatory cell infiltration without marked interface hepatitis (C). The interlobular bile ducts showed irregular configuration with partly attenuated epithelium and intra-epithelial neutrophils [granulocytic epithelial lesion (GEL)]. The triangles indicate GELs. The background infiltrate contained many lymphocytes, plasma cells, and scattered neutrophils and eosinophils (D and E). Immunoreactivity of CD38 with plasma cells was observed in the portal area (F), however, IgG4 was immunohistochemically

negative (G).

Figure 4. Histological findings of the liver on the 66th hospital day (A and C, hematoxylin and eosin-stained section; B, Elastica-Masson-stained section; A and B, 40x; C, 200x). The portal fibrosis was mild without scarring. Steatosis was shown in the periportal hepatocytes (A and B). There was little inflammation and no GEL in the portal tract (C).

Figure 1

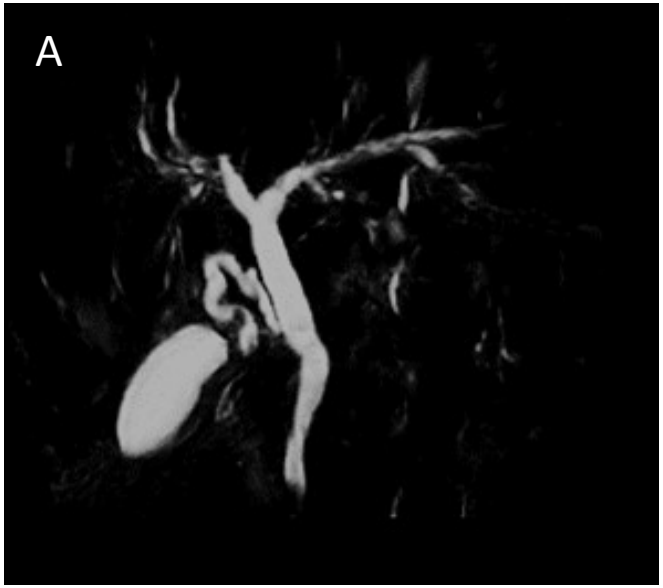

The 7th hospital day

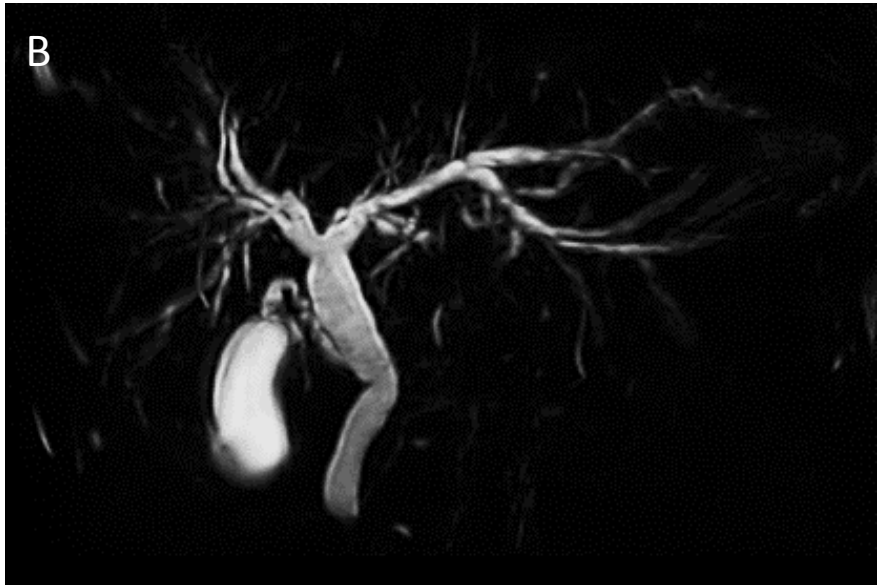

The 62nd hospital day

Figure 2

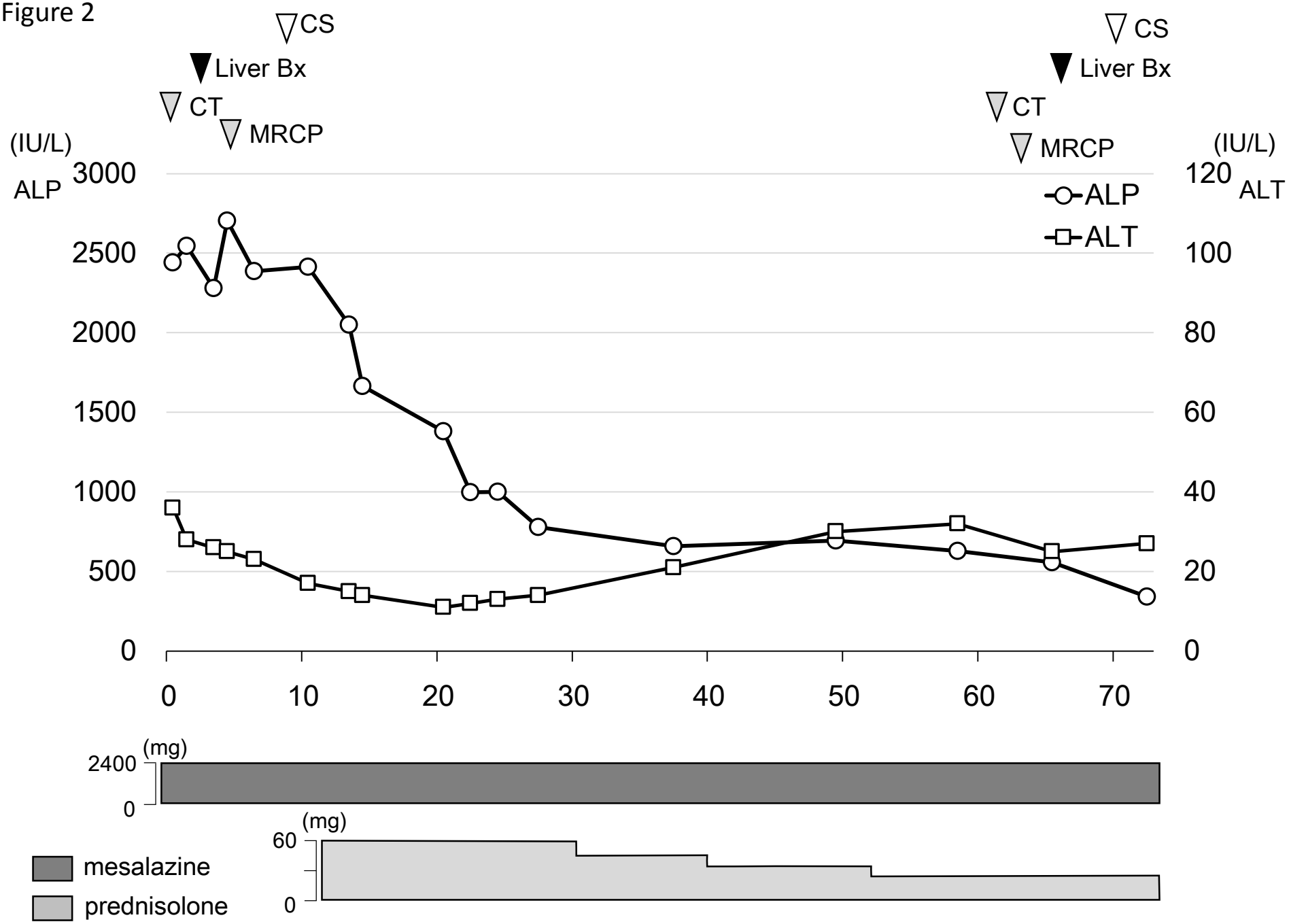
CS
Liver Bx
CT
MRCP
CS
Liver Bx
CT
MRCP
(IU/L)
ALP
3000
2500
2000
1500
1000
500
0
(IU/L)
ALT
120
100
80
60
40
20
0
ALP
ALT
0
10
20
30
40
50
60
70
(mg)
2400
0
(mg)
60
0
mesalazine
prednisolone

Figure 3

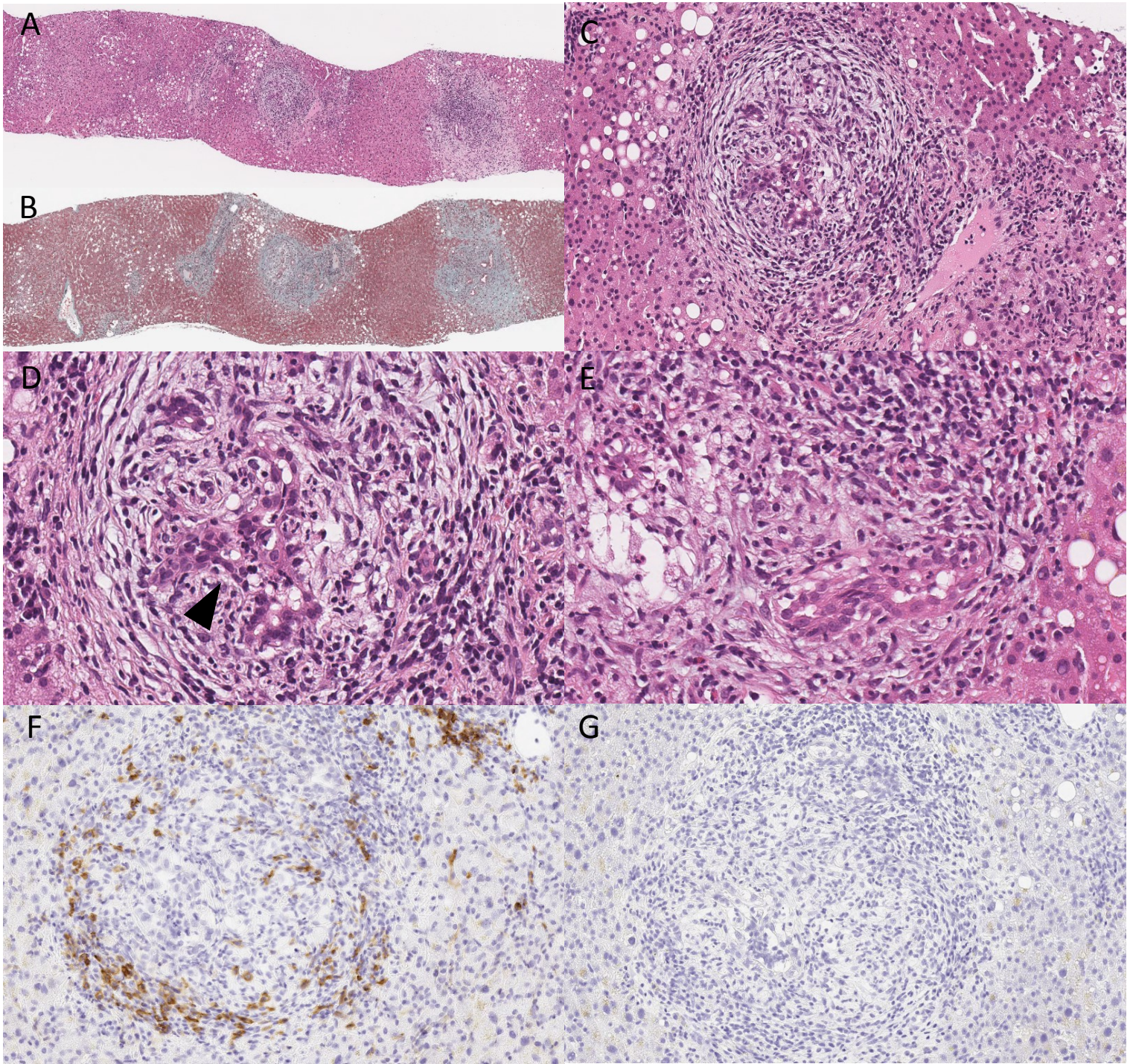

Figure 4

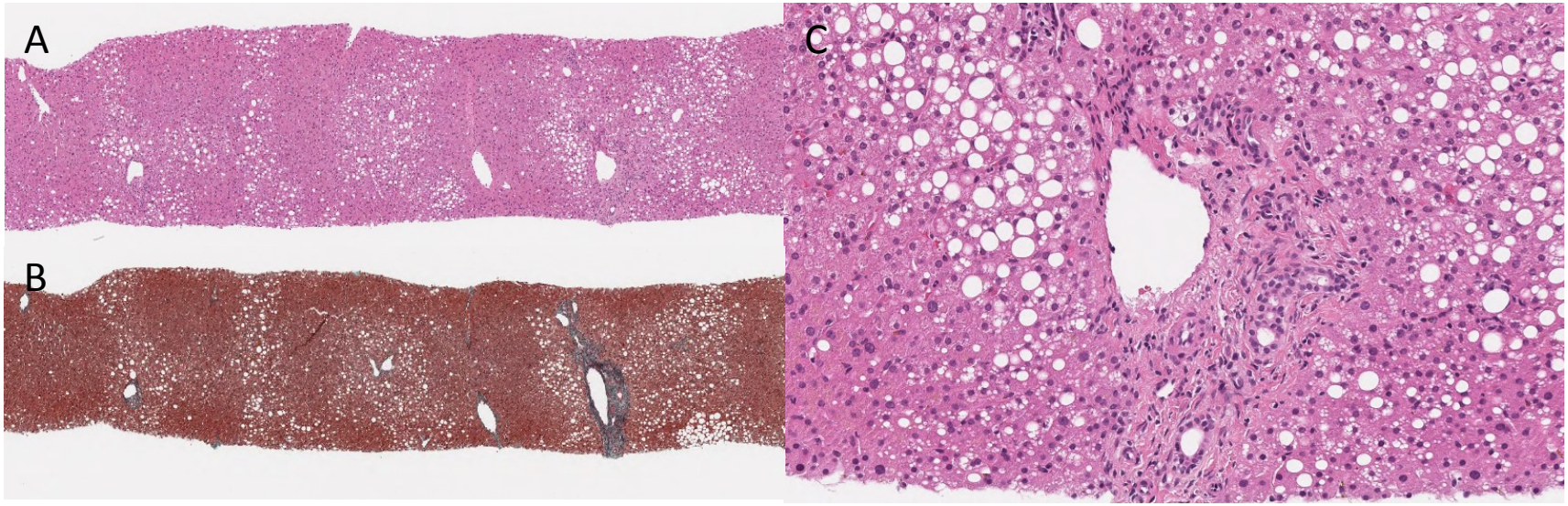

Table 1

Blood chemistry		
TP	6.5	g/dL
Albumin	2.1	g/dL
T-Bil	0.5	mg/dL
AST	36	IU/L
ALT	28	IU/L
ALP	2280	IU/L
γ–GTP	378	IU/L
BUN	8.9	mg/dL
Cre	0.39	mg/dL
IgG	2726	mg/dL
IgM	127	mg/dL
CRP	2.56	mg/dL

Hematology		
WBC	6.72	$10^3/\mu L$
Neutro	66.9	%
Lympho	17.4	%
Mono	9.1	%
Eosino	4.6	%
RBC	291	$10^6/\mu L$
Hb	6.7	g/dL
Plt	814	$10^3/\mu L$

Blood coagulation		
PT-INR	1.37	
APTT-R	1.08	
Fib	427	mg/dL
DD	1.8	μg/mL

Virus markers		
HBsAg	(-)	
HCVAb	(-)	
IgM HA	(-)	
HSV IgM	(-)	
HSV IgG	(+)	
CMV IgM	(-)	
CMV IgG	(+)	
EBVCA IgA	(-)	
EBVCA IgM	(-)	
EBNA Ab	(+)	
Autoantibodies		
ANA	x40	
AMA	(-)	
PR3-ANCA	29.8	EU
MPO-ANCA	<1.0	EU
Tumor markers		
CEA	2.1	ng/mL
AFP	0.9	ng/mL
PIVKA-2	20	mAU/mL
FBS	81	mg/dL
HbA1c	4.2	%

ALP isoenzyme		
ALP1	24	%
ALP2	73	%
ALP3	3	%
ALP2+3	(-)	
ALP3+4	(-)	
ALP5	(-)	

IgG Subclass		
IgG1	1690	mg/dL
IgG2	638	mg/dL
IgG3	80.7	mg/dL
IgG4	55.2	mg/dL

HLA		
A	A11	A26
B	B51	B56
DR	DR12	DR15