

# Bright Lesion Detection in Color Fundus Images Based on Texture Features

Ratna Bhargavi V<sup>\*1</sup>, Ranjan K. Senapati<sup>2</sup>

Department of Electronics and Communication Engineering,

K L University, Vaddeswaram, Guntur-522502, Andhra Pradesh, India

\*Corresponding author, e-mail: bhargavi6464@kluniversity.in<sup>1</sup>, ranjan.senapati@kluniversity.in<sup>2</sup>

## Abstract

*In this paper a computer aided screening system for the detection of bright lesions or exudates using color fundus images is proposed. The proposed screening system is used to identify the suspicious regions for bright lesions. A texture feature extraction method is also demonstrated to describe the characteristics of region of interest. In final stage the normal and abnormal images are classified using Support vector machine classifier. Our proposed system obtained the effective detection performance compared to some of the state-of-art methods.*

**Keywords:** Computer aided screening, feature extraction, classification, segmentation, Diabetic retinopathy

## 1. Introduction

Diabetic retinopathy (DR) is the leading cause of blindness and it is the diabetic eye disease. According to International diabetes federation (IDF) now people are having diabetes is about 387 million worldwide and it will be increased to 592 million by 2035. IDF declared that 52% of Indians do not know about diabetes that they are suffering with high blood sugar. In rural India around 34 million people effected with diabetes compared to urban Indians around 28 million people [1].

Due to the damage of the vessels of the retina this disease will occur. Blood vessels may swell and fluid leakage will happen. So that pathologies will occur. The pathologies in the early stage should be recognized to prevent blindness. For this purpose Computer aided detection (CADE) system will help as a second opinion for early diagnosis. Now some of diabeticians are also using fundus camera to analyze the color fundus images by screening diabetic retinopathy for lesions. This avoids vision loss in diabetes attacked patients. A physician and CADE system will do the same task, i.e., the identification of lesions from fundus images. But system software tool will identify and mark the suspicious regions for physician review. To raise the accuracy of diagnosis, CADE systems are developed to help the physicians or diabeticians as assistants for the recognition of lesions.

Bright lesions or exudates are the pathologies which appear bright yellow or white color with varying sizes and shapes. So the yellow color patches should be identified in the early stage to prevent the number of blindness. A numerous techniques are developed for pathologies detection. Exudates are one of the earliest signs of diabetic retinopathy. Sinthanayothin *et.al.* [2] proposed Recursive Region-Growing Segmentation (RRGS) and thresholding algorithms. This give rise to sensitivity and specificity of 88.5%, and 99.7% respectively. Jaya kumari C and Santhanam T [3] implemented contextual clustering and they used features such as convex area, solidity, orientation for classification. They reported sensitivity and specificity of 93.4%, 80% respectively. Welfer *et al.* [4] proposed morphological and thresholding techniques for lesion detection and they obtained sensitivity and specificity of 70.5% and 98.8% respectively. Pan Lin *et al.* [5] proposed an automated technique for exudates segmentation and it is based on Fuzzy c-means clustering algorithm. The obtained sensitivity and specificity are 84.8% and 87.5% respectively. Kittipol *et al.* [6] proposed the moving average histogram model, and exact locations of exudates are marked by sobel and Otsu's thresholding. The obtained area under curve (AUC) is 93.69%. M. Esmaeili *et.al.* [7] recently

proposed exudates detection by using digital curvelet transform and they used to change the coefficients of curvelets and level segmentation. The obtained sensitivity and specificity are 98.4% and 90.1% respectively. Anderson *et.al.* [8] proposed lesions identification in visual words and the AUC is 95.3%. Agurto *et.al.* [9] proposed multi-scale optimization approach for lesion detection. It uses AM-FM representations, where partial least square method has applied for classification in normal and abnormal images. Recently, Luca *et.al.* [10] proposed bright lesion detection based on the probability maps, color, and wavelet analysis. The AUC obtained is around 0.88 to 0.94. Ramon pires *et.al.* [11] proposed soft assignment coding/max pooling for exudates detection; and for feature extraction Speeded up robust feature extraction (SURF) algorithm is implemented. The reported AUC is 93.4%. Harangi *et.al.* [12] proposed multiple active contour technique for lesion detection and region wise classification is done for distinguishing the normal and abnormal images. The sensitivity, specificity and AUC are 92.1%, 68.4%, and 0.82 respectively. For the detection of lesions, motion patterns are created for region of interest in color fundus images by K. Deepak and J. Sivaswamy [13]. For feature extraction Radon transform is used. The sensitivity and specificity are reported to be 100% and 74% respectively. A. Pachiyappan *et.al.* [14] proposed morphological dilation, closing, filling, and threshold criteria for bright lesion detection. This give rise to an accuracy about 97.7%. Sohini *et al.* [15-16] proposed a novel technique based on maximum solidity and minimum intensity for lesion detection. Lesion classified based on hierarchical classification. The obtained sensitivity and specificity are 100% and 53.16% respectively. S. Ravishankar *et.al.* [7] proposed localization of lesions, based on color properties, intensity variations and morphological operations. They obtained sensitivity and specificity are 95.7% and 94.2% respectively. Van Grinsven *et.al.* [18] proposed a bag of visual words approach to characterize the fundus image. They implemented decomposition of image as patches. From each image patch, various features are extracted and classification was done based on weighed nearest neighbor method. The resulted AUC is 0.90.

In this paper we have made use novel combination of the existing techniques in order to achieve better sensitivity, specificity and accuracy than the previously used techniques. In our proposed method, the bilateral filtering step is applied as a preprocessing step, because fundus images in datasets are having noise and they are poorly illuminated. Contrast enhancement is done to increase the contrast between foreground with exudates and background elements like optic disk (OD) and vessels. The anatomical structures of OD and vessels are extracted and eliminated for visualization of lesions clearly. The remaining foreground lesions are segmented. In order to characterize the segmented lesions, texture features are calculated. Finally support vector machine classifier (SVM) is used to distinguish the lesions and non-lesions images.

The rest of the paper is as follows. Section-2 describes pre-processing, detection of Optic disk, vessels, identification of lesion parts, feature extraction and then classification. The analysis of obtained results is presented in Section-3. Finally, conclusions and future research directions are presented in Section-4.

## 2. Proposed Method

The proposed method is a four stage CADe system for lesion detection in color fundus images. The first stage comprises pre-processing and the next stage is segmentation of anatomical structures and pathological parts. The stage three is feature extraction and the final stage is classification. Figure 1 shows the block diagram of proposed technique and the following sections will give detailed explanation about each method.

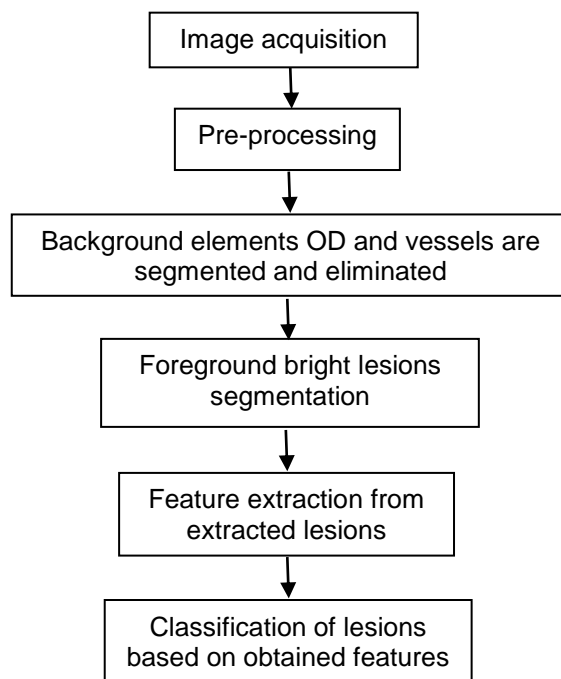


Figure 1. Block diagram of proposed CADe system for lesion detection

#### A. Image Pre-Processing

The pre-processing of fundus images reduces or removes the effects of noises, vessel parts and some patches visible like lesions. All images using here are preprocessed because images in datasets are often noisy and they are having poor illumination. First we extract green channel  $I_g$  so that exudates appear brighter in this channel compared to other channels. Now histogram equalization and contrast enhancement are applied on  $I_g$ . Then, contrast between foreground and background structures is increased and resulting  $I_{hist}$  shown in Figure 2(c). In order to remove unwanted some visible spots, noise, lines, obstacles, Bilateral filter (BF) [22-23] is used. Because it smoothens flat surfaces while preserving sharp edges in image by having same pixels placed in every neighborhood  $I_{bf}$ . This is shown in Figure 2(d).

#### B. Segmentation of Optic Disk and Vessels

In this stage first we extract the optic disk (OD) and main vessel parts. Then, these structures are masked out because there is higher order similarity in between bright lesions, OD vessel structures. Generally, OD and vessels are recognized as lesions by mistake. The OD structure is segmented using image dilation by having disk structuring element (10,4). The resulting binary image with OD is shown in Figure 2(e). The multi-scale hessian matrix shown in (1) is used to find the tubular structure. We have extracted the vessel structures using the same multi-scale hessian matrix.

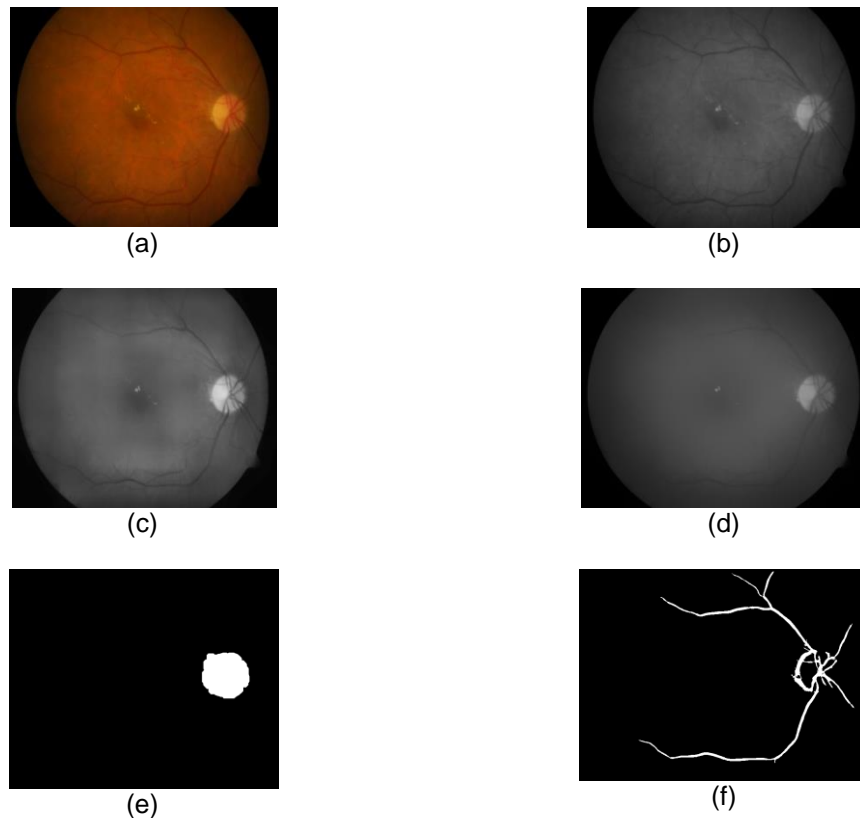


Figure 2. (a) Color fundus image (b) Green channel extracted image (c) Histogram equalized image (d) Bilateral filter applied image (e) Optic disk extracted image (f) Vessel extracted image based on Hessian matrix transform

$$H = \begin{bmatrix} \partial^2 I / \partial x^2 & \partial^2 I / \partial x \partial y \\ \partial^2 I / \partial y \partial x & \partial^2 I / \partial y^2 \end{bmatrix} \quad (1)$$

Where  $I$  is the pre-processed image. Second order partial derivative for the image  $I$  is done. We can have eigen values with following conditions for an ideal tubular structure.

$$\begin{aligned} |\lambda_1| &\approx 0 \\ |\lambda_1| &\ll |\lambda_2| \end{aligned}$$

The vessel function is given by  $V(I)$

$$V(I) = (|\lambda_1|/2) \cdot e^{b - |\lambda_1|/\sqrt{|\lambda_1 + \lambda_2|}} + (|\lambda_2|/2) \cdot e^{(|\lambda_2|/\sqrt{|\lambda_1 + \lambda_2|}) - b}$$

$V(I)$  is a function and its value gives the tubular structure for every pixel. The maximum function value  $V(I)$  corresponds to pixel value that stands for scale. The main vessel is having a large scale property. The extracted image  $I_M$  shown in Figure 2(f).

### C. Lesion Detection by Removing Opticdisk and Vessels

Now it is essential to remove the optic disk and main vessel parts. We are having the binary images with extracted optic disk  $I_{OD}$  and vessel structures  $I_M$  shown in Figure 2(e) and Figure 2(f). The elements of binary image with optic disk and the elements of binary image with vessel are subtracted from unity. Now in the resultant images, each element is multiplied with the illumination corrected image elements presented in (2) and (3). Then both the structures i.e., optic disk and main vessels are masked out. This is shown in Figure 3(a).

$$I_{M(OD)} = I_{illu} * (1 - ele(I_{OD})) \quad (2)$$

$$I_{M(V)} = I_{illu} * (1 - ele(I_M)) \quad (3)$$




Figure 3. (a) Masked out optic disk and vessels (b) Thresholded image (c) Lesion segmented image

After the masking of the optic disk and main vessel structures, lesion parts will be segmented by thresholding based on histogram. Canny edge detector [26] is applied to find the borders of the lesions based on thresholded image which contains exudates (see, Figure 3(b)). The contours of yellow color exudates are drawn in the illumination corrected fundus image based on intensity pixel values of thresholded image. This results in  $I_e$  shown in Figure 3(c).

#### D. Feature Extraction from Segmented Lesions

After the detection of suspicious regions of lesion parts, the feature extraction is done to characterize the lesions shown in Figure 3(c). Now we will find out the detected patches that are lesions or non lesions. The extracted features from the detected suspicious regions are shown in Table 1. In the detected suspicious regions we can consider 2x2 or 4x4 blocks. Mostly non-correlated feature values for normal and abnormal suspicious regions are shown in Table 2.

Table 1. Features extracted from ROI

No.	Feature
1	Total number of pixels in the ROI
2	Distance from centre of OD
3	Distance from vascular region
4	Minimum pixel intensity in $I_g$
5	Maximum pixel intensity in $I_g$
6	Mean pixel intensity in $I_g$
7	Skewness of ROI
8	Entropy of ROI
9	Standard deviation of ROI
10	Correlation coefficient in ROI block
11	Minimum correlation coefficient in ROI block
12	Maximum correlation coefficient in ROI block
13	Mean of pixel intensities in ROI block
14	Distance around the detected ROI
15	Variance of pixels for the detected ROI
16	Anisotropy for detected ROI
17	Maximum pixel intensity in ROI of $I_e$
18	Minimum pixel intensity in ROI of $I_e$
19	Sum of pixel intensities in ROI block of $I_e$
20	Distance from macular region in $I_e$

Table 2. Calculated Feature values

Feature values of detected ROIs of abnormal images	Feature values of detected ROIs of normal images
0.087	0.473
0.038	0.238
16	0.309
282	0.225
0.120	0.421
97	6
0.552	0.510
8.552	0.188
0.340	204
0.558	0.351
1.071	0.062
0.067	0.149
0.312	0.045
0.0227	0.084
0.175	0.287
0.153	0.270
0.097	5.396
0.028	88
0.164	0.247
0.107	0.126

### E. Classification

We have detected the structures with foreground and background and segmented the suspicious lesion regions. However, it is essential to classify whether the detected pathologies are true exudates or not. There are many methods available for the classification of data. In our work, we made use of support vector machine (SVM) classifier which is efficient for separating two different types of datasets. The SVM classifier uses a hyper plane to separate two datasets. The features are extracted from the segmented regions for lesion classification. Now by having the feature vectors  $f_1$  and  $f_2$  from suspicious regions of normal and abnormal images, we can train the classifier assigning class labels as  $y=+1$  or  $-1$ . During the testing of the classifier one feature vector  $f^*$  is adopted and it is tested by having the feature values. Finally, it will assign which class it belongs to i.e., whether  $+1$  or  $-1$ .

## 3. Experimental Results

### A. Dataset

The proposed CADe system is trained and tested by adopting two publicly available datasets for normal and diseased patients. DIARETDB1 [25] dataset is having total 89 images with  $50^\circ$  field of view. These images are separated into two groups for training and testing. MESSIDOR [24] dataset contains total 1200 images with  $45^\circ$  field of view. We have implemented our CAD screening system on these images.

The statistical measures used for analyzing the performance of CAD screening system defined in terms of True positives (TP), False positives (FP), True negatives (TN), False negatives (FN).

$$\text{Sensitivity (sen)} = \text{TP}/(\text{TP}+\text{FN})$$

$$\text{Specificity (spe)} = \text{TN}/(\text{TN}+\text{FP})$$

$$\text{Accuracy (acc)} = (\text{sen}+\text{spe})/2$$

Where, TP- Number of abnormal images correctly identified as abnormal.

TN-Number of normal images correctly identified as normal.

FP- Number of normal images incorrectly identified as abnormal.

FN- Number of abnormal images incorrectly identified as normal.

To know the diagnosis performance we have to measure the sen, spe, and acc parameters. Figure 4 shows the ROC curve. If an ROC curve shows  $\text{AUC}=1$ , then it is perfect

diagnosis, otherwise, if it shows 0.5, then it is worst case. In the proposed work have achieved AUC=0.966. The measure of accuracy is proportional to the AUC.

**B. Analysis of Classifier**

In this proposed system the used classifier is SVM. SVM is implemented in two datasets for classification of lesions and non lesions feature values which are shown in Table 2. By analyzing classifier, the false positives are got very less, and the TPs obtained are more than half of feature values taken. It is around 66.6%. Around 20 features are calculated and in stepwise (at a step of 5) features are considered for classification. The accuracy results are tabulated in Table 3. Finally our proposed system is compared with previous work done by several researchers on exudates detection. Accuracies of previous techniques are compared with proposed method and Table 4.

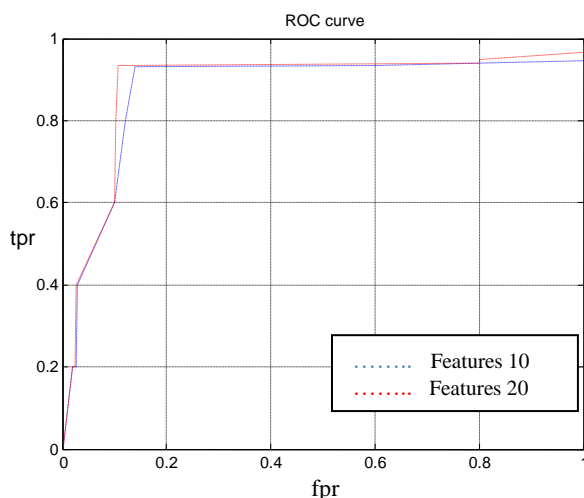


Figure 4. ROC curve for proposed system

Table 3. Feature values selected in stepwise for classification

Selected number of features	Sensitivity (%)	Specificity (%)	Accuracy (%)
05	95.03	94.67	94.85
10	95	90.1	92.55
15	95.03	100	95.32
20	100	94.6	96.66

Table 4. Comparison of performance of previous work done (%)

Technique	Year	Accuracy (%)
Sopharak [20]	2008	89.75
Sanchez [19]	2009	88.1
Pan Lin [5]	2012	86.15
Esmaili [7]	2012	94.25
Anderson [8]	2012	95.3
Luca [10]	2011	94.1
Ramon pires [11]	2013	93.4
Harangi [12]	2014	82.2
Sohini [16]	2014	95.35
Proposed method	2015	96.66

**4. Conclusion**

The proposed CADe system is a four stage detection system. Here around 20 features are obtained from lesion and non-lesion regions where feature values are calculated for classification. The AUC obtained is 0.966 and it out perform the methods proposed in the

literature. So, our screening system can be able to identify the lesions and it can be a better assistant for a diabetician or physician. In our work, 20 features show the satisfactory performance by segmenting the lesion areas. Future research direction is to implement a combination of classifiers which is expected to give better accuracy. Further, we would like to perform proposed method for other lesions like cottonwool spots, Microaneurysms and Haemorrhages.

## References

- [1] International Diabetes Federation. Public health foundation of India. Data from the 2013 fact sheet diabetes in India-Fact sheet. [Online]. available: <http://www.cadiresearch.org/topic/diabetes-indians/diabetes-urban-india>.
- [2] Sinthanayothin C, Boyce JF, Cook HL, Williamson TH. Automated Localization of the Optic Disc, Fovea, Retinal Blood Vessels From Digital Colour Fundus Images. *Br J Ophthalmology*. 1999; (83): 902–10.
- [3] Jayakumari C, Santhanam T. Detection of hard exudates for Diabetic Retinopathy Using Contextual Clustering and Fuzzy Art Neural Network. *Asian Journal of Information Techonology*. 2007; (8): 842-846.
- [4] D Welfer, J Scharcanski and DR Marinho. A coarse-to-fine strategy for automatically detecting exudates in color eye fundus images. *Computerized Medical Imaging and Graphics*. 2010; 34(3): 228-235.
- [5] PanLin, Zheng bingkun. "A effective approach to detect hard exudates in color retinal images". *Recent advances in information and computer science engineering lectures notes in electrical engineering*. 2012; 124: 541-546.
- [6] Kittipol, Nualsawat, Ekkarat,"Automatic detection of exudates in retinal images based on thresholding moving average models. *Biophysics*. 2015; 60(2): 288-297.
- [7] Esmaeli, Rabbani Dehnavi, Dehgani. "Automatic detection of exudates and optic disk in retinal images using curvelet transform". *IET image processing*. 2012: 1-9.
- [8] A Rocha, T Carvalho, HJelinek, S Goldenstein, and J Wainer. "Points of interest and visual dictionaries for automatic retinal lesion detection". *IEEE Trans. Biomed. Eng*. 2012; 59(8): 2244–2253.
- [9] C Agurto, V Murray, E Barriga, S Murillo, M Pattichis, H Davis, S Russell, M Abramoff, and P Soliz. "Multiscale AM-FM methods for diabetic retinopathy lesion detection". *IEEE Trans. Med. Imag*. 2010; 29(2): 502–512.
- [10] Luca Fabrice, Thomos, Seema garg, Kenneth, Edward. "Exudate-based diabetic macular edema detection in fundus images using publicly available datasets". *Medical image analysis*. 2012; 16: 216-226.
- [11] Ramon Pires, Herbert F Jelinek, Jacques Wainer, Siome Goldensteindo Valle, and Anderson Rocha. "Assessing the Need for Referral in Automatic Diabetic Retinopathy Detection". *IEEE Transactions on Bio-medical Engineering*. 2013; 60(12): 3391-3398.
- [12] Balazs Harangi, Andras Hajdu. "Automatic exudates detection by fusing multiple active contours and region wise classification". *Computers in biology and medicine*. 2014.
- [13] K Deepak and J Sivaswamy. "Automatic assessment of macular edema from color retinal images". *IEEE Trans. Med. Imag*. 2012; 31(3): 766–776.
- [14] Arulmozhivarman Pachiyappan, Undurti N Das, Tatavarti VSP Murthy and Rao Tatavar. "Automated diagnosis of diabetic retinopathy and glaucoma using fundus and OCT images". *Lipids in health and diseases*. 2012: 1-10.
- [15] S Roychowdhury, DD Koozekanani, and KK Parhi. "Screening fundus images for diabetic retinopathy". in *Proc. Conf. Record 46th Asilomar Conf. Signals, Syst. Comput*. 2012: 1641–1645.
- [16] Sohini, Keshabparhi, DD Koozekanani. "DREAM: Diabetic Retinopathy Analysis Using Machine Learning". *IEEE Journal of Bio-medical And Health Informatics*. 2014; 18(5).
- [17] S Ravishankar, A Jain, A Mittal. "Automated Feature Extraction for Early Detection of Diabetic Retinopathy in Fundus Images". *IEEE conference on Computer Vision and Pattern Recognition (CVPR 2009)*. 2009: 210-217.
- [18] MJJP Van Grinsven, A Chakravarty, J Sivaswamy, T Theelen, B van Ginneken, CI S´anchez. "A Bag Of Words Approach For Discriminating Between Retinal Images Containing Exudates or Drusen". *IEEE 10th International Symposium on Biomedical Imaging: From Nano to Macro San Francisco, CA, USA*. 2013.
- [19] CI Sánchez, R Hornero, MI López, M Aboy, J Poza and D Abásolo. "A novel automatic image



- processing algorithm for detection of hard exudates based on retinal image analysis". *Medical Engineering & Physics*. 2009; 30(3): 350-357.
- [20] A Sopharak, B Uyyanonvara, S Barman, and TH Williamson. "Automatic detection of diabetic retinopathy exudates from non-dilated retinal images using mathematical morphology methods". *Comput. Med. Imag. Graph.* 2008; 32(8): 720–727.
- [21] Jian Zheng, Pei-Rong Lu, Dehui Xiang, Ya-Kang Dai, Zhao-Bang Liu, Duo-Jie Kuai, Hui Xue, and Yue-Tao Yang. "Retinal Image Graph-Cut Segmentation Algorithm Using". *Multiscale Hessian-Enhancement-Based Nonlocal Mean Filter, Computational and Mathematical Methods in Medicine*, Article ID 927285. 2013: 1- 7.
- [22] E Eisemann and F Durand. "Flash photography enhancement via intrinsic relighting". *ACM Trans. Graph.* 2004; 23(3): 673–678.
- [23] G Petschnigg, R Szeliski, M Agrawala, M Cohen, H Hoppe, and K Toyama. "Digital photography with flash and no-flash image pairs". *ACM Trans. Graph.* 2004; 23(3): 664–672.
- [24] Methods to evaluate segmentation and indexing techniques in the field of retinal ophthalmology. (2011, Sep. 23). [Online]. Available: <http://messidor.crihan.fr/download-en.php>.
- [25] T Kauppi, V Kalesnykiene, JK Kmrinen, L Lensu, I Sorr, A Raninen, R Voutilainen, H Uusitalo, H Klviinen, and J Pietil. "Diaretdb1 diabetic retinopathy database and evaluation protocol". in *Proc. 11th Conf. Med. Image Understand. Anal.* 2007: 61–65.
- [26] J Canny. "Computational approach to edge detection". *IEEE Transactions on Pattern Analysis and Machine Intelligence*. 1986; 8(6): 679–698.