

# Brain abscesses in Malawian children: value of CT scan

L. MANKHAMBO\*, A. PHIRI\*, K. CHIWAYA\* & S. M. GRAHAM\*<sup>†</sup>

\**Malawi–Liverpool–Wellcome Trust Programme of Clinical Tropical Research and Department of Paediatrics, College of Medicine, Blantyre, Malawi and* <sup>†</sup>*The Liverpool School of Tropical Medicine, Liverpool, UK*

(Accepted November 2007)

**Abstract** The clinical presentation and management of brain abscess in three HIV-uninfected Malawian children are reported. One case was associated with staphylococcal empyema and severe malarial anaemia and another case with chronic suppurative otitis media and mastoiditis. The third case had no identified extracranial focus of infection. These cases illustrate the difficulties of diagnosis and management of brain abscesses in the resource-poor setting where other causes of encephalopathy caused by infection are common, and highlight the value of neuro-radiological imaging.

## Introduction

Brain abscess is relatively uncommon but is serious in children. Diagnosis can be difficult in the resource-poor setting where neuro-radiological imaging is often unavailable. For example, children presenting in a malaria-endemic area with altered mental state and seizures can be misdiagnosed as cerebral malaria.<sup>1</sup> The installation of a computerised tomography (CT) scanner at the Queen Elizabeth Central Hospital (QECH), Blantyre has improved diagnosis and management of acute encephalopathy in children. We report three cases of suppurative intracranial abscess in HIV-uninfected Malawian children presenting to QECH, Blantyre between January and July 2006.

## Case Reports

### Case 1

A boy aged 2 years 7 months presented with a 2-week history of fever, cough and lethargy

and worsening dyspnoea for 2 days. A week earlier, he had been admitted to a peripheral hospital for 4 days with the same complaints but continued to deteriorate and so his mother discharged him and brought him to QECH for assessment. Management at the peripheral hospital was unclear. There was no history of headache, seizures, vomiting or any other neurological symptom before admission. His past medical history revealed a previously well, fully immunised child (including BCG) with no known contact with tuberculosis (TB).

Clinical examination revealed a well nourished boy (weight 12 kg, weight-for-height >85%). He was comatose with a non-localising withdrawal response to painful stimuli only. He was pale, febrile (temperature 38.3°C) and tachycardic (pulse rate 160 bpm) with normal blood pressure (80/60 mmHg). He had severe respiratory distress with tachypnoea (respiratory rate 60 bpm), grunting, nasal flaring and subcostal indrawing. He was not cyanosed but was hypoxic with oxygen saturation of 79% in air. Chest examination revealed reduced air entry and bronchial

Reprint requests to: Dr S. M. Graham, MLW Clinical Research Programme, PO Box 30096, Blantyre 3, Malawi. E-mail: [sgraham@mlw.medcol.mw](mailto:sgraham@mlw.medcol.mw)

breathing on the right side. Abdominal examination demonstrated enlargement of the liver and spleen by 6 cm each. The remainder of the examination was unremarkable. There were no focal neurological signs. Pupillary size and reaction were normal, as was fundal examination. Cardiac examination was normal.

Initial investigations revealed hypoglycaemia (blood glucose 2.6 mmol/L), which was corrected with a bolus of intravenous dextrose, and elevated serum lactate (15.2 mmol/L). A thick blood film for malaria showed 1–10 asexual *Plasmodium falciparum* per high-powered film, and packed cell volume (PCV) was 13%. Lumbar puncture was traumatic and the cerebral spinal fluid (CSF) showed a white cell count of  $5 \times 10^6$ /L, red cell count of  $1600 \times 10^6$ /L, protein 0.30 g/L and glucose 5.5 mmol/L. Blood culture was performed and a chest radiograph was planned for when he was stable.

The initial diagnoses were pneumonia and severe malarial anaemia. He was commenced on parenteral chloramphenicol 25 mg/kg/6-hourly, a loading dose of quinine (20 mg/kg i.v.), oxygen by nasal prongs and was transfused with whole blood (20 ml/kg) 1 hour later; 5 hours later he deteriorated and became unresponsive with brisk deep tendon reflexes, a fixed upward gaze, acidotic breathing and hypoglycaemia. He was given dextrose (2.5 ml/kg of 10% dextrose i.v.), and parenteral gentamicin (6 mg/kg/day) was added. There was considerable improvement by day 3 when he was fully conscious and eating and PCV was 26%. No malaria parasites were detected on peripheral blood film. HIV test was negative and CSF culture was sterile. He was still febrile (axillary temperature 38°C) with chest signs consistent with pneumonia and a chest radiograph on day 4 showed diffuse opacification of the right lung. Chloramphenicol was stopped and i.v. cefuroxime (50 mg/kg/12-hourly) commenced. *Staphylococcus aureus* resistant to penicillin and chloramphenicol but sensitive

to gentamicin, erythromycin, tetracycline and cotrimoxazole was isolated from the blood culture on day 4. He was still sick and febrile with increasing respiratory distress and had developed dullness on percussion over the right chest. Chest ultrasonography showed a 4-cm effusion in the right chest and pleural aspirate demonstrated an empyema. Cloxacillin (25 mg/kg/6-hourly) was added. He was scheduled for an intrathoracic chest drain the following morning.

That night, however, his condition deteriorated. He had repeated generalised seizures and became comatose. A random blood glucose was normal. Oxygen and paraldehyde were administered and the seizures ceased. Ceftriaxone (100 mg/kg/day i.v.) was added to the cloxacillin and gentamicin and cefuroxime were stopped. A chest drain was inserted which drained 400 ml of thick pus. The pleural fluid also grew *Staphylococcal aureus*. Cloxacillin was continued, as was ceftriaxone, because septicaemia and focal disease owing to non-typhoidal salmonella are recognised as common complications in Malawian children with severe malarial anaemia.

The patient remained comatose with only a withdrawal response to painful stimuli. The possibility of either an intracranial abscess or encephalopathy secondary to septicaemia and hypoxia was considered. Cranial CT scan on day 7 after admission revealed a lesion in the left parietal-temporal region (Fig. 1a), reported as consistent with a haemorrhage or early abscess formation. He continued to remain febrile and toxic. The surgeons advised against operating at this stage, especially as he still had major respiratory problems. He developed decubitus ulcers and a broncho-pleural fistula with a persistent collapsed right lung despite effective drainage. Recurrent chest drain obstruction required four replacements. On day 24, he required another blood transfusion. On day 30, his fever began to settle. He became more responsive and was able to feed orally. An ophthalmological

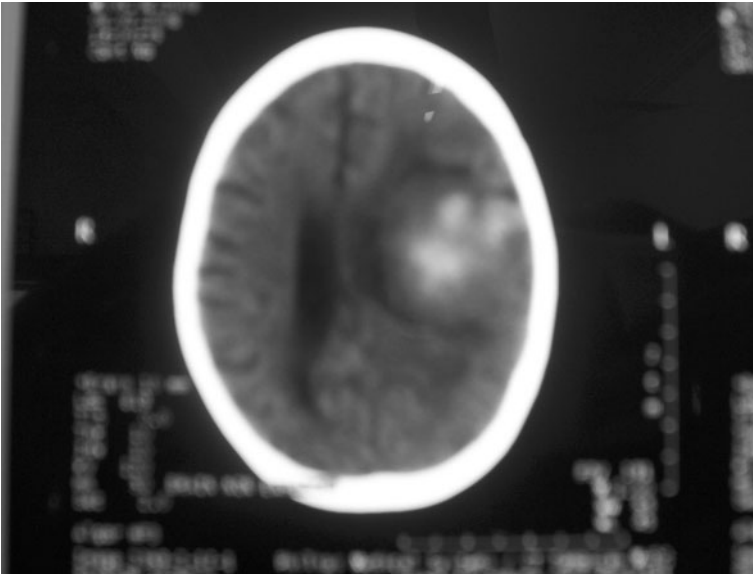


FIG. 1a. Case 1: CT scan with contrast 1 week after admission showing enhanced lesion in the left temporo-parietal region and midline shift to the right.

assessment on day 32 revealed marked visual loss and sluggish pupils. A second CT scan with contrast on day 35 showed a lesion with enhanced margins consistent with a brain abscess (Fig. 1b). The antibiotic treatment (cloxacillin and ceftriaxone) was continued and he was discharged on day 54. At follow-up 1 month later, his

progress was excellent. He was walking normally, feeding well, talking and able to fix and follow.

#### Case 2

A 6-year-old girl presented with a history of fever, headache and neck stiffness for 3 days

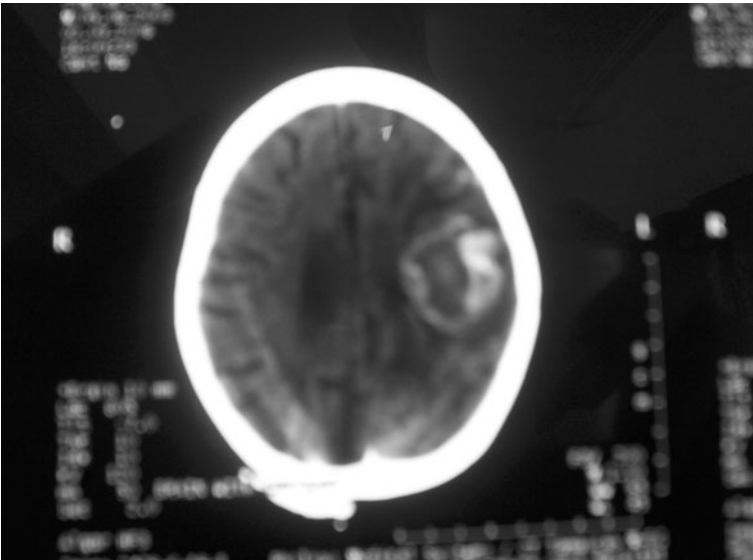


FIG. 1b. Case 1: Follow-up scan with contrast 1 month after treatment showing ring enhancement of left-sided lesion consistent with abscess.

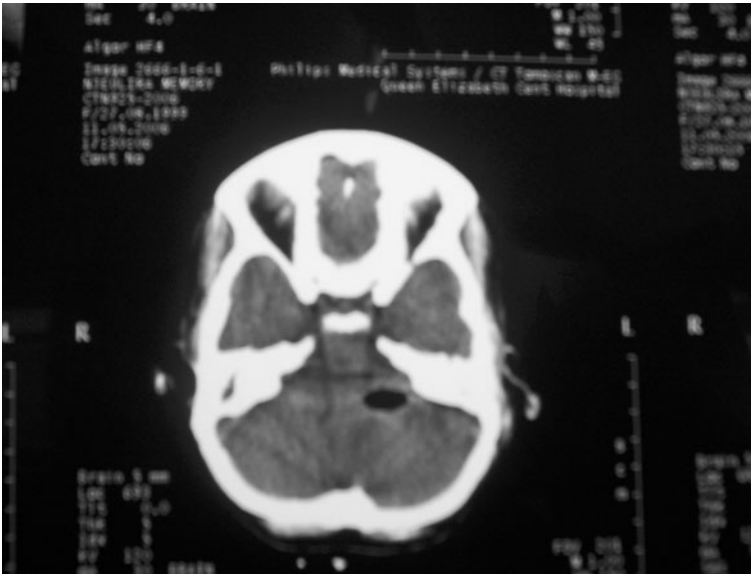

FIG. 2. Case 2: CT scan without contrast showing lesion in posterior fossa with air anteriorly and midline shift of the cerebellum to the right. Higher images from the same CT scan showed dilated ventricles.

and generalised seizures for 1 day. She was fully immunised. The only remarkable history was of bilateral chronic suppurative otitis media for a year. She had no history of TB contact.

On examination, she was thin (weight 17 kg, weight-for-age 80–90%), febrile (axillary temperature 38.7°C), alert and well perfused. Her pulse was 136 bpm, respiratory rate 34 bpm and BP 100/70 mmHg. She had marked neck stiffness and a right lateral gaze with generalised symmetrical brisk reflexes. She had bilateral chronic suppurative otitis media and a tender left mastoid but no swelling over the mastoid bone. The remainder of the examination was normal.

Lumbar puncture demonstrated a cloudy CSF and a thick blood film was negative for malarial parasites. Ceftriaxone (100 mg/kg/day i.v.) was commenced. Blood glucose was 6.5 mmol/L and lactate 5 mmol/L. The CSF showed a white cell count of  $15 \times 10^6$ /L, no red blood cells, protein 1.0 g/L and glucose 14 mmol/L. No organisms were detected on gram stain; Ziehl–Neelson stain was not done. An HIV test and blood culture were negative. On day 3 she started

to improve and her temperature settled. On day 5 she became irritable and confused and was unable to sit. Tuberculous meningitis was considered. Chest radiograph demonstrated right perihilar infiltrations and a tuberculin skin test (TST) (two units of tuberculin RT23, Serum Statens Institut, Copenhagen) resulted in a blistering reaction of 20 mm after 48 hours. On day 8, she was commenced on TB meningitis treatment and oral prednisolone 2 mg/kg/day. On day 10, a protruding left ear and a swelling over the left mastoid was noticed. The finding of mastoiditis made the diagnosis of intracranial abscess more likely than TB meningitis and a cranial CT scan was done. This demonstrated a lesion in the posterior fossa with midline shift of the cerebellum (Fig. 2) and dilated ventricles consistent with a brain abscess. The surgeons decided not to operate and parenteral ceftriaxone (100 mg/kg/day), metronidazole (7.5 mg/kg/8-hourly) and cloxacillin (25 mg/kg/6-hourly) were commenced. The treatment for TB meningitis was discontinued. The patient responded and was discharged on day 29 on oral ciprofloxacin and flucloxacillin for 3 weeks.

## Case 3

An 11-year-old boy was referred from a district hospital to which he had been admitted for a week after presenting with headache and fever for 4 weeks. At the district hospital, he tested positive for malaria and was treated with intravenous quinine, benzyl penicillin and chloramphenicol for suspected bacterial meningitis. While in the district hospital 4 days later, he developed a left-sided hemiparesis with left-sided focal seizures and was referred to QECH for further management. He was fully immunised, had previously been well and had no history of TB contact.

On examination, his temperature was 37.5°C, blood pressure 115/80 mmHg, respiratory rate 28/min and pulse 73/min. He was alert, well perfused, had neck stiffness, a positive Kernig's sign and a left-sided hemiparesis. On direct ophthalmoscopy, both discs showed 'fullness'. The remainder of the examination was unremarkable. Meningitis was diagnosed and differential diagnoses of intracranial abscess, TB meningitis and sickle cell disease were also considered.

Lumbar puncture demonstrated clear CSF under low pressure. The CSF showed a white cell count of  $18 \times 10^6/L$ , red cell count  $10 \times 10^6/L$ , protein 1.0 g/L, glucose 14 mmol/L; gram stain was negative. Intravenous ceftriaxone (100 mg/kg/day) was commenced. On day 2, he became stable and afebrile and no growth of CSF culture was reported. Ceftriaxone was discontinued. A peripheral blood film was examined for sickle cells and revealed no abnormality. An HIV test was negative and TST was non-reactive after 72 hours. A cranial CT demonstrated a right subdural abscess measuring  $3.5 \times 2.5$  cm with a midline shift. Ceftriaxone was restarted and surgical drainage was scheduled for the following day. That night, the patient developed focal left-sided seizures which responded to paraldehyde. A subdural empyema and infected cephalo-haematoma

were drained and metronidazole was added. His clinical condition improved and he became afebrile and fully conscious. On day 14, however, he was still complaining of a painful neck and pus was discharging from the incision site. Surgical wound exploration and debridement were undertaken. Over the following 2 weeks, the patient was clinically stable except for recurrent purulent discharge from the incision site which required surgical drainage and washouts on days 21, 23, 25 and 29. A repeat cranial CT on day 30 showed multiple right intracerebral abscesses (the largest being in the frontal and parietal regions) with oedema and shift of the midline to the left. At surgical exploration, pus was drained from abscesses in the occipital and parietal regions and the drains were removed after 48 hours. He remained stable over the next 15 days and on day 56 a repeat CT scan showed several small abscesses in the right cerebral hemisphere. Ceftriaxone and metronidazole were continued. By day 60, the facial palsy was improving and he was able to sit and eat. He was discharged on a 2-week course of oral cefuroxime and oral metronidazole. Unfortunately, however, he died at home a week later.

## Discussion

Suppurative brain abscess is uncommon in children. Recent retrospective studies from two tertiary referral hospitals in Pakistan and Australia each reported 30 cases over a 10-year period.<sup>2,3</sup> Most were children over 4 years of age, case fatality was 10–16% and the majority of survivors had longstanding neurological deficit. A recent review states that 25% of all brain abscesses occur in children under the age of 15 years with a peak at 4–7 years and high morbidity and mortality.<sup>4</sup> Brain abscess is likely to be underreported from resource-poor regions where diagnostic imaging is often unavailable.

The pathogenesis of brain abscess in children was reviewed recently.<sup>4,5</sup> Infection can arise either directly from a contiguous site such as middle ear, sinuses, teeth and compound skull fractures or indirectly via haematogenous spread from extracranial sources such as pulmonary infection, endocarditis or septicaemia. Organisms involved include streptococci (anaerobic and aerobic), responsible for about 50–70%, staphylococci (10–30%) and enteric bacteria (10–25%).<sup>4–6</sup> Mixed flora can be found in up to 30%. Aetiology is influenced by the location and predisposing condition of the abscess.<sup>4,5</sup> Abscesses arising from sinus or odontogenic foci tend to be frontal and caused by streptococci (aerobic and anaerobic), enterobacteriaceae, *Staphylococcus aureus* and anaerobes. Temporal or cerebellar lesions are usually otic in origin with mixed flora which include aerobic and anaerobic streptococci, enterobacteriaceae and *Pseudomonas aeruginosa*. Abscesses caused by haematogenous spread are usually caused by a single pathogen (*Streptococcus milleri* and *Staphylococcus aureus* are important causes) and occur in the distribution of the middle cerebral artery.<sup>3–5</sup> In immunocompromised children, a wider range of pathogens including fungi and mycobacteria can cause brain abscess.<sup>5,6</sup>

The three cases reported were all previously well, HIV-uninfected children. In two, a likely source of infection was identified, one a staphylococcal pulmonary infection and the other chronic suppurative otitis media and mastoiditis. The location of the abscesses was consistent with these associations. The source of infection was not obvious in the case with subdural empyema and multiple abscesses.

A causative pathogen was not isolated from the abscess in any of them. It could be presumed that the cause in case 1 was *Staphylococcal aureus* as it was cultured from blood and the empyema and thus cloxacillin was given for 6 weeks. Ceftriaxone was also used because of concerns that the brain abscess might be a complication of

salmonella septicaemia. The patient had severe malarial anaemia as well as severe pneumonia. Severe malarial anaemia is commonly associated with bacteraemia owing to non-typhoidal salmonella with a risk of focal sepsis such as salmonella meningitis or pneumonia following discharge.<sup>7,8</sup>

When the diagnosis was being considered, all three patients had clinical features consistent with a brain abscess<sup>4,5</sup>—fever, seizures and altered mental state. In case 1, it is possible that earlier drainage of the staphylococcal empyema might have reduced the risk of brain abscess, although it is also possible that the acute but temporary neurological deterioration that occurred 5 hours after admission correlated with the beginning of the infective cerebritis which later evolved to become an abscess. Also, there were multiple pathologies which might have contributed to the neurological deterioration on day 6 before the chest drain was inserted. He had had malaria, severe anaemia, staphylococcal septicaemia and hypoxia, although he had been stable for some days after this.

TB meningitis was considered in case 2 because of a lack of response to antibiotics that are usually very effective for bacterial meningitis (i.e. ceftriaxone) and the strongly reactive tuberculin test. The diagnosis of brain abscess was considered when the mastoid swelling was noted but, in retrospect, the finding of a tender (though not swollen) mastoid on admission was suggestive.

These cases highlight the value of neuro-radiological imaging. The presentation of fever, seizures and altered mental state is very common in children admitted to QECH. The commonest causes are cerebral malaria and acute bacterial meningitis. A blood film positive for malaria does not necessarily mean that the cause of coma is cerebral malaria<sup>1</sup> and a negative blood film does not necessarily exclude the diagnosis. The diagnosis of cerebral malaria is strongly supported by characteristic findings on

examination of the fundus<sup>9</sup> so that other diagnoses must be strongly considered if malarial retinopathy is absent. However, the recognition of malarial retinopathy requires training and experience. Bacterial meningitis is usually a straightforward diagnosis as long as there is a high index of suspicion. If cerebral malaria and bacterial meningitis have been excluded or there is a poor response to treatment for the same, other diagnoses include viral encephalitis, TB meningitis and brain abscess. Children with TB meningitis will usually have typical CSF findings while the CSF findings for a brain abscess that has not ruptured into a CSF compartment are non-specific and overlap with those of acute encephalitis. These three cases had only 5–18 white cells/mm<sup>3</sup> in the CSF.

The possibility of clinical overlap with other conditions which require different management emphasises the value of a CT scan, preferably with contrast, as abscesses show a typical ring enhancement. Imaging is also required to direct surgical intervention.<sup>4,5</sup> In carefully selected patients, surgical drainage is required in those with illness for >2 weeks who are neurologically impaired with signs of raised intracranial pressure and abscesses of >3 cm diameter. In developed countries, minimally invasive surgery with CT or MRI-guided stereotactic aspiration have replaced traditional open craniotomies for aspiration. Surgery can reduce the raised intracranial pressure, aid the obtaining of pus for microbial diagnosis and enhance antibiotic efficacy.

Cranial ultrasound is also useful for diagnosis of brain abscess but is limited to children with open fontanelles. It is also useful for diagnosing subdural collections which are common in children <2 years of age.<sup>2</sup> This diagnosis is not uncommon in our setting where the usual cause is non-typhoidal salmonella (S. M. Graham, unpublished observation) and repeated

needle aspiration through the fontanelle is a part of management. Brain abscess is typically seen in older children<sup>2,3</sup> and so ultrasound is not helpful for diagnosis.

In resource-poor settings, the management of brain abscess is challenging. The existence of other diseases with similar signs and symptoms can delay diagnosis. A high index of suspicion of brain abscess, although it is unusual, is essential, as is careful assessment of risk factors such as chronic ear or cardiac disease. Prompt referral to a centre with adequate facilities for prolonged broad-spectrum antibiotics and surgical drainage is important. Neuro-radiological imaging is extremely useful for accurate diagnosis and effective management.

## References

- 1 Taylor TE, Fu WJ, Carr RA, *et al.* Differentiating the pathologies of cerebral malaria by *postmortem* parasite counts. *Nature Med* 2004; **10**:143–5.
- 2 Leotta N, Chaseling R, Duncan G, Isaacs D. Intracranial suppuration. *J Pediatr Child Health* 2005; **41**:508–12.
- 3 Mehnaz A, Syed AU, Saleem AS, Khalid CN. Brain abscess in children. *Indian J Pediatr* 2006; **73**:401–4.
- 4 Yogev R, Bar-Meir M. Management of brain abscess in children. *Pediatr Infect Dis J* 2004; **23**:157–9.
- 5 Sáez-Llorens X. Brain abscess in children. *Semin Pediatr Infect Dis* 2003; **2**:108–14.
- 6 Brook I. Brain abscess in children: microbiology and management. *J Child Neurol* 1995; **10**:283–8.
- 7 Bronzan RN, Taylor TE, Mwenechanya J, *et al.* Bacteremia in Malawian children with severe malaria: prevalence, etiology, HIV coinfection and outcome. *J Infect Dis* 2007; **195**:895–904.
- 8 Mankhambo L, Chiwaya K, Phiri A, Graham SM. Lobar pneumonia caused by nontyphoidal *Salmonella* in a Malawian child. *Pediatr Infect Dis J* 2006; **25**:1190–2.
- 9 Beare NAV, Taylor TE, Harding S, Lewallen S, Molyneux ME. Malarial retinopathy: a newly established diagnostic sign in severe malaria. *Am J Trop Med Hyg* 2006; **75**:790–7.