

# BASAL CELL CARCINOMA IN XERODERMA PIGMENTOSUM IN AN 18-YEAR-OLD MALE

Satya Wydya Yenny, Frien Refla Syarif

Dermato-Venereology Department of Medical Faculty of Andalas University/  
dr. M. Djamil Hospital Padang

## **Abstract**

*Xeroderma pigmentosum (XP) is a rare autosomal recessive disorder that occurs because of inactivation of the xeroderma pigmentosum protein, which is an important DNA damage recognition protein involved in DNA nucleotide excision repair (NER). This defect, which prevents removal of a wide array of direct and indirect DNA lesions, is associated with a decrease in catalase activity. This photosensitive disorder results in multiple face, neck and head basal cell carcinomas (BCCs), squamous cell carcinomas (SCCs) and melanomas which is characterized by cellular hypersensitivity to ultraviolet radiation, development of cancers at an early age, severe actinic cancer, and photophobia. As a common stressor of skin, ultraviolet-B (UVB) induces a biphasic HIF-1 $\alpha$  variation through ROS generation in keratinocytes. We reported a case of an 18-year-old-male with XP presented with BCC on the left cheek. The patient had hypo- and hyperpigmented macules since early childhood, throughout the body, more on sun exposed areas.*

**Keywords:** xeroderma pigmentosum, basal cell carcinoma, nucleotide excision repair

## **Abstrak**

Xeroderma pigmentosum (XP) adalah kelainan autosomal resesif yang jarang terjadi disebabkan oleh inaktivasi protein xeroderma pigmentosum yang merupakan protein penting pengenal kerusakan DNA yang terlibat dalam *nucleotide excision repair (NER)* DNA. Defek ini mencegah penghapusan beragam lesi DNA langsung dan tidak langsung, terkait dengan penurunan aktivitas katalase. Kelainan fotosensitivitas ini menyebabkan terjadinya basal karsinoma sel (BCC), karsinoma sel skuamosa (SCC) dan melanoma pada wajah, leher dan kepala yang ditandai dengan hipersensitivitas seluler radiasi ultraviolet, perkembangan kanker pada usia dini, kanker actinic yang berat, dan fotofobia. Ultraviolet-B (UVB) merupakan stressor pada kulit yang menginduksi variasi HIF-1 $\alpha$  bifasik melalui generasi ROS dalam keratinosit. Kami melaporkan kasus XP dengan BCC di pipi kiri pada laki-laki berusia 18 tahun. Pasien memiliki makula hipo- dan hiperpigmentasi sejak masa kanak-kanak awal, seluruh tubuh, lebih pada daerah yang terpapar sinar matahari.

Kata kunci: xeroderma pigmentosum, karsinoma sel basal, nucleotide excision repair

Correspondence:

Satya Wydya Yenny

Jln. Perintis Kemerdekaan 45, Padang

Email: [gswydya@yahoo.com](mailto:gswydya@yahoo.com)

## PEMBAHASAN

Jumlah kasus baru kanker kulit terhadap seluruh jumlah kunjungan pasien ke Sub Bagian Tumor Poliklinik Kulit dan Kelamin Rs. Dr. M. Djamil selama periode Januari 2012- September 2014 adalah 26 kasus dari 1.073 kunjungan.

Pada penelitian retrospektif ini menunjukkan insiden terbanyak adalah karsinoma sel basal (76,9%) kemudian diikuti dengan karsinoma sel skuamosa (15,4%) pada urutan kedua lalu melanoma maligna (7,7%). Kanker kulit ditegakkan dari pemeriksaan histopatologi baik secara biopsi mau pada pemeriksaan secara langsung tumor setelah dilakukan penanganan bedah.

Hasil penelitian ini sama dengan yang diperoleh dari data The Cancer Association of South Africa (CANSA) memperlihatkan bahwa pada tahun 2000-2001 kanker yang paling sering terjadi adalah kanker kulit yang terdiri atas karsinoma sel basal, karsinoma sel skuamosa, dan melanoma.<sup>3</sup> Begitu juga dengan penelitian oleh Pilgrim W, dkk (Kanada, 2014) melaporkan bahwa di Kanada diperoleh insiden kanker kulit selama tahun 2002-2010 adalah karsinoma sel basal (68%), karsinoma sel skuamosa (24%) dan melanoma maligna (8%).<sup>4</sup>

Di Jakarta, pada tahun 2000-2009, Poliklinik Departemen Ilmu Kesehatan

Kulit dan Kelamin Rumah Sakit dr Cipto Mangunkusumo (RSCM) melaporkan 261 kasus karsinoma sel basal, diikuti dengan 69 karsinoma sel skuamosa, dan 22 melanoma.<sup>5</sup> Hasil berbeda didapatkan dengan data sebelumnya, di Rumah Sakit Kanker Dharmais selama tahun 2005-2007 mencatat bahwa yang tersering adalah karsinoma sel skuamosa diikuti oleh karsinoma sel basal dan melanoma.<sup>6</sup>

Distribusi frekuensi kanker kulit di Sub Bagian Tumor di Poliklinik Kulit dan Kelamin RS Dr. M. Djamil Padang berdasarkan jenis kelamin, Januari 2012- September 2014 diperoleh bahwa insiden kanker kulit banyak ditemukan pada jenis kelamin laki-laki sebanyak 57,7% dibandingkan perempuan 42,3%. Hasil ini juga sesuai dengan yang diperoleh Pilgrim W, dkk (Kanada, 2014) dimana jenis kelamin laki-laki lebih banyak menderita kanker kulit dibandingkan perempuan.<sup>4</sup> Distribusi frekuensi kanker kulit di Sub Bagian Tumor di Poli Kulit dan Kelamin RS Dr. M. Djamil Padang berdasarkan usia, Januari 2012- September 2014 diperoleh bahwa insiden kanker kulit terbanyak pada usia 45-64 tahun adalah 16 kasus (61,5%) dan pada usia > 65 tahun adalah 8 kasus (30,9%). Pada penelitian Pilgrim W, dkk (Kanada, 2014), insiden kanker kulit 43 kali lebih tinggi pada usia >75 tahun dibandingkan usia 0-44 tahun.<sup>4</sup>

## Daftar Pustaka

1. Rata IGA. Tumor Kulit. Dalam: Djuanda Adhi, Hamzah Mochtar, Aisyah Siti, penyunting. Buku Ilmu Penyakit kulit dan Kelamin. Edisi ke enam. Jakarta: Badan Penerbit Fakultas Kedokteran Universitas Indonesia, 2010; h. 229-241.
2. Horsham C, Auster J, Sendall MC, Stoneham M, Youl P, Crane P. Interventions to decrease skin cancer risk in outdoor workers: update to a 2007 systemic review. *Bio Med Central* 2014; 7:1-10.
3. Cansa. Statistics. National Cancer Registry 2010. The 2000-2001 NCR report. Tersedia pada <http://www.cansa.org.za/> . Diunduh pada tanggal 12 November 2014.
4. Pilgrim W, Hayes R, Hanson DW, Zhang B, Boudreau B, Leonfellner S. Skin cancer (Basal cell carcinoma, squamous cell carcinoma, and malignant melanoma): New cases, treatment practice, and health care cost in new Brunswick, Canada, 2002-2010. *Journal of Cutaneous Medicine and Surgery* 2014; 18:320-331.
5. Cipto H. Patients characteristic in skin tumor and skin surgery division, Department of Dermatovenereology FKUI/RSCM, Jakarta. *Indones J Oncol. In press.*
6. Sinuraya EV. Registrasi kanker berbasis rumah sakit di Rumah Sakit Kanker Dharmais. Jakarta: Rumah Sakit Kanker Dharmais/Departemen Kesehatan Indonesia. 2012.

## INTRODUCTION

Xeroderma pigmentosum (literally means dry pigmented skin) is defined by extreme sensitivity to sunlight, resulting in sunburn, pigment changes in the skin and greatly elevated incidence of skin cancers. Herba and Kaposi first described XP in 1974.<sup>1,2</sup> Kramer et al. found an equal sex predilection and significant parental consanguinity, confirming an autosomal recessive inheritance pattern.<sup>3</sup>

The prevalence of XP in United States and Europe is 1:250.000 and in Japan 1:40.000. Its incidence is not that significant in context to the other part of the world.<sup>4</sup> The basic defect underlying the clinical manifestations is a nucleotide excision repair (NER) defect leading to a defective repair of DNA damaged by ultraviolet (UV) radiation. Malignant melanoma arises in about 3% of patients with XP.<sup>5</sup>

Xeroderma pigmentosum is variably also known as Kaposi disease, xeroderma pigmentosum variant type, XP-V and XP. At least eight inherited forms of XP have been identified which are xeroderma pigmentosum, type A, I, XPA, classical form; xeroderma pigmentosum, type B, II, XPB; xeroderma pigmentosum, type C, III, XPC; xeroderma pigmentosum, type D, IV, XPD; xeroderma pigmentosum, type E, V, XPE; xeroderma pigmentosum, type F, VI, XPF; xeroderma pigmentosum, type G, VII, XPG; xeroderma pigmentosum, dominant type.<sup>6,7</sup> The process whereby DNA is removed and replaced with new DNA using the intact strand as a template, involves the products of various genes. Each gene (of which XPA to XPG have been identified), encodes for specific proteins that are involved in nucleotide excision and repair. Each protein has a specific role in the incision, removal and replication of the damaged DNA segments.<sup>8</sup>

Collectively they are known as the nucleotide excision repair (NER) enzymes e.g. endonucleases. Thus, seven variants of the disease, known as complementation groups, from XPA to XPG have been described, depending on the XP gene deficient. The various types of XP show clinical and epidemiological differences, the reason for which is not clear as yet. For example the XPC group, which is most prevalent in Europe, shows no neurological defects. The XPA groups exhibit neurological

disorders before the age of 7 but the XPD group after this age. A variant of the disease known as XPV has also been described and is present in 20% of the patients. This is due to a mutation in the gene encoding for DNA polymerase, such that the repaired DNA chains are lighter than normal. In patients with xeroderma pigmentosum, 80% show a defect in the initiation of DNA excision of ultra violet radiation byproducts e.g. Cyclobutamide or pyrimidine dimers.<sup>9</sup>

The course of the disease is divided into 3 stages. In stage 1, which usually occurs around 6 months of age, skin erythema, scaling and freckling appear. Stage 2 is the stage of poikiloderma while stage 3 is the tumor formation. Apart from skin tumors, intraoral tumors have also been reported.<sup>8</sup> Kraemer et al. constructed the Kaplan-Meier survival curve for patient with XP which 90% probability of surviving to age 13 years, 80% probability of surviving to 28 years, 70% probability of surviving to 40 years, overall, life expectancy of patients with XP reduced by 30 years.<sup>10</sup>

The treatment of XP is challenging because it is multi-organ and multi-system disease, and because usually by the time of diagnosis, significant tissue damage has already occurred. Early diagnosis and immediate implementation of rigorous sun-protection measures may prolong the lives of persons with XP.<sup>11</sup> Prenatal diagnosis by amniocentesis is possible, as post repair replication is reduced in amniotic fluid cells as well, but is not available currently at the study setup. Parents should be educated about and asked to look out for and detect any tell tale signs of the disease in siblings. Great emphasis was laid on the prevention of tumour formation by sun etiquette counselling which can be quite a daunting task.<sup>8</sup>

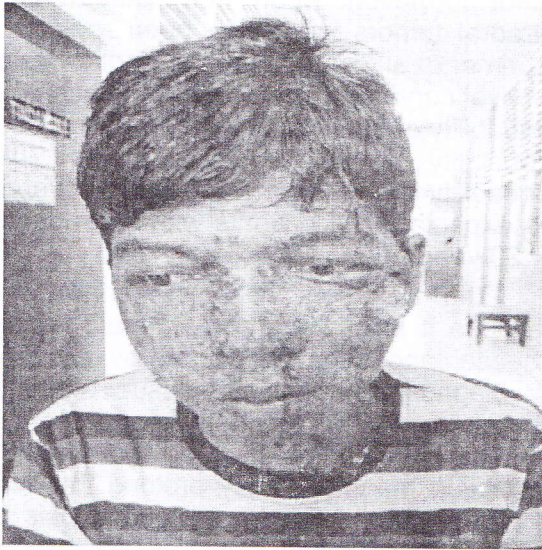## CASE REPORT

An 18-year-old male, a paddy field worker, came with chief complaints of freckles and hypo- and hyperpigmented macules all over the body as well as photo-sensitivity and increased watering from eyes since early childhood (4 year-old). The skin lesions initially appeared over the face and gradually involved the entire body surface. The skin pigmentation was progressive and more so after exposure to sunlight. He presented

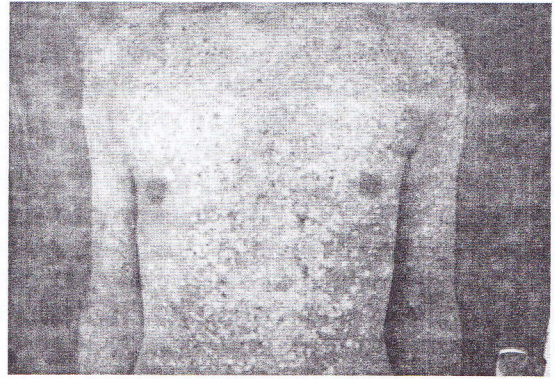
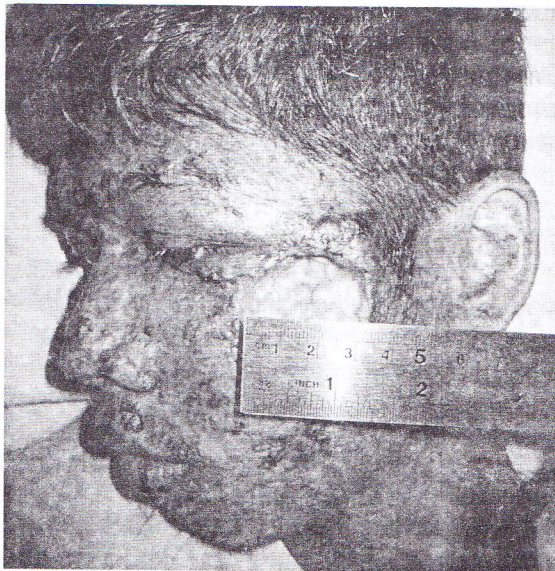with increase in size and ulceration of one lesion on his left cheek since 2 years ago and had been diagnosed as BCC. There was no history of consanguinity of the parents and his siblings were normal.

Dermatological state of this patient was multiple pigmented (hypo- and hyperpigmented) macules and freckles on all over the body and 3.5 cm in diameter ulcer with granulation tissue in it, regular border, and rising edge on his left cheek.

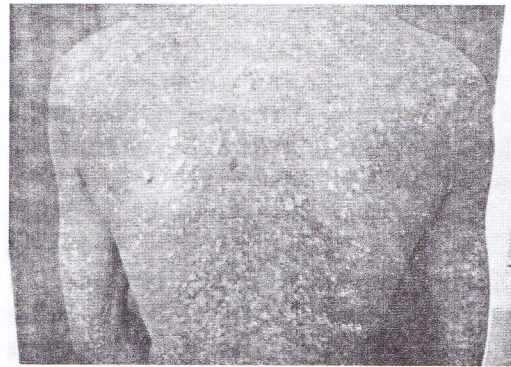
General examination was within normal limits and there was no regional lymphadenopathy found. Blood examination was within normal limits. Chest radiography was normal.



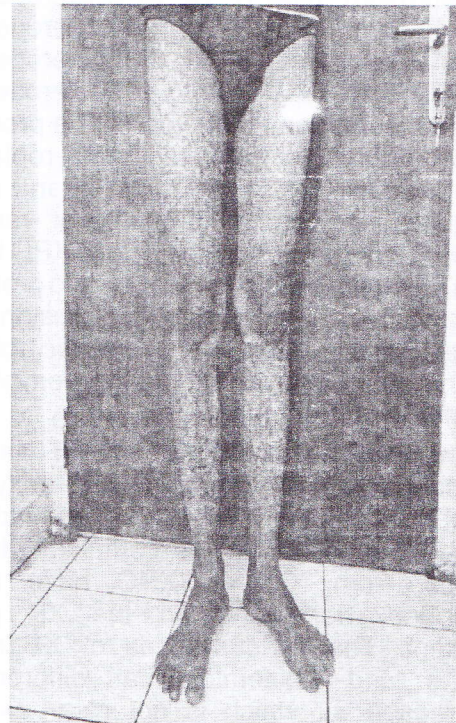
**Basal cell carcinoma on the left cheek, 3.5 cm in diameter.**



**Hypo- and hyperpigmented macules and freckles on the chest.**



**Hypo- and hyperpigmented macules and freckles on the back.**



**Hypo- and hyperpigmented macules and freckles on the legs.**

## DISCUSSION

Xeroderma pigmentosum is a rare autosomal recessive disorder, first described in 1874 by Hebra and Kaposi.<sup>1,2</sup> One study suggested a slightly higher ratio of males presented, though literature states sex incidence to be equal. This may be due to greater exposure of the male gender of this society to the outdoors compared with their female counterparts.<sup>8</sup> Our patient is a paddy field worker which exposes to the sun in daily time for so many hours.

Jan et al. found 70% of the patients had BCC and 15% had SCC. Also, 23 of 25 patients had more than one tumor at first presentation, highlighting the tendency of XP patients to form multiple tumors simultaneously. Tumor clearance rates were satisfactory through development of new tumors within 6 months was inevitable in almost all the patients.<sup>8</sup>

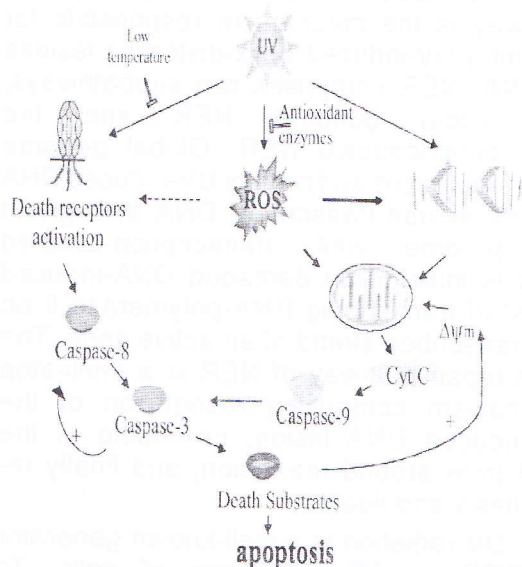
The ulcer on his left cheek had been diagnosed as BCC but had no previous treatment of this disease. He had 'salt and pepper' pigmentary changes all over his body, photosensitivity and watering eyes. There was no history of consanguinity of his parents and no other family members having XP. In this patient, excessive solar damage to the skin develops at an early stage. Three stages are recognized. First started at when he was 4 year-old, there were freckles appeared on his face. The second stage was mottled pigmentation developed and third stage appeared malignant tumor on the skin.

About 50% of persons with XP experience acute sun burn or minimal exposure to UV radiation and tend to develop neurological abnormalities. Cutaneous signs and symptoms usually emerge in children under 20 years. Up to 60% of persons with XP will eventually develop skin cancer, in many cases multiple primary lesions.<sup>10</sup> Xeroderma pigmentosum patients below 2 years of age have more than 1000 fold increased risk of developing skin cancer. The two most common types of cancer found in XP are BCC and SCC, mainly occurring in head, face and neck.<sup>12</sup> Ocular manifestations include photophobia as the earliest symptom, which is feature of keratitis. Other ocular complications include exposure keratitis, vascularization, ulceration, nodular dystrophy, and uveitis.<sup>13</sup> This patient has photosensitivity as photophobia and also watering eyes.

The nucleotide excision repair (NER) pathway is the mechanism responsible for repairing UV-induced helix-distorting lesions of DNA. NER comprises two subpathways, the global genome NER and the transcription-coupled NER. Global genome NER recognizes and repairs UV-induced DNA lesions in non-transcribed DNA throughout the genome, while transcription-coupled NER is initiated by damaged DNA-induced arrest of transcribing RNA-polymerase II on the transcribed strand of an active gene. The DNA repair pathway of NER is a multi-step mechanism comprising recognition of the UV-induced DNA lesion, unwinding of the DNA from around the lesion, and finally re-synthesis and ligation.<sup>9</sup>

UV radiation is a well-known generator of ROS in different types of cells. To neutralize ROS, living cells have acquired several lines of defense systems including non-enzymatic ( $\alpha$ -tocopherol and vitamin C) and enzymatic antioxidants at the forefront. When these systems are overwhelmed, degradation systems such as proteasomes and autophagy intervene. Finally, cell death (apoptosis) may occur. Apoptosis is a highly complex process involving extrinsic and intrinsic pathways through which caspase activation is triggered (Figure 1). Recent data have shown that in addition to death receptor activation and DNA damage, UVB-induced ROS generation contributes to induction of apoptosis. Reduction of the deleterious effects of UV-induced ROS through an increase in antioxidant defense systems supports this notion.<sup>9</sup>

XPA protein is recruited to the region to stabilize the intermediately open repair site, and positions XPF and XPG endonucleases, enabling them to excise the damaged strand. The cellular replication machinery then fills the remaining gap which is later sealed by ligase. The exact rôle of XPE protein in NER activity is unknown, but it has been suggested that it participates in damaged DNA recognition. Thus, subjects with XP have molecular defects in cellular DNA repair mechanisms because of mutations in one or more NER XP genes, leading to hypersensitivity to UV radiation. This results in the accumulation of unrepaired UV-induced DNA damage which either promotes cell death contributing to accelerated skin ageing, or promotes cellular transformation resulting in the development of cancer.<sup>9,11</sup>



**Figure 1.** UV-induced apoptosis in the epidermis. UVB-induced death receptor activation, DNA damage, and reactive oxygen species (ROS) generation all contribute to induction of apoptosis. Overexpression of antioxidant enzymes, especially catalase, limits apoptosis mainly through the reduction of a UV-induced intrinsic apoptotic pathway.<sup>9</sup>

Persons with XP are at a several thousand-fold increased risk of skin cancer compared to healthy subjects and show many features of photo-aging including corneal opacity, atrophy of both the epidermis and the dermis, poikiloderma (dyspigmentation) and skin laxity. However, clinical manifestations of XP are not predictable according to the type of the XP gene defect: some subjects with different molecular defects may manifest the same clinical features, while other subjects with the same molecular defects may manifest different clinical features.<sup>9</sup>

Different causes of monogenic disease, such as albinisms and nucleotide excision repair (NER) diseases, contribute to photosensitivity and cancer. The most important contributors to UV adaptive responses include (1) DNA lesions, which can induce a pigmentary response<sup>1</sup> and DNA repair machinery; (2) apoptosis, which deletes damaged cells; (3) enzymatic and non enzymatic antioxidant defenses; (4) melanogenesis; (5) stratum corneum, which

acts as a physical barrier and a sensor for UV danger responses;<sup>2</sup> and (6) the skin immune system, both innate and adaptive.<sup>3</sup> Interestingly, most of these responses include reactive oxygen species (ROS) mediated effects.<sup>9</sup>

In addition, genetic polymorphism in XP genes may have a functional impact on DNA repair mechanisms modifying cancer risk. Epigenetic diversity and differences in the stochastic nature of the accumulated damaged DNA may contribute to the substantial phenotypic variance among persons with XP carrying the same causative molecular defect. Although XP disorders exhibit phenotypic variability, there are common denominators to all XP variants (photosensitivity, susceptibility to cancer) since the NER mechanism is a multistep sequence, and a molecular defect at one step dysregulates the function of the downstream steps and subsequently of the whole system.<sup>8,9,11</sup>

Currently there is no specific treatment for XP. Management involves preventing damage and dealing with damage tissue at the earliest. Total protection from UV light greatly improves the prognosis and reduces skin changes and cancers.<sup>14</sup> Clinical management of carcinomas associated with XP consists of early diagnosis followed by a rigorous programme of the sun protection. However, the prophylactic usage of oral retinoids, topical retinoids, local injection of interferon and the external use of prokaryotic DNA repair enzymes may slow down the onset of skin cancers.<sup>15</sup>

Conventional methods of treating BCC e.g. surgery, cryotherapy and electrodesiccation may also be employed in XP-associated tumors. These treatments, although effective in the short term, may be associated with recurrence and scarring and may not be feasible for multiple tumors.<sup>15</sup> Following excision, all defects were reconstructed either by primary closure or with split skin grafts. Excision of tumors followed by total resurfacing by split thickness grafts on the face has been reported to arrest new tumors formation for 5 years.<sup>8</sup>

Yarosh et al. demonstrated that topical application of DNA repair enzymes (endonuclease V) to sun-damaged skin of patients with XP lowered the rate of development of skin cancers, including BCCs,

during a year of treatment.<sup>16</sup> Imiquimod 5% cream has resulted in researchers identifying its potential use in treating skin tumors even where these occur in the spectrum of hereditary conditions. These findings was successfully used in treating facial BCCs in XP patients as an alternative to surgery.<sup>15</sup>

A new approach to photoprotection is to repair DNA damage after UV exposure by delivering a DNA repair enzyme into the skin by means of specially engineered liposomes.<sup>10</sup> Gene therapy to supply the missing NER using viral vectors (adeno and retroviruses) is still in its experimental stage. Ex vivo gene therapy, in which grafted skin that has the genetic defect corrected, is also being tried. The future strategy will be to procure topical T4 endonuclease V and study its efficacy in preventing tumour formation.<sup>8</sup> T4 endonuclease V has been shown to repair cyclobutane pyrimidine dimers resulting from DNA damage. Genetic counselling of affected families is important. Amniocentesis may be done for prenatal diagnosis of XP and interruption of the pregnancy.<sup>10</sup>

## CONCLUSION

Reported a case of 18-year-old male with XP and facial BCC with no family history or consanguineous marriage of parents. This case was reported to create awareness among physicians and surgeons about this rare condition and importance of early detection and prevention of UV rays induced skin damage. Xeroderma pigmentosum may occur at an early age, so early diagnosis and management is very important. Genetic counseling implicating the effect of consanguineous marriages should be emphasized. Monogenic disorders of innate photoprotection are especially good cancer models, because they are triggered by a standardizable environmental hazard (UV irradiation). Based on the biochemical differences noted between two clinically distinct but molecularly related NER diseases and XP, antioxidant enzyme therapy is effective for photoprotection, at least during the acute stage following UV irradiation. This may ultimately lead to the implementation of new strategies for the prevention of skin as well as other cancers.

## REFERENCES

1. Butt FM, Moshi JR, Owibingire S, Chindia ML. Xeroderma pigmentosum: A review and case series. *J Craniomaxillofac Surg* 2010; 38: 534-7.
2. Rao TN, Bhagyalaxmi A, Ahmed K, Mohana RTS, Venkatachalam K. A case of melanoma in xeroderma pigmentosum. *Indian J Pathol Microbiol* 2009; 52: 524-6.
3. Webb S. Xeroderma pigmentosum. *BMJ* 2008; 336: 444-6.
4. Lehmann AR, McGibbon D, Stefanini M. Xeroderma pigmentosum. *Orphanet J Rare Dis* 2011; 6: 70.
5. Pradhan E, Padhye SB, Malla OK, Karki KJD. Case of xeroderma pigmentosum with well differentiated squamous cell carcinoma in the eye. *Kathmandu Univ Med J* 2003; 4: 278-83.
6. Patton LL, Valdez IH. Xeroderma pigmentosum: Review and report of a case. *Oral Surg Oral Med Oral Pathol* 1991; 71: 297-300.
7. Bhutto AM, Kirk SH. Population distribution of xeroderma pigmentosum. *Adv Exp Med Biol* 2008; 637: 138-43.
8. Jan Sn, Khan FA, Khan BA. Xeroderma pigmentosum. *Journal of the College of Physicians and Surgeons Pakistan* 2011; Vol.11(2): 93-6.
9. Rezvani HR, Mazurier F, Picard FM, Jouary T, Andre MC, Ged C, et al.. Xeroderma pigmentosum: Clues to understanding cancerinitiation. *Dermatologica Sinica* 2010; 28: 93-101.
10. Koley S, Choudhary SV, Choudhury S, Sharma S, Mukherjee T, Khan K. Xeroderma pigmentosum: Report of two cases and review of the literature. *Journal of Pakistan Association of Dermatologists* 2012; 22(3): 279-82.
11. Feller L, Wood NH, Motswaledi MH, Kammissa RAG, Meyer M, Lemmer J. Xeroderma pigmentosum: A case report and review of the literature. *J Prev Me Hyg* 2010; 51: 87-91.
12. Grampurohit VU, Dinesh US, Rao R. Multiple cutaneous malignancies in a patient of xeroderma pigmentosum. *Journal of Cancer Research and Therapeutics* 2011; Vol.7(Issue 2): 205-7.
13. Pathy S, Naik KK, Bhasker S, Sharma MC, Julka PK, Rath GK. Squamous

- cell carcinoma of face with xeroderma pigmentosa – A case report. *Indian Journal of Medical & Pediatric Oncology* 2005; Vol.26(1): 47-9.
14. Shetty R, Girish BS, Ballal R, Permi HS, Makannavar P, Alva V. Xeroderma pigmentosa with multiple cutaneous malignancies – A rare case report and review of literature. *NUJHS* 2013; Vol.3(1): 76-8.
  15. Giannotti B, Vanzi L, Difonzo EM, Pimpinelli N. The treatment of basal cell carcinoma in a patient with xeroderma pigmentosum with a combination of imiquimod 5% cream and oral acitretin. *Clinical and Experimental Dermatology* 2003; 28(Suppl.1): 33-5.
  16. Yarosh D, Klein J, O'Connor A, Hawk J, Rafal E, Wolf P. Effect of topically applied T4 endonuclease V in liposomes on skin cancer in xeroderma pigmentosum: A randomized study. *Xeroderma Pigmentosum Study Group* 2001; 357: 926-9.