

Accepted Manuscript

Title: An innovative quick solidifying technique for the forensic investigation of brain circulation using addition silicones

Authors: Baena Pinilla Salvador, Cisneros Gimeno Ana Isabel, Obón Nogués Jesús, Arredondo Díaz José Manuel, Querol Nasarre Paulino, Ramón Termis Dolores, Pérez Domingo Laura, Tardós Ascaso Lucía, Valer Martínez Ana, Whyte Orozco Jaime

PII: S0379-0738(19)30081-7
DOI: <https://doi.org/10.1016/j.forsciint.2019.02.057>
Reference: FSI 9693

To appear in: *FSI*



Please cite this article as: Salvador BP, Isabel CGA, Jesús ON, Manuel ADJ, Paulino QN, Dolores RT, Laura PD, Lucía TA, Ana VM, Jaime WO, An innovative quick solidifying technique for the forensic investigation of brain circulation using addition silicones, *Forensic Science International* (2019), <https://doi.org/10.1016/j.forsciint.2019.02.057>

This is a PDF file of an unedited manuscript that has been accepted for publication. As a service to our customers we are providing this early version of the manuscript. The manuscript will undergo copyediting, typesetting, and review of the resulting proof before it is published in its final form. Please note that during the production process errors may be discovered which could affect the content, and all legal disclaimers that apply to the journal pertain.

ORIGINAL ARTICLE

An innovative quick solidifying technique for the forensic investigation of brain circulation using addition silicones.

Baena Pinilla, Salvador ^{1,2}; Cisneros Gimeno Ana Isabel²; Obón Nogués, Jesús ²; Arredondo Díaz, José Manuel¹; Querol Nasarre, Paulino¹; Ramón Termis, Dolores¹; Pérez Domingo, Laura²; Tardós Ascaso, Lucía²; Valer Martínez, Ana², Whyte Orozco, Jaime ².

¹Medico-Legal and Forensic Sciences Institute of Aragon (Spain)

²Department of Human Anatomy and Histology. School of Medicine. University of Zaragoza (Spain)

Corresponding Author: Ana Isabel Cisneros Gimeno Department of Human Anatomy and Histology, School of Medicine, University of Zaragoza, C/Domingo Miral, s/n, 50009 Zaragoza, Spain

e-mail: aicisner@unizar.es

0000-0002-5494-343X

Highlights

- Examination of the cerebral vascular tree in autopsy.
- An arterial solidifying technique to analyze brain circulation.
- Vinylpolisiloxane mixtures is the material selected.
- Quick and effective method in a target organ such as the encephalon
- Respects arterial light and allows you to see the findings better.

ABSTRACT

Post-mortem study of the brain is extremely relevant to medico-legal autopsies. However, it can be difficult to handle due to its fragility.

This article presents a study on the development of an arterial solidifying technique that can be applied to analyze arterial circulation, consequently easing the handling and later diagnosis of diseases in this anatomical site. Vinylpolysiloxane silicone is introduced into the internal carotid arteries until it completely fills the arterial tree, creating a detailed model of the arterial's internal anatomy. This technique is fast, easy to apply and requires no previous tissue fixation. In addition, it allows for further toxicological and pathological tests.

In conclusion, this technique represents a simple, sensitive and efficient method to employ in conventional autopsies, which can help in the diagnosis of death.

KEYWORDS: Vinylpolysiloxane, colored silicone injection, cerebral arteries, forensic autopsy, solidification.

INTRODUCTION

The study and analysis of the cerebral vascular system is extremely relevant to the postmortem study of the brain circulation and it can lead to crucial medico-legal information by helping to identify the cause of death. It is also a target of many cerebrovascular diseases that can be transcendent in forensic studies. However, it can be difficult to achieve through simple macroscopic examination of the brain circulation at the autopsy room. In addition, the unfixed cerebral vascular tree is fragile and difficult to handle. Therefore, there have been several previous investigations [1-12] on different techniques that can be used to solidify and study blood vessels without disrupting their shape and characteristics.

The current study develops a simple and effective postmortem technique for the solidification of the arteries using addition silicones. These silicones are mainly used in the field of Odontology in order to obtain accurate molds of different anatomical sites. This method has never been used before for this specific purpose but it has the potential to be fast and easy to apply. The characteristics of this method offer several advantages compared to the aforementioned studies, such as the fast application of the silicone directly in unfixed brain tissues and the brief solidification time (less than 10 minutes), making it ideal for use during forensic autopsy.

The silicone fills the vessels, following the original shape with accuracy, capturing all the defects and details contained in the endothelium. The silicone mold of the vessels can then be studied without altering the native histologic structure of the tissues. The macroscopic findings can be later evinced using digital microscopes or digital image processing software.

This method can capture the distribution of the arteries located at the base of the brain and their small branches up to a diameter of 0.02 mm. In addition, it allows for the study of some of the most prevalent diseases such as aneurysms, atheromatous plaques or strokes, as well as other anatomical variants.

MATERIAL AND METHODS

Development of this method started in 2011 in IMLCFA (Medico-Legal and Forensic Sciences Institute of Aragon) [13], and it has been improved during the current study. This technique has been proved to be successful in more than 30 forensic cases.

The cause of death for all the corpses included in the study was different from traumatic brain injury, and showed no evidence of high intracranial pressure. Cadavers in an advanced state of decomposition were discarded, as well as those in which the normal anatomy of the brain could have been altered (for example severely burnt).

The process requires generic autopsy materials and a saw to open the cranial vault, as well as some other specific materials.

Addition colored silicones were used for this study. They are vinylpolysiloxane mixtures that come in a double cartridge, separating the base and a catalyst pastes, which mix together during the delivery of the material. These silicones are mainly used in the field of Odontology to create accurate molds of different anatomical sites, so their application to the field of forensics is innovative.

The following silicones were used in this study:

1. Green color: 3M ESPE Express™. Vinyl Polysiloxane Impression Material. Regular Set-Light-Body- Hydrophilic. ISO 4823 Type 3. 50ml. Base Paste/ Catalyst Paste. 7302. Made in Germany by 3M ESPE AG, D-82229 Seefeld.
2. Blue color: 3M ESPE Express™ 2 Light Body Flow Quick. VPS Impression Material. Hydrophilic Light-bodied Consistency. 50ml. Base Paste/ Catalyst Paste. Made in Germany by 3M ESPE AG, D-82229 Seefeld.
3. Intense blue color: 3M ESPE. Express™. Vinyl Polysiloxane Impression Material. Fast Set-Light-Body- Hydrophilic. ISO 4823 Type 3. 50ml. Base Paste/ Catalyst Paste. 7301. Made in Germany by 3M ESPE AG, D-82229 Seefeld.
4. Orange color: 3M ESPE. Impregnum™ Garant™ L DuoSoft™. Polyether Impression Material. Light-bodied consistency- hydrophilic. ISO 4823 Type 3. 50 ml. Base Paste/ Catalyst Paste. Made in Germany by 3M ESPE AG, D-82229 Seefeld.
5. Pink color: 3M ESPE. Impregnum™ Garant™ L DuoSoft™. Polyether Impression Material. Light-bodied consistency- hydrophilic. ISO 4823 Type 3. 50 ml. Base Paste/ Catalyst Paste. Made in Germany by 3M ESPE AG, D-82229 Seefeld.
6. Purple color: 3M ESPE. Express™ 2 Light Body Standard. VPS Impression Material. Hydrophilic Light-bodied Consistency. 50 ml. Base Paste/ Catalyst Paste. Made in Germany by 3M ESPE AG, D-82229 Seefeld.

Silicone number 3 (reference number 7301) obtained the best results due to its low viscosity, light consistency and shorter solidifying time (@23°C= 60 sec.). Numbers 4 to 6 were not successful.

Vinylpolysiloxanes have a very high dimensional stability and accuracy. They show a volumetric change of just 0.3% after 24 hours, and can resolve details down to 0.02 mm, thus minimizing the handling artifacts. Their solidifying time ranges from 7 to 10 minutes. They are hydrophilic

substances so they are not altered by humidity and have surfactant properties. Disinfectant solutions do not disturb the product. The silicones are also tear-resistant.

Automatic mixing and delivery of both the base paste and the catalyst paste is easy with the handgun cartridge dispenser 3M Garant™. Silicone is gently injected manually into the arteries through the plastic cannula at the end of the cartridge providing a moderate and constant pressure throughout the whole process. (Figure 1).

The autopsy is performed following the Virchow method in an I-shaped incision from chin to pubis. The chest cavity is completely opened prior to the neck dissection. Silicone injection turns out easier when the heart is extracted during the chest autopsy due to the retrograde reduction of blood pressure in the cephalic region. The order of organ removal depends highly on the case in question and can be modified depending on the needs of the autopsy.

During the dissection of the neck region, common carotid arteries are found contained in the carotid sheath along with the internal jugular vein and the vagus nerve (Figure 2). The internal carotid artery is then separated from the rest of the structures and tied off proximally with a length of suture or string. Before introducing the cannula, a small hole (no bigger than 1cm) is carved with a scalpel, wide enough to fit the cannula tightly. Then, the cannula, pointing towards the head, has to be adjusted with the ligature to seal the hole and prevent any leakage. Once the dispenser is secured, 10 to 12 silicone embolizations are injected manually, introducing approximately 20ml of the polymer into the vascular tree on each side (making 40ml at the end of the whole process) (Figure 3). Immediately afterwards the cannula is extracted and the string is adjusted to ligate the artery. This process has to be undertaken on both sides sequentially and with the cranial vault unopened.

From 7 to 10 minutes after the last embolization, the scalp is dissected with a mastoid-to-mastoid incision through the cranial vertex, exposing the cranial vault which is then opened with a circular bone saw. Sometimes, at this point, it is possible to observe some of the scalp arteries already filled with colored material. When the vault is opened, it is possible to perform a macroscopic study of the brain cortex arteries, which can provide useful information about potential diseases or alterations. Afterwards, encephalic structures are carefully lifted and separated from the cranial fossae by incision. First the optic chiasm is cut off, followed by the meninges and then through the brain stem, also cutting at the upper end of the vertebral arteries.

Once the brain is completely removed, it is time to ensure all the arteries are correctly filled with silicone, and therefore colored, in order to analyze distribution and disorders (Figure 4). From this moment on, different measurement methods can be undertaken to complete the study of the brain as needed. Also subsequent sampling for histology can be performed guided by the findings.

The total amount of time needed for the procedure is no longer than 40 minutes, making it a versatile technique that can be modified according to the requirements of the forensic autopsy.

RESULTS

The procedure was developed over a series of cases during a period of 5 years. Along the process, changes have been made according to the results achieved in order to improve the technique, obtaining an efficient and useful method (Figure 5).

Several different vinylpolysiloxane silicones were used during the study: Silicone number 3 (reference number 7301) obtained the best results due to its low viscosity, light consistency and shorter solidifying time (@23°C= 60 sec.). The optimal number of embolizations was found to be between 20 and 24, requiring around 40 ml of mixture to fill the arterial tree completely.

The procedure takes less than 1 hour and requires no previous fixation of the tissues, allowing for subsequent toxicological and pathological studies. It is a direct method that offers the chance to examine the brain right after extraction with no interruption of the usual autopsy procedure.

The success of this technique depends on the following factors, also noted by other authors [1,2]:

1. Cadaver-related factors:
 - Recently dead specimens have to be used to avoid damaged brain tissue.
 - Early and adequate head handling
 - Young specimens' arteries are less likely to suffer from stenosis, occlusions or other vascular degenerative diseases.
2. Silicone-related factors: low viscosity, light consistency and shorter solidifying time proved to be better.
3. Autopsy-related factors:
 - Extracting the heart prior to the injection of silicone helps reducing retrograde intracranial blood pressure.
 - Investigator's ability and training.

Cases in which the method was not successful were mainly those with congestive brain tissue, subdural and parenchymal massive hemorrhages and damaged arteries that block distal filling of the vessels. Also, some types of silicone proved to be useless for unknown reasons possibly related to viscosity, consistency and solidification time.

The technique works very well in the following assessments:

- Morphologic and morphometric analysis of blood vessels, evincing and delineating distribution, branches and anatomical variants. Up to 0.02mm diameter arteries can be seen and measured.
- Intraluminal and endothelial alterations such as blood clots or atheromatous plaques. Measurement of the stenosis of arterial inner surface.
- Aneurysms and malformations of intracranial arteries, as well as leakage sites.
- Cortical perfusion defects. A reduction in cortex vascularization could be related to vascular cognitive and neurodegenerative diseases.
- Vascular disturbances caused by tumors could also be studied using this technique although the experience in this specific field is still limited.

All this is especially important during an autopsy, as it can lead to the cause of death, complementing the forensic diagnose. In addition, injection of colored silicone into the vascular

tree can enhance the educational value of cadaveric head dissections and can be useful in anatomical and neurosurgical learning.

DISCUSSION

This study has developed an innovative technique that allows for a quick and complete examination of the cerebral vascular tree without relevant interruption of the usual autopsy process. It reproduces a fully detailed arterial brain circulation and it has had some encouraging results when applied to difficult or complex medico-legal cases as well as clinical autopsies.

This procedure offers several advantages when compared to previous studies. Firstly, it is faster and requires no additional fixation of brain tissue or vessels, thus simplifying the process and saving materials. This can be evinced when compared to other studies such as those undertaken by other investigators [1-12]. It also reduces the need for complimentary studies during the autopsy.

Vinylpolisiloxane silicone had not been used before in forensic studies. It offers some advantages in comparison to other materials used in previously published literature: self-curing silicones [1,2], elastomers [3], colored-latex [4,5], polyurethane [6] or different procedures with resins [7,8,9,10], as both economic and rapidity in time, among others. The solidifying time of vinylpolisiloxane is significantly quicker than other mixtures [1,4,7].

However, this method also presents some limitations. Firstly, it can be expensive for the forensic budget. Future studies could explore the possibility of using cheaper silicone alternatives such as industrial molding silicones, as this could lead to the standardization and regular application of this method. Secondly, this method cannot be used in cases showing high intracranial pressure and brain tissue congestion, severe traumatic brain injury, or in corpses at an advanced state of decomposition or which show anatomical alterations due to the cause of death or other conditions. Furthermore, brain venous system cannot be examined with this technique yet, leaving it as a possible future line of research.

References

1. Duvernoy H, Delon S, Vannson JL. The vascularization of the human cerebellar cortex. *Brain Res Bull.* 11 (1983) 419–480
2. El Khamlichi A, Azouzi M, Bellakhdar F, Ouhcein A, Lahlaoui A. Anatomic configuration of the circle of Willis in the adult studied by injection technics. A propos of 100 brains. *Neurochirurgie.* 31 (1985) 287–293
3. Sanan A, Aziz KM, Janjua RM, et al. Colored silicone injection for use in neurosurgical dissections: anatomic technical note. *Neurosurg.* 45(5) (1999) 1267-71
4. Kaya AH, Celik F, Sam B, et al. A quick-solidifying, coloured silicone mixture for injecting into brains for autopsy: Technical report. *Neurosurg Rev.* 29(4) (2006) 322-6
5. Forero P. Variaciones del círculo arterial cerebral (Willis) y de las arterias cerebrales. Un estudio anatómico directo. [Tesis doctoral]. Bucaramanga: Departamento de Patología. Universidad Industrial de Santander. (2006)
6. Meyer E, Beer G, Lang A, et al. Polyurethane elastomer: a new material for the visualization of cadaveric blood vessels. *Clin Anat.* 20(4) (2007) 448-54
7. Quintero-Oliveros ST, Ballesteros-Acuña LE, Ayala-Pimentel JO, Forero-Porras PL. Características morfológicas de aneurimas cerebrales del polígono de Willis: estudio anatómico directo. *Neurocirugía.* 20(2) (2009) 110-6
8. Alvernia JE, Pradilla G, Mertens P, Lanzino G, Tamargo RJ. Latex injection of cadaver heads: technical note. *Neurosurgery.* 67 (2 Suppl Operative) (2010) 362-7
9. Reyes-Soto G, Pérez-Cruz J, Delgado-Reyes L, Ortega-Gutiérrez C, Téllez-Palacios D. Asociación de tres variantes anatómicas de circulación cerebral anterior. *Cir Cir.* 80(4) (2012) 333-8
10. Limpastan K, Vaniyapong T, et al. Silicone injected cadaveric head for neurosurgical dissection: Prepared from defrosted cadaver. *Asian J. Neurosurg.* 8(2) (2013) 90-92
11. Martínez F, Spagnuolo E, Calvo-Rubal A, Laza S, Sgarbi N, Soria-Vargas VR, et al. Variaciones del sector anterior del polígono de Willis. Correlación anatomo-angiográfica y su implicancia en la cirugía de aneurismas intracraneanos (Arterias: árgos cerebral anterior, mediana del cuerpo caloso y cerebral media accesoria). *Neurocirugía.* 15(6) (2016) 578-88
12. Urgan K, Toktas Z, et al. A very quickly prepared, colored silicone material for injecting into cerebral vasculature for anatomical dissection: a novel and suitable material for both fresh and non-fresh cadavers. *Turk Neurosurg Online.* (2016)
13. Baena Pinilla S, Obón Nogués J, Arredondo Días J, et al. Solidificación del árbol arterial cerebral y magnificación de la imagen con fines forenses. In XVII Jornadas de la Asociación Nacional de Médicos Forenses (ANMF) (2011) Barcelona.

FIGURES

Fig. 1: Handgun cartridge dispenser 3M Garant™, silicone cartridge, plastic cannula

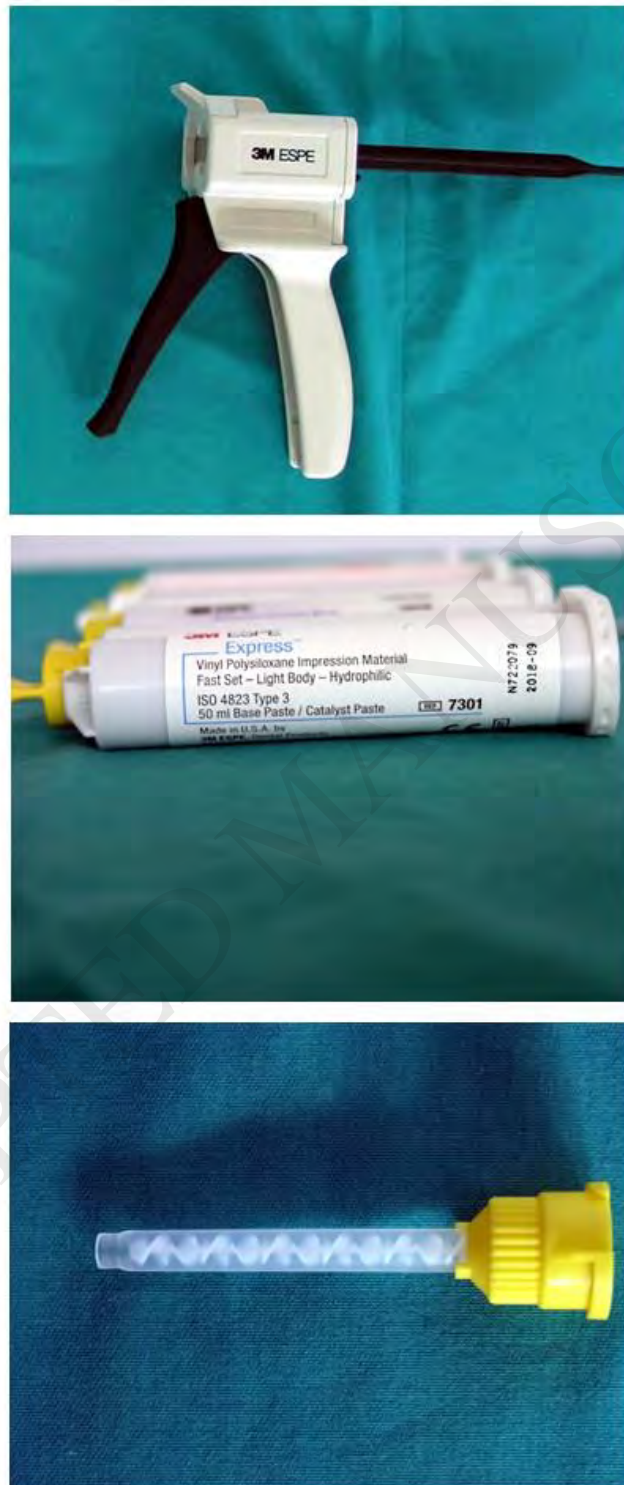

Fig. 2: Dissection of the neck region, carotid artery, internal jugular vein and the vagus nerve

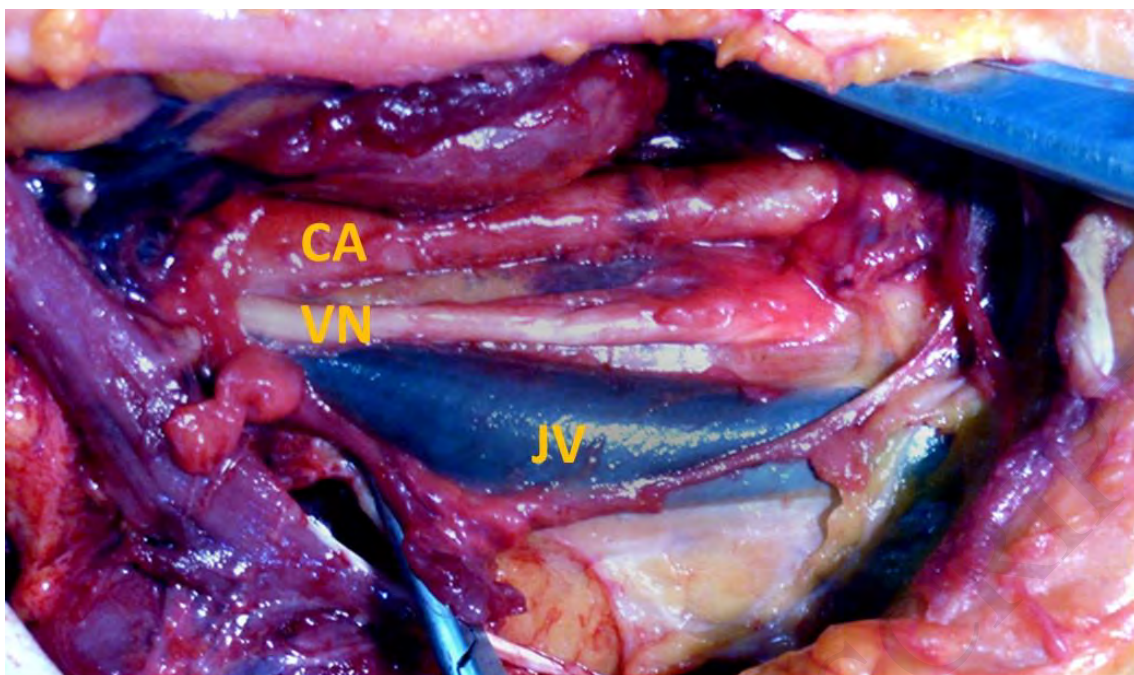


Fig 2 CA: Carotid artery VN: Vagus nerve JV: Jugular Vein

Fig. 3: Introducing plastic cannula in the internal carotid artery

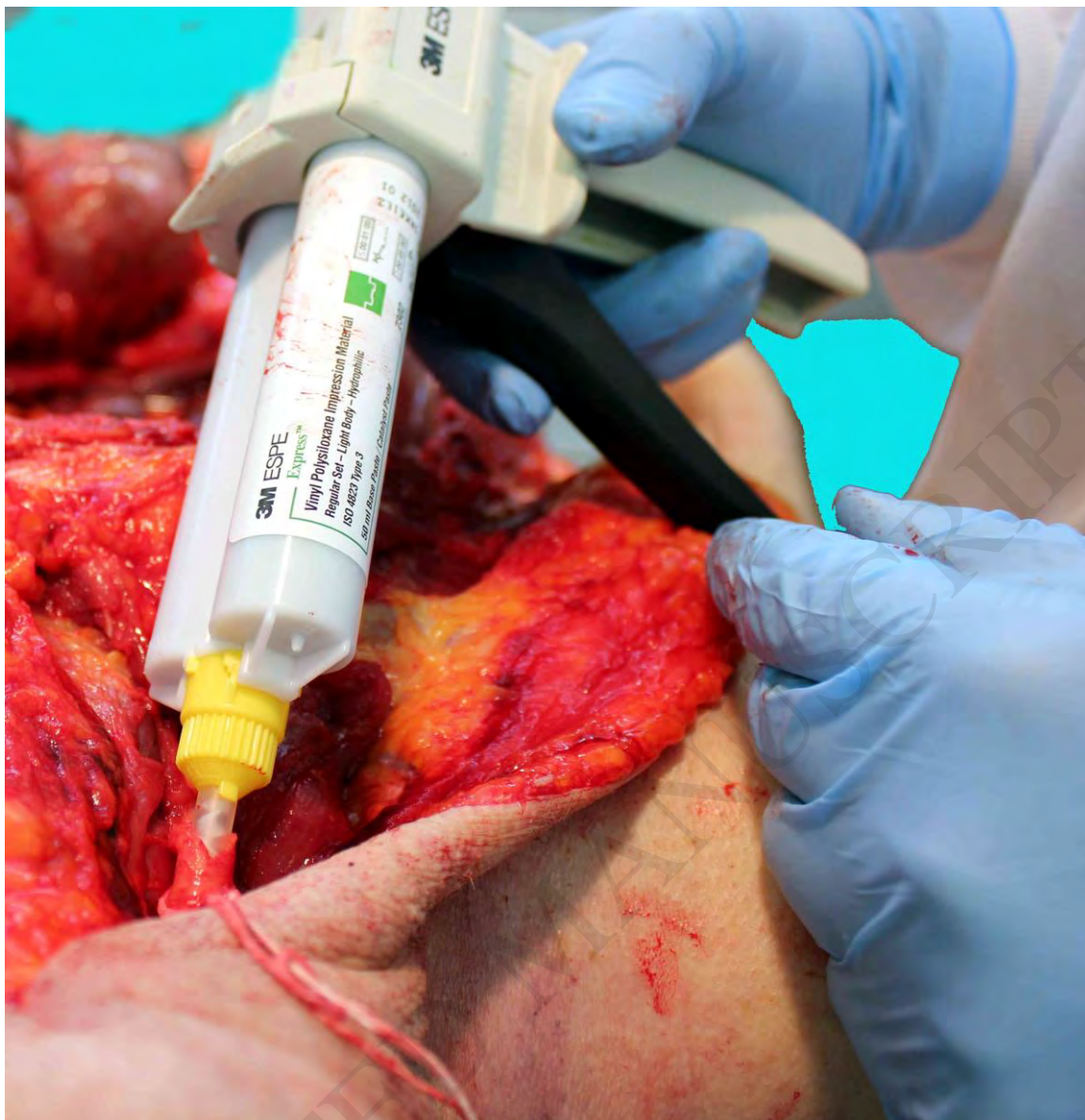

Fig. 4: Brain extraction with already solidified arteries

