

SCIENTIFIC LETTERS

Obstructive jaundice of a parasitic etiology

Key words: *Fasciola hepatica*. Obstructive jaundice. Endoscopic retrograde cholangiopancreatography.

Dear Editor,

Fascioliasis is a parasitic zoonosis caused by *Fasciola* flukes. Humans are accidental hosts that become infected via the consumption of aquatic vegetables or water with metacercariae (1). The clinical manifestations in the chronic phase are colicky pain, jaundice, cholecystitis, cholangitis and biliary obstruction (1-3).

In 2017, a 76-year-old male presented to the Hospital Universitario de León (León, Spain) due to a colic pain in the epigastrium and right hypochondrium of a 1 week evolution, which was accompanied by choluria and acholia, without fever or weight loss. Mucocutaneous jaundice and high values of aspartate aminotransferase (124 U/L), alanine aminotransferase (272 U/L) and C-reactive protein (29 mg/L) were found, whereas the levels of bilirubin (4.1 mg/dL) and eosinophilia (10%) were slightly elevated. Biliary obstruction with stenosis, some septum and microlithiasis inside the common bile duct were observed via abdominal echography and magnetic resonance imaging (MRC) (Fig. 1). Filling defects were observed via therapeutic ERCP (endoscopic retrograde cholangiopancreatography) and 3 mobile forms morpholog-

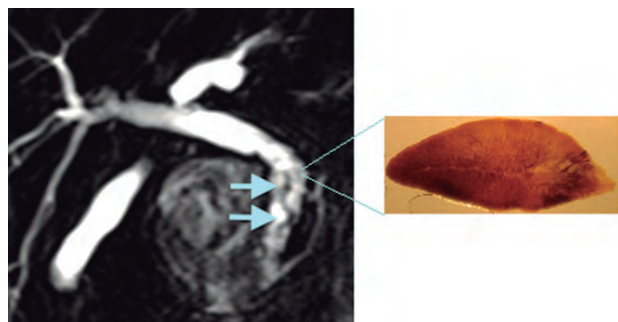


Fig. 1. MRC: sinuous structures inside the common bile duct (arrows) corresponding to parasites.

ically compatible with *Fasciola hepatica* were subsequently extracted after a sphincterotomy.

The patient lived in a rural area in contact with cattle and consumed wild cress. *Fasciola hepatica* eggs were found via a parasitological analysis of stool samples. Serological diagnosis had a titer of 1/1280 and the ELISA MM3 analysis was positive. The patient was treated for 2 days with oral Triclabendazole (750 mg/24 hours) and the subsequent controls were negative.

Fascioliasis is distributed worldwide and is endemic in the Andean highlands (1). In Spain, imported cases have been described (4) and autochthonous cases are restricted to rural areas (5). We highlight that the presence of obstructive jaundice, with or without eosinophilia, that should raise a suspicion of biliary obstruction by *Fasciola hepatica*. The history of water cress intake and parasitological and serological studies should be requested together with the imaging tests.

Acknowledgements: AySA DGA-FSE T51_17R.

M.ª Antonia Remacha¹, Pilar Goñi² and Jesús Espine³

¹Microbiology Service. Hospital Universitario de León. León, Spain. ²Area of Parasitology. Department of Microbiology, Medicine Preventive and Public Health. Faculty of Medicine. Universidad de Zaragoza. Zaragoza, Spain.

³Digestive System Service. Hospital Universitario de León. León, Spain

DOI: 10.17235/reed.2018.5827/2018

References

- Mas-Coma S, Bargues MD, Valero M. Human fascioliasis infection sources, their diversity, incidence factors, analytical methods and prevention measures. *Parasitology* 2018;111:1-35. DOI: 10.1017/S0031182018000914
- Cosme A, Marcos JM, Galvany A, et al. Obstrucción del colédoco por *Fasciola hepática*. *Med Clí* 1979;73:438-42.
- Ha JS, Choi HJ, Moon JH, et al. Endoscopic extraction of biliary fascioliasis diagnosed using intraductal ultrasonography in a patient with acute cholangitis. *Clin Endosc* 2015;48:579-82. DOI: 10.5946/ce.2015.48.6.579
- Guzmán-Calderón E, Vera-Calderón A, Díaz-Ríos R, et al. *Fasciola hepatica* in the common bile duct: spyglass visualization and endoscopic extraction. *Rev Esp Enferm Dig* 2018. DOI: 10.17235/reed.2018.5514/2018
- Dusak A, Onur MR, Cicek M, et al. Radiological Imaging Features of *Fasciola hepatica* Infection – A Pictorial Review. *J Clin Imaging Sci* 2012;2:2. DOI: 10.4103/2156-7514.92372