

# Gastrointestinal Intervention

journal homepage: [www.gi-intervention.org](http://www.gi-intervention.org)

## Review Article

## Enteral stents: Complications and their management

Jorge E. Lopera,<sup>1,\*</sup> Miguel Angel de Gregorio,<sup>2</sup> Alicia Laborda,<sup>2</sup> Rodrigo Castaño<sup>3</sup>

### A B S T R A C T

The treatment of malignant colonic and gastric outlet obstruction with self-expanding metallic stents (SEMS) is an established technique that can be performed by radiologic or a combination of radiologic and endoscopic guidance. The procedure is very effective to relieve the obstructive symptoms of advanced malignancies, with important clinical benefits and significant improvement in quality of life for the patients. Despite much advancement in the designs of SEMS, enteral stent placement is still associated with some significant early and late complications. Stent dysfunction mainly caused by tumor ingrowth/over growth, and stent migration when covered stent are used, are relatively common complications and many times require reinterventions.

Copyright © 2016, Society of Gastrointestinal Intervention. All rights reserved.

Keywords: Colonic neoplasms; Complications; Gastric outlet obstruction; Pancreatic neoplasms; Self-expandable metal stents

### Introduction

The clinical use of enteral self-expanding metallic stents (SEMS) has evolved over the years, when initially introduced, SEMS were used primarily for relieving obstructive symptoms in terminal cancer patients, clinical applications have now expanded to include patients with benign stenosis and other benign conditions such as post operative leaks. The initial enthusiasm for enteral stenting has been somewhat dampened by the myriad of complications, many requiring reinterventions. Long-term complications have been relatively common and the utility of SEMS in the palliation of certain gastrointestinal malignancies compared with the traditional surgical methods has been recently questioned. Twenty years of experience with SEMS has taught us many important lessons in a field that is still evolving, while the search for the ideal SEMS continues. The purpose of this chapter is to review the early and late complications of enteral (colonic and gastroduodenal [GD]) SEMS and their management.

### Complications after Colonic Stent Implantation

Colorectal cancer (CC) is the third most common malignancy and the third leading cause of cancer death in the civilized world.<sup>1</sup>

The prognosis of CC has improved due to advances in diagnosis and therapy. CC occasionally presents with urgent symptoms, such as rectal bleeding, perforation and obstruction. Colorectal acute malignant obstruction occurs between 8% and 29% of patients with CC, and this situation requires urgent treatment because of the possibility of serious complications, such as perforation, colonic necrosis and septic shock complications.<sup>2</sup>

Acute malignant colorectal obstruction causes high morbidity and mortality,<sup>3–5</sup> and is a poor prognostic factor.<sup>6–8</sup> Emergency surgical decompression is the gold standard for the treatment of acute malignant bowel obstruction. In these circumstances, the mortality and morbidity of emergency surgery are higher than for elective surgery.<sup>8,9</sup> Approximately 50% of patients undergoing this surgery end up with a permanent stoma, which worsens the quality of life of patients.<sup>10</sup>

Currently an effective, safe and feasible alternative for these patients with malignant colorectal obstruction is decompression by SEMS.<sup>11–14</sup> The normalization of intestinal transit by stenting via fluoroscopic or endoscopic facilitates elective surgery, decreases surgical time and avoids temporary or permanent stoma.

Both endoscopic and fluoroscopic techniques for SEMS placement have their advantages and disadvantages. Technical results are similar between the two techniques in the majority of series.<sup>15</sup>

<sup>1</sup>Department of Radiology, UT Health Science Center at San Antonio, San Antonio, TX, USA

<sup>2</sup>Minimally Invasive Techniques Research Group (GITMI), University of Zaragoza, Zaragoza, Spain

<sup>3</sup>Gastrohepatology Group, Universidad de Antioquia, Medellín, Colombia

Received February 1, 2016; Revised February 10, 2016; Accepted February 11, 2016

\* Corresponding author. UT Health Science Center at San Antonio, 7703 Floyd Curl Drive, San Antonio, TX 78229, USA.

E-mail address: [Lopera@uthscsa.edu](mailto:Lopera@uthscsa.edu) (J.E. Lopera).

Endoscopic guidance is very useful for proximal lesions and when very tortuous anatomy is present. In recent years dedicated colonic stents have been available with more flexible stents and longer delivery systems that have resulted in lesser incidence of device related complications; despite these recent advances, the overall re-intervention rate is still high and the ideal colorectal stent is yet to be developed.<sup>16</sup> Complications after colorectal stent placement are usually minor but severe life-threatening complications can develop any time after the procedure.<sup>17</sup>

### Frequency and Types of Complications

Complications are divided in early (< 30 days) and late (> 30 days) complications. Complications are also classified as minor complications, when they are self-limited and do not require additional interventions, while major complications are those that require additional interventions, hospital admission or lead to patient's death.

Perforation is the main early complication in all published series regardless of radiologic guidance, endoscopic guidance, or a combination of the two (range, 0%–13%). Minor complications related to colon stent placement such as mild to moderate rectal bleeding, transient anorectal pain, temporary incontinence, and fecal impaction are common in many reports (Table 1).<sup>16–26</sup>

Late complications related to SEMS mainly include re-obstruction and migration of the stent, and rarely perforation. Migration incidence varies from 4% to 26% and is one of the more frequent complications observed at early follow-up.<sup>20–26</sup> Obstruction can recur as a result of fecal impaction or tumor ingrowth.<sup>21</sup> Growth of the tumor through the mesh is the main disadvantage of uncovered stents, and its incidence varies from 2% to 20%.<sup>19,20</sup> The use of covered stents could prevent this complication, but with the potential inconvenience of a higher rate of migration.

Although some complications are unavoidable, certain factors

**Table 1 Main Complications after Colonic Stent Placement**

Complication	Incidence (%)
Early complications	
Major	
Death	0–15.0
Perforation	0–12.8
Migration	0–4.9
Re-obstruction	0–4.9
Bleeding	0–3.7
Minor	
Stent failure	0–11.7
Pain	0–7.4
Tenesmus	0–22.0
Fever	-
Late complications	
Major	
Re-obstruction	4–22.9
Migration	1–12.5
Perforation	0–4.0
Minor	
Incontinence	-
Fistula	-

Data based on the European Society of Gastrointestinal Endoscopy (ESGE) Clinical Guideline of the article of van Hooft et al (*Endoscopy*. 2014;46:990-1053).<sup>20</sup>

**Table 2 Some Factors Associated with Colonic Complications after Stent Placement**

Factor	Details
Operator experience	Excessive manipulation can be associated with perforation, most of the time caused by the guidewires trying to cross the obstruction. Inadequate centering of the stent in the lesion can result in early stent migration. Placing a stent that is too short with inadequate covering of the tumor margins can be associated with lack of resolution of the obstructing symptoms. Complications are more common when the procedure is performed by less experienced operators. <sup>15</sup>
Balloon dilatation	Many authors consider pre- or post-procedure balloon dilation of colonic stenosis an absolute contraindication. <sup>13,14</sup> A high incidence of perforations (10%) associated with balloon dilation was reported in review with 568 patients. <sup>21</sup>
Stent type	Certain stents maybe too rigid for the normal curvatures of the colon. A study demonstrated that the use of the Wallstent was associated with higher incidence of technical difficulties such as insufficient stent expansion and stent misplacement; and higher incidence of major complications such as perforation, stent occlusion, migration, stent erosion/ulcer and stent collapse than other stents. <sup>25</sup> Perforation can also be associated with the delivery system of the stent, it has been reported a high incidence of perforation with the use of dual colorectal stent due to the rigidity of the delivery system. <sup>15</sup> Covered stents have been used to prevent reocclusion of the stent by tumor ingrowth but are associated with a much higher incidence of stent migration.
Type of stricture	Higher incidence of stent migration, perforation, need for surgery and procedure related mortality has been reported in patients with extrinsic compression of the rectosigmoid area. However, other studies, reported similar rate of complications than patients with intrinsic lesions. Longer strictures (> 10 cm) also had worse outcomes than shorter strictures; possibly due to longer strictures tend to involve the curvatures of the colon. Angulated lesions have higher rate of stent migration and perforations, these types of lesions are usually seen in the rectosigmoid area. Some series report a higher incidence of overall complications when the obstruction is complete, this could be related to microperforations caused by the obstruction and/or technical difficulties when crossing the lesions with higher manipulations. Others reported higher clinical failures in case of complete obstructions. <sup>15</sup>
Chemoradiation use	The use of chemoradiation before and after colonic stents has been associated with a higher incidence of perforation and stent migration. Migration can be explained by improvement in the stenosis with tumor shrinkage after chemoradiation. In many of these patients there is no recurrence of the obstruction after stent migration and additional interventions may not be required. <sup>14</sup> The recent use of bevacizumab, an antiangiogenic agent in combination with other chemotherapy drugs have resulted in higher bowel perforation rates compared with controls in the absence of colonic stent placement. Perforations are more common and also appear to occur earlier in patients with palliative colonic stents taking bevacizumab. <sup>26</sup>

can be associated with a higher incidence of major complications (Table 2).<sup>13-15,21,25,26</sup>

### Minor Complications

In general minor complications only require clinical observation and most resolve without reinterventions.

#### Stent failure

Due to the rigidity of the tumor or by being located in a very acute angle, after proper release, the stent does not open enough to restore intestinal transit. In these cases, it is recommended to implant a second coaxial stent to provide more radial strength (Fig. 1).

#### Pain and tenesmus

Pain is one of the most common complains after stent placement. It is usually self-limited and tends to improve over time. If post-stenting pain becomes severe, care should be taken to rule out serious complications such as perforation and/or stent migration. Migration of stents into the anorectal area is also a potential source of significant pain that does not respond to analgesics. In a retrospective study by Song et al,<sup>27</sup> stents placed less than 7 cm from the anus caused significant pain and tenesmus that may require lifelong analgesics or removal of the stent. Retrievable stents seem to be a good choice for patients with low rectal obstructions, since pain, incontinence, or tenesmus are potential severe problems that could be not relieved unless the stents are removed. Currently several retrievable colonic stents are available in Europe and Asia.

#### Bleeding

The most common complication in this category, bleeding is usually related to the pressure of the stent against friable tumor. In the majority of the cases the hematochezia is resolved with conservative treatment. Blood transfusion and surgical intervention are rarely required. Late bleeding can be related to erosion/ulcers of the colonic mucosa by the stents. Occasionally radiation colitis may cause bleeding after stent placement.

### Fecal impaction

Fecal impaction usually presents as sudden onset of bowel obstruction. Diet counseling with a high fiber diet and routine use of laxatives are measures that may help prevent impaction. Once impaction is suspected, cleaning enemas are performed. Impaction may require the radiologist to perform a water soluble enema to diagnose the obstruction followed by flushing of the colon with saline. Endoscopic lavage is also frequently performed. In some cases lavage is not sufficient and mechanical recanalization under fluoroscopic or endoscopic guidance may be required to relieve the blockage. When intervention is required to relieve the impaction, this complication is classified as a major complication.

### Incontinence

This could be a very disabling complication that usually occurs after placement of low rectal stents that may interfere with the anal sphincter function. This complication may require removal of the stent. Patients with tumors located near the rectum need to be counseled about this possible problem before the procedure is performed.

### Bacteremia and fever

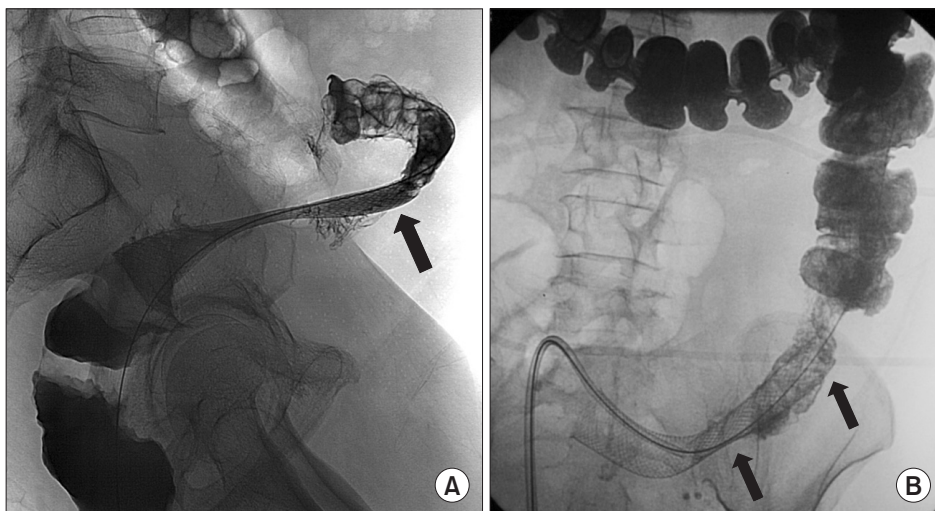
This is an infrequently reported complication; transient bacteremia produced by enteric bacteria has been reported. In spite of this possibility routine antibiotic prophylaxis is usually not recommended.<sup>14</sup>

### Major Complications

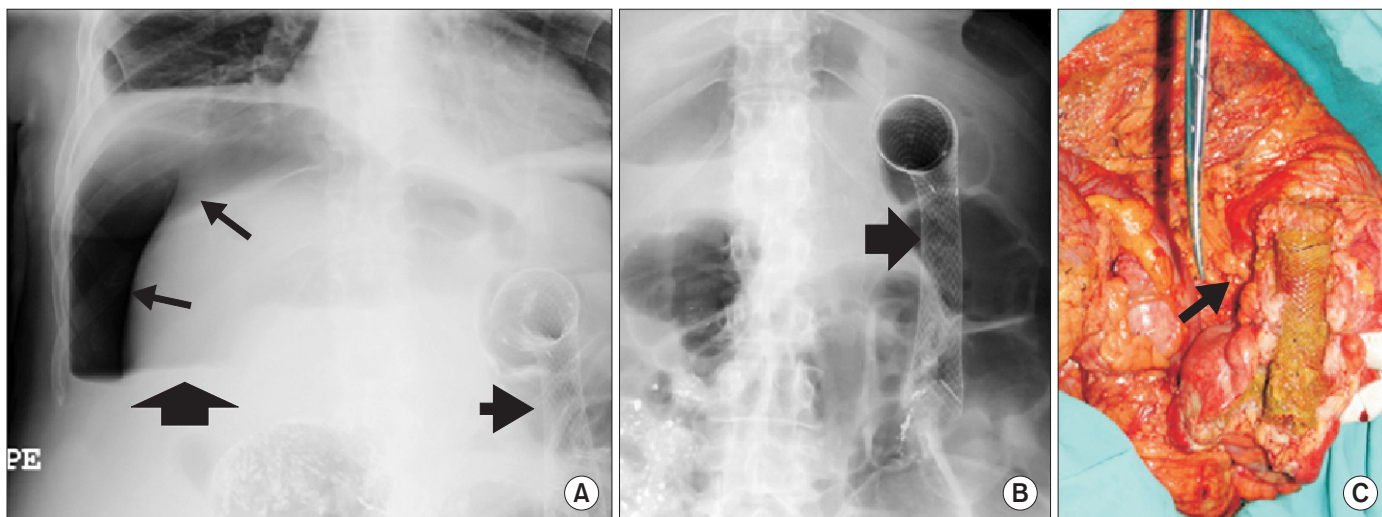
The three most important major complications due to their clinical implications are perforation, migration and reobstruction.

#### Perforation

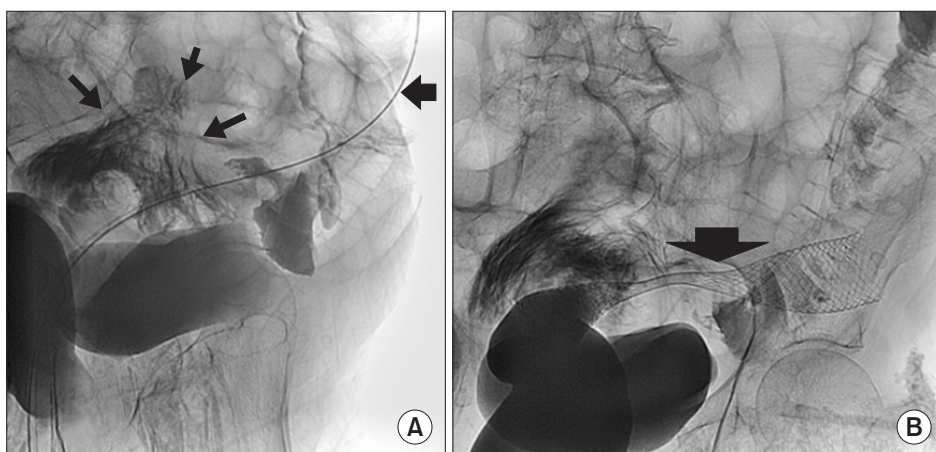
Perforation is the most serious complication after colorectal stent placement and the leading cause of death related to the procedure. Many patients with malignant colonic obstruction have advanced disease and are in a poor medical condition. These patients may not tolerate an exploratory laparotomy and may die soon after the perforation with or without surgery.<sup>14</sup> Perforation



**Fig. 1.** (A) Barium enema shows incomplete expansion of a Wallstent placed in the rectosigmoid area (arrow). Note the severe curvature of the colon distal to the stent. (B) Radiograph shows better stent expansion after placement of a coaxial stent (arrows).



**Fig. 2.** (A) Plain radiograph shows large pneumoperitoneum (arrows) in a patient that complained of severe abdominal pain and peritonitis two days after colonic stent placement. (B) Radiograph shows the stent in the transverse colon (arrow). (C) Photograph of the surgical specimen shows the stent with the site of perforation (arrow).



**Fig. 3.** (A) Radiograph shows extravasation of contrast (arrows) after difficult manipulation of the obstruction. (B) Radiograph shows the deployed stent (arrow). The patient remained without symptoms or signs of perforation and underwent elective surgery 11 days later.

should be suspected when patients develop symptoms of peritonitis (severe pain, fever, leukocytosis) or when free gas is detected at erect radiography after stent placement (Fig. 2). Minimal amounts of free intraabdominal gas are better detected with computed tomography (CT). Perforation can be confirmed as extraluminal contrast leakage on water soluble contrast enemas (Fig. 3). Perforation usually occurs in the first 3 days after stent placement. In a systematic review of 58 publications (598 cases) of stent placement for the treatment of colorectal obstruction, the perforation rate was 4%.<sup>21</sup> Other reported perforation rates range from 7% to 10%.<sup>14</sup> It is often difficult to know if these perforations were iatrogenically caused, preexistent, or worsened by manipulation. The greatest risk of perforation is in the rectosigmoid area. Perforation is usually an acute complication and procedure related. Excessive manipulation with the guidewire, more commonly in higher degrees of obstructions and procedures performed by inexperienced operators, are potential causes of acute perforation (Fig. 3). Balloon dilation before stent placement has been associated with a higher incidence of perforation and its routine use is not recommended. Perforation can also be related to unsuccessful bowel decompression after the procedure.<sup>24</sup> Late perforation

is related to stent pressure into the tumoral area and it is usually stent related. Perforations are also caused by the relatively rigid stents in the normally curved areas of the colon, or when the stents are placed in eccentric positions. The ends of the stents can traumatize the normal colonic mucosa during peristalsis or in the case of flared colorectal stents, cause perforations from pressure necrosis at the ends of the stents.<sup>27</sup> Perforation can also be related to stent migration with unresolved or recurrent bowel obstruction.<sup>15,17</sup> Perforations are almost always managed by emergency surgical exploration (65%). In some cases, limited perforations can be managed with bowel rest and broad spectrum antibiotics. Some limited perforations may present as localized abscesses and percutaneous drainage combined with prolonged broad spectrum antibiotic therapy has been successful in most cases, avoiding a major surgery in these terminal patients. A higher incidence of perforations is seen in patients receiving chemotherapy, especially in patients on bevacizumab.<sup>26</sup> As the overall long-term survival of patients with colon cancer improves with newer chemotherapy regimens improves, the incidence of stent-related complications is likely to increase.

## Migration

Migration rates associated with uncovered stents have ranged from 3% to 12%. The overall migration rates for covered stents are reported to be as high as 30% to 50%.<sup>21</sup> Prosthesis migration does not directly depend on the technique used for placement, but rather on the stent type and on the degree and location of the stenosis, because it is caused by a lack of fixation of the metallic mesh to the tumoral tissue.<sup>14</sup> The narrower the stenosis, the less the possibility of prosthesis migration. Migration rates are higher in the distal third of the descending colon and sigmoid colon because of the greater mobility of these segments. A higher rate of migration has been described in covered stents because of their lower degree of fixation to bowel walls. Migration can occur early and can be related to initial malposition of the stent. To avoid migration it is important to center the stent in the stricture and always use a longer stent that covers 2 to 4 cm of normal colon proximal and distal to the lesion. Manipulation of the stent by rectal exams and colonoscopy can cause displacement of the stents. Migration is more frequent after chemotherapy, laser pretreatment, and dilatation prior to stent insertion, as well as in patients with strictures of benign etiology. Migration can lead to recurrence of the obstructive symptoms, but in many cases the improvement of the stricture after chemoradiation leads to the migration and additional intervention may be not required.<sup>14,19</sup> In most instances, the stent migrates distally and sometimes the stent passes out through the anus (Fig. 4). However, the moving distal end of the migrated stent can cause severe pain or even perforation by the continuous irritation of the colorectal wall.<sup>2</sup> Migration of the stent proximal to the stricture is also possible, these stents are usually not removed due to the technical difficulties, restenting the obstruction is usually performed and the migrated stent is left in place.

Retrieving migrated stents is usually a very uncomfortable and painful procedure especially when significant manipulation is required. Care should be taken to avoid perforation or injury of the rectal mucosa during stent retrieval. The first step is to identify the type of migrated stents and the physical characteristics of the metal. The use of a plastic sheath through anus as protection such as a gynecologic speculum has been reported. Migrated stents can be retrieved using a variety of techniques. The choices

for fluoroscopic retrieval are more limited than the endoscopic techniques. Reported techniques include using snares to grab the ends of the stent, folding the stent after passing a wire through the stent lumen that then is snared, using special cups, forceps or finger extraction.

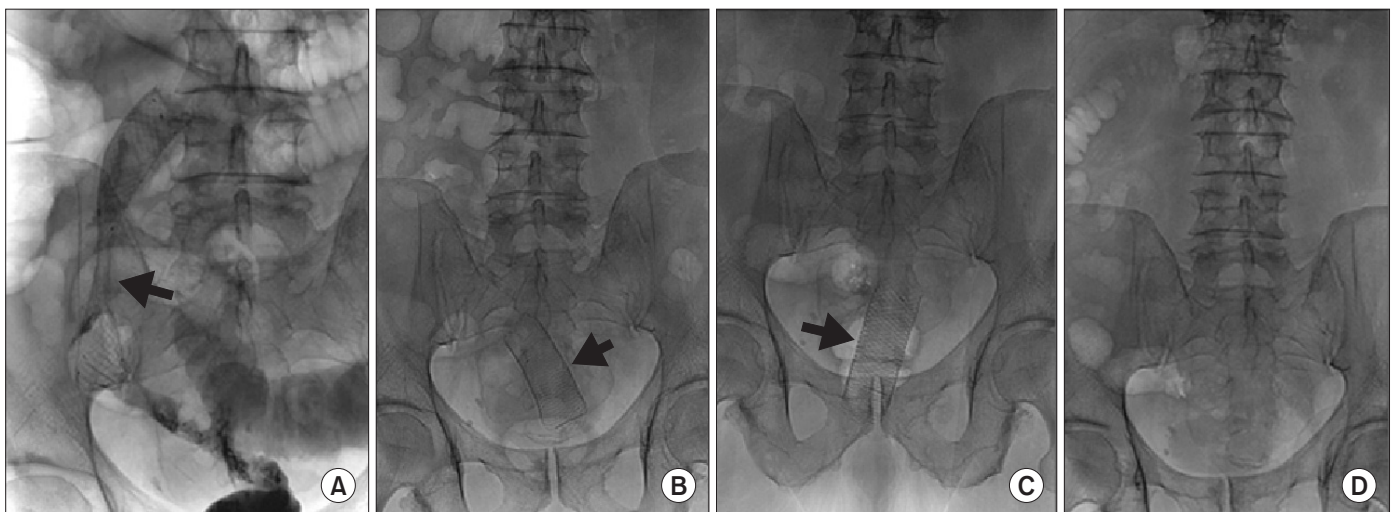
Many colorectal SEMs used in Asia and Europe have a retrieval systems that allow easy and atraumatic removal. The drawstring of the systems allows collapsing the distal end of the stent to facilitate retrieval.<sup>23</sup> The drawstring can be grabbed with a special hook under fluoroscopic guidance or with a forceps under endoscopic guidance. In some cases the drawstring is broken or embedded in the mucosa and may not be reachable, stent retrieval can be performed using the eversion technique where the more distal end of the stent is grabbed with the hook and the stent is everted and retrieved.<sup>28</sup> Another described technique is to grab the proximal mesh at the end of the stent and retrieve the stent in an expanded form.<sup>28</sup> Some stents can become encased by the colonic mucosa and may be impossible to remove; excessive manipulation may result in mucosal injury, perforation or severe bleeding.<sup>27</sup>

## Reobstruction

Colonic reobstruction is primarily reported in patients with colorectal SEMs placed for palliation. The median rate of reobstruction is 12% (range, 1%–92%). The majority of reobstructions result from tumor invasion.<sup>20</sup> Rarely stent collapse or stent fracture can lead to reocclusions. Stent obstructions occur from 48 hours to 480 days after placement and treatments included laser therapies to ablate obstructing tissue, restenting, surgery, and colonic irrigation.<sup>14,17</sup> In most cases restenting provides a definitive solution. Covered stents have a lower incidence of tumor ingrowth, but technical difficulties during deployment due to larger delivery systems, and a higher incidence of stent migration, have precluded a wider acceptance of this type of stents in the colon. Stoma creation may be ultimately required for patients that develop reobstruction when restenting and/or other minimally invasive alternative are not possible.

## Complications of Gastroduodenal Stenting

Gastric outlet obstruction (GOO) is a common complication



**Fig. 4.** (A) Posteroanterior radiograph shows a Wallstent placed in the rectosigmoid (arrow). (B, C) Anteroposterior radiographs taken 2 and 3 days after stent placement shows migration of the stent into the rectum (arrows). (D) Radiograph shows that the stent is no longer present. The stent was defecated.

**Table 3 Main Complications after Gastroduodenal Stent Placement**

Complication	Incidence (%)
Major	
Perforation	< 2
Migration	
Non covered stent	0–6
Covered stent	20–56
Partially covered	11
Stent dysfunction	3–46
Pancreatitis	Rare
Biliary obstruction	3–6
Bleeding	1–6
Minor	
Pain	2–8
Low grade fever	< 5
Stent collapse	0.3–1.9
Incomplete expansion	0.9

of some advanced malignancies, especially gastric cancer in the East, and pancreatic cancer in the West. Placement of SEMS has become a widely accepted alternative for the palliation of obstructive symptoms in patients that are not considered surgical candidates for tumor resection. The overall incidence of complications of GD stenting varies from 17% to 36% (Table 3).<sup>29–33</sup> Most randomized studies and meta analysis have demonstrated that GD stenting is associated with a decrease in the hospitalization days, faster initiation of oral intake and overall lower cost than surgical gastrojejunostomy; however, after 60 days, surgery has better oral intake rates than SEMS in some recent studies.<sup>30</sup> The higher reintervention rates and shorter patency of GD stents than surgery is mainly because of stent malfunction due to migration and stents occlusion.<sup>30,34</sup> Recent recommendations suggest that surgery may be a better option for patients where the expected survival is longer than 2 months, while patients with advanced disease, metastasis, severe malnutrition, concomitant biliary obstruction or poor performance status may benefit more from SEMS.<sup>35,36</sup> Nonetheless, SEMS placement is still considered the treatment of choice over surgical palliation in many institutions due to its less invasive nature.

### Procedural Complications

Adequate planning of the procedure and proper patient preparation are essential to prevent complications. Review of the previous radiological images such as upper digestive series and/or CT scans is very important in order to determine the length and location of the stenosis, rule out perforation and identify any additional sites of distal obstruction. Placement of a proximal stent may not relieve the obstruction in patients with multiple sites of obstruction; a potential problem in patients with advanced malignancies and peritoneal carcinomatosis. Early in the experience with GD stents, the use of the gastrostomy route was many times necessary, as the available stents were too short and too rigid. Additional complications related to the gastrostomy access have been reported such a leakage of ascites fluid.<sup>37</sup> Nowadays the use of this route is seldom required.

Aspiration of gastric contents can be a fatal complication in

these debilitated patients. The dilated stomachs should be drained with a nasogastric tube before the procedure, this will not only prevent aspiration, but also facilitates placement of the stent, as advancement of the stent delivery system in very dilated stomach can be very challenging.<sup>38</sup>

### Minor Complications

#### Abdominal pain

Most patients feel mild abdominal discomfort for a few days after GD SEMS placement. The pain disappears spontaneously in most patients within 1 to 3 days. Rarely patients may require analgesics until they die. The incidence of this complication varies from 2% to 8%.<sup>39,40</sup> The mechanism of pain is mostly unknown but potential reasons for pain include pressure of the stents against the tumor, sharp ends of the stent against the intestinal mucosa causing penetration/perforation. The presence of severe pain requires urgent investigation with CT scan and/or abdominal radiographs to rule out perforation. Chronic incapacitating pain is caused many times by the malignancy itself. In patients with pancreatic cancer with refractory pain, celiac ganglion block by radiological or endoscopic techniques can be very effective.

#### Low grade fever

Low grade fever can occur soon after SEMS placement; the exact incidence is not well reported. Most of the time fever resolves spontaneously within 1 to 2 days. The presence of high fevers should prompt an investigation to rule out serious complications such as perforation, cholangitis or abscess formation.

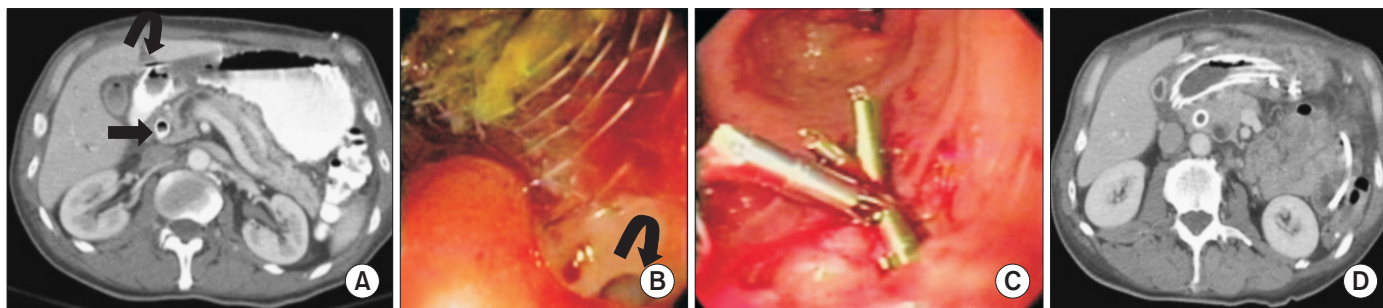
#### Stent collapse and incomplete expansion

The radial force of the stents varies among the different manufacturers. Some tumors have a very hard consistency and the stent won't expand but itself and may require balloon dilatation. The incidence of stent collapse seems to be higher with covered than with uncovered SEMS (1.9% vs 0.3%). The incidence of incomplete expansion is 0.9%.<sup>33</sup> In some rare cases even after balloon dilatation the stent won't expand completely and the patient may require dietary restrictions to a semi solid diet.<sup>41</sup>

### Major Complications

#### Bleeding

Significant gastrointestinal bleeding requiring blood transfusions or additional intervention is very unusual after placement of GD stenting. Most episodes of bleeding are self-limited and resolve spontaneously, with a reported incidence of 1% to 6% (average 4.1%).<sup>33,39,40</sup> Major bleeding has an incidence of 0.8%.<sup>33</sup> Friable tumors can bleed during the instrumentation to place the stent. Other potential causes of bleeding include pressure of the mesh of the stent over the tumors, sharp ends of some stents against the intestinal mucosa, or the pressure of the ends of the stents in angulated areas of the duodenum that can create areas of ulceration with associated bleeding. Bleeding can present as hematemesis or melena. Fatal bleeding is very rare but has been reported.<sup>41</sup> Management of bleeding includes initial stabilization of the blood pressure, correction of any coagulation disorders and blood transfusion. An initial upper endoscopy with possible cauterization or clipping of the bleeding sites is performed. In refrac-



**Fig. 5.** (A) Axial computed tomography (CT) with oral and intravenous contrast shows a contained perforation with free air near the edge of a duodenal stent (curved arrow). Note a metallic biliary stent (arrow). (B) Upper endoscopy reveals the perforation caused by the edge of the stent (curved arrow). (C) Upper endoscopy after stent removal shows clip placement to seal the perforation. (D) Axial CT scan shows placement of a new stent with successful exclusion of the perforation.

tory cases, catheter angiography with embolization is performed. Surgical intervention is rarely required. Tumoral bleeding can be controlled with additional radiotherapy. Massive bleeding related to an aorto-enteric fistula has been reported in one case that was managed with placement of a stent-graft in the aorta.<sup>42</sup>

### Perforation

Perforation can be an early or late complication. This complications is relatively rare (1.2%) but can have devastating consequences.<sup>33,43,44</sup> Some perforations are related to technical problems with stent deployment and advancement of the delivery system, especially in long and tortuous stenosis. Perforations can be caused by the guidewire, the stent delivery system or after balloon dilatation.<sup>33</sup> Procedural related perforations can be detected when extravasation of the contrast material is noted and can be managed by placement of a covered stent.<sup>11</sup> Potential mechanism of late perforation include stent migration, pressure ischemia/necrosis by the end of the stents, or penetration of the sharp end of the stents (Fig. 5).<sup>38–40,45</sup>

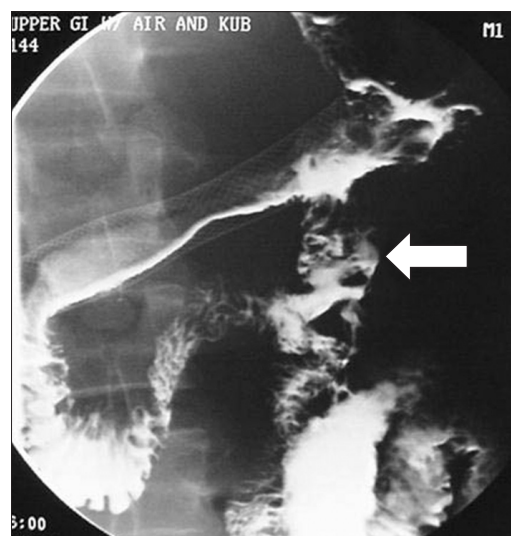
In most cases perforations are recognized when patients complain of severe abdominal pain and CT scans show the presence of free air. In most patients emergency laparotomy is required to close the perforation. Given the poor general condition of many of these patients, perforations are associated with high mortality rates. Some contained perforations may result in localized abscesses that be drained surgically or percutaneously. Focal perforations can be managed with stent removal and clip placement to seal the perforation or with placement of a covered stent. Some contained perforations can result in fistulas to the biliary or gastrointestinal system that may be detected incidentally during follow-up (Fig. 6).<sup>37</sup>

### Pancreatitis

Pancreatitis is a rarely reported after GD stent placement. One case of moderate pancreatitis was reported by Kanno et al<sup>46</sup> and two cases by Maetani et al<sup>47</sup> with the use of esophageal stents in the GD area. Postulated mechanisms include obstruction of the pancreatic duct by the stent, or most likely the axial and radial forces exerted by the stent over the pancreas.

### Stent dysfunction

The exact incidence of stent dysfunction is not really known as many terminal patients are too sick to have additional studies. The poor oral intake is many times attributed to stent dysfunction,

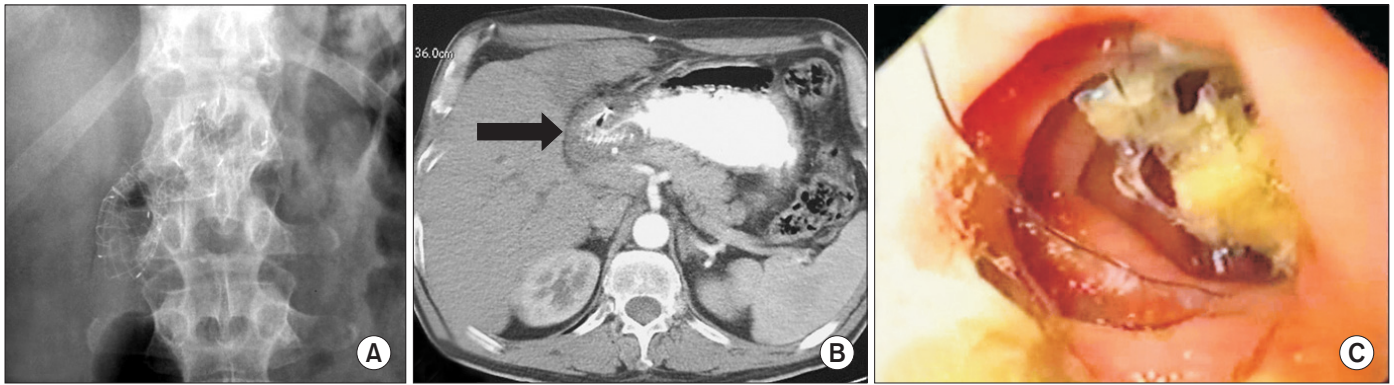


**Fig. 6.** Oblique upper gastrointestinal series with oral contrast shows a fistula between the duodenum and the jejunum (arrow) after placement of a duodenal stent. Patient was asymptomatic.

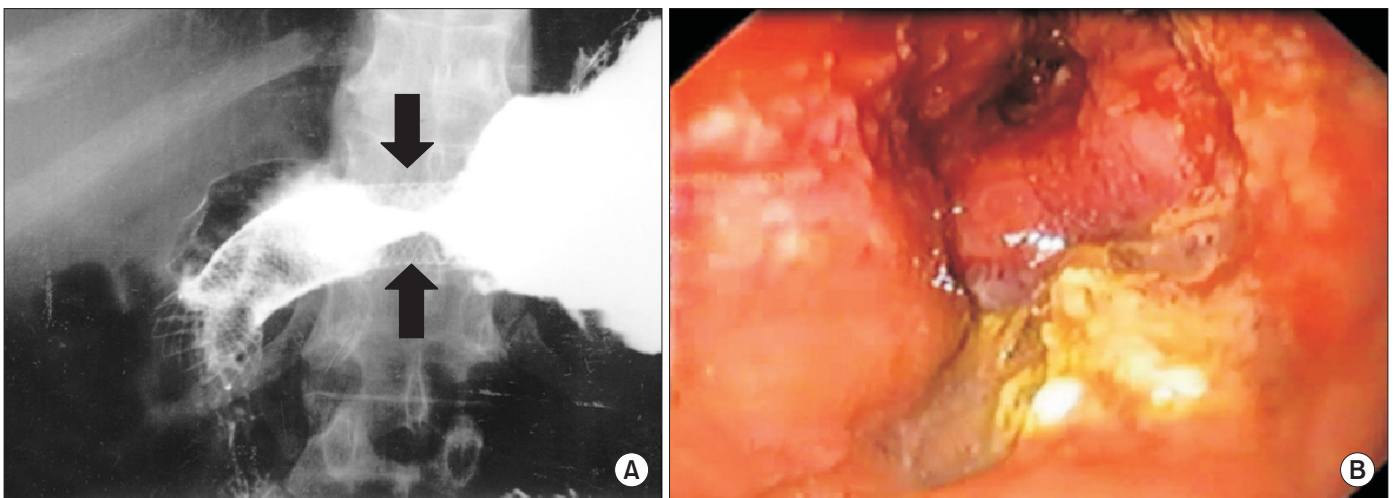
but other factors such severe anorexia, motility disorders refractory to prokinetic medications, and distal obstructions may cause the poor food tolerance.<sup>40</sup>

Overall recurrent obstruction rates varies from 3% to 46% with an average of 19.6%.<sup>33,35,39</sup> As palliative chemoradiotherapy regimens improve survival, the problem of stent dysfunction becomes an even more significant. Stent dysfunction can be related to incomplete stent expansion, stent collapse, stent migration, stent fracture (Fig. 7) and stent obstruction caused by tumor ingrowth or tumor overgrowth (Fig. 8).

Tumor ingrowth/overgrowth have been reported in 17.2% of patients who receive bare metal stents and 6.9% of those with covered stents.<sup>41,48</sup> However, the stent migration rates with covered stents have been very high. Tumor ingrowth has been also a problem with the use of some covered stents, as the polyurethane or silicone of the membrane covering some stents can disintegrate over time due to mechanical damage and/or chemical disintegration.<sup>48</sup> The use of more permanent materials such as polytetrafluoroethylene (PTFE) or nylon has reduced this problem.<sup>48,49</sup> Jang et al<sup>48</sup> reported an incidence of tumor overgrowth of 0.8% with the use of a dual stent covered with a nylon membrane with tumor obstruction occurring later after and more commonly in the duo-



**Fig. 7.** Patient with malignant gastric outlet obstruction treated with a Wallflex now with recurrent obstruction. (A) Plain film shows fracture of the metallic stent. (B) Computed tomography scan shows fractured stent with severe tumor ingrowth (arrow). (C) Upper endoscopy in another patient with fractured stent.



**Fig. 8.** Upper gastrointestinal series (A) and endoscopy (B) show tumor ingrowth (arrows) of a gastroduodenal uncovered stent, patient was treated with a second covered stent.

denal region.

Some studies support that the use of chemotherapy after stent placement is associated with improved stents patency,<sup>31,40</sup> while others<sup>50</sup> studies show that it does not improve stent patency in patients with malignant GOO. It has also been suggested that aggressive tumors such as pancreatic cancers tend to have shorter times for stent occlusion than other type of malignancies.<sup>51</sup>

In most cases the reobstruction is treated with additional stent placement with excellent technical and clinical success rates. The occlusion rates after secondary SEMS placement varies from 10% to 34%. Complications described after secondary stenting include perforation that may be more frequent with overlapping stents placed in the curved portions of the duodenum placement, especially when more rigid stents are used.<sup>39,48,52,53</sup>

When a patient presents with recurrent obstruction a careful evaluation of the overall patient condition and performance status is required to decide the best palliation method. Some patients in terminal stages may be better managed with supportive therapies, while others require reinterventions. In most cases revision of the occluded stents is done by endoscopic or radiological methods with secondary stent placement. Surgical or laparoscopic gastrojejunostomy is also a good alternative in those patients that still have a reasonable life expectancy. Recently the use of endoscopic

ultrasound (EUS)-guided gastrojejunostomy with placement of a covered stent has been reported.<sup>54</sup>

### Stent migration

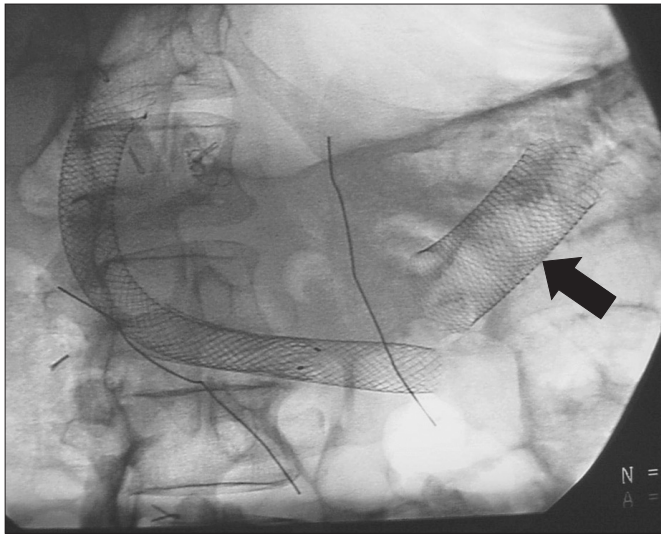
The incidence of stent migration of non-covered stent is relatively low varying from 0% to 6% (average 2.2%). The mesh of the stent tends to get embedded in the duodenal or gastric mucosa preventing migration.<sup>33,40,41</sup>

Placement of stents of appropriate length to cover the tumor at least 2 cm proximal and distal to the end of the obstruction is very important to prevent migration, as shorter and/or overlapping stents can migrate more frequently. When using braided stents such as the Wallstent and the Wallflex, the significant shortening of these stents needs to be taken into consideration to cover the lesion appropriately.

Migration with covered SEMS is common with frequencies of 20% to 56%<sup>32,33,43,55</sup> while migration rates for partially covered stents are 10.9%.<sup>33</sup> Placements of covered stents in the C loop of the duodenum and at anastomosis have a greater tendency to migrate.<sup>56</sup> Another cause of migration is the use of chemoradiation with tumor shrinkage.<sup>57</sup>

Various modifications in the designs of the SEMS have been



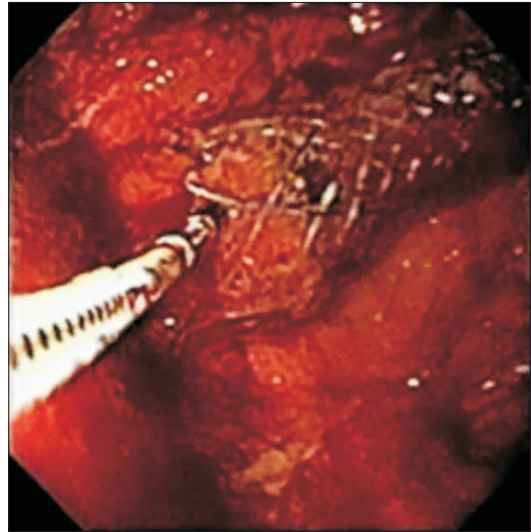


**Fig. 9.** Oblique abdominal radiograph shows distal migration of an overlapping duodenal stent (arrow).

described in order to decrease migration, including stents with an hourglass design, partially covered stents, modified large stents and dual stents.<sup>41,58–60</sup> A recent trial with a “bid cup” stent was stopped prematurely due to high migration rates.<sup>60</sup> Song et al<sup>41</sup> have described their extensive clinical experience using a dual stent where a non-covered stent is placed initially followed by placing covered stent inside, with reported migration rates of 2% to 4% and excellent patency rates.<sup>31</sup> The technique has not gained widespread popularity due to its technical complexity of needing to place two stents, and the fact that the procedures are done by fluoroscopy alone without the use of endoscopy. Recently the use of an endoscopic clip seems have shown to be a very successful technique in preventing stent migration.<sup>61,62</sup>

Migration can be partial or complete, and upwards or downwards. In the duodenal area migration is usually downward (Fig. 9), while upward migration is possible with stents placed in the antrum and pylorus (Fig. 10). Complete distal migration can result in bowel obstruction or perforation requiring surgery.<sup>38</sup> The stents can also pass spontaneously. If a decision is made to observe the migrated stent, close observation is needed to detect any signs of perforation early. In a study of 70 patients with migrated stents, mainly esophageal stents and 11 GD stents, forty migrated stents were removed with retrieval devices under fluoroscopic guidance, 15 stents exited via the rectum, 12 remained in the body without complications and 3 were surgically removed because they caused complicated intestinal obstructions.<sup>56</sup>

The techniques to remove the migrated stents vary between endoscopic and radiological methods. Many of the current stents have a retrieval system to allow collapsing the stent to facilitate removal. The migrated stent can be removed from the stomach using endoscopic or radiologic methods.<sup>38</sup> In terminal patients with no recurrent obstruction or pain caused by the migrated stent, leaving the stent in the stomach can be a safe alternative.<sup>63</sup> Removing a stent that have migrated distally into the small bowel can be very challenging and can be associated with perforation. A careful decision needs to be made if leaving the stent alone is possible with restenting the obstruction if the patient is symptomatic, versus surgical removal or attempt of removal by endoscopic means.<sup>56</sup> Radiological removal of GD stents has been reported in 6 patients by Yoon et al<sup>28</sup> using a retrieval hook to grab the lasso



**Fig. 10.** Upper endoscopy shows forceps grabbing proximal end of a gastro-duodenal stent that migrated into the stomach.

and collapse the stent, grabbing the proximal mesh, or using a technique to cause eversion of stent.

### Biliary obstruction

Patients with malignant GOO can present with biliary obstruction before the intestinal obstruction present with simultaneous biliary and duodenal obstruction, or develop the biliary obstruction after enteral stenting.<sup>29</sup> Prospective studies have shown that biliary obstruction occurs in 2% to 6% of patients following a GD stent placement for malignant GOO.<sup>39</sup>

In patients with GOO, secondary biliary obstruction is most common in patients with malignant tumors that involve the duodenum, especially pancreatic cancer. Placement of a covered stent in a duodenal obstruction may also cause bile duct obstruction by mechanical occlusion of the ampulla of Vater. Recent data suggest that if the patient has no associated biliary obstruction, developing secondary biliary obstruction after placement of a covered GD stent is not as frequent as initially reported. In one study, none of 53 patients with covered stents placed over the papilla developed biliary obstruction.<sup>64</sup> While Kim et al<sup>65</sup> reported only one case of stent caused biliary obstruction after duodenal covered ( $n = 27$ ) or non covered ( $n = 35$ ) SEMS placement under fluoroscopic guidance.

In patients undergoing GD stenting, simultaneous placement of a biliary stent without an overt or impending biliary obstruction, or so called prophylactic biliary stenting, has been a highly controversial issue. When the decision is made to stent both biliary and duodenal system using endoscopy, it is recommended to stent the biliary system first and then place the duodenal stent after, as placing a biliary stent through the mesh of a duodenal stent is technically very difficult.<sup>66</sup> Simultaneous biliary and duodenal stenting has its own challenges and complications. In patients with severe stenosis of the duodenum, balloon dilatation may be required in order to advance the side-viewing duodenoscope, this may result in bleeding, luminal edema and there is a risk of duodenal perforation due to the narrow, acute angulation in the duodenum.<sup>66,67</sup>

When patients with an existing GD stent develop jaundice, biliary stenting through the mesh of the stent can be performed

endoscopically but it is very difficult. Techniques described include balloon dilatation of the mesh, cutting wires or burning the wires with argon plasma coagulation.<sup>68,69</sup> Percutaneous drainage and stenting have a higher technical success.

Recently EUS-guided biliary drainage has been performed successfully through the duodenum or the mesh of an existing duodenal stent. Complications of EUS-guided procedures including bile leaks, peritonitis, pneumoperitoneum, bleeding, and cholangitis, can occur in up to 15% of patients.<sup>70</sup>

In conclusion, treating malignant colonic and GOO obstruction with SEMS is a safe, feasible, and effective procedure for palliation of obstructive symptoms, with important clinical benefits and significant improvement in quality of life for the patients. However, SEMS placement can be associated with some significant early and late complications that many times require reinterventions. While the search for the ideal SEMS continues, judicious use of SEMS in the appropriate clinical situation is of paramount importance. Collaborative and prospective randomized studies are needed to establish the best palliation method in every patient.

### Conflicts of Interest

No potential conflict of interest relevant to this article was reported.

### References

1. Ferlay J, Shin HR, Bray F, Forman D, Mathers C, Parkin DM. Estimates of worldwide burden of cancer in 2008: GLOBOCAN 2008. *Int J Cancer*. 2010;127:2893-917.
2. De Salvo GL, Gava C, Pucciarelli S, Lise M. Curative surgery for obstruction from primary left colorectal carcinoma: primary or staged resection? *Cochrane Database Syst Rev*. 2004;(2):CD002101.
3. McArdle CS, McMillan DC, Hole DJ. The impact of blood loss, obstruction and perforation on survival in patients undergoing curative resection for colon cancer. *Br J Surg*. 2006;93:483-8.
4. Biondo S, Parés D, Frago R, Martí-Ragué J, Kreisler E, De Oca J, et al. Large bowel obstruction: predictive factors for postoperative mortality. *Dis Colon Rectum*. 2004;47:1889-97.
5. Smothers L, Hynan L, Fleming J, Turnage R, Simmang C, Anthony T. Emergency surgery for colon carcinoma. *Dis Colon Rectum*. 2003;46:24-30.
6. Kato H, Yamashita K, Wang G, Sato T, Nakamura T, Watanabe M. Prognostic significance of preoperative bowel obstruction in stage III colorectal cancer. *Ann Surg Oncol*. 2011;18:2432-41.
7. Wang HS, Lin JK, Mou CY, Lin TC, Chen WS, Jiang JK, et al. Long-term prognosis of patients with obstructing carcinoma of the right colon. *Am J Surg*. 2004;187:497-500.
8. Phillips RK, Hittinger R, Fry JS, Fielding LP. Malignant large bowel obstruction. *Br J Surg*. 1985;72:296-302.
9. Mulcahy HE, Skelly MM, Husain A, O'Donoghue DP. Long-term outcome following curative surgery for malignant large bowel obstruction. *Br J Surg*. 1996;83:46-50.
10. Mealy K, O'Brien E, Donohue J, Tanner A, Keane FB. Reversible colostomy--what is the outcome? *Dis Colon Rectum*. 1996;39:1227-31.
11. Watt AM, Faragher IG, Griffin TT, Rieger NA, Maddern GJ. Self-expanding metallic stents for relieving malignant colorectal obstruction: a systematic review. *Ann Surg*. 2007;246:24-30.
12. Tilney HS, Lovegrove RE, Purkayastha S, Sains PS, Weston-Petrides GK, Darzi AW, et al. Comparison of colonic stenting and open surgery for malignant large bowel obstruction. *Surg Endosc*. 2007;21:225-33.
13. Mainar A, De Gregorio MA, Ariza MA, Tejero E, Tobio R, Alfonso E, Pinto I, et al. Acute colorectal obstruction: treatment with self-expandable metallic stents before scheduled surgery--results of a multicenter study. *Radiology*. 1999;210:65-9.
14. de Gregorio MA, Laborda A, Tejero E, Miguélena JM, Camevale FC, de Blas I, et al. Ten-year retrospective study of treatment of malignant colonic obstructions with self-expandable stents. *J Vasc Interv Radiol*. 2011;22:870-8.
15. Kim H, Kim SH, Choi SY, Lee KH, Won JY, Lee DY, et al. Fluoroscopically guided placement of self-expandable metallic stents and stent-grafts in the treatment of acute malignant colorectal obstruction. *J Vasc Interv Radiol*. 2008;19:1709-16.
16. Baron TH. Interventional palliative strategies for malignant bowel obstruction. *Curr Oncol Rep*. 2009;11:293-7.
17. Lopera JE, De Gregorio MA. Fluoroscopic management of complications after colorectal stent placement. *Gut Liver*. 2010;4(Suppl 1):S9-18.
18. Bayraktar B, Ozemir IA, Kefeli U, Demiral G, Sagiroglu J, Bayraktar O, et al. Colorectal stenting for palliation and as a bridge to surgery: a 5-year follow-up study. *World J Gastroenterol*. 2015;21:9373-9.
19. Jost RS, Jost R, Schoch E, Brunner B, Decurtins M, Zollikofer CL. Colorectal stenting: an effective therapy for preoperative and palliative treatment. *Cardiovasc Intervent Radiol*. 2007;30:433-40.
20. van Hooft JE, van Halsema EE, Vanbiervliet G, Beets-Tan RG, DeWitt JM, Donnellan F, et al. Self-expandable metal stents for obstructing colonic and extracolonic cancer: European Society of Gastrointestinal Endoscopy (ESGE) Clinical Guideline. *Endoscopy*. 2014;46:990-1053.
21. Khot UP, Lang AW, Murali K, Parker MC. Systematic review of the efficacy and safety of colorectal stents. *Br J Surg*. 2002;89:1096-102.
22. Shrivastava V, Tariq O, Tiam R, Nyhsen C, Marsh R. Palliation of obstructing malignant colonic lesions using self-expanding metal stents: a single-center experience. *Cardiovasc Intervent Radiol*. 2008;31:931-6.
23. de Gregorio MA, Mainar A, Rodriguez J, Alfonso ER, Tejero E, Herrera M, et al. Colon stenting: a review. *Semin Intervent Radiol*. 2004;21:205-16.
24. Garcia-Cano J, González-Huix F, Juzgado D, Igea F, Pérez-Miranda M, López-Rosés L, et al. Use of self-expanding metal stents to treat malignant colorectal obstruction in general endoscopic practice (with videos). *Gastrointest Endosc*. 2006;64:914-20.
25. Small AJ, Baron TH. Comparison of Wallstent and Ultraflex stents for palliation of malignant left-sided colon obstruction: a retrospective, case-matched analysis. *Gastrointest Endosc*. 2008;67:478-88.
26. Imbulgoda A, MacLean A, Heine J, Drolet S, Vickers MM. Colonic perforation with intraluminal stents and bevacizumab in advanced colorectal cancer: retrospective case series and literature review. *Can J Surg*. 2015;58:167-71.
27. Song HY, Kim JH, Kim KR, Shin JH, Kim HC, Yu CS, et al. Malignant rectal obstruction within 5 cm of the anal verge: is there a role for expandable metallic stent placement? *Gastrointest Endosc*. 2008;68:713-20.
28. Yoon CJ, Shin JH, Song HY, Lim JO, Yoon HK, Sung KB. Removal of retrievable esophageal and gastrointestinal stents: experience in 113 patients. *AJR Am J Roentgenol*. 2004;183:1437-44.
29. Dormann A, Meisner S, Verin N, Wenk Lang A. Self-expanding metal stents for gastroduodenal malignancies: systematic review of their clinical effectiveness. *Endoscopy*. 2004;36:543-50.
30. Jeurnink SM, Steyerberg EW, van Hooft JE, van Eijck CH, Schwartz MP, Vleggaar FP, et al. Surgical gastrojejunostomy or endoscopic stent placement for the palliation of malignant gastric outlet obstruction (SUSTENT study): a multicenter randomized trial. *Gastrointest Endosc*. 2010;71:490-9.
31. Kim JH, Song HY, Shin JH, Choi E, Kim TW, Jung HY, et al. Metallic stent placement in the palliative treatment of malignant gastroduodenal obstructions: prospective evaluation of results and factors influencing outcome in 213 patients. *Gastrointest Endosc*. 2007;66:256-64.
32. Kim JW, Jeong JB, Lee KL, Kim BG, Ahn DW, Lee JK, et al. Comparison between uncovered and covered self-expandable metal stent placement in malignant duodenal obstruction. *World J Gastroenterol*. 2015;21:1580-7.
33. van Halsema EE, Rauws EA, Fockens P, van Hooft JE. Self-expandable metal stents for malignant gastric outlet obstruction: a pooled analysis of prospective literature. *World J Gastroenterol*. 2015;21:12468-81.
34. No JH, Kim SW, Lim CH, Kim JS, Cho YK, Park JM, et al. Long-term outcome of palliative therapy for gastric outlet obstruction caused by unresectable gastric cancer in patients with good performance status: endoscopic stenting versus surgery. *Gastrointest Endosc*. 2013;78:55-62.
35. Stark A, Hines OJ. Endoscopic and operative palliation strategies for pancreatic ductal adenocarcinoma. *Semin Oncol*. 2015;42:163-76.
36. Gray PJ Jr, Wang J, Pawlik TM, Edil BH, Schulick R, Hruban RH, et al. Factors influencing survival in patients undergoing palliative bypass for pancreatic adenocarcinoma. *J Surg Oncol*. 2012;106:66-71.
37. Pinto Pabón IT, Diaz LP, Ruiz De Adana JC, López Herrero J. Gastric and duodenal stents: follow-up and complications. *Cardiovasc Intervent Radiol*. 2001;24:147-53.
38. Bessoud B, de Baere T, Denys A, Kuoch V, Ducreux M, Precetti S, et al. Malignant gastroduodenal obstruction: palliation with self-expanding metallic stents. *J Vasc Interv Radiol*. 2005;16:247-53.
39. Oh SY, Kozarek RA. Management of gastroduodenal stent-related complications. *Gastrointest Interv*. 2015;4:89-94.
40. Telford JJ, Carr-Locke DL, Baron TH, Tringali A, Parsons WG, Gabbrielli A, et al. Palliation of patients with malignant gastric outlet obstruction with the enteral Wallstent: outcomes from a multicenter study. *Gastrointest Endosc*. 2004;60:916-20.
41. Song HY, Shin JH, Yoon CJ, Lee GH, Kim TW, Lee SK, et al. A dual expandable nitinol stent: experience in 102 patients with malignant gastroduodenal strictures. *J Vasc Interv Radiol*. 2004;15:1443-9.
42. Phillips MS, Gosain S, Bonatti H, Friel CM, Ellen K, Northup PG, et al. Enteral stents for malignancy: a report of 46 consecutive cases over 10 years, with critical review of complications. *J Gastrointest Surg*. 2008;12:2045-50.
43. Woo SM, Kim DH, Lee WJ, Park KW, Park SJ, Han SS, et al. Comparison of uncovered and covered stents for the treatment of malignant duodenal obstruction caused by pancreaticobiliary cancer. *Surg Endosc*. 2013;27:2031-9.
44. Graber I, Dumas R, Filoche B, Boyer J, Coumaros D, Lamouliatte H, et al. The efficacy and safety of duodenal stenting: a prospective multicenter study. *Endoscopy*. 2007;39:784-7.
45. Thumbe VK, Houghton AD, Smith MS. Duodenal perforation by a Wallstent. *Endoscopy*. 2000;32:495-7.
46. Kanno Y, Ito K, Fujita N, Noda Y, Kobayashi G, Horaguchi J, et al. Efficacy and safety of a WallFlex enteral stent for malignant gastric obstruction. *Dig Endosc*.

- 2013;25:386-91.
47. Maetani I, Tada T, Shimura J, Ukita T, Inoue H, Igarashi Y, et al. Technical modifications and strategies for stenting gastric outlet strictures using esophageal endoprosthesis. *Endoscopy*. 2002;34:402-6.
  48. Jang JK, Song HY, Kim JH, Song M, Park JH, Kim EY. Tumor overgrowth after expandable metallic stent placement: experience in 583 patients with malignant gastroduodenal obstruction. *AJR Am J Roentgenol*. 2011;196:W831-6.
  49. Jung K, Ahn JY, Jung HY, Cho CJ, Na HK, Jung KW, et al. Outcomes of endoscopically inserted self-expandable metal stents in malignancy according to the type of stent and the site of obstruction. *Surg Endosc*. 2015. doi: 10.1007/s00464-015-4712-x. [Epub ahead of print]
  50. Cha BH, Lee SH, Kim JE, Yoo JY, Park YS, Kim JW, et al. Endoscopic self-expandable metallic stent placement in malignant pyloric or duodenal obstruction: does chemotherapy affect stent patency? *Asia Pac J Clin Oncol*. 2013;9:162-8.
  51. Oh SY, Edwards A, Mandelson M, Ross A, Irani S, Larsen M, et al. Survival and clinical outcome after endoscopic duodenal stent placement for malignant gastric outlet obstruction: comparison of pancreatic cancer and nonpancreatic cancer. *Gastrointest Endosc*. 2015;82:460-8.e2.
  52. Sasaki T, Isayama H, Nakai Y, Takahara N, Hamada T, Mizuno S, et al. Clinical outcomes of secondary gastroduodenal self-expandable metallic stent placement by stent-in-stent technique for malignant gastric outlet obstruction. *Dig Endosc*. 2015;27:37-43.
  53. Kim CG, Choi LJ, Lee JY, Cho SJ, Kim SJ, Kim MJ, et al. Outcomes of second self-expandable metallic stent insertion for malignant gastric outlet obstruction. *Surg Endosc*. 2014;28:281-8.
  54. Tyberg A, Kumta N, Karia K, Zerbo S, Sharaiha RZ, Kahaleh M. EUS-guided gastrojejunostomy after failed enteral stenting. *Gastrointest Endosc*. 2015;81:1011-2.
  55. Waidmann O, Trojan J, Friedrich-Rust M, Sarrazin C, Bechstein WO, Ulrich F, et al. SEMS vs cSEMS in duodenal and small bowel obstruction: high risk of migration in the covered stent group. *World J Gastroenterol*. 2013;19:6199-206.
  56. Ko HK, Song HY, Shin JH, Lee GH, Jung HY, Park SI. Fate of migrated esophageal and gastroduodenal stents: experience in 70 patients. *J Vasc Interv Radiol*. 2007;18:725-32.
  57. Kim CG, Park SR, Choi IJ, Lee JY, Cho SJ, Park YI, et al. Effect of chemotherapy on the outcome of self-expandable metallic stents in gastric cancer patients with malignant outlet obstruction. *Endoscopy*. 2012;44:807-12.
  58. Oh D, Lee SS, Song TJ, Choi JH, Park do H, Seo DW, et al. Efficacy and safety of a partially covered duodenal stent for malignant gastroduodenal obstruction: a pilot study. *Gastrointest Endosc*. 2015;82:32-6.e1.
  59. Lopera JE, Alvarez O, Castaño R, Castañeda-Zuñiga W. Initial experience with Song's covered duodenal stent in the treatment of malignant gastroduodenal obstruction. *J Vasc Interv Radiol*. 2001;12:1297-1303.
  60. van den Berg MW, Walter D, Vleggaar FP, Siersema PD, Fockens P, van Hooft JE. High proximal migration rate of a partially covered "big cup" duodenal stent in patients with malignant gastric outlet obstruction. *Endoscopy*. 2014;46:158-61.
  61. Kim ID, Kang DH, Choi CW, Kim HW, Jung WJ, Lee DH, et al. Prevention of covered enteral stent migration in patients with malignant gastric outlet obstruction: a pilot study of anchoring with endoscopic clips. *Scand J Gastroenterol*. 2010;45:100-5.
  62. Park SY, Park CH, Cho SB, Lee JS, Joo SY, Park HC, et al. The usefulness of clip application in preventing migration of self-expandable metal stent in patients with malignant gastrointestinal obstruction. *Korean J Gastroenterol*. 2007;49:4-9.
  63. Song HY, Park SI, Do YS, Yoon HK, Sung KB, Sohn KH, et al. Expandable metallic stent placement in patients with benign esophageal strictures: results of long-term follow-up. *Radiology*. 1997;203:131-6.
  64. Poincloux L, Goutorbe F, Rouquette O, Mulliez A, Goutte M, Bommelaer G, et al. Biliary stenting is not a prerequisite to endoscopic placement of duodenal covered self-expandable metal stents. *Surg Endosc*. 2016;30:437-45.
  65. Kim SY, Song HY, Kim JH, Kim KR, Shin JH, Lee SS, et al. Bridging across the ampulla of Vater with covered self-expanding metallic stents: is it contraindicated when treating malignant gastroduodenal obstruction? *J Vasc Interv Radiol*. 2008;19:1607-13.
  66. Moon JH, Choi HJ. Endoscopic double-metallic stenting for malignant biliary and duodenal obstructions. *J Hepatobiliary Pancreat Sci*. 2011;18:658-63.
  67. Maetani I, Nambu T, Omuta S, Ukita T, Shigoka H. Treating bilio-duodenal obstruction: combining new endoscopic technique with 6 Fr stent introducer. *World J Gastroenterol*. 2010;16:2828-31.
  68. Kaw M, Singh S, Gagneja H. Clinical outcome of simultaneous self-expandable metal stents for palliation of malignant biliary and duodenal obstruction. *Surg Endosc*. 2003;17:457-61.
  69. Vanbiervliet G, Demarquay JF, Dumas R, Caroli-Bosc FX, Piche T, Tran A. Endoscopic insertion of biliary stents in 18 patients with metallic duodenal stents who developed secondary malignant obstructive jaundice. *Gastroenterol Clin Biol*. 2004;28:1209-13.
  70. Yamao K, Hara K, Mizuno N, Sawaki A, Hijioka S, Niwa Y, et al. EUS-Guided Biliary Drainage. *Gut Liver*. 2010;4(Suppl 1):S67-75.