



THE UNIVERSITY *of* EDINBURGH

Edinburgh Research Explorer

Gender Specific Effects on the Development of White Matter Tracts after Preterm Birth

Citation for published version:

Anblagan, D, Bastin, M, Sparrow, S, Piyasena, C, Pataky, R, Moore, E, Wilkinson, G, Roberts, N, Semple, S & Boardman, J 2014, 'Gender Specific Effects on the Development of White Matter Tracts after Preterm Birth' The International Society for Magnetic Resonance Imaging, Milan, United Kingdom, 10/05/14 - 16/05/14, .

Link:

[Link to publication record in Edinburgh Research Explorer](#)

Document Version:

Peer reviewed version

General rights

Copyright for the publications made accessible via the Edinburgh Research Explorer is retained by the author(s) and / or other copyright owners and it is a condition of accessing these publications that users recognise and abide by the legal requirements associated with these rights.

Take down policy

The University of Edinburgh has made every reasonable effort to ensure that Edinburgh Research Explorer content complies with UK legislation. If you believe that the public display of this file breaches copyright please contact openaccess@ed.ac.uk providing details, and we will remove access to the work immediately and investigate your claim.



Gender Specific Effects on the Development of White Matter Tracts after Preterm Birth

Devasuda Anblagan^{1,2}, Mark E Bastin³, Sarah Sparrow², Chinthika Piyasena⁴, Rozi Pataky⁵, Emma Moore², Graham Wilkinson⁵, Neil Roberts¹, Scott I Semple^{1,4}, and James P Boardman²

¹Clinical Research Imaging Centre, University of Edinburgh, Edinburgh, United Kingdom, ²MRC Centre for Reproductive Health, University of Edinburgh, Edinburgh, United Kingdom, ³Centre for Clinical Brain Sciences, University of Edinburgh, Edinburgh, United Kingdom, ⁴Centre for Cardiovascular Sciences, University of Edinburgh, Edinburgh, United Kingdom, ⁵NHS Lothian, Edinburgh, United Kingdom

Target Audience: Researchers investigating neonatal brain development using diffusion MRI.

Purpose: Preterm delivery affects 11% of all live births worldwide and is a leading cause of neurodevelopmental impairment and suboptimal educational achievement in childhood¹. Some of the adverse neurodevelopmental sequelae of preterm birth are gender-specific: preterm males have a worse neurodevelopmental outcome than preterm females²; gender differences in brain structure after preterm birth have been observed²⁻⁴; and there may be gender specific effects of neuroprotective strategies⁵. Connectivity of developing white matter tracts is altered in association with preterm birth but the neural basis for differential gender effects is unknown. We present the first application of an automatic single seed point tractography-based segmentation method, probabilistic neighborhood tractography (PNT),^{6,7} to study gender specific effects in developing white matter tracts in preterm infants.

Methods: Scanning: Following ethics committee approval, 49 preterm infants born at postmenstrual age (PMA) of 29 ± 6 weeks were scanned on a MAGNETOM Verio 3 T clinical scanner (Siemens AG, Germany) at term equivalent age (PMA 40 ± 3 weeks) without sedation. All infants were scanned axially using a diffusion MRI (dMRI) protocol consisting of 11 T2- and 64 diffusion-weighted ($b = 750 \text{ s/mm}^2$) single-shot spin echo EPI volumes with 2 mm isotropic voxels. Analysis: 10 fasciculi-of-interest (FOI) were identified using PNT from the dMRI data (<http://www.tractor-mri.org.uk>): genu and splenium of corpus callosum, right and left projections of the arcuate, cingulum cingulate gyri (CCG), corticospinal tract (CST) and inferior longitudinal fasciculi (ILF). Using a neighborhood of seed voxels, the seed point that produced the best matching tract to the reference (MNI standard space) was determined using tract shape models produced from a group of adult volunteers aged 25–65 years. Streamlines that did not resemble the median path of the best-matched tract were pruned automatically. An experienced rater then visually assessed all best matched tracts and subjects with aberrant or truncated pathways that were not anatomically plausible representations of the FOI were excluded from further analysis. For anatomically acceptable tracts, the resulting tractography masks were applied to each subject's mean diffusivity ($\langle D \rangle$) and fractional anisotropy (FA) maps to provide tract-averaged measures of these biomarkers for the 10 FOI.

Results: The gender effect for tract-averaged FA and $\langle D \rangle$ for the 10 FOI in each subject were assessed using an independent t-test. Tract-averaged FA values of the left CCG were significantly increased in male infants ($p = 0.05$), while $\langle D \rangle$ of the left CCG were significantly increased in female infants ($p < 0.04$). To assess the effect of PMA at birth and PMA at scanning on these dMRI biomarkers, a general linear univariate model based on one between-subject variable was performed for FA and $\langle D \rangle$ in the 10 FOI. Two important covariates were included in all analyses: PMA at birth and PMA at scanning. Track averaged $\langle D \rangle$ of the left CCG was significantly increased ($p < 0.03$) in female infants ($1551 \pm 285 \mu\text{m}^2/\text{s}$) compared to male infants ($1397 \pm 858 \mu\text{m}^2/\text{s}$).

Discussion: These pilot data show for the first time that quantitative measurements of dMRI biomarkers can be made in the preterm brain from high angular resolution dMRI data using PNT. These values are comparable to other studies using tractography methods, and demonstrate increased diffusivities and reduced FA in the CCG of female preterm infants compared with male equivalents. Of particular interest is the fact that the method is able to identify successfully a range of fasciculi using reference tracts obtained from adult brain. This approach may be useful for studying sexual dimorphism early in human development. We are currently investigating whether the use of reference tracts from infants further improves this study, and whether the tract shape parameter R (the absolute goodness-of-fit of the best match tract to the reference) provides additional useful information about brain structure that can be used to assess cerebral development in preterm birth and potential therapeutic interventions.

References: [1] Mackay DF, et al. (2010) PLoS Med 7(6): e1000289, [2] Marlow N, et al. (2005) N Engl J Med 352: 9-19, [3] Kapellou O, et al. PLoS Med 3(8): e265, [4] Edwards D. (2004) J Pediatr 145(6):723-724, [5] Ment LR, et al. (2004), J Pediatr 145 (6): 832-834, [6] Clayden JD, et al. (2007), IEEE Trans Med Imaging 26: 1555-1561, [7] Clayden JD, et al. (2011), J Stat Software 44 (8): 1-18.

Acknowledgement: This work was carried out in collaboration with Siemens Medical Systems. We would like to acknowledge the work of Dr Thorsten Feiweier.

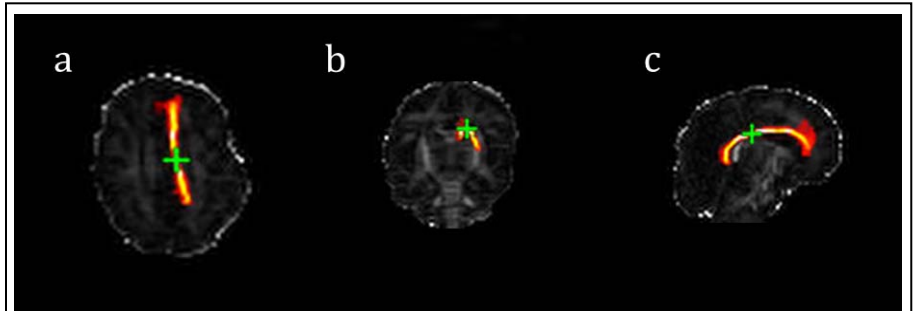


Figure 1: Maps of left cingulum cingulate gyri in a preterm infant (a. axial; b. coronal; and c. sagittal).