



THE UNIVERSITY *of* EDINBURGH

Edinburgh Research Explorer

Protocol for the perfusion and angiography imaging sub-study of the Third International Stroke Trial (IST-3) of alteplase treatment within six-hours of acute ischemic stroke

Citation for published version:

Wardlaw, JM, von Kummer, R, Carpenter, T, Parsons, M, Lindley, RI, Cohen, G, Murray, V, Kobayashi, A, Peeters, A, Chappell, F & Sandercock, PAG 2015, 'Protocol for the perfusion and angiography imaging sub-study of the Third International Stroke Trial (IST-3) of alteplase treatment within six-hours of acute ischemic stroke' *International Journal of Stroke*, vol. 10, no. 6, pp. 956-968. DOI: 10.1111/j.1747-4949.2012.00946.x

Digital Object Identifier (DOI):

[10.1111/j.1747-4949.2012.00946.x](https://doi.org/10.1111/j.1747-4949.2012.00946.x)

Link:

[Link to publication record in Edinburgh Research Explorer](#)

Document Version:

Publisher's PDF, also known as Version of record

Published In:

International Journal of Stroke

Publisher Rights Statement:

Available under Open Access

General rights

Copyright for the publications made accessible via the Edinburgh Research Explorer is retained by the author(s) and / or other copyright owners and it is a condition of accessing these publications that users recognise and abide by the legal requirements associated with these rights.

Take down policy

The University of Edinburgh has made every reasonable effort to ensure that Edinburgh Research Explorer content complies with UK legislation. If you believe that the public display of this file breaches copyright please contact openaccess@ed.ac.uk providing details, and we will remove access to the work immediately and investigate your claim.



Protocol for the perfusion and angiography imaging sub-study of the Third International Stroke Trial (IST-3) of alteplase treatment within six-hours of acute ischemic stroke

Joanna M. Wardlaw^{1,3*}, Rudiger von Kummer², Trevor Carpenter³, Mark Parsons⁴, Richard I. Lindley⁵, Geoff Cohen¹, Veronica Murray⁶, Adam Kobayashi⁷, Andre Peeters⁸, Francesca Chappell³, and Peter A. G. Sandercock¹

Rationale Intravenous thrombolysis with recombinant tissue Plasminogen Activator improves outcomes in patients treated early after stroke but at the risk of causing intracranial hemorrhage. Restricting recombinant tissue Plasminogen Activator use to patients with evidence of still salvageable tissue, or with definite arterial occlusion, might help reduce risk, increase benefit and identify patients for treatment at late time windows.

Aims To determine if perfusion or angiographic imaging with computed tomography or magnetic resonance help identify patients who are more likely to benefit from recombinant tissue Plasminogen Activator in the context of a large multi-center randomized trial of recombinant tissue Plasminogen Activator given within six-hours of onset of acute ischemic stroke, the Third International Stroke Trial.

Design Third International Stroke Trial is a prospective multi-center randomized controlled trial testing recombinant tissue Plasminogen Activator (0.9 mg/kg, maximum dose 90 mg) started up to six-hours after onset of acute ischemic stroke, in patients with no clear indication for or contraindication to recombinant tissue Plasminogen Activator. Brain imaging (computed tomography or magnetic resonance) was mandatory pre-randomization to exclude hemorrhage. Scans were read centrally, blinded to treatment and clinical information. In centers where perfusion and/or angiography imaging were used routinely in stroke, these images were also collected centrally, processed and assessed using validated visual scores and computational measures.

Study outcomes The primary outcome in Third International Stroke Trial is alive and independent (Oxford Handicap Score 0–2) at 6 months; secondary outcomes are symptomatic and fatal intracranial hemorrhage, early and late death. The

perfusion and angiography study additionally will examine interactions between recombinant tissue Plasminogen Activator and clinical outcomes, infarct growth and recanalization in the presence or absence of perfusion lesions and/or arterial occlusion at presentation. The study is registered ISRCTN25765518.

Key words: acute stroke therapy, CT scan, ischemic stroke, MRI, reperfusion, rt-PA

Background

Thrombolysis with recombinant tissue Plasminogen Activator (rt-PA) improves functional outcome after acute ischemic stroke (1,2). However, practical questions remain concerning how to reduce the major hazard (intracranial hemorrhage) and how to identify determinants of the latest time after stroke when thrombolysis might still be effective. Focusing treatment on patients with still viable tissue or persistent arterial occlusion might help reduce the risk of intracranial hemorrhage and death with thrombolysis, particularly at later time windows (2,3).

The most common scanning used to select patients in trials of iv rt-PA to date was plain brain computed tomography (CT). Brain CT scan rapidly and reliably excludes acute intracranial hemorrhage, stroke mimics and in many ischemic stroke patients, especially those with moderate to severe stroke symptoms, may show early ischemic changes (4–8). Early ischemic tissue changes indicating irreversible injury are subtle, however, during the first few hours after stroke onset (9), and plain CT does not identify the full extent of any ‘tissue at risk’ of infarction. Many patients who might benefit from thrombolysis remain untreated. Reasons for this are complex and include clinicians’ lack of confidence in diagnosing hyperacute stroke based on plain CT where the signs of early ischemia or infarction though frequent (9) are subtle (10). Magnetic resonance (MR) with diffusion weighted imaging (DWI) shows acute ischemia very clearly, is very sensitive to acute ischemic change e.g., cytotoxic edema, although there are very few direct comparisons of MR with CT in hyperacute stroke (11). However, MR is not widely available as an emergency investigation for stroke (12,13) and is not well tolerated by hyperacute stroke patients (14,15). CT is therefore more practical for use in patients with acute stroke.

Perfusion imaging

Distinguishing the lesion ‘core’ (i.e., infarction), ‘at risk’ and ‘not at risk’ tissue has become theoretically possible with CT perfusion (CTP) or MR DWI and perfusion imaging (MRP). CTP technology is now available on most modern CT scanners. Whilst some advocate widespread use of perfusion imaging (16), and some

Correspondence: Joanna M. Wardlaw*, Neuroimaging Sciences, Brain Research Imaging Centre, Western General Hospital, Edinburgh EH4 2XU, UK.

E-mail: joanna.wardlaw@ed.ac.uk

¹Clinical Neurosciences, University of Edinburgh, Edinburgh, UK

²Department of Neuroradiology, University of Dresden, Dresden, Germany

³Neuroimaging Sciences, University of Edinburgh, Edinburgh, UK

⁴Department of Neurology, John Hunter Hospital, Newcastle, NSW, Australia

⁵Discipline of Medicine, University of Sydney and the George Institute, Sydney, NSW, Australia

⁶Karolinska Institutet, Danderyd Hospital, Stockholm, Sweden

⁷2nd Department of Neurology, Institute of Psychiatry and Neurology, Warsaw, Poland

⁸Department of Neurology, UCL St Luc, Brussels, Belgium

Conflict of interest: None declared.

Re-use of this article is permitted in accordance with the Terms and Conditions set out at http://wileyonlinelibrary.com/onlineopen#OnlineOpen_Terms

DOI: 10.1111/j.1747-4949.2012.00946.x

observational studies provide encouraging results (17), several factors need to be resolved before MRP can be adopted into clinical practice with confidence.

First, several recent randomized trials of thrombolytic agents that used MR DWI/MRP mismatch to select patients for inclusion (18,19), or collected DWI/MRP information at randomization but randomized on the basis of plain CT brain scanning (20) were inconclusive or conflicting (DIAS 2, <http://www.strokecentre.org/trials/>). Indirect comparisons between RCTs that used plain CT and MR DWI/MRP showed no clear improvement in functional outcome or in scoring symptomatic intracranial hemorrhage (SICH) risk according to MR DWI/MRP tissue status (21,22). Image processing methods may help to demonstrate alterations in ischemic tissue growth into the penumbra with successful thrombolytic treatment (23), except that some studies that included patients without MR DWI/MRP mismatch found that about half the patients without mismatch also had some infarct growth (so might have benefited from treatment) (24,25). Similarly, some observational data suggest that CTP did not differentiate core from salvageable tissue (26).

Second, while MRP or CTP might help visualize the ischemic tissue, there are as yet unquantified practical drawbacks to MRP, such that the balance of benefit and harm is unclear. These include: additional radiation dose with CTP (typically 6 mSv at 80kVp, 100mAs, 8 cm coverage, or about three-years worth of background radiation); contraindications to intravenous contrast agent in patients with renal impairment (Nephrogenic Systemic Fibrosis, NSF, with MRP; lactic acidosis with CTP contrast agents in patients on oral hypoglycemic agents); contrast reactions (MRP allergies occur in 1:30 000; CTP allergies occur in 1:10 000); general risks of MR in stroke patients (e.g. hypoxia with poor airway protection) (15) and general contraindications to MR (pacemaker); patient compliance (14,15); (potentially) delayed thrombus lysis (27–30); and increase in delays to treatment of 10–20 min or longer due to the additional time required for acquisition and analysis. The true impact of these practical factors is unclear.

Thirdly, and perhaps the most important factor is the lack of consensus on how perfusion data should be acquired (31), processed (32–34), or interpreted (31). The thresholds that distinguish ‘tissue at risk’ from ‘core’ or ‘not at risk’ tissue (31,35), and definitions of these tissue states (31) are highly variable. A systematic review of CTP and MRP studies published up to 2011 identified 18 different definitions of tissue at risk and 11 different definitions of ischemic lesion core (31). Most of these studies were observational, in which rt-PA was given to various proportions of patients not by random allocation, or combined data from randomized patients not selected with mismatch and nonrandomized patients all with mismatch (36). Further studies published since then have added further to the list of parameters and thresholds (Table 1).

A distillation of current literature identifies most consistently the following parameters and thresholds (31). However, note that differences in definitions of unsalvageable tissue (e.g. use of DWI to indicate lesion ‘core’) (38) (39); and in whether or not reperfusion was accounted for (40), contribute to variation in the quoted values:

Table 1 Proposed perfusion parameters to test

MR perfusion(5)	CT perfusion
Raw data	Raw data
rCBF	rCBF
rCBV	rCBV
rMTT (first moment)	rMTT (1.45) (12)
TTP (various thresholds)	TTP (1.4 wrt normal side)
Tmax plus 2, 4 and 6 s as per EPITHET (20)	Tmax plus 2, 4 and 6 s as per EPITHET (20)
ATF	ATF
CBFq	CBFq (including 12.7 ml/100 g/min) (37)
CBVq	CBVq (including < 2.2 ml/100 g)(37)
MTTq	MTTq

- non-salvageable tissue (infarct core):
 - CTP, absolute CBV <2 ml/100 g (40);
 - MRP, relative CBF <31% (38) or relative CBF 45% (39,41)).
- ‘at risk’, potentially salvageable tissue (penumbra):
 - CTP, relative MTT >145% (40) or relative MTT>125% (41);
 - MRP, Tmax >6 sec (42–48),

Most of these thresholds were derived using receiver–operator characteristic curve (ROC) analysis. ROC analyses of perfusion values in individual voxels are increasingly used to identify threshold values that differentiate infarction, penumbra and not at risk tissue, and to test the predictive value of perfusion parameters. However, this approach relies on some assumptions that are not valid in this situation and may lead to spuriously positive results. Many have not been validated in independent studies so may overestimate sensitivity and specificity. The literature consistently argues against automated methods of threshold detection unless there is no alternative (49) as automated ROC curve analysis does not avoid the danger of missing the best threshold, but increases the danger of producing a biased threshold, the diagnostic equivalent of trusting post hoc analyses. ROC curve theory assumes that (1) there are two distinct groups (diseased and non-diseased) that can be identified as such by a gold standard, and (2) each unit-of-analysis in the sample is independent of each other. There is no problem with (2) if the unit-of-analysis is patients, and no problem with (1) if the patients may or may not have the disease in question. However, if the automated ROC curve analyses are being applied to voxels rather than patients, then there are not two distinct groups of patients, but two distinct types of brain tissue, i.e., lesion and nonlesion. Voxels from the same brain are not independent, which violates the second assumption and would mean that the precision of the estimates could be greatly inflated. While it is hard to say precisely *how* the estimates of threshold, sensitivity and specificity would be affected, one cannot assume that they *would not be*. These problems are avoided by restricting the analyses to validation and comparison of existing thresholds.

Fourth, how the perfusion information is visualized. Creating perfusion parameter maps at these thresholds requires image processing that is not always available on scanner consoles. Regardless of whether a threshold-delineated lesion is sought or possible to obtain, it is often not clear what assumptions underpin the perfusion processing algorithms or how they relate to the same

parameter produced by another manufacturer (50). The alternative, offline processing, requires rapid data transfer to a processing computer. Several pipelines are now available (e.g., Rapid processing of Perfusion and Diffusion (RAPID) (46)) but many scanners are not linked to the internet, nor do many healthcare providers have funds for additional processing workstations. A simple visual assessment of the perfusion defect might provide a valid alternative, is universally available, requires only minimum parameter processing on the scanner console, but there are few formal evaluations of visual versus computational processing of perfusion data or their observer reliability (51–53).

Angiographic and structural imaging markers of arterial occlusion

The other information that might guide use of thrombolysis, derivable from CT or MR imaging, is the presence and location of an occluded artery as this determines the likely extent of the tissue affected by the stroke (54). An occluded artery may be suspected by the presence of a hyperattenuated artery on plain CT or an absent flow void or a hypointense artery on T2/fluid attenuated inversion recovery (FLAIR) or T2* MR respectively. Disappearance of the hyperattenuated artery/absent flow void (i.e., presumed recanalization) is associated with improved clinical outcome with or without rt-PA (55,56) and its persistence is associated with worse clinical outcome (57). Arterial occlusion may be identified with computerised axial tomographic angiography (CTA) or magnetic resonance angiography (MRA) with intravenous injection of contrast agent. The angiographic images are generally faster to acquire than MRP, require some image reconstruction and careful interrogation, but there is, *in general*, less scope for variation in acquisition, processing or interpretation than with MRP, and the acquisition and image processing are faster than for MRP. However, there have been many fewer publications on angiographic imaging and the relationship to likely rt-PA response and clinical outcomes than for MRP. As with MRP, several factors need to be addressed before CT or MR angiography can be used reliably to inform clinical practice.

First, there are no completed randomized trials of rt-PA where randomization was on the basis of presence or absence of arterial occlusion, therefore information on the marginal benefit or hazard of rt-PA in the presence or absence of a visible arterial occlusion is unknown. Ongoing trials include only patients with angiography-confirmed arterial occlusion (e.g., DIAS 3 and 4, <http://clinicaltrials.gov/ct2/show/NCT00856661>; SYNTHESIS 2 (58); IMS 3, <http://clinicaltrials.gov/show/NCT00359424>). Some previous trials tested intra-arterial thrombolysis, but only in patients with an intra-arterial angiography-proven arterial occlusion (59). It is clear that improved outcome after ischemic stroke is associated with arterial recanalization in observational studies with and without thrombolytic treatment (60). Some consider that rt-PA may only be effective when a visible thrombus is present. Others consider that the absence of a visible occlusion may simply reflect lack of sensitivity of imaging to small peripheral thrombi or to occlusion at the origin of a proximal major branch point making that branch 'invisible' angiographically, that in any case the major arteries may be patent when the tissue

arterioles/capillaries are not, and that patients without a visible arterial occlusion should not be denied thrombolytic treatment in the absence of further information from RCTs.

Second, the hyperattenuated artery sign is fairly specific and sensitive for arterial occlusion compared with angiographic imaging (61–63) especially if thin section slices are used (64). However more information on the overall sensitivity and specificity of the hyperattenuated artery/absent flow void for angiographic occlusion in hyperacute stroke would be valuable.

Third, the thrombus attenuation/signal change probably reflects thrombus composition, but the reliability of the imaging appearance–composition relationship is unknown. Some thrombi may be relatively isoattenuated with blood probably due to their relative proportions of red cells, fibrin, cholesterol, calcium and other constituents. Indeed, there is an emerging (although conflicting) literature on thrombus attenuation, probable composition and likelihood of rt-PA responsiveness (65–69) that requires further testing prior to clinical use.

Fourth, angiography can be assessed visually using rating scores that quantify the degree and extent of arterial occlusion (Table 2). However, the visual rating scores have problems. They were originally derived in trials of thrombolysis in myocardial infarction [e.g., the Thrombolysis in Myocardial Infarction (TIMI) score] (70) using intra-arterial angiography (IAA) prior to the availability of CT or MR MRP; many of these scores combine assessment of the point of arterial occlusion with adequacy of perfusion of the distal tissue because, at the time, IAA was the only available tool for assessing tissue perfusion; they are also used to assess recanalization. Thus, three different components of tissue blood supply are rolled into one score. This is confusing, as to what primarily is being scored (76) e.g., the parent artery could be open, but the tissue not perfused or the parent artery which was occluded could reopen but the tissue not re-perfuse. One score for initial occlusion was described by Mori and colleagues based on IAA of the cerebral circulation but again became confused with recanalization (71); the TIMI score (70) was adapted to the cerebral circulation as the Thrombolysis in Cerebral Infarction (TICI) score and then further modified to describe degrees of distal arterial patency (54,75); the TICI and Arterial Occlusive Lesion (AOL) scales were then edited and used for categorizing degrees of recanalization after therapy and not the primary occlusion; these scores also muddle arterial patency with tissue perfusion, a cardinal cause of confusion (76); finally there are several further variations on the TICI score (Table 2). The very limited data on observer reliability of angiography scoring indicate poor agreement: the intra-observer agreement between nine neuroradiologists reading intra-arterial angiograms using the TICI score was poor ($\kappa < 0.2$) with little evidence of improvement with training, possibly because of the conflation of three concepts inherent in the score (54,77).

Finally, other angiographic features that may influence both tissue viability and rt-PA response and that are detectable angiographically are the burden of occlusive thrombus (78) and the adequacy of collateral pathways (79). Several scores exist to code the collateral circulation (73,80) but these in general have undergone little independent validation.

Table 2 Angiographic scores for CTA and MRA

Thrombolysis In Myocardial Infarction (TIMI) score (70):

- 0, no flow/patency;
- 1, minimal flow/patency;
- 2, partial flow/patency;
- 3, complete flow/patency (54).

Arterial Occlusive Lesion (AOL) score (54):

- Grade 0:** No recanalization of the primary occlusive lesion
- Grade 1:** Incomplete or partial recanalization of the primary occlusive lesion with no distal flow
- Grade 2:** Incomplete or partial recanalization of the primary occlusive lesion with any distal flow
- Grade 3:** Complete recanalization of the primary occlusion with any distal flow

Thrombolysis in Cerebral Infarction (TICI) score, adapted the TIMI score with further granularity for partial patency (73):

- Grade 0:** No Perfusion. No antegrade flow beyond the point of occlusion
- Grade 1:** Penetration With Minimal Perfusion. The contrast material passes beyond the area of obstruction but fails to opacify the entire cerebral bed distal to the obstruction for the duration of the angiographic run
- Grade 2:** Partial Perfusion. The contrast material passes beyond the obstruction and opacifies the arterial bed distal to the obstruction. However, the rate of entry of contrast into the vessel distal to the obstruction and/or its rate of clearance from the distal bed are perceptibly slower than its entry into and/or clearance from comparable areas not perfused by the previously occluded vessel, e.g., the opposite cerebral artery or the arterial bed proximal to the obstruction –
- Grade 2a:** Only partial filling (<2/3) of the entire vascular territory is visualized
- Grade 2b:** Complete filling of all of the expected vascular territory is visualized
- Grade 3:** Complete Perfusion. Antegrade flow into the bed distal to the obstruction occurs as promptly as into the obstruction and clearance of contrast material from the involved bed is as rapid as from an uninvolved other bed of the same vessel or the opposite cerebral artery.

Two further variations of the TICI score:

TICI Grade of perfusion confuses arterial patency/recanalization and perfusion including Grades 0 to 3 and subscores 2a to 2c (74);

Score to be used in IST-3: TICI – AOL hybrid (Fig. 1)

- 0, no patency – artery completely blocked at main obstruction point;
- 1, minimal patency – some contrast penetrates main obstruction point but no/minimal opacification of artery or branches distally;
- 2, patency of less than half of the lumen at the point of obstruction and
 - a) only partly filling (<1/2) or
 - b) incomplete filling but $\geq 1/2$ of the major branches of the affected artery;
- 3, patency of more than half of the lumen at the point of obstruction and filling of most of the major branches of the affected artery; and
- 4, complete patency – normal

MORI score (71):

- 0, no flow/patency;
- 1, minimal flow/patency;
- 2, flow/patency of less than half of the territory of the occluded artery;
- 3, flow/patency of more than half of the territory of the occluded artery; and
- 4, complete flow/patency (71,72).

TIMI score, adapted for the intracranial circulation in ischemic stroke (54):

- Grade 0:** No perfusion
- Grade 1:** Perfusion past the initial occlusion, but no distal branch filling
- Grade 2:** Perfusion with incomplete or slow distal branch filling
- Grade 3:** Full perfusion with filling of all distal branches, including M3, 4

TICI reperfusion(I) essentially the same as TIMI score applied in IMS 1 with grade 2 further divided into 2a Partial filling (<1/2) of ... and 2b Partial filling ($\geq 1/2$) of ... for post hoc analysis (75).

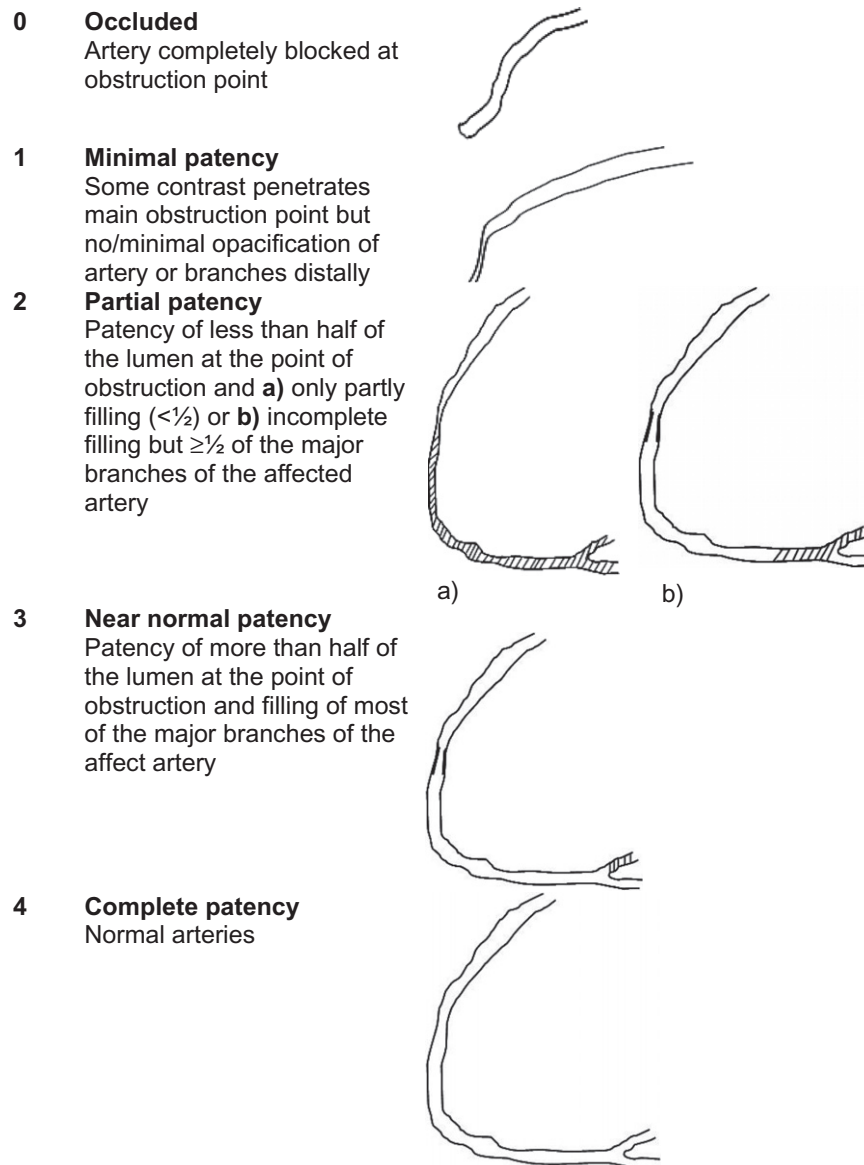


Fig. 1 Diagram of angiogram appearance according to original TIMI score, modified to focus on the primary point of occlusion and main distal vessels resulting in final TIC1 – AOL angiographic score.

The Third International Stroke Trial

The Third International Stroke Trial (IST-3) aims to evaluate whether iv rt-PA in a dose of 0.9 mg/kg (maximum 90 mg), when administered to a wider range of patients with acute ischemic stroke than were included in the trials to date, within six-hours of symptom onset, increases the proportion of people alive and independent at six-months (<http://www.ist3.com>) (1,81,82). In addition, where data could be collected, IST-3 sought to address whether perfusion or angiography imaging provided additional useful and reliable information about which patients were more or less likely to benefit from rt-PA to inform future clinical practice.

Study objectives

IST-3 is a multicenter prospective, randomized trial testing whether rt-PA is beneficial in a wider range of patients than meet

the current license criteria. The IST-3 Perfusion and Angiography Study was embedded in the IST-3 main trial and aimed to provide substantially more data on patients with and without perfusion deficits or arterial occlusion, randomized to rt-PA or control, to determine whether there is a differential benefit in those with, compared with those without, perfusion lesions or arterial occlusion. It aimed to examine visual assessment versus computational image processing of perfusion images, and associations between the amount of ‘tissue at risk’ pre-treatment, clinical features and outcome. If, as suggested in recent studies, very high proportions of patients with large artery territory cortical ischemic symptoms have MR DWI/MRP mismatch within six-hours of stroke (20), and if rt-PA is effective in those with mismatch, then simply determining the clinical stroke syndrome and time lapse since stroke may be almost as effective as complex imaging in guiding patient selection (as well as being quicker and less expensive).

If, on the other hand, the benefits of rt-PA are confined either to those with imaging evidence of tissue at risk or with arterial occlusion, regardless of time lapse since onset, and who cannot be identified by other means, then it will require substantial investment in imaging services to deliver effective thrombolysis. If the presence of perfusion-visible tissue at risk has no impact on responsiveness to rt-PA treatment, then clinicians will have greater confidence to treat patients on the basis of plain CT (or MR DWI) and thorough clinical assessment alone, which would immediately improve access to rt-PA.

Questions

Primary

Is the response to rt-PA treatment, as measured by (1) infarct growth and (2) functional outcome [modified Rankin Scale (mRS) 0–2]:

- better in patients with imaging evidence of tissue at risk on CT/CTP or DWI/MRP than those without tissue at risk?
- better in patients with CT/CTA or MR/MRA proven arterial occlusion than in patients without such occlusions?

Secondary

- in patients treated with rt-PA versus controls, which perfusion parameter (cerebral blood flow, cerebral blood volume or mean transit time based), processing method (qualitative, quantitative) and threshold best predicts (1) infarct growth at 24 hours and (2) good functional outcome at six-months?
- can imaging features on plain CT or MR DWI/FLAIR/T2 reliably differentiate viable from nonviable tissue?

Methods

Patient population

Patients were recruited in IST-3 as per trial protocol (<http://www.ist-3.com>) (1,81). To be included in IST-3, patients had to have: (1) symptoms and signs of clinically definite acute stroke, (2) known time of stroke onset less than six-hours previously (patients awaking with stroke were not eligible), (3) either CT or MR brain scanning had excluded intracranial hemorrhage and common stroke mimics, and (4) treatment could be started within six-hours of stroke. The exclusion criteria were: age <18, and standard contraindications to rt-PA related to high risk of bleeding. In centers where MR was the brain imaging method, additional exclusions included standard contraindications to MR imaging. Patients with symptoms of large and medium-sized cortical, lacunar and posterior circulation stroke were all included, with no upper age limit. Patients with early visible infarct signs were also included (though not if established infarct signs were present as these suggest a stroke onset of more than six-hours previously). Patients with early infarct signs have a higher risk of poor outcome compared to patients with no early infarct signs (4), but in the previous trials, there was no clear evidence of an interaction between the presence (versus absence) of early infarct signs and increased risk with rt-PA (9). More versus less extensive early infarct signs are also associated with worse outcome after stroke but the interaction with rt-PA is also unclear and will be

tested in IST-3. IST-3 was conducted in hospitals with stroke units where evidence-based care pathways for stroke (including for administration of rt-PA) were in use in Europe, Canada and Australia. Consent procedures were described in the protocol (<http://www.ist-3.com>).

Investigational product

IST-3 tested rt-PA (alteplase) total dose 0.9 mg per kg of body weight up to a maximum of 90 mg versus ‘open control’. Patients allocated control were to avoid treatment with rt-PA and to receive stroke care in exactly the same clinical environment as those allocated ‘immediate rt-PA’.

Clinical outcomes

In IST-3, all patients were followed up at seven-days, hospital discharge, transfer to another hospital or death, whichever occurred first, by the Hospital Coordinator at each collaborating center. Six-months after randomization, patients were followed up by the central trials office in each country, blind to original treatment allocation by postal questionnaire or telephone interview or clinic assessment by an independent physician, to record dependency using the Oxford Handicap Scale (OHS, similar to the mRS), health-related quality of life and, if dead, then the date and cause of death.

Primary outcome

The primary outcome measure in IST-3 was the proportion of patients who were dead or dependent (OHS 3–6) at six-months after stroke. Symptomatic intracranial hemorrhage, death and recurrent stroke were also assessed within seven-days, and the proportion who were dead and alive and independent (OHS 0–2) at six-months. In IST-3 perfusion and angiography analysis, the primary outcome measures will be the same clinical measures as for IST-3; secondary outcomes will include absolute infarct growth, defined as a change in the extent of hypoattenuated tissue on CT or of hyperintense tissue on MR FLAIR between baseline and 24–48 h follow-up, of one point or more on either the IST-3 scale score (83,84) or the Alberta Stroke Program Early CT Score (ASPECTS) score (85) if in the middle cerebral artery (MCA) territory.

Perfusion and angiography parameters and assessment

In centers where perfusion and/or angiography imaging with CT or MR was performed routinely for acute stroke, data from these imaging modalities was collected centrally according to established IST-3 methods. In those centers, patients were randomized into IST-3 according to plain CT or MR criteria so that decisions were not influenced by knowledge of perfusion or angiography information. As per routine clinical practice, patients with definite renal impairment (eGFR <30 ml/min/1.73 m²) or on metformin were excluded from the perfusion/angiography study. Reduced eGFR is common on admission to hospital in patients with acute ischemic stroke and usually normalizes with rehydration (86) therefore patients with eGFR 30–59 ml/min/1.73 m² could be included if there was no documented history of renal impairment and the low eGFR was considered likely to reflect dehydration, at the discretion of the recruiting physician. Low risk

MR contrast agents were to be used. Oxygen was continued in MR or CT where necessary.

Where possible patients were to be examined on the same scanner at baseline and follow up, although combinations, e.g., CT pre-randomization and MR at 24 h follow-up were allowed as local clinical practice dictated. Basic minimum acquisition standards were required (Appendix 1). Before a center could participate in the Perfusion and Angiography Study, a test perfusion and/or angiogram image data set had to be sent to the IST-3 trial coordinating center to ensure that the imaging met minimum standards and that the data could be processed centrally.

The image data were received, linked with their demographic data and trial records, anonymized and transferred into the image processing pipeline. Plain CT and MR images were read according to the IST-3 established structured image analysis protocol by a panel of experts via a web-based image reading system, the Systematic Image Review System (SIRS, <http://www.neuroimage.co.uk/>).

Structural lesion quantification

All image analysis will be performed blind to treatment allocation and all clinical baseline and follow-up information. The same methods will be applied to CT and MR images. These quantify any signs of acute ischemia as well as the appearance of the underlying brain. The structural MR and CT visible lesion are quantified using the established IST3 coding method. This identifies firstly whether there is any visible hypoattenuated lesion on CT and if so the degree (mild – grey matter same as white matter; severe – grey and white matter lower than white matter) or swelling using a structured scale. The visible lesion on MR is classed as visible on DWI only, DWI and faint FLAIR/T2, obvious DWI and FLAIR/T2 or no DWI and only FLAIR/T2. The visible lesion extent is quantified on structural MR (DWI/FLAIR/T2/GRE) and plain CT imaging using the IST-3 (10,83) and ASPECTS scores (85) which, in direct comparisons, have similar inter and intrarater reliability (84). The ASPECTS score quantifies both perfusion and structural lesions in the MCA territory (14). The IST-3 score assesses all vascular territories and codes lesion location, extent, degree of tissue attenuation/signal intensity and mass effect (83). Acute ischemic lesion swelling is quantified using a seven-point validated scale (83). The hyperattenuated artery or absent flow void is scored for presence/absence and location in the internal carotid artery, MCA mainstem or sylvian branch, anterior cerebral artery, posterior cerebral artery, basilar artery or combinations thereof (10,55,57). Hemorrhagic transformation is coded using a system developed for IST-3 that has been used in several observational studies and that is translatable to methods for SICH used in other trials (ECASS, ECASS 3 and SITS-MOST) including the association with neurological deterioration and imaging findings. The general appearance of the underlying brain is also scored for prior stroke lesions, leukoaraiosis (87), microbleeds (88) and atrophy (89).

The ‘final infarct’ will also be outlined on the follow-up plain CT or MR T2 or FLAIR image, blind to all clinical information and baseline imaging, to provide a ‘final’ lesion for mapping to the nonsalvageable and at-risk tissue maps.

Perfusion image processing and analysis

We will perform both visual and computational assessment of the perfusion lesion. Visual scoring will be performed using methods piloted in a three-center study of perfusion and angiography imaging within six hours of acute ischemic stroke (the TMRC Multicenter Acute Stroke Imaging Study, in preparation). All baseline and follow-up diffusion, perfusion and CT or MR structural data are registered to the baseline CT volume brain image or MR DWI B0 image and motion corrected. The primary perfusion parameter maps are generated centrally using validated in-house software (32,90), with deconvolution performed using singular value decomposition (SVD) using a delay insensitive method (block–circulant matrix) (32,90,91) taking arterial input function from the proximal contralateral MCA and venous outflow from the sagittal sinus.

Some studies suggest that although quantitative methods obtained with deconvolution using an arterial input function (e.g., Tmax) should confer better quantification of the perfusion lesion than relative measures of tissue perfusion obtained without deconvolution (time to peak (TTP)), the latter may be just as accurate (45), as deconvolution decouples delay in bolus arrival from tissue perfusion and may negatively impact on prediction of infarction (48). Other factors that may be unknown at the time of MRP, such as whether the internal carotid artery is occluded or tightly stenosed in the neck and will therefore slow bolus arrival and create the impression of a perfusion lesion unless delay in bolus arrival is accounted for (92), will be assessed in light of information from angiographic imaging. For these reasons, we will test both relative and quantitative perfusion parameters.

We will produce a set of perfusion parameter maps for visual rating and measurement of lesion volume without any threshold applied (Table 1): quantitative perfusion with deconvolution (cerebral blood flow, qCBF; cerebral blood volume, qCBV; mean transit time, qMTT; time to peak of the residue function, Tmax) and relative perfusion, i.e., without deconvolution (rCBF; arrival time fitted, rATF; time to peak, rTTP; peak time fitted, rPTF; rCmax; full width at half maximum, rFWHM).

Although IST-3 will have collected the largest ever amount of data on MRP in acute stroke specifically in a randomized trial of rt-PA to date, we are unlikely to have enough data to derive thresholds in one half of the data set and then validate these thresholds in the other half. Therefore, rather than attempting to derive new thresholds, we will focus on validating existing published thresholds suggested to be most diagnostic of nonsalvageable/at risk/not at risk tissue. Therefore, maps of the following perfusion thresholds will be produced for volumetric and visual measurement (details in Table 1):

- Representing nonsalvageable tissue:
 - on CTP, absolute CBV <2 ml/100 g (40);
 - on MRP, relative CBF <31% (38) and relative CBF <40% (39,41).
- Representing at risk tissue:
 - on CTP: rMTT >145% (40); rMTT >125% (41).
 - on MRP: Tmax >6 s (42–48); (Note Tmax >2 s was originally identified in EPITHET but subsequent analyses and other groups have identified Tmax >6 s as a preferred threshold).

The perfusion parameters chosen are designed to reflect commonly applied thresholds and image types whilst keeping the total number of comparisons manageable and restricting the potential for false positive results. Many of these thresholds have been defined for one modality only (mostly CTP) but could equally be applied to MR data and therefore will be tested.

The perfusion lesion extent is quantified visually using the ASPECTS score (85), subtracting one point from a total of 10 for each MCA ASPECTS region that is in part or wholly affected by the perfusion lesion even where perfusion image does not cover the whole ASPECTS region. We will also record if there was (1) no visible perfusion lesion, (2) a visible perfusion lesion that was less than 80%, (3) about the same size as, or (4) 20% or more larger than the structural ischemic lesion by visually-estimated volume on plain CT or MR DWI/FLAIR, these cut points chosen to reflect previous studies (17,20). Mismatch will be defined as a perfusion lesion >20% larger than the structural lesion. These methods have been evaluated in the TMRC Multicenter Acute Stroke Imaging Study (in preparation) and provided reliable associations between baseline imaging and stroke severity as well as predicting associations with clinical outcome data.

The perfusion *lesion volume* will also be measured by manual outlining by a trained observer blind to clinical and other data on two of the unthresholded parameter maps from above (qMTT and rCBF perfusion lesions) to represent at risk tissue and non-salvageable tissue, respectively. In addition, the perfusion lesion volume will also be measured on thresholded parameter maps listed above. These lesions will also be identified using a voxel-based approach to match geographic association with the “final infarct” (from the 24-hour follow-up image).

In secondary analyses, we will use the data set to test a range of alternative thresholds using MiStar analysis software (Parsons, Bivard, Newcastle, Australia) in a hypothesis generating exercise.

Angiographic image analysis

Using source image data and reconstructed angiographic images where available, we will assess the location and extent of any arterial occlusion, its completeness, the presence of collateral pathways, the clot burden (78) and the attenuation properties of the occluding thrombus. Location and extent will be coded as for the hyperattenuated artery/absent flow void in the internal carotid artery, MCA mainstem or sylvian branch, anterior cerebral artery, posterior cerebral artery, basilar artery, vertebral artery or combinations thereof (10,55,57).

Several scores are available to classify the degree of major arterial obstruction as discussed earlier (Table 2). Several combine scoring of the patency of the main affected artery with the degree of perfusion of that artery’s vascular bed and any recanalization. Conflating three different concepts, peripheral microvascular tissue perfusion, primary arterial patency and recanalization in a single score mixes three separate and probably semi-independent entities (76). We previously used the Mori (72) and TIMI (70) scores purely to classify arterial patency at the primary point of obstruction on CTA and MRA, and separately used CTP or MRP to classify tissue-level

perfusion and reperfusion which worked well. Other scores (summarized in Table 2) mixed primary occlusion, perfusion and recanalization (54,73–75).

In IST-3, we will use a score that combines the best elements of the TICI (including 2a and 2b) and AOL scores that only scores angiographic patency at the main point of occlusion and filling of immediate distal vessels, but not tissue perfusion or recanalization. This score, used in DIAS 3 and 4 (<http://clinicaltrials.gov/ct2/show/NCT00856661>) and IMS-3, (<http://clinicaltrials.gov/show/NCT00359424>), is described in Fig. 1. *Recanalization* will be indicated by a change in one point or more on the scale between randomization and follow-up scans.

We will also code *thrombus burden* using the *Clot Burden Score* (78) as follows: From a total score for normal arteries of 10, two points are subtracted for thrombus found on MRA in the supraclinoid ICA and each of the proximal and distal halves of the MCA trunk. One point is subtracted for thrombus found in the infraclinoid ICA and A1 segment and for each affected M2 branch giving a total score for normal arteries of 10.

We will score *Collateral pathways* (79) (in patients with ICA/MCA main stem occlusion only) using the *Score for Collateral Status*. Scores are A ‘Good’ (entire MCA distal to the occluded segment reconstituted with contrast); B ‘Moderate’ (some of the MCA branches reconstituted within the Sylvian fissure); C ‘Poor’ (only the distal superficial MCA branches reconstituted with contrast) (80).

The resulting coding forms can be seen at <http://www.bric.ed.ac.uk/research/imageanalysis.html#ais>.

Observer reliability

We will test the inter-observer reliability of perfusion lesion scoring and angiographic image analysis by inviting as many raters as possible to rate as many of the images as possible via the SIRS web-based image reading system (<http://www.neuroimage.co.uk/sirs>), modified to handle color images and to view two image modalities from the same acquisition time point (e.g., a perfusion and a structural CT image) side by side (SIRS2 [sirs2.neuroimage.co.uk/sirs2](http://www.neuroimage.co.uk/sirs2)).

Statistical analysis

The basic questions to be addressed are ‘should perfusion-structural imaging mismatch’ or ‘arterial occlusion’ influence whether patients receive rt-PA or not?’ We will first compare imaging variables with each other, then with clinical features and clinical outcomes and then test for interactions between imaging variables and rt-PA effects. Thus, we will assess:

- variation in the size of perfusion lesions and proportion with mismatch for each perfusion parameter tested
- associations between clinical and structural imaging variables at baseline, perfusion lesion extent and presence/absence of angiography lesions
- associations between baseline perfusion or angiography imaging variables and subsequent infarct growth, swelling and hemorrhagic transformation on follow-up scanning

- then associations between baseline perfusion and angiography lesions and six month functional outcome, and
- then test for an interaction between treatment with rt-PA and perfusion lesion extent, presence or absence of mismatch, angiographic arterial occlusion and SICH and six-month functional outcome.

All analyses will be unadjusted and adjusted for key baseline variables using an established prognostic model determined in the IST-3 main trial analysis (93). In most countries, patients are followed up to 18 months offering the opportunity to examine long term outcomes.

Second, we will also compare: quantitative perfusion lesion volume with qualitative visual perfusion lesion assessment as coded by the ASPECTS score; different perfusion processing algorithms (in this case the in house software and MiStar); and test if relative (i.e., to the contra-lateral hemisphere) parameters are more consistent than quantitative parameters between different software, by comparing (1) the measured volumes of different perfusion parameter lesions, i.e., mm³, and (2) also by taking account of geometric concordance.

Power calculation

We estimate that 60% will have mismatch at randomization based on MTT (17); 70% with mismatch will have infarct growth vs. 30% without mismatch; rt-PA will reduce infarct growth by 20% in those with, but not those without mismatch (24). At 80% power and alpha of 0.05, a sample of 100 patients would detect a 27% difference in infarct growth, with versus without rt-PA, in the presence versus absence of mismatch; 160 patients would detect a 20% difference in infarct growth; 400 patients would detect a 15% difference in infarct growth.

Data and safety monitoring

The IST-3 DSMC (details in (82)) met annually to consider trial recruitment and the unblinded results on safety and efficacy and recommended that the trial continue to completion. The main trial results have been published (1).

Study organization and funding

IST-3 is managed by a Steering Committee with independent chair. The Perfusion and angiography substudy was reviewed by the Steering Committee at its annual meetings. The University of Edinburgh and Lothian Health Board are joint sponsors for the study acting through the Edinburgh Clinical Trials Unit and the NHS Lothian R&D Department and ERI Proposal Administration in a joint office known as ACCORD (Academic and Clinical Central Office for Research and Development). IST3 has ethics approval from the UK MREC (99/0/078), including use of MR instead of CT for baseline and follow-up imaging and of CT and MR perfusion and angiography, and for the collection and central analysis of these data. The perfusion and angiography study was funded by the Efficacy and Mechanisms Evaluation Programme (EME). The IST-3 main trial is funded by the UK Medical Research Council and numerous other bodies in the UK and elsewhere (details in (1,82)).

Progress and discussion

The baseline characteristics of the 3035 patients recruited in IST-3 at 31 July 2011 when trial recruitment ceased (82), the main trial results (1) and the IST-3 results in context with all prior rt-PA trials (2), have been published.

The total patient recruitment in the perfusion and angiography study was 473 patients from 48 centers in 8 countries performing CT perfusion and/or angiography and 37 centers in 11 countries performing MR perfusion and/or angiography (Fig. 2). The 473 total includes 52 patients with only MRP, 321 patients with only angiography imaging and 100 patients with both perfusion and angiography imaging. At randomization, 129 patients had perfusion and 261 patients had angiography imaging. At follow-up, 11 patients had perfusion and 117 patients had angiography imaging. A further 12 patients and 43 patients had perfusion and angiography imaging respectively at both randomization and follow-up. Therefore, allowing for some patients having both randomization and follow-up imaging, the total number of patients with MRP is 141 at randomization and 23 at follow-up and with angiographic imaging is 304 at randomization and 160 at follow-up.

Most imaging at randomization was with CT and at follow-up was with MR, a consistent pattern throughout the study. Figure 2 details expected against actual recruitment to the perfusion and angiography study in IST-3. We anticipated recruiting between four and eight patients per year in up to 15 active centers (i.e., between 180 and 360 in total). In the event, we had more centers that were able to recruit overall, and angiography proved to be more accessible for acute stroke than MRP, therefore we exceeded our overall target with 473 patients.

We were concerned that patients randomized in IST-3 with perfusion or angiography imaging would be different in many respects to those randomized with a plain CT or MR scan. However initial analysis of the baseline characteristics indicates only that patients with perfusion and angiography were randomized slightly later (median 4.5–6 h versus 3–4.5 h) and that the randomizing clinician thought that more of the patients with MRP had a visible ischemic lesion on structural imaging (but not the patients with angiography). Otherwise, there was no difference in age, NIHSS, proportion with atrial fibrillation, predicted outcome, or in the blinded expert reader interpretation of the plain CT or MR imaging between those randomized with or without perfusion and/or angiography imaging. The blinded expert readers did not have access to the perfusion and angiography imaging, thereby illustrating the importance of separating the perfusion/angiography images from the structural image interpretation when trying to determine the true additional contribution of the perfusion and angiography.

Publication

All papers will be published in the name of the IST-3 Collaborative Group, Perfusion and Angiography Imaging Study Subgroup. The raw data and processed data from the IST3 perfusion project will be made available upon written (email) request to

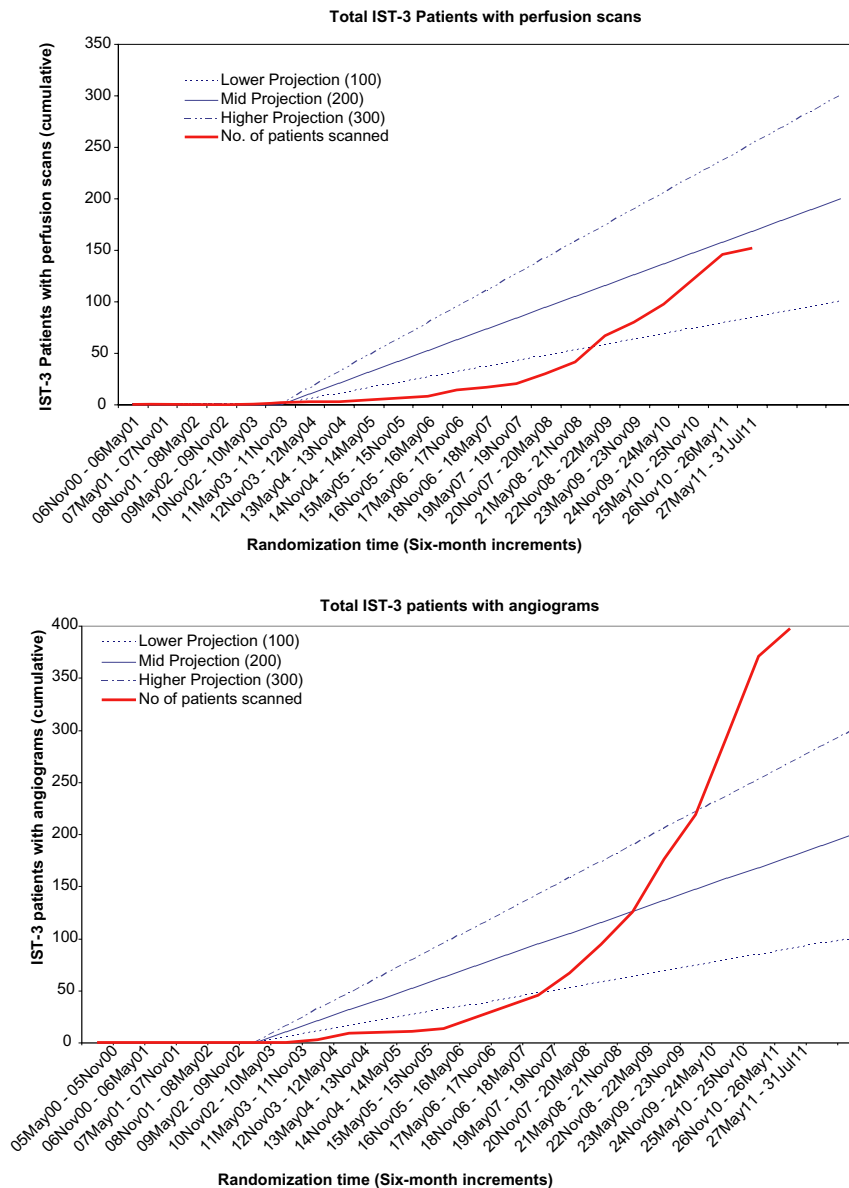


Fig. 2 Patient accrual in IST-3 perfusion and angiography studies against anticipated targets.

researchers or other appropriate individuals. These data will be published using electronic transfer mechanisms available within the Division of Clinical Neuroscience, the University of Edinburgh or any mechanism provided by the funder, as we did previously with IST (94), which recently won the 2012 BMC ‘Open Data’ award (<http://www.biomedcentral.com/researchawards/>). These data will not be made available on physical media such as DVD. The availability of the data will be publicized via the IST3 newsletter/website, University of Edinburgh collections catalogue, the SINAPSE collaboration (<http://www.sinapse.ac.uk>), the Stroke Imaging Repository (STIR) collaboration and any mechanisms provided by the funding body. Any such data made available will be fully, ambiguously and irreversibly rendered anonymous. All publications resulting from the analysis of the data collected will also be deposited with the publications archive.

Funding

IST-3 perfusion and angiography imaging study

The EME is funded by the MRC and NIHR, with contributions from the CSO in Scotland, NISCHR in Wales and the HSC R&D, Public Health Agency in Northern Ireland, and is managed by the NIHR. The views and opinions expressed therein are those of the authors and do not necessarily reflect those of the funding agencies or UK Department of Health.

IST-3 main trial funding

Medical Research Council (managed by NIHR on behalf of the MRC-NIHR partnership), Stroke Association, The Health Foundation, The Research Council of Norway, AFA Insurances (Sweden), the Swedish Heart Lung Fund, The Foundation of Marianne and Marcus Wallenberg, Stockholm County Council and Karolinska Institute Joint ALF-project grants (Sweden), the

Government of Poland (Ministry of Science Grant No. 2PO 5B 109 28), the Australian Heart Foundation, Australian NHMRC, the Swiss National Research Foundation, the Swiss Heart Foundation, the Foundation for health and cardio-/neurovascular research, Basel, Switzerland and the Assessorato alla Sanita, Regione dell'Umbria. Drug and placebo for the 300 patients in the double-blind component of the start-up phase were supplied by Boehringer-Ingelheim GmbH. IST-3 acknowledges the extensive support of the NIHR Stroke Research Network, NHS Research Scotland (NRS), through the Scottish Stroke Research Network, and the National Institute for Social Care and Health Research Clinical Research Centre (NISCHR CRC). The imaging work was undertaken at the Brain Imaging Research Centre, a member of the SINAPSE collaboration, at the Division of Clinical Neurosciences, University of Edinburgh. SINAPSE is funded by the Scottish Funding Council (SFC) and the Chief Scientist Office of the Scottish Executive (CSO). Additional support was received from Chest Heart and Stroke Scotland, Desacc, University of Edinburgh, Danderyd Hospital R&D Department, Karolinska Institutet, the Dalhousie University Internal Medicine Research Fund.

References

- 1 The IST-3 Collaborative Group. The benefits and harms of intravenous thrombolysis with recombinant tissue plasminogen activator within 6 h of acute ischaemic stroke (the third international stroke trial [IST-3]): a randomised controlled trial. *Lancet* 2012; **379**:2352–63.
- 2 Wardlaw JM, Murray V, Berge E *et al.* Recombinant tissue plasminogen activator for acute ischaemic stroke: an updated systematic review and meta-analysis. *Lancet* 2012; **379**:2364–72.
- 3 Lees KR, Bluhmki E, von Kummer R *et al.* Time to treatment with intravenous alteplase and outcome in stroke: an updated pooled analysis of ECASS, ATLANTIS, NINDS and EPITHET trials. *Lancet* 2010; **375**:1695–703.
- 4 Wardlaw JM, West TM, Sandercock PA, Lewis SC, Mielke O. Visible infarction on computed tomography is an independent predictor of poor functional outcome after stroke, and not of haemorrhagic transformation. *J Neurol Neurosurg Psychiatry* 2003; **74**:452–8.
- 5 von Kummer R, Meyding-Lamade U, Forsting M *et al.* Sensitivity and prognostic value of early CT in occlusion of the middle cerebral artery trunk. *AJNR Am J Neuroradiol* 1994; **15**:9–15.
- 6 von Kummer R, Nolte PN, Schnitger H, Thron A, Ringelstein EB. Detectability of cerebral hemisphere ischaemic infarcts by CT within 6 h of stroke. *Neuroradiology* 1996; **38**:31–3.
- 7 von Kummer R, Allen KL, Holle R *et al.* Acute stroke: usefulness of early CT findings before thrombolytic therapy. *Radiology* 1997; **205**:327–33.
- 8 von Kummer R, Bourquain H, Bastianello S *et al.* Early prediction of irreversible brain damage after ischemic stroke at CT. *Radiology* 2001; **219**:95–100.
- 9 Wardlaw JM, Mielke O. Early signs of brain infarction at CT: observer reliability and outcome after thrombolytic treatment – systematic review. *Radiology* 2005; **235**:444–53.
- 10 Wardlaw JM, Farrall AJ, Perry D *et al.* Factors influencing the detection of early computed tomography signs of cerebral ischemia. An internet-based, international multiobserver study. *Stroke* 2007; **38**:1250–6.
- 11 Brazzelli M, Sandercock PAG, Grazia Celani M *et al.* MRI versus CT for detection of acute vascular lesions in patients presenting with stroke symptoms. *Stroke* 2010; **41**:e27–e28.
- 12 Leys D, Ringelstein EB, Kaste M, Hacke W. Facilities available in European hospitals treating stroke patients. *Stroke* 2007; **38**:2985–91.
- 13 Kane I, Whiteley WN, Sandercock PA, Wardlaw JM. Availability of CT and MR for assessing patients with acute stroke. *Cerebrovasc Dis* 2008; **25**:375–7.
- 14 Barber PA, Hill MD, Eliasziw M *et al.* Imaging of the brain in acute ischaemic stroke: comparison of computed tomography and magnetic resonance diffusion-weighted imaging. *J Neurol Neurosurg Psychiatry* 2005; **76**:1528–33.
- 15 Hand PJ, Wardlaw JM, Rowat AM, Haisma JA, Lindley RI, Dennis MS. Magnetic resonance brain imaging in patients with acute stroke: feasibility and patient-related difficulties. *J Neurol Neurosurg Psychiatry* 2005; **76**:1525–7.
- 16 Schellinger PD. EPITHET: failed chance or new hope? *Lancet Neurol* 2008; **7**:286–7.
- 17 Albers GW, Thijs VN, Wechsler L *et al.* Magnetic resonance imaging profiles predict clinical response to early reperfusion: the Diffusion and Perfusion Imaging Evaluation for Understanding Stroke Evolution (DEFUSE) study. *Ann Neurol* 2006; **60**:508–17.
- 18 Hacke W, Albers G, Al Rawi Y *et al.* The Desmoteplase in Acute Ischemic Stroke Trial (DIAS): a phase II MRI-based 9-hour window acute stroke thrombolysis trial with intravenous desmoteplase. *Stroke* 2005; **36**:66–73.
- 19 Furlan AJ, Eyding D, Albers GW *et al.* Dose escalation of desmoteplase for acute ischemic stroke (DEDAS). Evidence of safety and efficacy 3 to 9 hours after stroke onset. *Stroke* 2006; **37**:1227–31.
- 20 Davis SM, Donnan G, Parsons MW *et al.* Effects of alteplase beyond 3 h after stroke in the Echoplanar Imaging Thrombolytic Evaluation Trial (EPITHET): a placebo-controlled randomised trial. *Lancet Neurol* 2008; **7**:299–309.
- 21 Wardlaw JM, Murray VE, Berge E, del Zoppo GJ. Thrombolysis in acute ischaemic stroke. *Cochrane Database Syst Rev* 2009; (4):CD000213. doi: 10.1002/14651858.CD000213.pub2.
- 22 Mishra NK, Albers GW, Davis SM *et al.* Mismatch-based delayed thrombolysis. A meta-analysis. *Stroke* 2010; **41**:e25–e33.
- 23 Nagakane Y, Christensen S, Brekenfeld C *et al.* EPITHET: positive result after reanalysis using baseline diffusion-weighted imaging/perfusion-weighted imaging co-registration. *Stroke* 2011; **42**:59–64.
- 24 Kane I, Sandercock P, Wardlaw J. Magnetic resonance perfusion diffusion mismatch and thrombolysis in acute ischaemic stroke: a systematic review of the evidence to date. *J Neurol Neurosurg Psychiatry* 2007; **78**:485–91.
- 25 Rivers CS, Wardlaw JM, Armitage P *et al.* Do acute diffusion- and perfusion-weighted MRI lesions identify final infarct volume in ischemic stroke? *Stroke* 2006; **37**:98–104.
- 26 Zhao L, Barlinn K, Bag AK *et al.* Computed tomography perfusion prognostic maps do not predict reversible and irreversible neurological dysfunction following reperfusion therapies. *Int J Stroke* 2011; **6**:544–6.
- 27 Morcos SK, Thomsen HS, Exley CM. Contrast media: interactions with other drugs and clinical tests. *Eur Radiol* 2005; **15**:1463–8.
- 28 Pislaru S, Pislaru C, Szilard M, Arnout J, van de Werf F. In vivo effects of contrast media on coronary thrombolysis. *J Am Coll Cardiol* 1998; **32**:1102–8.
- 29 Dehmer GJ, Gresalfi N, Daly D, Oberhardt B, Tate DA. Impairment of fibrinolysis by streptokinase, urokinase and recombinant tissue-type plasminogen activator in the presence of radiographic contrast agents. *J Am Coll Cardiol* 1995; **25**:1069–75.
- 30 Dzialowski I, Puetz V, Buchan AM, Demchuk AM, Hill MD. Does the application of x-ray contrast agents impair the clinical effect of intravenous recombinant tissue-type plasminogen activator in acute ischemic stroke patients? *Stroke* 2012; **43**:1567–71.
- 31 Dani KA, Thomas RGR, Chappell FM *et al.* Computed tomography and magnetic resonance perfusion imaging in ischemic stroke: definitions and thresholds. *Ann Neurol* 2011; **70**:384–401.
- 32 Kane I, Carpenter T, Chappell F *et al.* Comparison of 10 different magnetic resonance perfusion imaging processing methods in acute

- ischemic stroke. Effect on lesion size, proportion of patients with diffusion/perfusion mismatch, clinical scores, and radiologic outcomes. *Stroke* 2007; **38**:3158–64.
- 33 Hjort N, Butcher K, Davis SM *et al.* Magnetic resonance imaging criteria for thrombolysis in acute cerebral infarct. *Stroke* 2005; **36**:388–97.
- 34 Wintermark M, Albers GW, Alexandrov AV *et al.* Acute stroke imaging research roadmap. *Stroke* 2008; **39**:1621–8.
- 35 Bandera E, Botteri M, Minelli C, Sutton A, Abrams KR, Latronico N. Cerebral blood flow threshold of ischemic penumbra and infarct core in acute ischemic stroke. A systematic review. *Stroke* 2006; **37**:1334–9.
- 36 Ogata T, Nagakane Y, Christensen S *et al.* A topographic study of the evolution of the MR DWI/PWI mismatch pattern and its clinical impact: a study by the EPITHET and DEFUSE Investigators. *Stroke* 2011; **42**:1596–601.
- 37 Schaefer PW, Barak ER, Kamalian S *et al.* Quantitative assessment of core/penumbra mismatch in acute stroke: CT and MR perfusion imaging are strongly correlated when sufficient brain volume is imaged. *Stroke* 2008; **39**:2986–92.
- 38 Campbell BC, Christensen S, Levi CR *et al.* Cerebral blood flow is the optimal CT perfusion parameter for assessing infarct core. *Stroke* 2011; **42**:3435–40.
- 39 Bivard A, McElduff P, Spratt N, Levi C, Parsons M. Defining the extent of irreversible brain ischemia using perfusion computed tomography. *Cerebrovasc Dis* 2011; **31**:238–45.
- 40 Wintermark M, Flanders AE, Velthuis B *et al.* Perfusion-CT assessment of infarct core and penumbra. Receiver operating characteristic curve analysis in 130 patients suspected of acute hemispheric stroke. *Stroke* 2006; **37**:979–85.
- 41 McVerry F, The TMRC Acute Stroke Study Collaborators. Perfusion CT in acute ischaemic stroke. *Int J Stroke* 2009; **4**:3.
- 42 Calamante F, Christensen S, Desmond PM, Ostergaard L, Davis SM, Connelly A. The physiological significance of the time-to-maximum (Tmax) parameter in perfusion MRI. *Stroke* 2010; **41**:1169–74.
- 43 Takasawa M, Jones PS, Guadagno JV *et al.* How reliable is perfusion MR in acute stroke? Validation and determination of the penumbra threshold against quantitative PET. *Stroke* 2008; **39**:870–7.
- 44 Olivot J-M, Mlynash M, Thijs VN *et al.* Optimal Tmax threshold for predicting penumbral tissue in acute stroke. *Stroke* 2009; **40**:469–75.
- 45 Zaro-Weber O, Moeller-Hartmann W, Heiss WD, Sobesky J. Maps of time to maximum and time to peak for mismatch definition in clinical stroke studies validated with positron emission tomography. *Stroke* 2010; **41**:2817–21.
- 46 Straka M, Albers GW, Bammer R. Real-time diffusion-perfusion mismatch analysis in acute stroke. *J Magn Reson Imaging* 2010; **32**:1024–37.
- 47 Lansberg MG, Lee J, Christensen S *et al.* RAPID automated patient selection for reperfusion therapy: a pooled analysis of the Echoplanar Imaging Thrombolytic Evaluation Trial (EPITHET) and the Diffusion and Perfusion Imaging Evaluation for Understanding Stroke Evolution (DEFUSE) Study. *Stroke* 2011; **42**:1608–14.
- 48 Christensen S, Mouridsen K, Wu O *et al.* Comparison of 10 perfusion MRI parameters in 97 sub-6-hour stroke patients using voxel-based receiver operating characteristics analysis. *Stroke* 2009; **40**:2055–61.
- 49 Leeftang MM, Moons KG, Reitsma JB, Zwinderman AH. Bias in sensitivity and specificity caused by data-driven selection of optimal cutoff values: mechanisms, magnitude, and solutions. *Clin Chem* 2008; **54**:729–37.
- 50 Kudo K, Sasaki M, Yamada K *et al.* Differences in CT perfusion maps generated by different commercial software: quantitative analysis by using identical source data of acute stroke patients. *Radiology* 2010; **254**:200–9.
- 51 Coutts SB, Simon JE, Tomanek AI *et al.* Reliability of assessing percentage of diffusion-perfusion mismatch. *Stroke* 2003; **34**:1681–5.
- 52 Parsons M, Spratt N, Bivard A *et al.* A randomized trial of tenecteplase versus alteplase for acute ischemic stroke. *N Engl J Med* 2012; **366**:1099–107.
- 53 Campbell BCV, Christensen S, Foster SJ *et al.* Visual assessment of perfusion-diffusion mismatch is inadequate to select patients for thrombolysis. *Cerebrovasc Dis* 2010; **29**:592–6.
- 54 Khatri P, Neff J, Broderick JP, Khoury JC, Carrozzella J, Tomsick T. Revascularization end points in stroke interventional trials: recanalization versus reperfusion in IMS-I. *Stroke* 2005; **36**:2400–3.
- 55 Kharitonova T, Ahmed N, Thorén M *et al.* Hyperdense middle cerebral artery sign on admission CT scan – prognostic significance for ischaemic stroke patients treated with intravenous thrombolysis in the Safe Implementation of Thrombolysis in Stroke International Stroke Thrombolysis Register. *Cerebrovasc Dis* 2009; **27**:51–9.
- 56 Kobayashi A, Wardlaw JM, Lindley RI, Lewis SC, Sandercock PAG, Czlonkowska A. Oxfordshire Community Stroke Project clinical stroke syndrome and appearances of tissue and vascular lesions on pre-treatment CT in hyperacute ischaemic stroke among the first 510 patients in the Third International Stroke Trial (IST-3). *Stroke* 2009; **40**:743–8.
- 57 Kharitonova T, Thoren M, Ahmed N *et al.* Disappearing hyperdense middle cerebral artery sign in ischemic stroke patients treated with intravenous thrombolysis – clinical course and prognostic significance. *J Neurol Neurosurg Psychiatry* 2008; **80**:273–8.
- 58 Ciccone A, Valvassori L, Nichelatti M. SYNTHESIS Expansion: design of a nonprofit, pragmatic, randomized, controlled trial on the best fast-track endovascular treatment vs. standard intravenous alteplase for acute ischemic stroke. *Int J Stroke* 2011; **6**:259–65.
- 59 Furlan A, Higashida R, Wechsler L *et al.* Intra-arterial prourokinase for acute ischemic stroke. The PROACT II study: a randomized controlled trial. *Polype in Acute Cerebral Thromboembolism. JAMA* 1999; **282**:2003–11.
- 60 Rha J, Saver JL. The impact of recanalization on ischemic stroke outcome. A meta-analysis. *Stroke* 2007; **38**:967–73.
- 61 Bastianello S, Pierallini A, Colonnese C *et al.* Hyperdense middle cerebral artery CT sign. Comparison with angiography in the acute phase of ischemic supratentorial infarction. *Neuroradiology* 1991; **33**:207–11.
- 62 Kim EY, Yoo E, Choi HY, Lee JW, Heo JH. Thrombus volume comparison between patients with and without hyperattenuated artery sign on CT. *AJNR Am J Neuroradiol* 2008; **29**:359–62.
- 63 Riedel CH, Jensen U, Rohr A *et al.* Assessment of thrombus in acute middle cerebral artery occlusion using thin-slice nonenhanced computed tomography reconstructions. *Stroke* 2010; **41**:1659–64.
- 64 Riedel CH, Zoubie J, Ulmer S, Gierthmuehlen J, Jansen O. Thin-slice reconstructions of nonenhanced CT images allow for detection of thrombus in acute stroke. *Stroke* 2012; **43**:2319–23.
- 65 Kirchhof K, Welzel T, Zoubaa S *et al.* New method of embolus preparation for standardized embolic stroke in rabbits. *Stroke* 2002; **33**:2329–33.
- 66 Liebeskind DS, Sanossian N, Yong WH *et al.* CT and MRI early vessel signs reflect clot composition in acute stroke. *Stroke* 2011; **42**:1237–43.
- 67 Kimura K, Iguchi Y, Shibasaki K, Watanabe M, Iwanaga T, Aoki J. M1 susceptibility vessel sign on T2* as a strong predictor for no early recanalization after IV-t-PA in acute ischemic stroke. *Stroke* 2009; **40**:3130–2.
- 68 Gersh KC, Nagaswami C, Weisel JW. Fibrin network structure and clot mechanical properties are altered by incorporation of erythrocytes. *Thromb Haemost* 2009; **102**:1169–75.
- 69 Marder VJ, Chute DJ, Starkman S *et al.* Analysis of thrombi retrieved from cerebral arteries of patients with acute ischemic stroke. *Stroke* 2006; **37**:2086–93.
- 70 TIMI Study Group. The Thrombolysis in Myocardial Infarction (TIMI) trial. Phase I findings. *N Engl J Med* 1985; **312**:932–6.
- 71 Mori E, Yoneda Y, Tabuchi M *et al.* Intravenous recombinant tissue plasminogen activator in acute carotid artery territory stroke. *Neurology* 1992; **42**:976–82.
- 72 Mori E, Tabuchi M, Yoshida T, Yamadori A. Intracarotid urokinase with thromboembolic occlusion of the middle cerebral artery. *Stroke* 1988; **19**:802–12.

- 73 Higashida RT, Furlan AJ. Trial design and reporting standards for intra-arterial cerebral thrombolysis for acute ischemic stroke. *Stroke* 2003; **34**:1923–4.
- 74 Noser EA, Shaltoni HM, Hall CE *et al.* Aggressive mechanical clot disruption: a safe adjunct to thrombolytic therapy in acute stroke? *Stroke* 2005; **36**:292–6.
- 75 Tomsick T, Broderick J, Carrozella J *et al.* Revascularization results in the Interventional Management of Stroke II trial. *Am J Neuroradiol* 2008; **29**:582–7.
- 76 Tomsick T. TIMI, TIBI, TICI: I came, I saw, I got confused. *AJNR Am J Neuroradiol* 2007; **28**:382–4.
- 77 Arnold M, Nedeltchev K, Remonda L *et al.* Recanalisation of middle cerebral artery occlusion after intra-arterial thrombolysis: different recanalisation grading systems and clinical functional outcome. *J Neurol Neurosurg Psychiatry* 2005; **76**:1373–6.
- 78 Tan IY, Demchuk AM, Hopyan J *et al.* CT angiography clot burden score and collateral score: correlation with clinical and radiologic outcomes in acute middle cerebral artery infarct. *Am J Neuroradiol* 2009; **30**:525–31.
- 79 Shuaib A, Butcher K, Mohammad AA, Saqur M, Liebeskind DS. Collateral blood vessels in acute ischaemic stroke: a potential therapeutic target. *Lancet Neurol* 2011; **10**:909–21.
- 80 Miteff F, Levi CR, Bateman GA, Spratt N, McElduff P, Parsons MW. The independent predictive utility of computed tomography angiographic collateral status in acute ischaemic stroke. *Brain* 2009; **132**:2231–8.
- 81 Whiteley W, Lindley R, Wardlaw J, Sandercock P, on behalf of the IST Collaborative Group. Third international stroke trial. *Int J Stroke* 2006; **1**:172–6.
- 82 Sandercock P, Lindley R, Wardlaw J *et al.* Update on the Third International Stroke Trial (IST-3) of thrombolysis for acute ischaemic stroke and baseline features of the 3035 patients recruited. *Trials* 2011; **12**:252.
- 83 Wardlaw JM, Sellar RJ. A simple practical classification of cerebral infarcts on CT and its interobserver reliability. *AJNR Am J Neuroradiol* 1994; **15**:1933–9.
- 84 Wardlaw JM, von Kummer R, Farrall AJ, Chappell FM, Hill M, Perry D. A large web-based observer reliability study of early ischaemic signs on computed tomography. The Acute Cerebral CT Evaluation Of Stroke Study (ACCESS). *PLoS ONE* 2010; **5**:e15757. doi:10.1371/journal.pone.0015757.
- 85 Barber PA, Demchuk AM, Zhang J, Buchan AM. Validity and reliability of a quantitative computed tomography score in predicting outcome of hyperacute stroke before thrombolytic therapy. ASPECTS Study Group. Alberta Stroke Programme Early CT Score. *Lancet* 2000; **355**:1670–4.
- 86 Rowat A, Graham C, Dennis M. Dehydration in hospital-admitted stroke patients: detection, frequency, and association. *Stroke* 2011; **43**:857–9.
- 87 van Swieten JC, Hijdra A, Koudstaal PJ, van Gijn J. Grading white matter lesions on CT and MRI: a simple scale. *J Neurol Neurosurg Psychiatry* 1990; **53**:1080–3.
- 88 Cordonnier C, Potter GM, Jackson CA *et al.* Improving interrater agreement about brain microbleeds. Development of the Brain Observer MicroBleed Scales (BOMBS). *Stroke* 2009; **40**:94–9.
- 89 Farrell C, Chappell F, Armitage PA *et al.* Development and initial testing of normal reference MR images for the brain at ages 65–70 and 75–80 years. *Eur Radiol* 2008; **19**:177–83.
- 90 Carpenter T, Armitage PA, Bastin ME, Wardlaw JM. DSC perfusion MRI – quantification and reduction of systematic errors arising in areas of reduced cerebral blood flow. *Magn Reson Med* 2006; **55**:1342–9.
- 91 Wu O, Ostergaard L, Weisskoff RM, Benner T, Rosen BR, Sorensen AG. Tracer arrival timing-insensitive technique for estimating flow in MR perfusion-weighted imaging using singular value decomposition with a block-circulant deconvolution matrix. *Magn Reson Med* 2003; **50**:164–74.
- 92 Hand PJ. 'Brain Attack'. A new approach to stroke and transient ischaemic attack. 2002; 1–526.
- 93 Sandercock P, Lindley R, Wardlaw J, Whiteley W, Murray G, on behalf of The IST3 Collaborative Group. Statistical analysis plan for the third International Stroke Trial (IST-3); part of a 'thread' of reports of the trial. *Int J Stroke* 2012; **7**:186–7.
- 94 International Stroke Trial Collaborative Group. The International Stroke Trial (IST): a randomised trial of aspirin, subcutaneous heparin, both, or neither among 19435 patients with acute ischaemic stroke. International Stroke Trial Collaborative Group. *Lancet* 1996; **349**:1569–81.

Supporting information

Additional Supporting Information may be found in the online version of this article:

Appendix 1

- A. Advisory minimum standards for (i) MR and (ii) CT perfusion acquisition.
- B. Advisory minimum standards for (i) MR and (ii) CT angiography acquisition.