



THE UNIVERSITY *of* EDINBURGH

Edinburgh Research Explorer

Interpretation of Immunohistochemical Analysis of MisMatch Repair (MMR) Protein Expression in Tissue Sections for Investigation of Suspected Lynch / Hereditary Non-Polyposis Colorectal Cancer (HNPCC) Syndrome

Citation for published version:

Arends, M, Ibrahim, M, Happerfield, L, Frayling, IM & Miller, K Interpretation of Immunohistochemical Analysis of MisMatch Repair (MMR) Protein Expression in Tissue Sections for Investigation of Suspected Lynch / Hereditary Non-Polyposis Colorectal Cancer (HNPCC) Syndrome.

Link:

[Link to publication record in Edinburgh Research Explorer](#)

Document Version:

Publisher's PDF, also known as Version of record

General rights

Copyright for the publications made accessible via the Edinburgh Research Explorer is retained by the author(s) and / or other copyright owners and it is a condition of accessing these publications that users recognise and abide by the legal requirements associated with these rights.

Take down policy

The University of Edinburgh has made every reasonable effort to ensure that Edinburgh Research Explorer content complies with UK legislation. If you believe that the public display of this file breaches copyright please contact openaccess@ed.ac.uk providing details, and we will remove access to the work immediately and investigate your claim.



Introduction

In Lynch / HNPCC syndrome tumours that have lost mismatch repair (MMR) function, immunohistochemistry (IHC) can be used to show abnormal MMR protein expression. Lynch / HNPCC sufferers inherit one germline mutant MMR allele and one normal, wild-type MMR allele. During tumour formation, the normal allele is inactivated by mutation or loss, thus leaving no expression of functional alleles. MMR abnormal expression in Lynch / HNPCC tumours may thus be detected by IHC in two patterns: either complete loss of expression (when there is no expression of that MMR protein or only expression of a truncated protein to which the antibody does not bind), or patchy/weak expression (if the mutation generates a prematurely truncated but variably stable protein, or a protein with alterations to the epitope recognised by the antibody, e.g. missense mutation). It is important to realise, however, that a small proportion, perhaps 5-20% of Lynch / HNPCC-related tumours do not exhibit any abnormality on analysis by IHC even though they have lost MMR function, as manifested by microsatellite instability (MSI) and this may be due to mutations that functionally inactivate the MMR protein but allow its expression as a stable protein with nuclear localisation and intact epitope.

IHC Recommendations

Where possible, IHC should be carried out using an automated staining machine. Manual IHC is prone to significant variation, both within and between batches. Automated immunostaining generates more consistent and reproducible staining patterns.

Use of 4 MMR antibodies (MSH2, MLH1, MSH6 & PMS2) is recommended over the use of only 2 MMR antibodies (MSH2 & MLH1), as there is a heterodimeric association of proteins, such that abnormality of MSH2 is almost always accompanied by abnormality of MSH6, and MLH1 with an abnormality of PMS2. This heterodimeric binding of the proteins acts as a very useful confirmatory finding.

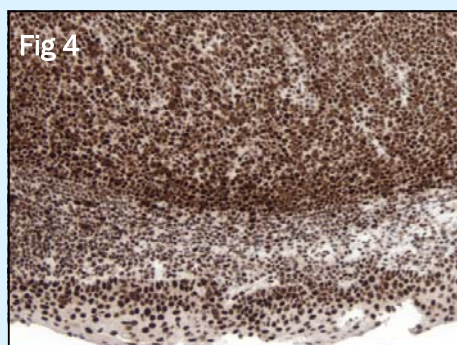
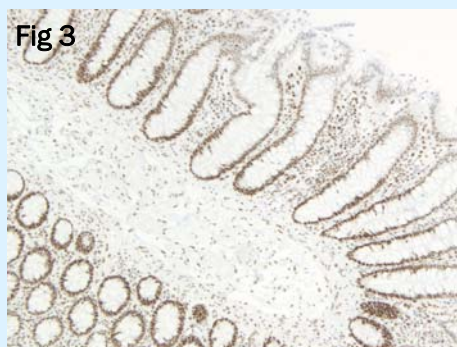
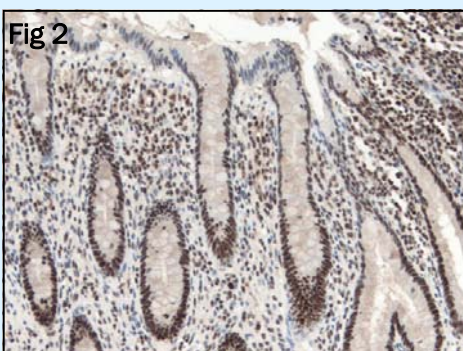
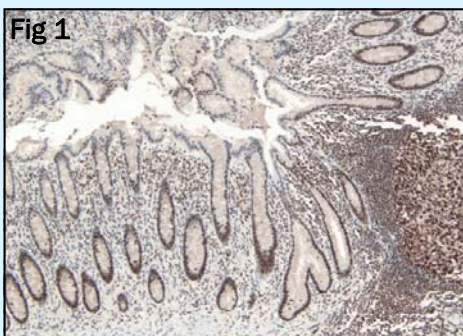
The antigenic epitopes for the four anti-MMR antibodies are particularly fixation-sensitive and immunostaining patterns should only be assessed in well-fixed regions of the tissue section, for example

where the adjacent normal epithelium or the intra- or peri-tumoural lymphoid cells or stromal cells such as fibroblasts show clear, strong nuclear immunopositivity for all four of the MMR proteins. Any poorly fixed central parts of the tumour should not be taken into consideration.

Control Tissue

Appendix (Fig 1 & 2) or normal colon (Fig 3) are appropriate control tissues to use for immunohistochemistry for all 4 MMR proteins and this should show:

- Strong nuclear staining of the epithelium at the base and lower half of the crypts (Fig 1-3), with fading of nuclear staining intensity in the middle and upper third of the crypts (Fig 2 & 3), to negative or weak staining of epithelial nuclei at the luminal surface.
- There should be very strong staining of lymphoid follicles (Fig 1).



Interpretation & Reporting guidelines

1. We recommend reporting MMR IHC findings in tumours as either:

a) Normal: Demonstrating strong immunopositivity of the tumour cell nuclei for all four MMR proteins, similar in staining intensity to that of the adjacent normal epithelium or intra-tumoural lymphoid cells or stromal cells.

b) Negative: Showing complete loss of staining, relative to the strongly intensive immunopositivity of the adjacent normal epithelium or intra-tumoural lymphoid cells or stromal cells.

c) Patchy/weak: Staining intensity of one or two of the MMR proteins is either weak or patchy in the tumour cell nuclei, compared to adjacent normal epithelium or intra-tumoural lymphoid cells or stromal cells, that show strong nuclear positivity in a well fixed region of the tumour.

This patchy/weak staining may often be seen in the cytoplasm rather than the nucleus, whereas, the adjacent normal epithelium or intra-tumoural activated lymphocytes or stromal cells show the usual pattern of strong nuclear immunopositivity for the MMR protein (due to the expression of the wild-type allele). This suggests that destabilisation of the MMR protein complexes has occurred and the proteins are no longer bound to the nuclear DNA.

Tonsil has been used as a control tissue, but this tends to show too strong a nuclear staining signal in both the lymphoid follicles and the overlying squamous epithelium (Fig 4), making it difficult to gauge the sensitivity of the stain. Appendix is therefore recommended as the better tissue to use for control purposes.

Reports

Reports should conclude with a statement that evidence of abnormal MMR immunohistochemical expression has, or has not, been found. If abnormal MMR expression has been found the comment is made that this is compatible with, but not necessarily diagnostic of Lynch / HNPCC, and that, if not already organised, referral of the individual and their family should be made to clinical genetic services.

Because abnormality of MMR protein expression is evidence in itself of loss of MMR function in that tumour, then a comment may also be made that MSI studies are not needed.

A small minority of tumours may show unusual combinations of abnormal MMR protein expression, e.g. loss of both MSH2 and MLH1, or three out of the four proteins (MSH2, MLH1, MSH6 & PMS2). It is suggested that the IHC be repeated and then a clinico-pathological review of the case be carried out, as necessary, to decide whether to proceed with e.g. testing of other tumours from the same individual or family, or proceeding directly with mutation detection.

Discussion

Abnormality of MMR protein expression is not in itself necessarily diagnostic of Lynch / HNPCC, as around 15% of sporadic colon cancers show loss of MLH1 staining due to acquired promoter methylation, and some sporadic colorectal tumours will also lose MSH2, MSH6 or PMS2. While there is evidence that abnormal MMR expression in rectal cancers is more predictive of Lynch Syndrome, it is by no means an absolute. Where available and appropriate, it can be suggested that testing for the *BRAF* V600E mutation is a way of distinguishing a proportion of MLH1-negative tumours as sporadic. It is important to appreciate that full interpretation of MMR immunostaining can only be made in the wider context of e.g. family history data and mutation detection studies, preferably by means of a multidisciplinary team including geneticists. Only then can a diagnosis of Lynch / HNPCC syndrome can be made. If abnormal MMR expression has not been found the covering statement is made that MSI studies should be carried out to include or exclude MMR functional abnormality in the tumour (because of the proportion of tumours with MSI that do not exhibit an abnormality of MMR protein expression).

The use of **scoring systems** that attempt to quantify the extent of immunopositivity are considered to be **inappropriate** as variation

in extent of immunostaining reflects variation in fixation of the epitope or effects of epitope retrieval, which are not biological phenomena. Geneticists wish to know if there is an abnormal expression pattern that reflects genetic abnormalities, and this requires identification of a well fixed part of the tumour where the intensity of immunopositivity in tumour cell nuclei can be directly compared with the strong nuclear staining intensity in well fixed adjacent normal epithelium or lymphoid cells or stromal cells. Artefactually distorted staining patterns due to poor fixation (affecting both stromal cells as well as tumour cells) in central parts of the tumour are irrelevant. It should be borne in mind that geneticists may use the *in vivo* expression pattern of MMR proteins to interpret mutations of uncertain significance, and that both false-negative and false-positive staining (or interpretation) may potentially cause misinterpretation of DNA sequence findings. This could result in a mutation being interpreted as pathogenic when it is, in fact, neutral in effect, and thus result in inappropriate predictive genetic testing being offered to the family. Hence, care is needed in both staining and interpretation.

Selected References

1. Vasen HF, Möslein G, Alonso A et al., (2007) Guidelines for the clinical management of Lynch syndrome (hereditary non-polyposis cancer). *J Med Genet.* 44 (6):353-62.

Free download from:

<http://www.jmg.bmj.com/cgi/content/full/44/6/353>

2. Dr Philippa Brice. Biomarkers in familial colorectal cancer screening. Expert workshop, 14th February 2006. Public Health Genetics Unit, Cambridge, UK.

Free download from:

<http://www.phgfoundation.org/file/2743/>

Correspondence

Dr. Merdol Ibrahim: UK NEQAS ICC & ISH Manager. Room 3/2, Hamilton House. Mabledon Place, London, WC1H 9BB

Tel: 02075548678

E-mail: merdol.ibrahim@ucl.ac.uk

Dr Mark Arends: Dept. Pathology, Addenbrooke's Hospital, Cambridge

Ms Lisa Happerfield: Dept. Pathology, Addenbrooke's Hospital, Cambridge

Dr Ian Frayling: Institute of Medical Genetics University Hospital of Wales Cardiff

Mr Keith Miller: UK NEQAS ICC & ISH Organiser