



THE UNIVERSITY *of* EDINBURGH

Edinburgh Research Explorer

The management of an accessory or replaced right hepatic artery during multiorgan retrieval

Citation for published version:

Cherian, PT, Hegab, B, Oliff, SP & Wigmore, SJ 2010, 'The management of an accessory or replaced right hepatic artery during multiorgan retrieval: results of an angiographic study' *Liver Transplantation*, vol 16, no. 6, pp. 742-7., 10.1002/lt.22075

Digital Object Identifier (DOI):

[10.1002/lt.22075](https://doi.org/10.1002/lt.22075)

Link:

[Link to publication record in Edinburgh Research Explorer](#)

Document Version:

Publisher final version (usually the publisher pdf)

Published In:

Liver Transplantation

Publisher Rights Statement:

OnlineOpen

General rights

Copyright for the publications made accessible via the Edinburgh Research Explorer is retained by the author(s) and / or other copyright owners and it is a condition of accessing these publications that users recognise and abide by the legal requirements associated with these rights.

Take down policy

The University of Edinburgh has made every reasonable effort to ensure that Edinburgh Research Explorer content complies with UK legislation. If you believe that the public display of this file breaches copyright please contact openaccess@ed.ac.uk providing details, and we will remove access to the work immediately and investigate your claim.



The Management of an Accessory or Replaced Right Hepatic Artery During Multiorgan Retrieval: Results of an Angiographic Study

P. Thomas Cherian, Bassem Hegab, Simon P. Oliff, and Stephen J. Wigmore

Liver Unit, University Hospital Birmingham, Edgbaston, United Kingdom

In the presence of anatomical variants such as an accessory or replaced (A/R) right hepatic artery (RHA), a conflict of interest can arise during organ retrieval between liver and pancreatic teams. This angiographic study examines the anatomy of the inferior pancreaticoduodenal artery (IPDA), its relation to the A/R RHA, and the implications for the use of livers and pancreases from multiorgan donors. Gastrointestinal angiograms performed in our institution for unrelated indications were reviewed, and the relevant arteries, their diameters, the distances between origins, the time at which variants were found, and the blood supply to relevant solid organs were recorded. A review of 122 angiograms identified 100 patients in whom both the superior mesenteric artery (SMA) and the celiac axis were cannulated synchronously; these patients composed our study cohort. The IPDA was identified in 95% of the cases. There were 8 patients with a replaced RHA and 4 with an accessory RHA. In all 12, the IPDA had an SMA origin; 3 of these shared a common origin with the A/R RHA on the SMA. In the rest, the mean distance between them was 29 mm (range = 17.8-48.3 mm). All anomalous arteries found were segmental vessels. In conclusion, the A/R RHA incidence in our series was 12%, and no case had an IPDA originating from the A/R RHA. Separate accessory RHA and IPDA origins potentially allow an uncompromised accessory RHA (with its Carrel patch) without risk of prejudice to the pancreatic graft if retrieval is accurately performed. Rarely (3%), there is a common origin between the A/R RHA and the IPDA, and back-bench reconstruction would be required to allow the use of both the liver and pancreas. *Liver Transpl* 16:742-747, 2010. © 2010 AASLD.

Received November 24, 2009; accepted March 2, 2010.

The combination of the organ shortage and the success of newer programs such as pancreatic transplantation has led to increasing pressure to maximize the use of organs from multiorgan donors. In such retrievals, the presence of anatomical variants, such as an accessory or replaced (A/R) right hepatic artery (RHA) with a superior mesenteric artery (SMA) origin, can raise a conflict of interest between the multiple teams present (Figs. 1 and 2). Because the inferior pancreaticoduodenal artery (IPDA) originates from the SMA, both pancreatic and liver teams would ideally like to have the SMA-aortic cuff as a potential Carrel patch. The presence of more than 1 anatomical variant (ie, an A/R RHA and an IPDA originating from this A/R RHA) theoretically can lead to an even more conten-

tious situation. The lack of detailed information about the frequency and patterns of anatomical variations of the IPDA and A/R RHA makes it difficult for administrative authorities to make sensible recommendations about best practices in the multiorgan donor. This study presents the findings of a detailed angiographic investigation of the IPDA and A/R RHA in an aged donor population with specific reference to the potential consequences for organ retrieval, vascular reconstruction, and transplantation.

PATIENTS AND METHODS

The radiology department records at our tertiary level hospital were retrospectively reviewed to find patients

Abbreviations: A/R, accessory or replaced; CA, celiac axis; CBD, common bile duct; CHA, common hepatic artery; DSA, digital subtraction angiogram; INFR, inferior; IPDA, inferior pancreaticoduodenal artery; RHA, right hepatic artery; SMA, superior mesenteric artery; SUPR, superior.

This study was not supported by any financial grants or donations.

Address reprint requests to Stephen J. Wigmore, M.D., F.R.C.S., Scottish Liver Transplant Unit, Royal Infirmary of Edinburgh, EH16 4SA, United Kingdom. Telephone: 0131 2423661; E-mail: s.wigmore@ed.ac.uk

DOI 10.1002/lt.22075

Published online in Wiley InterScience (www.interscience.wiley.com).

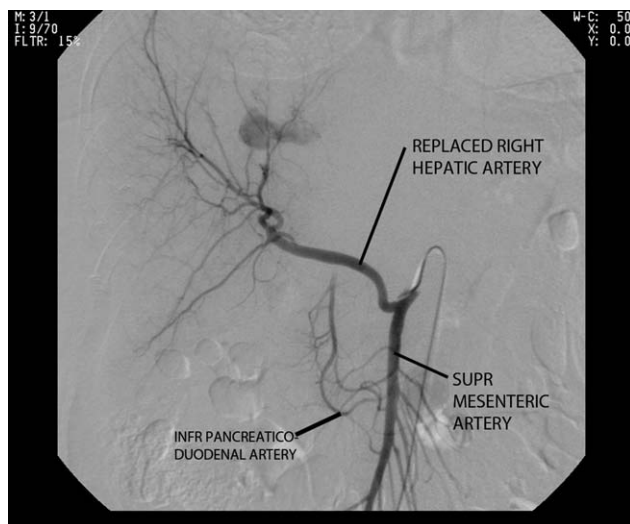


Figure 1. Superior mesenteric angiogram showing a large, replaced RHA.

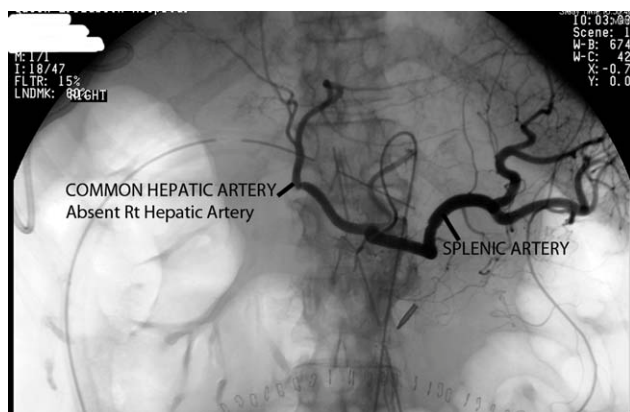


Figure 2. CA angiogram for the same patient showing an absent RHA and confirming that the artery shown in Fig. 1 was indeed a replaced RHA.

who had undergone mesenteric angiography in the preceding 5 years. The records for patients with digital subtraction angiograms (DSAs) that included selective cannulation of the gastrointestinal arteries were then isolated. DSA sequences for every patient were retrieved from archives and subjected to individual angiographic review by 2 senior liver transplant surgery trainees. Prior to the review, they received additional targeted training in the evaluation of radiological anatomy with specific regard to celiac and mesenteric angiograms from a consultant interventional radiologist (S.P.O.) who also clarified angiographic uncertainties during the study.

The study aimed to accrue 100 patients with opacification of both the celiac axis (CA) and SMA trunks after exclusions. Recruitment was consecutive and unselected, and this led to the indications for angiography being varied and unrelated. Demographics for each patient, including the indications for angiography and history, were recorded. Patients for whom a previous intervention or surgery would have altered the relevant arterial anatomy were excluded.

The presence, origins, and sizes (mm) of all relevant arteries, including the CA, SMA, common hepatic artery (CHA), A/R RHA, and IPDA, were recorded. In accordance with accepted convention, the RHA originating from the SMA was considered accessory if it was accessory or additional to an RHA originating from the CHA (CA) in supplying arterial blood to the right liver lobe, and the RHA was considered replaced when it was the sole artery to the right liver, in which it replaced the conventional arterial supply of the right lobe from the CHA/CA. Diameters and distances between the origins and branches were recorded when variants were found. In every case, by looking for an anterior and posterior IPDA and communicating arcades to vessels such as the superior pancreaticoduodenal artery, we attempted to estimate blood flow crudely on the basis of the vessel size and distribution with specific regard to the hepatic and pancreatic arterial blood supply. The distances between the origins of vessels were analyzed. Because of the retrospective nature of the study, which used an anonymous-subject database, ethical approval was not required. Statistical analysis was performed on arterial diameters with STATA SE 11. Given the small sample sizes of the 2 groups, we adopted nonparametric, unpaired tests for 2 groups (Mann-Whitney test). These tests have some limitations, particularly in the case of the third group that contained only 4 patients.

RESULTS

Among all the patients who underwent DSA in our center from 2003 to 2007, we found approximately 892 who had selective contrast opacification of abdominal vessels. One hundred twenty-two of these angiograms were reviewed to reach our target cohort of 100 angiograms with selective cannulation of both the CA and the SMA at the same sitting. The median age was 62 years (range = 22-85 years), and 52 were female. The commonest indication within the 100 was bleeding (52: 44 with gastrointestinal bleeding, 4 with hepatic artery aneurysms, and 4 with hepatocellular carcinoma), which was followed by tumor embolization (25), splenic artery embolization (7), chronic pancreatitis (3), carcinoid tumors (3), Budd-Chiari syndrome (1), and other miscellaneous nonhepatobiliary indications (9).

According to a review of our target cohort, 12 patients had a variant arterial supply to the right liver. In all 12, the RHA originated from the SMA; in 8, the RHA was replaced, and in 4, it was accessory (Figs. 1 and 2). In addition, there were 2 patients who also had a left hepatic artery originating from the left gastric artery. The mean replaced RHA size was 4.96 mm (range = 3.4-5.9 mm), whereas the mean accessory RHA size was 5.37 mm (range = 3.9-5.6 mm). There was almost no difference between the overall mean SMA size of 6.97 mm (range = 4-11.7 mm) and the mean SMA size of 7.0 mm (range = 4-9.1 mm) in the A/R RHA subgroup (Figs. 3 and 4 and Table 1).

In the presence of an accessory RHA or replaced RHA and in the absence of variance (ie, normal anatomy), the mean diameters of the CHA were 6.17, 4.38, and 5.93 mm, respectively (Figs. 3 and 4). Nonparametric 1-way analysis of variance (Kruskal-Wallis) testing for the 3 groups with the CHA as the outcome showed a significant difference between overall CHA sizes ($P = 0.004$). Furthermore, in hypothesis testing using the Mann-Whitney U test, we saw highly significant ($P = 0.0007$) differences between the CHA sizes of the normal anatomy and replaced RHA groups but not between those of the normal and accessory RHA groups [the CHA was bigger (mean = 6.17 mm) in the group with an accessory RHA versus the group with a replaced RHA (4.38 mm)]. In other words, the size of

the CHA was significantly smaller in the cohort with a replaced RHA compared to the cohort with an accessory RHA because the CHA was not supplying the right liver in this instance. These results statistically substantiate the presence of segmental flow to the right liver and therefore the real need to maintain a dual arterial supply to the graft during implantation in such cases.

There were 8 cases (8%) with a replaced RHA (Fig. 3) and 4 cases (4%) with an accessory RHA (Fig. 4). Among the final cohort of 100 patients, the IPDA was not visible in 5. The overall IPDA size was 2.49 mm (range = 1.2-3.9 mm). The diameter of the IPDA in those with a replaced RHA was 2.61 mm, and the diameter of the IPDA in those with an accessory RHA was 2.25 mm (Figs. 3 and 4). We were able to follow

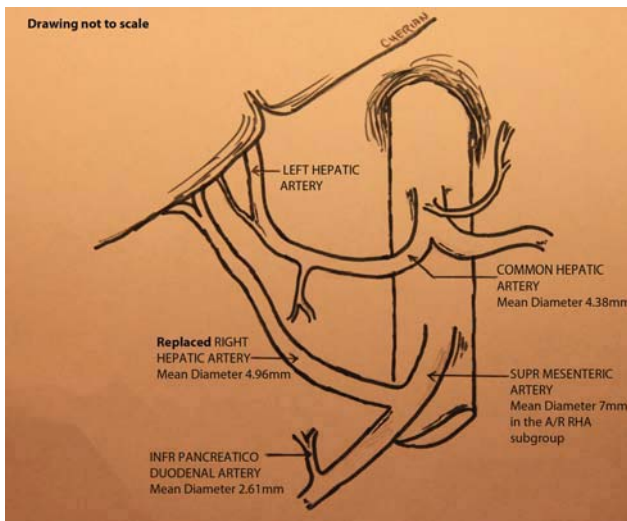


Figure 3. Diagrammatic representation of the replaced RHA (8% incidence in the present series). Here the sole blood supply to the right liver is derived from the SMA. Often, small segment 4 vessels come off the CHA as shown in the diagram. The mean diameters of the vessels in the presence of a replaced RHA, as found in the present study, are depicted. [Color figure can be viewed in the online issue, which is available at www.interscience.wiley.com.]

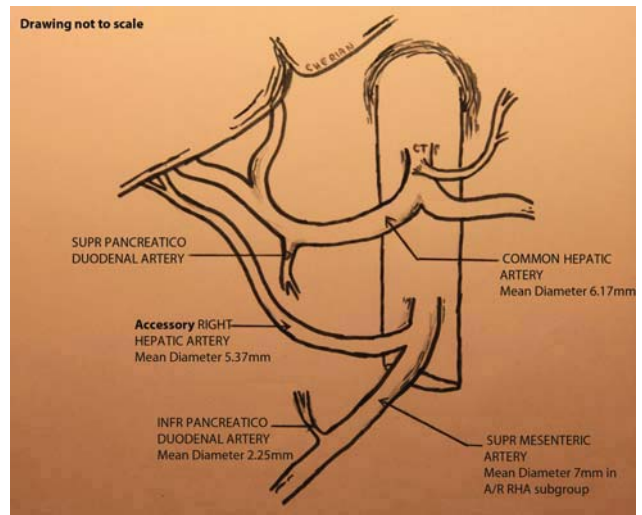


Figure 4. Diagrammatic representation of the accessory RHA (4% incidence in the present series). Here the blood supply to the right liver is derived from the SMA and the celiac trunk. The mean diameters of the vessels in the presence of an accessory RHA, as found in the present study, are depicted. [Color figure can be viewed in the online issue, which is available at www.interscience.wiley.com.]

TABLE 1. Details of All Twelve Patients for Whom a Superior Mesenteric Angiogram Showed an A/R RHA in the Cohort of 100 Patients

Patient	SMA Size (mm)	CHA Size (mm)	A/R RHA Size (mm)	IPDA Size (mm)	Distance Between IPDA and A/R RHA (mm)
1	6.8	2.5	3.4	2	30.7
2	4	5.6	4	1.2	Common origin
3	7.4	5.1	5	3	Common origin
4	7.6	4.4	5.1	3.4	25.2
5	7.5	4.8	5.1	2.2	17.8
6	9.1	4.2	5.5	3.9	Common origin
7	8.3	3.4	5.7	2	30
8	7.3	5.1	5.9	3.2	26.3
9	5.5	8.7	3.9	2.9	23.1
10	6.9	5.1	5	2	40.7
11	7.1	4.5	5.6	2	48.3
12	6.5	6.4	7	2.1	19.2

the IPDA for a distance of 25.69 mm on average (range = 7.9-44.4 mm). Arterial arcades between the superior pancreaticoduodenal artery and IPDA were found in 76 patients (76%). No other artery was found to communicate with the IPDA. In all except 3 patients (3%), there was a separate anterior and posterior branch to the IPDA.

In our series, all the IPDAs in the 12 patients with an A/R RHA originated from the SMA, and 3 of these had a common origin with the A/R RHA on the SMA. A more detailed look at the IPDA and A/R RHA origins on the SMA showed that the mean distance between them was 29 mm (range = 17.8-48.3 mm), the 3 with common origins being excluded. Likewise, looking at the distances of the IPDA origin to the aorta (ie, the site of the SMA origin), we found that there was 1 patient with a common origin between the IPDA and the SMA on the aorta. In the others, the average distance between them was 27.40 mm (range = 17.3-47.8 mm). In the 6 patients for whom the distance between the aorta and an A/R RHA was known, the mean distance was 2.5 mm (range = 2.30-3.83 mm). Although the mean distances between the IPDA and aorta and the A/R RHA and IPDA seem similar (27.40 and 29 mm, respectively), the wide ranges in both of these series meant that it was not common for them to have origins close to each other (Fig. 5).

In our series, no IPDA originated from the A/R RHA, and this suggests that the risk of an IPDA originating from the accessory vessel in the presence of an A/R RHA is low. This is obviously another situation in which the pancreatic team will have to sacrifice the branch patch.

DISCUSSION

In his seminal paper,¹ Michels described a classification scheme for the arterial blood supply to the liver based on 200 cadaveric dissections in 1955. Since then, many publications have elaborated on the topic, but none to our knowledge have provided finer detail of this particular region "where nature and embryology have contrived to create the most complex of anatomy."² Moreover, no report has evaluated arterial diameters and measured distances between divisions, particularly in the specific situation of the A/R RHA and its relation to the IPDA. Although variable and superfluous to requirements in most circumstances, in the unique situation of combined pancreas and liver procurement, precise knowledge of arteries with common origins supplying separate organs is mandatory.

A review of the history of multiorgan retrievals showed that initially the presence of shared vascular structures between the liver and pancreas precluded the retrieval of both organs in favor of providing an uninterrupted arterial supply to the lifesaving liver.^{3,4} Obviously, the desire to preserve an uninterrupted arterial tree stems from reports showing a relationship between aberrations of graft arteries, multiple anastomoses, and an increased incidence of hepatic artery

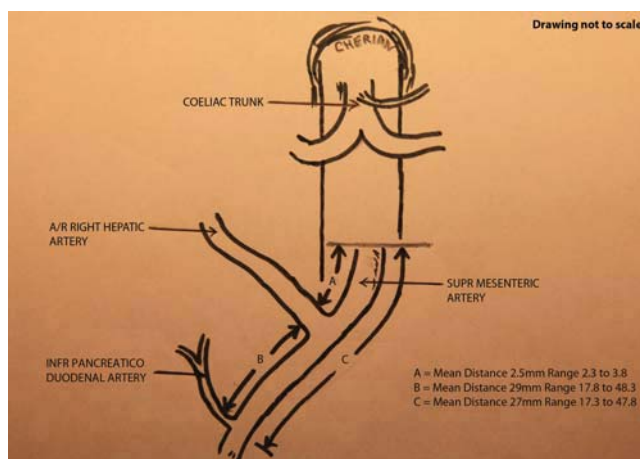


Figure 5. Diagrammatic representation of the relation of the IPDA to the A/R RHA on the SMA. In this series, no IPDA originated from the A/R RHA; this suggests that the risk of an IPDA originating from the accessory vessel in the presence of an A/R RHA is low. The mean distances between vessels, as found in the present study, are depicted. [Color figure can be viewed in the online issue, which is available at www.interscience.wiley.com.]

thrombosis and biliary complications.⁵ In addition, utilization of distal anastomotic sites (eg, the proper hepatic artery) is associated with a significantly higher risk of hepatic artery thrombosis, and conversely, the use of a Carrel patch on the donor artery is associated with a significantly reduced incidence of hepatic artery thrombosis.⁶

However, with advancing skills and experience, many centers now advocate alternate techniques to ensure the retrieval of both organs despite anomalous arterial anatomy.⁷⁻¹⁰ However, this advance is often facilitated by division of the replaced RHA at the level of the pancreatic head, which then necessitates back-bench reconstruction of the hepatic arterial supply, usually with the A/R RHA stump being anastomosed to the gastroduodenal artery stump.

Although this practice is acceptable, it can be potentially damaging. The commonest grievance is the division of the A/R RHA close to the liver, which leaves little room for tension-free reconstruction. Occasionally, it can cause division of a low bifurcation of the CHA mistakenly identified as an A/R RHA. This is particularly unfortunate as one might have otherwise achieved liver reperfusion with a single anastomosis without pancreatic graft compromise. In a rare and worst case scenario, a completely replaced proper hepatic artery/CHA arising from the SMA might be divided, and this could potentially result in the need for complex back-bench reconstruction. All of this raises the need to revisit these unwritten protocols.^{11,12} Obviously, the counterargument has been possible injury to the pancreatic capsule.⁷ However, we believe that, with the vessels being in the connective tissue outside the capsule rather than in the pancreatic parenchyma with natural tissue planes between them, damage should be rare with an awareness of the anatomy and with attention to detail. It is to be noted that

dissection of the CHA off the pancreas is not dissimilar and is currently routine.

In our study, we used DSA because it is an accepted standard for the study of arterial anatomy. In addition, it offers advantages over the dissection technique for study of the arterial anatomy, such as the ability to locate smaller vessels and reveal undisturbed anatomy (in comparison with autopsy and donor liver studies). In our opinion, the validity of such studies is subject to the quality of dissection and, at the best of times, depicts extra-organ anatomy.

Analyzing our findings, we found that the prevalence of anomalous vessels and visualized communications, such as that of the IPDA, was in keeping with past literature.¹³⁻¹⁵ In the current study, the size of individual vessels and the variations found, especially in the presence of anomalous arteries (eg, the mean CHA diameter was 5.27 mm versus 5.93 mm when an A/R RHA was absent), reconfirmed their importance in providing segmental flow to the target organ. Although it is probably too simplistic to correlate blood flow to the width of the vessel during angiography, we felt that recording the size of vessels might help us in appreciating the approximate proportion of blood flow through a vessel to an organ; this is especially interesting in the presence of accessory vessels. Furthermore, the size of vessels is clearly of importance when vascular reconstruction is considered. It should be noted that the images provided by DSA represent the internal diameter of the vessel, so inclusion of the vessel wall will add approximately 2 mm to the diameter of the vessel. In the absence of Doppler measurements of individual vessels, which themselves might be flawed because of local arterial spasms (secondary to the dissection required), it provides a surrogate.

Most importantly, our study has demonstrated that even in the presence of anomalous arteries and anatomy (the mean distance noted here between the IPDA and the A/R RHA was 29 mm), careful dissection will provide sufficient length and a Carrel patch to both teams in a majority (75%) of cases (the IPDA/SMA junction for the pancreatic team and the A/R RHA with a short segment of the SMA for the liver team; Fig. 6). In a quarter of cases, because of the observed common origins, the liver team might need the SMA and leave the IPDA without a cuff. It is worth noting that because the back-bench vascular reconstruction of the pancreatic whole organ graft normally involves anastomosis of the donor SMA to a limb of the donor iliac artery Y graft, the size discrepancy between the IPDA without an SMA cuff and the iliac branch might make the pancreatic graft unusable on those occasions when the SMA patch does not accompany the IPDA (ie, in the presence of a common origin).

In practice, the technical aspects of multiorgan retrieval can be uncomplicated despite accessory vessels. Initially, in the warm phase, we recommend looking for the A/R RHA directly behind the common bile duct (CBD) within the hepatoduodenal ligament just above the pancreatic head by palpation and/or direct vision. If the A/R RHA is not obvious, then divi-

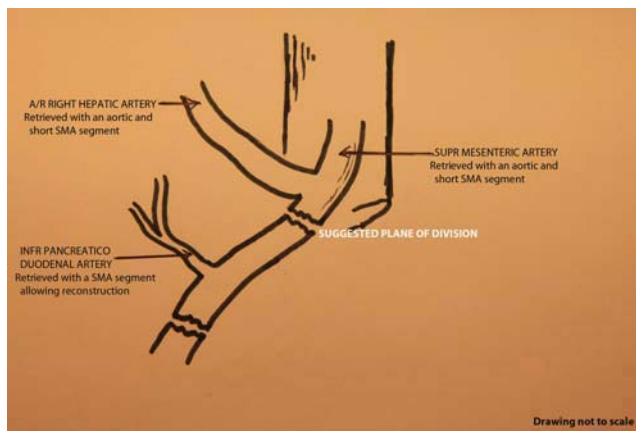


Figure 6. Diagrammatic representation of the suggested plane of division of the SMA. Separate accessory RHA and IPDA origins potentially allow an uncompromised accessory RHA (with its Carrel patch) without risk of prejudice to the pancreatic graft if retrieval is accurately performed. In this series, 3 of the IPDAs in the 12 patients with an A/R RHA had a common origin with the A/R RHA on the SMA, in which the aforementioned division would not have been possible. [Color figure can be viewed in the online issue, which is available at www.interscience.wiley.com.]

sion of the periductal (CBD) lymphatics and exposure of the CBD, followed by the ligation and division of the CBD itself, will facilitate further examination of the anatomical area in which the A/R RHA normally lies. It is important to ensure that the artery itself is not taken up in the tie during ligation of the CBD. Once its presence is suspected or confirmed, no further action of special note is required at this stage. It is crucial not to divide or tie the A/R RHA prior to perfusion as this will lead to significant underperfusion of the right lobe if indeed it is a replaced artery (as opposed to an accessory artery; Figs. 1 and 2). In the cold phase, after perfusion and division of the CBD and the portal vein, follow this often sizeable vessel carefully and dissect behind the pancreatic capsule; this is similar to following the CHA on the anterosuperior surface of the pancreas. As mentioned previously, the vessel is always embedded in the retroperitoneum behind the pancreatic capsule, and its origin to the SMA can be reached without capsular damage to the pancreatic graft. Both in our collective retrieval surgery experience and in the present angiographic study, the A/R RHA mostly branched off from the SMA within 5 to 10 mm of the SMA origin. Once the junction between the SMA and the A/R RHA is visualized, the SMA can be divided just distally to it, the SMA stump being left with the IPDA (Fig. 6). The liver can then be retrieved along with the SMA and the celiac trunk on 1 aortic patch. Although it is in theory possible to open the lumen of the aorta and trace the origin of the SMA or to dissect enough to find the IPDA origin and its branches from the inside, this would be difficult and potentially damaging to the vessel (traction injury) or the pancreatic capsule and cannot be recommended.

In addition to demonstrating an alternative surgical technique for multiorgan retrieval in the presence of anomalous vessels, this study serves as a current reference standard for the common patterns, sizes, and origins of vessels in this region, which could also be relevant for pancreatic resections in which anatomical variants of the hepatic blood supply (found in 20.1% of the cases) need to be kept in mind.¹⁶ However, because this study includes only patients and not the general population, which potentially might have a different prevalence of anatomical variants, an inherent selection bias is possible.

In conclusion, the A/R RHA incidence in our series was 12%, and no case had an IPDA originating from the A/R RHA. Separate accessory RHA and IPDA origins on the SMA potentially allow an uncompromised accessory RHA (with its Carrel patch) without concession of the pancreatic graft in most cases if retrieval is accurately performed.

However, in a quarter of the cases in which there is an A/R RHA, a common origin with the IPDA might necessitate back-bench reconstruction to enable the transplantation of both organs. Our measurements serve as a reference for such retrievals.

REFERENCES

1. Michels NA. Blood Supply and Anatomy of the Upper Abdominal Organs with a Descriptive Atlas. Philadelphia, PA: Lippincott; 1955.
2. Androulakis J, Colborn GL, Skandalakis PN, Skandalakis LJ, Skandalakis JE. Embryologic and anatomic basis of duodenal surgery. *Surg Clin North Am* 2000;80:171-199.
3. Sollinger HW, Vernon WB, D'Alessandro AM, Kalayoglu M, Stratta RJ, Belzer FO. Combined hepatic and pancreaticoduodenal procurement with Belzer-UW solution. *Surgery* 1989;106:685-691.
4. Marsh CL, Perkins JD, Sutherland DE, Corry RJ, Sterioff S. Combined hepatic and pancreaticoduodenal procurement for transplantation. *Surg Gynecol Obstet* 1989;168:254-258.
5. Ferraz-Neto BH, Meira-Filho SR, Hidalgo R, Rezende MB, Zurstrassen MP, Thomé T, et al. Correlation between graft arterial anatomy and biliary complications after liver transplantation. *Transplant Proc* 2007;39:2514-2515.
6. Merion RM, Burtch GD, Ham JM, Turcotte JG, Campbell DA. The hepatic artery in liver transplantation. *Transplantation* 1989;48:438-443.
7. Molmenti EP, Klein AS, Henry ML. Procurement of liver and pancreas allografts in donors with replaced/accessory right hepatic arteries. *Transplantation* 2004;78:770-771.
8. Ames SA, Kisthard JK, Smith JL, Piper JB, Corry RJ. Successful combined hepatic and pancreatic allograft retrieval in donors with a replaced right hepatic artery. *Surg Gynecol Obstet* 1991;173:216-222.
9. Mayes JT, Schulak JA. Pancreas revascularization following combined liver and pancreas procurement. *Transplant Proc* 1990;22:588-589.
10. Sansalone CV, De Carlis L, Rondinara GF, Colella G, Rossetti O, Slim AO, et al. Right hepatic artery replacement from superior mesenteric artery in combined liver-whole pancreas procurement. Technical problems and liver graft artery reconstruction. *Transplant Proc* 1994;26:3537-3539.
11. Covey AM, Brody LA, Maluccio MA, Getrajdman GI, Brown KT. Variant hepatic arterial anatomy revisited: digital subtraction angiography performed in 600 patients. *Radiology* 2002;224:542-547.
12. Hiatt JR, Gabbay J, Busuttill RW. Surgical anatomy of the hepatic arteries in 1000 cases. *Ann Surg* 1994;220:50-52.
13. Chevallier JM, Hannoun L. Anatomic bases for liver transplantation. *Surg Radiol Anat* 1991;13:7-16.
14. López-Andújar R, Moya A, Montalvá E, Berenguer M, De Juan M, San Juan F, et al. Lessons learned from anatomic variants of the hepatic artery in 1,081 transplanted livers. *Liver Transpl* 2007;13:1401-1404.
15. Arjhansiri K, Charoenrat P, Kitsukjit W. Anatomic variations of the hepatic arteries in 200 patients done by angiography. *J Med Assoc Thai* 2006;89(suppl 3):S161-S168.
16. Yang SH, Yin YH, Jang JY, Lee SE, Chung JW, Suh KS, et al. Assessment of hepatic arterial anatomy in keeping with preservation of the vasculature while performing pancreatoduodenectomy: an opinion. *World J Surg* 2007;31:2384-2391.