



# THE UNIVERSITY *of* EDINBURGH

## Edinburgh Research Explorer

### Experimental infection of sheep with visna/maedi virus via the conjunctival space

**Citation for published version:**

Niesalla, H, McNeilly, TN, Ross, M, Rhind, SM & Harkiss, GD 2008, 'Experimental infection of sheep with visna/maedi virus via the conjunctival space' *Journal of General Virology*, vol. 89, no. 6, pp. 1329-1337.  
DOI: 10.1099/vir.0.2008/000133-0

**Digital Object Identifier (DOI):**

[10.1099/vir.0.2008/000133-0](https://doi.org/10.1099/vir.0.2008/000133-0)

**Link:**

[Link to publication record in Edinburgh Research Explorer](#)

**Document Version:**

Publisher's PDF, also known as Version of record

**Published In:**

*Journal of General Virology*

**Publisher Rights Statement:**

Open Access Article

**General rights**

Copyright for the publications made accessible via the Edinburgh Research Explorer is retained by the author(s) and / or other copyright owners and it is a condition of accessing these publications that users recognise and abide by the legal requirements associated with these rights.

**Take down policy**

The University of Edinburgh has made every reasonable effort to ensure that Edinburgh Research Explorer content complies with UK legislation. If you believe that the public display of this file breaches copyright please contact [openaccess@ed.ac.uk](mailto:openaccess@ed.ac.uk) providing details, and we will remove access to the work immediately and investigate your claim.



# Experimental infection of sheep with visna/maedi virus via the conjunctival space

Heide Niesalla,† Tom N. McNeilly,‡ Margaret Ross, Susan M. Rhind and Gordon D. Harkiss

Correspondence  
Gordon D. Harkiss  
gordon.harkiss@ed.ac.uk

Division of Veterinary Biomedical Sciences, College of Medicine and Veterinary Medicine, University of Edinburgh, Summerhall, Edinburgh EH9 1QH, UK

Experiments were performed to determine whether visna/maedi virus (VMV), a small ruminant lentivirus (SRLV), could infect sheep via ocular tissues. The EV1 strain of VMV was administered into the conjunctival space of uninfected sheep, and the animals monitored for the presence of provirus DNA and anti-VMV antibodies in blood. The results showed that provirus DNA appeared in peripheral blood mononuclear cells of all animals within a few weeks of receiving either  $10^6$  TCID<sub>50</sub> or  $10^3$  TCID<sub>50</sub> of VMV. Of the animals receiving the higher dose of virus via the conjunctival space, two seroconverted by 7 and 10 weeks post-infection, one seroconverted 8 months post-infection, and one had not seroconverted by 15 months post-infection. With the lower virus dose, the animals infected via the trachea seroconverted by 4 and 14 weeks, respectively. After ocular infection with this dose, one animal showed a transitory seroconversion with low levels of antibody, peaking at 2 weeks post-administration. The remaining three of the animals infected via the eyes did not seroconvert over a period of 13 months. At post-mortem, evidence for the presence of proviral DNA was obtained from ocular tissue, lungs or mediastinal lymph node in both groups of animals. Histological analysis of lung tissue from animals receiving the lower dose of virus showed the presence of early inflammatory lesions. The results thus show for the first time that transmission of VMV can occur via ocular tissues, suggesting that the conjunctival space may be an additional route of natural transmission.

Received 8 January 2008  
Accepted 28 February 2008

## INTRODUCTION

Visna/maedi virus (VMV) and caprine arthritis encephalitis virus (CAEV) are small ruminant lentiviruses (SRLV) that cause chronic progressive inflammatory disease in the lungs, brain, joints and mammary glands of sheep and goats (Haase, 1986). Lymphoid tissue hyperplasia is also a feature, and more rarely lesions can be found in other tissues such as the kidneys, liver and heart (Georgsson & Palsson, 1971; Brellou *et al.*, 2007). Recently, evidence for involvement of ocular tissues has been provided in natural cases of VMV infection (Capucchio *et al.*, 2003).

The SRLV show a distinct tropism for cells of the monocyte-macrophage lineage and hence target organs rich in these cell types (Narayan *et al.*, 1982; Gendelman *et al.*, 1986). The main routes of infection are thought to be ingestion of colostrum or milk containing infected macrophages and/or free virus or via contact with respiratory aerosols (Cutlip

*et al.*, 1985; Adams *et al.*, 1983; van der Molen & Houwers, 1987; Palsson, 1976). It is known that alveolar macrophages are a target for infection (Gendelman *et al.*, 1986) and it has been recently demonstrated that lung fluid from naturally infected sheep contains free virus at levels commensurate with efficient transmission via contact with respiratory secretions (McNeilly *et al.*, 2007). It has also been shown that infection via the distal lung tissues is very efficient compared with tracheal (McNeilly *et al.*, 2007) or nasal tissues (Torsteinsdóttir *et al.*, 2003). The available information thus points to transmission between adult animals occurring through inhalation of aerosolized free virus and possibly aerosolized alveolar macrophages and subsequent infection of recipient alveolar macrophages or respiratory tract dendritic cells (Pepin *et al.*, 1998).

The observation that ocular tissues may be a natural target for infection (Capucchio *et al.*, 2003) indicates that appropriate target cells for VMV reside in eye tissues. Virus antigen was found in the third eyelid, a structure that is contiguous with conjunctival tissue (Baba *et al.*, 1995). Indeed, conjunctiva-associated lymphoid tissue (CALT) has been described in many species (Baba *et al.*, 1995; Knop & Knop, 2005). CALT patches have been shown to contain lymphocytes, M cells, dendritic cells and lymphoid follicles with germinal centres (Kageyama *et al.*, 2006). Given that

Published online ahead of print on 11 March 2008 as DOI 10.1099/vir.0.2008/000133-0.

†Present address: Institute of Biotechnology, University of Cambridge, Tennis Court Road, Cambridge CB2 1QT, UK.

‡Present address: Division of Parasitology, Moredun Research Institute, Pentlands Science Park, Penicuik, Midlothian EH26 0PZ, UK.

aerosolized lung fluid could contain free virus, it is conceivable that infection may occur through ocular contact of such infected fluid with CALT patches in either conjunctival tissue or the third eyelid by aerosol droplets or through eye licking. However, the eyes possess natural defence mechanisms which could limit infection through this route. For example, the production of lysozyme, proteases, defensins and other components of innate defences act to provide a barrier to pathogens (Streilein, 1999). Constant drainage of ocular extracellular fluid into the nasal passages also serves to clear the eyes of potential infectious agents. Despite this, it has been shown that many virus infections can occur via ocular tissues either naturally, experimentally or iatrogenically. Examples include adenovirus (Bell *et al.*, 1956), measles virus (Rozina *et al.*, 1988), cytomegalovirus (Zhang *et al.*, 2007), herpes simplex virus 1 (Orlando *et al.*, 2006; Robert *et al.*, 2005) and Ebola virus (Jaax *et al.*, 1996). Recent data also raise the possibility that avian influenza virus H7N7 and adenovirus 37 may gain access via ocular tissues (Olofsson *et al.*, 2005).

In this report, we have investigated whether the lentivirus VMV can infect sheep via the conjunctival space. We have used the tracheal route of infection as a known efficient route of infection as a control, and tested two doses of virus to assess the efficiency of ocular infection in sheep.

## METHODS

**Virus propagation and titration.** Low-passage VMV strain EV1 (Sargan *et al.*, 1991) was propagated routinely on ovine skin fibroblast cells (OSCs) in Dulbecco's modified Eagle's medium (DMEM) supplemented with 10% fetal calf serum (FCS). Virus-containing culture medium was clarified by centrifugation for 10 min at 400 g and subsequently filtered through a 0.2 µm syringe-driven filter (Nalgene). Tissue culture medium from uninfected OSCs was used as a negative control. Virus titres were determined as described previously using OSCs as indicator cells (Ebrahimi *et al.*, 2000). Titres were expressed as tissue culture infectious dose 50% (TCID<sub>50</sub>).

**Isolation of peripheral blood mononuclear cells (PBMCs).** Blood was collected into an EDTA-containing Vacutainer (Becton Dickinson) and PBMCs were isolated using a Ficoll-Paque density gradient (GE Healthcare) according to the manufacturer's instructions. Cells were pelleted by centrifugation at 100 g for 10 min and the resultant cell pellet was resuspended in 200 µl phosphate buffered saline. DNA was subsequently extracted using a DNeasy mini kit (Qiagen).

**Detection of VMV provirus.** VMV provirus was detected by semi-nested PCR (snPCR) using the first-round primer pair *gag* 1 and *gag* 5 and second-round primer pair *gag* 1 and *gag* 2 to give a 463 bp product as described previously (McNeilly *et al.*, 2007). The detection threshold of the snPCR was 50 plasmid copies/reaction.

**Detection of VMV-specific serum antibodies.** Serum samples diluted 100-fold were tested for the presence of virus-specific antibodies to the major core protein p25 of VMV and/or the viral transmembrane protein gp46 using a commercial ELISA kit (ELITEST-MVV/CAEV; Hyphen BioMed) (Saman *et al.*, 1999). Absorbance values were measured using a BioTek Microplate Autoreader (BioTek Instruments). Based on pre-infection values, an arbitrary cut-off of 0.1 optical density values was used to determine positive and negative reactions.

**Sheep and experimental design.** Fifteen Blackface or Blackface cross ewes aged between 18 months and 2 years were used for the experimental infection studies. All sheep were commercially sourced. Prior to VMV infection studies, sheep were determined to be free from VMV proviral DNA using snPCR, and seronegative for VMV-specific antibodies using ELISA. All experimental procedures involving animals were approved by The University of Edinburgh's Biological Services Ethical Review Committee and were performed under licence as required by the UK Animals (Scientific procedures) Act 1986.

Six sheep received a 10<sup>6</sup> TCID<sub>50</sub> dose of the EV1 strain of VMV; a second group of six sheep received a 10<sup>3</sup> TCID<sub>50</sub> dose of EV1. Two animals in each group received VMV via the trachea. The four remaining animals in each group received virus via the conjunctival space. One negative control sheep (C1) received uninfected tissue culture medium in the same manner via the conjunctival space. Blood samples were taken at regular intervals over a period of several weeks or months for measurement of VMV provirus and anti-VMV antibodies. A further two sheep (C2 and C3) were untreated and were used as negative controls in the post-mortem studies.

**Intra-tracheal and ocular inoculation of VMV.** Sheep were sedated by intramuscular injection of xylazine hydrochloride (Rompun; Bayer) at a dose rate of approximately 0.5 mg kg<sup>-1</sup>. One millilitre volumes of cell-free virus (10<sup>6</sup> TCID<sub>50</sub>) were injected into the proximal third of the trachea via a 21 gauge needle, avoiding the tracheal cartilage. The neck was held in dorsiflexion for 1–2 min post-instillation. For ocular inoculation, sheep were similarly sedated and 500 µl of the same virus preparation or control medium was introduced drop-wise into the conjunctival space of each eye over a period of approximately two minutes.

**Post-mortem provirus detection and histopathological analysis.** Two sheep receiving the 10<sup>6</sup> TCID<sub>50</sub> dose of virus intratracheally (sheep 607c, 329c) or ocularly (sheep 405, 301) were killed 8 months post-infection and necropsied. The remaining two of the sheep in this group (sheep 271 and 200) were blood sampled for a further 7 months and necropsied at 15 months post-infection. All sheep receiving the 10<sup>3</sup> TCID<sub>50</sub> dose of virus were necropsied at 13 months post-infection. Two uninfected control sheep (C2, C3) were also necropsied at the same time.

Bronchiolar lavage was performed as follows: a Luer-tipped 50 ml syringe was wedged into selected segmental bronchi and a single 40 ml aliquot of normal saline was used to wash the lung segment. Bronchiolar lavage samples were passed through sterile gauze into sterile 50 ml Falcon tubes on ice and subsequently centrifuged at 400 g for 7 min at 4 °C to separate out the cellular fraction (BAL cells). DNA was extracted from the BAL cells for snPCR analysis. The following tissues were taken for DNA extraction and sectioning: left cardiac lung lobes, right and left conjunctiva, and right and left third eyelids. Tissue sections were stained with haematoxylin and eosin for histopathological analysis. The degree of airways mononuclear cell infiltration, interstitial pneumonia and lymph node follicular reactivity were assessed and lesions were categorized as mild, moderate or severe by an experienced pathologist.

## RESULTS

### Provirus in blood of experimentally infected sheep

To determine whether sheep can be infected via the ocular route, blood samples were taken at regular intervals after experimental infection of sheep via the conjunctival space

or the trachea and proviral DNA measured in PBMCs. Positive snPCR reactions were first observed in sheep that received  $10^6$  TCID<sub>50</sub> via the trachea 2–4 weeks post-infection (Table 1). In sheep that received  $10^6$  TCID<sub>50</sub> VMV via the conjunctival space, the animals first became positive by snPCR at 4, 5 and 9 weeks post-infection. Thereafter, positive reactions were found in all sheep over the following 22 weeks. All sheep tested gave intermittent negative reactions on occasions, and the strength of the PCR band obtained ranged from weak to strong in the same animal over time. Representative examples of the snPCR results are shown in Fig. 1. No reactions were observed in samples taken prior to infection in either group (Fig. 1a, high-dose group). The results obtained on week 15 post-infection with  $10^6$  TCID<sub>50</sub> are shown in Fig. 1b. All sheep gave positive bands, though the reactions obtained with sheep 301 and sheep 200 at this time point were weak. A similar analysis was performed on sheep infected with  $10^3$  TCID<sub>50</sub>. Again, positive reactions were obtained from week 2 post-infection in both sheep infected via the trachea and one of the sheep infected via the eyes (Table 1). The other three animals of the latter group became positive at 4 weeks post-infection. Similar fluctuations in positivity and strength of reaction were observed in this group of animals as was found in animals that received the higher dose of virus. PBMCs from control animal C1 were tested by snPCR on weeks 0, 2, 4, 6 and 7 post-inoculation with uninfected tissue culture medium and were consistently negative (not shown).

The proportions of samples that were PCR positive are shown in Table 1. For statistical purposes, the data from

animals infected via the conjunctival space ( $n=8$ ) were pooled and compared with the pooled data from the sheep infected via the trachea ( $n=4$ ) using the Mann–Whitney rank test. The median and inter-quartile range for the tracheal group was 64 and 48–79, while for the conjunctival group it was 57 and 46–70. There was no significant difference between the two routes of infection.

### Seroconversion of experimentally infected sheep

To ascertain whether virus gene expression had taken place *in vivo* after ocular infection, serum samples obtained from the experimentally infected animals were analysed for evidence of seroconversion by ELISA. The results are shown in Figs 2 and 3 and Table 1. The animals infected via the trachea with a virus dose of  $10^6$  TCID<sub>50</sub> both seroconverted by 2 weeks post-infection, and remained seropositive for the period of sampling (sheep 607c and 329c) (Fig. 2). Similarly, two animals that received this virus dose via the conjunctival space also seroconverted, at 7 and 10 weeks post-infection, respectively (sheep 405 and 301). Sheep 271 was negative throughout the period of observation while sheep 200 showed delayed seroconversion, taking approximately 8 months for antibodies to appear.

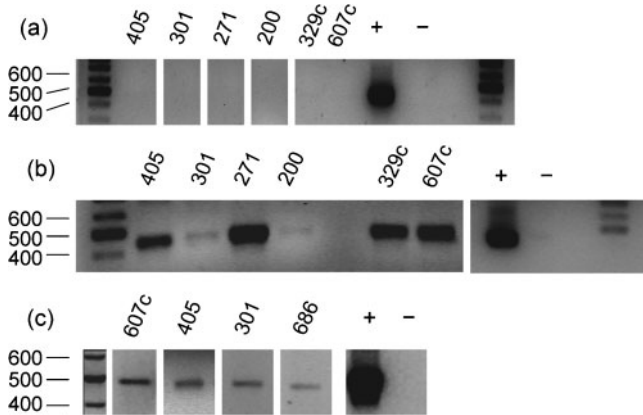
The animals that were infected with  $10^3$  TCID<sub>50</sub> dose via the trachea seroconverted 4 and 14 weeks post-infection, with sheep 297c showing very high levels of antibody while sheep 361c had only low levels (Fig. 3). In contrast, only one of four animals infected via the conjunctival space seroconverted, as determined by ELISA, over the 13 month

**Table 1.** Summary of provirus detection in blood by PCR following tracheal or ocular infection with  $10^6$  TCID<sub>50</sub> or  $10^3$  TCID<sub>50</sub> EV1 strain of VMV

NR, Negative reaction; NSC, no seroconversion; p.i., post-infection.

Sheep number	Inoculation route	Time to become PCR positive (weeks p.i.)	Number of samples PCR positive/tested (%)*	Time to seroconversion (weeks p.i.)
$10^6$ TCID <sub>50</sub>				
607c	Trachea	4	10/16 (63)	2
329c	Trachea	2	11/17 (65)	2
405	Conjunctival space	9	10/18 (56)	7
271	Conjunctival space	4	12/18 (67)	NSC
301	Conjunctival space	5	13/18 (72)	10
200	Conjunctival space	4	9/18 (50)	31
$10^3$ TCID <sub>50</sub>				
297c	Trachea	2	11/12 (92)	4
361c	Trachea	2	4/12 (33)	14
299	Conjunctival space	4	7/12 (58)	2
236	Conjunctival space	4	4/12 (33)	NSC
606	Conjunctival space	4	5/12 (42)	NSC
686	Conjunctival space	2	9/12 (75)	NSC
Negative control				
C1	Conjunctival space	NR	0/4 (0)	NSC

\*Over a period of 22 weeks post-challenge for sheep that received  $10^6$  TCID<sub>50</sub> VMV, 12 weeks post-challenge for sheep that received  $10^3$  TCID<sub>50</sub> VMV, and 7 weeks post-challenge with saline for control sheep C1. All sheep were negative pre-challenge.



**Fig. 1.** Detection of VMV provirus DNA in peripheral blood mononuclear cells (PBMC) or ocular tissues following infection with EV1 strain of VMV. Sheep identification numbers are shown above each track. Sheep 405, 301, 271 and 200 received virus into the conjunctival space; sheep 329c and 607c received virus via the trachea. The sizes of the molecular mass markers are given as number of base pairs. (a) Provirus DNA in PBMC samples from week 0 pre-infection with  $10^6$  TCID<sub>50</sub> VMV. (b) Provirus DNA in PBMC samples from week 15 post-infection with  $10^6$  TCID<sub>50</sub> VMV. (c) Provirus DNA in samples from left conjunctiva (sheep 607c) and right third eyelid (sheep 405 and sheep 301) of sheep infected with  $10^6$  TCID<sub>50</sub> VMV, and left conjunctiva of sheep 686 which was infected with  $10^3$  TCID<sub>50</sub> VMV. +, Positive; -, negative.

period of observation. The antibody response in this animal (sheep 299) was low and transitory, peaking around 3 weeks post-infection (Fig. 3). We interpreted the appearance of a 'peak' of antibody values above 0.1 OD cut-off in sheep 361c and sheep 299 as evidence in favour of a 'real' seroconversion. However, sheep 236, 606 and 686 did not show a pattern that could be convincingly described as a 'peak' with values above 0.1 OD. Sera from control animal C1 were tested by ELISA on weeks 0, 2, 4, 6 and 7, and were consistently negative (not shown).

There was no obvious correlation between the viral load as measured by the number of successful PCR reactions and the serological status of the animals.

**Proviral DNA in tissues of experimentally infected sheep**

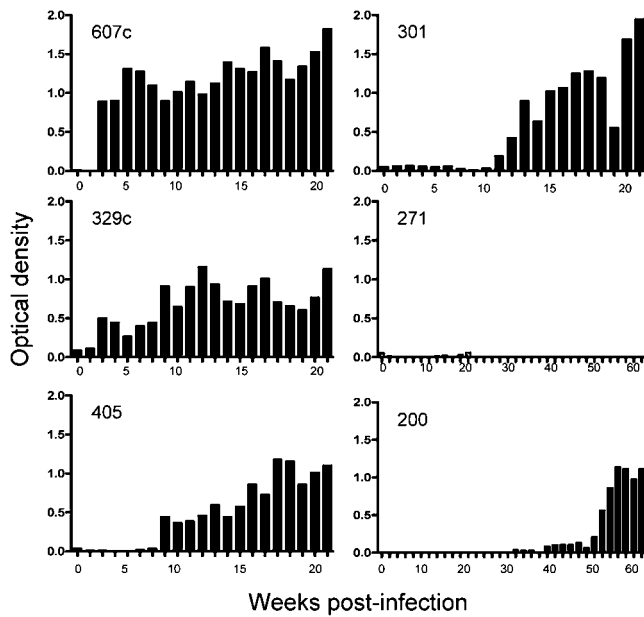
To determine whether VMV was present at and/or had disseminated from the site of inoculation, tissues from the eyes, lung, and mediastinal lymph node (MLN) were taken at post-mortem and analysed for the presence of proviral DNA by snPCR. All sheep gave positive PCR reactions in blood samples taken immediately prior to post-mortem (not shown). An analysis of proviral DNA in pulmonary and ocular tissues was undertaken in both groups of sheep. The results are shown in Table 2 and representative snPCR gels are shown in Fig. 1c. In sheep infected with a  $10^6$

**Table 2.** Summary of provirus detection in tissues by PCR following tracheal or ocular infection with  $10^6$  TCID<sub>50</sub> or  $10^3$  TCID<sub>50</sub> EV1 strain of VMV

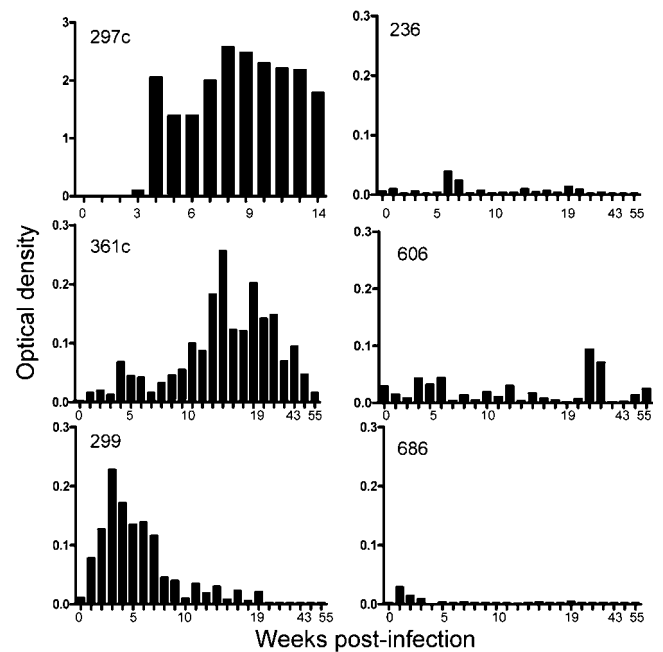
RC, Right conjunctiva; LC, left conjunctiva; R3L, right third eyelid; L3L, left third eyelid; Lung, left cranial lung lobe; MLN, mediastinal lymph node; BAL, bronchiolar lavage cells; UT, untreated.; ND, not done; +, positive by PCR; -, negative by PCR; +/-, equivocal PCR reactions.

Sheep number*	Inoculation route	Tissue sampled						
		RC	LC	R3L	L3L	Lung	MLN	BAL
<b><math>10^6</math> TCID<sub>50</sub></b>								
607c	Trachea	-	+	-	-	+	ND	ND
329c	Trachea	-	+	-	-	-	ND	ND
405	Conjunctival space	+	-	+	-	-	ND	ND
271	Conjunctival space	+/-	+/-	-	+/-	+/-	-	ND
301	Conjunctival space	-	+	+	+	+	ND	ND
200	Conjunctival space	-	-	-	-	-	+/-	ND
<b><math>10^3</math> TCID<sub>50</sub></b>								
297c	Trachea	-	-	-	-	-	-	+
361c	Trachea	-	-	-	-	-	-	-
299	Conjunctival space	-	-	-	-	-	-	-
236	Conjunctival space	-	-	+/-	-	+/-	-	-
606	Conjunctival space	-	-	-	-	-	-	-
686	Conjunctival space	-	+	-	-	-	-	-
<b>Negative control</b>								
C1	Conjunctival space	-	-	-	-	-	-	-
C2	UT	-	-	-	-	-	-	-
C3	UT	-	-	-	-	-	-	-

\*One negative control sheep (C1) and two untreated control sheep (C2, C3) were also necropsied.



**Fig. 2.** Detection of anti-VMV antibody by ELISA in sheep infected with  $10^6$  TCID<sub>50</sub> EV1 strain of virus. Sheep 405, 301, 271 and 200 received virus into the conjunctival space; sheep 329c and 607c received virus via the trachea. Optical density scale 0–2.0 for all panels.



**Fig. 3.** Detection of anti-VMV antibody by ELISA in sheep infected with  $10^3$  TCID<sub>50</sub> EV1 strain. Sheep 236, 299, 606 and 686 received virus into the conjunctival space; sheep 361c and 297c received virus via the trachea. Optical density scale 0–3.0 for sheep 297c, and 0–0.3 for other panels.

TCID<sub>50</sub> dose of VMV via the trachea, positive snPCR signals were obtained from the left conjunctiva and lung of sheep 607c. In sheep 329c, a positive reaction was found in the left conjunctival tissue (Table 2).

Several positive reactions were found in sheep infected via the conjunctival space. Sheep 405 showed clear positive reactions in the right third eyelid and right conjunctiva, while sheep 301 was tested positive for proviral DNA in the right third eyelid and the lung tissue (Fig. 1c). Very weak equivocal reactions were discernible in sheep 271 and 200 when compared with control samples from two uninfected animals analysed at the same time (not shown).

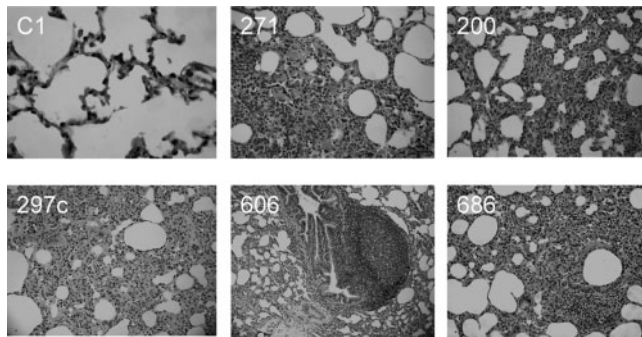
One of the two sheep receiving the  $10^3$  TCID<sub>50</sub> virus dose via the trachea (sheep 297c) gave a positive reaction in BAL cells, but gave negative reactions in all other tissues (Table 2). Sheep 361c gave negative reactions for all tissues examined. Sheep 686 received virus via the conjunctival space and gave a positive signal from the left conjunctiva (Fig. 1c). Sheep 236 showed weak positive signals in the right third eyelid and lung, while sheep 299 and 606 gave negative signals in all tissues (Table 2).

### Histopathological analysis of experimentally infected sheep

To determine whether infection via the eyes resulted in the development of lesions in the eyes, lung or MLN, tissue samples taken at post-mortem were subjected to

histopathological analysis. Two sheep infected via the ocular route were analysed from the group receiving  $10^6$  TCID<sub>50</sub>, while all sheep receiving a  $10^3$  TCID<sub>50</sub> dose were examined. The degree of airways mononuclear cell infiltration, interstitial pneumonia and lymph node follicular reactivity were assessed and the lesions scored for severity. Representative lesions are shown in Fig. 4. Samples from the three negative control sheep showed no evidence of significant lesion formation in lungs (Fig. 4) or ocular tissues (not shown). Very mild follicular reactivity was present in the MLN of one control animal. Two sheep that had been infected via the conjunctival space with the  $10^6$  TCID<sub>50</sub> virus dose had mild lesions in the lungs (Fig. 4). This consisted of perivascular and peribronchiolar infiltration by mononuclear cells and some prominent bronchiole-associated lymphoid tissue. These animals also had mild to moderately severe follicular reactivity in the MLN (not shown).

Two animals receiving the  $10^3$  TCID<sub>50</sub> virus dose via the trachea showed evidence of perivascular and peribronchiolar infiltration by mononuclear cells, mild interstitial lesion formation in lung tissue (Fig. 4), and mild to moderate follicular reactivity in the MLN (not shown). Three out of four animals infected via the conjunctival space (sheep 299, 606 and 686) showed evidence of perivascular and peribronchiolar infiltration with mononuclear cells, mild focal interstitial lung lesions (Fig. 4), and mild to moderate follicular reactivity (not shown).



**Fig. 4.** Histological lesions in lung tissue at post-mortem following infection with  $10^6$  TCID<sub>50</sub> VMV via the conjunctival space (sheep 271, 200) or  $10^3$  TCID<sub>50</sub> VMV via the trachea (sheep 297c) or conjunctival space (sheep 606, 686). The sheep identification numbers are shown in each panel.

No differences in the degree of mononuclear cell infiltration or follicular reactivity were noted in the ocular tissues of infected animals of either group of animals compared with negative controls (not shown).

## DISCUSSION

The main *in vivo* target cells for VMV are macrophages and dendritic cells (Gendelman *et al.*, 1986; Gorrell *et al.*, 1992; Brodie *et al.*, 1995; Ryan *et al.*, 2000), and any peripheral tissue containing these cells could potentially be involved in transmission and support replication and dissemination of virus to the blood stream (Blacklaws *et al.*, 2004; Peterhans *et al.*, 2004). In infected animals, it has been shown that the bone marrow acts as a reservoir of infected cells and releases infected monocytes into the blood stream for dissemination to target tissues (Gendelman *et al.* 1985). Monocytes are thought not to be permissive for virus replication for reasons of immaturity, and it is only once these cells migrate into tissues and differentiate into mature macrophages that they are able to support productive infection (Narayan *et al.*, 1983; Gendelman *et al.*, 1986). It is likely that further activation of such infected macrophages by inflammatory stimuli or possibly housekeeping activities is required for a full virus replication cycle to take place (Small *et al.*, 1989). Following infection, animals tend to show an initial burst of replication within a few weeks, followed by an extended period of restricted replication or latency (Brahic *et al.*, 1981; Haase *et al.*, 1977; Vigne *et al.*, 1987; Staskus *et al.*, 1991). The mechanisms underlying such *in vivo* restriction are not well understood, though interferon-like cytokines may be involved (Zink & Narayan, 1989).

In the present study, we investigated whether sheep could be infected via the conjunctival space by first determining the presence of proviral DNA in blood by snPCR (Table 1). Positive signals were obtained from all animals infected this way in the first few weeks after infection. The proviral DNA

positivity fluctuated on a weekly basis, as did the apparent strength of reactions. The pattern of positive reactions over a period of 3–4 months was consistent with that described in the literature for virus isolation after experimental infection via other routes (Petursson *et al.*, 1976; Larsen, Hyllseth & Krogsrud, 1982a; Torsteinsdóttir *et al.*, 1997; Juste *et al.*, 1998). The results showed clearly that animals could be infected via the ocular route even with the relatively low virus dose of  $10^3$  TCID<sub>50</sub>. In a study by Torsteinsdóttir *et al.* (2003), it was shown that infection via the tracheal route could be achieved by as little as 10 TCID<sub>50</sub> of virus, while the minimum infectious dose for nasal transmission was  $10^6$  TCID<sub>50</sub>. We recently showed that the minimum infectious virus dose for tracheal tissue *in vitro* was  $10^5$  TCID<sub>50</sub>, and that *in vivo* the tracheal route was less efficient than direct virus exposure of the lung (McNeilly *et al.*, 2007). Thus, infection via the ocular route appears to be intermediate in efficiency between the deep lung and tissues of the upper respiratory tract.

To determine whether virus gene expression occurred following infection via the conjunctival space, animals were monitored for the appearance of anti-VMV antibodies by ELISA. In the animals that received the higher virus dose, seroconversion was evident a few weeks after infection in sheep infected via the trachea and in three out of four sheep infected via the conjunctival space. One of the sheep infected via the ocular route showed delayed seroconversion around 8 months post-infection. Delayed seroconversion is an established feature of SRLV, SIV, FIV and HIV infections (Houwens & van der Moelen, 1987; Cheevers *et al.*, 1988; Rimstad *et al.*, 1993; Villinger *et al.*, 1991; Hopper *et al.*, 1989; Horsburgh *et al.*, 1989; Clerici *et al.*, 1991). Large variations in time to seroconversion have been documented in VMV and CAEV infection, ranging from a few weeks to several months to years, and are thought to be due to the virus entering a state of restricted replication (Brahic *et al.*, 1981; Haase *et al.*, 1977; Staskus *et al.*, 1991). It was, therefore, not unexpected for delayed seroconversion to be observed in some of our experimentally infected animals. The results showed that virus replication was indeed productive and virus antigens had been recognized by the host immune system. No correlation between the number of positive PCR reactions and seroconversion was evident, though measuring viral load using quantitative real-time PCR methods might reveal a relationship.

In sheep that received the lower dose of virus, seroconversion was observed in both animals that had been infected via the trachea, but transiently in only one of the four animals infected via the conjunctival space. These animals were clearly virus-positive given their repeated positive reaction in the snPCR assay of PBMCs. In other studies, we have infected sheep with  $10^3$  TCID<sub>50</sub> of the same EV1 virus stock via the trachea and obtained evidence of infection using the same PCR and ELISA (data not shown). Other investigators have documented the efficiency of infection via the trachea (Juste *et al.*, 1998; Torsteinsdóttir *et al.*, 2003). The reason for the lack of seroconversion in three of

four animals receiving the lower dose of VMV via the eyes in the present study is unclear. Persistently virus-positive antibody-negative animals have been described by other workers studying natural transmission, though these tended to be only a small proportion of animals (De Boer *et al.*, 1979). In the latter study, some animals were found to be virus-positive but antibody-negative over several years of observation. It is possible that, had we followed our animals for longer, they may have eventually all seroconverted. As they stand, the results suggest that infection via the ocular route with low doses of virus may be an efficient way of generating PCR-positive, seronegative animals.

Transient or intermittent antibody production following experimental or natural infection has also been described in several studies (de Andrés *et al.*, 2005; Mordasini *et al.*, 2006). The reasons underlying this phenomenon are unknown, but are thought to be due to control of virus replication by the immune response. It is likely that this is due to cell-mediated responses, since neutralizing antibody responses are slow to develop in SRLV infections (Larsen *et al.*, 1982b).

At post-mortem, evidence was obtained for proviral DNA in one or more target tissues. Clear positive signals from the eye and/or lung were obtained from two out of four sheep infected via the conjunctival space with the higher virus dose, and weak signals could be discerned from tissues of the other two animals. When tissues from animals receiving the lower virus dose were examined, one out of four animals infected via the ocular route showed evidence of snPCR reactivity, while the remaining three animals gave either equivocal or negative signals. Detection of virus in tissues is often difficult, given the restricted replication pattern *in vivo* and the long protracted course of the infection. Hence, it would be expected that there would be only low numbers of virus-infected cells in target tissues, particularly after a relatively short period of infection.

It is also clear that there is great variability in which the organ system is affected in natural disease (Narayan & Clements, 1989). Therefore, while it might be expected that virus introduced into the lung via the trachea would establish foci of infection in the lung tissue and draining mediastinal lymph node, the low numbers of infected cells likely to be present after this time period could render detection uncertain. Thus, following introduction of virus into the conjunctival space, it was not at all certain that any of that input virus would reach the pulmonary system or locate there preferentially. It is therefore significant that positive signals from lung tissue were obtained following ocular administration. The results indicate that virus exited the eye tissues and gained access to the lungs. The high proportion of samples found positive by PCR in the blood of these animals is consistent with dissemination of virus into the circulation from the conjunctival space.

In the case of the eyes, the physiological function of the innate defences is to clear incoming pathogens quickly

through destruction and drainage into the nasal cavity. Hence, unless a focus of infection in the eyes was established, the expectation of detecting virus in the ocular tissues more than a year after administration would be low. However, positive signals were obtained from such tissues in the animals receiving the higher virus dose. This could indicate either that chronic infection was established in the eye tissue from input virus in at least some of the animals, or that virus dissemination to the blood stream and bone marrow had taken place with subsequent infiltration of the eye tissues by infected monocytes.

It is of interest to note that, despite the lack of seroconversion in some animals, evidence for the presence of early lesion formation was found in the lungs (mononuclear cell infiltration and interstitial proliferation) and/or draining mediastinal lymph node (follicular reactivity). While these inflammatory lesions are not pathognomonic for VMV infection, they are consistent with lesions typically found in animals infected naturally or experimentally with this virus (Petursson *et al.*, 1976; Houwers & van der Molen, 1987; Lujan *et al.*, 1994), and were not found in uninfected controls. It is generally thought that the lesions in SRLV infections are immune-mediated (Nathanson *et al.*, 1976). Indeed, replication is enhanced in the presence of activated CD4<sup>+</sup> T-cells and reduced in their absence (Eriksson *et al.*, 1999). Similarly, vaccination studies using inactivated whole virus as antigen or peptides from the *gag* precursor tend to increase virus replication and/or enhance lesion formation (McGuire *et al.*, 1986; Nenci *et al.*, 2007). It is possible that localized immune responses in the lungs caused lesion development without systemic humoral responses being elevated. A PCR investigation of DNA isolated from histological slides may help to determine the relationship between the presence of virus and lesion formation in these animals.

In summary, sheep can be infected via the conjunctival space and induce lesions in the lung, though seroconversion appears to be inefficient. The results suggest that ocular contact with infected respiratory fluid in the field may result in virus transmission.

## ACKNOWLEDGEMENTS

This work was funded by the University of Edinburgh and the EC, contract number: QLRT-2001-00617. The authors wish to thank Paul Wright for excellent care of the experimental animals used in the study.

## REFERENCES

- Adams, D. S., Klevjer-Anderson, P., Carlson, J. L., McGuire, T. C. & Gorham, J. R. (1983). Transmission and control of caprine arthritis-encephalitis virus. *Am J Vet Res* **44**, 1670–1675.
- Baba, M. A., Sinha, R. D. & Prasad, R. (1995). Comparative histological studies on the third eyelid of goat and sheep. *Indian Vet J* **72**, 1166–1169.



- Bell, J. A., Huebner, R. J., Paffenbarger, R. S., Jr, Rowe, W. P., Suskind, R. G. & Ward, J. G. (1956). Studies of adenoviruses (APC) in volunteers. *Am J Public Health* **46**, 1130–1146.
- Blacklaws, B. A., Berriatua, E., Torsteinsdóttir, S., Watt, N. J., de Andrés, D., Klein, D. & Harkiss, G. D. (2004). Transmission of small ruminant lentiviruses. *Vet Microbiol* **101**, 199–208.
- Brahic, M., Stowring, L., Ventura, P. & Haase, A. T. (1981). Gene expression in visna virus infection in sheep. *Nature* **292**, 240–242.
- Brellou, G. D., Angelopoulou, K., Poutahidis, T. & Vlemmas, I. (2007). Detection of maedi-visna virus in the liver and heart of naturally infected sheep. *J Comp Pathol* **136**, 27–35.
- Brodie, S. J., Pearson, L. D., Zink, M. C., Bickle, H. M., Anderson, B. C., Marcom, K. A. & DeMartini, J. C. (1995). Ovine lentivirus expression and disease. Virus replication, but not entry, is restricted to macrophages of specific tissues. *Am J Pathol* **146**, 250–263.
- Capucchio, M. T., Sanna, E., Sanna, M. P., Farigu, S., Minelli, R. & Guarda, F. (2003). Maedi-visna detection in ovine third eyelids. *J Comp Pathol* **129**, 37–43.
- Cheevers, W. P., Knowles, D. P., McGuire, T. C., Cunningham, D. R., Adams, D. S. & Gorham, J. R. (1988). Chronic disease in goats orally infected with two isolates of the caprine arthritis-encephalitis lentivirus. *Lab Invest* **58**, 510–517.
- Clerici, M., Berzofsky, J. A., Shearer, G. M. & Tacket, C. O. (1991). Exposure to human immunodeficiency virus (HIV) type I indicated by HIV-specific T helper cell responses before detection of infection by polymerase chain reaction and serum antibodies. *J Infect Dis* **164**, 178–182.
- Cutlip, R. C., Lehmkuhl, H. D., Brogden, K. A. & Bolin, S. R. (1985). Mastitis associated with ovine progressive pneumonia virus infection in sheep. *Am J Vet Res* **46**, 326–328.
- de Andrés, D., Klein, D., Watt, N. J., Berriatua, E., Torsteinsdóttir, S., Blacklaws, B. A. & Harkiss, G. D. (2005). Diagnostic tests for small ruminant lentiviruses. *Vet Microbiol* **107**, 49–62.
- De Boer, G. F., Terpstra, C. & Houwers, D. J. (1979). Studies in epidemiology of maedi/visna in sheep. *Res Vet Sci* **26**, 202–208.
- Ebrahimi, B., Allsopp, T. E., Fazakerley, J. K. & Harkiss, G. D. (2000). Phenotypic characterisation and infection of ovine microglial cells with Maedi-Visna virus. *J Neurovirol* **6**, 320–328.
- Eriksson, K., McInnes, E., Ryan, S., Tonks, P., McConnell, I. & Blacklaws, B. (1999). CD4<sup>+</sup> T-cells are required for the establishment of maedi-visna virus infection in macrophages but not dendritic cells *in vivo*. *Virology* **258**, 355–364.
- Gendelman, H. E., Narayan, O., Molineaux, S., Clements, J. E. & Ghotbi, Z. (1985). Slow, persistent replication of lentiviruses: role of tissue macrophages and macrophage precursors in bone marrow. *Proc Natl Acad Sci U S A* **82**, 7086–7090.
- Gendelman, H. E., Narayan, O., Kennedy-Stoskopf, S., Kennedy, P. G., Ghotbi, Z., Clements, J. E., Stanley, J. & Pezeshkpour, G. (1986). Tropism of sheep lentiviruses for monocytes: susceptibility to infection and virus gene expression increase during maturation of monocytes to macrophages. *J Virol* **58**, 67–74.
- Georgsson, G. & Palsson, P. A. (1971). The histopathology of maedi a slow, viral pneumonia of sheep. *Vet Pathol* **8**, 63–80.
- Gorrell, M. D., Brandon, M. R., Sheffer, D., Adams, R. J. & Narayan, O. (1992). Ovine lentivirus is macrophagetropic and does not replicate productively in T lymphocytes. *J Virol* **66**, 2679–2688.
- Haase, A. T. (1986). Pathogenesis of lentivirus infections. *Nature* **322**, 130–136.
- Haase, A. T., Stowring, L., Narayan, P., Griffin, D. & Price, D. (1977). Slow persistent infection caused by visna virus: role of host restriction. *Science* **195**, 175–177.
- Hopper, C. D., Sparkes, A. H., Gruffydd-Jones, T. J., Crispin, S. M., Muir, P., Harbour, D. A. & Stokes, C. R. (1989). Clinical and laboratory findings in cats infected with feline immunodeficiency virus. *Vet Rec* **125**, 341–346.
- Horsburgh, C. R., Jr, Ou, C. Y., Jason, J., Holmberg, S. D., Longini, I. M., Jr, Schable, C., Mayer, K. H., Lifson, A. R., Schochetman, G. & other authors (1989). Duration of human immunodeficiency virus infection before detection of antibody. *Lancet* **2**, 637–640.
- Houwers, D. J. & van der Molen, E. J. (1987). A five-year serological study of natural transmission of maedi-visna virus in a flock of sheep, completed with post mortem investigation. *Zentralbl Veterinarmed B* **34**, 421–431.
- Jaax, N. K., Davis, K. J., Geisbert, T. J., Vogel, P., Jaax, G. P., Topper, M. & Jahrling, P. B. (1996). Lethal experimental infection of rhesus monkeys with Ebola-Zaire (Mayinga) virus by the oral and conjunctival route of exposure. *Arch Pathol Lab Med* **120**, 140–155.
- Juste, R. A., Kwang, J. & de la Concha-Bermejillo, A. (1998). Dynamics of cell-associated viremia and antibody response during the early phase of lentivirus infection in sheep. *Am J Vet Res* **59**, 563–568.
- Kageyama, M., Nakatsuka, K., Yamaguchi, T., Owen, R. L. & Shimada, T. (2006). Ocular defense mechanisms with special reference to the demonstration and functional morphology of the conjunctiva-associated lymphoid tissue in Japanese monkeys. *Arch Histol Cytol* **69**, 311–322.
- Knop, N. & Knop, E. (2005). Ultrastructural anatomy of CALT follicles in the rabbit reveals characteristics of M-cells, germinal centres and high endothelial venules. *J Anat* **207**, 409–426.
- Larsen, H. J., Hyllseth, B. & Krogsrud, J. (1982a). Experimental maedi virus infection in sheep: early cellular and humoral immune response following parenteral inoculation. *Am J Vet Res* **43**, 379–383.
- Larsen, H. J., Hyllseth, B. & Krogsrud, J. (1982b). Experimental maedi virus infection in sheep: cellular and humoral immune response during three years following intranasal inoculation. *Am J Vet Res* **43**, 384–389.
- Lujan, L., Begara, I., Collie, D. & Watt, N. J. (1994). Ovine lentivirus (maedi-visna virus) protein expression in sheep alveolar macrophages. *Vet Pathol* **31**, 695–703.
- McGuire, T. C., Adams, D. S., Johnson, G. C., Klevjer-Anderson, P., Barbee, D. D. & Gorham, J. R. (1986). Acute arthritis in caprine arthritis-encephalitis virus challenge exposure of vaccinated or persistently infected goats. *Am J Vet Res* **47**, 537–540.
- McNeilly, T. N., Tennant, P., Lujan, L., Perez, M. & Harkiss, G. D. (2007). Differential infection efficiencies of peripheral lung and tracheal tissues in sheep infected with visna/maedi virus via the respiratory tract. *J Gen Virol* **88**, 670–679.
- Mordasini, F., Vogt, H-R., Zahno, M-L, Maeschli, A., Nenci, C., Zanoni, R., Peterhans, E. & Bertoni, G. (2006). Analysis of the antibody response to an immunodominant epitope of the envelope glycoprotein of a lentivirus and its diagnostic potential. *J Clin Microbiol* **44**, 981–991.
- Narayan, O. & Clements, J. E. (1989). Biology and pathogenesis of lentiviruses. *J Gen Virol* **70**, 1617–1639.
- Narayan, O., Wolinsky, J. S., Clements, J. E., Strandberg, J. D., Griffin, D. E. & Cork, L. C. (1982). Slow virus replication: the role of macrophages in the persistence and expression of visna viruses of sheep and goats. *J Gen Virol* **59**, 345–356.
- Narayan, O., Kennedy-Stoskopf, S., Sheffer, D., Griffin, D. E. & Clements, J. E. (1983). Activation of caprine arthritis-encephalitis virus expression during maturation of monocytes to macrophages. *Infect Immun* **41**, 67–73.

- Nathanson, N., Panitch, H., Pálsson, P. A., Petursson, G. & Georgsson, G. (1976). Pathogenesis of visna. II. Effect of immunosuppression upon early central nervous system lesions. *Lab Invest* **35**, 444–451.
- Nenci, C., Zahno, M. L., Vogt, H. R., Obexer-Ruff, G., Doherr, M. G., Zanoni, R., Peterhans, E. & Bertoni, G. (2007). Vaccination with a T-cell-priming Gag peptide of caprine arthritis encephalitis virus enhances virus replication transiently *in vivo*. *J Gen Virol* **88**, 1589–1593.
- Olofsson, S., Kumlin, U., Dimock, K. & Arnberg, N. (2005). Avian influenza and sialic acid receptors: more than meets the eye. *Lancet Infect Dis* **5**, 184–188.
- Orlando, J. S., Balliet, J. W., Kushnir, A. S., Astor, T. L., Kosz-Vnenchak, M., Rice, S. A., Knipe, D. M. & Schaffer, P. A. (2006). ICP22 is required for wild-type composition and infectivity of herpes simplex virus type 1 virions. *J Virol* **80**, 9381–9390.
- Pálsson, P. A. (1976). Maedi and visna in sheep. *Front Biol* **44**, 17–43.
- Pepin, M., Vitu, C., Russo, P., Mornex, J. F. & Peterhans, E. (1998). Maedi-visna virus infection in sheep: a review. *Vet Res* **29**, 341–367.
- Peterhans, E., Greenland, T., Badiola, J., Harkiss, G., Bertoni, G., Amorena, B., Eliaszewicz, M., Juste, R., Krassnig, R. & other authors (2004). Routes of transmission and consequences of small ruminant lentiviruses (SRLVs) infection and eradication schemes. *Vet Res* **35**, 257–274.
- Petursson, G., Nathanson, N., Georgsson, G., Panitch, H. & Pálsson, P. A. (1976). Pathogenesis of visna. I. Sequential virologic, serologic, and pathologic studies. *Lab Invest* **35**, 402–412.
- Rimstad, E., East, N. E., Torten, M., Higgins, J., DeRock, E. & Pedersen, N. C. (1993). Delayed seroconversion following naturally acquired caprine arthritis-encephalitis virus infection in goats. *Am J Vet Res* **54**, 1858–1862.
- Robert, P. Y., Adenis, J. P., Denis, F. & Ranger-Rogez, S. (2005). Transmission of viruses through corneal transplants. *Clin Lab* **51**, 419–423.
- Rozina, E. E., Khudaverdyan, O. E., Brudno, I. A., Dorofeev, V. M., Kropotova, N. S. & Shteinberg, L. S. (1988). Comparative clinico-morphological investigations of the CNS of monkeys and of the eye teguments of guinea pigs infected with different measles virus strains. *Acta Virol* **32**, 123–128.
- Ryan, S., Tiley, L., McConnell, I. & Blacklaws, B. (2000). Infection of dendritic cells by the maedi-visna lentivirus. *J Virol* **74**, 10096–10103.
- Saman, E., Van Eynde, G., Lujan, L., Extramiana, B., Harkiss, G., Tolari, F., González, L., Amorena, B., Watt, N. & Badiola, J. (1999). A new sensitive serological assay for detection of lentivirus infections in small ruminants. *Clin Diagn Lab Immunol* **6**, 734–740.
- Sargan, D. R., Bennet, I. D., Cousens, C., Roy, D. J., Blacklaws, B. A., Dalziel, R. G., Watt, N. J. & McConnell, I. (1991). Nucleotide sequence of EV1, a British isolate of maedi-visna virus. *J Gen Virol* **72**, 1893–1903.
- Small, J. A., Bieberich, C., Ghotbi, Z., Hess, J., Scangos, G. A. & Clements, J. E. (1989). The visna virus long terminal repeat directs expression of a reporter gene in activated macrophages, lymphocytes, and the central nervous systems of transgenic mice. *J Virol* **63**, 1891–1896.
- Staskus, K. A., Couch, L., Bitterman, P., Retzel, E. F., Zupancic, M., List, J. & Haase, A. T. (1991). *In situ* amplification of visna virus DNA in tissue sections reveals a reservoir of latently infected cells. *Microb Pathog* **11**, 67–76.
- Streilein, J. W. (1999). Immunoregulatory mechanisms of the eye. *Prog Retin Eye Res* **18**, 357–370.
- Torsteinsdóttir, S., Agnarsdóttir, G., Matthiasdóttir, S., Rafnar, B., Andrésdóttir, V., Andrésón, O. S., Staskus, K., Pétursson, G., Pálsson, P. A. & Georgsson, G. (1997). *In vivo* and *in vitro* infection with two different molecular clones of visna virus. *Virology* **229**, 370–380.
- Torsteinsdóttir, S., Matthiasdóttir, S., Vidarsdóttir, N., Svansson, V. & Petursson, G. (2003). Intratracheal inoculation as an efficient route of experimental infection with maedi-visna virus. *Res Vet Sci* **75**, 245–247.
- van der Molen, E. J. & Houwers, D. J. (1987). Indurative lymphocytic mastitis in sheep after experimental infection with maedivisna virus. *Vet Q* **9**, 193–202.
- Vigne, R., Barban, V., Querat, G., Mazarin, V., Gourdou, I. & Sauze, N. (1987). Transcription of visna virus during its lytic cycle: evidence for a sequential early and late gene expression. *Virology* **161**, 218–227.
- Villinger, F., Powell, J. D., Jehuda-Cohen, T., Neckelmann, N., Vuchetich, M., De, B., Folks, T. M., McClure, H. M. & Ansari, A. A. (1991). Detection of occult simian immunodeficiency virus SIVsmm infection in asymptomatic seronegative nonhuman primates and evidence for variation in SIV gag sequence between *in vivo*- and *in vitro*-propagated virus. *J Virol* **65**, 1855–1862.
- Zhang, M., Zhou, J., Marshall, B., Xin, H. & Atherton, S. S. (2007). Lack of iNOS facilitates MCMV spread in the retina. *Invest Ophthalmol Vis Sci* **48**, 285–292.
- Zink, M. C. & Narayan, O. (1989). Lentivirus-induced interferon inhibits maturation and proliferation of monocytes and restricts the replication of caprine arthritis-encephalitis virus. *J Virol* **63**, 2578–2584.