



THE UNIVERSITY *of* EDINBURGH

Edinburgh Research Explorer

Giant haemangioma of the liver

Citation for published version:

Duxbury, MS & Garden, OJ 2010, 'Giant haemangioma of the liver: observation or resection?' Digestive surgery, vol. 27, no. 1, pp. 7-11. DOI: 10.1159/000268108

Digital Object Identifier (DOI):

[10.1159/000268108](https://doi.org/10.1159/000268108)

Link:

[Link to publication record in Edinburgh Research Explorer](#)

Document Version:

Early version, also known as pre-print

Published In:

Digestive surgery

General rights

Copyright for the publications made accessible via the Edinburgh Research Explorer is retained by the author(s) and / or other copyright owners and it is a condition of accessing these publications that users recognise and abide by the legal requirements associated with these rights.

Take down policy

The University of Edinburgh has made every reasonable effort to ensure that Edinburgh Research Explorer content complies with UK legislation. If you believe that the public display of this file breaches copyright please contact openaccess@ed.ac.uk providing details, and we will remove access to the work immediately and investigate your claim.



Giant Haemangioma of the Liver: Observation or Resection?

Mark S. Duxbury O. James Garden

Clinical and Surgical Sciences (Surgery), University of Edinburgh, Royal Infirmary, Edinburgh, UK

Key Words

Cavernous haemangioma · Giant haemangioma, liver · Giant haemangiomas, management · Kasabach-Merritt syndrome · Liver function tests · Liver haemangiomas

Abstract

Background: Haemangiomas are the most frequent benign solid liver lesion. The management of giant (≥ 5 cm) haemangiomas of the liver remains controversial. **Methods:** A search of relevant peer-reviewed literature was conducted using PubMed and original articles were reviewed. **Results and Conclusions:** The vast majority of giant haemangiomas remain asymptomatic and have a benign and uncomplicated natural history. Decisions regarding the optimal management of giant haemangiomas depend on a high level of confidence in diagnostic imaging. Diagnostic biopsy to differentiate giant haemangiomas from malignant lesions should be discouraged. Despite limitations and alternative modalities, surgery remains the only consistently effective curative treatment for giant haemangiomas. Surgery is not generally justified to prevent complications in asymptomatic patients. Principal indications for the surgical management of giant haemangiomas include established complications, incapacitating symptoms and uncertainty of diagnosis. Patients should only be selected for surgery based on a careful assessment of risks and benefits of intervention.

Copyright © 2010 S. Karger AG, Basel

Key Points

1. Cavernous haemangiomas are the most common benign solid tumour of the liver.
2. Giant haemangiomas are defined as those measuring ≥ 5 cm in diameter.
3. The natural history of liver haemangiomas is generally uncomplicated.
4. Liver function tests are usually normal.
5. The successful management of giant haemangiomas depends on establishing the diagnosis, determining the requirement for surgical intervention and, where necessary, defining the optimal type of surgery.
6. Patients must be counselled that surgery may not alleviate their symptoms.
7. Surgery should only be considered for patients with complicated or symptomatic lesions, or where the diagnosis remains uncertain despite appropriate specialist investigation.

Introduction

Liver haemangiomas are a common incidental finding, reflecting a high prevalence within the population. With increasing application and resolution of abdominal imaging modalities, haemangiomas are detected more frequently. Originating from the mesodermal layer, these lesions represent a congenital, non-neoplastic hamartomatous proliferation of vascular endothelial cells [1]. Current evidence indicates that haemangiomas have no malignant

potential. Macroscopically, haemangiomas are well-circumscribed, hypervascular and compressible lesions with a clear sheath of compressed liver parenchyma between haemangiomatous tissue and normal liver [2]. Microscopically, haemangiomas typically consist of ectatic blood-filled spaces, lined with vascular endothelium and separated by fibrous septa with a variable sclerotic component.

Approximately 80% of haemangiomas are of the cavernous type. Unlike the less common capillary type, which are generally smaller in size, more frequently multiple and do not generally cause symptoms, cavernous haemangiomas can grow to reach large sizes and may become symptomatic. Giant haemangiomas are defined as those measuring ≥ 5 cm in diameter [3].

The first resection of a liver haemangioma was reported by Hermann Pfannenstiel in 1898. Today, surgery is the most effective therapeutic modality for the definitive treatment of liver haemangiomas [4]. However, the optimal approach for the management of patients with giant haemangiomas remains controversial.

Cavernous Haemangioma: Presentation and Natural History

Cavernous haemangiomas are the most common benign solid tumour of the liver [5] and have been reported in up to 7.3% of autopsy studies [6]. These lesions are more usually found in women (female:male ratio = 5:1), with a mean age at diagnosis of 50 years, most lesions being detected between the 3rd and 5th decades. Prevalence is greatest in women with higher parity [7, 8]. Although there is no proven association with oral contraceptive use, this relationship remains controversial. Cavernous haemangiomas occur more frequently within the right liver and multiple lesions occur in 10% of cases [6]. Similar haemangiomatous lesions may occur in other organs [9].

The majority of evidence indicates that the natural history of liver haemangiomas is uncomplicated [10–13] and most lesions are asymptomatic. Symptoms associated with haemangiomas should be interpreted cautiously. In a series of 87 patients with liver haemangioma, Farges et al. [10] reported that 54% of these patients had other identifiable causes for their abdominal symptoms. While lesions < 10 cm in diameter seldom cause symptoms, patients with larger lesions may present with abdominal pain, due to stretching of Glisson's capsule, compression of local structures, intralesional thrombosis and infarction or, less commonly, haemorrhage. The risk of clinically relevant haemorrhage appears to be less than 1% [14]. Haemangiomas

tend to remain stable in size. Weimann et al. [15] reported size increases in 11 (10.6%) of 104 patients with liver haemangiomas. Jaundice is unusual and, despite reaching large dimensions, spontaneous rupture of a giant haemangioma is exceptional. While fewer than 50 cases of spontaneous rupture have been reported [10], the mortality rate can be appreciable, up to 60% in one series [16]. Traumatic rupture is a recognised but rare complication with a handful of cases described in the literature [17].

Liver function tests (LFT) are generally normal in the presence of giant haemangioma, although LFT abnormalities have been reported as a consequence of biliary compression by the mass [18]. Patients with a giant haemangioma may exhibit inflammatory features, and Bornman et al. [19] described a clinical triad in 4 patients, consisting of signs suggestive of an acute inflammatory process within the liver, normal white cell count and normal LFT. Haematological markers of inflammation, e.g. raised erythrocyte sedimentation rate, thrombocytosis and hyperfibrinogenaemia, may be detected in association with giant haemangioma and can be reversed by resection [20]. However, in a further small group of patients with giant haemangioma exhibiting inflammatory features, none displayed a leucocytosis [18]. Clinical features of polymyalgia rheumatica have also been described in association with a giant cavernous haemangioma. These features also resolved following resection of the lesion [21].

Kasabach-Merritt syndrome [22] is characterised by thrombocytopenia and consumptive coagulopathy in association with large haemangiomas (fig. 1), and may prompt intervention. Platelet trapping in the haemangioma is thought to result in activation of platelets and the clotting cascade, resulting in a consumptive coagulopathy [22]. The mortality rate of Kasabach-Merritt syndrome approaches 30% [23].

Reported Experience

In a series of 163 hepatic haemangiomas, reported by Farges et al. [10], with a mean follow-up of 92 months, only 9 haemangiomas increased in size and 7 decreased. Complications included 2 cases of Kasabach-Merritt syndrome, 1 intrahepatic bleed, and 2 cases of Budd-Chiari syndrome. 16 patients underwent intervention including 8 resections, 5 arterial embolisations, 2 transjugular intrahepatic portosystemic shunts, 1 right hepatic artery ligation, and 1 liver transplantation. Liver transplantation has been used by a number of groups for unresectable disease, and for Kasabach-Merritt syndrome [24]. Groups

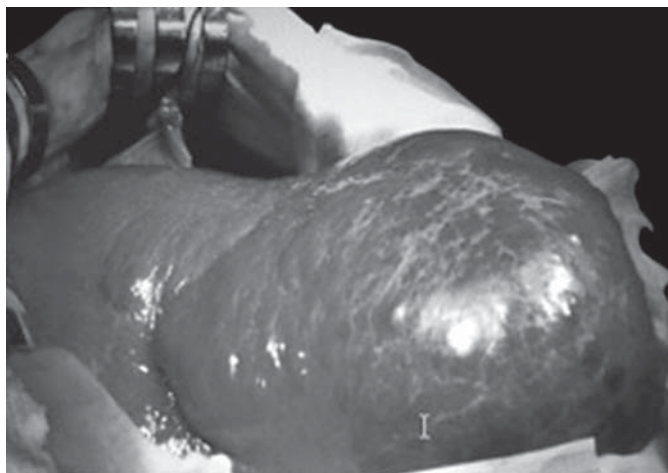


Fig. 1. Giant haemangioma of the right lobe which was associated with thrombocytopenia and consumptive coagulopathy: Kasabach-Merritt syndrome.

have also reported extracorporeal resection for 'unresectable' giant haemangiomas [25]. Non-operative adjunctive measures such as transarterial bland embolisation or chemoembolisation have been reported as a 'bridge to surgery' [26], as well as a unimodality treatment.

In a series of 115 patients, recognised as being selected surgical referrals, Yoon et al. [27] reported 6 episodes of thrombosis and 3 cases of infarctions or necrosis, but no cases of rupture. The authors concluded that complications were uncommon and that indications for resection should include severe symptoms, inability to exclude malignancy and complications. These authors advocated enucleation, first described by Alper et al. [28] in 1988, with good long-term outcomes [29].

Lerner et al. [4] reported outcomes from a case series of 52 resections for giant cavernous haemangioma. This group has moved towards a policy of enucleation rather than resection over time. The perceived benefits of enucleation over resection include reduced intraoperative blood loss, reduced bile leak rates [30] as well as maximising preservation of functional hepatic parenchyma.

In a series from the Memorial Sloan-Kettering Center, 35% of resections were performed in asymptomatic patients. Haemangiomas >10 cm were overrepresented in the resected group (58%), the median size in this group being 11 versus 4 cm in the unresected group. In this series, enucleation was performed in 14% of cases where malignancy was suspected. Enucleation of potentially malignant lesions is difficult to justify and data regarding the long-term outcome of this approach are not available.

Management

The successful management of giant haemangiomas depends on: (1) confirming the diagnosis; (2) determining whether the lesion requires surgical treatment; (3) determining the optimal type of surgery, and (4) avoiding unnecessary surgical intervention. A detailed history should be obtained, addressing relevant risk factors. Symptoms unrelated to an incidentally detected haemangioma should be clarified and alternative cases, e.g. cholelithiasis, liver disease, excluded. Liver biochemistry is usually normal, although abnormalities may indicate haemorrhage, infarction, neoplasia or be associated with a non-haemangiomatic aetiology.

Management: The Case for Observation

In the face of a large body of evidence indicating a benign and uncomplicated natural history for the majority of haemangiomas, including giant haemangiomas, a policy of non-operative management will be the optimal approach for the majority of patients. While morbidity and mortality rates associated with liver resection and enucleation in specialist centres are low, adverse events do occur. The risk of potential complication must be carefully weighed against operative risk. Surgery should therefore be reserved for cases of absolute necessity.

The decision to manage giant haemangiomas expectantly depends largely on the certainty of diagnosis, which in turn is reliant on the quality of non-invasive imaging and its interpretation. Transabdominal ultrasound is diagnostic in approximately two thirds of cases [31]. However, axial imaging will usually also be undertaken. Haemangiomas tend to be hypodense on non-contrast computerised tomography and show peripheral followed by central enhancement. Isoenhancement with the arteries is typical. Delayed scans show persisting contrast enhancement and features such as corkscrewing and 'cotton wool' appearance reflect the abnormal vessels within the lesion. Globular enhancement, isodense with the aorta, has been shown to be 67% sensitive and 100% specific in differentiating haemangiomas from metastases [32].

Magnetic resonance imaging (MRI) may be of value in establishing the diagnosis. Typical features include high signal intensity on T₂-weighted series and discontinuous nodular peripheral enhancement (fig. 2). In some cases, MRI features can be correlated with histological ones, e.g. presence of hypocellular myxoid tissue [33].

Applying a combination of axial imaging modalities will generally allow the diagnosis of haemangioma

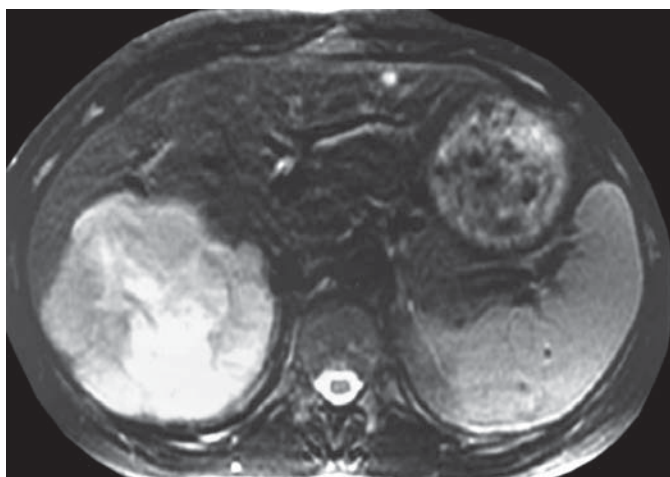


Fig. 2. T₂-weighted MRI of giant haemangioma replacing much of right posterior sector.

to be made with an adequate degree of certainty to justify a plan of expectant management. The static nature of giant haemangiomas means that once the diagnosis is established, further follow-up may be unnecessary [34].

Management: The Case for Operative Management

Established Complications. In the minority of cases that present as a surgical emergency due to haemorrhage, rupture, thrombosis and infarction, surgical management may be the only appropriate course of action. There is also a role for the elective surgical management of giant haemangiomas, albeit in a highly selected group of patients. As demonstrated by the data presented above, an operative approach with the objective of preventing future complications of giant haemangiomas is less easy to justify.

Diagnostic Uncertainty. Despite improvements in non-invasive imaging technology, cases of diagnostic uncertainty continue to pose a challenge. In situations where it is not possible to exclude malignancy, surgical intervention by formal liver resection may be indicated. In almost all situations, the use of percutaneous liver biopsy for the differentiation of giant haemangiomas from malignant liver lesions cannot be justified. The risks of haemorrhage as a result of biopsying a giant haemangioma are appreciable and, together with the risks of needle track seeding and intra-abdominal dissemination of a potentially curable malignancy, mean that biopsy in this setting must be avoided.

Incapacitating Symptoms. Having taken all possible steps to ensure that symptoms are attributable to the haemangioma, surgical resection may be justified on grounds of intractable symptoms. Patients with clearly defined abdominal compressive symptoms may be more likely to derive benefit from surgery than patients with non-specific abdominal discomfort, although this is not backed up by a meaningful body of evidence. Management of this group of patients is, by necessity, highly individualised. Despite apparently satisfactory surgical management, symptoms persist in approximately 25% of patients following resection of seemingly symptomatic haemangiomas.

Conclusions

Decision-making with regard to the optimal management of giant haemangiomas depends on a high level of confidence in diagnostic imaging. Diagnostic biopsy to differentiate giant haemangiomas from malignant lesions should in general be discouraged. The risks of potential complications and the severity of symptoms need to be carefully weighed against surgical risk. Patients must be counselled that surgery may not alleviate their symptoms and an individualised approach is essential. Despite limitations and alternative modalities, surgery remains the only consistently effective curative treatment for giant haemangiomas and should be considered for patients with complicated or symptomatic lesions, where operative risk is acceptable, or where the diagnosis remains uncertain despite appropriate specialist investigation. The choice of enucleation versus formal resection depends upon factors including the certainty of diagnosis and anatomical considerations such as the location and extent of the lesion. Formal resection may be preferable for potentially malignant lesions, and for lesions that totally replace an anatomical section of the liver. However, enucleation offers the benefit of potentially lower operative morbidity.

The advent of minimally invasive resectional liver surgery offers the possibility for the further reduction of perioperative morbidity and mortality. While this development should not substantially lower the threshold for selecting haemangioma patients for surgery, if individual surgeons can demonstrate more favourable outcomes for those treated laparoscopically than by open surgery, this approach may alter the balance of risk and benefit in favour of surgical management of giant haemangiomas in a small proportion of symptomatic patients.

References

- Nichols FC III, van Heerden JA, Weiland LH: Benign liver tumors. *Surg Clin North Am* 1989;69:297-314.
- Baer HU, Dennison AR, Mouton W, Stain SC, Zimmermann A, Blumgart LH: Enucleation of giant hemangiomas of the liver. Technical and pathologic aspects of a neglected procedure. *Ann Surg* 1992;216:673-676.
- Adam YG, Huvos AG, Fortner JG: Giant hemangiomas of the liver. *Ann Surg* 1970;172:239-245.
- Lerner SM, Hiatt JR, Salamandra J, Chen PW, Farmer DG, Ghobrial RM, et al: Giant cavernous liver hemangiomas: effect of operative approach on outcome. *Arch Surg* 2004;139:818-821.
- Ochsner JL, Halpert B: Cavernous hemangioma of the liver. *Surgery* 1958;43:577-582.
- Ishak KG, Rabin L: Benign tumors of the liver. *Med Clin North Am* 1975;59:995-1013.
- Sewell JH, Weiss K: Spontaneous rupture of hemangioma of the liver. A review of the literature and presentation of illustrative case. *Arch Surg* 1961;83:729-733.
- Schwartz SI, Husser WC: Cavernous hemangioma of the liver. A single institution report of 16 resections. *Ann Surg* 1987;205:456-465.
- Erdogan B, Sen O, Aydin VM, Yildirim T, Bircan S, Altinors N: Multi-organ cavernous hemangiomas: case report. *Neurol Res* 2003;25:92-94.
- Farges O, Daradkeh S, Bismuth H: Cavernous hemangiomas of the liver: are there any indications for resection? *World J Surg* 1995;19:19-24.
- Okano H, Shiraki K, Inoue H, Ito T, Yamataka T, Deguchi M, et al: Natural course of cavernous hepatic hemangioma. *Oncol Rep* 2001;8:411-414.
- Pietrabissa A, Giulianotti P, Campatelli A, Di Candio G, Farina F, Signori S, et al: Management and follow-up of 78 giant haemangiomas of the liver. *Br J Surg* 1996;83:915-918.
- Tait N, Richardson AJ, Muguti G, Little JM: Hepatic cavernous haemangioma: a 10-year review. *Aust NZ J Surg* 1992;62:521-524.
- Gilon D, Slater PE, Benbassat J: Can decision analysis help in the management of giant hemangioma of the liver? *J Clin Gastroenterol* 1991;13:255-258.
- Weimann A, Ringe B, Klempnauer J, Lamesch P, Gratz KF, Prokop M, et al: Benign liver tumors: differential diagnosis and indications for surgery. *World J Surg* 1997;21:983-990.
- Cappellani A, Zanghi A, Di Vita M, Zanghi G, Tomarchio G, Petrillo G: Spontaneous rupture of a giant hemangioma of the liver. *Ann Ital Chir* 2000;71:379-383.
- Hotokezaka M, Kojima M, Nakamura K, Hidaka H, Nakano Y, Tsuneyoshi M, et al: Traumatic rupture of hepatic hemangioma. *J Clin Gastroenterol* 1996;23:69-71.
- Pol B, Disdier P, Le Treut YP, Campan P, Hardwigen J, Weiller PJ: Inflammatory process complicating giant hemangioma of the liver: report of three cases. *Liver Transpl Surg* 1998;4:204-207.
- Bornman PC, Terblanche J, Blumgart RL, Jones EP, Pickard H, Kalvaria I: Giant hepatic hemangiomas: diagnostic and therapeutic dilemmas. *Surgery* 1987;101:445-449.
- Pateron D, Babany G, Belghiti J, Hadengue A, Menu Y, Flejou JF, et al: Giant hemangioma of the liver with pain, fever, and abnormal liver tests. Report of two cases. *Dig Dis Sci* 1991;36:524-527.
- Kadry Z, Mentha G, Cereda JM: Polymyalgia rheumatica as a manifestation of a large hepatic cavernous hemangioma. *J Hepatol* 2000;32:358-360.
- Hall GW: Kasabach-Merritt syndrome: pathogenesis and management. *Br J Haematol* 2001;112:851-862.
- El Dessouky M, Azmy AF, Raine PA, Young DG: Kasabach-Merritt syndrome. *J Pediatr Surg* 1988;23:109-111.
- Longeville JH, de la Hall P, Dolan P, Holt AW, Lillie PE, Williams JA, et al: Treatment of a giant haemangioma of the liver with Kasabach-Merritt syndrome by orthotopic liver transplant a case report. *HPB Surg* 1997;10:159-162.
- Ikegami T, Soejima Y, Taketomi A, Kaya-shima H, Sanefuji K, Yoshizumi T, et al: Extracorporeal hepatic resection for unresectable giant hepatic hemangiomas. *Liver Transpl* 2008;14:115-117.
- Seo HI, Jo HJ, Sim MS, Kim S: Right trisegmentectomy with thoracoabdominal approach after transarterial embolization for giant hepatic hemangioma. *World J Gastroenterol* 2009;15:3437-3439.
- Yoon SS, Charny CK, Fong Y, Jarnagin WR, Schwartz LH, Blumgart LH, et al: Diagnosis, management, and outcomes of 115 patients with hepatic hemangioma. *J Am Coll Surg* 2003;197:392-402.
- Alper A, Ariogul O, Emre A, Uras A, Okten A: Treatment of liver hemangiomas by enucleation. *Arch Surg* 1988;123:660-661.
- Ozden I, Emre A, Alper A, Tunaci M, Acarli K, Bilge O, et al: Long-term results of surgery for liver hemangiomas. *Arch Surg* 2000;135:978-981.
- Kuo PC, Lewis WD, Jenkins RL: Treatment of giant hemangiomas of the liver by enucleation. *J Am Coll Surg* 1994;178:49-53.
- Erdogan D, Busch OR, van Delden OM, Ben-nink RJ, ten Kate FJ, Gouma DJ, et al: Management of liver hemangiomas according to size and symptoms. *J Gastroenterol Hepatol* 2007;22:1953-1958.
- Leslie DF, Johnson CD, Johnson CM, Ilstrup DM, Harmsen WS: Distinction between cavernous hemangiomas of the liver and hepatic metastases on CT: value of contrast enhancement patterns. *AJR Am J Roentgenol* 1995;164:625-629.
- Danet IM, Semelka RC, Braga L, Armao D, Woosley JT: Giant hemangioma of the liver: MR imaging characteristics in 24 patients. *Magn Reson Imaging* 2003;21:95-101.
- Ng WW, Cheung YS, Lee KF, Wong J, Yu SC, Lee PS, et al: Is regular follow-up scan for giant liver haemangioma necessary? *Hong Kong Med J* 2007;13:353-358.