



THE UNIVERSITY *of* EDINBURGH

Edinburgh Research Explorer

Pyrexia of undetermined origin in the era of HAART

Citation for published version:

Whitely, W, Tariq, A, Peters, B, Kocjan, G, Miller, RF & Whiteley, W 2000, 'Pyrexia of undetermined origin in the era of HAART' *Sexually transmitted infections*, vol. 76, no. 6, pp. 484-8. DOI: 10.1136/sti.76.6.484

Digital Object Identifier (DOI):

[10.1136/sti.76.6.484](https://doi.org/10.1136/sti.76.6.484)

Link:

[Link to publication record in Edinburgh Research Explorer](#)

Document Version:

Early version, also known as pre-print

Published In:

Sexually transmitted infections

Publisher Rights Statement:

BMJ, available via europepmc open access

General rights

Copyright for the publications made accessible via the Edinburgh Research Explorer is retained by the author(s) and / or other copyright owners and it is a condition of accessing these publications that users recognise and abide by the legal requirements associated with these rights.

Take down policy

The University of Edinburgh has made every reasonable effort to ensure that Edinburgh Research Explorer content complies with UK legislation. If you believe that the public display of this file breaches copyright please contact openaccess@ed.ac.uk providing details, and we will remove access to the work immediately and investigate your claim.



Clinico-
pathological
conference

Pyrexia of undetermined origin in the era of HAART

W Whitely, A Tariq, B Peters, G Kocjan, R F Miller

Case presentation (Dr W Whitely, Dr R F Miller)

A 30 year old white homosexual male presented to the outpatient clinic and was admitted to hospital in early March 2000. He reported an 8 week history of dry cough, 6 weeks of diarrhoea with occasional vomiting, increasing anorexia and malaise associated with weight loss of 8 kg, and night sweats. Ten days before admission he had noted fever and mild bifrontal headaches and for 4 days both he and his partner observed a change in his personality. The patient's symptoms had persisted despite empirical ciprofloxacin prescribed by his primary care physician.

In the past the patient had had hepatitis A in 1990 and was first found to be HIV-1 antibody positive in April 1999, at which time the CD4+ T lymphocyte count was 220 cells $\times 10^9/l$ and HIV viral load was 421 400 copies/ml (Chiron quantiplex b DNA assay v 3.0). An STD screen was negative and he was hepatitis B immune. At the time of diagnosis of HIV infection he had declined HAART as he was asymptomatic but had started co-trimoxazole as primary prophylaxis against *Pneumocystis carinii* pneumonia. He was subsequently monitored in the outpatient clinic on a regular basis. In late 1999 his CD4+ T lymphocyte count began to fall. By early February 2000 it was 70 cells $\times 10^9/l$ and the HIV viral load was 308 900 copies/ml. The patient began zidovudine 250 mg twice daily, lamivudine 150 mg twice daily, and efavirenz 600 mg at night, 10 days before admission to hospital.

The patient worked in the media, was a non-smoker, and drank alcohol occasionally. He had travelled widely within Europe. Systematic review was non-contributory. Examination on admission showed the patient to be unwell, his temperature varied between 38.2°C and 40°C over the first few hours. The mucosae were pale and oral candida was present. There was a single shotty left supraclavicular lymph node, 0.5 cm in diameter, and multiple similar sized glands in both inguinal regions. The pulse was 110 and regular, blood pressure 115/60, and there was no postural drop. Auscultation of the heart revealed no murmurs. Examination of the chest was normal and the SO_2 was 98% (while breathing room air). In the abdomen there was 4 cm firm hepatomegaly and the spleen was just tipped. Examination of the central nervous system revealed no focal signs. The patient was fully oriented but had slow mentation. At fundoscopy no papilloedema was present but a single hard exudate was noted in the periphery of the right eye; the skin was normal.

Discussion (Dr B Peters)

My initial thoughts about this case are as follows. I think it is important to remember the travel history in any patient, whether immunosuppressed or not, who presents with fever. I get the impression there has been a subacute presentation with a rather more acute deterioration latterly. It is always worth remembering non-HIV associated diseases may also present in this way in an HIV infected patient—for example, infective endocarditis. I am already wondering about the possibility of a disseminated infection—the travel history, together with the symptoms and the presence of hepatosplenomegaly, are quite in favour of some disseminated process. At the back of my mind I am considering leishmaniasis or a fungal infection. I am a little bit concerned to hear that there was a change in personality and wondered if possibly this was related to commencing the efavirenz? Finally, I think it is important to flag up that by the background of several weeks of developing symptoms HAART was commenced only 10 days before admission. At this stage I am not considering an immune reconstitution phenomenon as being high on my list as the time course appears rather short.

Case presentation (Dr Whitely, Dr Miller)

On admission investigations showed haemoglobin 7.4 g/dl and mean cell volume 74. The serum ferritin was markedly raised at 2796 $\mu g/l$ (normal 16–323 $\mu g/l$ and the serum iron was low at 4.4 $\mu mol/l$ (normal 9–30 $\mu mol/l$); the TIBC was normal. The reticulocyte count was 1.2%, serum B_{12} and red cell folate were normal. A peripheral blood film showed anisocytosis, poikilocytosis, and occasional burr cells. The erythrocyte sedimentation rate was 24 mm in the first hour. The total white blood count was 6.2 (neutrophils 5.6) $\times 10^9/l$ and platelets 183 $\times 10^9/l$. A clotting screen was normal. There was evidence of previous but not current parvovirus infection—IgG was positive and IgM was negative; parvovirus DNA was not detected using dot/blot analysis. The urea and electrolytes were normal apart from the serum sodium which was 124 mmol/l (normal 137–145 mmol/l). Liver function tests were normal. The C reactive protein (CRP) was 148 mg/ml (normal 0–12 mg/ml). The serum osmolality was low, 266 mmol/kg water (normal 280–300 mmol/kg water). Urine analysis showed protein+, and was otherwise normal; the urine osmolality was normal. Urine microscopy was negative, as was culture for bacteria. Three early morning urines were obtained and set up for mycobacterial culture. Three stool

Department of Sexually Transmitted Diseases, Windeyer Institute of Medical Sciences, Royal Free and University College Medical School, University College London and Mortimer Market Centre, Camden and Islington Community Health Services NHS Trust, London WC1E 6AU, UK

W Whitely
R F Miller

Academic Department of Genitourinary Medicine, Guys, King's and St Thomas's Medical School, St Thomas's Hospital, London SE1 7EH, UK
B Peters

Department of Histopathology, University College London Hospitals NHS Trust, London WC1E 6AU, UK
G Kocjan

Department of Genitourinary Medicine, Whittall Street Clinic, Birmingham, B4 6DH, UK
A Tariq

Correspondence to:
Dr R F Miller
rmiller@gum.ucl.ac.uk

Accepted for publication
12 October 2000

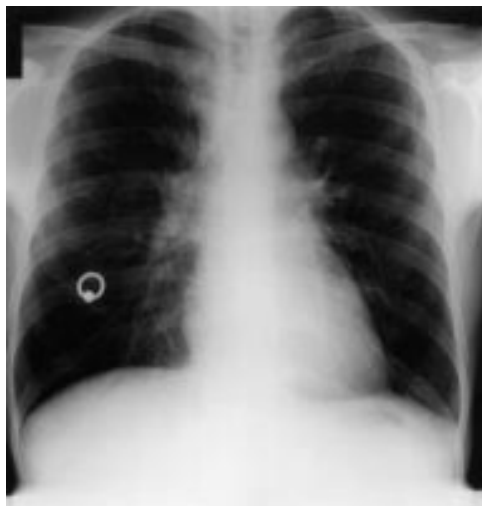

Figure 1 Chest radiograph on admission showing bilateral hilar and right paratracheal lymphadenopathy with diffuse reticular infiltrates and mild focal infiltrates at the left costophrenic angle and within the right mid-zone

samples were negative for bacterial pathogens, including *Clostridium difficile*, *Salmonella* spp, *Shigella* spp, *Campylobacter* spp and *Escherichia coli*. Three "hot" stools for ova, cysts, and parasites revealed no cryptosporidia or microsporidia. Three stool samples for faecal occult bloods were negative. A chest radiograph was abnormal (fig 1) showing bilateral hilar and right paratracheal lymphadenopathy with diffuse reticular infiltrates and mild focal infiltrates at the left costophrenic angle and within the right mid-zone. A sputum sample was negative on Gram and auramine staining and was sent for culture for bacteria, mycobacteria, and fungi. An ultrasound scan of the abdomen confirmed hepatosplenomegaly but showed no ascites or intra-abdominal lymphadenopathy. Admission blood cultures were reported as negative. Blood serology, including toxoplasma latex and syphilis TPHA and RPR were negative. Hepatitis A IgG was positive, IgM was negative; hepatitis B serology showed anti-HB core positivity, HBs Ag negative and anti-HB surface positive. Hepatitis C antibody was negative as was hepatitis C RNA. An investigation was performed which was diagnostic.

Discussion (Dr Peters)

I am still concerned about the possibility of a disseminated infection. The chest radiographic appearances, although very abnormal are not at all specific and could be due to infection caused by bacteria, mycobacteria, fungi, including *P carinii*, or protozoa such as toxoplasmosis. The anaemia and the hepatosplenomegaly worry me. The hyponatraemia is also an important finding and together with the low serum osmolality and the normal urine osmolality, make me wonder about the syndrome of inappropriate ADH secretion. I would be keen to see the result of a serum cryptococcal latex agglutination (CRAG) test, and if this was positive then I would want to see the results of a lumbar puncture, despite the absence of focal neurology, after a computed tomographic (CT) or magnetic resonance imaging scan of

the head had been carried out. Another important investigation to consider, in view of the microcytic anaemia and absence of a source of blood loss, is a bone marrow aspirate and trephine.

Case presentation (Dr Whitely, Dr Miller)

The investigation that proved diagnostic was the serum CRAG which was positive at a dilution of 1 in 128. Further investigations included a CT scan of the head with contrast which was normal. At lumbar puncture clear colourless cerebrospinal fluid (CSF) was obtained with an opening pressure of 13 cm H₂O. Analysis gave a CSF glucose of 2.5 mmol/l (simultaneous blood glucose 7.0 mmol/l). The CSF protein was 1.2 g/l, and WBC 2/mm³. An Indian ink stain was negative and cytology revealed no cells. Culture of the CSF was negative for bacteria; ongoing culture was set up for both fungi and mycobacteria. CSF serology showed a negative toxoplasma latex and negative syphilis TPHA/RPR; however, the CSF CRAG was positive with a dilution of 1 in 2000. The polymerase chain reaction on cell-free CSF was negative for herpes simplex virus 1 and 2, Epstein-Barr virus, cytomegalovirus, varicella zoster virus, and JC virus. A bone marrow aspirate and trephine showed a normocellular marrow with dysplastic megakaryocytes. The myeloid series showed a left shift and these findings were interpreted as showing a reactive marrow consistent with HIV associated changes. Routine staining for bacteria, mycobacteria, and fungi was negative. A sample of bone marrow aspirate was cultured for these pathogens. Two days after admission a repeat CD4+ T lymphocyte count was 190 cells ×10⁹/l and repeat HIV viral load was 500 copies/ml.

The patient was thought to have disseminated cryptococcosis together with poor prognostic signs, including poor mentation and hyponatraemia. The HAART was continued and he was treated with intravenous amphotericin B and also transfused with whole blood. An upper gastrointestinal endoscopy was performed in order to investigate further the cause of his iron deficiency anaemia. This revealed only candida in the oesophagus and stomach. Biopsies of the duodenum were normal.

After 1 week in hospital the patient remained pyrexial and had persistent headache which was attributed to the lumbar puncture. However, his mentation had improved. At this point *Streptococcus pneumoniae* was cultured from blood. This was treated initially with intravenous benzyl penicillin and subsequently oral amoxicillin. Over the next week there was a marked clinical improvement with a reduction in fever being associated with a reduction in CRP levels. The serum CRAG remained positive. The patient received a total of 2 weeks of amphotericin B and then treatment was changed to oral fluconazole 600 mg once daily. At this time the patient reported an increase in size and tenderness of the lymph node in the left cervical chain. Over a period of 4 days the lymph node enlarged to a size of 10 × 12 cm and was exquisitely painful. This was accompa-

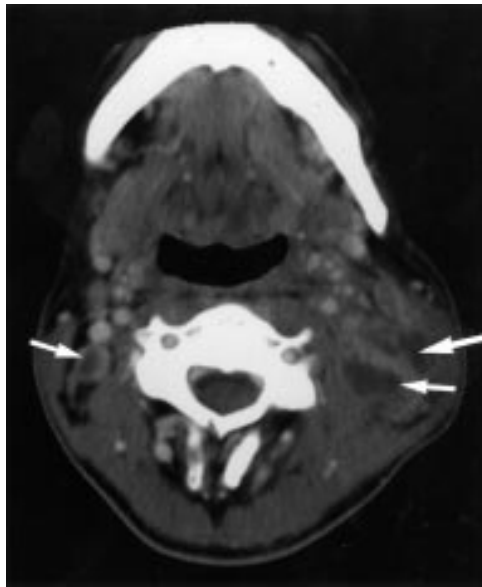


Figure 2 CT scan of the neck showing multiple, up to 2 cm diameter, highly vascular nodes, with low attenuation centres (arrows), on both sides of the neck, more markedly on the left than the right.

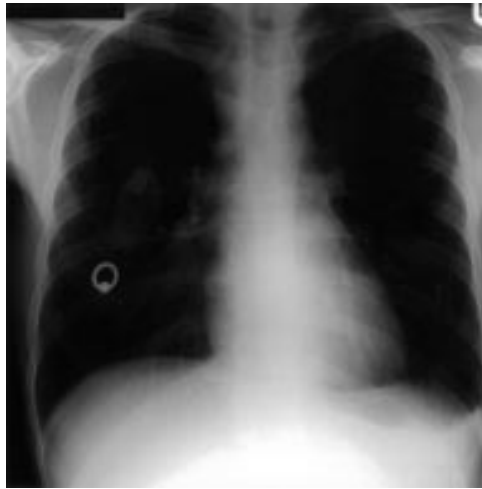

Figure 3 Chest radiograph on day 19 of admission. The lung fields have cleared but there is persistent lymphadenopathy.

nied by a recrudescence in fever. Repeat cultures of urine, stool, and blood were negative. An ultrasound of the neck revealed multiple homogeneous lymph nodes. A CT scan of the neck revealed multiple highly vascular lymph nodes (fig 2) and a repeat chest radiograph showed normal lung fields but persistent lymphadenopathy (fig 3). Four days after the onset of increasing cervical lymphadenopathy a fine needle aspirate (FNA) was performed. This was initially reported as showing only red blood cells, polymorphs, neutrophils, and necrotic debris.

Discussion (Dr Peters)

I wonder what further analysis of the lymph node FNA showed? I am particularly keen to know what the special stains showed? Were any infections identified? If the lymph node FNA was really non-diagnostic it might have been necessary to proceed to a surgical excision

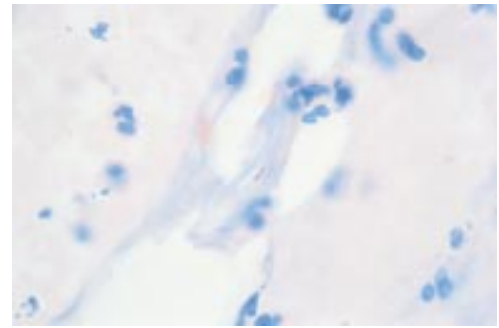


Figure 4 Fine needle aspirate from lymph node. Ziehl-Neelsen stain showing epithelioid cells. In the centre are two acid and alcohol fast bacilli. Magnification $\times 600$ (oil immersion).

biopsy.¹ Given the initial response to amphotericin B documented both clinically and by reductions in CRP, I think it is unlikely that the lymphadenopathy is due to cryptococcus. Rapidly enlarging lymph nodes in the HIV infected immunosuppressed patient may be caused by malignancy, including Kaposi's sarcoma, non-Hodgkin's lymphoma, and by mycobacteria, both typical and atypical. I do not think that we can assume that what is happening in the lymph nodes is cryptococcal infection. Occam's razor—of diagnostic parsimony—often does not apply in this patient population and I think we need to consider a second pathology. The rise in CD4⁺ T lymphocyte count and fall in viral load has occurred in a very short interval and I just wonder if this is an immune reconstitution phenomenon—caused by *Mycobacterium avium* complex.

Pathology (Dr G Kocjan)

The lymph node FNA smears contained red cells, polymorphs, necrotic debris, and granulomatous inflammation, including epithelioid cells. A Ziehl-Neelsen stain for acid fast bacilli was positive (fig 4). A Grocott methenamine silver stain was negative for *Cryptococcus neoformans* and other fungi. No malignant cells were identified.

Case presentation (Dr Whitely, Dr Miller)

The HAART was continued and treatment was begun with rifabutin, isoniazid, ethambutol, and clarithromycin. This combination was chosen in order to cover both *M avium* complex and also *M tuberculosis*. At the same time, to compensate for the cytochrome P 450 inducing effects of rifabutin, the dose of fluconazole was increased to 800 mg once daily and also the dose of efavirenz was increased from 600 to 800 mg at night.

Seven weeks after commencing HAART, just before starting antimycobacterial therapy, the patient's CD4⁺ T lymphocyte count was 490 cells $\times 10^6/l$ and HIV viral load 100 copies/ml. At this time culture of peripheral blood obtained at the time of the admission, and the bone marrow aspirate, revealed *Cryptococcus neoformans*.

After 4 weeks of antimycobacterial therapy there had been little impact on the patient's symptoms and no reduction in the size of the lymphadenopathy. Further lymph nodes had enlarged and some began to discharge (fig 5).

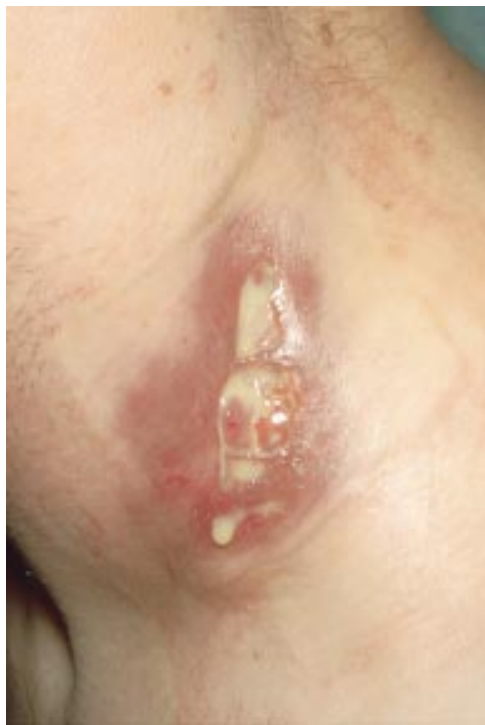

Figure 5 Discharging cervical lymph nodes.

Culture of aspirate from the lymph nodes showed that the mycobacteria were *M avium* complex. This organism was also cultured from stool and sputum samples which had been collected from the patient on admission to hospital. The isoniazid was discontinued and a course of oral prednisolone was given. This and subsequent non-steroidal anti-inflammatory therapy has had little impact on the size of the lymph nodes, which continue to discharge, 4 months later.

Discussion (Dr Peters)

I think this case has many interesting aspects. There has clearly been a very rapid, partial immune reconstitution and what has happened is that an immune reconstitution inflammatory syndrome (IRIS) has occurred in response to subclinical infection with *M avium* complex, producing lymphadenitis.² In this context adjuvant prednisolone and non-steroidal anti-

inflammatory drugs are sometimes of benefit and there are some reports that thalidomide, being used for its anti-inflammatory action, or interleukin 2 together with granulocyte colony stimulating factor have a beneficial effect, presumably via an immune modifying effect.

I am sure you did the right thing by continuing with the antiretroviral therapy as well as starting antimycobacterial therapy. There are some potential drug-drug interactions involving therapy that are metabolised by the hepatic cytochrome P 450 system.³ You were able to modify doses and continue therapy. By culturing the lymph node aspirate you were able to demonstrate that the mycobacteria were *M avium* complex and this enabled you to focus therapy and to reduce the number of tablets the patient was taking.

Another aspect of this case is the presence of two pathologies occurring simultaneously. Cryptococcal lymphadenitis is well described in HIV infected patients and, recently, IRIS lymphadenitis and meningitis due to cryptococcus has also been described.^{4,5} I wonder if the patient's prodromal cough heralded the onset of the disseminated cryptococcosis? In one case series of cryptococcosis in patients with AIDS 78% of patients had respiratory symptoms in the 4 months before diagnosis.⁶ It was postulated that the portal of entry of cryptococcus into the body was the lungs.

Finally, it is clear that in an HIV infected patient, fever without localising signs of presentation is rarely due to HIV itself and that the clinician faced with such a patient ought to search carefully for infection.⁷ This case demonstrates clearly that this holds true even in the era of HAART.

Pathology (Dr Kocjan)

Before the widespread availability of HAART, the finding of paucibacillary mycobacteriosis in a biopsy or aspirate was strongly suggestive of *M tuberculosis*, regardless of the degree of underlying HIV induced immunosuppression and regardless of whether or not there was an associated granulomatous response. This case suggests that this view should be questioned, particularly in patients receiving HAART, and it appears even more important to culture aspirate and biopsy specimens in order to speciate the mycobacteria that have been identified by staining.

Final diagnoses

- (1) Disseminated cryptococcosis
- (2) Immune reconstitution inflammatory syndrome with atypical mycobacteriosis causing lymphadenitis.

This clinicopathological conference was presented at the joint meeting of the Midlands HIV Interest Group and the Midlands Society for Genitourinary Medicine on 8 September 2000 at which time the case was described by Dr Rob Miller and the discussant was Dr Barry Peters. Dr Anjum Tariq transcribed the presentation for publication. We are grateful to Dr Ian Williams, who was the consultant in charge of the patient, for allowing us to present this case.

Source of financing: nil.
Conflict of interest: nil.

1 Reid AJC, Miller RF, Kocjan GI. Diagnostic utility of fine needle aspiration (FNA) cytology in HIV-infected patients with lymphadenopathy. *Cytopathology* 1998;9:230-9.

Key points

- Pyrexia of undetermined origin may present in the setting of partial immune reconstitution induced by HAART.
- "Occam's razor"—of diagnostic parsimony—may not apply in the immunosuppressed HIV positive patient as more than one pathology may be present simultaneously.
- All aspirate/biopsy material from lymph nodes of HIV positive patients should be stained specifically to look for infective organisms.
- In addition to identifying mycobacteria by staining and microscopy, culture is *mandatory* in order to speciate the organisms.
- Exclude intercurrent (opportunistic) infection when diagnosing/treating immune reconstitution inflammatory syndrome (IRIS).
- In addition to antimycobacterial therapy for IRIS lymphadenitis, it may also be necessary to give glucocorticoids and/or non-steroidal anti-inflammatories.

- 2 Race M, Adelson-Mitty J, Kriegel GR, et al. Focal mycobacterial lymphadenitis following the initiation of protease-inhibitor therapy in patients with advanced HIV-1 disease. *Lancet* 1998;351:252-5.
- 3 Pozniak AL, Miller R, Ormerod LP. Treatment of tuberculosis in HIV infected persons. *AIDS* 1999;13:435-45.
- 4 Blanche P, Gombert B, Ginsberg C, et al. HIV combination therapy: immune restitution causing cryptococcal lymphadenitis dramatically improved by anti-inflammatory therapy. *Scand J Infect Dis* 1998;30:615-16.
- 5 Woods ML, MacGinley R, Eisen D, et al. HIV combination therapy: partial immune restitution unmasking latent cryptococcal infection. *AIDS* 1998;12:1491-4.
- 6 Driver JA, Saunders CA, Heinze-Lacey B, et al. Cryptococcal pneumonia in AIDS: is cryptococcal meningitis preceded by clinically recognisable pneumonia? *J Acq Immun Defic Syndr* 1995;9:168-71.
- 7 Miller RF, Hingorani AD, Foley NM. Pyrexia of undetermined origin in patients with human immunodeficiency virus infection and AIDS. *Int J STD AIDS* 1996;7:170-5.