



DIGITAL ACCESS TO SCHOLARSHIP AT HARVARD

Intravitreal Fasudil Combined with Bevacizumab for Treatment of Refractory Diabetic Macular Edema; a Pilot Study

The Harvard community has made this article openly available.
[Please share](#) how this access benefits you. Your story matters.

Citation	Nourinia, Ramin, Hamid Ahmadiéh, Mohammad-Hassan Shahheidari, Souska Zandi, Shintaro Nakao, and Ali Hafezi-Moghadam. 2013. "Intravitreal Fasudil Combined with Bevacizumab for Treatment of Refractory Diabetic Macular Edema; a Pilot Study." <i>Journal of Ophthalmic & Vision Research</i> 8 (4): 337-340.
Accessed	February 19, 2015 3:43:38 PM EST
Citable Link	http://nrs.harvard.edu/urn-3:HUL.InstRepos:12064471
Terms of Use	This article was downloaded from Harvard University's DASH repository, and is made available under the terms and conditions applicable to Other Posted Material, as set forth at http://nrs.harvard.edu/urn-3:HUL.InstRepos:dash.current.terms-of-use#LAA

(Article begins on next page)

Intravitreal Fasudil Combined with Bevacizumab for Treatment of Refractory Diabetic Macular Edema; a Pilot Study

Ramin Nourinia¹, MD; Hamid Ahmadi¹, MD; Mohammad-Hassan Shahheidari¹, MD
Souska Zandi², PhD; Shintaro Nakao², PhD; Ali Hafezi-Moghadam², MD, PhD

¹Ophthalmic Research Center, Labbafinejad Medical Center, Shahid Beheshti University of Medical Sciences, Tehran, Iran
²Center for Excellence in Functional and Molecular Imaging, Brigham and Women's Hospital, and Department of Radiology, Harvard Medical School, Boston, MA, USA

Purpose: To evaluate the effect of intravitreal injection of a Rho-associated protein kinase (ROCK) inhibitor (Fasudil, Asahi Kasei Pharma Corporation, Tokyo, Japan) combined with intravitreal bevacizumab (IVB) on refractory diabetic macular edema (DME).

Methods: This prospective, interventional case series included 15 eyes of 15 patients with DME unresponsive to previous IVB injections. Eligible eyes underwent intravitreal injection of 0.025 mg Fasudil and 1.25 mg bevacizumab. Best corrected visual acuity (BCVA) and central macular thickness (CMT) were evaluated before and 4 weeks after treatment.

Results: Mean age was 64.6±7.3 (range, 49-79) years and mean number of previous IVB injections was 2.8. Mean pre-injection BCVA was 0.84±0.35 LogMAR, which was improved to 0.49±0.29 LogMAR four weeks after intervention (P=0.003). Mean CMT was decreased from 448±123 µm before treatment, to 347±76 µm at four weeks (P=0.001); no adverse event was observed during the study period.

Conclusion: Intravitreal ROCK inhibitors seem to entail structural and visual benefits in eyes with DME refractory to IVB monotherapy.

Keywords: Diabetic Macular Edema; Rho Kinase; Angiogenesis

J Ophthalmic Vis Res 2013; 8 (4): 337-340.

Correspondence to: Ramin Nourinia, MD. Labbafinejad Medical Center, Pajouh St., Boostan 9 St., Pasdaran, Tehran 16666, Iran; Tel: +98 21 2258 5952, Fax: +98 21 2259 0607; e-mail: ramin.retin@gmail.com

Received: June 27, 2013

Accepted: September 06, 2013

INTRODUCTION

Non-proliferative diabetic retinopathy is characterized by retinal microvascular damage, leading to vascular hyper-permeability and diabetic macular edema (DME). Many studies have demonstrated that intravitreal injection of bevacizumab¹⁻⁶, triamcinolone^{1,2,7,8} and sustained release dexamethasone⁹ have a beneficial effect on refractory DME in terms of central macular thickness (CMT) reduction and visual acuity (VA) improvement; but satisfying visual and anatomical

results may not always be achieved. Anti vascular endothelial growth factor (VEGF) therapy requires monthly injection of the antibodies for a long time to maintain vision, which poses a cumulative risk of ocular and systemic complications. Therefore, new treatment modalities and intravitreal drugs with more efficacy and long term effects seem to be necessary.

Improved understanding of the pathophysiology of diabetic retinopathy has facilitated the development of new drugs for treatment of DME in cases refractory to current

therapies. In addition to the previously known high VEGF levels, increased activity of the Rho/Rock pathway has recently been demonstrated in diabetic patients. This pathway promotes leukocyte adhesion to the retinal vascular endothelium by increasing intercellular adhesion molecule 1 (ICAM-1) expression and stimulating myosin regulatory light chain (MLC) phosphorylation.^{10,11} Furthermore, increased activity of the Rho/Rock pathway inactivates endothelial nitric oxide synthase (eNOS), thereby reducing physiological levels of nitric oxide (NO), a potent vasodilator and anti-apoptotic factor. Therefore, retinal endothelial cell damage occurs as a result of leukocyte adhesion and decreased eNOS activity.¹² Experimental studies have demonstrated that Fasudil (Asahi Kasei Pharma Corporation, Tokyo, Japan) as a potent ROCK inhibitor can suppress leukocyte adhesion and prevent neutrophil-induced retinal endothelial cell damage.¹³

In this prospective interventional case series, we evaluated the anatomical and visual outcomes of combined injection of intravitreal bevacizumab (IVB) and Fasudil in patients with refractory DME.

METHODS

Fifteen eyes of 15 patients with the following criteria were included: presence of type 2 diabetes

mellitus and DME with no CMT reduction or VA improvement after one or more IVB injections, BCVA \leq 20/40 and severe DME defined as CMT more than 320 μ m associated with large cystoid changes and/or neurosensory detachment. Exclusion criteria were active proliferative diabetic retinopathy, monocularly or VA of fellow eye $<$ 20/40, other macular disorders, intravitreal bevacizumab injection within the past 3 months, and ocular surgery over the past 6 months.

All patients received IVB (1.25 mg/0.05 ml) and intravitreal Fasudil injection (0.025 mg/0.05 ml) using two separate syringes and at two separate sites followed by anterior chamber paracentesis. Best-corrected visual acuity (BCVA) was measured and optical coherence tomography (OCT) images were obtained before and one month after the injections.

The study was approved by the Ethics Committee of the Ophthalmic Research Center and written informed consent was obtained from all participants.

RESULTS

Mean age of the patients was 64.6 ± 7.3 (range, 49-79) years and the mean number of previous IVB injections was 2.8. Mean BCVA was 0.84 ± 0.35 logMAR before intervention improving to 0.49 ± 0.29 logMAR four weeks after treatment

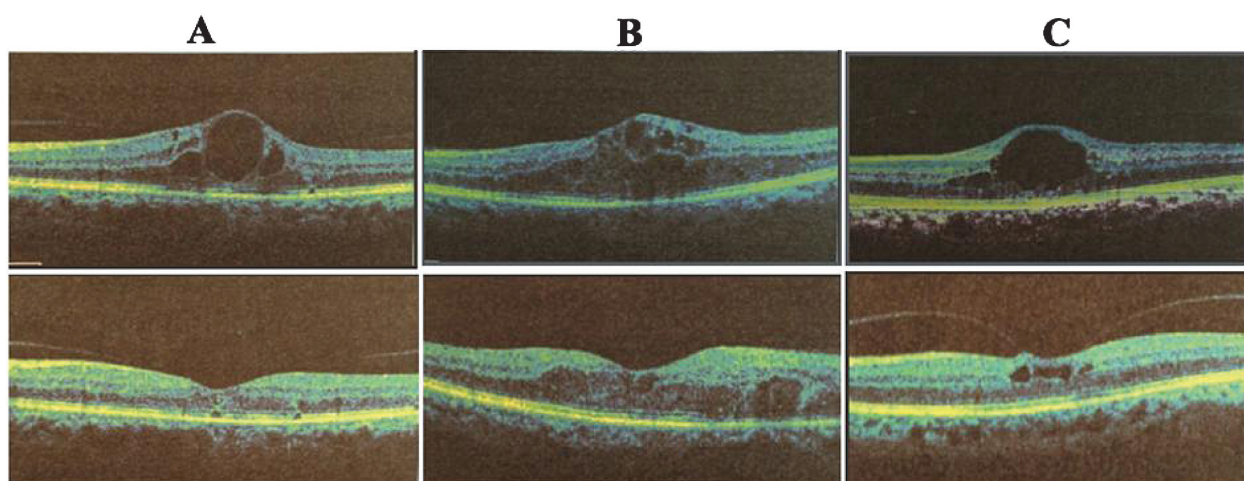


Figure 1. Optical coherence tomography images of three patients (A, B and C) show significant reduction of central macular thickness (CMT) one month after intravitreal injection of bevacizumab and Fasudil. CMT before treatment (top images) was 559, 516 and 455 μ m decreasing to 281, 344 and 330 μ m one month after treatment (lower images) in patients A, B and C, respectively.

Table 1. Number of previous intravitreal bevacizumab injections; best-corrected visual acuity and central macular thickness at baseline and 4 weeks after combined intravitreal injection of bevacizumab and Fasudil

No	Age (years)	Sex	Eye	Hx MPC	Hx IVB	BCVA Snellen (logMAR)			CMT (μm)		
						Baseline	4 wk after treatment	Change (%)	Baseline	4 wk after treatment	Change (%)
1	63	M	OD	1	2	1/10 (1)	3/10 (0.52)	48	400	371	7
2	79	M	OS	1	3*	1/10 (1)	3/10 (0.52)	48	367	344	6
3	59	M	OS	1	2	4/10 (0.4)	8/10 (0.1)	75	372	291	22
4	64	F	OS	1	3	CF 3 (1.3)	CF 3 (1.3)	0	493	302	39
5	65	M	OS	1	7	CF 2 (1.5)	3/10 (0.52)	65	439	323	26
6	64	M	OD	1	2	1/10 (1)	6/10 (0.22)	78	516	344	33
7	61	M	OS	1	3	1/10 (1)	2/10 (0.7)	30	392	344	12
8	76	M	OS	1	3	3/10 (0.52)	7/10 (0.15)	71	358	330	8
9	49	M	OS	1	4	2/10 (0.7)	4/10 (0.4)	43	570	441	23
10	67	M	OS	1	4	4/10 (0.4)	4/10 (0.4)	0	324	327	-1
11	67	M	OS	1	1	3/10 (0.52)	3/10 (0.52)	0	559	281	50
12	70	M	OD	1	1	3/10 (0.52)	3/10 (0.52)	0	784	581	26
13	63	F	OS	1	2	CF 4 (1.2)	2/10 (0.7)	42	455	330	27
14	56	F	OS	1	1	3/10 (0.52)	5/10 (0.3)	42	341	326	4
15	66	F	OD	1	5	1/10 (1)	3/10 (0.52)	48	344	275	20
Mean \pm SD						0.84 \pm 0.35	0.49 \pm 0.29	39 \pm 28	448 \pm 123	347 \pm 76	20 \pm 14
P-value for the change (Wilcoxon signed rank test)						0.003			0.001		

M, male; F, female; OD, right eye; OS, left eye; Hx, history of previous treatment; MPC, macular photocoagulation; IVB, intravitreal bevacizumab; BCVA, best-corrected visual acuity; CMT, central macular thickness; SD, standard deviation

*Also treated once by IVT

($P=0.003$). Mean pre-injection CMT was 448 ± 123 μm decreasing to 347 ± 76 μm four weeks after treatment ($P=0.001$) (Table 1 & Figure 1). No adverse effects such as intraocular inflammation, vascular accident and IOP rise were observed following intravitreal injection of Fasudil and bevacizumab.

DISCUSSION

The short term results of this case series showed that in DME refractory to IVB, combined intravitreal bevacizumab and Fasudil injection resulted in structural (CMT reduction) and functional (BCVA) improvement. These results are comparable or superior to other studies reporting intravitreal injection of bevacizumab, triamcinolone and sustained release dexamethasone in patients with refractory DME.¹⁻⁹

Multiple factors contribute to hyper-permeability of retinal vessel walls in diabetic patients. Rho/ROCK pathway activity in diabetic patients leads to adhesion of leukocytes to vascular endothelial cells, damaging them by affecting the expression of adhesion molecules

including ICAM-1 and integrin.^{10,11} Endothelial cell damage results in hyper-permeability of vessel walls, leading to macular edema. Fasudil is a potent and selective ROCK inhibitor. In vivo studies have demonstrated that intravitreal injection of Fasudil effectively suppresses increased ICAM-1 expression and retinal leukocyte adhesion in diabetic animals. Moreover, in a recent study, Fasudil effectively suppressed endothelial damage even when leukocytes firmly adhered to the endothelium.¹³ This suggests that Fasudil may protect vascular endothelial cells directly. This effect may be due to reversion of eNOS activity, in addition to inhibition of leukocyte adhesion.

We used 0.025 mg Fasudil intravitreally to achieve an intraocular concentration of $10\mu\text{M/L}$.¹⁴ Previous animal studies have not shown any obvious electrophysiological or morphological toxicity up to a maximum concentration of $100\mu\text{M/L}$.¹⁵ ERG findings in our previous study¹⁴ and comprehensive ocular examinations in the current study did not show any toxic effect associated with intravitreal Fasudil injection.

The results of this study and our previous report on a smaller number of cases¹⁴

demonstrate a possible beneficial effect from intravitreal injection of Fasudil in combination with IVB in patients with DME unresponsive to monotherapy with IVB. This combination may reduce retinal vessel hyper-permeability via simultaneous inhibition of VEGF activity and endothelial cell damage more effectively than intravitreal injection of an anti-VEGF alone.

In summary, combined intravitreal injection of bevacizumab and Fasudil seems to entail a beneficial effect in terms of structural and functional outcomes in eyes with severe DME resistant to current therapeutic modalities. Studies with larger sample size and longer follow-up are required to establish the use of Fasudil for DME.

Conflicts of Interest

None.

REFERENCES

- Ahmadieh H, Ramezani A, Shoeibi N, Bijanzadeh B, Tabatabaei A, Azarmina M, et al. Intravitreal bevacizumab with or without triamcinolone for refractory diabetic macular edema; a placebo – controlled, randomized clinical trial. *Graefes Arch Clin Exp Ophthalmol* 2008;246:483-489.
- Shoeibi N, Ahmadieh H, Entezari M, Yaseri M. Intravitreal bevacizumab with or without triamcinolone for refractory diabetic macular edema: long-term results of a clinical trial. *J Ophthalmic Vis Res.* 2013;8:99-106.
- Rajendram R, Fraser-Bell S, Kaines A, Michaelides M, Hamilton RD, Esposti SD, et al. A 2-year prospective randomized controlled trial of intravitreal bevacizumab or laser therapy (BOLT) in the management of diabetic macular edema: 24-month data: report 3. *Arch Ophthalmol* 2012;130:972-979.
- Mehta S, Blinder KJ, Shah GK, Kymes SM, Schlieff SL, Grand MG. Intravitreal bevacizumab for the treatment of refractory diabetic macular edema. *Ophthalmic Surg Lasers Imaging* 2010;41:323-329.
- Kook D, Wolf A, Kreutzer T, Neubauer A, Strauss R, Ulbig M, et al. Long- term effect of intravitreal bevacizumab (avastin) in patients with chronic diffuse diabetic macular edema. *Retina* 2008;28:1053-1060.
- Gulkilik G, Taskapili M, Kocabora S, Muftuoglu G, Demirci G. Intravitreal bevacizumab for persistent macular edema with proliferative diabetic retinopathy. *Int Ophthalmol* 2010;30:697- 702.
- Gillies MC, Sutter FK, Simpson JM, Larsson J, Ali H, Zhu M. Intravitreal triamcinolone for refractory diabetic macular edema: two-year results of a double-masked, placebo-controlled, randomized clinical trial. *Ophthalmology* 2006;113:1533-1538.
- Gillies MC, Simpson JM, Gaston C, Hunt G, Ali H, Zhu M, et al. Five-year results of a randomized trial with open-label extension of triamcinolone acetonide for refractory diabetic macular edema. *Ophthalmology* 2009;116:2182-2187.
- Haller JA, Kuppermann BD, Blumenkranz MS, Williams GA, Weinberg DV, Chou C, et al. Randomized controlled trial of an intravitreal dexamethasone drug delivery system in patients with diabetic macular edema. *Arch Ophthalmol* 2010;128:289-296.
- Lee H, Lin CI, Liao JJ, Lee YW, Yang HY, Lee CY, et al. Lysophospholipids increase ICAM-1 expression in HUVEC through a Gi- and NF-kappa-B-dependent mechanism. *Am J Physiol Cell Physiol* 2004;287:1657-1666.
- Kimura K, Ito M, Amano M, Chihara K, Fukata Y, Nakafuku M, et al. Regulation of myosin phosphatase by Rho and Rho-associated kinase (Rho-Kinase). *Science* 1996;273:245-248.
- Ming XF, Viswambharan H, Barandier C, Ruffieux J, Kaibuchi K, Rusconi S, et al. Rho GTPase/Rho kinase negatively regulates endothelial nitric oxide synthase phosphorylation through the inhibition of protein kinase B/Akt in human endothelial cells. *Mol Cell Biol* 2002;22:8467-8477.
- Arita R, Hata Y, Nakao S, Kita T, Miura M, Kawahara S, et al. Rho kinase inhibition by fasudil ameliorates diabetes-induced microvascular damage. *Diabetes* 2009;58:215-226.
- Ahmadieh H, Nourinia R, Hafezi-Moghadam A. Intravitreal fasudil combined with bevacizumab for persistent diabetic macular edema: a novel treatment. *JAMA Ophthalmol* 2013;131:923-924.
- Kita T, Hata Y, Arita R, Kawahara S, Miura M, Nakao S, et al. Role of TGF- β in proliferative vitreoretinal diseases and ROCK as a therapeutic target. *Proc Natl Acad Sci USA* 2008;105:17504-17509.