



DIGITAL ACCESS TO SCHOLARSHIP AT HARVARD

Mapping cortical anatomy in preschool aged children with autism using surface-based morphometry

The Harvard community has made this article openly available. [Please share](#) how this access benefits you. Your story matters.

| | |
|--------------------------|--|
| Citation | Raznahan, Armin, Rhoshel Lenroot, Audrey Thurm, Marta Gozzi, Allison Hanley, Sarah J. Spence, Susan E. Swedo, and Jay N. Giedd. 2012. "Mapping cortical anatomy in preschool aged children with autism using surface-based morphometry ." <i>NeuroImage : Clinical</i> 2 (1): 111-119. doi:10.1016/j.nicl.2012.10.005. http://dx.doi.org/10.1016/j.nicl.2012.10.005 . |
| Published Version | doi:10.1016/j.nicl.2012.10.005 |
| Accessed | February 19, 2015 2:42:35 PM EST |
| Citable Link | http://nrs.harvard.edu/urn-3:HUL.InstRepos:11878930 |
| Terms of Use | This article was downloaded from Harvard University's DASH repository, and is made available under the terms and conditions applicable to Other Posted Material, as set forth at http://nrs.harvard.edu/urn-3:HUL.InstRepos:dash.current.terms-of-use#LAA |

(Article begins on next page)



Mapping cortical anatomy in preschool aged children with autism using surface-based morphometry[☆]



Armin Raznahan^{a,*}, Rhoshel Lenroot^a, Audrey Thurm^b, Marta Gozzi^b, Allison Hanley^a, Sarah J. Spence^{b,c}, Susan E. Swedo^b, Jay N. Giedd^a

^a Child Psychiatry Branch, NIMH, NIH, Bethesda, MD, USA

^b Pediatrics and Developmental Neurosciences Branch, NIMH, NIH, Bethesda, MD, USA

^c Department of Neurology, Children's Hospital Boston, Harvard Medical School, USA

ARTICLE INFO

Article history:

Received 24 July 2012

Received in revised form 10 October 2012

Accepted 18 October 2012

Available online 31 October 2012

Keywords:

Cortical thickness

Surface area

Autism

Neuroimaging

ABSTRACT

The challenges of gathering in-vivo measures of brain anatomy from young children have limited the number of independent studies examining neuroanatomical differences between children with autism and typically developing controls (TDCs) during early life, and almost all studies in this critical developmental window focus on global or lobar measures of brain volume. Using a novel cohort of young males with Autistic Disorder and TDCs aged 2 to 5 years, we (i) tested for group differences in traditional measures of global anatomy (total brain, total white, total gray and total cortical volume), and (ii) employed surface-based methods for cortical morphometry to directly measure the two biologically distinct sub-components of cortical volume (CV) at high spatial resolution—cortical thickness (CT) and surface area (SA). While measures of global brain anatomy did not show statistically significant group differences, children with autism showed focal, and CT-specific anatomical disruptions compared to TDCs, consisting of relative cortical thickening in regions with central roles in behavioral regulation, and the processing of language, biological movement and social information. Our findings demonstrate the focal nature of brain involvement in early autism, and provide more spatially and morphometrically specific anatomical phenotypes for subsequent translational study.

© 2012 The Authors. Published by Elsevier Inc. All rights reserved.

1. Introduction

Autism is a relatively common (Baird et al., 2006; CDC, 2009), early-onset (Zwaigenbaum et al., 2005) syndrome characterized by impairments in communication, social interaction and behavioral flexibility (Volkmar et al., 2004). Children who meet full criteria for Autistic Disorder (American Psychiatric Association, 2000) show clearly abnormal socio-communicative development within the first 3 years of life, and over 50% will also fulfill diagnostic criteria for mental retardation [referred to as intellectual disability (ID) below] (Charman et al., 2011). This severe, paradigmatic autism phenotype, first formally described over 65 years ago (Kanner, 1943), is now considered to be part of a range of autistic presentations (including Asperger Disorder and Pervasive Developmental Disorder Not Otherwise Specified) that vary in severity and are collectively referred to as Autism Spectrum Disorder (ASD).

Although it is clear that genetic risks (Abrahams and Geschwind, 2008) and early disruptions of brain development (Amaral et al.,

2008) play central roles in ASD pathogenesis, it has been hard to establish firm links between specific risk factors and markers of aberrant neurodevelopment in ASD. One way forward may be to better leverage recent insights regarding the biological architecture of typical brain development, when seeking to delineate aspects of disrupted brain development for closer study in ASD. For example, to date, structural neuroimaging studies of the cortical sheet in young children with autism have largely used volume-based approaches, and focused on measurement of global or lobar cortical anatomy (Calderoni et al., 2012; Courchesne et al., 2001; Hazlett et al., 2005, 2011; Schumann et al., 2010). However, it is now clear from studies of typically developing populations that cortical volume (CV) can be fractionated into biologically distinct morphometric sub-components (Raznahan et al., 2011b), that are differentially impacted by genetic (Panizzon et al., 2009) and environmental (Raznahan et al., 2012) factors in a regionally specific manner. The capacity to tease apart such biologically informative, non-volumetric aspects of cortical anatomy at high spatial-resolution has largely arisen through the advent of tools for Surface Based Cortical Morphometry (SBM) (Fischl and Dale, 2000; MacDonald et al., 2000) from structural Magnetic Resonance Imaging (sMRI) data. Our current study represents the first application of SBM to characterize disruptions of cortical anatomy in preschool aged children with an ASD.

[☆] This is an open-access article distributed under the terms of the Creative Commons Attribution-NonCommercial-ShareAlike License, which permits non-commercial use, distribution, and reproduction in any medium, provided the original author and source are credited.

* Corresponding author at: Rm 4C108, Building 10, 10 Center Drive, Bethesda, MD, 20892, USA.

E-mail address: raznahan@mail.nih.gov (A. Raznahan).

The early developmental period spanned by our study is particularly important for models of autism biology because it captures the time when typically developing individuals are undergoing profound neuro-behavioral change (Courchesne et al., 2000; Knickmeyer et al., 2008), and when the symptoms of autism are clearly manifested in most affected individuals (Shumway et al., 2011). Neurostructural alterations already apparent in young children with ASD may also better index primary disease processes than disruptions of brain anatomy charted in older populations; the latter being more prone to inclusion of secondary neuroanatomical alterations reflecting consequences of having an ASD on brain structure (Murphy et al., 2011). The challenges of gathering high-quality neuroimaging data from preschool aged children have however proven to be a significant obstacle, particularly for groups with ASD. To date, reports are available for three independent single-site cohorts (Calderoni et al., 2012; Hazlett et al., 2011; Schumann et al., 2010), and two composite cohorts (Estes et al., 2011; Hoefl et al., 2011). These pioneering studies have shed light on altered brain anatomy in ASD during early childhood, but fail to reach consensus on several fundamental issues including: the developmental stability of brain volume differences between individuals with ASD and typically developing controls (TDCs) [stable differences (Hazlett et al., 2011), vs age-dependent differences (Schumann et al., 2010)]; the presence of significant differences in total brain volume (TBV) between individuals with ASD and TDCs once age-effects have been taken into account [presence (Courchesne et al., 2001) vs. absence (Calderoni et al., 2012; Hazlett et al., 2005, 2011) of differences]; and which sub-divisions within the brain exhibit volume alterations in ASD [fronto-temporal only (Schumann et al., 2010) vs all lobes (Hazlett et al., 2011)]. These inconsistent findings regarding global and lobar measures of brain anatomy are accompanied by the absence of any spatially fine-grained surface-based analyses of brain anatomy in young children with ASD.

The current study had three main objectives. First, we sought to re-visit the question of whether young children with ASD (specifically diagnosed with Autistic Disorder) show global and lobar abnormalities of total brain volume, within a fourth (Calderoni et al., 2012; Hazlett et al., 2011; Schumann et al., 2010) independently recruited single-site clinical cohort. Second, with the aim of distinguishing separate morphometric components of cortical development that could be differentially impacted by ASD, we sought to decompose CV into cortical thickness (CT) and surface area (SA). This fractionation of CV builds on a recent report that CV dysmaturational in adolescents and older adults with ASD is driven by CT rather than SA (Raznahan et al., 2010b). To date, the only study to have tested for dissociable abnormalities of CT and SA in young children with ASD inferred SA from measures of CV and CT (Hazlett et al., 2011). In the current study, we use SBM to directly measure CV, CT and SA.

The third, and perhaps most critical objective of our study was to provide the first spatially fine-grained SBM analysis of cortical anatomy in young children with autism. All but one (Hoefl et al., 2011) of the existing studies in this age range only assayed regional cortical anatomy using classical lobar boundaries (Carper et al., 2002; Hazlett et al., 2005, 2011; Schumann et al., 2010). Therefore, using a well-validated (Kabani et al., 2001; MacDonald et al., 2000; Shaw et al., 2008) SBM method to fine-map CT and SA across the cortical sheet, we tested the hypothesis that regions of the cortex previously reported as structurally abnormal in older groups with ASD (Chung et al., 2005; Ecker et al., 2010; Hadjikhani et al., 2006; Raznahan et al., 2010b) (see Fig. 1), and known to be crucial for social cognition (Adolphs, 2003), language (Price, 2010), and behavioral control (Langen et al., 2011a; Langen et al., 2011b), would already show focal disruption at the early ages evaluated in our study. These regions include (but are not limited to) inferior frontal gyrus, medial prefrontal cortex, superior temporal sulcus, middle temporal gyrus, fusiform gyrus, and inferior parietal lobule. We were

particularly interested in whether focal disruptions of cortical anatomy in autism during early childhood would be better captured by CT or SA.

Since several existing reports suggest that anatomical differences between groups with ASD and controls may vary with age (Carper et al., 2002; Mak-Fan et al., 2012; Raznahan et al., 2010b; Wallace et al., 2010), we directly examined whether anatomical differences between children with autism and TDCs were modulated by age.

2. Materials and methods

2.1. Participants

All 95 participants were male and aged between 2 and 5 years of age. Sixty-six participants fulfilled DSM-IV diagnostic criteria for Autistic Disorder (AUT), and 29 were typically developing controls (TDCs). Initially, children diagnosed with autism or referred with concerns of a possible autism diagnosis were screened for participation, after responding to recruitment materials placed in the community (e.g. pediatricians' offices and early intervention providers). The presence of Autistic Disorder was then established by doctoral level clinicians after research-reliable administrations of the Autism Diagnosis Interview-Revised (Lord et al., 1994) (or a Toddler version), the Autism Diagnostic Observation Schedule [ADOS (Lord et al., 2000)], and clinical judgment. None of the participants had defined genetic disorders associated with an increased risk for ASD (e.g. Tuberous Sclerosis, Fragile X, Smith-Magenis syndrome), as determined by clinical assessment, karyotyping Fragile X testing, and CGH microarray testing. Other exclusionary criteria were a diagnosis of cerebral palsy or other neurological conditions that would prevent study procedure completion. Recruitment of TDCs was through advertisement in the local community and inclusion required cognitive scores higher than 1.5 standard deviations below standardized test means. Exclusionary criteria for TDCs included a first-degree relative with ASD, a history of extremely low birth-weight, or a history of receiving special education services/early intervention prior to study enrollment. Screening for TDCs included cognitive testing, as well as administration of the ADOS (Lord et al., 2000), Social Communication Questionnaire (Berument et al., 1999) and Child Behavior Checklist (Achenbach et al., 1991).

Developmental quotients [full (DQ), verbal (VDQ) and nonverbal (NVDQ)] were measured for all participants using either the Mullen Scales of Early Learning (Mullen, 1995) or the Differential Ability Scales (2nd edition) (Elliott, 2007). Due to floor effects on tests, Developmental Quotient (DQ's), based on age equivalent divided by chronological age multiplied by 100, were used to fully characterize individual variation. Since two TDC participants had DQs greater than 130, we tested for and confirmed robustness of our findings by removal of these two individuals.

In all cases, written informed consent was obtained from the participant's parent(s). The study was approved by an NIH Institutional Review Board.

2.2. Neuroimaging

The neuroimaging methods used in this study have been previously described (Lenroot et al., 2007; Raznahan et al., 2011b; Shaw et al., 2008) and are fully detailed in Supplementary Texts 1 and 2. Briefly, all scans were T-1 weighted images with contiguous 1.5 mm axial slices, obtained on the same 1.5-T General Electric (Milwaukee, WI) Signa scanner using a 3D spoiled gradient recalled echo sequence. Given the difficulty of obtaining high-quality neuroimaging data in young children with autism, we scanned children with autism under sedation using propofol. Sedation was performed at the NIH by board-certified

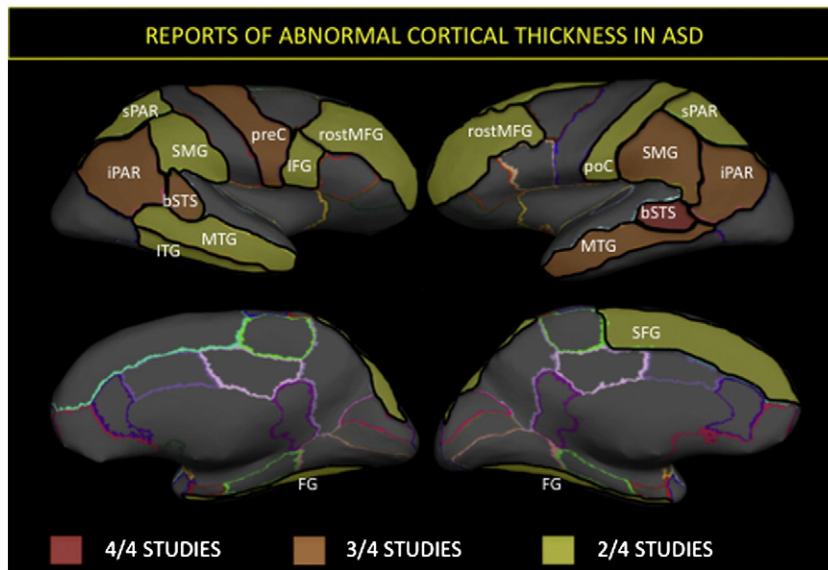


Fig. 1. Synthesis of findings from existing studies of cortical thickness differences between individuals with ASD and TDCs. Four (Hadjikhani et al., 2006; Raznahan et al., 2010b; Scheel et al., 2011; Wallace et al., 2010) of the six (Chung et al., 2005; Mak-Fan et al., 2012) existing studies that compare cortical thickness (CT) between people with an ASD diagnosis and controls have used the same procedure for surface based cortical morphometry (Fischl and Dale, 2000), which allows the findings of these studies to be integrated using the same nomenclature for cortical parcellation into gyral-based regions of interest (Desikan et al., 2006). The number of times each gyral region has shown an abnormality in ASD compared to controls across these four studies is color coded for those regions that have shown abnormalities in at least two studies. Despite methodological differences between studies, there are clear convergences in reported patterns of CT abnormality (collapsing across reports of CT excess, deficit and age-related abnormalities). [SFG—superior frontal gyrus, rostrMFG—rostral middle frontal gyrus, IFG—inferior frontal gyrus, preC—precentral gyrus, postC—postcentral gyrus, spar—superior parietal lobule, iPL—inferior parietal lobule, bSTS—bank of the superior temporal sulcus, MTG—middle temporal gyrus, ITG—inferior temporal gyrus, FG—fusiform gyrus].

anesthesiologists following a strict clinical protocol. Typically developing controls were scanned during natural sleep at nighttime (with repeat scans taken in the event of excess movement). Native sMRI scans were then submitted to the CIVET pipeline for automated morphometric analysis. This pipeline generates (i) estimates of total gray matter volume (GMV), total white matter volume (WMV) and cerebro-spinal fluid (CSF) using a validated neural net approach to voxel classification (Cocosco et al., 2003; Zijdenbos et al., 2002), (ii) global and lobar estimates of total CV, total SA and mean CT by registration of all cortical surfaces to a manually labeled surface group template, and propagation of labels from the template to each individual surface (Im et al., 2008), and (iii) “vertex-based” estimates of CT and SA at ~80,000 points on the cortical sheet by modeling gray/white and pial cortical surfaces for each scan using a deformable-mesh approach (MacDonald et al., 2000). Vertex CT was calculated as the distance between homologous vertices in pial and gray/white surfaces (MacDonald et al., 2000), and vertex SA as the total area of all six triangles surrounding each vertex on a tessellated intermediate surface mesh between pial and gray/white surfaces (Jubault et al., 2011). Vertex SA is dependent on the spatial distribution of vertices in the tessellated mesh defining a given the cortical surface. However, the potential for group differences in cortical shape to generate mesh-dependent biases in vertex SA is minimized by all cortical surfaces being resampled with a common mesh in spherical template space before reversing registration for each scan so that vertex SA measures are taken in native space (Lyttelton et al., 2007). While the resampling algorithm applied in spherical template space is non-conservative, group-differences in the area of facets surrounding each vertex still provide a meaningful index of relative SA expansion/contraction at each vertex. Vertex-based group analyses were conducted using on smoothed native CT and SA values in spherical template space. All scans included in analyses passed rigorous quality assessment and control of CIVET output for errors in skull removal and definition of

cortical surfaces. Supplementary Fig. 1 provides an example of CIVET output as generated for a scan within our study.

2.3. Statistical analysis

We examined anatomical indices in three stages: (1) gross global measures of anatomy—TBV, total tissue volume (TTV—the sum of GMV and WMV), total GMV, and total WMV, (2) global and lobar measures of cortical anatomy—CV, CT and SA, (3) vertex-based CT and SA measures. Age was modeled in a linear fashion as preliminary analyses failed to identify statistically significant higher-order (e.g. quadratic) age-effects on anatomy. In the absence of statistically significant interactions between linear age and diagnostic group for any of the anatomical measures examined, we moved to a simpler model that included only the main effects of age and diagnosis:

$$\text{Anatomy} = \text{Intercept} + \beta_1(\text{Age}) + \beta_2(\text{Group}). \quad (1)$$

For global anatomical indices, statistical significance of the β_2 term in model (1) above was determined using a $p = 0.05$ threshold, and for lobar analyses, a Bonferroni-corrected p value threshold of $p = 0.015$ was applied (0.05/4). For vertex-based analyses, the same β_2 term was mapped across the cortical sheet after application of a False Discovery Rate correction for multiple comparisons with q (the expected proportion of falsely rejected null hypotheses) set at 0.05 (see Fig. 2). We also generated unthresholded maps of the β_2 term t-statistic for vertex-based CT and SA analyses (see Supplementary Figs. 2 and 3 respectively).

Global anatomical indices were not included as covariates in lobar or vertex-based analyses because they did not differ significantly between groups (see below), and are known to show complex non-linear relationships with most SBM metrics (Im et al., 2008).

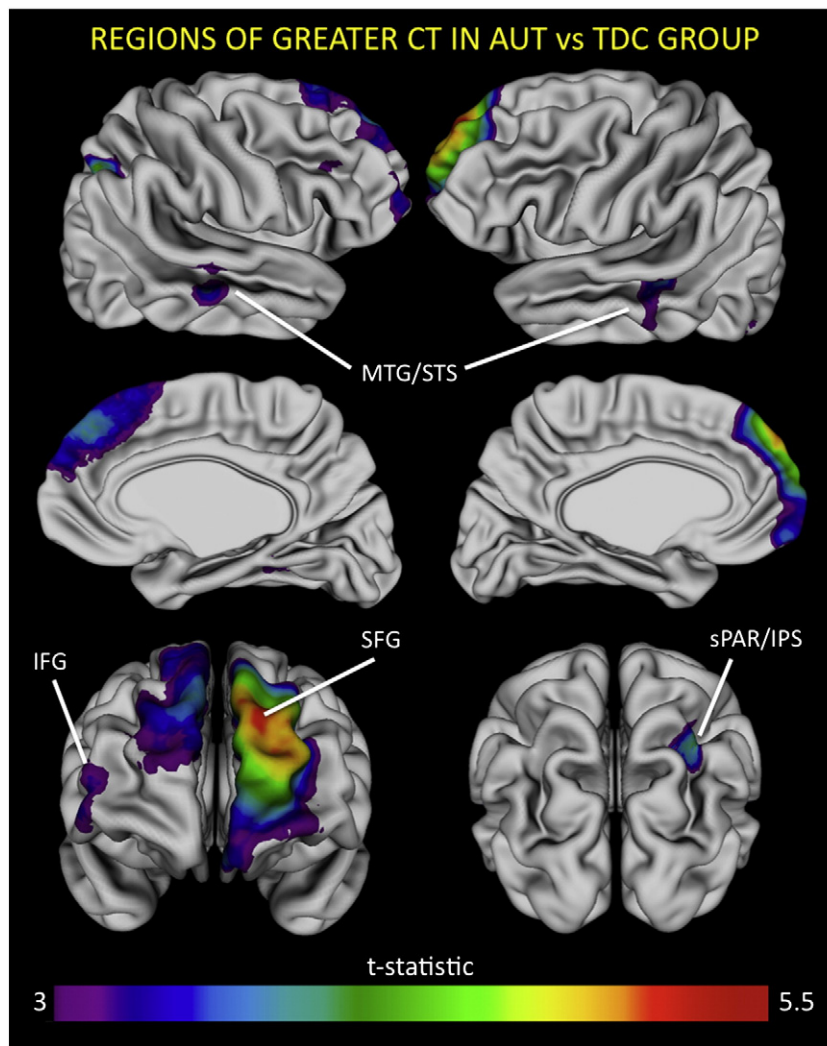


Fig. 2. Vertex-map of regions showing regions of statistically significant cortical thickness (CT) excess in children with autism (AUT) compared to typically developing controls (TDCs). Colored regions denote areas of significant group differences in estimated CT. There were no regions where CT was significantly less in the AUT relative to TDC group. Statistical significance was determined by application of a False Discovery Correction for multiple comparisons with q (the expected proportion of falsely rejected null hypotheses) set a 0.05.

Table 1

Participant characteristics. SES was assessed using the Hollingshead scale. Continuous and categorical demographic variables were compared between participants with autism and TDCs using t-tests and Chi-squared tests, respectively.

| Characteristic | Autism | TDC | Group difference |
|--------------------------------|-----------|------------|------------------|
| Number | 66 | 29 | |
| Age, years | | | n.s. |
| Mean (s.d.) | 3.8 (1.0) | 3.8 (1.1) | |
| Range | 2.2–5.9 | 2.0–5.9 | |
| Race | | | n.s. |
| Caucasian | 44 | 21 | |
| Black | 13 | 5 | |
| Asian | 3 | 1 | |
| Mixed | 6 | 2 | |
| SES, mean (s.d.) | 54 (8.3) | 57 (8.5) | t=1.4, p=0.2 |
| ADOS severity, mean (s.d) | 7.7 (1.5) | 1.2 (0.4) | t=22.4, p<0.0005 |
| Full Development Quotient (DQ) | | | t=12.9, p<0.0005 |
| Mean (s.d.) | 54 (17.5) | 109 (12.8) | |
| Range | 22–101 | 86–144 | |
| Verbal DQ | | | t=15.0, P<0.0005 |
| Mean (s.d.) | 44 (20.4) | 109 (17.0) | |
| Range | 12–96 | 83–151 | |
| Non-verbal DQ | | | t=12.9, p<0.0005 |
| Mean (s.d.) | 63 (16.6) | 109 (13.6) | |
| Range | 32–109 | 81–148 | |

3. Results

3.1. Participant characteristics

Participant characteristics are summarized in Table 1. There were no significant group differences in age, ethnicity, or socioeconomic status (SES). As expected, mean DQ, VDI and NVDQ were all significantly lower in children with Autistic Disorder than in TDCs, and ADOS severity scores were significantly higher.

We were unable to detect a statistically significant interaction between age and group for any of the anatomical indices examined. The following sections therefore describe group differences in anatomy with age included as a covariate of main effect.

3.2. Global volumes

We did not identify statistically significant differences in TBV, TTV, total WMV or total GMV between AUT and TDC groups (see Table 2).

Table 2

Global and lobar measures of anatomy in young children with autism (AUT) and typically developing controls (TDCs). Results are shown separately for global volumetric indices [total brain volume (TBV), total tissue volume (TTV), total white matter volume (WMV) and total gray matter volume (GMV)], and SBM measures of cortical anatomy [cortical volume (CV), cortical thickness (CT) and surface area (SA)]. Levene's test did not detect any statistically significant group differences in anatomical variance.

| Measure | Volume, cm ³ , Mean (s.e.) | | Comparison, AUT-TDC | | | |
|-----------------------|---------------------------------------|-------------|-----------------------------|---------------------|-----|-----|
| | TDC | AUT | Difference, cm ³ | Difference, percent | t | p |
| TBV (GMV + WMV + SCF) | 1422 (21.9) | 1441 (14.8) | +19 | 1 | 0.8 | 0.5 |
| TTV (GMV + WMV) | 1297 (20.9) | 1313 (14.1) | +16 | 1 | 0.7 | 0.5 |
| WMV | 412 (8.5) | 415 (5.7) | +3 | 0.5 | 0.3 | 0.8 |
| GMV | 885 (14.0) | 899 (9.5) | +14 | 1.5 | 0.8 | 0.4 |

| Measure | Volume, cm ³ , Mean (s.e.) | | Comparison, AUT-TDC | | | |
|--------------|---------------------------------------|-----------|-----------------------------|---------------------|------|-----|
| | TDC | AUT | Difference, cm ³ | Difference, percent | t | p |
| Global CV | 658 (11.3) | 667 (7.7) | +8.8 | 1 | 0.7 | 0.5 |
| Frontal CV | 243 (4.0) | 246 (2.7) | +2.5 | 1 | 0.5 | 0.6 |
| Temporal CV | 209 (3.8) | 213 (2.6) | +3.8 | 2 | 0.9 | 0.4 |
| Parietal CV | 128 (2.6) | 132 (1.7) | +4.2 | 3 | 1.4 | 0.2 |
| Occipital CV | 77 (1.80) | 75 (1.2) | -1.6 | -2 | -0.8 | 0.4 |

| Measure | Thickness, mm, Mean (s.e.) | | Comparison, AUT-TDC | | | |
|--------------|----------------------------|------------|---------------------|---------------------|-----|------|
| | TDC | AUT | Difference, mm | Difference, percent | t | p |
| Global CT | 3.8 (0.03) | 3.9 (0.02) | +0.06 | 1.5 | 1.6 | 0.1 |
| Frontal CT | 4.0 (0.03) | 4.1 (0.02) | +0.09 | 2 | 2.1 | 0.04 |
| Temporal CT | 4.0 (0.03) | 4.1 (0.02) | +0.04 | 1 | 1 | 0.3 |
| Parietal CT | 3.6 (0.03) | 3.7 (0.03) | +0.06 | 2 | 1.5 | 0.1 |
| Occipital CT | 3.4 (0.04) | 3.4 (0.03) | +0.01 | <0.5 | 0.3 | 0.8 |

| Measure | Area, cm ² , Mean (s.e.) | | Comparison, AUT-TDC | | | |
|--------------|-------------------------------------|-----------|-----------------------------|---------------------|------|-----|
| | TDC | AUT | Difference, cm ² | Difference, percent | t | p |
| Global SA | 187 (2.5) | 188 (1.7) | +1 | <0.5 | 0.3 | 0.8 |
| Frontal SA | 71 (1.0) | 71 (0.7) | -0.3 | <0.5 | -0.2 | 0.8 |
| Temporal SA | 48 (0.7) | 49 (0.5) | +0.6 | <0.5 | 1.1 | 0.3 |
| Parietal SA | 44 (0.7) | 44 (0.5) | +0.2 | <0.5 | 0.2 | 0.8 |
| Occipital SA | 24 (0.5) | 24 (0.3) | +0.03 | <0.5 | 0.1 | 0.9 |

3.3. Global and lobar cortical measures

We did not identify statistically significant group-differences in total CV, mean CT or total SA (see Table 2). Analyses of lobar metrics identified a trend towards increased bilateral frontal CT in the AUT relative to TDC group however, although this did not survive Bonferroni correction for multiple comparisons ($t = 2.1$, $p = 0.04$).

3.4. Vertex-level cortical thickness and surface area

These analyses revealed a largely bilateral set of cortical regions where CT was significantly greater in the AUT group than TDCs after False Discovery Rate (FDR) correction for multiple comparisons. These regions included bilateral superior frontal gyrus (lateral and medial aspects, with extension into ventromedial and rostral

prefrontal cortex in the left hemisphere) and superior temporal sulcus, as well as left inferior frontal gyrus (ventrolateral prefrontal cortex) and right intraparietal sulcus [see Fig. 2 (thresholded), Supplementary Fig. 2 (unthresholded), and Table 3]. In contrast, vertex-based analyses of SA did not identify statistically significant group-differences that survived FDR correction for multiple comparisons. Regional trends towards greater SA in the AUT group relative to TDCs did however emerge at a nominal threshold of $p \leq 0.05$. These did not overlap with regions of significant CT difference between groups, and fell within the bilateral superior temporal gyrus, bilateral temporo-occipital junction, and right superior parietal lobule [Supplementary Figs. 3A (thresholded) and 3B (unthresholded)].

In light of the potential for non-normality of vertex-based SA data (Winkler et al., 2012), we tested for, and confirmed, robustness of our vertex-based SA results to log transformation of vertex-SA.

Table 3

Regional cortical thickness (CT) excesses in young children with autism (AUT) relative to typically developing controls (TDCs).

| Peak vertex | MNI co-ordinate, x,y,z | Brodmann area | Cortical thickness, mm, mean (s.e.m.) | | Group difference | | |
|--|------------------------|---------------|---------------------------------------|------------|------------------|-------------|----------|
| | | | TDC | AUT | % | t-statistic | p value |
| <i>Left</i> | | | | | | | |
| Superior frontal gyrus (extending into rostral prefrontal and medial frontal cortex) | -13, 65, 21 | 10 | 3.9 (0.07) | 4.3 (0.05) | 10 | 5.1 | 0.000002 |
| Superior temporal sulcus (extending into middle temporal cortex) | -48, -38, 2 | 41 | 3.9 (0.04) | 4.1 (0.03) | 8 | 3.8 | 0.0003 |
| <i>Right</i> | | | | | | | |
| Superior frontal gyrus (extending into medial frontal cortex) | 9, 62, 27 | 10 | 3.9 (0.08) | 4.2 (0.06) | 8 | 3.9 | 0.0002 |
| Middle frontal gyrus (extending into inferior frontal gyrus) | 39, 55, -2 | 10 | 3.8 (0.06) | 4.0 (0.04) | 5 | 3.3 | 0.001 |
| Superior temporal sulcus (extending into middle temporal cortex) | 59, -26, 1 | 41 | 4.0 (0.04) | 4.2 (0.03) | 5 | 3.5 | 0.0007 |
| Rostral intraparietal sulcus | 32, -62, 53 | 7 | 3.3 (0.05) | 3.6 (0.04) | 9 | 4 | 0.0001 |

4. Discussion

4.1. Summary of main findings

Within our pre-school aged sample, there was no evidence for increased TBV in children with autism relative to TDCs, and this lack of a significant volumetric group difference held for WMV, GMV and CV. Global SBM-derived measures of CT and SA also failed to show statistically significant group-differences, although lobar analyses suggested a trend towards increased frontal CT in children with autism relative to TDCs. Moving beyond global and lobar indices revealed a clear pattern of focal anatomical disruption in preschool aged children with autism however. Children with autism showed CT excesses relative to TDCs within a set of cortical regions that are not only known to be important for social cognition (Adolphs, 2003), language (Price, 2010), and behavioral control (Langen et al., 2011a, 2011b), but have also shown structural and functional alterations in older ASD populations (Amaral et al., 2008). In contrast we did not detect statistically significant group differences in regional SA.

4.2. Global volumes

To help better contextualize our volumetric results, Table 4 summarizes the findings of all existing single-site sMRI studies that have examined comparable anatomical indices in young children with an ASD and TDCs.

Integration of our findings with earlier work strengthens the notion that children with autism do not show age-related alterations of TBV, WMV or GMV relative to TDCs during the preschool age-range (Hazlett et al., 2005, 2011). The absence of age-invariant group-differences in WMV within our sample also converges with all prior investigations of this phenomenon during the preschool age range (Hazlett et al., 2005, 2011). There is less agreement across studies regarding the presence of fixed TBV and GMV abnormalities in young children with ASD relative to TDCs however, which may reflect true neuroanatomical heterogeneity in ASD, or methodological differences between studies. Although no obvious methodological characteristics co-segregate with the presence (Courchesne et al., 2001; Hazlett et al., 2011) or absence [current study and (Hazlett et al., 2005)] of significant TBV differences between young children with an ASD relative to TDCs it is notable that all “positive” GMV studies have considered children with an ASD (Calderoni et al., 2012; Hazlett et al., 2011), whereas all “negative” GMV studies have focused on more narrowly defined Autistic Disorder [current report and (Hazlett et al., 2005)]. This raises the testable hypothesis that some aspect of the behaviorally-defined boundary between Autistic Disorder and other ASDs may be relevant for GMV heterogeneity within the autism spectrum.

4.3. Global and lobar cortical measures

Of the anatomical phenotypes examined in our study, most prior information is available for CV. Two independent single-site cohorts other than our own have examined CV in preschool aged children with an ASD and TDCs [University of California, San Diego (Schumann et al., 2010), and University of North Carolina (Hazlett et al., 2005, 2011)]. The latest studies from these two cohorts have used longitudinal methodology to directly measure within-group CV change (Hazlett et al., 2011; Schumann et al., 2010), but describe different patterns of CV dysmaturation in children with ASD relative to TDCs, which are in turn each dissimilar from prior cross-sectional findings within the same cohorts (Courchesne et al., 2001; Hazlett et al., 2005) (see Table 5). The inconsistency of earlier findings regarding total CV, together with the lack of any significant group-differences in total CV within our current cohort underlines the challenges faced in seeking to clarify if and how global volumetric measures of brain anatomy are disrupted in ASD during early childhood.

The absence of significant group-differences in global CV within our study was accompanied by negative findings for mean CT and total SA. At a lobar level of analysis however, we found evidence for a trend towards greater frontal CT in children with autism relative to TDCs. Our SBM findings differ from the only existing study of CT and SA in young children with autism, which found CV excesses in autism to be driven by SA rather than CT (Hazlett et al., 2011). Direct comparison between studies is complicated however by fundamental differences in the techniques used to derive measures of the cortical sheet [e.g. volume-based (Hazlett et al., 2011) vs. surface-based measurement of CT (see Supplementary Texts 1 and 2 for further details)], and in the age and diagnostic composition of samples.

4.4. Vertex-level cortical thickness and surface area

Measurements of global cortical properties may be fundamentally limited in their ability to provide replicable and mechanistically informative disease biomarkers if aberrant development in ASD is concentrated within specific neural systems. Our vertex-based results support this idea, as they indicate that even at relatively early ages, disruptions of cortical development in autism are localized in nature. Furthermore, CT appears to be a more sensitive marker of aberrant cortical anatomy in autism than SA. It will however be important to revisit differential involvement of CT and SA in ASD using newly-evolving approaches that seek to optimize registration and interpolation steps for the study of absolute local SA (Winkler et al., 2012).

The cortical regions where we find CT abnormalities in preschool aged children with autism have (i) been linked to cognitive domains relevant to ASD by basic science studies in older children and adults (Adolphs, 2003; Langen et al., 2011a, 2011b; Price, 2010), (ii) shown resting-state and language-related activation abnormalities in fMRI studies comparing preschool aged children with ASD and TDCs (Redcay and Courchesne, 2008; Redcay et al., 2008), and (iii) shown CT abnormalities across several independent SBM studies of older children, adolescents and adults with ASD (Chung et al., 2005; Ecker et al., 2010; Hadjikhani et al., 2006; Mak-Fan et al., 2012; Raznahan et al., 2010b; Wallace et al., 2010). This convergence is most apparent for the IFG, IPL, STS and MTG; regions which are also notable for being simultaneously relevant to multiple cognitive neuroscience accounts of ASD including those emphasizing disruptions of language [IFG, MTG, STS, IPL (Price, 2010)], action-observation/execution and imitation [IFG, STS, IPL (Rizzolatti and Craighero, 2004)], and the perception of social stimuli [STS (Adolphs, 2003)].

The regionally-specific and early-onset nature of CT alterations identified by our study has consequences for etiological models of autism. First, the early timing of these alterations serves to narrow the developmental window within which any hypothesized experience-dependent contributions towards regionally-specific “derailment” of cortical development in ASD would have to operate. Second, the specific regions that alterations were found in strengthens disease models in which genetic or early environmental risk factors for ASD perturb specific cortical systems destined to later process language and social stimuli. Thirdly, it suggests that future progress in the delineation of molecular and cellular processes underlying aberrant cortical development in ASD may be more rapid if energy is directed towards cellular and molecular processes of known relevance for CT (rather than SA) maturation. There is already some evidence that CT maturation is modulated by functional genetic variants within signaling pathways that have been implicated in ASD (Raznahan et al., 2010a, 2011a). Our understanding of dissociable anatomical alterations in ASD promises to be further refined as approaches for measuring and parsing the diverse range of anatomical phenotypes that can be discerned from the cerebral cortex via in-vivo sMRI continues to improve.

The findings of our study should be interpreted in light of several caveats and limitations. First, although comparable with other sMRI

Table 4

Summary of existing reports for the global volumetric indices in children with autism (or ASD) and typically developing controls. This table only considers reports for those anatomical indices examined in our study. The single-site studies included in this table originate from one of two centers: University of California, San Diego, USA (UCSD), University of North Carolina, USA (UNC), and University of Pisa, Italy (UP).

| Center | First Author | Year | Design | Cases | | | | | Controls | | | | Measure | Finding | |
|--------|--------------|------|-----------------|-----------------|------|--------|-----|-------|-----------------|------|-----|-------|---------|-----------------------------|---|
| | | | | Number | Type | +/- ID | Sex | Age | Number | Type | Sex | Age | | Group difference | Age effects on anatomy |
| UCSD | Courchesne | 2001 | Cross sectional | 30 ^a | AUT | Mixed | M | 2–4 | 12 ^a | TDC | M | 2–4 | TBV | AUT > TDC | Significant group difference over larger 2–16 year age range |
| | | | | | | | | | | | | | CV | AUT > TDC | Significant group differences over larger 2–16 year age range |
| | Schumann | 2011 | Longitudinal | 41 | AUT | Mixed | M,F | 1.5–5 | 44 | TDC | M,F | 1.5–5 | CV | No significant difference | Less curvilinear CV increase in AUT than TDC group |
| | | | Longitudinal | 32 | AUT | Mixed | M | 1.5–5 | 32 | TDC | M | 1.5–5 | CV | No significant difference | No significant difference |
| UNC | Hazlett | 2005 | Cross Sectional | 41 | AUT | Mixed | M,F | 1.5–4 | 44 | TDC | M,F | 1.5–4 | CV | AUT > TDC | Not examined |
| | | | Cross Sectional | 51 | AUT | Mixed | M,F | 1.5–3 | 14 ^b | TDC | M,F | 1.5–3 | TBV | No significant difference | No significant group difference |
| | Hazlett | 2011 | Longitudinal | 59 ^c | ASD | Mixed | M,F | 1.5–5 | 26 ^c | TDC | M,F | 1.5–5 | GMV | No significant difference | No significant group difference |
| | | | | | | | | | | | | | WMV | No significant difference | No significant group difference |
| | | | | | | | | | | | | | CV | AUT > TDC trend at p = 0.09 | No significant group difference |
| | | | | | | | | | | | | | TBV | ASD > TDC | No significant group difference |
| UP | Calderoni | 2012 | Cross-sectional | 19 | ASD | No ID | F | 2–7 | 19 | TDC | F | 2–7 | GMV | ASD > TDC | No significant group difference |
| | | | | | | | | | | | | | WMV | No significant difference | Not examined |
| NIH | Raznahan | 2012 | Cross-sectional | 66 | AUT | Mixed | M | 2–5 | 29 | TDC | M | 2–5 | TBV | No significant difference | No significant group difference |
| | | | | | | | | | | | | | GMV | No significant difference | No significant group difference |
| | | | | | | | | | | | | | WMV | No significant difference | No significant group difference |
| | | | | | | | | | | | | | CV | No significant difference | No significant group difference |

^a Sample size for a sub-group of participants that was defined by study authors and best overlaps with the age-range examined in our report.

^b Sample size of typically developing controls.

^c Sample size at first time-point.

studies in young children with ASD (Hazlett et al., 2005, 2011; Schumann et al., 2010), the number of participants included in our study is relatively small, and further studies of this age-range using larger samples will be important. Second, since our study is cross-sectional rather than longitudinal, inferences regarding age-related phenomena are not based on measures of intra-individual anatomical change and should be regarded as preliminary. However, our study design did allow us to carry out the first test for age-related alterations of CV, CT and SA in preschool aged children with an ASD using SBM methods of established reliability (Kabani et al., 2001; MacDonald et al., 2000; Shaw et al., 2008). Third, although we only used scans that were free of excess movement artifact as determined by visual inspection, it is conceivable that sub-threshold group-differences in head motion, arising from differential use of sedation across groups, could have exerted a systematic influence on morphometric analysis. Fourth, while our study provides information about

biologically distinct components of the cortical sheet in autism, in-vivo sMRI studies of human brain anatomy are currently unable to provide information about the cellular underpinning of macroscopic anatomical variation. Fifth, our focus on males with Autistic Disorder, the majority of whom also had ID, limits generalizability of findings to females or autistic individuals without ID. These limitations were necessary in order to enhance internal validity of our findings by increasing sample homogeneity. Since sex robustly modifies brain anatomy (Lenroot et al., 2007; Raznahan et al., 2010a) and risk for ASD (Baron-Cohen et al., 2011), directly testing for sex-differences in the neural correlates of ASD may be a preferable strategy to co-varying for sex as a main effect in neuroimaging studies of ASD that use mixed sex-groups where males far outnumber females. With regard to ID, while prospective neuroimaging studies in high-risk groups are still being gathered, studies of ASD during early childhood will necessarily be biased towards earlier-presenting cases

of ASD that tend to have more frank and severe symptoms (Shattuck et al., 2009). One response to this bias has been to use mixed groups of patients with idiopathic ID as controls with the objective of identifying anatomical correlates of ASD that exist “above and beyond” any ID (Hazlett et al., 2011). Our use of typically developing individuals as controls prevents testing for specificity of the identified anatomical alterations to autism rather than ID. However, motivation for distinguishing sMRI markers of ASD and ID in populations where both behavioral syndromes co-occur has waned as an increasing number of studies show that many of the best-established genetic risks for (Kendler, 2005) ASD are also robustly associated with ID (Mitchell, 2011).

Despite these limitations our study reports results from a valuable new independent cohort of young children with autism, and uses SBM for the first time within this population to move beyond global and lobar measures of brain volume, and dissociate alterations of CT and SA at high-spatial resolution across the cortical sheet. We show that preschool aged children with ASD have significant CT (rather than SA) abnormalities within cortical systems crucial for the processing of language and social information. These findings provide (i) more refined intermediate phenotypes for future genetic studies in autism, and (ii) the first direct evidence that disease mechanisms in autism can already produce targeted disruption of cortical thickness by early childhood. Finally, establishing that cortical involvement in ASD shows pronounced regional heterogeneity, raises questions about the utility of continued focus on global and lobar aspects of cortical anatomy in ASD.

Supplementary data to this article can be found online at <http://dx.doi.org/10.1016/j.nicl.2012.10.005>.

References

- Abrahams, B.S., Geschwind, D.H., 2008. Advances in autism genetics: on the threshold of a new neurobiology. *Nature Reviews Genetics* 9, 341–355.
- Achenbach, T.M., Howell, C.T., Quay, H.C., Conners, C.K., 1991. National survey of problems and competencies among four- to sixteen-year-olds: parents' reports for normative and clinical samples. *Monographs of the Society for Research in Child Development* 56, 1–131.
- Adolphs, R., 2003. Cognitive neuroscience of human social behaviour. *Nature Reviews Neuroscience* 4, 165–178.
- Amaral, D.G., Schumann, C.M., Nordahl, C.W., 2008. Neuroanatomy of autism. *Trends in Neurosciences* 31, 137–145.
- American Psychiatric Association, 2000. *Diagnostic and Statistical Manual of Mental Disorders: Test Revision (DSM-IV-TR)*. American Psychiatric Association, Washington DC.
- Baird, G., Simonoff, E., Pickles, A., Chandler, S., Loucas, T., Meldrum, D., Charman, T., 2006. Prevalence of disorders of the autism spectrum in a population cohort of children in South Thames: the Special Needs and Autism Project (SNAP). *Lancet* 368, 210–215.
- Baron-Cohen, S., Lombardo, M.V., Auyeung, B., Ashwin, E., Chakrabarti, B., Knickmeyer, R., 2011. Why are autism spectrum conditions more prevalent in males? *PLoS Biology* 9, e1001081.
- Berument, S.K., Rutter, M., Lord, C., Pickles, A., Bailey, A., 1999. Autism screening questionnaire: diagnostic validity. *The British Journal of Psychiatry* 175, 444–451.
- Calderoni, S., Retico, A., Biagi, L., Tancredi, R., Muratori, F., Tosetti, M., 2012. Female children with autism spectrum disorder: an insight from mass-univariate and pattern classification analyses. *NeuroImage* 59, 1013–1022.
- Carper, R.A., Moses, P., Tigue, Z.D., Courchesne, E., 2002. Cerebral lobes in autism: early hyperplasia and abnormal age effects. *NeuroImage* 16, 1038–1051.
- CDC, 2009. Prevalence of autism spectrum disorders—Autism and Developmental Disabilities Monitoring Network, United States, 2006. *MMWR Surveillance Summaries* 58, 1–20.
- Charman, T., Pickles, A., Simonoff, E., Chandler, S., Loucas, T., Baird, G., 2011. IQ in children with autism spectrum disorders: data from the Special Needs and Autism Project (SNAP). *Psychological Medicine* 41, 619–627.
- Chung, M.K., Robbins, S.M., Dalton, K.M., Davidson, R.J., Alexander, A.L., Evans, A.C., 2005. Cortical thickness analysis in autism with heat kernel smoothing. *NeuroImage* 25, 1256–1265.
- Coccosco, C.A., Zijdenbos, A.P., Evans, A.C., 2003. A fully automatic and robust brain MRI tissue classification method. *Medical Image Analysis* 7, 513–527.
- Courchesne, E., Chisum, H.J., Townsend, J., Cowles, A., Covington, J., Egaas, B., Harwood, M., Hinds, S., Press, G.A., 2000. Normal brain development and aging: quantitative analysis at in vivo MR imaging in healthy volunteers. *Radiology* 216 (3), 672–682.
- Courchesne, E., Karns, C.M., Davis, H.R., Ziccardi, R., Carper, R.A., Tigue, Z.D., Chisum, H.J., Moses, P., Pierce, K., Lord, C., Lincoln, A.J., Pizzo, S., Schreibman, L., Haas, R.H., Akshoomoff, N.A., Courchesne, R.Y., 2001. Unusual brain growth patterns in early life in patients with autistic disorder: an MRI study. *Neurology* 57, 245–254.
- Desikan, R.S., Segonne, F., Fischl, B., Quinn, B.T., Dickerson, B.C., Blacker, D., Buckner, R.L., Dale, A.M., Maguire, R.P., Hyman, B.T., Albert, M.S., Killiany, R.J., 2006. An automated labeling system for subdividing the human cerebral cortex on MRI scans into gyral based regions of interest. *NeuroImage* 31, 968–980.
- Ecker, C., Marquand, A., Mourao-Miranda, J., Johnston, P., Daly, E.M., Brammer, M.J., Maltezos, S., Murphy, C.M., Robertson, D., Williams, S.C., Murphy, D.G., 2010. Describing the brain in autism in five dimensions—magnetic resonance imaging-assisted diagnosis of autism spectrum disorder using a multiparameter classification approach. *Journal of Neuroscience* 30, 10612–10623.
- Elliott, C.D. (Ed.), 2007. *Manual for the Differential Ability Scales*, Second edition. Harcourt Assessment, San Antonio, TX.
- Estes, A., Shaw, D.W., Sparks, B.F., Friedman, S., Giedd, J.N., Dawson, G., Bryan, M., Dager, S.R., 2011. Basal ganglia morphometry and repetitive behavior in young children with autism spectrum disorder. *Autism Research* 4, 212–220.
- Fischl, B., Dale, A.M., 2000. Measuring the thickness of the human cerebral cortex from magnetic resonance images. *Proceedings of the National Academy of Sciences of the United States of America* 97, 11050–11055.
- Hadjikhani, N., Joseph, R.M., Snyder, J., Tager-Flusberg, H., 2006. Anatomical differences in the mirror neuron system and social cognition network in autism. *Cerebral Cortex* 16, 1276–1282.
- Hazlett, H.C., Poe, M., Gerig, G., Smith, R.G., Provenzale, J., Ross, A., Gilmore, J., Piven, J., 2005. Magnetic resonance imaging and head circumference study of brain size in autism: birth through age 2 years. *Archives of General Psychiatry* 62, 1366–1376.
- Hazlett, H.C., Poe, M.D., Gerig, G., Styner, M., Chappell, C., Smith, R.G., Vachet, C., Piven, J., 2011. Early brain overgrowth in autism associated with an increase in cortical surface area before age 2 years. *Archives of General Psychiatry* 68, 467–476.
- Hoefl, F., Walter, E., Lightbody, A.A., Hazlett, H.C., Chang, C., Piven, J., Reiss, A.L., 2011. Neuroanatomical differences in toddler boys with fragile x syndrome and idiopathic autism. *Archives of General Psychiatry* 68, 295–305.
- Im, K., Lee, J.M., Lyttelton, O., Kim, S.H., Evans, A.C., Kim, S.I., 2008. Brain size and cortical structure in the adult human brain. *Cerebral Cortex* 18, 2181–2191.
- Jubault, T., Gagnon, J.F., Karama, S., Ptito, A., Lafontaine, A.L., Evans, A.C., Monchi, O., 2011. Patterns of cortical thickness and surface area in early Parkinson's disease. *NeuroImage* 55, 462–467.
- Kabani, N., Le, G.G., MacDonald, D., Evans, A.C., 2001. Measurement of cortical thickness using an automated 3-D algorithm: a validation study. *NeuroImage* 13 (2), 375–380.
- Kanner, L., 1943. Autistic disturbances of affective contact. *The Nervous Child* 2, 217–250.
- Kendler, K.S., 2005. “A gene for...”: the nature of gene action in psychiatric disorders. *The American Journal of Psychiatry* 162, 1243–1252.
- Knickmeyer, R.C., Gouttard, S., Kang, C., Evans, D., Wilber, K., Smith, J.K., Hamer, R.M., Lin, W., Gerig, G., Gilmore, J.H., 2008. A structural MRI study of human brain development from birth to 2 years. *Journal of Neuroscience* 28, 12176–12182.
- Langen, M., Durston, S., Kas, M.J., van Engeland, H., Staal, W.G., 2011a. The neurobiology of repetitive behavior: ...and men. *Neuroscience and Biobehavioral Reviews* 35, 356–365.
- Langen, M., Kas, M.J., Staal, W.G., van Engeland, H., Durston, S., 2011b. The neurobiology of repetitive behavior: of mice. *Neuroscience and Biobehavioral Reviews* 35, 345–355.
- Lenroot, R.K., Gogtay, N., Greenstein, D.K., Wells, E.M., Wallace, G.L., Clasen, L.S., Blumenthal, J.D., Lerch, J., Zijdenbos, A.P., Evans, A.C., Thompson, P.M., Giedd, J.N., 2007. Sexual dimorphism of brain developmental trajectories during childhood and adolescence. *NeuroImage* 36, 1065–1073.
- Lord, C., Rutter, M., Le Couteur, A., 1994. Autism Diagnostic Interview-Revised: a revised version of a diagnostic interview for caregivers of individuals with possible pervasive developmental disorders. *Journal of Autism and Developmental Disorders* 24, 659–685.
- Lord, C., Risi, S., Lambrecht, L., Cook Jr., E.H., Leventhal, B.L., DiLavore, P.C., Pickles, A., Rutter, M., 2000. The autism diagnostic observation schedule-generic: a standard measure of social and communication deficits associated with the spectrum of autism. *Journal of Autism and Developmental Disorders* 30, 205–223.
- Lyttelton, O., Boucher, M., Robbins, S., Evans, A., 2007. An unbiased iterative group registration template for cortical surface analysis. *NeuroImage* 34, 1535–1544.
- MacDonald, D., Kabani, N., Avis, D., Evans, A.C., 2000. Automated 3-D extraction of inner and outer surfaces of cerebral cortex from MRI. *NeuroImage* 12, 340–356.
- Mak-Fan, K.M., Taylor, M.J., Roberts, W., Lerch, J.P., 2012. Measures of cortical grey matter structure and development in children with autism spectrum disorder. *Journal of Autism and Developmental Disorders* 42, 419–427.
- Mitchell, K.J., 2011. The genetics of neurodevelopmental disease. *Current Opinion in Neurobiology* 21, 197–203.
- Mullen, E.M. (Ed.), 1995. *Mullen Scales of Early Learning*. American Guidance Service, Circle Pines, MN.
- Murphy, D.G., Beecham, J., Craig, M., Ecker, C., 2011. Autism in adults. New biological findings and their translational implications to the cost of clinical services. *Brain Research* 1380, 22–33.
- Panizzon, M.S., Fennema-Notestine, C., Eyler, L.T., Jernigan, T.L., Prom-Wormley, E., Neale, M., Jacobson, K., Lyons, M.J., Grant, M.D., Franz, C.E., Xian, H., Tsuang, M., Fischl, B., Seidman, L., Dale, A., Kremen, W.S., 2009. Distinct genetic influences on cortical surface area and cortical thickness. *Cerebral Cortex* 19, 2728–2735.
- Price, C.J., 2010. The anatomy of language: a review of 100 fMRI studies published in 2009. *Annals of the New York Academy of Sciences* 1191, 62–88.
- Raznahan, A., Lee, Y., Stidd, R., Long, R., Greenstein, D., Clasen, L., Addington, A., Gogtay, N., Rapoport, J.L., Giedd, J.N., 2010a. Longitudinally mapping the influence of sex and androgen signaling on the dynamics of human cortical maturation in adolescence. *Proceedings of the National Academy of Sciences of the United States of America* 107, 16988–16993.

- Raznahan, A., Toro, R., Daly, E., Robertson, D., Murphy, C., Deeley, Q., Bolton, P.F., Paus, T., Murphy, D.G., 2010b. Cortical anatomy in autism spectrum disorder: an in vivo MRI study on the effect of age. *Cerebral Cortex* 20, 1332–1340.
- Raznahan, A., Lee, Y., Long, R., Greenstein, D., Clasen, L., Addington, A., Rapoport, J.L., Giedd, J.N., 2011a. Common functional polymorphisms of DISC1 and cortical maturation in typically developing children and adolescents. *Molecular Psychiatry* 16, 917–926.
- Raznahan, A., Shaw, P., Lalonde, F., Stockman, M., Wallace, G.L., Greenstein, D., Clasen, L., Gogtay, N., Giedd, J.N., 2011b. How does your cortex grow? *Journal of Neuroscience* 31, 7174–7177.
- Raznahan, A., Greenstein, D., Lee, N.R., Clasen, L.S., Giedd, J.N., 2012. Prenatal growth in humans and postnatal brain maturation into late adolescence. *Proceedings of the National Academy of Sciences of the United States of America* 109 (28), 11366–11371.
- Redcay, E., Courchesne, E., 2008. Deviant functional magnetic resonance imaging patterns of brain activity to speech in 2–3-year-old children with autism spectrum disorder. *Biological Psychiatry* 64, 589–598.
- Redcay, E., Haist, F., Courchesne, E., 2008. Functional neuroimaging of speech perception during a pivotal period in language acquisition. *Developmental Science* 11, 237–252.
- Rizzolatti, G., Craighero, L., 2004. The mirror-neuron system. *Annual Review of Neuroscience* 27, 169–192.
- Scheel, C., Rotarska-Jagiela, A., Schilbach, L., Lehnhardt, F.G., Krug, B., Vogeley, K., Tepest, R., 2011. Imaging derived cortical thickness reduction in high-functioning autism: key regions and temporal slope. *NeuroImage* 58, 391–400.
- Schumann, C.M., Bloss, C.S., Barnes, C.C., Wideman, G.M., Carper, R.A., Akshoomoff, N., Pierce, K., Hagler, D., Schork, N., Lord, C., Courchesne, E., 2010. Longitudinal magnetic resonance imaging study of cortical development through early childhood in autism. *Journal of Neuroscience* 30, 4419–4427.
- Shattuck, P.T., Durkin, M., Maenner, M., Newschaffer, C., Mandell, D.S., Wiggins, L., Lee, L.C., Rice, C., Giarelli, E., Kirby, R., Baio, J., Pinto-Martin, J., Cuniiff, C., 2009. Timing of identification among children with an autism spectrum disorder: findings from a population-based surveillance study. *Journal of the American Academy of Child and Adolescent Psychiatry* 48, 474–483.
- Shaw, P., Kabani, N.J., Lerch, J.P., Eckstrand, K., Lenroot, R., Gogtay, N., Greenstein, D., Clasen, L., Evans, A., Rapoport, J.L., Giedd, J.N., Wise, S.P., 2008. Neurodevelopmental trajectories of the human cerebral cortex. *Journal of Neuroscience* 28, 3586–3594.
- Shumway, S., Thurm, A., Swedo, S.E., Deprey, L., Barnett, L.A., Amaral, D.G., Rogers, S.J., Ozonoff, S., 2011. Brief report: symptom onset patterns and functional outcomes in young children with autism spectrum disorders. *Journal of Autism and Developmental Disorders* 41, 1727–1732.
- Volkmar, F.R., Lord, C., Bailey, A., Schultz, R.T., Klin, A., 2004. Autism and pervasive developmental disorders. *Journal of Child Psychology and Psychiatry, and Allied Disciplines* 45, 135–170.
- Wallace, G.L., Dankner, N., Kenworthy, L., Giedd, J.N., Martin, A., 2010. Age-related temporal and parietal cortical thinning in autism spectrum disorders. *Brain* 133 (Pt 12), 3745–3754.
- Winkler, A.M., Sabuncu, M.R., Yeo, B.T., Fischl, B., Greve, D.N., Kochunov, P., Nichols, T.E., Blangero, J., Glahn, D.C., 2012. Measuring and comparing brain cortical surface area and other areal quantities. *NeuroImage* 61, 1428–1443.
- Zijdenbos, A.P., Forghani, R., Evans, A.C., 2002. Automatic “pipeline” analysis of 3-D MRI data for clinical trials: application to multiple sclerosis. *IEEE Transactions on Medical Imaging* 21, 1280–1291.
- Zwaigenbaum, L., Bryson, S., Rogers, T., Roberts, W., Brian, J., Szatmari, P., 2005. Behavioral manifestations of autism in the first year of life. *International Journal of Developmental Neuroscience* 23, 143–152.