



DIGITAL ACCESS TO SCHOLARSHIP AT HARVARD

Acute Herpetic Keratitis: What is the Role for Ganciclovir Ophthalmic Gel?

The Harvard community has made this article openly available.
[Please share](#) how this access benefits you. Your story matters.

Citation	Sahin, Afsun, and Pedram Hamrah. 2012. Acute herpetic keratitis: what is the role for ganciclovir ophthalmic gel? <i>Ophthalmology and Eye Diseases</i> 4: 23-34.
Published Version	doi:10.4137/OED.S7267
Accessed	February 19, 2015 12:08:02 PM EST
Citable Link	http://nrs.harvard.edu/urn-3:HUL.InstRepos:11178961
Terms of Use	This article was downloaded from Harvard University's DASH repository, and is made available under the terms and conditions applicable to Other Posted Material, as set forth at http://nrs.harvard.edu/urn-3:HUL.InstRepos:dash.current.terms-of-use#LAA

(Article begins on next page)

REVIEW

OPEN ACCESS
Full open access to this and
thousands of other papers at
<http://www.la-press.com>.

Acute Herpetic Keratitis: What is the Role for Ganciclovir Ophthalmic Gel?

Afsun Sahin^{1,2} and Pedram Hamrah¹

¹Ocular Surface Imaging Center, Cornea and Refractive Surgery Service, Massachusetts Eye and Ear Infirmary, and Department of Ophthalmology, Harvard Medical School, Boston, MA. ²Eskisehir Osmangazi University Medical School, Department of Ophthalmology, Eskisehir, Turkey. Corresponding author email: pedram_hamrah@meei.harvard.edu

Abstract: Herpes simplex keratitis (HSK) is a major cause of corneal blindness in the world. Following the primary infection, the virus enters into a latent phase. Recurrent infectious or immune keratitis cause structural damage to the cornea, scarring, and may lead to blindness. Several commercially available topical and oral antiviral drugs for HSK are currently available. However, toxicity and low patient compliance hamper their use in HSK. Further, oral antiviral drugs alone are not always effective in HSK. Thus, there had been a need for safe and effective topical antiviral agents against HSK. Systemic ganciclovir has been in use for the treatment of cytomegalovirus infections. Recently, topical ganciclovir has become available for use in patients with HSK. Ganciclovir 0.15% ophthalmic gel has been shown to be both safe and effective against viruses of the herpes family. Topical ganciclovir ophthalmic gel is well tolerated and does not cause significant toxic effects on the ocular surface. Several multicenter studies have revealed the potential role of ganciclovir ophthalmic gel in the treatment and prophylaxis of epithelial HSK. In this paper, we have reviewed the pharmacology, efficacy, side effects, and the role of ganciclovir ophthalmic gel 0.15% in the treatment of acute herpetic keratitis.

Keywords: herpes simplex, ganciclovir, antiviral, keratitis, herpetic

Ophthalmology and Eye Diseases 2012:4 23–34

doi: [10.4137/OED.S7267](https://doi.org/10.4137/OED.S7267)

This article is available from <http://www.la-press.com>.

© the author(s), publisher and licensee Libertas Academica Ltd.

This is an open access article. Unrestricted non-commercial use is permitted provided the original work is properly cited.

Introduction

The herpes simplex virus type 1 (HSV-1) and type 2 (HSV-2) belong to family of herpes viridae, including varicella-zoster, Epstein-Barr, cytomegalovirus, and human herpes viruses types 6–8.^{1,2} While ocular disease is typically caused by HSV-1, and HSV-2 infections generally affect the genital area, this division is not mutually exclusive. Following the primary infection with HSV-1, the virus undergoes a characteristic non-replicating latent state in the trigeminal ganglion.^{3,4} Although the primary infection may be asymptomatic, it can also have a severe presentation, particularly in children and newborns, with involvement of the central nervous system in the form of encephalitis or meningitis.^{1,4}

HSV keratitis (HSK) is the most common infectious cause of unilateral blindness in the developed world.^{5–7} In the United States alone, the total number of episodes is estimated to be around 48,000 per year, with approximately 20,000 new cases per year.^{8–10} In contrast, congenital ocular herpetic disease is rather rare, with HSV-2 accounting for 80% of cases.¹ Primary ocular HSV presents as periocular and eyelid vesicles, acute follicular conjunctivitis, and in some cases with keratoconjunctivitis (Fig. 1).⁵ While latent in the trigeminal ganglion, HSV can reactivate anytime during lifetime, particularly by stress, UV radiation, a compromised immune system, and hormonal changes.^{1,2,5,7–12} Though recurrent disease may affect any ocular tissue, it is more common in the cornea and uvea. Recurrent HSK can ultimately lead to corneal scarring, ocular surface disease, neurotrophic keratopathy, and consequently to corneal perforation and blindness in severe cases^{1,2} (Fig. 2). Therefore prompt treatment is extremely important in the management of ocular HSV disease.

In the past two decades, management of ocular HSV infection has improved considerably due to advances in topical and systemic antiviral drugs. Treatment of HSK is tailored to patients depending on the clinical manifestation, the affected layer, and severity of disease. Epithelial forms are generally treated with oral and/or topical antiviral therapy. Until recently, five topical ophthalmic antiviral drugs have been available in the United States and Europe: idoxuridine (IDU), iododesoxycytidine, vidarabine, trifluridine 1% (Viroptic), and acyclovir 3% (Zovirax®). However, toxicity of these topical antiviral drugs and their poor tolerance have remained a major problem.^{13,14} More recently, ganciclovir has become available as an 0.15% ophthalmic gel (Zirgan™).

Idoxuridine was the first antiviral used to treat HSV-1 infections; however, side effects and poor aqueous solubility limited its topical use. Vidarabine, also developed for the treatment of HSK, had fewer toxic side effects than IDU, but had poor solubility. Currently, trifluridine ophthalmic solution (Viroptic) is the most widely used topical antiviral drug for the treatment of epithelial HSK in the United States (US). TFT, a nucleoside analogue, is activated by viral and host cell thymidine kinase and is integrated into the DNA of both the herpes virus and host cells.^{15–17} TFT should not be used longer than 3 weeks by patients, due to its severe ocular toxicity. Moreover, because of its low solubility, the corneal penetration is limited when the corneal epithelium is intact.^{13,14,18–25}

Acyclovir and the more recent addition to the armamentarium against HSV, ganciclovir, both target only infected cells and are therefore less toxic than their previous counterparts.^{26,27} They inhibit viral replication in a similar manner as trifluridine. However, thymidine kinase phosphorylates acyclovir

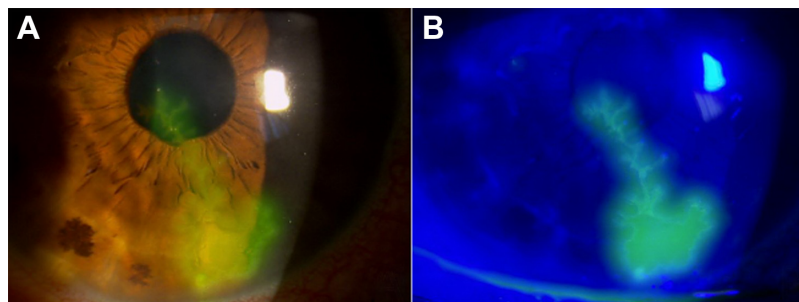


Figure 1. (A) Dendritic corneal lesion caused by herpes simplex virus. (B) After topical fluorescein drop installation the same lesion shows hyperfluorescence under cobalt blue light.

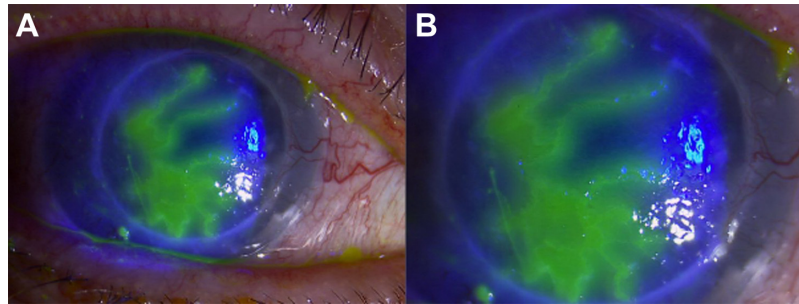


Figure 2. (A) Geographical ulcer showing hyperfluorescence on a corneal graft. (B) High magnification photo of the same lesion. **Note:** Terminal bulbs, which are characteristic of herpetic epithelial keratitis, are present.

and ganciclovir primarily in infected cells.^{16,17} After phosphorylation, they inhibit viral DNA polymerase and/or directly incorporate into the viral primer strand DNA.^{28–32} Acyclovir has poor aqueous solubility and is thus formulated as an ointment. Although acyclovir is highly effective against HSK, patient compliance is severely hindered due to blurring of vision after application of the ointment. Moreover, acyclovir ophthalmic ointment is not commercially available in the United States. Ganciclovir, which has a similar activity as acyclovir, has previously been widely used via both oral and intravenous routes.^{33–40} Ganciclovir has a wide-spectrum against HSV-1, HSV-2, Epstein-Barr virus, varicella zoster virus, cytomegalovirus, human herpes viruses, and adenoviruses.^{35,36,40–42} In contrast to acyclovir, however, ganciclovir has good water solubility, allowing for preparation of its gel form. Although ganciclovir ophthalmic gel 0.15% (ZirganTM) was approved for topical use in some European countries as Virgan since 1995, it was only just recently approved in the United States for acute herpetic keratitis in September 2009.^{31,43}

Herein, we will review the pharmacology, efficacy, side effects, and role of ganciclovir ophthalmic gel 0.15% in the treatment of acute herpetic keratitis.

Mechanism of Action, Metabolism, and Pharmacokinetic Profile

Ganciclovir is a synthetic nucleoside analogue of 2'-deoxyguanosine and has a molecular weight of 255.23.^{28,43} The chemical name is 9-[[2-hydroxy-1-(hydroxymethyl)ethoxy]methyl]guanine (CAS number 82410-32-0).^{28,43} It is selectively phosphorylated by viral thymidine kinase of the herpes viruses and by protein kinase of CMV.^{29,40,44} This phosphorylated form is further phosphorylated by both viral

and cellular thymidine kinases of virus infected cells.⁴⁴ The ultimate product, ganciclovir triphosphate, is the active metabolite and accumulates only in infected host cells avoiding toxicity to the uninfected healthy cells. It has an intracellular half-life more than 24 hours. The active metabolite inhibits viral DNA synthesis by competitively binding to DNA polymerase. Further, it works through direct incorporation of the active metabolite into viral strand primer DNA, which results in chain termination and inhibition of viral replication.⁴³

Although it is structurally and pharmacologically similar to acyclovir, ganciclovir has a lower antiviral activity against cytomegalovirus (CMV) and a lower selectivity for viral DNA.⁴⁰ Oral, intravenous (IV), intravitreal, and topical forms are available. Parenteral ganciclovir is being used for induction and maintenance therapy against CMV retinitis in patients with acquired immune deficiency syndrome (AIDS).⁴⁵ Oral ganciclovir has been approved for maintenance therapy against CMV retinitis in patients whose active retinitis was resolved by IV induction therapy.⁴⁶ Oral ganciclovir is also approved in patients with advanced human immunodeficiency virus (HIV) infection for the prophylaxis against CMV retinitis.⁴⁶ Oral ganciclovir is poorly absorbed from the gastrointestinal tract.⁴⁷ The absolute bioavailability of oral ganciclovir under fasting conditions is about 5%, and about 6% to 9% when administered with food.⁴⁷ Thus, subsequently, the ganciclovir intravitreal implant (Vitrasert[®]) was developed and approved by the FDA in March 1996, for intraocular treatment of CMV retinitis in patients with AIDS.⁴⁸

Systemic ganciclovir is widely distributed to all tissues and crosses the placenta, without marked accumulation in any one type of tissue.^{47,49}



In addition, systemic ganciclovir has a good intraocular distribution. Following IV administration, subretinal concentrations reach between 0.87 to 2-fold higher concentrations than the plasma at 5.5 and 8 hours, respectively.⁴⁹ Concentrations of ganciclovir in the aqueous humor and the vitreous body have been reported to be 0.4 and 0.6 higher, than concurrent plasma concentrations at 2.5 hours following IV administration.⁴⁹

Ganciclovir has a similar antiviral activity to acyclovir against HSV-1 and HSV-2.^{38,40} Although it has lower antiviral activity against CMV when compared to that of acyclovir, intracellular concentrations of its active metabolite are higher.⁴⁰ In vitro, the mean effective dose of ganciclovir against HSV-1 and HSV-2 is 0.23 $\mu\text{g}/\text{mL}$.^{41,50,51} Several studies have reported on the required ganciclovir concentrations necessary to achieve 50% inhibition of viral activity (ID_{50}). The range for treatment against HSV-1 has been reported to be 0.2–2.0 $\mu\text{mol}/\text{L}$, while for HSV-2 this range has been reported to be 0.3–10.0 $\mu\text{mol}/\text{L}$.^{29,38} In contrast, the 50% inhibitory concentrations (IC_{50}) for CMV is 10.0 $\mu\text{mol}/\text{L}$, 8.0 $\mu\text{mol}/\text{L}$ for VZV, and 1.0 $\mu\text{mol}/\text{L}$ for EBV.⁴⁴ Further, ganciclovir has a ID_{50} value of 26–47 $\mu\text{mol}/\text{L}$ for adenoviruses.⁴⁴

The pharmacokinetics and efficacy of ganciclovir ophthalmic gel have been evaluated in preclinical studies. In an experimental model of HSK in rabbits,⁵² 0.1% ganciclovir ointment demonstrated antiviral activity. Castela et al⁵³ used ganciclovir ophthalmic gel in the same model, where the gel was prepared in Carbomer 934P (NF XVII, Transphyto SA, Clermont-Ferrand, France) at concentrations of 0.0125%, 0.05%, and 0.2%. The efficacy was compared against placebo and 3% acyclovir ophthalmic ointment. Both acyclovir and ganciclovir were found to reach higher levels in the cornea than in the aqueous humor. This higher penetration in the cornea was attributed to the small size of ganciclovir molecule, its high lipophilicity, and its high cellular affinity stemming from its endogenous structural nucleosides. All three ganciclovir gel concentrations effectively treated herpetic keratitis, without any reported ocular toxicity. In the same study by Castela et al,⁵³ ganciclovir was detected in the aqueous humor of healthy rabbits even four hours after the last topical administration of a 2% concentration. The fact that ganciclovir is retained and detected in the aqueous

humor for a prolonged period of time after the last topical administration, might be attributed to the slow diffusion of the drug through the cornea.

Although the ocular distribution and tissue concentration of ganciclovir ophthalmic gel 0.15% are similar to acyclovir 3% ointment, its systemic absorption is very low.⁵⁴ This shows the limited plasma diffusion of the drug and its lack of systematic toxicity.³¹ Pharmacokinetics studies of topical ganciclovir in 6 healthy volunteers,^{55,56} receiving ganciclovir 0.15% ophthalmic gel into each eye in 3-hour intervals for 12 hours demonstrated a mean concentration of ganciclovir in tears ranging from 0.92 to 6.86 $\mu\text{g}/\text{mL}$ and no ocular discomfort. This concentration is higher than the inhibitory concentrations for HSV-1. The wide range of intra- and inter-individual variations noted in the tears was attributed to reflex tearing during tear collection.

Topical drugs require an ideal balance between solubility and lipophilicity, in order to penetrate deeper into tissues. As such, highly lipophilic compounds are not able to penetrate the lipoidal corneal epithelial layer. Thus, due to the relatively hydrophilicity of ganciclovir, its tissue permeation is limited and it passes the cornea primarily by passive diffusion.^{57,58} Moreover, tight junctions between corneal epithelial cells limit paracellular diffusion, requiring a high concentration gradient across the corneal epithelium in order to achieve therapeutic concentrations in deeper corneal layers. Although lipophilic ganciclovir prodrugs have been developed using acid esters, poor aqueous solubility of these prodrugs has hampered their usage as topical or intravitreal agents.^{59,60} The features and properties of ganciclovir ophthalmic gel and acyclovir ophthalmic ointment are shown in Table 1.

The first antiviral agent idoxuridine suffered the same problem since poor aqueous solubility limited its topical use.⁶¹ Another drug, vidarabine, had fewer toxic effects, however it was also poorly soluble. Previous studies showed that the more lipophilicity, the lower solubility.^{59,60} Majumdar et al⁶² reported that the divaline acyclovir ester prodrug has greater solubility and corneal permeability relative to acyclovir.⁶³ Based on this data, the authors evaluated permeability of Val-ganciclovir, Val-val-ganciclovir, Tyr-Val-ganciclovir, and Val-Tyr-ganciclovir.⁶² They demonstrated seven- to eight-fold greater transcorneal

**Table 1.** Features and properties of ganciclovir ophthalmic gel and acyclovir ophthalmic ointment.

	Ganciclovir 0.15% ^{67–70,†}	Acyclovir 3% ^{67–70,*}	Trifluridine 1% ^{14,18,20}
Chemical name	9-[[2-hydroxy-1-(hydroxymethyl)ethoxy]methyl]guanine	9-((2-hydroxyethoxy)methyl)guanine	α,α,α -trifluorothymidine
Indication [†]	Treatment of Herpes simplex keratitis	Treatment of Herpes simplex keratitis	Treatment of Herpes simplex keratitis
Dosage and Administration	One drop in the affected eye(s) five times a day	1 cm ribbon of ointment, inside the lower conjunctival sac five times a day	One drop of solution onto the cornea of the affected eye every 2 hours while awake for a maximum daily dosage of nine drops
Contraindication	None	Patients with known hypersensitivity to acyclovir or valacyclovir	Patients who develop hypersensitivity reactions or chemical intolerance to trifluridine
Use in pregnancy	Category C	Category B3	Category C
Use in lactation	Not known	Does pass into breast milk	Should not be prescribed for nursing mothers unless the potential benefits outweigh the potential risks
Adverse events	Blurred vision, eye irritation, punctate keratitis, and conjunctival hyperemia	Transient mild stinging, superficial punctate keratopathy, mild hyperemia	Mild, transient burning or stinging upon instillation, palpebral edema, superficial punctate keratopathy

Notes: *Not available in United States. Available in Europe and other countries. [†]approved for epithelial dendritic keratitis in the United States and for herpetic keratitis in Europe.

permeability of Val-ganciclovir and Val-Val-ganciclovir as compared to ganciclovir.⁶² Further, their in vivo studies in a rabbit HSK model showed that 1% Val-val-ganciclovir was more effective than 1% triflurothymidine in controlling epithelial HSV keratitis, suggesting Val-val-ganciclovir as an ideal candidate for topical ophthalmic application in the treatment of HSK.

Clinical Trials

The safety and tolerability of topical ganciclovir 0.15% ophthalmic gel in acute herpetic keratitis setting has been evaluated in two separate phase I trials,^{56,64} and four randomized, multinational, single-masked, phase IIb or open-label, phase III comparative clinical trials.^{54,55,65–70} These studies are reported in the US FDA drug approval review.⁷¹

Three of these four multicenter trials were phase IIb trials conducted in Africa (study 1), Europe (study 2), and Pakistan (study 3). A fourth study was a phase III trial that stratified patients by dendritic or geographic ulcers (study 4) and was carried out in four European and African centers. The inclusion criteria were similar for all trials. Immunocompetent patients with a

clinical diagnosis of dendritic or geographic ulcers without a virological confirmation were included in these studies.^{28,29,54,65,72} Exclusion criteria included antiviral treatment during the previous 14 days, severe stromal keratitis, keratouveitis, previous corneal transplantation (in the affected eye), a secondary bacterial infection of the cornea or conjunctiva, recent ocular trauma, visual acuity < 20/100 in the unaffected eye, or known sensitivity to treatment.^{28,29,54,65,72}

The patients were randomized to separate groups either receiving five daily drops of ganciclovir ophthalmic gel or five applications of acyclovir 3% ointment. Double masking was impossible, as ganciclovir is an aqueous gel, while acyclovir is an ointment. All patients were treated until the ulcers were completely healed. In studies 1 and 3, patients were randomized to one of two ganciclovir strengths: 0.15% or 0.05%. Maximum treatment duration was established at 21 days for dendritic lesions and 35 days for geographic ulcers (Table 2).

Safety

In a randomized double-masked phase I clinical trial, ganciclovir ophthalmic gel 0.15% was administered



Table 2. Results from randomized, open label, three multicenter (Study I, II, IV), one single center (Study III) clinical trials.

	Study I ⁵²			Study II ⁵³			Study III ⁵⁴			Study IV ⁵⁵		
	GCV 0.15%	GCV 0.05%	ACV 3%	GCV 0.15%	GCV 0.05%	ACV 3%	GCV 0.15%	GCV 0.05%	ACV 3%	GCV 0.15%	GCV 0.15%	ACV 3%
No. of subjects	23	22	22	18	17	17	36	35	38	84	80	
Recovery at day 14 (%)	19 (82.6)	17 (77.3)	16 (72.7)	15 (83.3)	12 (70.6)	12 (70.6)	31 (86.1)	28 (80)	27 (71.1)	63 (88.7)	61 (91)	
Relapses by day 14(%)	1 (4.3)	1 (1.45)	3 (13.6)	0	1 (5.9)	1 (5.9)	0 (0)	2 (5.7)	3 (7.9)	NA	NA	
Time to healing in days (median)	7	7	8	6	7*	7*	6	4	7	7	7	
Withdrawals (%)	3 (13)	6 (27.3)	7 (31.8)	2 (11.1)	7 (41.2)*	7 (41.2)*	2 (5.56)	4 (11.4)	7 (21.1)*	9 (12.37)	7 (10.5)	
Blurred vision	13%	13.6%	13.6%	38.5%*	76.9%*	76.9%*	-	-	-	28.1%-45.7%	50.9%-63.6%	
Stinging/burning	17%	22.7%	45.4%	16%*	50%*	50%*	-	-	-	9.3%-21.43%	14.3%-26.42%	
SPK	13%	0%	1%	0	0	0	-	-	-	0	0	

Notes: *P < 0.05; †no. of patients.

Abbreviations: GCV, Ganciclovir; ACV, Acyclovir; SPK, Superficial punctate keratitis.

to one eye and the vehicle gel was administered to the other in 10 healthy volunteers. Both were applied 5 times daily for 7 days.⁶⁴ Before treatment, on the second and seventh day of treatment, subjective measures and ophthalmologic examination were performed. Overall, tolerance was good and no changes were observed in the physical examination between the visits. In a separate phase I trial, six healthy male volunteers instilled one dose of ganciclovir 0.15% ophthalmic gel into each eye at 3-hour intervals for 12 hours (total of 4 instillations).⁵⁶ Systemic absorption of ganciclovir ophthalmic gel 0.15% was found to be minimal with the total daily topical dose approximately 0.04% and 0.1% of the oral dose and IV doses, respectively, thus minimal systemic exposure is expected. Ganciclovir is designated by the FDA as pregnancy Category C and no controlled studies have been performed in pregnant women. Further, no data is available on possible secretion of ganciclovir in human milk. However, studies in rabbits and mice have shown that ganciclovir is both teratogenic and embryotoxic. Moreover, ganciclovir has been detected in the milk of laboratory animals, causing significant adverse effects in their offspring.

In the first clinical trial in patients with herpes simplex keratitis, performed between April 1990–May 1992, 67 eyes of 66 patients were treated with 0.15% (23 eyes), 0.05% (22 eyes) ganciclovir ophthalmic gel or 3% acyclovir ointment (22 eyes) five times daily.⁶⁷ The withdrawal rates due to poor tolerance were 13% in the 0.15% ganciclovir gel group, 27.3% in the 0.05% ganciclovir gel group, and 31.8% in the 3% acyclovir ointment group. These differences were not statistically significant. Stinging and burning was reported in 10 out of 22 patients receiving 3% acyclovir ointment, but only reported in 4 and 5 patients receiving 0.15% and 0.05% ganciclovir gel, respectively. Blurred vision and toxic superficial punctate keratitis did were not statistically significant between the treatment groups.

In the second trial, performed between December 1990–May 1992, 37 patients were divided to receive either 0.15% ganciclovir gel or 3% acyclovir ointment.^{54,55,68} More than 75% of the patients receiving acyclovir experienced blurred vision, as compared to less than 40% in patients receiving ganciclovir gel. Acyclovir caused burning and stinging in more than 50% of patients, whereas only 16.7% of patients



experienced these symptoms in the ganciclovir group. During the trial, investigators and study subjects were also asked to assess the tolerance of the drugs. All patients and investigators rated ganciclovir as excellent, while only 67% of the patients and 75% of the investigators rated acyclovir excellent.

In the third trial, performed between May 1991–October 1992, 109 patients were included.^{54,55,69} Patients were divided into three groups: 36 patients were treated with ganciclovir 0.15% gel, 35 patients were treated with ganciclovir 0.05% gel, and 38 patients were treated with acyclovir 3% ointment. The tolerability was satisfactory for all 3 treatment groups. One subject in the ganciclovir 0.15% group, 5 subjects in the ganciclovir 0.05% group, and 3 subjects in the acyclovir 3% group reported stinging and burning. Although lower concentration of ganciclovir caused more stinging and burning, the difference was not statistically significant. The number of superficial punctate keratitis cases that appeared or were exacerbated while receiving treatment was similar throughout all treatment groups. No hematological side effects were observed.

In the fourth and largest multicenter clinical trial, performed between September 1992–September 1994, 164 patients were enrolled at 28 study centers.^{54,55,70,72} Patients were given either ganciclovir 0.15% gel ($n = 84$) or acyclovir 3% ointment ($n = 80$) 5 times daily. Subjects in the ganciclovir 0.15% group tolerated the drug better than those in the acyclovir 3% group. Fewer patients (28.1%–45.7% of patients, range across visits through day 14) in the ganciclovir group reported blurring when compared to patients in the acyclovir group (50.9%–63.6% of patients, range across visits through day 14) at all time points ($P < 0.02$ at all time points except day 10 where $P = 0.056$). Average duration of blurring was significantly shorter in ganciclovir 0.15% group (164–301 seconds, range across visits through day 14) when compared to that of acyclovir 3% group (474–972 seconds, range across visits through day 14) at all time points, except for Day 14 for the ganciclovir 0.15% group. Fewer subjects reporting stinging or burning sensation in the ganciclovir 0.15% group ($P = 0.03$) at Day 14. However, duration of stinging and burning was not statistically significant between groups. In addition, the frequency of toxic superficial punctate keratitis was reduced by half in the ganciclovir 0.15% group as compared with the acyclovir group ($P = 0.03$ at day 10). Further, the

number of investigators, who considered ganciclovir as excellent based on a questionnaire, were significantly higher when compared with the acyclovir group ($P = 0.00006$ at all time points combined). Similarly, patients reported that the overall tolerability with ganciclovir 0.15% was more frequently considered excellent compared with acyclovir ($P = 0.0002$ at all time points combined). Taken together, ganciclovir exhibited lower rates of visual disturbances and toxic superficial punctate keratopathy (SPK). Moreover, ganciclovir caused less stinging/burning. Finally, the percentage of patients and investigators rating tolerability as excellent was significantly higher for ganciclovir.^{55,70}

Efficacy

The efficacy of topical ganciclovir ophthalmic gel 0.15% in the treatment of acute herpetic keratitis has been evaluated in preclinical animal models and in prospective randomized clinical trials.^{28,52–54,72,73}

Study I

Patients were treated with ganciclovir 0.15%, ganciclovir 0.05%, or acyclovir 3% 5 times daily until healing of the ulcer and then 3 times daily for 1 week. Twenty-three eyes received ganciclovir 0.15%, 22 eyes received acyclovir 3% ointment, and 22 eyes received ganciclovir 0.05%. All eyes were included in the intention-to-treat (ITT) analysis. The per protocol (PP) analysis included 59 eyes (20 in the ganciclovir 0.15% group, 18 in the acyclovir group, and 21 in the ganciclovir 0.05% group). The healing rate (in the ITT analysis) was 82.6% for the ganciclovir 0.15% group, 77.3% for the ganciclovir 0.05% group, and 72.7% for the acyclovir group. The median healing time was 7 days in the ganciclovir 0.15% and ganciclovir 0.05% groups and 8 days in the acyclovir group. The number of relapses was 1 in the ganciclovir 0.15% and ganciclovir 0.05% groups and 3 in the acyclovir group. In the ITT analyses, a tendency emerged in favor of ganciclovir 0.15% in comparison with ganciclovir 0.05% and a slightly greater efficacy of ganciclovir 0.05% compared with acyclovir 3%.^{29,31,55}

Study II

This study was conducted at 4 study centers located in France (Brest, Clermont-Ferrand), Switzerland (Lausanne), and the United Kingdom (Bristol) from



December 1990 through May 1992.^{55,68} Thirty seven patients enrolled in this study in which 19 patients were treated with ganciclovir 0.15% gel and 18 patients were treated with acyclovir 3% ophthalmic ointment. Patients were given either ganciclovir or acyclovir 5 times daily until healing of the ulcer and then 3 times daily for 1 week. It was found that ganciclovir 0.15% was at least as effective as acyclovir 3% in healing the ulcers. Healing rate was 83.3% in the ganciclovir 0.15% group and 70.6% in the acyclovir 3% group at day 14. The median time of healing was 6 and 7 days for ganciclovir 0.15% and 7 acyclovir 3%, respectively. There were no recurrences for ganciclovir 0.15% and 1 for acyclovir 3%. While only 35 patients were included in the efficacy analysis, all 37 patients receiving the test agents were included in the tolerance analysis.^{29,31,55}

Study III

One hundred and nine patients were enrolled in this study. It was conducted from May 1991 to October 1992 at one study center in Karachi, Pakistan, ganciclovir 0.15% was found to be at least as effective as acyclovir 3%.^{55,69} Thirty six patients were treated with ganciclovir 0.15%, 35 patients were treated with ganciclovir 0.05%, and 38 patients were treated with acyclovir 3%. In the ITT population, the healing rate was 86.1% with ganciclovir 0.15%, 80.0% with ganciclovir 0.05%, and 71.05% with acyclovir 3%. The median time to healing was 7 days with acyclovir, 6 days with ganciclovir 0.15%, and 4 days with ganciclovir 0.05%. There were 3 relapses with acyclovir, compared to 0 with ganciclovir 0.15% and 2 with ganciclovir 0.05%. Additionally, 21.05% of acyclovir patients, 11.4% of ganciclovir 0.05% patients, and 5.6% of ganciclovir 0.15% patients withdrew from the study due to worsening of the ulcer.^{29,31,55}

Study IV

This study included 164 patients at 28 European centers. It was conducted from September 1992 through September 1994. The study centers were in the following locations: Aulnay-Sous-Bois, Bamako, Birmingham, Bobigny, Bordeaux (2 centers), Brest, Bristol, Chambéry, Chateaulin, Clermont-Ferrand (5 sites), Cournon, Dublin, Le Golfe Juan, Lesneven,

London, Marseille, Palaiseau, Paris (2 sites), Sousse, Tananarivo, Thiers, and Toulon (Transphyto 1994; Hoh et al 1996).^{54,55,70,72} Patients were given either ganciclovir 0.15% or acyclovir 3% 5 times daily until healing of the ulcer and then 3 times daily for 1 week. The clinical study results showed that ganciclovir 0.15% was as at least as effective as acyclovir 3% for the treatment of acute herpetic keratitis. The efficacy results for dendritic epithelial ulcers of the ITT and PP analyses were similar. In the ITT dendritic epithelial ulcer groups, the percent healed on day 14 were 88.7% in the ganciclovir 0.15% group and 91% in the acyclovir 3% group, and in the PP group, the percent healed were 92.2% and 93.6% for ganciclovir and acyclovir groups respectively. The median time to healing was 7 days for the ITT analysis for both treatment groups, and 6 days and 7 days for the PP analysis for the ganciclovir 0.15% and acyclovir 3% groups, respectively. None of these results were statistically significant.

In summary, ganciclovir 0.15% ophthalmic gel showed a comparable efficacy to acyclovir 3% ophthalmic ointment in all four studies mentioned above. Moreover, ganciclovir 0.15% gel was associated with a lower relapse rate when compared to that of acyclovir. There were no statistically significant differences between healing rates of ganciclovir and acyclovir (83%–89% with ganciclovir and 71%–92% with acyclovir) Since study I reported the number of eyes treated, whereas studies II–IV reported the number of patients treated, and patient recruitment goals were not met, it was impossible to calculate the statistical significance between treatments. However, a pooled analysis of intent-to-treat patients in the three studies revealed a statistically significant difference in treatment success (ulcer resolution at end-point) between ganciclovir 0.15% (85%) and acyclovir 3% (71%) ($P = 0.04$).^{29,31,55}

Acyclovir resistance has been a concern given the widespread use of acyclovir for treatment and long-term prophylaxis. Since acyclovir and ganciclovir are similar in structure, cross-resistance is a growing problem especially in immunocompromised patients.⁷⁴ The prevalence of acyclovir-resistant HSV isolates is low in the immunocompetent population (0.1%–0.98%).^{75,76} In comparison, resistant isolates are more common in the diverse immunocompromised patients (3.92%–14.3%).^{74–77}



In a study of 173 immunocompetent patients with HSV keratitis by Duan et al,⁷⁸ 11 (6.4%) had acyclovir-resistant isolates. Ten of the 11 had mutations in the viral thymidine kinase gene conferring the resistant phenotype. Another study analyzed 40 HSV-1 isolates from 35 patients in whom thirteen of the cases had keratitis and found that one isolate was resistant whereas three had reduced sensitivity.⁷⁹ The principal mechanism of resistance to ganciclovir is the decreased ability to form the active triphosphate moiety. Mutations in the viral DNA polymerase have also been reported to confer viral resistance to ganciclovir.⁴⁷

Patient Preference

The patient preference and tolerability were studied in those four single-blinded randomized studies mentioned above. Because there was relatively few number of individuals in each trial, pooled data from all these trials were reviewed in FDA drug approval review. Local tolerability was found to be better in the recipients of ganciclovir ophthalmic gel 0.15%, than recipients of acyclovir ointment 3%, when assessed by study investigator (79% vs. 44%; $P < 0.001$) and by the patient (75% vs. 44%; $P < 0.001$) in study 4. In study 2, these numbers were 82% vs. 19%; $P < 0.001$ and 61% vs. 19%; $P < 0.05$, respectively.^{28,29,54,65,80} The major advantage of ganciclovir over acyclovir is its aqueous formulation. This feature let the drug be tolerated better than acyclovir. It caused less stinging and burning and most importantly less blurring of vision, improving tolerability significantly.

Place in Therapy

The treatment and prophylaxis of herpetic keratitis is expensive.⁸¹ Approximately 17 million US dollars are spent annually to treat new and recurrent herpetic cases. While significant progress has been made in the treatment of ocular herpes infection during the last two decades, the toxicity of some antiviral agents still remains as a major problem. Epithelial keratitis is most often treated with topical and/or oral antiviral therapy. Idoxuridine, iododesoxycytidine, and vidarabine are very toxic and are no longer in use. Trifluridine 1%, until recently, the only topical agent available in the United States, has very high toxicity as well, while acyclovir and ganciclovir are less toxic agents, do to the higher selectivity. However,

acyclovir ophthalmic ointment 3% is not commercially available in the United States. Ganciclovir has been approved in the United States since 2009 and is indicated for epithelial dendritic ulcers only. However, in Europe and other countries the indication for ganciclovir is not specified.

Currently, acyclovir 3% ophthalmic ointment and ganciclovir ophthalmic gel 0.15% are being used as a first line treatment for the treatment of acute epithelial herpetic keratitis outside the United States. Ganciclovir 0.15% ophthalmic gel is recommended as one drop five times daily until corneal ulcer heals, followed by one drop three times daily for 7 days.⁴³ Although acyclovir ointment has an excellent systemic safety profile, it suffers from two major drawbacks: epithelial toxicity and poor patient tolerance due to blurring and stinging. Randomized clinical trials demonstrated that ganciclovir ophthalmic gel 0.15% caused less visual disturbances and toxicity among patients when compared to acyclovir 3% ointment. The efficacy of ganciclovir was analyzed in a meta-analysis reported in Cochrane database.²⁶ There was no difference in terms of odds ratio in the efficacy against herpetic epithelial keratitis between acyclovir 3% and ganciclovir 0.15%.

Topical ganciclovir ophthalmic gel 0.15% has a good tolerance, prolonged corneal contact time, a similar tonicity to tears, and a long and stable shelf life. Its pH is adjusted to a physiological level. It has a good penetration into the aqueous humor. It is as effective as acyclovir but at a much lower concentration. Given these characteristics, ganciclovir ophthalmic gel has a promising place in the treatment of acute epithelial herpetic keratitis (Table 3). Long-term prophylaxis with ganciclovir in patients with recurrent herpetic keratitis has not been evaluated. Recurrence of herpetic keratitis in the corneal graft is a challenging

Table 3. Benefits of ganciclovir ophthalmic gel.

Broad spectrum against herpes viridae
Selective efficacy on infected cells with virus
Aqueous humor penetration
Long shelf life
Physiologic pH
Prolonged corneal contact time
Good tolerability (No blurred vision, stinging, and burning)
No systemic side effect



problem. The failure rate is about 50% following corneal transplantation in patients with herpetic keratitis. Low-dose oral acyclovir is effective in preventing recurrent herpetic keratitis. However, it does not appear to be cost-effective.⁸¹ Topical use of ganciclovir in those patients may potentially prevent systemic side effects of oral antiviral therapy. Moreover the solid aqueous humor penetration of ganciclovir may be beneficial for the treatment and prophylaxis of herpetic keratitis. However, additional studies are needed to demonstrate the long-term safety and efficacy of ganciclovir in the treatment of herpetic keratitis.

Conclusions

Herpetic keratitis is a major cause of blindness in the world.⁷ It is a significant community health problem and is associated with a major burden on the economy. Particularly, treatment of recurrent cases poses a dilemma to ophthalmologists.

Ganciclovir 0.15% ophthalmic gel is an effective, safe, and well-tolerated treatment for acute dendritic herpetic keratitis. Local tolerance is better than acyclovir, hence increasing patient compliance. It is commercially available in over 30 countries in Europe since 1996 and is approved by FDA in United States since 2009. Randomized multi-center clinical trials demonstrated that ganciclovir ophthalmic gel 0.15% is as effective as acyclovir in the treatment of acute epithelial herpetic keratitis.^{29,54,55,67-70} However, due to its formulation it is less toxic than acyclovir. It also has a prolonged contact time with the cornea and causes less blurring and stinging, improving patient tolerance. Given its equivalent efficacy with acyclovir and lower toxicity and side effects, ganciclovir ophthalmic gel is a valuable and important addition to the armamentarium in the treatment of acute epithelial herpetic keratitis.

Funding

This research was supported by a Career Development Grant K08-ER020575 (PH) from the National Institutes of Health, Bethesda, Maryland. PH is also the recipient of a Career Development Award from research to prevent blindness.

Author contributions

Conceived and designed the experiments: AS, PH. Analysed the data: AS, PH. Wrote the first draft of

the manuscript: AS, PH. Contributed to the writing of the manuscript: AS, PH. Agree with manuscript results and conclusions: AS, PH. Jointly developed the structure and arguments for the paper: AS, PH. Made critical revisions and approved final version: AS, PH. All authors reviewed and approved of the final manuscript.

Competing Interests

None of the authors have financial disclosure.

Disclosures and Ethics

As a requirement of publication author(s) have provided to the publisher signed confirmation of compliance with legal and ethical obligations including but not limited to the following: authorship and contributorship, conflicts of interest, privacy and confidentiality and (where applicable) protection of human and animal research subjects. The authors have read and confirmed their agreement with the icmje authorship and conflict of interest criteria. The authors have also confirmed that this article is unique and not under consideration or published in any other publication, and that they have permission from rights holders to reproduce any copyrighted material. Any disclosures are made in this section. The external blind peer reviewers report no conflicts of interest. Provenance: the authors were invited to submit this paper.

References

- Holland EJ, Brilakis HS, Schwartz GS. Herpes Simplex Keratitis. In: Krachmer JH, Mannis MJ, Holland EJ, editors. *Cornea*: Elsevier Mosby, 2005;1.
- Holland EJ, Schwartz GS. Classification of herpes simplex virus keratitis. *Cornea*. 1999;18(2):144-54.
- Stevens JG, Nesburn AB, Cook ML. Latent herpes simplex virus from trigeminal ganglia of rabbits with recurrent eye infection. *Nat New Biol*. 1972;235(59):216-7.
- Obara Y, Furuta Y, Takasu T, et al. Distribution of herpes simplex virus types 1 and 2 genomes in human spinal ganglia studied by PCR and in situ hybridization. *J Med Virol*. 1997;52(2):136-42.
- Dawson CR, Togni B. Herpes simplex eye infections: clinical manifestations, pathogenesis and management. *Surv Ophthalmol*. 1976;21(2):121-35.
- Pepose J, Keadle T, Morrison L. Ocular herpes simplex: changing epidemiology, emerging disease patterns, and the potential of vaccine prevention and therapy. *Am J Ophthalmol*. 2006;141(3):547-77.
- Liesegang TJ. Herpes simplex virus epidemiology and ocular importance. *Cornea*. 2001;20(1):1-13.
- Liesegang TJ. A community study of ocular herpes simplex. *Curr Eye Res*. 1991;10 Suppl:111-5.
- Liesegang TJ. Epidemiology of ocular herpes simplex. Natural history in Rochester, Minn, 1950 through 1982. *Arch Ophthalmol*. 1989;107(8):1160-5.



10. Liesegang TJ, Melton LJ 3rd, Daly PJ, Ilstrup DM. Epidemiology of ocular herpes simplex. Incidence in Rochester, Minn, 1950 through 1982. *Arch Ophthalmol*. 1989;107(8):1155–9.
11. Liesegang TJ. Classification of herpes simplex virus keratitis and anterior uveitis. *Cornea*. 1999;18(2):127–43.
12. Klein RJ. Pathogenetic mechanisms of recurrent herpes simplex virus infections. *Arch Virol*. 1976;51(1–2):1–13.
13. Maudgal PC, Van Damme B, Missotten L. Corneal epithelial dysplasia after trifluridine use. *Graefes Arch Clin Exp Ophthalmol*. 1983;220(1):6–12.
14. Naito T, Shiota H, Mimura Y. Side effects in the treatment of herpetic keratitis. *Curr Eye Res*. 1987;6(1):237–9.
15. Heidelberger C, Parsons DG, Remy DC. Syntheses of 5-Trifluoromethyluracil and 5-Trifluoromethyl-2'-Deoxyuridine. *J Med Chem*. 1964;7:1–5.
16. Kaufman HE, Maloney ED, Uotila MH. Antiviral agents. *Invest Ophthalmol*. 1964;3:512–6.
17. Kaufman HE, Heidelberger C. Therapeutic antiviral action of 5-trifluoromethyl-2'-deoxyuridine in herpes simplex keratitis. *Science*. 1964;145(3632):585–6.
18. Trifluridine (viroptic) for herpetic keratitis. *Med Lett Drugs Ther*. 1980;22(11):46–8.
19. Gilbert P, Work K. Trifluorothymidine in the treatment of herpes simplex corneal ulcers. A clinical evaluation. *Acta Ophthalmol (Copenh)*. 1980;58(1):117–20.
20. Hyndiak RA, Charlin RE, Alprent TV, Schultz RO. Trifluridine in resistant human herpetic keratitis. *Arch Ophthalmol*. 1978;96(10):1839–41.
21. Kaufman HE, Varnell ED, Centifanto-Fitzgerald YM, Sanitato JG. Virus chemotherapy: antiviral drugs and interferon. *Antiviral Res*. 1984;4(6):333–8.
22. Kaufman HE, Varnell ED, Thompson HW. Trifluridine, cidofovir, and penciclovir in the treatment of experimental herpetic keratitis. *Arch Ophthalmol*. 1998;116(6):777–80.
23. la Lau C, Oosterhuis JA, Versteeg J, et al. Acyclovir and trifluorothymidine in herpetic keratitis: a multicentre trial. *Br J Ophthalmol*. 1982;66(8):506–8.
24. la Lau C, Oosterhuis JA, Versteeg J, et al. Aciclovir and trifluorothymidine in herpetic keratitis. Preliminary report of a multicentered trial. *Doc Ophthalmol*. 1981;50(2):287–90.
25. Pavan-Langston D, Nelson DJ. Intraocular penetration of trifluridine. *Am J Ophthalmol*. 1979;87(6):814–8.
26. Wilhelmus KR. Therapeutic interventions for herpes simplex virus epithelial keratitis. Cochrane database of systematic reviews (Online). 2008;1:CD002898.
27. Wilhelmus KR. Antiviral treatment and other therapeutic interventions for herpes simplex virus epithelial keratitis. Cochrane database of systematic reviews (Online). 2010;12:CD002898.
28. Colin J. Ganciclovir ophthalmic gel, 0.15%: a valuable tool for treating ocular herpes. *Clin Ophthalmol*. 2007;1(4):441–53.
29. Croxtall JD. Ganciclovir ophthalmic gel 0.15%: in acute herpetic keratitis (dendritic ulcers). *Drugs*. 2011;71(5):603–10.
30. Wilhelmus KR. The treatment of herpes simplex virus epithelial keratitis. *Trans Am Ophthalmol Soc*. 2000;98:505–32.
31. Tabbara KF, Al Balushi N. Topical ganciclovir in the treatment of acute herpetic keratitis. *Clin Ophthalmol*. 2010;4:905–12.
32. O'Brien JJ, Campoli-Richards DM. Acyclovir. An updated review of its antiviral activity, pharmacokinetic properties and therapeutic efficacy. *Drugs*. 1989;37(3):233–309.
33. Perrotet N, Csajka C, Pascual M, et al. Population pharmacokinetics of ganciclovir in solid-organ transplant recipients receiving oral valganciclovir. *Antimicrob Agents Chemother*. 2009;53(7):3017–23.
34. Reusser P. Oral valganciclovir: a new option for treatment of cytomegalovirus infection and disease in immunocompromised hosts. *Expert Opin Investig Drugs*. 2001;10(9):1745–53.
35. McGavin JK, Goa KL. Ganciclovir: an update of its use in the prevention of cytomegalovirus infection and disease in transplant recipients. *Drugs*. 2001;61(8):1153–83.
36. Noble S, Faulds D. Ganciclovir. An update of its use in the prevention of cytomegalovirus infection and disease in transplant recipients. *Drugs*. 1998;56(1):115–46.
37. Follansbee SE, Stempien MJ, Buhles WC. Oral ganciclovir for cytomegalovirus infections. *Adv Exp Med Biol*. 1996;394:93–103.
38. Faulds D, Heel RC. Ganciclovir. A review of its antiviral activity, pharmacokinetic properties and therapeutic efficacy in cytomegalovirus infections. *Drugs*. 1990;39(4):597–638.
39. Fletcher CV, Balfour HH Jr. Evaluation of ganciclovir for cytomegalovirus disease. *DICP*. 1989;23(1):5–12.
40. Crumacker CS. Ganciclovir. *N Engl J Med*. 1996;335(10):721–9.
41. Trousdale MD, Goldschmidt PL, Nobrega R. Activity of ganciclovir against human adenovirus type-5 infection in cell culture and cotton rat eyes. *Cornea*. 1994;13(5):435–9.
42. De Clercq E, Naesens L, De Bolle L, et al. Antiviral agents active against human herpesviruses HHV-6, HHV-7 and HHV-8. *Rev Med Virol*. 2001;11(6):381–95.
43. Zirgan package insert. <http://www.bausch.com/en/ECP/Our-Products/Rx-Pharmaceuticals/Rx-Pharmaceuticals-ECP/Zirgan-ECP>; v. 2011.
44. Matthews T, Boehme R. Antiviral activity and mechanism of action of ganciclovir. *Rev Infect Dis*. 1988;10 Suppl 3:S490–4.
45. Biron KK. Antiviral drugs for cytomegalovirus diseases. *Antiviral Res*. 2006;71(2–3):154–63.
46. Stewart MW. Optimal management of cytomegalovirus retinitis in patients with AIDS. *Clin Ophthalmol*. 2010;4:285–99.
47. Roche Laboratories—Cytovene IV/Cytovene Complete Product Information, Feb 2010:3. Available at: <http://www.gene.com/gene/products/information/cytovene/pdf/pi.pdf>. Accessed Dec 21, 2011.
48. Teoh SC, Ou X, Lim TH. Intravitreal ganciclovir maintenance injection for cytomegalovirus retinitis: efficacy of a low-volume, intermediate-dose regimen. *Ophthalmology*. 2011.
49. AHFS Drug Information, 2004.
50. Smee DF, Campbell NL, Matthews TR. Comparative anti-herpesvirus activities of 9-(1,3-dihydroxy-2-propoxymethyl)guanine, acyclovir, and two 2'-fluoropyrimidine nucleosides. *Antiviral Res*. 1985;5(5):259–67.
51. Smee DF, Martin JC, Verheyden JP, Matthews TR. Anti-herpesvirus activity of the acyclic nucleoside 9-(1,3-dihydroxy-2-propoxymethyl)guanine. *Antimicrob Agents Chemother*. 1983;23(5):676–82.
52. Trousdale MD, Nesburn AB, Willey DE, Taaid H. Efficacy of BW759 (9-[[2-hydroxy-1(hydroxymethyl)ethoxy]methyl]guanine) against herpes simplex virus type 1 keratitis in rabbits. *Curr Eye Res*. 1984;3(8):1007–15.
53. Castela N, Vermerie N, Chast F, et al. Ganciclovir ophthalmic gel in herpes simplex virus rabbit keratitis: intraocular penetration and efficacy. *J Ocul Pharmacol*. 1994;10(2):439–51.
54. Colin J, Hoh HB, Easty DL, et al. Ganciclovir ophthalmic gel (Virgan; 0.15%) in the treatment of herpes simplex keratitis. *Cornea*. 1997;16(4):393–9.
55. Colin J. Ganciclovir ophthalmic gel, 0.15%: a valuable tool for treating ocular herpes. *Clin Ophthalmol*. 2007;1(4):441–53.
56. Clirofta. 1994b. Cinétique du ganciclovir dans les larmes, après instillations multiples d'un gel ophtalmique de ganciclovir 0,15%, Virgan, chez le volontaire sain. Nice, France: Rapport clinique Virgan/F-94-02. Dossier d'AMM.
57. Majumdar S, Tirucherai GS, Pal D, Mitra AK. Functional differences in nucleoside and nucleobase transporters expressed on the rabbit corneal epithelial cell line (SIRC) and isolated rabbit cornea. *AAPS Pharm Sci*. 2003;5(2):E15.
58. Majumdar S, Gunda S, Mitra A. Functional expression of a sodium dependent nucleoside transporter on rabbit cornea: Role in corneal permeation of acyclovir and idoxuridine. *Curr Eye Res*. 2003;26(3–4):175–83.
59. Tirucherai GS, Mitra AK. Effect of hydroxypropyl beta cyclodextrin complexation on aqueous solubility, stability, and corneal permeation of acyl ester prodrugs of ganciclovir. *AAPS Pharm Sci Tech*. 2003;4(3):E45.
60. Dias CS, Anand BS, Mitra AK. Effect of mono- and di-acylation on the ocular disposition of ganciclovir: physicochemical properties, ocular bioreversion, and antiviral activity of short chain ester prodrugs. *J Pharm Sci*. 2002;91(3):660–8.
61. Lass JH, Langston RH, Foster CS, Pavan-Langston D. Antiviral medications and corneal wound healing. *Antiviral Res*. 1984;4(3):143–57.



62. Majumdar S, Nashed YE, Patel K, et al. Dipeptide monoester ganciclovir prodrugs for treating HSV-1-induced corneal epithelial and stromal keratitis: in vitro and in vivo evaluations. *J Ocul Pharmacol Ther.* 2005;21(6):463–74.
63. Anand B, Nashed Y, Mitra A. Novel dipeptide prodrugs of acyclovir for ocular herpes infections: Bioreversion, antiviral activity and transport across rabbit cornea. *Curr Eye Res.* 2003;26(3–4):151–63.
64. Clirophtha. 1994a. Evaluation de la tolérance locale chez le volontaire sain, après instillations multiples d'un gel ophtalmique de ganciclovir 0,15%, Virgan. Nice, France: Rapport clinique Virgan/F-94-01. Dossier d'AMM.
65. Foster SC. Ganciclovir gel—a new topical treatment for herpetic keratitis. *US Ophthalmol Rev.* 2007;3:52–6.
66. Kaufman HE. Ganciclovir: a promising topical antiviral gel for herpetic keratitis. *Expert Rev Ophthalmol.* 2009;4(4):367–75.
67. Transphyto. 1993a. Etude clinique comparative multicentrique de l'effet de l'instillation de GV 550 dans l'herpes cornéen superficiel. Clermont-Ferrand, France: Rapport clinique No. 42-2.GV 550/02.90. Dossier d'AMM.
68. Transphyto. 1993b. Etude clinique comparative multicentrique de l'effet de l'instillation de GV 550 dans l'herpes cornéen superficiel. Clermont-Ferrand, France: Rapport clinique No. 44.GV 550/12.90-46.GV 550/07.90. Dossier d'AMM.
69. Transphyto. 1993c. Etude clinique comparative randomisée en simple insu de l'effet de l'instillation de ganciclovir gel ophtalmique dans le traitement de l'herpes cornéen superficiel. Clermont-Ferrand, France: Rapport clinique No. 47.GV 550/09.90. Dossier d'AMM.
70. Transphyto. 1994. Etude multicentrique comparative de l'effet de l'instillation de Virgan dans l'herpes cornéen superficiel. Clermont-Ferrand, France: Rapport clinique No. 64GV 550/04.92-66GV 550/06.92. Dossier d'AMM.
71. US Food and Drug Administration 022211 Medical Review(s): ganciclovir ophthalmic gel 0.15%. Available at: http://www.accessdata.fda.gov/drug_satfda_docs/nda/2009/022211_zirgan_toc.cfm. Accessed Dec 21, 2011.
72. Hoh HB, Hurley C, Claoue C, et al. Randomised trial of ganciclovir and acyclovir in the treatment of herpes simplex dendritic keratitis: a multicentre study. *Br J Ophthalmol.* 1996;80(2):140–3.
73. Shaw MM, Gurr WK, Watts PA, et al. Ganciclovir and penciclovir, but not acyclovir, induce apoptosis in herpes simplex virus thymidine kinase-transformed baby hamster kidney cells. *Antivir Chem Chemother.* 2001;12(3):175–86.
74. Gilbert C, Bestman-Smith J, Boivin G. Resistance of herpesviruses to antiviral drugs: clinical impacts and molecular mechanisms. *Drug Resist Updat.* 2002;5(2):88–114.
75. Bacon TH, Levin MJ, Leary JJ, et al. Herpes simplex virus resistance to acyclovir and penciclovir after two decades of antiviral therapy. *Clin Microbiol Rev.* 2003;16(1):114–28.
76. Christophers J, Clayton J, Craske J, et al. Survey of resistance of herpes simplex virus to acyclovir in northwest England. *Antimicrob Agents Chemother.* 1998;42(4):868–72.
77. Ziyaeyan M, Alborzi A, Japoni A, et al. Frequency of acyclovir-resistant herpes simplex viruses isolated from the general immunocompetent population and patients with acquired immunodeficiency syndrome. *Int J Dermatol.* 2007;46(12):1263–6.
78. Duan R, de Vries RD, Osterhaus AD, et al. Acyclovir-resistant corneal HSV-1 isolates from patients with herpetic keratitis. *J Infect Dis.* 2008;198(5):659–63.
79. Charles SJ, Gray JJ. Ocular herpes simplex virus infections: reduced sensitivity to acyclovir in primary disease. *Br J Ophthalmol.* 1990;74(5):286–8.
80. Drug Approval Package Zirgan (ganciclovir ophthalmic gel) 0.15% Company: Sirion Therapeutics, Inc. Application No. 022211. Approval Date: Sep 15, 2009. http://www.accessdata.fda.gov/drugsatfda_docs/nda/2009/022211_zirgan_toc.cfm. 2011.
81. Lairson DR, Begley CE, Reynolds TF, Wilhelmus KR. Prevention of herpes simplex virus eye disease: a cost-effectiveness analysis. *Arch Ophthalmol.* 2003;121(1):108–12.