



DIGITAL ACCESS TO SCHOLARSHIP AT HARVARD

Gastrointestinal Stromal Tumor: A Rare Abdominal Tumor

The Harvard community has made this article openly available.
[Please share](#) how this access benefits you. Your story matters.

Citation	Shaheen, Shagufta, and Achuta K. Guddati. 2013. Gastrointestinal stromal tumor: a rare abdominal tumor. <i>Case Reports in Oncology</i> 6(1): 148-153.
Published Version	doi:10.1159/000350061
Accessed	February 19, 2015 12:06:42 PM EST
Citable Link	http://nrs.harvard.edu/urn-3:HUL.InstRepos:11181010
Terms of Use	This article was downloaded from Harvard University's DASH repository, and is made available under the terms and conditions applicable to Other Posted Material, as set forth at http://nrs.harvard.edu/urn-3:HUL.InstRepos:dash.current.terms-of-use#LAA

(Article begins on next page)

Gastrointestinal Stromal Tumor: A Rare Abdominal Tumor

Shagufta Shaheen Achuta K. Guddati

Department of Internal Medicine, Massachusetts General Hospital, Harvard Medical School, Harvard University, Boston, Mass., USA

Key Words

Gastrointestinal stromal tumor · Abdominal tumor · CD117 · Rare tumor · Size · Gastric tumor

Abstract

Gastrointestinal stromal tumors (GISTs) are rare abdominal tumors which arise from the interstitial cells of Cajal in the gastrointestinal tract. Gastric GISTs are the most commonly seen GIST tumors and may grow to a very large size. They are often associated with abdominal pain, anorexia and weight loss. Most of them can be detected by CT. These tumors have been found to harbor mutations in CD117 which causes constitutional activation of the tyrosine kinase signaling pathway and is considered to be pathognomic. Tyrosine kinase inhibitors such as imatinib have revolutionized the treatment of these tumors, which are otherwise resistant to conventional chemotherapy and radiotherapy. Although surgical resection is the mainstay of treatment, tyrosine kinase inhibitors have been useful in prolonging the recurrence-free survival of these patients. Resistance to imatinib has been reported in GISTs with specific mutations. We present a case of gastric GIST which grew to a very large size and was associated with abdominal pain and weight loss. It was successfully resected and the patient was commenced on imatinib therapy.

Introduction

Gastrointestinal stromal tumors (GISTs) are mesenchymal tumors that may arise from any part of the gastrointestinal tract. GISTs have been shown to originate from the interstitial cells of Cajal, which are located in the submucosal and myenteric plexus of the gastrointestinal tract [1–3]. GISTs are rare tumors and comprise less than 1% of all gastrointestinal tumors, and it is estimated that up to 6,000 new cases are diagnosed in the US every year [4, 5]. This likely represents an underestimation as many smaller-sized GISTs may go undetected [6, 7]. They are rarely detected in children and present with metastasis in adults over the

Dr. Achuta Kumar Guddati, MD, PhD
Massachusetts General Hospital
50 Fruit Street
Boston, MA 02114 (USA)
E-Mail aguddati@partners.org

age of 50 years [8]. An equal distribution in gender has been observed though there have been reports of a male preponderance [9]. GISTs present as round masses with clearly defined borders arising from the submucosal layer. Based on their histology, they are divided into eight subtypes, but all of them stain for the stem cell factor receptor (CD117/KIT) [10]. GISTs which do not express KIT may express alpha-type platelet-derived growth factor receptor (PDGFRA), protein kinase C theta (PKC- θ) and discovered on GIST-1 (DOG-1) [11–13]. Malignancies such as melanoma, mastocytoma, Ewing's sarcoma, lung small cell carcinoma, etc. may also express KIT, and their presence in the gastrointestinal tract likely represents metastases and they need to be distinguished from GISTs [14–16]. An autosomal dominant pattern of inheritance has been described in familial GIST [17–19]. Mutations involving succinate dehydrogenase subunits B, C and D have been observed in the familial form of GIST [20]. GISTs have been observed in the small intestine of patients with neurofibromatosis type-1 [21, 22]. A separate inherited syndrome consisting of paragangliomas and GISTs has also been described [23].

Gastric GISTs are known to reach sizes exceeding 40 cm and have a better prognosis than intestinal GISTs of similar size and mitotic rate [10]. Extraintestinal GISTs (EGISTs) have been reported in the gall bladder, urinary bladder and rectovaginal septum [24–26]. EGISTs are considered to be metastases but paradoxically exhibit a better overall prognosis [27]. CT scans and endoscopic ultrasound are commonly used diagnostic modalities.

Case Summary

The patient is a 41-year-old male with a past medical history significant for type 1 diabetes, gastroesophageal reflux disease and hypertension. He presented in our gastroenterology clinic with abdominal discomfort, distention and unintentional weight loss of 24 pounds over the past 2 months. The patient underwent a CT scan of the abdomen which revealed a 20-cm epigastric mass with several areas of necrosis suggestive of hemangioma of the liver. The patient was scheduled to be seen in the general surgery clinic, but his symptoms worsened and he presented to our hospital with a fever of 102 F and worsening abdominal pain. A repeated CT scan of the abdomen revealed a large heterogeneous mass measuring 31 × 10 × 26 cm, predominantly solid and containing small cystic areas in the right abdomen and pelvis. The patient was admitted to the medical service where he became hypotensive and anemic with a significant hematocrit drop. The patient was hemodynamically stabilized and underwent an arterial embolization of the gastroduodenal artery to control the hemorrhage. Thereafter, the patient underwent resection of the tumor en bloc with the stomach, gastrectomy, Billroth II reconstruction and wedge biopsy of segment six of the liver. The patient tolerated the procedure well, with no significant post-operative complications. On gross examination, the tumor measured 34 cm in its greatest dimension, with notable hemorrhage and necrosis (fig. 1). Microscopic examination and immunohistochemical staining confirmed the tumor to be a GIST with tumor cells staining positive for CD117 (fig. 2a, b). Segment 6 of the liver was reported as metastatic GIST. The patient was started on chemotherapy with imatinib.

Discussion

The most common site of occurrence for GISTs is the stomach (60%) followed by the small intestine (30%) [28]. It is difficult to distinguish extraintestinal GISTs from metastases.

The mainstay of management of GISTs is surgical resection when possible. Regional lymphadenectomy is not advocated as GISTs have not been observed to metastasize to lymph nodes [29, 30]. However, there is a very high risk of recurrence if there is intraperitoneal rupture or spillage during surgery [31]. The 5-year overall survival in patients with complete resection has been estimated to be superior compared to that of patients with incomplete resection (42 vs. 95%) [32]. Tyrosine kinase inhibitors such as imatinib have been successfully used to treat GISTs [33]. KIT mutations cause constitutive activation of tyrosine kinase and the most common mutations are duplications in the 3' region of exon 11 of the KIT gene. Mutations involving codons 557–558 and point deletions carry a worse prognosis [34]. Imatinib resistance has been noted in patients with PDGFRA mutations in the absence of KIT mutations [35]. Chromosomal losses at 1p, 14q (gastric GISTs), 15q (intestinal GISTs) and 22q have been observed, and the type of mutations have been noted to correlate with the response to imatinib [36, 37]. Mitotic rate, tumor size and location have been utilized for predicting the risk of progression in completely resected primary GISTs [38, 39].

Considering that GISTs may reach large sizes and therefore making surgical resection risky, neoadjuvant therapy with tyrosine kinase inhibitors has been utilized to reduce their size. This strategy has been used to reduce surgical morbidity and improve the operability of these tumors [40, 41]. However, the mutational status (KIT vs. PDGFRA) of the tumor largely determines the effect of preoperative tyrosine kinase inhibitor therapy and monitoring of response by PET scan is advised. A duration of 4–6 months of neoadjuvant therapy with continuous monitoring has been recommended [42, 43]. Up to 66% of patients with high-risk GISTs who have undergone resection experience recurrence [44]. The American College of Surgeons Oncology Group (ACOSOG) Z9000 clinical trial showed that patients with PDGFRA mutations had the best outcomes with 90% recurrence-free survival at 3 years. The ACOSOG Z9001 trial involved adjuvant therapy with 400 mg of imatinib and resulted in 98% recurrence-free survival [45]. The dosing and the type of tyrosine kinase inhibitors that are optimal for the patient's treatment depend on the type of mutation [46–48]. Abdominal CT, MRI and PET scans have been used for follow-up and for monitoring the progression of the disease [49]. The follow-up frequency has ranged from months to years and depends on the risk profile of the initial disease [50].

Acknowledgement

The study has not been presented in any form in any meeting or forum and is not under consideration in any other journal. The authors declare that there was no funding for this study.

Disclosure Statement

The authors declare no conflict of interest.

References

- 1 Mazur MT, Clark HB: Gastric stromal tumors. Reappraisal of histogenesis. *Am J Surg Pathol* 1983;7:507–519.

- 2 Walker P, Dvorak AM: Gastrointestinal autonomic nerve (GAN) tumor. Ultrastructural evidence for a newly recognized entity. *Arch Pathol Lab Med* 1986;110:309–316.
- 3 Robinson TL, Sircar K, Hewlett BR, Chorneyko K, Riddell RH, Huizinga JD: Gastrointestinal stromal tumors may originate from a subset of CD34-positive interstitial cells of Cajal. *Am J Pathol* 2000;156:1157–1163.
- 4 Judson I, Demetri G: Advances in the treatment of gastrointestinal stromal tumours. *Ann Oncol* 2007;18(suppl 10):x20–x24.
- 5 Corless CL, Heinrich MC: Molecular pathobiology of gastrointestinal stromal sarcomas. *Annu Rev Pathol* 2008;3:557–586.
- 6 Kawanowa K, Sakuma Y, Sakurai S, et al: High incidence of microscopic gastrointestinal stromal tumors in the stomach. *Hum Pathol* 2006;37:1527–1535.
- 7 Agaimy A, Wunsch PH, Hofstaedter F, et al: Minute gastric sclerosing stromal tumors (GIST tumorlets) are common in adults and frequently show c-KIT mutations. *Am J Surg Pathol* 2007;31:113–120.
- 8 Nowain A, Bhakta H, Pais S, Kanel G, Verma S: Gastrointestinal stromal tumors: clinical profile, pathogenesis, treatment strategies and prognosis. *J Gastroenterol Hepatol* 2005;20:818–824.
- 9 Miettinen M, Sarlomo-Rikala M, Lasota J: Gastrointestinal stromal tumors: recent advances in understanding of their biology. *Hum Pathol* 1999;30:1213–1220.
- 10 Miettinen M, Lasota J, Sobin LH: Gastrointestinal stromal tumors of the stomach in children and young adults: a clinicopathologic, immunohistochemical, and molecular genetic study of 44 cases with long-term follow-up and review of the literature. *Am J Surg Pathol* 2005;29:1373–1381.
- 11 Sevinc A, Camci C, Yilmaz M, Buyukhatipoglu H: The diagnosis of C-kit negative GIST by PDGFRA staining: clinical, pathological, and nuclear medicine perspective. *Onkologie* 2007;30:645–648.
- 12 Motegi A, Sakurai S, Nakayama H, Sano T, Oyama T, Nakajima T: PKC theta, a novel immunohistochemical marker for gastrointestinal stromal tumors (GIST), especially useful for identifying KIT-negative tumors. *Pathol Int* 2005;55:106–112.
- 13 West RB, Corless CL, Chen X, et al: The novel marker, DOG1, is expressed ubiquitously in gastrointestinal stromal tumors irrespective of KIT or PDGFRA mutation status. *Am J Pathol* 2004;165:107–113.
- 14 Montone KT, van Belle P, Elenitsas R, Elder DE: Proto-oncogene c-kit expression in malignant melanoma: protein loss with tumor progression. *Mod Pathol* 1997;10:939–944.
- 15 Arber DA, Tamayo R, Weiss LM: Paraffin section detection of the c-kit gene product (CD117) in human tissues: value in the diagnosis of mast cell disorders. *Hum Pathol* 1998;29:498–504.
- 16 Miettinen M, Sobin LH, Sarlomo-Rikala M: Immunohistochemical spectrum of GISTs at different sites and their differential diagnosis with a reference to CD117 (KIT). *Mod Pathol* 2000;13:1134–1142.
- 17 Nishida T, Hirota S, Taniguchi M, et al: Familial gastrointestinal stromal tumours with germline mutation of the KIT gene. *Nat Genet* 1998;19:323–324.
- 18 Chompret A, Kannengiesser C, Barrois M, et al: PDGFRA germline mutation in a family with multiple cases of gastrointestinal stromal tumor. *Gastroenterology* 2004;126:318–321.
- 19 Kleinbaum EP, Lazar AJ, Tamborini E, et al: Clinical, histopathologic, molecular and therapeutic findings in a large kindred with gastrointestinal stromal tumor. *Int J Cancer* 2008;122:711–718.
- 20 Matyakhina L, Bei TA, McWhinney SR, et al: Genetics of carney triad: recurrent losses at chromosome 1 but lack of germline mutations in genes associated with paragangliomas and gastrointestinal stromal tumors. *J Clin Endocrinol Metab* 2007;92:2938–2943.
- 21 Takazawa Y, Sakurai S, Sakuma Y, et al: Gastrointestinal stromal tumors of neurofibromatosis type I (von Recklinghausen's disease). *Am J Surg Pathol* 2005;29:755–763.
- 22 Miettinen M, Fetsch JF, Sobin LH, Lasota J: Gastrointestinal stromal tumors in patients with neurofibromatosis 1: a clinicopathologic and molecular genetic study of 45 cases. *Am J Surg Pathol* 2006;30:90–96.
- 23 Carney JA, Stratakis CA: Familial paraganglioma and gastric stromal sarcoma: a new syndrome distinct from the Carney triad. *Am J Med Genet* 2002;108:132–139.
- 24 Peerlinck ID, Irvin TT, Sarsfield PT, Harington JM: GIST (gastro-intestinal stromal tumour) of the gallbladder: a case report. *Acta Chir Belg* 2004;104:107–109.
- 25 Mekni A, Chelly I, Azzouz H, et al: Extragastric stromal tumor of the urinary wall bladder: case report and review of the literature. *Pathologica* 2008;100:173–175.
- 26 Zhang W, Peng Z, Xu L: Extragastric stromal tumor arising in the rectovaginal septum: report of an unusual case with literature review. *Gynecol Oncol* 2009;113:399–401.
- 27 Reith JD, Goldblum JR, Lyles RH, Weiss SW: Extragastric (soft tissue) stromal tumors: an analysis of 48 cases with emphasis on histologic predictors of outcome. *Mod Pathol* 2000;13:577–585.
- 28 Edge SB; American Joint Committee on Cancer: *AJCC Cancer Staging Manual*. New York, Springer, 2010, xiv, p 648.
- 29 Pierie JP, Choudry U, Muzikansky A, Yeap BY, Souba WW, Ott MJ: The effect of surgery and grade on outcome of gastrointestinal stromal tumors. *Arch Surg* 2001;136:383–389.
- 30 Gold JS, Gonen M, Gutierrez A, et al: Development and validation of a prognostic nomogram for recurrence-free survival after complete surgical resection of localised primary gastrointestinal stromal tumour: a retrospective analysis. *Lancet Oncol* 2009;10:1045–1052.

- 31 Rutkowski P, Nowecki ZI, Michej W, et al: Risk criteria and prognostic factors for predicting recurrences after resection of primary gastrointestinal stromal tumor. *Ann Surg Oncol* 2007;14:2018–2027.
- 32 Novitsky YW, Kercher KW, Sing RF, Heniford BT: Long-term outcomes of laparoscopic resection of gastric gastrointestinal stromal tumors. *Ann Surg* 2006;243:738–745, discussion 737–745.
- 33 Lopes LF, Bacchi CE: Imatinib treatment for gastrointestinal stromal tumour (GIST). *J Cell Mol Med* 2010;14:42–50.
- 34 Martin J, Poveda A, Llombart-Bosch A, et al: Deletions affecting codons 557–558 of the c-KIT gene indicate a poor prognosis in patients with completely resected gastrointestinal stromal tumors: a study by the Spanish Group for Sarcoma Research (GEIS). *J Clin Oncol* 2005;23:6190–6198.
- 35 Corless CL, Schroeder A, Griffith D, et al: PDGFRA mutations in gastrointestinal stromal tumors: frequency, spectrum and in vitro sensitivity to imatinib. *J Clin Oncol* 2005;23:5357–5364.
- 36 Gunawan B, von Heydebreck A, Sander B, et al: An oncogenetic tree model in gastrointestinal stromal tumours (GISTs) identifies different pathways of cytogenetic evolution with prognostic implications. *J Pathol* 2007;211:463–470.
- 37 Heinrich MC, Owzar K, Corless CL, et al: Correlation of kinase genotype and clinical outcome in the North American Intergroup Phase III Trial of imatinib mesylate for treatment of advanced gastrointestinal stromal tumor: CALGB 150105 Study by Cancer and Leukemia Group B and Southwest Oncology Group. *J Clin Oncol* 2008;26:5360–5367.
- 38 Fletcher CD, Berman JJ, Corless C, et al: Diagnosis of gastrointestinal stromal tumors: a consensus approach. *Hum Pathol* 2002;33:459–465.
- 39 Miettinen M, Lasota J: Gastrointestinal stromal tumors: pathology and prognosis at different sites. *Semin Diagn Pathol* 2006;23:70–83.
- 40 Fiore M, Palassini E, Fumagalli E, et al: Preoperative imatinib mesylate for unresectable or locally advanced primary gastrointestinal stromal tumors (GIST). *Eur J Surg Oncol* 2009;35:739–745.
- 41 Catania V, Consoli A, Cavallaro A, Liardo RL, Malaguarnera M: The neo-adjuvant treatment in gastrointestinal stromal tumor. *Eur Rev Med Pharmacol Sci* 2010;14:727–730.
- 42 Hohenberger P, Wardelmann E: Surgical considerations for gastrointestinal stroma tumor (in German). *Chirurg* 2006;77:33–40.
- 43 Eisenberg BL, Smith KD: Adjuvant and neoadjuvant therapy for primary GIST. *Cancer Chemother Pharmacol* 2011;67(suppl 1):S3–S8.
- 44 Nilsson B, Bumming P, Meis-Kindblom JM, et al: Gastrointestinal stromal tumors: the incidence, prevalence, clinical course, and prognostication in the pre-imatinib mesylate era – a population-based study in western Sweden. *Cancer* 2005;103:821–829.
- 45 Corless CL, Ballman KV, Antonescu C, et al: Relation of tumor pathologic and molecular features to outcome after surgical resection of localized primary gastrointestinal stromal tumor (GIST): results of the intergroup phase III trial ACOSOG Z9001. *J Clin Oncol* 2010;28(suppl.):abstr. 10006.
- 46 Debiec-Rychter M, Sciot R, Cesne AL, et al: KIT mutations and dose selection for imatinib in patients with advanced gastrointestinal stromal tumours. *Eur J Cancer* 2006;42:1093–1103.
- 47 Kontogianni-Katsarou K, Dimitriadis E, Lariou C, Kairi-Vassilatou E, Pandis N, Kondi-Paphiti A: KIT exon 11 codon 557/558 deletion/insertion mutations define a subset of gastrointestinal stromal tumors with malignant potential. *World J Gastroenterol* 2008;14:1891–1897.
- 48 Patel S, Zalberg JR: Optimizing the dose of imatinib for treatment of gastrointestinal stromal tumours: lessons from the phase 3 trials. *Eur J Cancer* 2008;44:501–509.
- 49 Reichardt P, Blay JY, Mehren M: Towards global consensus in the treatment of gastrointestinal stromal tumor. *Expert Rev Anticancer Ther* 2010;10:221–232.
- 50 Casali PG, Blay JY: Gastrointestinal stromal tumours: ESMO Clinical Practice Guidelines for diagnosis, treatment and follow-up. *Ann Oncol* 2010;21(suppl 5):v98–v102.

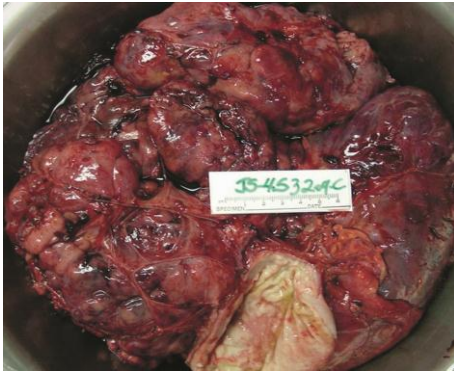

Fig. 1. Excised tumor with a part of the stomach. The gastric mucosa can be seen in the lower part of the specimen.

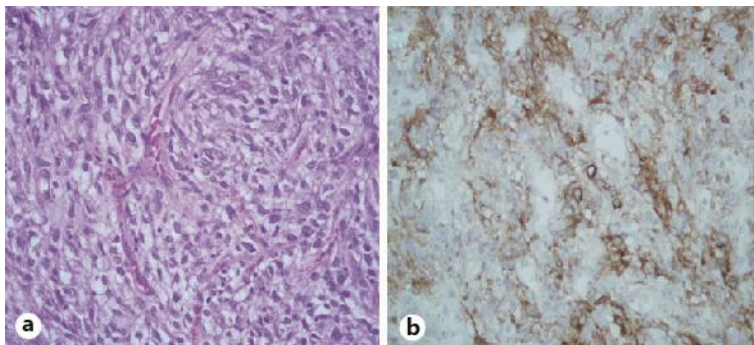


Fig. 2. **a** Hematoxylin and eosin staining of the tumor shows a mildly eosinophilic cytoplasm. **b** CD117 staining with a membranous distribution is shown.