



DIGITAL ACCESS TO SCHOLARSHIP AT HARVARD

Feasibility of real time integration of high-resolution scar images with invasive electrograms in electro-anatomical mapping system in patients undergoing ventricular tachycardia ablation

The Harvard community has made this article openly available. [Please share](#) how this access benefits you. Your story matters.

Citation	Roujol, Sébastien, Tamer A Basha, Alex Y Tan, Elad Anter, Alfred E Buxton, Mark E Josephson, and Reza Nezafat. 2013. Feasibility of real time integration of high-resolution scar images with invasive electrograms in electro-anatomical mapping system in patients undergoing ventricular tachycardia ablation. <i>Journal of Cardiovascular Magnetic Resonance</i> 15(Suppl 1): E94.
Published Version	doi:10.1186/1532-429X-15-S1-E94
Accessed	February 19, 2015 11:59:31 AM EST
Citable Link	http://nrs.harvard.edu/urn-3:HUL.InstRepos:11181145
Terms of Use	This article was downloaded from Harvard University's DASH repository, and is made available under the terms and conditions applicable to Other Posted Material, as set forth at http://nrs.harvard.edu/urn-3:HUL.InstRepos:dash.current.terms-of-use#LAA

(Article begins on next page)

POSTER PRESENTATION

Open Access

Feasibility of real time integration of high-resolution scar images with invasive electrograms in electro-anatomical mapping system in patients undergoing ventricular tachycardia ablation

Sébastien Roujol*, Tamer A Basha, Alex Y Tan, Elad Anter, Alfred E Buxton, Mark E Josephson, Reza Nezafat

From 16th Annual SCMR Scientific Sessions
San Francisco, CA, USA. 31 January - 3 February 2013

Background

Ventricular tachycardia (VT) ablation is generally guided by invasive mapping of the left ventricle (LV) using electro-anatomical voltage mapping (EAM) to identify the VT substrate [1]. Late gadolinium enhancement (LGE) MRI allows excellent visualization of the scar. Heterogeneous area in LGE images has been shown to correlate with the VT substrate in animal models of VT. Retrospective studies in patients have also correlated the LGE signal enhancement to low voltage in EAM maps. However, current clinical EAM platform such as the Carto3 (Biosense Webster) does not allow integration of LGE images for facilitating the VT ablation. In this study, we described a workflow to integrate scar geometry extracted from high-resolution 3D LGE images with EAM.

Methods

The proposed workflow for LGE scar integration into the Carto3 system is described in figure 1. A 3D high-resolution LGE sequence ($1.3 \times 1.3 \times 1.3 \text{ mm}^3$ at 1.5T) [2] is first acquired prior to the VT ablation procedure. Endocardial and epicardial contours are manually drawn on LGE data using an in-house software developed in Matlab (Mathworks, Nattick MA). All remaining LGE data processing steps are performed automatically. Two 3D mesh geometries are generated by interpolation of the drawn contours. A 3D binary volume representing the epicardial surface is also generated from the epicardial mesh. Each endocardial mesh points are projected to the binary epicardial surface by using a rapid minimal distance search to the nearest point on the binary representation of the

epicardial surface. The transmural intensity is then extracted for each endocardial mesh point and can be used to measure spatial characteristics of the scar such as the scar thickness or the scar transmural level. The scar spatial characteristic of each endocardial mesh point is then color coded and the overall endocardial mesh is saved into the VTK format (Kitware Inc). This file is then imported into the Carto3 system before the ablation procedure and is fused with EAM using the landmark registration tool available into the Carto3 system. The feasibility of the proposed workflow is demonstrated in a VT patient undergoing a high resolution LGE exam followed by a VT ablation.

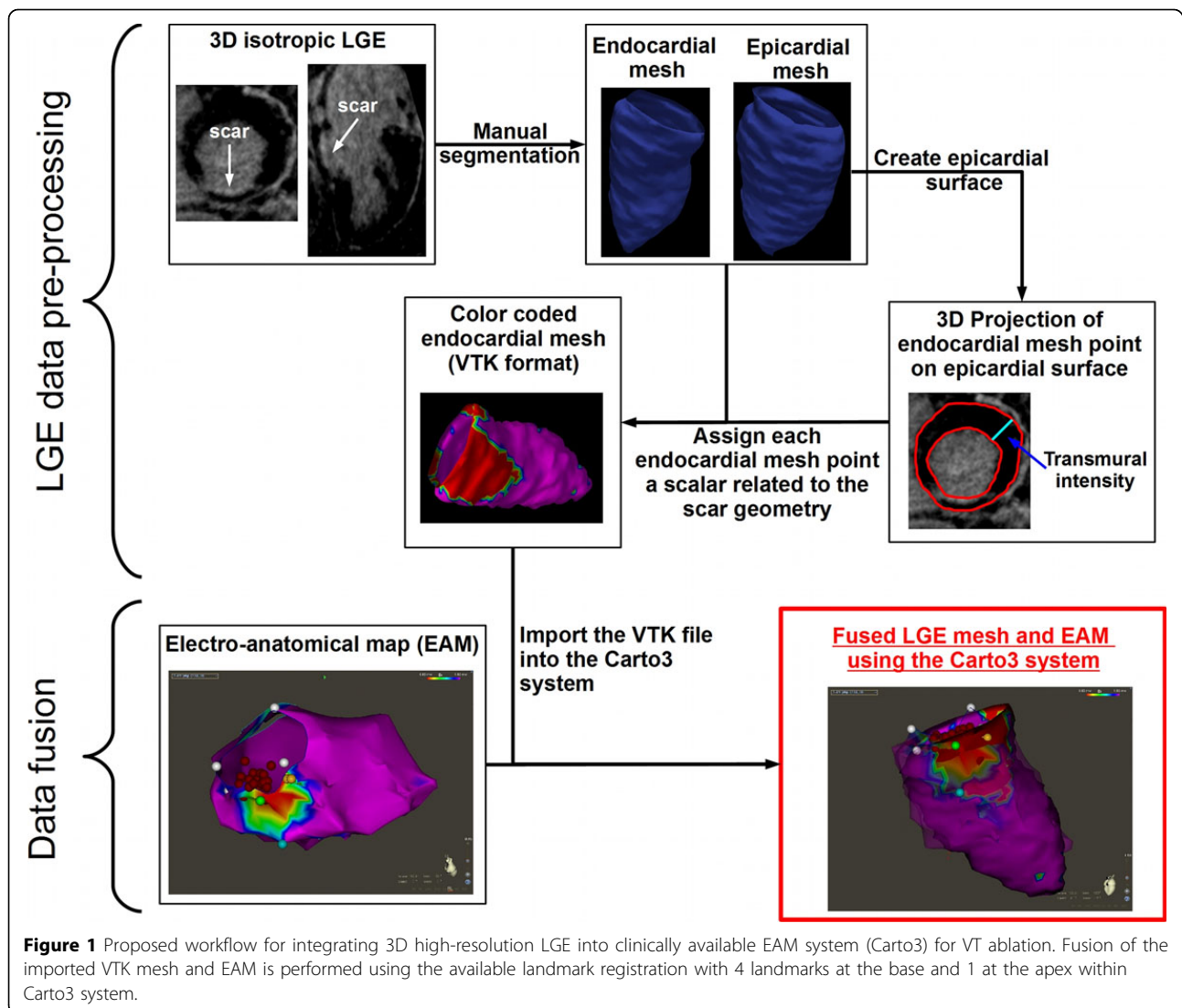
Results

Using the proposed methodology, a VTK file representing the average transmural intensity of LGE was successfully generated (Figure 1). The LGE data processing was performed in ~20min (manual contour delineation ~20min and all remaining steps ~10s). The resulting VTK file was imported into the Carto3 system before ablation and successfully merged with EAM (Figure 1).

Conclusions

Real time integration of scar from high-resolution 3D LGE into the Carto3 system is now feasible which allows visualization of LGE scar, EAM voltage map and catheter location in real-time. Further clinical validation is needed to investigate the potential benefit of real time LGE integration for VT ablation guidance.

Medicine, BIDMC / Harvard Medical School, Boston, MA, USA



Funding

NIH:R01EB008743-01A2.

Published: 30 January 2013

References

1. Josephson.: *Circulation* 1978.
2. Akcakaya.: *Radiology* 2012.

doi:10.1186/1532-429X-15-S1-E94

Cite this article as: Roujol et al.: Feasibility of real time integration of high-resolution scar images with invasive electrograms in electro-anatomical mapping system in patients undergoing ventricular tachycardia ablation. *Journal of Cardiovascular Magnetic Resonance* 2013 15(Suppl 1):E94.

Submit your next manuscript to BioMed Central and take full advantage of:

- Convenient online submission
- Thorough peer review
- No space constraints or color figure charges
- Immediate publication on acceptance
- Inclusion in PubMed, CAS, Scopus and Google Scholar
- Research which is freely available for redistribution

Submit your manuscript at
www.biomedcentral.com/submit

