



# DIGITAL ACCESS TO SCHOLARSHIP AT HARVARD

## Occupational Asthma and Contact Dermatitis in a Spray Painter after Introduction of an Aziridine Cross-Linker.

The Harvard community has made this article openly available.  
[Please share](#) how this access benefits you. Your story matters.

<b>Citation</b>	Leffler, Christopher T. and Donald K. Milton. 1999. Occupational asthma and contact dermatitis in a spray painter after introduction of an aziridine cross-linker. Environmental Health Perspectives 107(7): 599-601.
<b>Published Version</b>	<a href="https://doi.org/10.1289/ehp.99107599">doi:10.1289/ehp.99107599</a>
<b>Accessed</b>	February 19, 2015 1:17:59 AM EST
<b>Citable Link</b>	<a href="http://nrs.harvard.edu/urn-3:HUL.InstRepos:4595270">http://nrs.harvard.edu/urn-3:HUL.InstRepos:4595270</a>
<b>Terms of Use</b>	This article was downloaded from Harvard University's DASH repository, and is made available under the terms and conditions applicable to Other Posted Material, as set forth at <a href="http://nrs.harvard.edu/urn-3:HUL.InstRepos:dash.current.terms-of-use#LAA">http://nrs.harvard.edu/urn-3:HUL.InstRepos:dash.current.terms-of-use#LAA</a>

*(Article begins on next page)*



HARVARD SCHOOL OF PUBLIC HEALTH

## Occupational Asthma and Contact Dermatitis in a Spray Painter after Introduction of an Aziridine Cross-Linker

Christopher T. Leffler and Donald K. Milton

Occupational Health Program, Department of Environmental Health, Harvard School of Public Health, Boston, Massachusetts, USA

A 23-year-old spray painter developed contact dermatitis and respiratory difficulty characterized by small airways obstruction shortly after the polyfunctional aziridine cross-linker CX-100 began to be used in his workplace as a paint activator. The symptoms resolved after he was removed from the workplace and was treated with inhaled and topical steroids. Painters may have an increased risk of asthma due to exposure to a variety of agents, such as isocyanates, alkyd resins, and chromates. This case illustrates the importance of using appropriate work practices and personal protective equipment to minimize exposure. Occupational asthma is diagnosed by a history of work-related symptoms and exposure to known causative agents. The diagnosis is confirmed by serial pulmonary function testing or inhalational challenge testing. The risk of asthma attributable to occupational exposures is probably underappreciated due to underreporting and to inappropriate use of narrow definitions of exposure in epidemiologic studies of attributable risk. *Key words:* aziridine, contact dermatitis, occupational asthma, personal protective equipment, spray painting. *Environ Health Perspect* 107:599–601 (1999). [Online 16 June 1999] <http://ehpnet1.niehs.nih.gov/docs/1999/107p599-601/leffler/abstract.html>

### Case Presentation

A 23-year-old spray painter developed dermatitis and difficulty breathing after a new paint additive began to be used in his workplace in late December 1992. The rash began on his hands and progressed to his forearms, legs, and neck. The initial diagnosis was tinea corporis, and then asteototic dermatitis with nummular lesions. In January 1993, he was given nasal beclomethasone for congestion and an inhaler for breathing difficulties.

In February 1993, the patient was treated for bronchitis. By March, the rash was worse and he was given an albuterol inhaler for continued wheezing. He also had several episodes of eye irritation and redness and some periorbital and unilateral facial swelling.

During a 2-week vacation in July, the patient needed the bronchodilator less often. The rash on his hand appeared unchanged, but he noted improvement in the pruritis and in the back of his neck and legs.

In August 1993, the patient was referred to occupational medicine for the dermatitis. He brought material safety data sheets for water-based low-bake enamel paints. The new paint additive was a polyfunctional aziridine cross-linker, CX-100 (1). At this time, the patient was using diphenhydramine, inhaled albuterol, and topical triamcinolone. He had a scaly erythematous fissured rash on the dorsum of the hands, and palmar, forearm, and

facial erythema. An erythematous, scaly area extended over the posterior neck and upper back, and he had an intertriginous rash under the abdominal skin fold and an erythematous rash with circumscribed, raised edges on the scrotum and upper thighs. The patient's legs had erythematous papules and confluent areas of dermatitis. His nasal mucosa was boggy and pink, with a milky-colored discharge. There were bilateral expiratory wheezes throughout the lung fields, and his peak expiratory flow rate was 710 L/min. The diagnosis was a delayed hypersensitivity contact dermatitis, probably due to the aziridine cross-linker. Occupational asthma was considered because of the relation of symptoms to exposure onset and his reduced symptoms during a vacation, even if changes were not noted on weekends.

While working, the patient's forced vital capacity (FVC) was 4.7 L (97% of predicted). His forced expiratory volume in the first second (FEV<sub>1</sub>) was 3.74 L (87% of predicted). The ratio of FEV<sub>1</sub> to FVC was 0.79. The patient's midexpiratory flow was 3.13 L/sec (62% of predicted). After the patient used bronchodilators, his FEV<sub>1</sub> was unchanged, but the midexpiratory flow rate increased by 19%. This pattern was consistent with mild small airways disease. The patient had a 5% cross-shift drop in the peak expiratory flow rate on workdays. After

he was removed from the workplace, the corresponding peak flow rates rose.

By September, the patient had been out of work for 1 week. His dermatitis had improved and his lungs were clear. He then left this job permanently.

In October, the patient was given a methacholine challenge test that showed a provocative concentration resulting in a 20% drop in the FEV<sub>1</sub> (PC<sub>20</sub>) of 0.5 mg/mL (with < 8 mg/mL considered diagnostic of hyperreactive airways). The patient's dermatitis was resolved in all areas but the hands. He used a bronchodilator in the morning for chest tightness and cough and triamcinolone two puffs twice per day; he used fluocinonide cream for his hands.

In late October, the patient was prescribed triamcinolone cream and gloves at night for a vesicular eruption on his fingers. He discontinued inhaled steroids in late 1993 because of improvement. By April 1994, the rash on the right hand had resolved, but his left hand had a small lichenified, excoriated area. He used a bronchodilator three mornings per week and after exercise.

**Past medical and occupational history.** The patient denied childhood skin or respiratory problems and had never smoked. He noticed tears in his eyes when he was around cats. His identical twin got hives after bee stings.

The patient first worked in auto shops doing body work and painting. Then, as a technical student for 2 years, he spray-painted and refinished furniture. His most recent job (for 4 years) involved spray-painting furniture on an overhead conveyer belt, wearing a solvent respirator without eye protection. He stood between the furniture and the exhaust vent when spraying the back of each piece.

The painters added activator to the paint in a small room with a wall fan. They

Address correspondence to D.K. Milton, 665 Huntington Avenue, Boston, MA 02115 USA. Telephone: (617) 432-3324. Fax: (617) 432-0219. E-mail: dmilton@hohp.harvard.edu

Received 22 March 1999; accepted 22 April 1999.

wore rubber gloves when available, but no respiratory protection.

## Discussion

This patient, who had worked as a spray painter, experienced asthma and dermatitis shortly after beginning work with a new aziridine cross-linker. Aziridines are three-membered ring compounds with one nitrogen and include propyleneimine, ethyleneimine, and polyfunctional aziridines (2). Polyfunctional aziridine (PFA) compounds are used as hardeners in industry and are synthesized from two components (Figure 1). The first is an aziridine, either ethyleneimine or propyleneimine. The second component is a multifunctional acrylate such as trimethylolpropane triacrylate (TMPTA) or pentaerythritol triacrylate (2). The specific PFA hardener in this case, polyfunctional aziridine cross-linker CX-100, is a copolymer of propyleneimine and TMPTA (1). The cross-linker is reportedly not contaminated with free TMPTA (1). PFA hardeners may be contaminated with free *N,N*-dimethylethanolamine and propyleneimine (2).

Mono- and polyfunctional aziridines have both irritating and sensitizing properties. Ethyleneimine (C<sub>2</sub>H<sub>5</sub>N), commonly termed "aziridine," is irritating to eyes, skin, and mucous membranes. Ethyleneimine vapors can cause swelling of the face, mouth, eyelids, and throat. Ethyleneimine may cause delayed upper and lower respiratory tract irritation, conjunctivitis, vomiting, coughing (3), pulmonary edema, laryngeal edema, and secondary bronchial pneumonia. Fatal ethyleneimine intoxication has been reported (2) and may follow rapid skin absorption. Ethyleneimine is a skin sensitizer, which causes allergic contact dermatitis (2).

Propyleneimine alone has not been reported to cause allergic reactions (2). Although propyleneimine or a related hardener was suspected of causing six cases of bronchiolitis obliterans organizing pneumonia (BOOP) (2), the clinical features of this case were more suggestive of asthma, as noted below.

The aziridine cross-linker is a potent skin irritant and may cause contact sensitization. Closely related compounds have been implicated as causative agents in contact dermatitis from dental mold compounds. Skin sensitization to the cross-linker can be demonstrated with patch testing (1,2). In two recent reports (2,4), PFA hardeners were associated with allergic contact dermatitis in four patients, occupational asthma in four patients, and both conditions in an additional three patients. Three patients were painters, and one of these was a spray painter with asthma (2). Immunologically mediated occupational

asthma was confirmed with specific bronchoprovocation tests.

Taken together, epidemiologic studies suggest a trend toward an increased risk of asthma in painters, specifically spray painters. A Singapore case-control study identified no increase in risk of asthma in painters (5). A surveillance program in the United Kingdom concluded that the asthma rate was elevated in all painters and that spray painters had a rate of occupational asthma 30 times that of the general population (6). Male Swedish painters and laquerers had a nonsignificant trend toward an increase in asthma mortality, with a standardized mortality ratio of 1.31 and a 95% confidence interval (CI) of 0.54–2.09 (7). Kogevinas et al. (8) reported a trend toward an increased risk of asthma in both spray painters (odds ratio = 4.83; CI, 0.92–25.39) and non-spray painters. The effect measures were higher for spray painters than for other painters when bronchial reactivity was included in the case definition, but the sample sizes were small. A subsequent study from New Zealand did not report an increased risk of wheezing in either group of painters, but spray painters exhibited a trend toward increased bronchial hyperresponsiveness (9).

Painters may be exposed to a variety of other agents that can cause occupational asthma, including isocyanates, alkyd resins, and chromates (10). Perhaps the most common exposures that may cause asthma in painters are diisocyanates such as toluene diisocyanate, isophorone diisocyanate, hexamethylene diisocyanate (HDI), and prepolymer of HDI (10). In one surveillance program, isocyanates were the reported causal agent in 22.2% of occupational asthma, and 28% of isocyanate-induced cases occurred in painters (6). The case described here involved exposure to toluene diisocyanate, which causes bronchial asthma, skin irritation, and allergic eczema. In this case, the symptom onset coincided with exposure to another agent, but it is possible that long-term exposure to diisocyanates was a contributory sensitizing factor. The mean latency in those who have isocyanate-associated asthma between starting work and symptom onset is 7 years (11).

The importance of occupational exposures as causes of asthma is underappreciated. Estimates from surveillance studies (6,12) are low because physicians often do not ask about or report an occupational component. Community-based cross-sectional studies offer somewhat higher estimates (8,9), but because of narrowly defined exposures, the attributable risks must still be regarded as lower bounds (13). A clinic-based case-control study found that the attributable risk of asthma due to manufacturing or service work

was 33% (5). A health maintenance organization-based prospective study of adult-onset asthma, which examined both the potential occupational exposures and the relation of symptoms to the workplace, found that occupational exposure accounted for 21% of clinically significant adult-onset asthma cases (14).

In many instances, immunologically mediated occupational asthma causes prolonged disability due to chronic airway inflammation (15). The improvement in respiratory function in the current case may have resulted from the relatively short duration of exposure. Early workplace removal is associated with a better prognosis (15). By 2

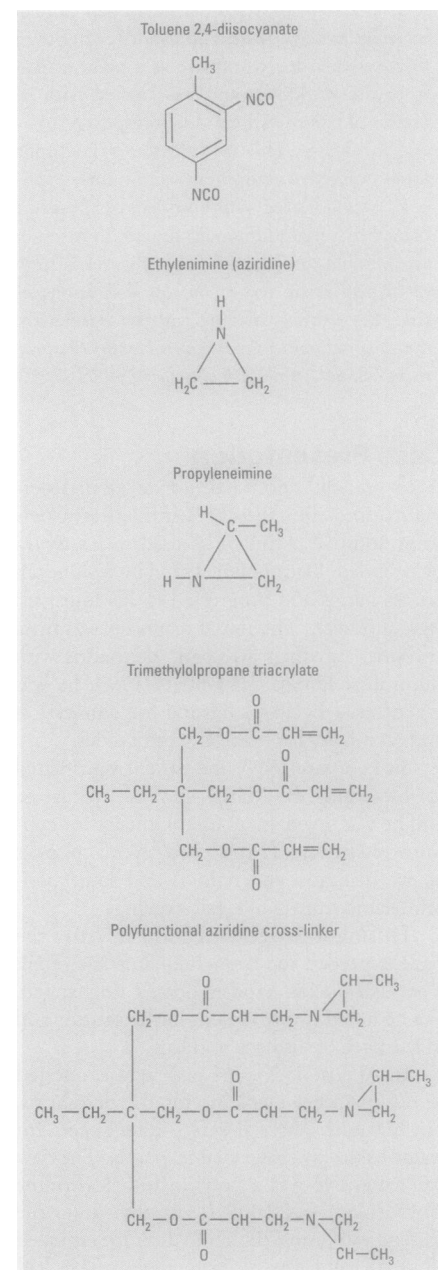


Figure 1. Chemical structure of compounds used in the manufacture of paint products.

years after workplace removal, function will have reached a plateau and an evaluation of permanent impairment and disability can be conducted (15).

The diagnosis of occupational asthma is based on a combination of history and objective tests (15,16). The history includes typical respiratory symptoms associated with working and exposure to agents known to cause asthma. It may be less apparent that illness is work-related when symptoms occur in response to nonspecific irritants and are severe enough to last through the weekends (16). The objective tests include serial pulmonary function testing to document variable airflow limitation and challenges to pharmacologic agents or the specific agent in question. Challenge tests can be falsely negative after the worker leaves the workplace for several days. Skin tests or radioallergosorbent tests for serum antibodies can establish sensitization to some agents, most of which are of high-molecular weight (15), such as latex.

The pattern observed on pharmacologic challenge is associated with the etiologic agent and the immunologic mechanism (15,16) (Table 1). Immunologically mediated asthma involves at least a short latency period. High-molecular weight agents ( $\geq 5,000$  daltons) cause asthma by induction of IgE antibodies (15). Some low-molecular weight agents such as acid anhydrides and platinum salts combine with a native protein to induce IgE antibodies. IgE-dependent reactions can involve an early asthmatic reaction, between several minutes and 2 hr after exposure (15). Most low-molecular weight agents cause asthma through an IgE-independent immunologic mechanism. IgE-independent responses often involve a late asthmatic reaction, occurring between 4 and 48 hr after exposure. Biphasic responses,

consisting of both early and late reactions, can occur following exposure to agents considered either IgE dependent or IgE independent (15). Irritants, such as chlorine, can cause asthma without latency through undetermined mechanisms (15,17,18).

The differential diagnosis includes several other respiratory conditions, including hypersensitivity pneumonitis (HP) and BOOP. HP, also termed extrinsic allergic alveolitis, can occur with chronic exposure to certain agents that also cause occupational asthma, such as diisocyanates. Although late HP is classically associated with a restrictive pattern on pulmonary function testing, HP can also cause small airways obstruction. The chest radiograph in chronic HP will generally involve a diffuse reticulonodular infiltrate, but may be normal early in the disease. Fever and other systemic symptoms are common, but are not always seen. Exposure to an agent that causes HP can sometimes be confirmed by checking for serum precipitins. Definitive diagnosis can be made by bronchoalveolar lavage or lung biopsy.

BOOP is often idiopathic, and frequently results in features not observed in this case, such as leukocytosis, crackles on lung auscultation, a restrictive pattern on pulmonary function testing, and patchy infiltrates on the chest radiograph. However, BOOP was not definitively excluded, given that the drops in the peak flow rate associated with work were small and no biopsy was performed. The positive methacholine response does not exclude BOOP, given that certain exposures can cause both BOOP and nonspecific bronchial hyperactivity (19).

This case demonstrates the importance of proper work practices. Rubber gloves

were not always available. The patient did not wear a respirator during the mixing process. The respirator the patient wore during painting was designed to protect against solvents, as opposed to particulates. Moreover, the respirator did not protect the eyes. In addition, if the worker had been able to rotate the piece being painted, it would not have been necessary for him to be located between the paint being sprayed and the ventilation exhaust.

## REFERENCES AND NOTES

- Ibbotson SH, Lawrence CM. Allergic contact dermatitis from aziridine crosslinker cx100. *Contact Dermatitis* 30:306-307 (1994).
- Kanerva L, Keskinen H, Autio P, Estlander T, Tuppurainen M, Jolanki R. Occupational respiratory and skin sensitization caused by polyfunctional aziridine hardener. *Clin Exp Allergy* 25:432-439 (1995).
- Weightman J, Hoyle JP. Accidental exposure to ethylenimine and N-ethylethylenimine vapors. *JAMA* 189:543-545 (1964).
- Kanerva L, Estlander T, Jolanki R, Tarvainen K. Occupational allergic contact dermatitis and contact urticaria caused by polyfunctional aziridine hardener. *Contact Dermatitis* 33:304-309 (1995).
- Ng TP, Hong CY, Goh LG, Wong ML, Koh KT, Ling SL. Risks of asthma associated with occupations in a community-based case-control study. *Am J Ind Med* 25:709-718 (1994).
- Meredith S. Reported incidence of occupational asthma in the United Kingdom. *J Epidemiol Community Health* 47:459-463 (1993).
- Toren K. Self reported rate of occupational asthma in Sweden 1990-2. *Occup Environ Med* 53:757-761 (1996).
- Kogevinas M, Anto JM, Soriano JB, Tobias A, Bumej P. The risk of asthma attributable to occupational exposures. A population-based study in Spain. Spanish Group of the European Asthma Study. *Am J Respir Crit Care Med* 154:137-143 (1996).
- Fishwick D, Pearce N, D'Souza W, Lewis S, Town I, Armstrong R, Kogevinas M, Crane J. Occupational asthma in New Zealanders: a population based study. *Occup Environ Med* 54:301-306 (1997).
- Chan-Yeung M, Malo JL. Aetiological agents in occupational asthma. *Eur Respir J* 7:346-371 (1994).
- Vandenplas O, Malo JL, Saetta M, Mapp CE, Fabbri LM. Occupational asthma and extrinsic allergic alveolitis due to isocyanates: current status and perspectives. *Br J Ind Med* 50:213-228 (1993).
- Reijula K, Haahtela T, Klaukka T, Rantanen J. Incidence of occupational asthma and persistent asthma in young adults has increased in Finland. *Chest* 110:58-61 (1996).
- Milton DK. Occupational asthma in New Zealanders: a population based study [letter]. *Occup Environ Med* 55:215-216 (1998).
- Milton DK, Solomon GM, Rosiello RA, Herrick RF. Risk and incidence of asthma attributable to occupational exposure among HMO members. *Am J Ind Med* 33:1-10 (1998).
- Chan-Yeung M, Malo JL. Occupational asthma. *N Engl J Med* 333:107-112 (1995).
- Cartier A. Definition and diagnosis of occupational asthma. *Eur Respir J* 7:153-160 (1994).
- Gautrin D, Boulet LP, Boutet M, Dugas M, Bherer L, L'Archeveque J, Lavolette M, Cote J, Malo JL. Is reactive airways dysfunction syndrome a variant of occupational asthma? *J Allergy Clin Immunol* 93:12-22 (1994).
- Alberts WM, Brooks SM. Reactive airways dysfunction syndrome. *Curr Opin Pulm Med* 2:104-110 (1996).
- Sole Jover A, Martinez Frances ME, Cordero Rodriguez PJ, Valterra Musoles J, Macian Gisbert V. Adverse effects on the respiratory system in textile printing sprayers [in Spanish]. *Rev Clin Esp* 196:157-161 (1996).

**Table 1.** Common causes of occupational asthma.

Agent	Workers at risk
High-molecular weight agents	
Cereals	Bakers, millers
Animal-derived allergens	Animal handlers
Enzymes	Detergent users, pharmaceutical workers, bakers
Gums	Carpet makers, pharmaceutical workers
Latex	Health professionals
Seafoods	Seafood processors
Low-molecular weight agents	
Isocyanates	Spray painters; insulation installers; manufacturers of plastics, rubbers, foam
Wood dusts	Forest workers, carpenters, cabinetmakers
Anhydrides	Users of plastics, epoxy resins
Amines	Shellac and lacquer handlers, solderers
Fluxes	Electronics workers
Chloramine-T	Janitors, cleaners
Dyes	Textile workers
Persulfate	Hairdressers
Formaldehyde, glutaraldehyde	Hospital staff
Acrylate	Adhesives handlers
Drugs	Pharmaceutical workers, health professionals
Metals	Solderers, refiners

Reprinted from Chan-Yeung (15) with permission from the Massachusetts Medical Society. Copyright © 1995 Massachusetts Medical Society. All rights reserved.