

PRACA ORYGINALNA  
ORIGINAL ARTICLE

## MORPHOMETRIC AND HISTOCHEMICAL CHARACTERISTICS OF THE CRIBRIFORM TYPE OF INTRADUCTAL CARCINOMA OF THE MAMMARY GLAND

Dmytro Y. Nikolenko, Dmytro M. Boiko, Olexandr A. Shkurupii, Oksana V. Ovcharenko

UKRAINIAN MEDICAL STOMATOLOGICAL ACADEMY, POLTAVA, UKRAINE

### ABSTRACT

**Introduction:** Due to the increasing morbidity and mortality rates from breast cancer, the problem of early, especially morphological diagnosis, continues to be important.

**The aim** of this study to investigate the karyometric and histochemical features of cribriform pattern of parenchyma of intraductal carcinoma of the mammary gland.

**Materials and methods:** Operational and biopsy material was studied in form of serial sections of micropreparations of cribriform type intraductal carcinoma of the mammary gland. Fixation with 10% neutral formalin, paraffin sections are stained with hematoxylin and eosin, complex Bergman + Periodic Acid - Schiff (PAS) reaction + alcyan blue. Cariometry was performed on 100 parenchymal tumor cell, tenth logarithms of the nucleus volume (LgV) were determined, kariocavrogram was constructed.

**Results:** The atypical cellular polymorphism of the tumor, cribriform structures with cancerous cells in the state of apoptosis was revealed. The modal nuclear classes are defined in the interval LgV 0,75; 0,9; 1,2; 1,45, and do not comply with the law of rhythmic growth of nuclei in normal and confirm the cellular atypism of a cancerous tumor. Results are deprived of subjectivity through mathematical analysis of data in percentages (%). Histochemically, in the cytoplasm of cancer cells, precursors of lipids were detected in the form of a Schiff (PAS) positive reaction; alcyan-positive basal membrane of the duct; Bergman-positive protein structures in the nuclei.

**Conclusions:** Cariometry and histochemical analysis of intraductal carcinoma of the mammary gland is an objective and accessible complex method for the analysis of atypical cells, reveals the degree of differentiation, apoptosis of cells and non-invasive stage of cancer.

**KEY WORDS:** morphometry, histochemistry, cribriform type, duct cancer, mammary gland

Wiad Lek 2019, 72, 5 cz. I, 748-752

### INTRODUCTION

Over the past decade, breast cancer incidence and mortality rates have been observed among women in Ukraine and in most developed countries, indicating the acute relevance of this problem. According to the data of the National Cancer Registry of Ukraine, in the past two years, more than 14,000 new cases of the illness have been detected, accounting for 63.7% out of 100,000 female population, in Poltava region it reaches up to almost 61.0%, as in the world this standardized indicator is 43.9%. At the same time, mortality in Ukraine from breast cancer has reached 24.4%, but the incidence among women in the world is 15.6% [1,2]. That is why, despite some successes in clinical diagnosis and treatment of breast cancer, the problem of early, especially morphological diagnosis of malignant tumors of the mammary gland (MG), continues to be important.

It should be noted that morphologically the mammary glands have certain features. They respond to rhythmic changes in the hormonal state of the ovaries. As a result, there is a periodic stimulus to the proliferation of parenchyma of the germinal zones of the MG: in the intercalated part of the terminal ducts, the epithelium of which has a morphological identity to the cuticular epithelium, and in the strained zone of the pathway of milk, with a pseudo-layered epithelium structure similar to the embryonic milkpoints in embryogenesis [3, 4,5,6,7].

That is why the proximity of the structure of the germinal zones of the MG ducts to the embryonic analogues makes them too sensitive to adverse factors, in particular carcinogens, which influence the proliferative process and lead to oncogenesis in the mature period of the woman's life [8,9,10].

It is known that the nucleus contains the genetic material of the cell, organized as multiple long linear DNA molecules that coil around to form chromosomes. These compact structures are stained with hematoxylin (chromatin). It binds to basophilic substances. In this case, the dynamics of the cell cycle of the chromosome may be in a state of complete decondensation (euchromatin). At the same time, the maximum condensation of chromatin (heterochromatin) occurs in mitosis of cells. The nucleus (one or two) is also associated with the activity of cells, forming ribosomal RNA [11,12]. Normally, the matrix of the cytoplasm stained with eosin shows cytoplasm blue. The cytoplasm contains membranous and non-membranous organelles that produce various substances with the accumulation of glycogen stores, fat drops and other substances [11,13].

However, specialists of pathomorphology are well-known in the difficulties associated with differential and histogenetic diagnosis of MG cancer ducts. It is due to the

fact that the usual histological methods have certain limits and are used to establish a formal diagnosis of malignant neoplasia. At that time, as it is known, a qualitative morphological diagnosis of a malignant tumor needs to take into account a complex of features: morphometric and morpho-functional characteristics, tissue and cell atypism, which allows to determine the degree of differentiation of the tumor. The above have a direct impact on the prognosis of the disease and the choice of cancer treatment methods [9,14,15,16].

According to the new classification of tumors WHO (2012), most carcinomas of MG develop from the terminal lumen-flow structural unit (TDLU, terminal duct lobular unit). An in situ carcinoma (DCIS) code 8500/2 has features in the form of proliferation of atypical epithelial cells of nonspecific type with clear boundaries and absence of polarity; degree of malignancy (low, moderate, high) depending on nuclear atypia; various type of structure, among which there is a cribriform type [17,18,19,20].

In this case, the karyometric and histochemical characteristics of the cribriform type of non-invasive stage of development in the elaborated scientific-practical medical literature are not sufficiently highlighted.

## THE AIM

The aim of the study is to investigate the karyometric and histochemical features of the parenchyma of the cribriform type of non-invasive intraductal carcinoma of the mammary gland.

## MATERIALS AND METHODS

The research was carried out within the framework of the Agreement on scientific and practical cooperation between the Dnipropetrovsk State Medical Academy and the Ukrainian Medical Stomatological Academy (Poltava), the state registration number 0101U4001002 and is a fragment of the topic "Individualization of the treatment of malignant tumors, taking into account the biological indices of the activity of the tumor process and markers of chemo hormone-resistance". The material was collected from both the archives database and the current histological study at the Poltava Regional Pathological Bureau, taking into account the "Law of Ukraine on burial and funeral affairs with changes introduced in accordance with the Law № 2246-IV February 16, 2004; BBP, 2005, № 4, Art. 105", and the Agreement on Scientific and Practical Cooperation between the Ukrainian Medical Stomatological Academy and the PRPB.

Serial sections of histological preparations of 24 cases of operative and biopsy material with intraductal carcinoma of the mammary gland in women aged 30-70 years with a formally verified cribriform type of cancer stained with hematoxylin and eosin were subject to the study. Fixation of the material in a 10% solution of neutral formalin, paraffin histological sections of the tumor tissue was repeatedly stained with hematoxylin and eosin, as well as the

combined histochemical Bergman + Periodic Acid - Schiff (PAS) reaction + alcyan blue. The reason for conducting Periodic Acid - Schiff (PAS) reaction with additional treatment with amylase was that neutral polysaccharides react during cell proliferation to reorganize the energy metabolism [21]. In the presence of crimson coloration of cells, this is considered a Periodic Acid - Schiff (PAS)-positive reaction. The clarification of the presence of acidic glycosaminoglycans in the histostructure of the tumor occurred alcian blue by Steedmen, blue-green color was considered alcian-positive [22]. The coloring of micropreparations by the Bergman method reveals the neurosecretory granules in the cytoplasm and the clear outlines of the brown nucleus, which was important for caryometry. In the microscopy of the tumor tissue, the degree of basophilia of the nucleus of the cells was considered, which is related to fine, medium, and large-splintered chromatin.

Cariometry, as the most informative among morphometric methods [23, 24], was carried out on microfot imprints in a size of 18x24 cm with enlarged study objects in 1000 times in 100 atypical cells. The size of the nuclei was determined (V) by the formula:

$$V = \frac{\pi}{6} k^3 d,$$

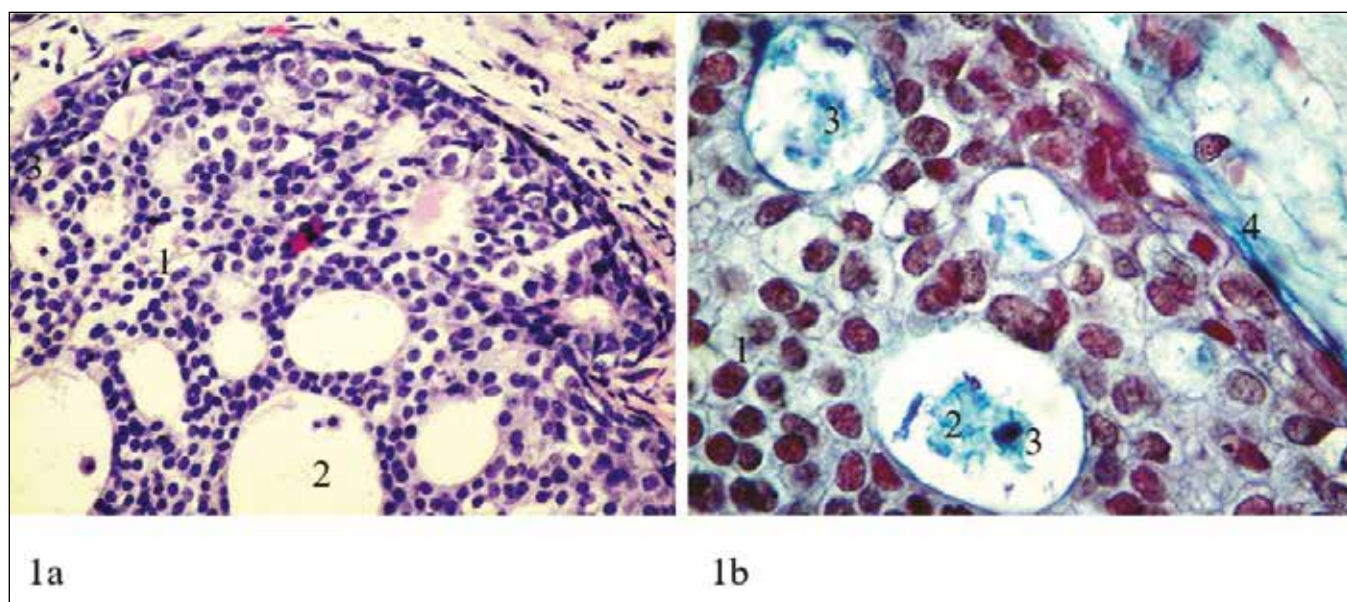
where d is the small diameter of the nucleus, D - the large diameter of the nucleus, k - coefficient of increase of an object (1,545);  $\pi$  (3.14). The error did not exaggerate 0.03%, which corresponds to the requirements for medical biology research ( $P < 0.005$ ). All values of the volume of the nuclei were logarithmized ( $\lg V$ ) by the formula for the rotary ovoid:

$$\lg V = \lg \frac{p \times \pi}{6} d^2,$$

where p is the multiplicity of increase (1,545);  $\pi$  - 3.14; d - small diameter of the nucleus, D is the large diameter of the nucleus, followed by computer processing [25,26,27]. The quantity of all nuclear classes acquire the values in percent (%) of the maximum nuclear class taken for 100%. The combination of these results was karyocovariogram. Study of stained micropreparations was carried out using the light microscope of the company «Olympus BX41» with lenses x10, x20, x40, x100. The statistical processing of the karyometric data was performed on an IBMPC compatible computer using the «Microsoft office Excel, 2007» licensing program for Windows XP. The work was followed by legal norms and requirements for scientific morphological studies [28].

## RESULTS AND DISCUSSION

An overview optical-optical microscopy of hematoxylin-colored and eosin-colored histopathologic preparations of intraductal carcinoma of the mammary gland revealed the duct with canceromatosis, the lumen of which is completely filled with polymorphic cellular elements (Fig. 1a). They have a mostly chaotic orientation with the loss of



**Fig. 1.** Cribriform type of intraductal carcinoma of the mammary gland.  
 a) Hematoxylin & Eosin staining (x400 magnification): 1 - Atypical cells in the lumen of the duct; 2- “cribriform structures” in the cancer population; 3-moderate lymphoid infiltration.  
 b) Bergman + Periodic Acid - Schiff (PAS) reaction + alcyan blue staining (x1000 magnification): 1- Schiff-positive coloration of the cell cytoplasm; 2-Alcyan-positive secret in the secondary lumina; 3 - apoptotic nucleus; 4-Alcyan-positive staining of the basal membrane of the cancerous duct.

stratification and their polarity. At the same time, attention is drawn to the orderly arrangement of some tumor cells with radial orientation around randomly located round cavities - cribriform (lattice) structures, among some isolated solid layers of tumor tissue from the periphery. Most of the cellular elements of the tumor are not in contact with the basal membrane of the cancerous duct, which is a sign of the entropy of the atypical proliferation. An analysis of the cancer cell complex found in most cells in the center a large nucleus with a convoluted nuclear membrane. There is a change in the ratio of the nucleus and cytoplasm of tumor cells, which correlates with the change of their nuclear chromatin. Cell elements with a broad rim of cytoplasm containing basophilic inclusions have an intranuclear content of preferably light-basophilic chromatin and one or two nucleoli. In this case, the chromatin is in the dusty state and occasionally coarse-shaped. This character of chromatin characterizes, according to literature [13], the decondensation of chromosomal material (euchromatin) in the synthetic process of transcription and reduplication of genetic material in the interphase of the cell cycle, which is a sign of the functional activity of atypical cells. This cell corresponds to a modal nuclear class with LgV 0.9 and is the maximum, the most numerous, taken for 100%. Among the atypical cellular population of the MG ducts, there are also such cells that have a narrow rim of a pale pink cytoplasm surrounding the large hyperchromic nucleus. It contains predominantly mass chromatin, which is highly condensed in mitosis of atypical cells. These cellular elements are tumors of different ploidy, have no signs of functional activity and constitute, in our opinion, a population that provides tumor growth. In this case,

the LgV nuclei of these cells is 0.75, which is 35% of the maximum nuclear class.

Atypical cells of the duct cancer that form the environment of cribriform structures in the neoplasia and the one pole in contact with the fluid (the secret) are not located on the basal membrane. These cells contain a rounded hyperchromic nucleus, in some of them it is pressed to the membrane of the cytoplasm with colorless vacuoles. This sign sometimes reveals the developed atypical secretory activity, which is characteristic of malignant tumors at the expense of partial differentiation [16, 29]. The presence of two more modal nuclear classes among the aforementioned cell population was detected by kariometry. They are located within LgV 1.2 and 1.45 (representing 75% and 68% respectively of the maximum nuclear class). The difference is LgV of the nucleus in 0.2, according to the Beningoff's law [25], corresponds to an increase in the volume of the nucleus under functional load, and confirms the established signs of secretion founded in cribriform structures. Combined histochemical coloring of micro-samples of the tumor (Bergman + Periodic Acid - Schiff (PAS) reaction + alcyan blue) revealed, first of all, the presence of the Periodic Acid - Schiff (PAS) reaction-positive substances in the cytoplasm of pale-raspberry color around the nuclei of atypical cells (Fig.1b). Obviously, these are precursors of lipids – acetal lipids, which, according to literature review [22], contain aldehyde groups and with a Schiff reagent form lipid peroxides; and secondly: alcyan-positive substance both in the cytoplasm of atypical cells, and in its outer membrane, as well as in the lumen of cribriform structures. It should be noted that the blue color of alcyan-positive content in the structure of the

tumor, has a different degree of saturation. It is especially expressed in the lumen of the cavities in the tumor, has a deep structure and resembles fragments of cell nuclei in a state of apoptosis. Along with this, alcian-positive coloration also acquired the basal membrane of the MG ducts, which is affected by the tumor, as well as the submembrane structures of the surrounding connective tissue. It should be noted that the varying degree of saturation of the alcian-positive color of the basal membrane of the cancerous duct of the gland demonstrates both continuity and fluctuations in its organic structure, and hence the threat of the development of invasive growth of the intraductal carcinoma of the mammary gland.

## CONCLUSIONS

1. It has been determined that the cell population of the cribriform type of the non-invasive form of intraductal carcinoma of the mammary gland is varied by morphological features and functional activity.
2. It has been established that the atypical cell proliferate in the affected duct of the mammary gland is polymorphic-cellular, characterized by four growing modal nuclear classes with LgV 0.75; 0.9; 1.2; 1.45i confirms neoplastic nuclear polymorphism, while:
  - a) the smallest nucleus (LgV 0.75 and 0.9) have an oval or rounded shape, a dark basophilic color, and are surrounded by a narrow rim of weak eosinophilic cytoplasm, indicating a population of atypical epithelial cells capable of mitosis.
  - b) the largest by volume nuclei (LgV 1.2 and 1.45) with a difference of 0.2 have a rounded shape, a light basophilic color, the nuclei are shifted by optically empty vacuoles of the cytoplasm, apparently, due to the secretion of acetyl lipids, as a result of moderate differentiation of atypical cells.
3. It was found out that the atypical epithelium of cribriform structures with a combined histochemical color (Bergman + Periodic Acid - Schiff (PAS) reaction + alcyan blue) has:
  - a) Schiff-positive cytoplasm and alcyan-positive secret in cribriform structures, together with apoptotic fragments of cell nuclei;
  - b) continuous alcyan-positive basal membrane indicates on absence of invasive growth of the duct carcinoma.
4. To determine the prediction of the cribriform type of intraductal carcinoma of the mammary gland it is expedient to carry out the histochemical coloration of Bergman + Periodic Acid - Schiff (PAS) reaction + alcyan blue with the detection of Schiff- and alcyan-positive secretion, which determine the degree of differentiation of atypical cells, and the continuity of the alcyan-positive basal membrane indicates a non-invasive form of growth cancer.

**Prospects for Further Research:** In the future, it is planned to improve the technique of morphological research, to improve the tactics of anticancer therapy in patients with intraductal carcinoma of the mammary gland.

## REFERENCES

1. Biuleten Natsionalnoho kantser-reiestru Ukrainy № 10 « Rak v Ukraini, 2007-2008: zakhvoriuvanist, smertnist, pokaznyky diialnosti onkologichnoi sluzhbi» [Cancer in Ukraine, 2007-2008: morbidity, mortality, indicators of the oncology service activity]. Pid red.: I.B.Shepotina. 10-te vydannia. Kyiv: Natsionalnyi instytut raku; 2009, 103 s. (UA)
2. Biuleten Natsionalnoho kantser-reiestru Ukrainy № 9. «Rak v Ukraini, 2016-2017: zakhvoriuvanist, smertnist, pokaznyky diialnosti onkologichnoi sluzhbi» [Cancer in Ukraine, 2016-2017: morbidity, mortality, indicators of the oncology service activity]. Kyiv: Natsionalnyi instytut raku; 2018, S. 39–40. (UA)
3. Volkova O. V. Embriohenez i vozrastnaia histolohiia vnutrennikh orhanov cheloveka [Embryogenesis and age histology of human internal organs]. Moskva: Meditsina; 1976, 410s. (RU)
4. Afanasev Yi. Y. Histolohiia [Histology]: uchebnik. 5-e izd., pererab. idop. Moskva: Meditsina; 2002, 743 s. (RU)
5. Kokolina V. F. Razvitie molochnoi zhelezy v protsesse reproductivnoi sistemy [Breast development in the process of reproductive system]. Ros. Vestnik akushera-hinekolo. 2006;6(3):26–32. (RU)
6. Nikolenko D. Y. Morfolohiia molochnoi zaloz y zhinky reproductyvnoho viku [Morphology of the mammary gland of a woman of reproductive age]. Aktualni problem suchasnoi medytsyny. 2007;4(24):275–278. (UA)
7. Nikolenko D. Y. Zarodok molochnoi zalozy yak prototypy i herminatyvnoi zony u zhinky reproductyvnoho viku [Breast gland as a prototype of it germinal zone in a woman of reproductive age]. Svitmedytsyny ta biolohii. 2008;2(2):78–82. (UA)
8. Hilakivi-Clarce L, Shayahan A, Yu B, de Assis S. Differentiation of Mammary Glands as a Mechanism to Reduce Breast Cancer Risk. J Nutr. 2006;136:2697S–2699S.
9. Kantserohenez [Carcinogenesis]. Pod. red. D.H.Zaridze. Moskva: Meditsina; 2004, 576s. (RU)
10. Celia-Terrasa T. Mammary Stem Cells and Breast Cancer Stem Cells: Molecular Connections and Clinical Implications. Biomedicine. 2018;6(2):E50. doi: 10.3390/biomedicine6020050.
11. Khiem A, Kormak D. Histolohiia [Histology]: Per. s anhl. Moskva: Mir; 1983, S. 5–25. (RU)
12. Crum CP, Lester SC, Cotran RS. The Female Genital System and Breast. In: Kumar V, Cotran RS, Robbins SL. Robbins Basic Pathology. Philadelphia, London, Toronto, Montreal, Sydney, Tokyo: Saunders; 2003, p. 679–718.
13. Afanasev Yu. Y., Yurina N. A., Kotovskii E. F. i dr. Histolohiia [Histology]: Uchebnik. 5-e izd., pererab. idop. Moskva: Meditsina; 1999, S. 73. (RU)
14. Honcharova S. V. Kriterii klinichnoi morfolohichnoi diahnostiki preinvazivnii (in situ) ta invazivnoho raku molochnoizalozy [Criteria for clinical and morphological diagnosis of preinvasive (in situ) and invasive breast cancer]. Vestnik neotlozhnoi y vosstanovyv. medytsyny. 2006;7(1):126–130. (UA)
15. Farid Moinfar Essentialis of Diagnostic Breast Pathology. A Practical Approach. Springer-Verlag Berlin Heidelberg; 2007, p. 496.
16. Viale G. Specifics of breast cancer diagnosis in every day practice. Arhivpatoloh. 2013;75(4):54–61.
17. Frank H. A., Danilova N. V., Andreeva Yu. Yu., et al. Klassifikatsiia opukholei molochnoi zhelezy VOZ 2012 hoda [WHO classification of breast cancer 2012]. Arkhivpatolohii. 2013;75(2):53–62. (RU)
18. Holovin D. I. Oshibki i trudnosti histolohicheskoi diahnostiki opukholei [Errors and difficulties of histological diagnosis of tumors]: rukovodstvo dlia vrachei. Leninhad: Meditsina; 1982, S. 182–200. (RU)
19. Tumor of the Breast and female genital organs. World Health Organization Classification of Tumors. Edit. by F.A. Tavassoli, P. Devilee. Lyon: JARC Press; 2003, P. 432.

20. ABC of breast diseases. Edit. by J. Michael Dixon. 3rd ed. Blackwell Publishing; 2006, P. 112.
21. Lilli R. Patohistologicheskaiatekhnikaiprakticheskaiahistokhimiia [Pathological technique and practical histochemistry]. Moskva: Izdatelstvo «Mir»; 1969, S. 645. (RU)
22. Pirs M. Histokhimiia [Histochemistry]. Moskva: izd. inostr. liter.; 1962, 962 s. (RU)
23. Avtandilov H. H. Osnovy kolichestvennoi patolohicheskoi anatomii [Fundamentals of quantitative pathological anatomy]. Moskva: Meditsina; 2002, 240 s. (RU)
24. Tsyhanova V. I., Melnikova N. P., Mohileva H. L., et. al. Morfotipy yade rzhelezistoho epiteliia pri dobrokachestvennykh i zlokachestvennykh zabolivaniakh molochnykh zhelez [Morphotypes of nuclei of ferruginous epithelium in benign and malignant diseases of the mammary glands]. Klin Lab d-ka. 2004;1:43–45. (RU)
25. Khesin Ya. E. Razmery yader i funktsionalnoe sostoianie kletki [The size of the nucleus and the functional state of the cell]. Moskva: Meditsina; 1967, S. 10-12. (RU)
26. Jacobi W. Uber das rhythische Wachstum der Zellendurch Verdoppelung ihres Volumens. Arch Entwicklunsmech. 1935;10:S.124-126.
27. Tashke E. K. Vvedenie v kolichestvennuu situ-histologicheskuiu morfologiu [Introduction to quantitative cytological and histological morphology.]. Rumynia: Iz-vo Akademiia; 1980, S.7-25. (RU)
28. Mishalov V. D., Chaikovskiy Yu. B., Tverdokhlib I. V. Pro pravovi zakonodavchi ta etychninormy vymohy pry vykonani naukovykh morfologichnykh doslidzhen [On legal and ethical norms and requirements when performing scientific morphological research]. Morfolohiia. 2007;1(2):1-5. (UA)
29. Russo I, Mailo D, Hu YF, et. al. Breast differentiation and its implication in cancer prevention. Clin Cancer Res. 2005;11:931s – 6s.

**Authors' contributions:**

*According to the order of the Authorship.*

**Conflict of interest:**

*The Authors declare no conflict of interest.*

---

**CORRESPONDING AUTHOR**

**Dmytro M. Boiko**

Ukrainian Medical Stomatological Academy

Shevchenko 23 str., 36011 Poltava, Ukraine

e-mail: dim.xata@gmail.com

**Received:** 01.03.2019

**Accepted:** 24.04.2019