



# Sciatic neuropathy in an acromegalic cat without concurrent diabetes mellitus

Andrea Corsini , Ezio Bianchi, Antonella Volta and Mattia Bonazzi

*Journal of Feline Medicine and Surgery Open Reports*  
1–6

© The Author(s) 2020

Article reuse guidelines:

sagepub.com/journals-permissions

DOI: 10.1177/2055116920906936

journals.sagepub.com/home/jfmsopenreports

This paper was handled and processed by the European Editorial Office (ISFM) for publication in *JFMS Open Reports*



## Abstract

**Case summary** A 17-year-old neutered male European Shorthair cat was presented owing to an inability to jump and respiratory stridor. The owner did not report any other clinical signs. On physical examination, the main findings were plantigrade stance, broad facial features and inspiratory stridor. Neurological examination revealed posterior paraparesis, hypotonia and right hindlimb muscle atrophy. Laboratory findings were unremarkable and glycaemia was normal. Serum insulin-like growth factor 1 concentration was elevated ( $>1000$  ng/ml). A total body CT scan showed an enlarged pituitary gland, thickening of the nasal turbinates and an L7–S1 right foraminal stenosis. Electrodiagnostic testing confirmed the presence of a neuropathy affecting both sciatic nerves. The cat was treated with gabapentin only and was still alive and euglycaemic 16 months after the diagnosis.

**Relevance and novel information** This case describes for the first time sciatic neuropathy, an occasional complication of acromegaly in people, as a possible clinical presentation in acromegalic cats without concurrent diabetes mellitus.

**Keywords:** Acromegaly; hypersomatotropism; neuropathy; diabetes mellitus

**Accepted:** 27 January 2020

## Introduction

Hypersomatotropism (HST) is defined as an excess secretion of growth hormone (GH) typically caused by a pituitary somatotroph adenoma; however, some cases of pituitary acidophilic hyperplasia have also been described.<sup>1</sup> In cats, GH-producing pituitary tumours are the most common type of pituitary tumour, with a prevalence 10-fold greater than humans.<sup>2</sup> Acromegaly is the clinical syndrome that develops from GH overproduction in adults. GH has both anabolic and catabolic effects, and enhances production of insulin-like growth factor 1 (IGF-1), mainly by the liver, causing increased protein synthesis and tissue overgrowth. Consequently, the main clinical findings reported in acromegalic cats are broad face, prognathia inferior, enlarged paws, abdominal organomegaly, hypertrophic cardiomyopathy, respiratory stridor and increased body weight.<sup>2–7</sup> Because of its slow progressive nature, it is quite common for

there to be few or no clinical signs present in the early course of the disease. Moreover, even when present, signs can be subtle and difficult to note both for the owner and the clinician.<sup>2,7</sup>

Notably, an excess of GH causes marked insulin resistance, mainly due to a decrease in insulin receptor expression and post-receptor antagonism.<sup>3</sup> For this reason, insulin-resistant diabetes mellitus (DM) is a typical complication of acromegaly both in humans and in cats. In acromegalic people, the prevalence of DM has been estimated to range from 12% to 37.6%, with evidence of

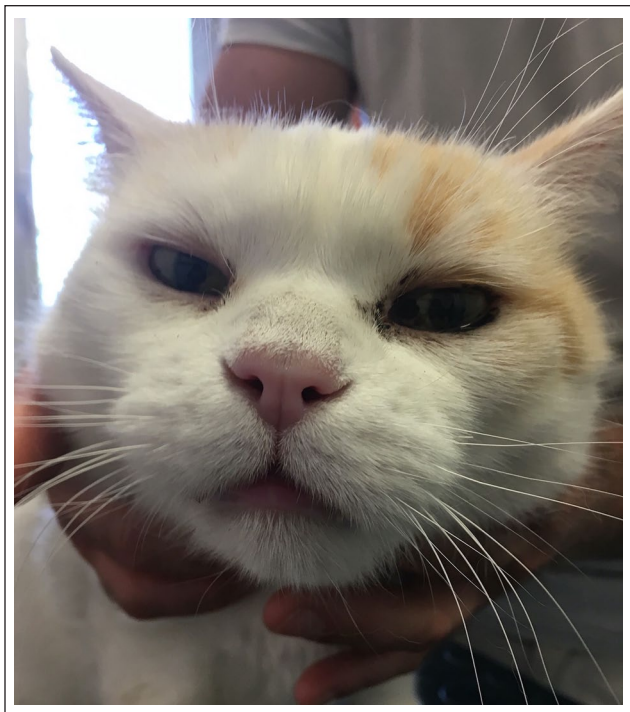Department of Veterinary Science, University of Parma, Parma, Italy

### Corresponding author:

Andrea Corsini DVM, PhD, Department of Veterinary Science, University of Parma, Strada del Taglio 10, Parma 43126, Italy

Email: andrea.corsini@unipr.it





**Figure 1** A 17-year-old male European Shorthair cat at time of presentation, when acromegaly was diagnosed. Note the broad facial features

glucose dysregulation ranging from 16% to 54%.<sup>8</sup> Despite this, for a long time, DM has been reported as the presenting problem in all acromegalic cats, sometimes being the only abnormality recognised.<sup>3</sup> Only recently have cases of acromegalic cats without DM been described.<sup>9,10</sup> These findings highlight the importance of not overlooking acromegaly as a possible differential diagnosis in cats with compatible clinical signs, even in the absence of DM. Increased knowledge of clinical presentation in these cats could improve the diagnosis of acromegaly, thus increasing the number of acromegalic cats diagnosed before DM development. The present article describes an acromegalic cat without DM with an uncommon clinical presentation.

### Case description

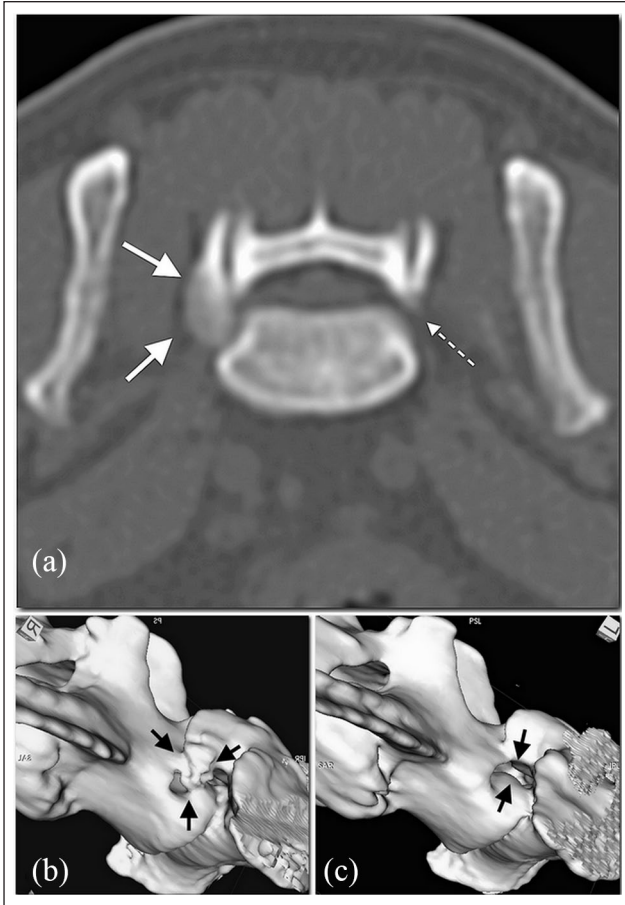
A 17-year-old neutered male European Shorthair cat was presented owing to an inability to jump, weakness and respiratory stridor. All these signs had started a few months previously. The cat was kept strictly indoors, had no history of trauma and the owner did not report any other clinical signs or pre-existing disease. The physical examination revealed a plantigrade stance, pelvic limb muscle atrophy that was more severe on the right, broad facial features (Figure 1) and inspiratory stridor.

Neurological examination showed the cat had a reluctance to move, lameness of the hindlimbs and

paraparesis with plantigradism. Postural reactions and flexor reflexes were reduced in both pelvic limbs. Neurological signs were more severe on the right pelvic limb. A lesion affecting the sciatic nerves, more severe on the right side, was suspected because the cat was not ataxic, and the other nerves originating from L4–S3 spinal cord (femoral nerve, pelvic nerve, pudendal nerve, etc) were apparently not affected. A lesion affecting the nerve roots of the sciatic nerve at the level of the cauda equina could not be excluded, but was considered less likely because of the marked asymmetry of the clinical signs and the absence of evidence of involvement of the pelvic and pudendal nerve and coccygeal nerves. Degenerative (lumbosacral stenosis, disc herniation), neoplastic (lymphoma, paraneoplastic polyneuropathy) or metabolic (lumbosacral stenosis associated with acromegaly, diabetic polyneuropathy) conditions were included as differential diagnoses.

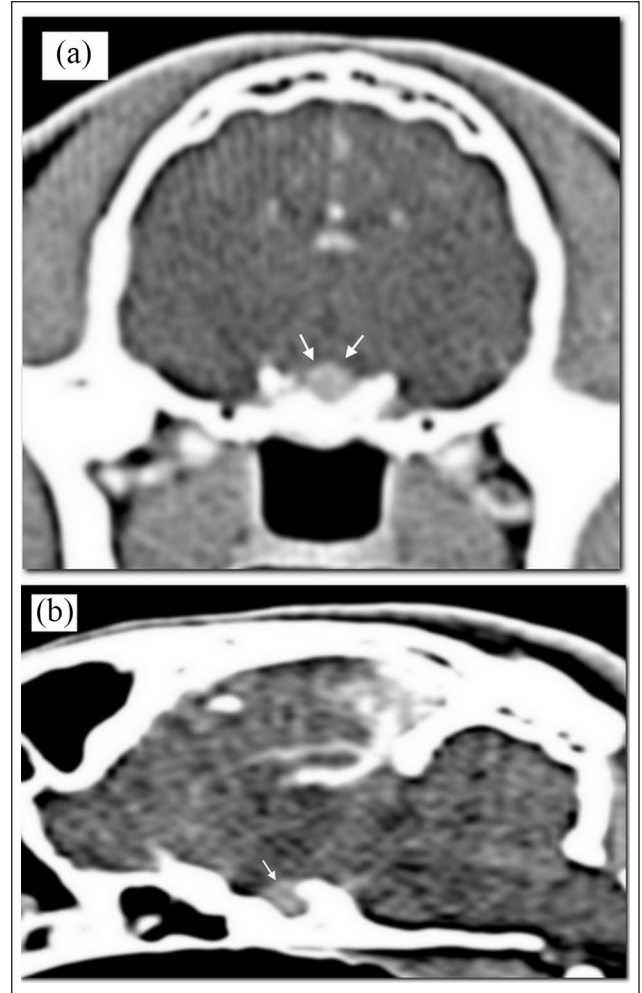
Routine laboratory examination, including a complete blood count, serum biochemistry and complete urinalysis, was unremarkable. Serum glucose concentration was 5.4 mmol/l (reference interval [RI] 4.1–6.4 mmol/l) and serum fructosamine concentration was 211 µmol/l (RI 220–350 µmol/l). Serum total thyroxine concentration was also normal (32 nmol/l; RI 10–60 nmol/l). Serum IGF-1 concentration, measured with a validated commercially available chemiluminescence assay (Immulite; IDEXX Laboratories),<sup>11</sup> was higher than the assay detection limit (1000 ng/ml). Basal GH concentration was not measured. Abdominal ultrasound evaluation revealed visceral organs of normal size (liver, spleen, pancreas, kidneys and adrenal glands). An echocardiography was performed, which showed no evidence of cardiac hypertrophy.

A CT scan of the lumbosacral spine and the head was performed with a single slice helical scanner (Siemens Somatom Emotion). The cat was placed in sternal recumbency under general anaesthesia and a scan of the lumbosacral spine was obtained with a 2 mm slice thickness. Subsequently, the head was scanned with 1 mm slice thickness, pre- and post-contrast (Iomeprol with an iodine concentration of 300 mg/ml, dosage of 600 mg iodine/kg EV [Iomeron 300; Bracco]). In the precontrast CT examination, the right cranial articular process of S1 was hypertrophic, with severe impingement on the right L7–S1 foramen (Figure 2). The left L7–S1 foramen was also mildly stenotic due to mild bony hypertrophy of the left caudal articular process of L7 (Figure 2). Ventral spondylosis between L6 and L7 without involvement of the L6–L7 foramina was also detected. Post-contrast CT examination showed an enlarged pituitary gland (4 mm in height, 4.5 mm in width, 4 mm in length) with a mild suprasellar extension (Figure 3). Hypertrophic ethmoidal turbinates and left fluid-filled tympanic bulla indicating otitis media were other findings.



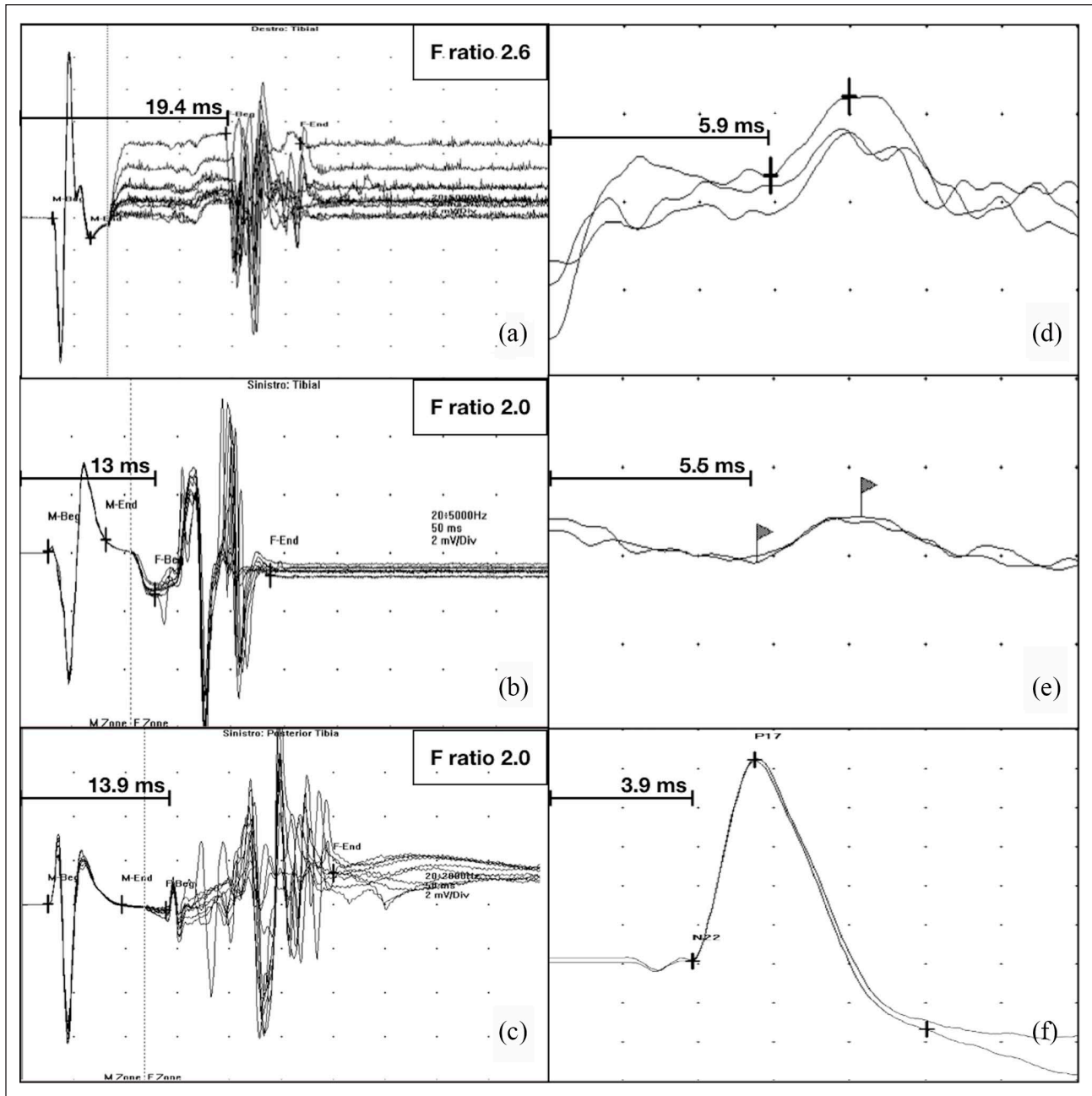
**Figure 2** Pre-contrast CT images of the spine at the level of L7–S1. On the transverse plane, a hypertrophied cranial articular process of S1 causing severe right foramen stenosis is seen (arrows, a). A mild left foramen stenosis is also detected due to bony hypertrophy of caudal left articular process of L7 (dashed arrow, a). These findings (arrows) are clearly apparent in three-dimensional surface rendering reconstructions on the (b) right side and on the (c) left side

In order to better characterise the peripheral neuropathy, electrodiagnostic tests were performed. Electromyography showed mild spontaneous pathological activity of the appendicular muscles innervated by the right sciatic nerve. Motor nerve conduction studies (MNCS) and sensory nerve conduction studies (SNCS) of both sciatic tibial nerves and of the right ulnar nerve were within normal limits. Minimum F waves latencies and F ratio were severely increased in the right tibial nerve. Onset latency of cord dorsum potential obtained by stimulating the tibial nerve was increased in both pelvic limbs, and more severely in the right one. Electrodiagnostic findings were indicative of a lesion of the proximal portion of both sciatic nerves or their roots, which was more severe on the right side (Figure 4).



**Figure 3** Post-contrast transverse CT image of the brain at the level of hypophyseal fossa. The pituitary gland is mildly enlarged (arrows, a). A mild suprasellar extension is detected in the multiplanar reconstruction on the longitudinal plane (arrow, b)

The final diagnosis was acromegaly and entrapment neuropathy of the sciatic nerve as a consequence of lumbosacral/foraminal stenosis due to bone hypertrophy. Medical treatment for acromegaly using cabergoline was suggested, but the owner declined it. Surgical treatment of the foraminal stenosis was discussed, but a medical approach was preferred owing to the age of the cat. As a result, treatment was aimed to control and prevent neuropathic pain (gabapentin 10mg/kg q12h) and re-checks were arranged every 3 months to evaluate neurological condition and glycaemic control. The clinical condition slightly improved in the first weeks of treatment. Sixteen months after the first presentation, the cat was still euglycaemic and neurological signs were stable. Serum IGF-1 concentration was re-evaluated at the time and was still over the detection limit of the assay.



**Figure 4** (a) F waves of the right tibial nerve. (b) F waves of the left tibial nerve. (c) F waves of the tibial nerve of a normal age-matched domestic shorthair (DSH) cat. Note the increased minimum F wave latency and F ratio of the right tibial nerve vs the left one and vs the normal subject. (d) Cord dorsum potential (CDP) of the right tibial nerve. (e) CDP of the left tibial nerve and (f) CDP of the tibial nerve of a normal age-matched DSH cat; 2 ms/div, 2  $\mu$ V/div. Note increased CDP onset latencies in the affected subject

## Discussion

The cat described in this report was suspected of being acromegalic because of its broad facial features and recent onset of respiratory stridor. Serum IGF-1 concentration was measured on two different occasions, 16 months apart, and was markedly increased ( $>1000$  ng/ml) both times. Finding a serum level of IGF-1  $>1000$  ng/ml was considered to have a positive predictive value of

95%.<sup>11,12</sup> Basal serum GH concentration was not measured for a different reason. First, a feline GH assay is not widely available. Also, owing to its pulsatile secretion, multiple sampling is usually suggested. However, the finding of an increased basal GH concentration is considered strongly suggestive of the disease.<sup>12</sup> Despite not being routinely evaluated, serum GH concentration measurement could have further supported the

diagnosis in this case. CT of the head showed an enlarged pituitary gland but no evidence of pituitary adenoma.<sup>13</sup> This is an unusual but possible finding in acromegalic cats. Moreover, incidental pituitary enlargement in older cats is rare.<sup>2,7</sup> Recently, two different reports described a total of four acromegalic cats without DM.<sup>9,10</sup> These findings prove that, as happens in people, cats with HST can develop acromegaly without concurrent DM.

Notably, the presenting problem of the cat described herein was plantigradism. It is uncommonly reported in acromegalic cats as a consequence of diabetic neuropathy.<sup>2</sup> In this case, electrodiagnostic tests confirmed the presence of a neuropathy affecting both sciatic nerves in the absence of DM. In particular, abnormal cord dorsum and F waves, with an increased F ratio, in a subject with normal MNCS and SNCS, identified the bilateral lesion of the sciatic nerve as focal and affecting the proximal part of the nerve fibres. F waves and cord dorsum potential are, indeed, tests that evaluate the proximal fibres, motor and sensory ones, respectively. Based on the findings of the CT scan, a sciatic nerve entrapment resulting from the lumbosacral/foraminal stenosis appears to be the most likely cause of the focal lesion. Interestingly, plantigradism was also reported in two of the four previously described non-diabetic acromegalic cats, despite the fact that in those cases no further diagnostic tests to evaluate the peripheral nervous system were performed.<sup>9</sup>

Generalised peripheral nerve dysfunction is a well-known complication in acromegalic people.<sup>14</sup> Carpal tunnel syndrome (CTS) is the most commonly described neuropathy in acromegalic patients.<sup>15</sup> A study evaluating acromegalic human patients treated with somatostatin analogue, both clinically and electrophysiologically, found that 87% showed peripheral nervous system abnormalities. 50% of the cases was diagnosed with CTS and 37% with polyneuropathy. Neuropathic pain was present in 14% of cases. No differences were found between diabetic and non-diabetic patients.<sup>16</sup> Pathogenesis of neurological conditions in acromegaly could be related both to concurrent DM or hypersomatotropism by itself. Possible explanations are compression of the nerves due to hypertrophic connective or bone tissue, and swelling of the nerve.<sup>14</sup>

In the case described here, CT examination revealed lumbar spinal stenosis. It is highly likely this finding plays a role in clinical manifestations. Lumbar spinal stenosis is a possible cause of peripheral nerves dysfunction and is described in acromegalic human patients.<sup>17</sup> In this case, a concomitant polyneuropathy causing generalised mild functional abnormalities cannot be completely excluded based on electrodiagnostic tests, in the absence of nerve biopsies. Nevertheless, a polyneuropathy alone cannot explain clinical and electrodiagnostic findings of this cat.

Finally, neurological lameness is usually associated with neuropathic pain (nerve root signature). Neuropathic pain was very likely in this case, also considering the CT findings of foraminal stenosis. Gabapentin was preferred over other analgesic drugs for its efficacy in treatment of neuropathic pain.

## Conclusions

This case is the first description of a non-diabetic acromegalic cat with a sciatic neuropathy confirmed by an electrodiagnostic test. Acromegaly should be considered a possible differential diagnosis in cats with mono-neuropathies and entrapment syndromes.

**Conflict of interest** The authors declared no potential conflicts of interest with respect to the research, authorship, and/or publication of this article.

**Funding** The authors received no financial support for the research, authorship, and/or publication of this article.

**Ethical approval** This work involved the use of non-experimental animal(s) only (owned or unowned), and followed established internationally recognised high standards ('best practice') of individual veterinary clinical patient care. Ethical approval from a committee was not necessarily required.

**Informed consent** Informed consent (either verbal or written) was obtained from the owner or legal custodian of all animal(s) described in this work for the procedure(s) undertaken. For any animals or humans individually identifiable within this publication, informed consent for their use in the publication (verbal or written) was obtained from the people involved.

**ORCID iD** Andrea Corsini  <https://orcid.org/0000-0003-1673-8715>

## References

- 1 Scudder CJ, Mirczuk SM, Richardson KM, et al. **Pituitary pathology and gene expression in acromegalic cats.** *J Endocr Soc* 2019; 3: 181–200.
- 2 Niessen SJ, Forcada Y, Mantis P, et al. **Studying cat (*Felis catus*) diabetes: beware of the acromegalic imposter.** *PLoS One* 2015; 10: e0127794. DOI: 10.1371/journal.pone.0127794.
- 3 Greco DS. **Feline acromegaly.** *Top Comp Anim Med* 2012; 27: 31–35.
- 4 Peterson ME, Taylor RS, Greco DS, et al. **Acromegaly in 14 cats.** *J Vet Intern Med* 1990; 4: 192–201.
- 5 Borgeat K, Niessen SJM, Wilkie L, et al. **Time spent with cats is never wasted: lessons learned from feline acromegalic cardiomyopathy, a naturally occurring animal model of the human disease.** *PLoS One* 2018; 13: e0194342. DOI: 10.1371/journal.pone.0194342.
- 6 Lourenço BN, Randall E, Seiler G, et al. **Abdominal ultrasonographic findings in acromegalic cats.** *J Feline Med Surg* 2015; 17: 698–703.

- 7 Lamb CR, Ciasca TC, Mantis P, et al. **Computed tomographic signs of acromegaly in 68 diabetic cats with hypersomatotropism.** *J Feline Med Surg* 2014; 16: 99–108.
- 8 Hannon AM, Thompson CJ and Sherlock M. **Diabetes in patients with acromegaly.** *Curr Diab Rep* 2017; 17: 8. DOI: 10.1007/s11892-017-0838-7.
- 9 Fletcher JM, Scudder CJ, Kiupel M, et al. **Hypersomatotropism in 3 cats without concurrent diabetes mellitus.** *J Vet Intern Med* 2016; 30: 1216–1221.
- 10 Fracassi F, Salsi M, Sammartano F, et al. **Acromegaly in a non-diabetic cat.** *JFMS Open Rep* 2016; 2. DOI: 10.1177/2055116916646585.
- 11 Raiman Y. **Reference range of the IGF-1 concentration in feline plasma using an immunochemiluminescence assay.** *MS thesis, Utrecht University*, 2014.
- 12 Niessen SJ, Petrie G, Gaudiano F, et al. **Feline acromegaly: an underdiagnosed endocrinopathy?** *J Vet Intern Med* 2007; 21: 899–905.
- 13 Nadimi S, Molazem M, Jarolmasjed S, et al. **Volumetric evaluation of pituitary gland in dog and cat using computed tomography.** *Vet Res Forum* 2018; 9: 337–341.
- 14 Jamal GA, Kerr DJ, McLellan AR, et al. **Generalised peripheral nerve dysfunction in acromegaly: a study by conventional and novel neurophysiological techniques.** *J Neurol Neurosurg Psychiatry* 1987; 50: 886–894.
- 15 Prencipe N, Floriani I, Guaraldi F, et al. **ACROSCORE: a new and simple tool for the diagnosis of acromegaly, a rare and underdiagnosed disease.** *Clin Endocrinol (Oxf)* 2016; 84: 380–385.
- 16 Alibas H, Gogas Yavuz D, Kahraman Koytak P, et al. **Peripheral nervous system assessment in acromegaly patients under somatostatin analogue therapy.** *J Endocrinol Invest* 2017; 40: 33–40.
- 17 Melancia JL, Francisco AF and Antunes JL. **Spinal stenosis.** In: Biller J and Ferro J (eds). *Handbook of clinical neurology*. Elsevier, 2014, pp 541–549.