

# Epidemiologic and Clinical Characteristics of Optic Neuritis in Japan

著者 (英)	Kiyotaka NAKAMAGOE
journal or publication title	Ophthalmology
volume	126
number	10
page range	1385-1398
year	2019-10
権利	(C) 2019 by the American Academy of Ophthalmology This is an open access article under the CC BY-NC-ND license ( <a href="http://creativecommons.org/licenses/by-nc-nd/4.0/">http://creativecommons.org/licenses/by-nc-nd/4.0/</a> ). Published by Elsevier Inc.
URL	<a href="http://hdl.handle.net/2241/00159732">http://hdl.handle.net/2241/00159732</a>

doi: 10.1016/j.ophtha.2019.04.042



# Epidemiologic and Clinical Characteristics of Optic Neuritis in Japan

Hitoshi Ishikawa, MD, PhD,<sup>1</sup> Takeshi Kezuka, MD, PhD,<sup>2</sup> Keigo Shikishima, MD, PhD,<sup>3</sup> Akiko Yamagami, MD,<sup>4</sup> Miki Hiraoka, MD, PhD,<sup>5</sup> Hideki Chuman, MD, PhD,<sup>6</sup> Makoto Nakamura, MD, PhD,<sup>7</sup> Keika Hoshi, DDS, PhD,<sup>8,9</sup> Toshiaki Goseki, MD, PhD,<sup>10</sup> Kimiyo Mashimo, BS,<sup>11</sup> Osamu Mimura, MD, PhD,<sup>12</sup> Takeshi Yoshitomi, MD, PhD,<sup>13</sup> Keiko Tanaka, MD, PhD,<sup>14</sup> on behalf of the Working Group on Diagnostic Criteria for Refractory Optic Neuritis Based on Neuroimmunological Perspective\*

**Purpose:** To elucidate the clinical and epidemiologic characteristics of optic neuritis in Japan.

**Design:** Multicenter cross-sectional, observational cohort study.

**Participants:** A total of 531 cases of unilateral or bilateral noninfectious optic neuritis identified in 33 institutions nationwide in Japan.

**Methods:** Serum samples from patients with optic neuritis were tested for anti-aquaporin-4 antibodies (AQP4-Abs) and anti-myelin oligodendrocyte glycoprotein antibodies (MOG-Abs) using a cell-based assay and were correlated with the clinical findings.

**Main Outcome Measures:** Antibody positivity, clinical and radiologic characteristics, and visual outcome.

**Results:** Among 531 cases of optic neuritis, 12% were AQP4-Ab positive, 10% were MOG-Ab positive, 77% were negative for both antibodies (double-negative), and 1 case was positive for both antibodies. Pretreatment visual acuity (VA) worsened to more than a median 1.0 logarithm of the minimum angle of resolution (logMAR) in all groups. After steroid pulse therapy (combined with plasmapheresis in 32% of patients in AQP4-Ab-positive group), median VA improved to 0.4 logMAR in the AQP4-Ab-positive group, 0 logMAR in the MOG-Ab-positive group, and 0.1 logMAR in the double-negative group. The AQP4-Ab-positive group showed a high proportion of females, exhibited diverse visual field abnormalities, and demonstrated concurrent spinal cord lesions on magnetic resonance imaging (MRI) in 22% of the patients. In the MOG-Ab-positive group, although posttreatment visual outcome was good, the rates of optic disc swelling and pain with eye movement were significantly higher than those in the AQP4-Ab-positive and double-negative groups. However, most cases showed isolated optic neuritis lesions on MRI. In the double-negative group, 4% of the patients had multiple sclerosis. Multivariate logistic regression analysis of all participants identified age and presence of antibodies (MOG-Ab and AQP4-Ab) as significant factors affecting visual outcome.

**Conclusions:** The present large-scale cohort study revealed the clinicoepidemiologic features of noninfectious optic neuritis in Japan. Anti-aquaporin-4 antibody-positive optic neuritis has poor visual outcome. In contrast, MOG-Ab positive cases manifested severe clinical findings of optic neuritis before treatment, but few showed concurrent lesions in sites other than the optic nerve and generally showed good treatment response with favorable visual outcome. These findings indicate that autoantibody measurement is useful for prompt diagnosis and proper management of optic neuritis that tends to become refractory. *Ophthalmology* 2019;126:1385-1398 © 2019 by the American Academy of Ophthalmology. This is an open access article under the CC BY-NC-ND license (<http://creativecommons.org/licenses/by-nc-nd/4.0/>).

The previous large-scale nationwide epidemiologic survey of optic neuritis in Japan, the Optic Neuritis Trial Multicenter Cooperative Research Group Japan, dates back to 1995. According to the Optic Neuritis Trial Multicenter Cooperative Research Group Japan report, the incidence of optic neuritis in Japan is estimated to be 1.03 per 100 000 population.<sup>1</sup> Among 550 patients analyzed, the male-to-female ratio was 1:1.22, 65.9% of the patients were 14 to 55 years of age, 28.2% showed bilateral disease, 18.6% were recurrent cases, and 7.5% had a history of optic neuritis in the contralateral eye. However, these data should consider the situations at the time of survey: magnetic resonance imaging (MRI) and genetic diagnosis for Leber's

hereditary optic neuropathy were not widely available, and neuromyelitis optica (NMO) was included as a subtype of multiple sclerosis (MS). Epidemiologic studies of optic neuritis in other countries report annual incidences (per 100 000 population) of 0.942 in Finland,<sup>2</sup> 1.46 in Sweden,<sup>3</sup> and 1 in the United Kingdom.<sup>4</sup> There is a slight female preponderance worldwide.

In 2004, Lennon et al<sup>5</sup> discovered anti-aquaporin-4 antibodies (AQP4-Abs) as a pathogen of NMO and distinguished NMO as a completely different entity from MS. Thereafter, AQP4-Ab seropositive cases of NMO were found to be more severe and resistant to treatment.<sup>6</sup> In addition, recent reports have shown that among patients

with AQP4-Ab-negative NMO, those with optic neuritis showing good a response to treatment but a high recurrence rate show positive results for anti-myelin oligodendrocyte glycoprotein antibodies (MOG-Abs),<sup>7–11</sup> which have revolutionized the understanding of optic neuritis. Hence, there is a necessity to update epidemiologic characteristics of optic neuritis in Japan. In this regard, our study group sought to reinvestigate the epidemiologic and clinical characteristics of optic neuritis in Japan based on the neuroimmunologic background.

In this study, we analyzed a total of 531 cases of unilateral or bilateral noninfectious optic neuritis identified at 33 institutions nationwide in Japan. However, it should be noted that although the sample was large and represented diverse geography in Japan, this study was not a population-based survey. The aim of this study was to elucidate the frequencies and clinical features of AQP4-Ab-positive optic neuritis, MOG-Ab-positive optic neuritis, or both, which are important causes of optic neuritis, and to compare our data with data from abroad, with the ultimate goal of establishing effective treatments and optimal prophylaxis for recurrence in the future.

## Methods

### Participants

Thirty-three facilities participated in this study, of which 30 were ophthalmology centers and 3 were neurology centers. The facilities were distributed nationwide from Hokkaido in the north to Kyushu in the south, covering 20 of 47 prefectures of Japan, and were affiliated hospitals of councilors of the Japanese Neuro-ophthalmology Society. Development of the common consensus contents of this research was led by Kitasato University and the Japanese Neuro-Ophthalmology Society. Because the cases were collected from 6 main regions in Japan divided by geography, climate, and culture (Hokkaido, Tohoku, Kanto-Koshinetsu, Chubu-Kansai, Chugoku-Shikoku, and Kyushu), we speculate that the case series was a good representation of all patients with a diagnosis of optic neuritis receiving care at medical institutions in Japan. The research was approved by the ethics committee of each participating university (representative: Kitasato University B 14-228). All studies adhered to the tenets of the Declaration of Helsinki. All participants provided informed consent.

A total of 571 Japanese patients with noninfectious optic neuritis who sought treatment at the 33 facilities because of unilateral or bilateral vision deterioration between April 2015 and January 2018 were included, and serum samples were collected. The diagnosis of optic neuritis was based on the following criteria: (1) acute visual disturbance or visual field defect, (2) presence of a relative afferent pupillary defect in unilateral cases, (3) reduced critical fusion frequency, and (4) normal or swollen optic disc. Patients with cataract, glaucoma, or retinal diseases were excluded.

Serum samples were collected before initiation of treatment and assayed for AQP4-Ab and MOG-Ab by methods described below. In this study, we analyzed and evaluated the findings of the affected eyes in patients with unilateral optic neuritis and the eyes that were affected more seriously (higher activity) in patients with bilateral optic neuritis.

### Antibody Assays

Presence of MOG-Ab was measured using a cell-based assay at Kanazawa Medical University and Niigata University by an

investigator (K.T.) masked to the clinical information of the patients, according to the method described previously.<sup>12</sup> In brief, a full-length human myelin oligodendrocyte glycoprotein cDNA expression vector (a gift from Dr. M. Reindl, Innsbruck Medical University, Innsbruck, Austria) was transfected into human embryonic kidney 293 cells using Lipofectamine reagent (Invitrogen Japan, Tokyo, Japan). Cell cultures were maintained in Dulbecco's modified Eagle's medium (Sigma-Aldrich, Tokyo, Japan) supplemented with 10% fetal calf serum. Twelve hours after transfection, the human embryonic kidney cells were fixed in 4% paraformaldehyde in 0.1 M phosphate-buffered saline (pH, 7.4) for 20 minutes. Nonspecific binding was blocked with 10% goat serum in phosphate-buffered saline. Thereafter, the cells were incubated with patient sera diluted 1:50 in 0.02% Triton X-100/10% goat serum in phosphate-buffered saline for 1 hour at room temperature, followed by fluorescence-conjugated anti-human immunoglobulin G1 (dilution, 1:500; Dako Denmark, Glostrup, Denmark) for 1 hour. SlowFade Gold anti-fade reagent (Invitrogen) was then applied to the slides, which were mounted and observed under a fluorescence microscope (AxioVision; Carl Zeiss Microscopy, Jena, Germany). The presence of green fluorescence on the cells was scored as MOG-Ab seropositivity. Serum anti-AQP4 IgG antibody levels were measured by a previously reported indirect immunofluorescence assay using human embryonic kidney 293 cells transfected with an expression vector containing M23 human aquaporin-4 cDNA.<sup>13</sup>

### Clinical Parameters

At the same time, the clinical course survey reports were collected. The antibody status and clinical data were correlated to analyze the characteristics of various types of optic neuritis. The group that showed negative results for both AQP4-Ab and MOG-Ab was considered to show idiopathic optic neuritis, but this group also included patients with clinically definite MS (CDMS) and clinically isolated syndrome (CIS),<sup>14–16</sup> although none demonstrated optic neuropathy associated with systemic sarcoidosis.<sup>17</sup> Diagnosis of MS was conducted carefully, chiefly by neurologists at individual centers. Clinically definite MS was diagnosed according to the 2010 revisions to the McDonald criteria.<sup>18</sup> None of the patients with positive AQP4-Ab and MOG-Ab results were diagnosed with CDMS or CIS.

Pretreatment visual acuity (VA) was defined as the worst data (nadir) obtained before treatment during the study period. Post-treatment VA was defined as the best VA obtained after treatment during the study period.

As for the imaging conditions for MRI, gadolinium imaging was used as far as possible.<sup>19</sup> However, when contrast medium could not be used because of contrast agent hypersensitivity and other conditions, a short  $\tau$  inversion recovery sequence was used. Whether ocular MRI, head MRI, or both were performed was decided by the doctor in charge at an individual center. Only ocular MRI was available for 41 patients, only head MRI was available for 9 patients, and both were available for 403 patients.

Basically, patients were treated with steroid pulse therapy at a dose of 1000 mg for 3 days, followed by tapering with oral prednisolone starting from 40 to 60 mg. When there was no therapeutic response, usually this treatment was repeated after an interval of 4 days. Patients who did not respond to steroid pulse therapy were given plasmapheresis in combination. Indication for plasmapheresis and the timing of treatment were decided by individual facilities.

### Statistical Analyses

Statistical analyses were conducted using the statistics software package JMP version 13 (SAS Institute, Inc, Cary, NC). For

statistical analyses, VA was presented in logarithm of the minimum angle of resolution (logMAR) units, where counting fingers (CF) was converted to 2.6 logMAR, hand movements was converted to 2.9 logMAR, light perception was converted to 3.1 logMAR, and no light perception was converted to 3.4 logMAR.<sup>20</sup> For intergroup comparisons, the Fisher exact test was used for nominal variables and the Steel-Dwass test and Welch *t* test were used for continuous variables, depending on the distribution in each group. Specifically, the Fisher exact test was used to compare among AQP4-Ab-positive, MOG-Ab-positive, and double-negative groups for the following variables (all proportions of patients): women, pretreatment VA of CF or worse, optic disc swelling, pain during eye movement, visual field abnormalities, treatment with steroid, posttreatment VA of CF or worse, posttreatment VA of 0.5 or more, posttreatment VA of 0.2 or more, autoantibodies other than AQP4-Ab and MOG-Ab, optic nerve swelling on MRI, sites of optic nerve lesion on MRI, and length of optic nerve lesion on MRI. The Steel-Dwass test was used to compare age, age at onset, pretreatment VA, and posttreatment VA among the 3 groups. The Welch test was used to examine pretreatment and posttreatment VA comparing presence versus absence of optic nerve swelling and lesion length of one half or more versus less than one half. The Student *t* test was used to compare age at onset between men and women in each antibody group. A *P* value of less than 0.05 was considered significant for 2-group comparisons. For 3-group comparisons (AQP4-Ab vs. MOG-Ab vs. double-negative groups), Bonferroni correction was conducted, and *P* < 0.016 (0.05/3) was considered significant. In addition, for all patients in the 3 groups, Spearman's rank correlation was used to analyze the correlation between age and VA, and these were compared before and after treatment. In addition, multivariate logistic regression analysis was conducted to identify the factors influencing visual outcome.

## Results

Initially 571 patients diagnosed with noninfectious optic neuritis were recruited. However, in 40 patients, the diagnosis was subsequently changed to ischemic, compressive, hereditary, or toxic optic neuropathy, and these patients were excluded. Eventually, 531 patients were studied, and 531 blood samples were analyzed for antibody serostatus. In addition, the number of patients in various analyses as detailed below differed depending on the testing conditions and status of entry in clinical course survey reports.

### Rates of Positive Results for Anti-Aquaporin-4 Antibodies and Anti-Myelin Oligodendrocyte Glycoprotein Antibodies

Among 531 serum samples analyzed, 66 (12%) showed AQP4-Ab-positive results, 54 (10%) showed MOG-Ab-positive results, 410 (77%) showed both AQP4-Ab- and MOG-Ab-negative results (double-negative group), and 1 sample was both AQP4-Ab- and MOG-Ab-positive (double-positive group). In the double-negative group (*n* = 410), 15 patients (4%) demonstrated clinically definite MS and 18 patients (4%) demonstrated CIS (Table 1).

### Age and Male-to-Female Ratio

All the clinical parameters were compared among the AQP4-Ab-positive, MOG-Ab-positive, and double-negative groups (Table 1). There was no significant difference in median age among the 3 groups. The proportion of female patients was 84%

in the AQP4-Ab-positive group and significantly higher than in the MOG-Ab-positive group (51%) and double-negative group (64%; AQP4-Ab-positive vs. MOG-Ab-positive group, *P* = 0.0003, Fisher exact test; AQP4-Ab-positive vs. double-negative group, *P* = 0.0014, Fisher exact test). In addition, when comparing the mean onset ages of male and female patients in each group, female patients were significantly older than male patients in the AQP4-Ab-positive group (55.8 years vs. 42.8 years; *P* = 0.024, Student *t* test). The distribution of patients' ages at onset is shown in Figure 1. The AQP4-Ab-positive group showed a trend of increase with age. The MOG-Ab-positive group showed biphasic peaks in the fourth and sixth decades of life groups. The double-negative group showed a uniform distribution among almost all age groups. The youngest patient, 3 years of age, was in the MOG-Ab-positive group, and the oldest patient, 84 years of age, was in the AQP4-Ab-positive group.

### Pretreatment Visual Acuity

Visual acuity in the AQP4-Ab-positive group was lower compared with the double-negative group (2.6 vs. 1.2; *P* < 0.0001, Steel-Dwass test; Table 1). In addition, 53% of patients in the AQP4-Ab-positive group showed a VA of CF or worse, and the percentage was significantly higher than in the MOG-Ab-positive and double-negative groups (25% and 22%, respectively; AQP4-Ab-positive vs. MOG-Ab-positive group, *P* = 0.008, Fisher exact test; AQP4-Ab-positive vs. double-negative group, *P* < 0.0001, Fisher exact test).

### Optic Disc Swelling and Pain during Eye Movement at Presentation

In the MOG-Ab-positive group, the frequencies of optic disc swelling (76%) and pain during eye movement or orbital pain (77%) were both significantly higher compared with the AQP4-Ab-positive group (34% and 53%, respectively) and double-negative group (46% and 46%, respectively; MOG-Ab-positive vs. AQP4-Ab-positive group, *P* < 0.0001 and *P* = 0.0148, respectively, Fisher exact test; MOG-Ab-positive vs. double-negative group, *P* = 0.0002 and *P* = 0.0001, respectively, Fisher exact test; Table 1).

### Visual Field Abnormalities

In the MOG-Ab-positive group, the vast majority (95%) of the patients demonstrated central scotoma or complete visual field loss. However, in the AQP4-Ab-positive optic neuritis group, the patients not only demonstrated central scotoma but also various patterns of visual field abnormalities (Table 1).

### Treatments

Methylprednisolone pulse therapy was administered in 82% of all patients in this study: 89% in the AQP4-Ab-positive group, 86% in the MOG-Ab-positive group, and 80% in the double-negative group. Furthermore, plasmapheresis was added to pulse steroid therapy in 32% of the patients in the AQP4-Ab-positive group. All patients who underwent plasmapheresis were treated with pulse steroid therapy in combination (Table 1).

### Posttreatment Visual Acuity

There was no significant difference in posttreatment VA among the 3 groups (Table 1). However, in the AQP4-Ab-positive group, 22% of the patients showed posttreatment VA of CF or worse, and this proportion was significantly higher compared with the double-negative group (8%; *P* = 0.0051, Fisher exact test). In the MOG-Ab-positive group, VA recovered to

Table 1. Serostatus of Anti-Aquaporin-4 Antibody and Anti-Myelin Oligodendrocyte Glycoprotein Antibody in Japanese Patients with Optic Neuritis and Comparison of Clinical Parameters among 3 Groups

Total (n = 531, Including 1 Double-Positive Patient)	Anti-Aquaporin-4 Antibody-Positive Group	Anti-Myelin Oligodendrocyte Glycoprotein Antibody-Positive Group	Double-Negative Group*	P Value <sup>†</sup>			Statistical Method
				Anti-Aquaporin-4 Antibody-Positive Group vs. Anti-Myelin Oligodendrocyte Glycoprotein Antibody-Positive Group	Anti-Aquaporin-4 Antibody-Positive Group vs. Double-Negative Group	Anti-Myelin Oligodendrocyte Glycoprotein Antibody-Positive Group vs. Double-Negative Group	
No. of antibody positive/total no. of samples (%)	66/531 (12)	54/531(10)	410/531 (77)	0.2448	<0.0001 <sup>‡</sup>	<0.0001 <sup>‡</sup>	Fisher exact test
Age (yrs), median (range)	52.5 (13–84)	47.0 (3–82)	47.5 (4–87)	0.0981	0.1253	0.5269	Steel-Dwass test
No. of females/total (%)	52/62 (84)	25/49 (51)	247/388 (64)	0.0003 <sup>‡</sup>	0.0014 <sup>‡</sup>	0.0883	Fisher exact test
Age at onset, mean ± SD (no. of patients/total)							
Male	42.8±21.9 (10/62)	41.1±22.2 (24/49)	49.6±15.8 (139/388)	0.9874	0.4651	0.1622	Steel-Dwass test
Female	55.8±15.1 (52/62)	48.4±18.8 (25/49)	48.1±20.3 (245/388)	0.2551	0.0368 <sup>‡</sup>	0.9999	Steel-Dwass test
P value, Student t test	0.0241 <sup>§</sup>	0.2159	0.4586				
Pretreatment VA, median (IQR)	2.6 (1.2–3.1) (n = 59)	1.6 (0.7–2.5) (n = 44)	1.2 (0.5–2.0) (n = 357)	0.1431	<0.0001 <sup>‡</sup>	0.2646	Steel-Dwass test
Proportion of pretreatment VA CF or worse, no. of patients/total (%)	31/59 (53)	11/44 (25)	80/357 (22)	0.0080 <sup>‡</sup>	<0.0001 <sup>‡</sup>	0.7043	Fisher exact test
Optic disc swelling, no. of patients/total (%)	21/61 (34)	34/45 (76)	166/361 (46)	<0.0001 <sup>‡</sup>	0.0968	0.0002 <sup>‡</sup>	Fisher exact test
Pain during eye movement, no. of patients/total (%)	31/59 (53)	36/47 (77)	161/347 (46)	0.0148 <sup>‡</sup>	0.4004	0.0001 <sup>‡</sup>	Fisher exact test
Visual field, no. of patients/total (%)							
Complete visual field loss	14/55 (26)	9/41 (22)	45/311 (15)	0.8101	0.0478	0.2467	Fisher exact test
Central scotoma	25/55 (46)	30/41 (73)	194/311 (61)	0.0074 <sup>‡</sup>	0.0246	0.2267	Fisher exact test
Temporal hemianopia	4/55 (7)	0/41 (0)	12/311 (4)	0.2122	0.4331	0.4111	Fisher exact test
Altitudinal hemianopia	12/55 (22)	1/41 (2)	46/311 (15)	0.0145 <sup>‡</sup>	0.2276	0.0522	Fisher exact test
Nasal hemianopia	0/55 (0)	1/41 (2)	14/311 (5)	0.8822	0.2328	0.8685	Fisher exact test
Treatment, no. of patients/total (%)							
Pulse steroid only	32/56 (57)	35/42 (83)	247/333 (74)	0.0081 <sup>‡</sup>	0.0153 <sup>‡</sup>	0.2554	Fisher exact test
Plasmapheresis + pulse steroid	18/56 (32)	1/42 (2)	19/333 (6)	0.0002 <sup>‡</sup>	<0.0001 <sup>‡</sup>	0.5897	Fisher exact test
Observation	6/56 (11)	6/42 (14)	67/333 (20)	0.7571	0.1370	0.5343	Fisher exact test
Posttreatment VA							
Median (IQR)	0.398 (–0.079 to 2) (n = 54)	0 (–0.079 to 0.523) (n = 39)	0.097 (–0.079 to 1) (n = 314)	0.0244	0.1286	0.1082	Steel-Dwass test
CF or worse, no. of patients/total (%)	12/54 (22)	2/39 (5)	25/314 (8)	0.0476	0.0051 <sup>‡</sup>	0.7577	Fisher exact test
≥0.5, no. of patients/total (%)	30/54 (56)	32/39 (82)	215/314 (69)	0.0082 <sup>‡</sup>	0.0849	0.0960	Fisher exact test
≥0.2, no. of patients/total (%)	24/54 (44)	29/39 (74)	176/314 (56)	0.0056 <sup>‡</sup>	0.1390	0.0380	Fisher exact test
Autoantibodies other than AQP4-Ab and MOG-Ab, no. of patients/total (%)							
Antinuclear antibody (+)	16/49 (33)	7/35 (20)	65/272 (24)	0.2249	0.2123	0.6780	Fisher exact test
SS-A-Ab (+)	8/46 (17)	0/28 (0)	7/238 (3)	0.0511	0.0007 <sup>‡</sup>	0.7675	Fisher exact test
SS-B-Ab (+)	1/45 (2)	0/28 (0)	2/234 (1)	0.8095	0.9797	0.5107	Fisher exact test

Table 1. (Continued.)

	P Value <sup>†</sup>				Statistical Method
	Anti-Aquaporin-4 Antibody-Positive Group vs. Anti-Myelin Oligodendrocyte Glycoprotein Antibody-Positive Group	Anti-Aquaporin-4 Antibody-Positive Group vs. Double-Negative Group	Anti-Myelin Oligodendrocyte Glycoprotein Antibody-Positive Group vs. Double-Negative Group	Anti-Myelin Oligodendrocyte Glycoprotein Antibody-Positive Group vs. Double-Negative Group	
Total (n = 531, Including 1 Double-Positive Patient)					
TPO-Ab	3/37 (8)	34/210 (16)	2/24 (8)	0.6653	Fisher exact test
Tg-Ab (+)	4/33 (12)	32/200 (16)	2/22 (9)	0.9296	Fisher exact test
Rheumatoid factor (+)	3/41 (7)	16/227 (7)	5/28 (18)	0.3371	Fisher exact test

AQP4-Ab = anti-aquaporin-4 antibody; CF = counting fingers; IQR = interquartile range; MOG-Ab = anti-myelin oligodendrocyte glycoprotein antibody; SD = standard deviation; SS-A-Ab = anti-Sjögren's syndrome-related antigen A antibody; SS-B-Ab = anti-Sjögren's syndrome type B antibody; TPO-Ab = antiperoxidase antibody; Tg-Ab = antithyroglobulin antibody; VA = visual acuity; + = positive.

Visual acuity is expressed in logarithm of the minimum angle of resolution units.

\*Negative results for AQP4-Ab and MOG-Ab.

<sup>†</sup>Significant level at  $P < 0.016$ , Bonferroni correction for 3-group comparison.

<sup>‡</sup>Significant difference ( $P < 0.016$ ).

<sup>§</sup>Significant difference,  $P < 0.05$ , age at onset for males vs. females (blue line), Student *t* test.

0.5 (decimal VA, 0.3) or higher in 82% of the patients and 0.2 (decimal VA, 0.7) or higher in 74%. The rate of recovery to 0.5 or more was significantly higher in the MOG-Ab-positive group than in the AQP4-Ab-positive group (82% vs. 56%;  $P = 0.0082$ , Fisher exact test).

### Autoantibodies Other Than Anti-Aquaporin-4 Antibodies and Anti-Myelin Oligodendrocyte Glycoprotein Antibodies

When positive rates of autoantibodies other than AQP4-Ab and MOG-Ab were compared among the 3 groups, the positive rate for anti-Sjögren's syndrome-related antigen A (SS-A) antibody was significantly higher in the AQP4-Ab-positive group than in the double-negative group (17% vs. 3%;  $P = 0.0007$ , Fisher exact test). In the MOG-Ab-positive group, none of the patients showed positive results for SS-A antibody or anti-Sjögren's syndrome type B antibody (Table 1).

### Magnetic Resonance Imaging Findings

The frequency of optic nerve swelling on MRI was significantly higher in the MOG-Ab-positive group than in the double-negative group (91% vs. 67%;  $P = 0.0007$ , Fisher exact test; Table 2). Regarding the lesion site, more patients in the AQP4-Ab-positive group showed posterior lesions, whereas more patients in the MOG-Ab-positive group showed anterior lesions. In both the AQP4-Ab-positive and MOG-Ab-positive groups, the lengths exceeded one half of the intraorbital optic nerve length in more than 60% of the lesions.

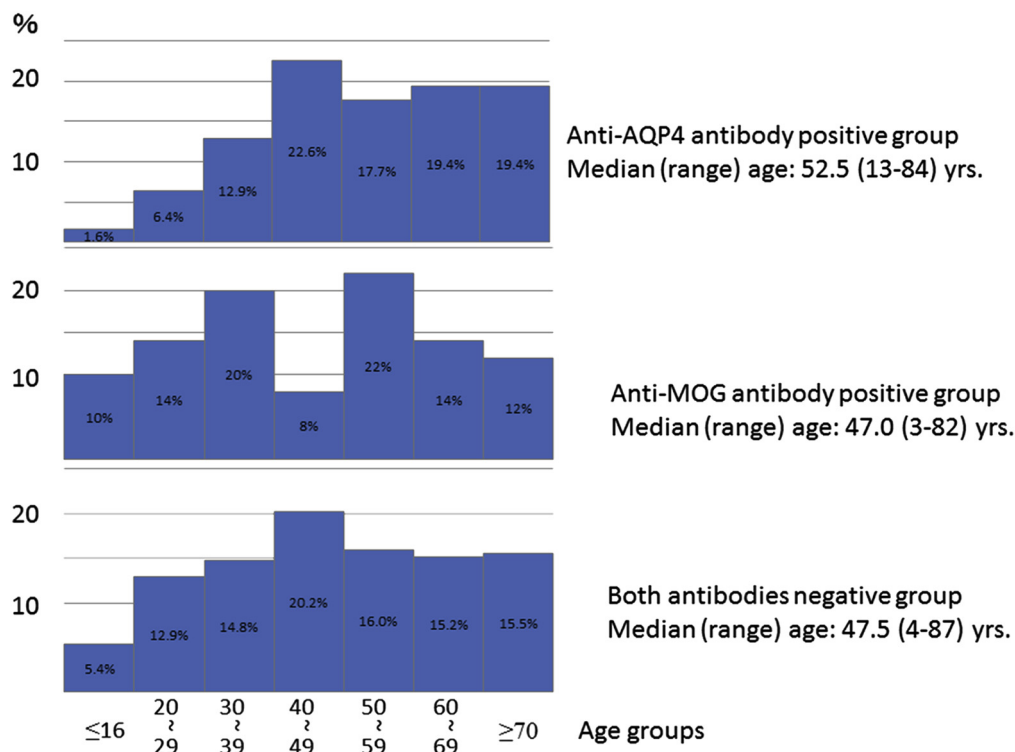
In the AQP4-Ab positive group, extra-optic nerve lesions were observed in the cerebral white matter, brainstem, and spinal cord; in particular, concurrent spinal cord lesions were found in 8 patients (22%). Among these 8 patients, 1 patient showed longitudinally extensive transverse myelitis. In the double-negative group, lesions were found mainly in the cerebral white matter, but also in the brainstem, spinal cord, and cerebellum. However, in the MOG-Ab-positive group, extra-optic nerve lesions were found in only 3 patients: cerebral white matter lesion in 1 patient (2%) and spinal cord lesion in 2 patients (8%).

### Effect of Optic Disc Swelling and Magnetic Resonance Imaging Lesion Length on Visual Acuity

In the AQP4-Ab-positive group, patients with pretreatment optic disc swelling showed significant improvement in posttreatment VA compared with patients without optic disc swelling (0.071 vs. 1;  $P = 0.0443$ , Welch test; Table 3). Furthermore, in the double-negative group, patients with pretreatment lesion length on MRI exceeding one half of the intraorbital optic nerve length showed significantly poorer VA both before (1.301 vs. 1;  $P = 0.0211$ , Welch test) and after (0.046 vs. -0.079;  $P = 0.0106$ , Welch test) treatment compared with patients with lesion length less than one half of the intraorbital optic nerve length.

### Correlation between Age and Visual Acuity

Spearman's rank correlation was conducted to examine the correlation between age and VA using the data of all the patients analyzed. The results showed that both pretreatment and post-treatment VA decreased significantly as age increased (Fig 2).



**Figure 1.** Graphs showing distributions of patients by age at onset in each group. The anti-aquaporin-4 antibody (AQP4-Ab)-positive rate tends to increase with age until the fifth decade, followed by a plateau. The anti-myelin oligodendrocyte glycoprotein antibody (MOG-Ab)-positive rate shows a biphasic distribution peaking in the fourth and sixth decades. The double-negative rate shows almost uniform distribution from the third to eighth decades. y-axis = antibody positive rate.

### Factors Affecting Visual Outcome

Multivariate logistic regression analysis was conducted to identify factors affecting the visual outcome using the data of all the patients analyzed. In model 1, age and presence or absence of antibodies (AQP4-Ab and MOG-Ab) were used as explanatory variables. In model 2, in addition to age and antibody status, lesion length on MRI and presence or absence of the optic disc swellings were included as explanatory variables (Table 4).

For model 1, in the first case, when posttreatment VA remained worse than CF, the odds ratio for recovery to CF decreased by 0.97-fold with a 1-year increase in age, and furthermore, the presence of AQP4-Ab significantly impeded recovery. In the second case, for recovery to posttreatment VA of 0.1 (decimal VA, approximately 0.7), age again showed a significant effect (decreased by 0.96-fold with 1-year increase in age), whereas the presence of MOG-Ab significantly increased the odds ratio. For model 2, age remained a significant factor in the both the first and second cases above, with lesion length on MRI being extracted additionally as a significant factor in the second case.

### One Patient with Anti-Myelin Oligodendrocyte Glycoprotein Antibody- and Anti-Aquaporin-4 Antibody-Positive (Double-Positive) Optic Neuritis

In the present study, 1 patient with MOG-Ab- and AQP4-Ab-positive (double-positive) optic neuritis was identified. The patient was a 24-year-old woman who lost light perception because of optic neuritis in the right eye at 13 years of age. At 18 years of age, she demonstrated optic neuritis in the left eye and was found to show

AQP4-Ab-positive results. She was treated with steroid pulse therapy at 1000 mg/day for 3 days. After 3 courses, decimal VA recovered to 1.5. At 22 years of age, she visited the hospital again because of recurrent left optic neuritis. Because the time of her visit was within our study period, this patient was included in our study. Examination of her blood sample revealed that she also showed MOG-Ab-positive results. For that episode, she received 2 courses of steroid pulse therapy (1000 mg/day for 3 days per course) with inadequate response. Subsequently, intravenous immunoglobulin therapy improved VA. Thereafter, she has been observed while undergoing treatment with a combination of steroid and immunosuppressant (azathioprine) therapy. Apart from ocular findings, no other abnormalities were observed during follow-up.

### Discussion

#### Rates of Anti-Aquaporin-4 Antibody- and Anti-Myelin Oligodendrocyte Glycoprotein Antibody-Positive Results

In the present study, 531 patients could be analyzed. Among these patients, the AQP4-Ab-positive rate was 12%, with median age at onset of 53 years, and the MOG-Ab-positive rate was 10%, with median age at onset of 47 years. The double-negative group occupied 77% and included 15 patients (4%) with clinically definite MS and 18 patients (4%) with CIS. The median age at onset in the double-negative group was 48 years, and there was no significant difference in age at onset among the 3 groups. The distribution

Table 2. Comparison of Magnetic Resonance Imaging Findings among the 3 Groups

Magnetic Resonance Imaging Findings	Anti-Aquaporin-4 Antibody-Positive Group	Anti-Myelin Oligodendrocyte Glycoprotein Antibody-Positive Group	Double-Negative Group*	P Value <sup>†</sup>			Statistical Method
				Anti-Aquaporin-4 Antibody-Positive Group vs. Anti-Myelin Oligodendrocyte Glycoprotein Antibody-Positive Group	Anti-Aquaporin-4 Antibody-Positive Group vs. Double-Negative Group	Anti-Myelin Oligodendrocyte Glycoprotein Antibody-Positive Group vs. Double-Negative Group	
Optic nerve swelling	42/51 (82) <sup>‡</sup>	39/43 (91)	209/314 (67)	0.3856	0.0232	0.0007 <sup>§</sup>	Fisher exact test
Site of optic nerve lesion							
Anterior	9/37 (24)	14/32 (44)	75/185 (41)	0.1249	0.0666	0.8460	Fisher exact test
Posterior	18/37 (49)	7/32 (22)	82/185 (44)	0.0257	0.7181	0.0194	Fisher exact test
Entire length	10/37 (27)	11/32 (34)	28/185 (15)	0.6030	0.0946	0.0218	Fisher exact test
Optic chiasma (overlap in some cases)	5/50 (10)	3/39 (8)	17/313 (6)	0.9967	0.2053	0.8349	Fisher exact test
Length of optic nerve lesion							
Long (more than half of orbital length)	24/36 (67)	20/33 (61)	88/187 (47)	0.6254	0.0443	0.1868	Fisher exact test
Short (less than half of orbital length)	12/36 (33)	13/33 (39)	99/187 (53)	0.6254	0.0443	0.1868	Fisher exact test
Site of extraoptic nerve lesion							
Cerebral cortex lesion	5/51 (10)	1/42 (2)	50/321 (16)	0.3049	0.3950	0.0377	Fisher exact test
Brainstem lesion	3/50 (6)	0/37 (0)	16/309 (5)	0.3565	0.9202	0.3158	Fisher exact test
Spinal cord lesion	8/36 (22)	2/26 (8)	19/191 (10)	0.2360	0.0488	0.9909	Fisher exact test
Cerebellum lesion	0/50 (0)	0/37 (0)	9/305 (3)	—	0.4562	0.6064	Fisher exact test

\*Negative results for anti-aquaporin-4 antibody and anti-myelin oligodendrocyte glycoprotein antibody.

<sup>†</sup>Significant at  $P < 0.016$ , Bonferroni correction for 3-group comparison.

<sup>‡</sup>All data are expressed as number with (positive) finding/total number tested (%).

<sup>§</sup>Significant difference ( $P < 0.016$ ).



Table 3. Effects of Status of Disc Swelling and Magnetic Resonance Imaging Lesion Length on Visual Acuity

	Anti-Aquaporin-4 Antibody-Positive Group	Anti-Myelin Oligodendrocyte Glycoprotein Antibody-Positive Group	Double-Negative Group*
Effect of disc swelling on VA			
Pretreatment VA, median (IQR) (no. of patients/total no.)			
With optic disc swelling	1.699 (0.611–3.1) (21/59)	1.523 (0.73–2) (32/43)	1.222 (0.533–2.499) (161/349)
Without optic disc swelling	2.9 (1.398–3.1) (38/59)	2 (0.753–3.1) (11/43)	1.046 (0.567–2) (188/349)
P value	0.1553	0.6923	0.1763
Posttreatment VA			
With optic disc swelling	0.071 (–0.079 to 1.165) (18/53)	0.079 (–0.079 to 0) (27/37)	0.046 (–0.079 to 0.730) (134/299)
Without optic disc swelling	1 (–0.079 to 2.9) (35/53)	0.097 (–0.079 to 0.567) (10/37)	0.097 (–0.079 to 1) (165/299)
P value	0.0443 <sup>†</sup>	0.0877	0.7312
Effect of MRI lesion length on visual acuity			
Pretreatment VA, median (IQR) (no. of patients/total no.)			
Lesion length half or more	3 (0.523–3.4) (22/34)	1.097 (0.523–3.1) (19/32)	1.301 (0.699–2.9) (87/184)
Lesion length less than half	2 (1.191–3.05) (12/34)	2 (1.261–3.15) (13/32)	1 (0.301–2) (97/184)
P value	0.7012	0.1546	0.0211 <sup>†</sup>
Posttreatment VA			
Lesion length half or more	1.023 (–0.02 to 3.025) (22/34)	–0.079 (–0.079 to 0) (16/27)	0.046 (–0.079 to 1.242) (74/161)
Lesion length less than half	–0.079 (–0.079 to 1) (12/34)	0.046 (–0.079 to 0.824) (11/27)	–0.079 (–0.079 to 0.155) (87/161)
P value	0.1196	0.1756	0.0106 <sup>†</sup>

IQR = interquartile range; MRI = magnetic resonance imaging; VA = visual acuity expressed in logarithm of the minimum angle of resolution units.

\*Negative results for anti-aquaporin-4 antibody and anti-myelin oligodendrocyte glycoprotein antibody.

<sup>†</sup>Significant difference,  $P < 0.05$ , Welch  $t$  test.

patterns of age at onset differed in the 3 groups. The proportion of patients increased almost with increasing age in the AQP4-Ab-positive group, showed bimodal peaks in the fourth and sixth decades of life in the MOG-Ab-positive group, and showed a peak in the fifth decade of life in the double-negative group.

The proportion of female patients was 84% in the AQP4-Ab-positive group and significantly higher compared with the other 2 groups. Gold et al<sup>21</sup> reported that female gender is a risk factor for demyelinated disease of the central nervous system, including neuromyelitis optica spectrum disorders. When the age at onset was compared by gender, female patients showed significantly higher age at onset only in the anti-AQP 4-positive group.

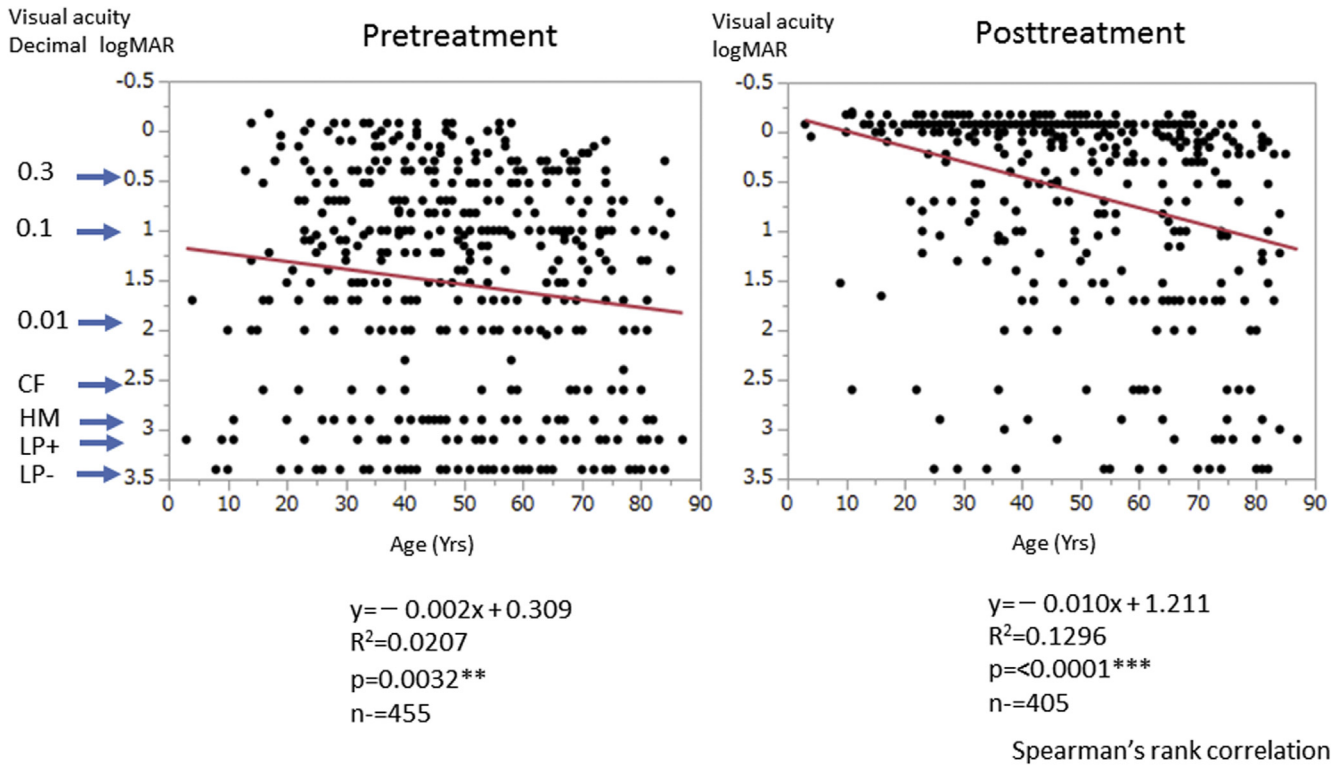
Jitrapaikulsan et al<sup>22</sup> conducted a cross-sectional cohort study analyzing 246 recurrent optic neuritis patients at the Mayo Clinic between 2000 and 2017 and reported an AQP4-Ab-positive rate of 19% and MOG-Ab-positive rate of 13%. In a study of 109 patients with demyelinating optic neuritis in China, 45 patients (41.3%) showed AQP4-Ab-positive results and 20 patients (18.3%) showed MOG-Ab-positive results, with a mean age at onset of  $35.6 \pm 15.7$  years in the AQP4-Ab-positive optic neuritis group and  $20.2 \pm 17.4$  years in the MOG-Ab-positive optic neuritis group,<sup>23</sup> showing a higher AQP4-Ab-positive rate and a tendency of younger onset compared with our findings. However, a study from Denmark of 51 patients with acute optic neuritis reported that 20 patients demonstrated MS at follow-up, none showed positive results for AQP4-Ab, and 2 showed positive results for MOG-Ab.<sup>24</sup> Furthermore, a study in Thailand reported that among 150 patients with optic neuritis, 58 patients (38.7%) showed NMO, 23 patients (15.3%) showed MS, and 69 patients (46.0%) showed idiopathic disease.<sup>25</sup> The above studies were

conducted in specialized institutions, and the study populations presumably vary because of racial differences and contained a large proportion of severe cases of disease. Our present multicenter collaborative study included facilities with neuro-ophthalmologists. Hence, there is a high possibility that a homogeneous study population of optic neuritis was collected.

The prevalence of an AQP4-Ab-positive NMO and NMO spectrum disorder (NMOSD) in Japan is estimated to be 2 to 4 per 100 000 population, and NMO occupies 27% to 28% of inflammatory demyelinating disease of the central nervous system in Japanese persons compared with 1% to 2% among white persons in Western countries.<sup>26,27</sup> In a report from South Korea, among 270 patients with inflammatory demyelinating disease, 18.1% showed AQP4-Ab-positive results and 6.3% showed MOG-Ab-positive results, whereas no patients with positive results for both antibodies were found.<sup>28</sup>

Furthermore, although there is no accurate investigation in Japan of the percentage of MS as a cause of optic neuritis, the Optic Neuritis Treatment Trial (ONTT) in the United States found that among 389 patients with optic neuritis, 50% progressed to MS during a follow-up period of 15 years.<sup>29</sup> Although the present study design differs from the 15-year long-term follow-up observation of the ONTT study, the contribution of MS as a cause of optic neuritis may be lower in Japan compared with Western countries. In our double-negative group, the prevalence of CDMS and CIS was low, but a higher percentage of patients showed cerebral white matter lesions. In this group, the number of patients converting to MS is anticipated to increase as follow-up continues long term.

In this study, 1 patient with optic neuritis and positive results for both MOG-Ab and AQP4-Ab (double-positive)



**Figure 2.** Scatterplots showing the relationship between age at onset and visual acuity analyzed by Spearman's rank correlation. Both (A) pretreatment and (B) posttreatment visual acuity decreases significantly as age increases. CF = counting fingers; HM = hand movements; LP+ = light perception; logMAR = logarithm of the minimum angle of resolution; LP- = no light perception.

was identified. Double-positive optic neuritis is rare, but 2 reports of similar cases indicate poor prognosis.<sup>30,31</sup> In the present patient, it remains unknown which positive antibody results appeared first. It is likely that the 2 antibodies with different pathogenetic mechanisms synergistically worsen visual functions.

### Optic Disc Swelling and Pain during Eye Movement

In the present results, optic disc swelling was found in 76% of MOG-Ab-positive optic neuritis patients, 34% of AQP4-Ab-positive patients, and 46% of double-negative

Table 4. Logistic Regression Analysis of Factors Influencing Visual Outcome of Optic Neuritis

Variable	Simple Regression	Model 1	Model 2
Visual acuity worse than CF			
Age	0.968 (0.950–0.987), 0.0012*	0.970 (0.951–0.989), 0.0026*	0.963 (0.935–0.989), 0.0044*
AQP4-Ab: +/-	0.290 (0.137–0.615), 0.0013*	0.336 (0.157–0.749), 0.0058*	0.350 (0.125–1.021), 0.0544
MOG-Ab: +/-	2.068 (0.479–8.930), 0.3303	1.507 (0.417–9.675), 0.5906	0.971 (0.223–6.802), 0.9720
Lesion length on MRI: long/short	0.346 (0.130–0.921), 0.0251 <sup>†</sup>	—	0.405 (0.132–1.109), 0.0794
Optic disc swelling: +/-	0.948 (0.476–1.901), 0.8788	—	1.057 (0.385–2.946), 0.9147
Visual acuity worse than 0.1 logMAR (approximate decimal equivalent, 0.7)			
Age	0.962 (0.950–0.973), <0.0001 <sup>‡</sup>	0.963 (0.951–0.974), <0.0001 <sup>‡</sup>	0.964 (0.947–0.980), <0.0001 <sup>‡</sup>
AQP4-Ab: +/-	0.578 (0.322–1.026), 0.0612	0.743 (0.401–1.366), 0.3395	0.551 (0.244–1.241), 0.1492
MOG-Ab: +/-	2.436 (1.190–5.392), 0.0140 <sup>†</sup>	2.287 (1.067–5.269), 0.0404 <sup>†</sup>	1.077 (0.397–3.169), 0.8875
Lesion length on MRI: long/short	0.450 (0.251–0.794), 0.0057*	—	0.465 (0.242–0.879), 0.0183 <sup>†</sup>
Optic disc swelling: +/-	1.665 (1.109–2.511), 0.0139 <sup>†</sup>	—	1.475 (0.769–2.859), 0.2420

AQP4-Ab = anti-aquaporin-4 antibody; CF = counting fingers; logMAR = logarithm of the minimum angle of resolution; MOG-Ab = anti-myelin oligodendrocyte glycoprotein antibody; MRI = magnetic resonance imaging; + = positive; - = negative; — = not done.

Data are odds ratio (95% confidence interval), P value.

\*P < 0.01.

<sup>†</sup>P < 0.05.

<sup>‡</sup>P < 0.001.

patients, with a significantly higher rate in the MOG-Ab-positive group compared with the other 2 groups. These results, together with the results of MRI to be described later, suggest that the major site of inflammation in MOG-Ab-positive optic neuritis is the proximal part of the optic nerve, that is, the anterior intraorbital portion, whereas inflammation in AQP4-Ab-positive optic neuritis does not usually spread to the proximal part of the optic nerve. In a Japanese study reported in 1999, 50% of idiopathic optic neuritis patients showed optic disc swelling.<sup>32</sup> Furthermore, in the earlier report of the ONTT (1991) in the United States, optic disc swelling was observed in 35.3%.<sup>33</sup> In a later report of the ONTT (2008), optic disc swelling was associated with a significantly lower likelihood of MS developing. Therefore, the presence or absence of optic disc swelling is a very important finding.

In a report of the ONTT (1991), pain during eye movement was found in 92.2% of optic neuritis patients.<sup>33</sup> However, previous reports from Japan show that the rate of pain during eye movement is 57% in optic neuritis overall<sup>32</sup> and 51% in AQP4-Ab-positive optic neuritis,<sup>34</sup> which are lower rates compared with the United States report. In the present study, the highest rate of pain during eye movement of 77% was found in the MOG-Ab-positive group, and the rate was almost the same as that of optic disc swelling in the same group. However, the report of the ONTT in 1991 showed no association between optic disc swelling and pain during eye movement.<sup>33</sup> Pain during eye movement is related to retro-orbital lesions caused by traction of the common tendinous ring, whereas periocular pain is presumably trigeminal nerve distribution pain. Fazzone et al<sup>35</sup> reported that pain during eye movement and periocular pain in the trigeminal nerve distribution area were significantly more frequent when the intraorbital segment of the optic nerve was inflamed, whereas pain was less frequent when inflammation was restricted to the canalicular or intracranial segment.<sup>35</sup>

The MOG-Ab-positive group manifested severe optic disc and optic nerve swelling as well as strong inflammation involving the orbital tissues around the optic nerve, suggesting that pain during eye movement is intensified by the effects from the dura sheath surrounding the optic nerve, sclera, and intraorbital tissues through which the trigeminal nerve is distributed and through traction of the extraocular muscles in the common tendinous ring.

### Visual Function and Treatment

Pretreatment VA was significantly lower in the AQP4-Ab-positive group than in the double-negative group. Furthermore, the proportion of patients in the AQP4-Ab-positive group with VA of CF was significantly higher compared with the other 2 groups. However, the VAs were 2.6 logMAR, 1.6 logMAR, and 1.2 logMAR in the AQP4-Ab-positive, MOG-Ab-positive, and double-negative groups, respectively, and it is impossible to clinically predict the presence or absence of AQP4-Ab and MOG-Ab from VA at presentation alone.

For visual field defects, more than 95% in the MOG-Ab-positive group showed complete visual field loss or

central scotoma, whereas the AQP4-Ab-positive group showed various types of visual field abnormalities, including altitudinal hemianopia, nasal hemianopia, and temporal hemianopia. Binocular vision loss resulting from chiasmal lesions, bitemporal hemianopia, and homonymous hemianopia<sup>36</sup> or altitudinal hemianopia are relatively common characteristics of NMO and NMOSD, whereas they are rare in optic neuritis resulting from other causes.<sup>37</sup>

Regarding treatment, methylprednisolone pulse therapy was administered in 80% of the patients in all 3 groups, and plasmapheresis was used in combination in 32% of the patients in the AQP4-Ab-positive group. In the MOG-Ab-positive group, plasmapheresis was used in only 1 patient. These findings demonstrate that MOG-Ab-positive optic neuritis responds well to steroid pulse therapy. However, for the treatment of AQP4-Ab-positive optic neuritis in Japan, Endo et al<sup>34</sup> report that methylprednisolone pulse therapy is used an average of  $3.3 \pm 4.1$  times, indicating the refractory nature of this disease. Clinicians should not hesitate to add plasmapheresis in patients showing positive AQP4-Ab results and inadequate response to steroid therapy, aiming to recover or maintain visual function.<sup>38</sup> In particular, early use of plasmapheresis in AQP4-Ab-positive patients is reported to achieve good outcomes.<sup>39</sup>

A report from Japan in 1995 shows that steroids are used for the treatment of optic neuritis in more than 94% of the facilities in Japan, and 30% of those facilities perform methylprednisolone pulse therapy.<sup>1</sup> In a survey conducted in United States at approximately the same time, 35% of the physicians replied that steroids are not used,<sup>40</sup> which highlighted the difference in treatment policy between Japan and the United States. Recently, steroid pulse therapy has become the mainstay of treatment for optic neuritis because of its merits, including immediate effect for recovery of visual function.

With respect to VA after treatment, the response to treatment was evidently good in the MOG-Ab-positive group, with visual recovery to 0.5 (decimal VA, 0.3) or higher in 82% of the patients and 0.2 (decimal VA, 0.7) or higher in 74% of patients. Matsuda et al<sup>10</sup> reported good visual outcomes in MOG-Ab-positive optic neuritis patients. Furthermore, Zhao et al<sup>23</sup> also reported good VA outcomes after treatment in MOG-Ab-positive optic neuritis patients. However, although AQP4-Ab-positive optic neuritis patients recovered VA after treatment to 0.4, VA remained CF or worse in 22% of patients. Likewise, Jitrapaikulsan et al<sup>22</sup> reported that both pretreatment and posttreatment VA are poor in the AQP4-Ab-positive group, whereas visual outcomes are good in the MOG-Ab-positive group.

### Autoantibodies Other Than Anti-Aquaporin-4 Antibody and Anti-Myelin Oligodendrocyte Glycoprotein Antibody

Nagaishi et al<sup>41</sup> reported the coexistence of various autoantibodies (antinuclear antibody, anti-SS-A and anti-Sjögren's syndrome type B antibody, anti-thyroid stimulating hormone receptor antibody, antithyroglobulin

antibody, and antiperoxidase antibody) other than AQP4-Ab in patients with NMO. Furthermore, an association of the presence of anti-SS-A antibody with AQP4-Ab-positive NMOSD has been reported.<sup>42</sup> However, coexistence of other autoantibodies with MOG-Ab is not common compared with AQP4-Ab.<sup>23</sup> The findings in the present study show the same tendency as previous reports.

### Magnetic Resonance Imaging Findings

In this study, the frequency of swollen optic nerve (inflammatory findings on MRI) was 91% in the MOG-Ab-positive group, 82% in the AQP4-Ab-positive group, and 67% in the double-negative group. In addition, the lesions tended to involve the anterior portion of the optic nerve in MOG-Ab-positive optic neuritis and posterior portion of the optic nerve in AQP4-Ab-positive optic neuritis. These results are in line with the above-mentioned finding of a high frequency of optic disc swelling in the MOG-Ab-positive group. Furthermore, these findings are consistent with the MRI characteristics of optic neuritis associated with AQP4-Ab, MOG-Ab, and MS reported by Ramanathan et al.<sup>43</sup> The significantly lower frequency in the double-negative group compared with the other 2 groups is probably because most patients in this group showed idiopathic optic neuropathy, which is characterized by mild and partial inflammation. Moreover, in an MRI study of optic neuritis, compared with recurrent MS patients, NMO patients showed longitudinally extensive lesions extending from the posterior globe to the optic tract, and at a cutoff lesion length of 17.6 mm, the sensitivity and specificity for diagnosis of NMO were improved. Conversely, MS lesions were more commonly focal and localized in anterior intraorbital segment.<sup>44</sup>

In the studies of Akaishi et al,<sup>45,46</sup> the lesion length of the optic nerve in the acute phase was significantly longer in MOG-Ab-positive optic neuritis patients compared with MS and AQP4-Ab-positive optic neuritis patients. Moreover, in MOG-Ab-positive optic neuritis patients, edema and meandering of the optic nerve, as well as strong contrast enhancement in orbital tissues around the optic nerve, were observed. Also, the optic nerve lesion length measured on MRI, especially the length anterior to the optic canal (from the anterior orbit segment to optic canal), was a significant prognostic factor for AQP4-Ab-positive optic neuritis.<sup>45</sup> However, they reported that MOG-Ab-positive optic neuritis is characterized by intracranial lesions from the optic canal, and this observation is contrary to our finding that an anterior intraorbital lesion was dominant in MOG-Ab-positive optic neuritis. Thus, in optic neuritis, the lesion length not only affects the visual outcome but is also an important factor that may discriminate between NMO and MS depending on certain conditions. Further detailed study is required.

Magnetic resonance imaging examination of sites other than the optic nerve detected lesions in the cerebral white matter, brainstem, and spinal cord in 10%, 6%, and 22%, respectively, in the AQP4-Ab-positive group: 16%, 5%, and 10%, respectively, together with a cerebellar lesion in 3% in the double-negative group. However, there was only 1 cerebral lesion and 2 spinal cord lesions in the MOG-Ab-positive group. Based on these results, AQP4-

Ab-positive optic neuritis is more likely to show concurrent spinal cord abnormalities, whereas patients with double-negative disease and MS show widely distributed lesions in the cerebral white matter and cerebellum, and MOG-Ab-positive optic neuritis patients mostly show only optic nerve lesions.

From the findings of the present study, MOG-Ab-positive optic neuritis showed optic nerve lesions on MRI in 91% of the patients, but few radiologic findings were observed in other sites, and although manifesting severe optic neuritis in the early stage, the visual outcome was favorable. In recent reports on MOG-Ab-positive disease, the proposal of treating this disease as a distinct disease entity apart from MS and NMO is conspicuous.<sup>47,48</sup> In fact, characteristics of MOG-Ab-positive optic neuritis similar to our findings have been reported from Mayo Clinic and associated facilities<sup>49</sup> and by Jarius et al.<sup>50</sup> Kim et al<sup>28</sup> also reported that MOG-Ab-positive disease is characterized by strong enhancement in soft tissues around the optic nerve in 33% of patients and also enhancement around the lateral ventricle in 30% of patients, with very low frequency of spinal cord lesions compared with anti-AQP4-positive disease. In addition, Sato et al<sup>8</sup> reported the characteristics of MOG-Ab-positive NMOSD as having a male preponderance, more optic nerve lesions than spinal cord lesions, bilateral simultaneous optic neuritis, and good recovery.

### Factors Affecting Visual Outcome

No detailed reports have been published to date on age and visual function in patients with optic neuritis. The present study found no significant difference in age at onset among the 3 groups. Furthermore, when all patients were analyzed, a negative correlation was observed between age and VA both before and after treatment. However, the pretreatment distribution data do not show clearly that VA declines significantly as age increases. Although posttreatment visual recovery is apparently better in the second and third decades, there are no definite data indicating that patients beyond these age groups recover significantly.

Multivariate analysis of factors affecting visual function using the entire study population statistically revealed that age (accompanying age increase) and the presence of AQP4-Ab adversely affected visual function, whereas the presence of MOG-Ab improved visual function. For model 2, in addition to age and antibody status, lesion length on MRI and optic disc swelling were included as explanatory variables. In this analysis, only age showed a significant effect on visual function, and the serostatus of antibodies was no longer a significant factor. In the AQP4-Ab-positive group with poor visual outcome, 24 of 36 patients demonstrated lesion length on MRI exceeding one half of the intraorbital optic nerve length. In the MOG-Ab-positive group with good visual outcome, 34 of 45 patients showed optic disc swelling. Considering these findings along with the statistical results, the fact that AQP4-Ab positivity and MOG-Ab positivity were extracted as significant factors in model 1 but not in model 2 was the result of the occurrence of significant offset effect, that is, multicollinearity.

## Limitations of This Study and Future Perspective

A limitation of this study is that although the sample analyzed was large and drawn from diverse geography in Japan, the study was not a population-based survey, and this limitation may introduce bias into estimates drawn from our data. Endo et al.<sup>34</sup> reported that in Japan, AQP4-Ab-positive optic neuritis recurs  $1.5 \pm 2.3$  times, and 46.8% of all patients show a bilateral decrease in VA. For MOG-Ab-positive optic neuritis also, a high percentage of bilateral recurrent disease has been reported.<sup>10,22,23,51</sup> Therefore, in evaluating optic neuritis, laterality and recurrence are very important findings. Of 531 patients analyzed herein, 353 (66.5%) showed primary (first episode of) optic neuritis, and long-term follow-up was not available for these patients. Although the longest follow-up was 20 years, the follow-up periods of the patients differed widely. The medications used for prevention of relapse also varied among facilities. Therefore, the results likely do not provide a complete profile of optic neuritis in Japanese patients. We are currently conducting studies on recurrence and laterality. Furthermore, the number of patients diagnosed with MS was small in this study. In the double-negative group, the number of patients showing extra-optic nerve lesions on MRI was higher than the number with a diagnosis of CDMS and CIS. In this respect, careful long-term follow-up, including checking for conversion to MS, is required.

## Acknowledgments

The authors thank Teresa Nakatani, PhD, for critical revision of the manuscript and Hikaru Ito, CO, for data organization.

## References

1. Wakakura M, Ishikawa S, Oono S, et al. Incidence of acute idiopathic optic neuritis and its therapy in Japan. Optic Neuritis Treatment Trial Multicenter Cooperative Research Group (ONMRG) [in Japanese]. *Nippon Ganka Gakkai Zasshi*. 1995;99:93–97.
2. Wikström J. The epidemiology of optic neuritis in Finland. *Acta Neurol Scand*. 1975;52:196–206.
3. Jin YP, de Pedro-Cuesta J, Söderström M, et al. Incidence of optic neuritis in Stockholm, Sweden 1990–1995: I. Age, sex, birth and ethnic-group related patterns. *J Neurol Sci*. 1998;159:107–114.
4. MacDonald BK, Cockerell OC, Sander JW, et al. The incidence and lifetime prevalence of neurological disorders in a prospective community-based study in the UK. *Brain*. 2000;123:665–676.
5. Lennon VA, Wingerchuk DM, Kryzer TJ, et al. A serum autoantibody marker of neuromyelitis optica: distinction from multiple sclerosis. *Lancet*. 2004;364:2106–2112.
6. Jarius S, Ruprecht K, Wildemann B, et al. Contrasting disease patterns in seropositive and seronegative neuro-myelitis optica: a multicenter study of 175 patients. *J Neuroinflammation*. 2012;9:14.
7. Kezuka T, Usui Y, Yamakawa N, et al. Relationship between NMO antibody and MOG-ab in optic neuritis. *Neuroophthalmol*. 2012;32:107–110.
8. Sato DK, Callegaro D, Lana-Peixoto MA, et al. Distinction between MOG antibody seropositive and AQP4 antibody seropositive NMO spectrum disorders. *Neurology*. 2014;82:474–481.
9. Kitley J, Waters P, Woodhall M, et al. Neuromyelitis optica spectrum disorders with aquaporin-4 and myelin-oligodendrocyte glycoprotein antibodies: a comparative study. *JAMA Neurol*. 2014;71:276–283.
10. Matsuda R, Kezuka T, Umazume A, et al. Clinical profile of anti-myelin oligodendrocyte glycoprotein antibody seropositive cases of optic neuritis. *Neuroophthalmol*. 2015;39:213–219.
11. Kezuka T, Ishikawa H. Diagnosis and treatment of anti-myelin oligodendrocyte glycoprotein antibody positive optic neuritis. *Jpn J Ophthalmol*. 2018;62:101–108.
12. Tanaka M, Tanaka K. Anti-MOG-antibodies in adult patients with demyelinating disorders of the central nervous system. *J Neuroimmunol*. 2014;270:98–99.
13. Tanaka K, Tani T, Tanaka M, et al. Anti-aquaporin 4 antibody in selected Japanese multiple sclerosis patients with long spinal cord lesions. *Mult Scler*. 2007;13:850–855.
14. Miller D, Barkhof F, Montalban X, et al. Clinically isolated syndromes suggestive of multiple sclerosis, part I: natural history, pathogenesis, diagnosis, and prognosis. *Lancet Neurol*. 2005;4:281–288.
15. Montalban X, Tintoré M, Swanton J, et al. MRI criteria for MS in patients with clinically isolated syndromes. *Neurology*. 2010;74:427–434.
16. Swanton JK, Rovira A, Tintore M, et al. MRI criteria for multiple sclerosis in patients presenting with clinically isolated syndromes: a multicentre retrospective study. *Lancet Neurol*. 2007;6:677–686.
17. Kidd DP, Burton BJ, Graham EM, et al. Optic neuropathy associated with systemic sarcoidosis. *Neurol Neuroimmunol Neuroinflamm*. 2016;3(5):e270.
18. Polman CH, Reingold SC, Banwell B, et al. Diagnostic criteria for multiple sclerosis: 2010 revisions to the McDonald criteria. *Ann Neurol*. 2011;69(2):292–302.
19. Kupersmith MJ, Alban T, Zeiffer B, et al. Contrast-enhanced MRI in acute optic neuritis: relationship to visual performance. *Brain*. 2002;125:812–822.
20. Johnson LN, Guy ME, Krohel GB, et al. Levodopa may improve vision loss in recent-onset, nonarteritic anterior ischemic optic neuropathy. *Ophthalmology*. 2000;107:521–526.
21. Gold SM, Willing A, Leyboldt F, et al. Sex differences in autoimmune disorders of the central nervous system. *Semin Immunopathol*. 2019;41(2):177–188.
22. Jitrapaikulsan J, Chen JJ, Flanagan EP, et al. Aquaporin-4 and myelin oligodendrocyte glycoprotein autoantibody status predict outcome of recurrent optic neuritis. *Ophthalmology*. 2018;125:1628–1637.
23. Zhao Y, Tan S, Chan TCY, et al. Clinical features of demyelinating optic neuritis with seropositive myelin oligodendrocyte glycoprotein antibody in Chinese patients. *Br J Ophthalmol*. 2018;102:1372–1377.
24. Soelberg K, Jarius S, Skejoe H, et al. A population-based prospective study of optic neuritis. *Mult Scler*. 2017;23(14):1893–1901.
25. Hansapinyo L, Vivattanaseth C. Clinical characteristics, treatment outcomes and predictive factors in optic neuritis. *Open Ophthalmol J*. 2018;12:247–255.
26. Multiple Sclerosis International Federation. *Epidemiology of MS 2013. P8–11*. London: Multiple Sclerosis International Federation; 2013.

27. Miyamoto K. Epidemiology of multiple sclerosis and neuromyelitis optica. *Jpn J Clin Med.* 2014;72:1903–1907.
28. Kim SM, Woodhall MR, Kim SJ, et al. Antibodies to MOG in adults with inflammatory demyelinating disease of the CNS. *Neurol Neuroimmunol Neuroinflamm.* 2015;2:e163.
29. The Optic Neuritis Study Group. Multiple sclerosis risk after optic neuritis: final optic neuritis treatment trial follow-up. *Arch Neurol.* 2008;65:727–732.
30. Kezuka T, Tanaka K, Matsunaga Y, et al. Distinction between MOG antibody-positive and AQP4 antibody-positive NMO spectrum disorders. *Neurology.* 2014;83:475.
31. Di Pauli F, Höftberger R, Reindl M, et al. Fulminant demyelinating encephalomyelitis: insights from antibody studies and neuropathology. *Neurol Neuroimmunol Neuroinflamm.* 2015;2(6):e175.
32. Wakaura M, Minei RH, Oono S, et al. Baseline features of idiopathic optic neuritis as determined by multicenter treatment trial in Japan. *Jpn J Ophthalmol.* 1999;43:127–132.
33. Optic Neuritis Treatment Trial. The clinical profile of optic neuritis. Experience of the Optic Neuritis Treatment Trial. *Arch Ophthalmol.* 1991;109:1673–1678.
34. Endo T, Fujikado T, Morimoto T, et al. National clinical investigation of anti-aquaporin-4 seropositive optic neuritis [in Japanese]. *Nippon Ganka Gakkai Zasshi.* 2014;118:751–758.
35. Fazzone HE, Lefton DR, Kupersmith MJ. Optic neuritis: correlation of pain and magnetic resonance imaging. *Ophthalmology.* 2003;110:1646–1649.
36. Nakajima H, Hosokawa T, Sugino M, et al. Visual field defects of optic neuritis in neuromyelitis optica compared with multiple sclerosis. *BMC Neurol.* 2010;18:45.
37. Behbehani R. Clinical approach to optic neuropathies. *Clin Ophthalmol.* 2007;1:233–246.
38. Mori S, Kurimoto T, Ueda K, Nakamura M. Short-term effect of additional apheresis on visual acuity changes in patients with steroid-resistant optic neuritis in neuromyelitis optica spectrum disorders. *Jpn J Ophthalmol.* 2018;62:525–530.
39. Kleiter I, Gahlen A, Borisow N, et al. Apheresis therapies for NMOSD attacks: a retrospective study of 207 therapeutic interventions. *Neurol Neuroimmunol Neuroinflamm.* 2018;5(6):e504.
40. Beck RW. The Optic Neuritis Treatment Trial. *Arch Ophthalmol.* 1988;106(8):1051–1053.
41. Nagaishi A, Takagi M, Umemura A, et al. Clinical features of neuromyelitis optica in a large Japanese cohort: comparison between phenotypes. *J Neurol Neurosurg Psychiatry.* 2011;82:1360–1364.
42. Park JH, Hwang J, Min JH, et al. Presence of anti-Ro/SSA antibody may be associated with anti-aquaporin-4 antibody positivity in neuromyelitis optica spectrum disorder. *J Neurol Sci.* 2015;348:132–135.
43. Ramanathan S, Prelog K, Barnes EH, et al. Radiological differentiation of optic neuritis with myelin oligodendrocyte glycoprotein antibodies, aquaporin-4 antibodies, and multiple sclerosis. *Mult Scler.* 2016;22(4):470–482.
44. Mealy MA, Whetstone A, Orman G, et al. Longitudinally extensive optic neuritis as an MRI biomarker distinguishes neuromyelitis optica from multiple sclerosis. *J Neurol Sci.* 2015;355(1–2):59–63.
45. Akaishi T, Nakashima I, Takeshita T, et al. Lesion length of optic neuritis impacts visual prognosis in neuromyelitis optica. *J Neuroimmunol.* 2016;293:28–33.
46. Akaishi T, Nakashima I, Takeshita T, et al. Different etiologies and prognoses of optic neuritis in demyelinating diseases. *J Neuroimmunol.* 2016;299:152–157.
47. Ramanathan S, Dale RC, Brilot F. Anti-MOG antibody: the history, clinical phenotype, and pathogenicity of a serum biomarker for demyelination. *Autoimmun Rev.* 2016;15:307–324.
48. Weber MS, Deraus T, Metz I, Brück W. Defining distinct features of anti-MOG antibody associated central nervous system demyelination. *Ther Adv Neurol Disord.* 2018;11:1–15.
49. Chen JJ, Flanagan EP, Jitrapakulsan J, et al. Myelin oligodendrocyte glycoprotein antibody-positive optic neuritis: clinical characteristics, radiologic clues, and outcome. *Am J Ophthalmol.* 2018;195:8–15.
50. Jarius S, Ruprecht K, Kleiter I, et al. MOG-IgG in NMO and related disorders: a multicenter study of 50 patients. Part 2: epidemiology, clinical presentation, radiological and laboratory features, treatment responses, and long-term outcome. *J Neuroinflammation.* 2016;13:280.
51. Ramanathan S, Reddel SW, Henderson A, et al. Antibodies to myelin oligodendrocyte glycoprotein in bilateral and recurrent optic neuritis. *Neurol Neuroimmunol Neuroinflamm.* 2014;1:e40.

## Footnotes and Financial Disclosures

Originally received: January 27, 2019.

Final revision: April 17, 2019.

Accepted: April 24, 2019.

Available online: May 6, 2019.

Manuscript no. 2019-198.

<sup>1</sup> Department of Orthoptics and Visual Science, School of Allied Health Sciences, Kitasato University, Kanagawa, Japan.

<sup>2</sup> Department of Ophthalmology, Tokyo Medical University, Tokyo, Japan.

<sup>3</sup> Department of Ophthalmology, The Jikei University School of Medicine, Tokyo, Japan.

<sup>4</sup> Inouye Eye Hospital, Tokyo, Japan.

<sup>5</sup> Department of Ophthalmology, Sapporo Medical University, Hokkaido, Japan.

<sup>6</sup> Department of Ophthalmology, University of Miyazaki, Miyazaki, Japan.

<sup>7</sup> Department of Surgery, Division of Ophthalmology, Kobe University Graduate School of Medicine, Hyogo, Japan.

<sup>8</sup> Department of Hygiene, Kitasato University, Kanagawa, Japan.

<sup>9</sup> Center for Public Health Informatics, National Institute of Public Health, Saitama, Japan.

<sup>10</sup> Department of Ophthalmology, Kitasato University School of Medicine, Kanagawa, Japan.

<sup>11</sup> Department of Ophthalmology, Kitasato University School of Medicine, Kanagawa, Japan.

<sup>12</sup> Department of Ophthalmology, Hyogo College of Medicine, Hyogo, Japan.

<sup>13</sup> Department of Ophthalmology, Akita University, Akita, Japan.

<sup>14</sup> Department of Cellular Neurobiology, Brain Research Institute, Niigata University, Niigata, Japan.

Presented in part at: Ophthalmological Society of Taiwan 58th Annual Meeting, November 2017, Taiwan.

\*Working Group on Diagnostic Criteria for Refractory Optic Neuritis Based on Neuroimmunological Perspective: Kitasato University, Kanagawa: Hitoshi Ishikawa, MD, PhD, Keika Hoshi, DDS, PhD, Toshiaki Goseki, MD, PhD, Kimiyo Mashimo, BS. Tokyo Medical University, Tokyo: Takeshi Kezuka, MD, PhD. Jikei University, Tokyo: Keigo Shikishima, MD, PhD. Inouye Eye Hospital, Tokyo: Akiko Yamagami, MD. Sapporo Medical University, Hokkaido: Miki Hiraoka, MD, PhD. University of Miyazaki, Miyazaki: Hideki Chuman, MD, PhD. Kobe

University, Hyogo, Japan: Makoto Nakamura, MD, PhD. Hyogo College of Medicine, Hyogo: Osamu Mimura, MD, PhD. Akita University. Akita: Takeshi Yoshitomi, MD, PhD. Niigata University, Niigata: Keiko Tanaka, MD, PhD. Osaka Medical College, Osaka: Jun Sugawara, MD, PhD. Osaka University Graduate School of Medicine, Osaka: Takashi Fujikado, MD, PhD. Kanazawa University Graduate School of Medical Science, Ishikawa: Shinji Okubo, MD, PhD. Kyorin University, Tokyo: Toshiki Watanabe, MD, PhD. Kinki University, Osaka: Keiichi Aomatsu, MD, PhD. The University of Tokyo, Tokyo: Hajime Aihara, MD, PhD. Dokkyo Medical University Saitama Medical Center, Saitama: Tone Suzuki, MD, PhD. Graduate School of Medical and Dental Science, Niigata University, Niigata: Satoshi Ueki, MD, PhD. Kawasaki Medical School, Okayama: Atsushi Miki, MD, PhD. Faculty of Medicine and Graduate School of Medicine, Hokkaido University, Hokkaido: Yasuhiro Shinmei, MD, PhD. National Defense Medical College, Saitama: Masaru Takeuchi, MD, PhD. Kochi Medical School, Kochi: Atsuki Fukusima, MD, PhD. Kyoto University Graduate School of Medicine, Kyoto: Masayuki Hata, MD, PhD. Yamaguchi University Graduate School of Medicine, Yamaguchi: Ryoji Yanai, MD, PhD. Kyushu University Graduate School of Medical Science, Fukuoka: Kohei Sonoda, MD, PhD. Dokkyo Medical University, Tochigi: Tadashi Senoo, MD, PhD. Teikyo University, Tokyo: Atsushi Mizota, MD, PhD. Yamagata University Faculty of Medicine, Yamagata: Yutaka Kaneko, MD, PhD. Kiyosawa Eye Clinic, Tokyo: Motohiro Kiyosawa, MD, PhD. Osaka City University Graduate School of Medicine, Osaka: Nobuhiko Ueda, MD, PhD. Shiga University of Medical Science, Shiga: Tomoaki Higashiyama, MD, PhD. University of Tsukuba Faculty of Medicine, Ibaraki: Kiyotaka Nakamagoe, MD, PhD. St. Marianna University School of Medicine, Kanagawa: Hisanao Akiyama, MD, PhD.

Financial Disclosure(s):

The author(s) have made the following disclosure(s): H.I.: Financial support — Santen Pharmaceuticals, Senju Pharmaceuticals, Alcon Laboratories, Kowa, Co. Ltd., Cosmic Corp., Kao Corporation

T.K.: Financial support — AbbVie, Inc., Alcon Laboratories, Inc., Cosmic Corp., Eisai, Co. Ltd., Kowa, Co. Ltd., Mitsubishi Tanabe Pharmaceuticals, Santen, Inc., Senju, Pharmaceuticals, Teijin Pharma Ltd.; Nonfinancial support — Cosmic Corp.

M.N.: Financial support — Santen Pharmaceuticals, Senju Pharmaceuticals

O.M.: Financial support — Santen Pharmaceuticals, Senju Pharmaceuticals, Teijin Pharma Ltd.

T.Y.: Financial support — Santen Pharmaceuticals

Supported by the Ministry of Health, Labour and Welfare (Grant-in-aid for Scientific Research no.: H27-Nanchito-(Nan)-Ippan-023). The sponsor or funding organization had no role in the design or conduct of this research.

**HUMAN SUBJECTS:** Human subjects were included in this study. The IRB/ethics committee of each participating university approved this study. The research was approved by the ethics committee of each participating university (representative: Kitasato University B14-228). All research adhered to the tenets of the Declaration of Helsinki. All participants provided informed consent.

No animal subjects were included in this study.

Author Contributions:

Conception and design: Ishikawa, Kezuka, Shikishima, Yamagami

Analysis and interpretation: Ishikawa, Hoshi, Goseki, Mashimo, Tanaka

Data collection: Ishikawa, Kezuka, Shikishima, Yamagami, Hiraoka, Chuman, Nakamura, Goseki, Mimura, Yoshitomi, Tanaka

Obtained funding: Ishikawa, Kezuka, Nakamura, Mimura, Yoshitomi

Overall responsibility: Ishikawa, Kezuka, Shikishima, Yamagami, Hiraoka, Chuman, Nakamura, Mimura, Yoshitomi, Tanaka

Abbreviations and Acronyms:

**AQP4-Ab** = anti-aquaporin 4 antibody; **CDMS** = clinically definite multiple sclerosis; **CF** = counting fingers; **CIS** = clinically isolated syndrome; **IQR** = interquartile range; **logMAR** = logarithm of the minimum angle of resolution; **MOG-Ab** = anti-myelin oligodendrocyte glycoprotein antibody; **MRI** = magnetic resonance imaging; **MS** = multiple sclerosis; **NMO** = neuromyelitis optica; **NMOSD** = neuromyelitis optica spectrum disorder; **ONTT** = Optic Neuritis Treatment Trial; **SS-A** = anti-Sjögren's syndrome-related antigen A; **VA** = visual acuity.

Correspondence:

Takeshi Kezuka, MD, PhD, Department of Ophthalmology, Tokyo Medical University, 6-7-1 Nishi-shinjuku, Shinjuku-ku, Tokyo 160-0023, Japan. E-mail: [tkezuka1000@gmail.com](mailto:tkezuka1000@gmail.com).