



## Functional neuroimaging of recovery from motor conversion disorder

### A case report

Dogonowski, Anne-Marie; Andersen, Kasper W; Sellebjerg, Finn; Schreiber, Karen; Madsen, Kristoffer H; Siebner, Hartwig R

*Published in:*  
NeuroImage

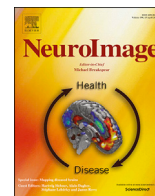
*DOI:*  
[10.1016/j.neuroimage.2018.03.061](https://doi.org/10.1016/j.neuroimage.2018.03.061)

*Publication date:*  
2019

*Document version*  
Publisher's PDF, also known as Version of record

*Document license:*  
[CC BY-NC-ND](https://creativecommons.org/licenses/by-nc-nd/4.0/)

*Citation for published version (APA):*  
Dogonowski, A.-M., Andersen, K. W., Sellebjerg, F., Schreiber, K., Madsen, K. H., & Siebner, H. R. (2019). Functional neuroimaging of recovery from motor conversion disorder: A case report. *NeuroImage*, 190, 269-274. <https://doi.org/10.1016/j.neuroimage.2018.03.061>



## Functional neuroimaging of recovery from motor conversion disorder: A case report

Anne-Marie Dogonowski<sup>a,b,\*</sup>, Kasper W. Andersen<sup>a,1</sup>, Finn Sellebjerg<sup>c</sup>, Karen Schreiber<sup>c</sup>, Kristoffer H. Madsen<sup>a,d</sup>, Hartwig R. Siebner<sup>a,b,\*\*</sup>

<sup>a</sup> Danish Research Centre for Magnetic Resonance, Centre for Functional and Diagnostic Imaging and Research, Copenhagen University Hospital Hvidovre, Kettegaard Allé 30, 2650 Hvidovre, Denmark

<sup>b</sup> Department of Neurology, Copenhagen University Hospital Bispebjerg, Bispebjerg Bakke 23, 2400 Copenhagen, NV, Denmark

<sup>c</sup> Danish Multiple Sclerosis Center, Department of Neurology, Copenhagen University Hospital, Rigshospitalet, Blegdamsvej 9, 2100 Copenhagen, Denmark

<sup>d</sup> Cognitive Systems, Department of Applied Mathematics and Computer Science, Technical University of Denmark, 2800 Kgs. Lyngby, Denmark

### ARTICLE INFO

#### Keywords:

Conversion disorder  
Dorsal premotor cortex (PMd)  
fMRI  
Inhibition of intentional actions  
Medial prefrontal cortex (mPFC)  
Motor  
Recovery

### ABSTRACT

A patient with motor conversion disorder presented with a functional paresis of the left hand. After exclusion of structural brain damage, she was repeatedly examined with whole-brain functional magnetic resonance imaging, while she performed visually paced finger-tapping tasks. The dorsal premotor cortex showed a bilateral deactivation in the acute-subacute phase. Recovery from unilateral hand paresis was associated with a gradual increase in task-based activation of the dorsal premotor cortex bilaterally. The right medial prefrontal cortex displayed the opposite pattern, showing initial task-based activation that gradually diminished with recovery. The inverse dynamics of premotor and medial prefrontal activity over time were found during unimanual finger-tapping with the affected and non-affected hand as well as during bimanual finger-tapping. These observations suggest that reduced premotor and increased medial prefrontal activity reflect an effector-independent cortical dysfunction in conversion paresis which gradually disappears in parallel with clinical remission of paresis. The results link the medial prefrontal and dorsal premotor areas to the generation of intentional actions. We hypothesise that an excessive ‘veto’ signal generated in medial prefrontal cortex along with decreased premotor activity might constitute the functional substrate of conversion disorder. This notion warrants further examination in a larger group of affected patients.

### Introduction

Conversion paresis is characterised by loss of voluntary motor function that cannot be explained by known neurological or medical disorder. Onset of symptoms is often associated with psychological stressors. The underlying neurobiological mechanisms still remain poorly understood. Studies have shown increased cortical thickness and grey matter volume in the bilateral premotor cortex of patients with conversion paresis (Aybek et al., 2014). Functional neuroimaging studies have demonstrated a failure to activate contralateral motor (Marshall et al., 1997; Stone et al., 2007) and premotor cortex during action execution, action selection (Voon et al., 2011), movement observation (Burgmer et al.,

2006) and during recall of clinically repressed events (Kanaan et al., 2007) in affected patients. In addition, prefrontal areas, insula, amygdala and anterior cingulate cortex have been implicated in motor conversion disorder (Boeckle et al., 2016).

Here we used functional magnetic resonance imaging (MRI) to assess task-based brain activation of the motor system in a 25-year old woman who presented with acute conversion paresis of her left hand. MRI measurements of motor brain activity were repeatedly performed until the patient had fully recovered from paresis. We hypothesised that recovery of symptoms would be associated with dynamic changes in premotor activation during a motor task. We were a-priori interested in tracing activity changes in the dorsal premotor cortex (PMd) due to its

\* Corresponding author. Danish Research Centre for Magnetic Resonance, Copenhagen University Hospital Hvidovre, Department 340, 2650 Hvidovre, Denmark.

\*\* Corresponding author. Danish Research Centre for Magnetic Resonance, Copenhagen University Hospital Hvidovre, Department 340, 2650 Hvidovre, Denmark.  
E-mail addresses: [anne-marie.dogonowski@regionh.dk](mailto:anne-marie.dogonowski@regionh.dk) (A.-M. Dogonowski), [kasperwj@drcmr.dk](mailto:kasperwj@drcmr.dk) (K.W. Andersen), [finn.thorup.sellebjerg@regionh.dk](mailto:finn.thorup.sellebjerg@regionh.dk) (F. Sellebjerg), [karen.ingrid.schreiber@regionh.dk](mailto:karen.ingrid.schreiber@regionh.dk) (K. Schreiber), [kristofferm@drcmr.dk](mailto:kristofferm@drcmr.dk) (K.H. Madsen), [h.siebner@drcmr.dk](mailto:h.siebner@drcmr.dk) (H.R. Siebner).

<sup>1</sup> Both authors have contributed equally to this work.

<https://doi.org/10.1016/j.neuroimage.2018.03.061>

Received 3 September 2017; Received in revised form 23 March 2018; Accepted 26 March 2018

Available online 27 March 2018

1053-8119/© 2018 The Authors. Published by Elsevier Inc. This is an open access article under the CC BY-NC-ND license (<http://creativecommons.org/licenses/by-nc-nd/4.0/>).

central role in the planning and preparation of movement and in the action selection network (Graziano, 2006; O’Shea et al., 2007). Therefore, we chose a simple sensorimotor task devoid of cognitive or emotional content to minimise the functional engagement of prefrontal or limbic areas. We hypothesised that a conversion paresis would be associated with deficient recruitment of PMd during volitional actions. This deactivation would gradually recover to a normal level with the resolution of symptoms. We further wished to examine whether the reduction of PMd activation was specific to movement of the affected hand, or represented a more general pattern also expressed during movements with the non-affected hand.

**Material and methods**

*Patient history*

We studied a 25-year old right-handed woman who met the diagnostic criteria for conversion disorder (Diagnostic and Statistical Manual of Mental Disorders, 5th ed.). She developed a paresis of her left hand with subacute onset and was initially suspected of presenting the first symptom of multiple sclerosis. She presented with decreased muscle strength of her left arm and hand graded by a neurologist on the Medical Research Council (MRC) scale: shoulder abduction 4+, elbow extension 4, elbow flexion 4+, wrist extension and flexion 4, finger abduction 3, finger extension and flexion 3. Deep tendon reflexes of the left upper extremity were described discretely more brisk compared to the right side and the plantar responses were normal. Structural MRI examinations of the brain and the spinal cord before and after intravenous gadolinium injection showed no abnormality (including fluid attenuation inversion recovery and diffusion weighted imaging). Cerebrospinal fluid was normal without oligoclonal bands and normal IgG-index. Motor evoked potentials with triple stimulation, visual evoked potentials and somatosensory evoked potentials were all normal. The patient entered a rehabilitation program once weekly and over the subsequent months her motor function recovered completely. Written informed consent was

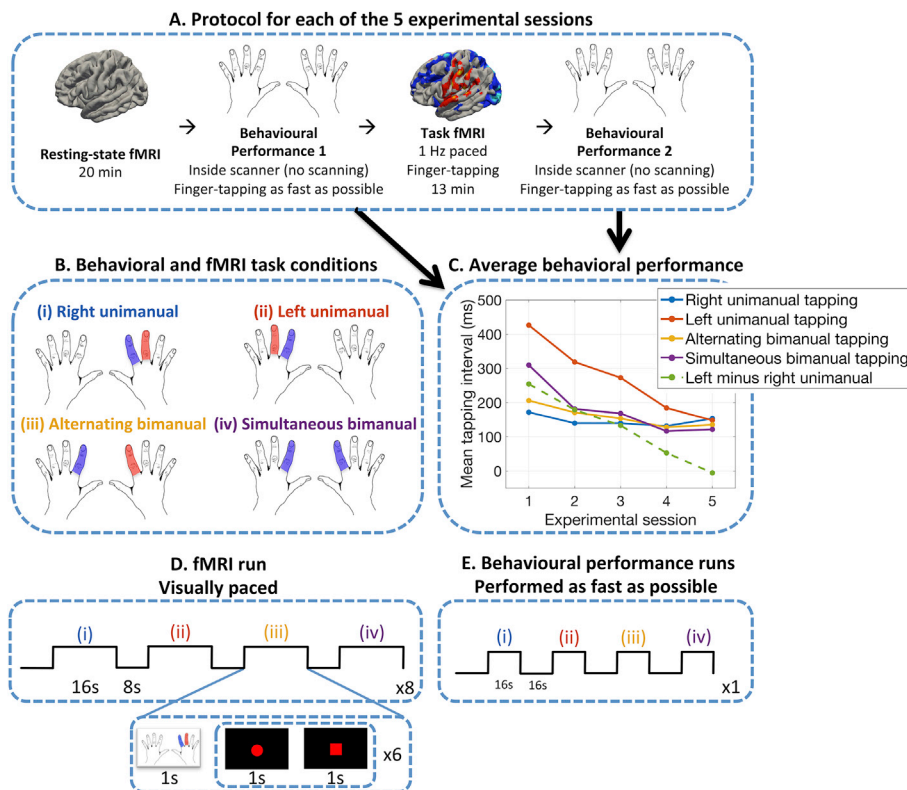
obtained from the patient prior to scanning, and all protocols were approved by the local scientific ethical committee (protocol no. KF01–131/03).

*Assessment of motor performance*

Motor performance was assessed at each session before and after functional MRI (fMRI) scanning of the brain (Fig. 1A). Using a blocked design, the patient performed four finger-tapping tasks in blocks lasting 16 s, separated by a break of equal duration. She was instructed to perform as many finger taps as possible during a task block (Fig. 1E). The four tapping tasks consisted of: (i) alternate tapping with right index and middle finger, (ii) alternate tapping with left index and middle finger, (iii) alternate tapping with left and right index finger, and (iv) simultaneous tapping with right and left index finger (Fig. 1B). Motor performance was indexed as the mean interval between consecutive button presses with either finger for each of the four tasks separately. For each task the average performance across the two performance runs was calculated (Fig. 1C).

*Functional magnetic resonance imaging*

The patient underwent five fMRI examinations of the brain. The first fMRI session was performed at day 17 after paresis onset. Successive fMRI sessions were performed on a 3.0T Magnetom Trio Scanner (Siemens, Erlangen) equipped with an 8-channel receive head coil, and scans were obtained 4 and 7 weeks as well as 3 and 9 months after paresis onset. Resting-state and task-based changes in blood-oxygen-level-dependent (BOLD)-signal were mapped using an echo planar imaging (EPI) sequence (TR = 2490 ms, TE = 30 ms, flip angle = 90°). Each brain volume had a 3 × 3 × 3 mm isotropic voxel resolution and consisted of 42 slices (192 × 192 mm) acquired in interleaved order. The task fMRI run consisted of 311 brain volumes (~13 min) preceded by a resting-state fMRI run consisting of 480 brain volumes (20 min) per session. The first MRI session also included a structural T1-weighted scan of the brain,



**Fig. 1. Experimental protocol and motor performance.** (A) Time line of a single experimental session. (B) Illustration of the four experimental finger-tapping tasks. (C) Relative change in tapping performance (y-axis) estimated as reduction in the mean interval between button presses across the five experimental sessions (x-axis). Unimanual finger-tapping with the index and middle finger of the paretic left hand (red line), simultaneous bimanual finger-tapping (purple line) and alternating bimanual finger-tapping (yellow line) gradually improved across experimental sessions. Unimanual finger-tapping with the index and middle finger of the non-paretic right hand (blue line) remained stable over sessions. The dotted green line reflects the mean difference between unimanual finger-tapping with the left and right hand. (D) Time line of a single fMRI run, which consisted of eight blocks per finger-tapping condition. During fMRI, tapping rate was visually paced. (E) The behavioural performance runs were acquired inside the MRI scanner before and after each fMRI run without scanning. These runs consisted of a single block (16 s) of each of the four tapping conditions, where the subject performed the tapping as fast as possible.

using a magnetisation prepared rapid acquisition gradient echo (MPRAGE) sequence (TR = 1550 ms, TE = 3.04 ms, inversion time = 800 ms, flip-angle = 9°, 256 × 256 acquisition matrix, 1 mm isotropic voxels, 192 slices).

### Motor fMRI paradigm

We employed a blocked fMRI paradigm which alternated between the same four conditions as in the behavioural performance task (Fig. 1B and D): (i) alternate tapping with right index and middle finger, (ii) alternate tapping with left index and middle finger, (iii) alternate tapping with left and right index finger and (iv) simultaneous tapping with left and right index finger. However, as opposed to the behavioural performance tasks (where the subject performed the tapping as fast as possible), the fMRI tapping condition was visually paced at a frequency of 0.5 Hz (Fig. 1D). The low tapping rate ensured equivalent performance during fMRI acquisition across the four conditions and five sessions. The four conditions were visually instructed by presenting a drawing of the left and right hand (dorsal view) on a screen. The two fingers that were required to tap in a given block were labelled with red or blue colour. Different colours instructed alternating tapping with one finger marked in red and the other in blue (Fig. 1B). When both fingers were marked with the same blue colour, they had to be tapped simultaneously (Fig. 1B). A single finger-tapping block lasted for 16 s, including the instruction screen (displayed for 1 s), and pauses at the beginning and end of the block. Within each block, six repetitions (each consisting of a sequence of two finger taps, one per finger) were cued by a centrally placed red circle (displayed for 1 s) that changed appearance to a square (displayed for 1 s) for each repetition. Each block was followed by an 8 s period of rest. Each tapping condition was repeated 8 times during the experiment. The visual presentation was provided by means of a LCD projector (Canon LV7540) located outside the scanner room. A zoom lens (BuhlOptics 849MCZ087) projected the image onto a screen behind the patient's head. The screen covered 24° × 18° of the visual field and was visible to the patient through a mirror.

### Pre-processing

Both task-based and resting-state fMRI data were pre-processed using statistical parametric mapping software (SPM12, <http://www.fil.ion.ucl.ac.uk/spm>). The first two brain volumes were excluded from analysis to allow for T1 equilibrium. The EPI images were motion corrected by a six-parameter rigid body realignment to the time series mean using a two-step procedure, and spatially normalised to the Montreal Neurological Institute (MNI) 305 template and then spatially smoothed using a Gaussian kernel with 8 mm full-width at half maximum.

### Statistical analysis

The task-specific performance indices, obtained before and after the task-based fMRI scanning, were treated as linear regressor (1–5) in a general linear model to test for linear improvements across sessions (Fig. 1C).

For task-based fMRI, the five sessions were modelled using a fixed-effects (within-subject) general linear model (GLM) in SPM12 using session-specific regressors. Each of the four tapping conditions was modelled separately by convolving the 16 s blocks with the canonical hemodynamic response function. In addition, a 24 parameter Volterra expansion of the motion-parameters were included per run as nuisance-regressors to account for residual motion effects in the data (Friston et al., 1996). We modelled changes in tapping-induced BOLD activity (mean across the four conditions) associated with motor recovery. To this end, we calculated the difference in tapping performance between the affected left (condition (ii)) and the unaffected right hand (condition (i)) for each session and used this metric to specify an appropriate contrast vector in the GLM (Fig. 1C, green dotted line). Significance level was set

at  $p < 0.05$ , applying family-wise error (FWE) correction at the cluster-level, using an uncorrected cluster-forming threshold of  $p < 0.001$ .

The GLM analysis of task-based fMRI data revealed three cortical regions, the right medial prefrontal cortex (mPFC), left and right PMd, where task-related activity scaled linearly with recovery of motor function. This prompted post-hoc connectivity analyses to delineate time-dependent changes in functional connectivity among these three cortical regions during the course of functional recovery. Connectivity analysis estimated partial correlation between the mean time-series in each of the three clusters controlling for the same 24 nuisance parameters as the main GLM model. The correlation was performed separately for each of the four conditions by only considering time-points where the specific condition was performed and it was done separately for each session.

Functional connectivity analyses were also extended to the resting-state fMRI data to test for recovery-related changes in functional connectivity among right mPFC, right and left PMd in the absence of finger movements. Resting-state fMRI analysis included the 24 motion regressors as nuisance variable.

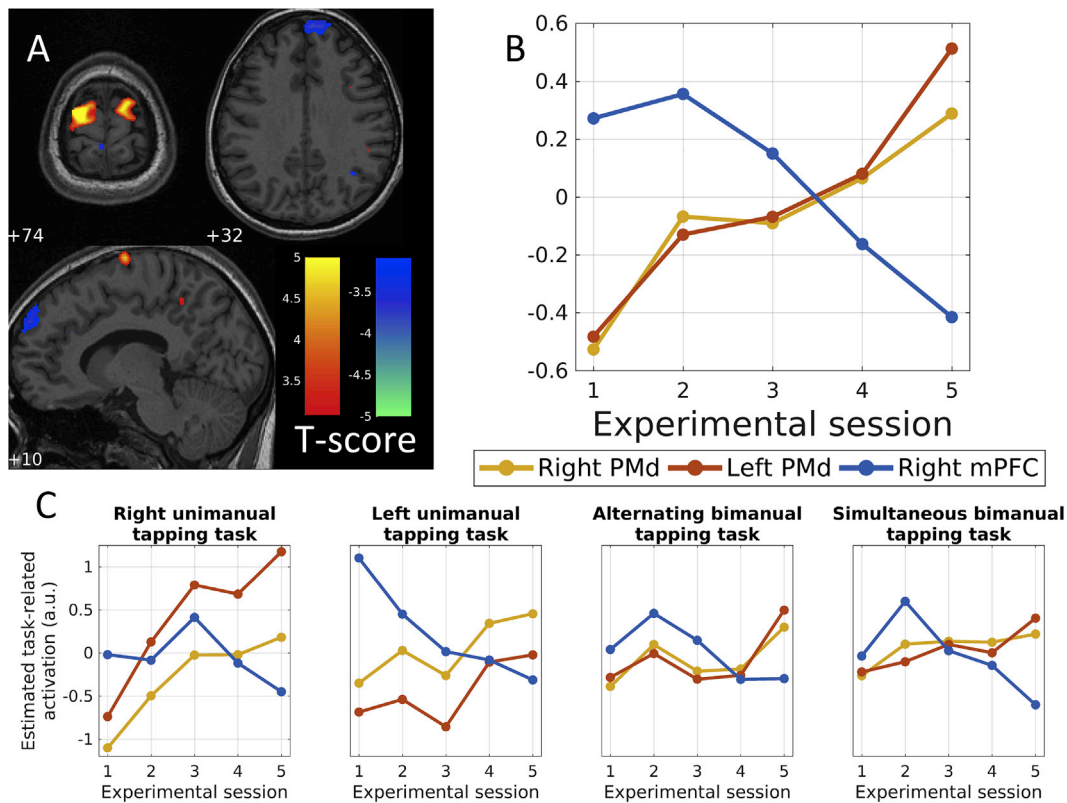
### Results

At the time of inclusion, the patient presented with marked weakness of the left hand. Left hand motor function gradually returned to the normal level over the subsequent three months. Paresis had recovered completely at the final assessment after nine months (Fig. 1C). We assessed the behavioural improvement over time by correlating behavioural performance with a linear regressor reflecting the 5 time points (1–5). We found that left hand ( $r = -0.99$ ,  $p = 0.002$ ) but also the difference between left and right hand performance (green dotted line, Fig. 1C) significantly improved over time ( $r = -0.998$ ,  $p < 0.001$ ). This was also the case for bimanual alternating finger-tapping ( $r = -0.93$ ,  $p = 0.020$ ) and bimanual simultaneous finger-tapping ( $r = -0.89$ ,  $p = 0.041$ ), whereas unimanual right hand finger-tapping remained stable across the five sessions ( $r = -0.45$ ,  $p = 0.446$ ; Fig. 1C).

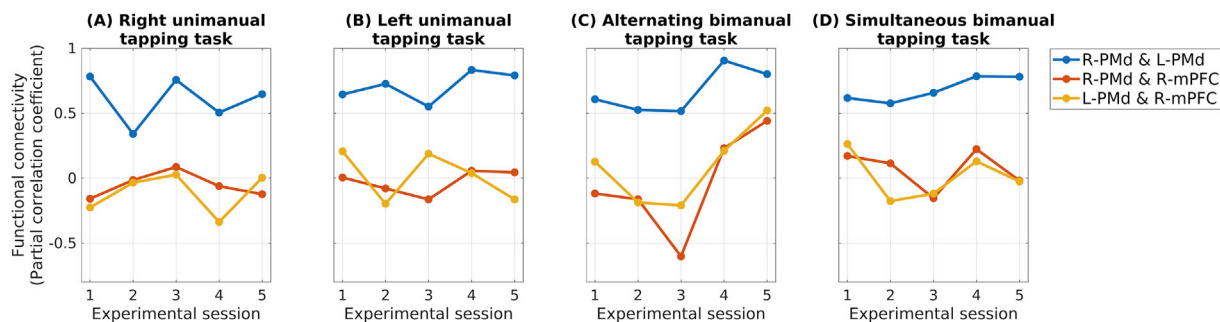
The fMRI measurements were performed five times during the period of left hand recovery and the patient could perform the task adequately from the beginning. Baseline contrasts for each tapping condition and each session are illustrated in Supplementary material (Fig. 1S). Regression analysis revealed a statistically significant relationship between functional activation in the right ( $P_{FWE} = 0.001$ , peak MNI coordinates  $x,y,z = 14,-4,74$ ) and left ( $P_{FWE} < 0.001$ , peak MNI coordinates  $x,y,z = -20,-8,72$ ) PMd and motor improvement (Fig. 2A). The PMd showed a bilateral deactivation in the acute-subacute phase. The motor activation of left and right PMd gradually increased over time, reflecting the magnitude of clinical improvement (Fig. 2A and B). When we extracted the parameter estimates per condition, we saw that this activation pattern was present for finger-tapping with the affected (left) and unaffected (right) hand, and to a lesser extent with bimanual finger-tapping (Fig. 2C). A single brain region in right mPFC ( $P_{FWE} < 0.001$ , peak MNI coordinate  $x,y,z = 6,60,32$ ) showed the opposite relationship (Fig. 2A and B). This activation pattern was most pronounced with finger-tapping of the paretic hand as illustrated by extracting the parameter estimates per condition (Fig. 2C).

Descriptive post-hoc analysis of functional connectivity revealed an increase in functional connectivity between right mPFC and bilateral PMd in the bimanual alternating tapping task in the last two sessions where the patient had recovered clinically (Fig. 3). Increasing functional connectivity was also observed between right and left PMd with motor recovery in the two bimanual tasks (Fig. 3). No clear trends were detected in the other conditions. Formal statistical testing revealed that only the correlation between left and right PMd significantly increased over time ( $r = 0.89$ ,  $p = 0.044$ ), while all other correlations were non-significant ( $p > 0.19$ ).





**Fig. 2. Functional activation of dorsal premotor cortex and medial prefrontal cortex reflect motor improvement.** The PMd showed a bilateral deactivation in the acute-subacute phase that turned into increased motor activation in proportion to the magnitude of clinical improvement. The stronger motor remission, the more the activation of bilateral PMd increased. The right medial prefrontal cortex (mPFC) showed the opposite relationship, an initial increased activation that gradually decreased in proportion to motor remission (Fig. 2A and B). Fig. 2C shows the parameter estimates per condition over sessions. It illustrates that the inverse dynamic of PMd and mPFC activation were present regardless of tapping with the left (paretic hand) and right hand, and to a lesser extent with bimanual movements. The axial slices are arranged from most cranial to most caudal (z-coordinates, Montreal Neurological Institute (MNI)). The red and blue overlays indicate t-values as shown in the colour bar to the right.

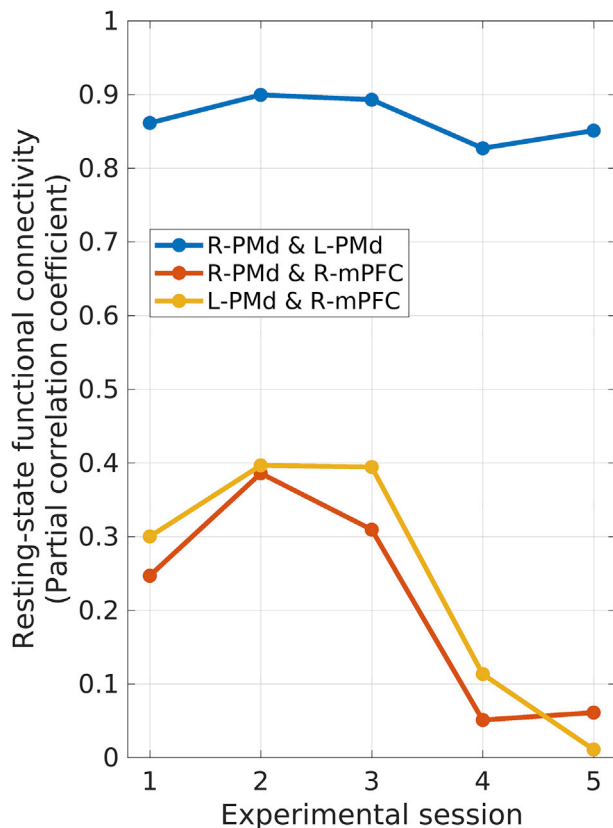


**Fig. 3. Functional connectivity patterns for each motor condition.** Functional connectivity (y-axis) for each motor condition across the five experimental sessions (x-axis). A trend towards increased functional connectivity between right mPFC and bilateral PMd was seen in the bimanual alternating tapping task in the last two sessions where the patient had recovered clinically (red and yellow lines in panel C). Functional coupling between right and left PMd also increased with motor recovery in the bimanual tapping tasks (blue lines in panels C and D). With formal testing only the correlation between right and left PMd over time significantly increased.

The resting-state functional connectivity analysis showed significant within-session correlation between right mPFC and both right and left PMd in the first three fMRI sessions ( $p < 0.001$ , uncorrected). This inter-area correlation decreased to a non-significant level for the last two sessions ( $p > 0.015$ , uncorrected; Fig. 4). Accordingly, we observed a weak statistical trend towards a decrease in resting-state connectivity between right mPFC and right PMd ( $r = 0.75$ ,  $p = 0.14$ ) and between right mPFC and left PMd ( $r = 0.80$ ,  $p = 0.11$ ). Functional connectivity between left and right PMd was highly significant across all five experimental sessions.

**Discussion**

This is the first longitudinal fMRI study on a single-case patient with conversion paresis from impairment to full recovery. We found an inversely related activation pattern between PMd and mPFC. The PMd showed bilateral deactivation in the acute-subacute phase that gradually changed into increased activation in proportion to motor recovery, whereas the right mPFC displayed the opposite pattern. These inverse dynamics were present during tapping with the affected or non-affected hand as well as during bimanual finger-tapping.



**Fig. 4. Resting-state functional connectivity between right medial prefrontal cortex and dorsal premotor cortex.** Change in resting-state functional connectivity (y-axis) across the five experimental sessions (x-axis). Resting-state functional connectivity between right mPFC and bilateral PMd was significantly increased during the first three sessions and decreased to a non-significant level during the last two sessions in which the patient had recovered clinically (red and yellow lines). Resting-state functional connectivity between bilateral PMd was higher than prefrontal-premotor connectivity and remained stable across all five fMRI sessions.

The PMd is particularly well positioned to produce functional paresis and to mediate recovery of motor function since it takes part in the action selection network and in the planning and preparation of movements (Graziano, 2006; O’Shea et al., 2007). Moreover, the PMd serves an integrative role of converging input from subcortical motor (basal ganglia and cerebellum) and parietal cortex afferents, and sends projections to the primary motor cortex and directly to the corticospinal tract (Dum and Strick, 1991). A recent study has shown increased cortical thickness in bilateral premotor cortex in hemiparetic conversion patients which could represent a compensatory response to the increased challenge of motor function (Aybek et al., 2014). Functional imaging studies have reported a failure to activate the premotor cortex in patients with left side paralysis (Marshall et al., 1997) and in patients with excessive motor symptoms (Voon et al., 2011) during an action selection task. These findings are in line with our observations of a deactivation of PMd in the initial course of events. In parallel with clinical motor improvement we found a gradual increase in activation of PMd which most likely reflects a return to a normal activation pattern.

The mPFC expressed the opposite pattern with increased activation in the acute-subacute phase which gradually diminished with motor recovery. Indeed it is interesting that a corresponding region in medial prefrontal cortex is activated when inhibiting intentional actions (Brass and Haggard, 2007). Brass et al. investigated the neural correlates to the endogenous inhibition of intentional action using fMRI. Comparing intentional inhibition of action with the execution of

action, they found activity in the dorso-fronto-medial cortex. They proposed this region to represent the ‘whether’ component of intentional action which may involve a final check whether or not the action goes ahead (a ‘veto’-region) (Brass and Haggard, 2008). Earlier imaging studies have proposed that top-down regulation from higher order frontal regions may inhibit the motor networks downstream as a pathway to produce functional symptoms (Marshall et al., 1997; Spence et al., 2000). A simultaneous activation of frontal inhibitory areas and inhibition of the somatosensory cortex has previously been demonstrated in motor conversion patients (Marshall et al., 1997; Tiihonen et al., 1995). The inverse dynamics of PMd and mPFC activity is compatible with the notion of top-down inhibition of PMd in the acute-subacute phase which gradually diminishes with the resolution of symptoms. It is tempting to speculate that an overactivation of the ‘veto’ or ‘whether’ region in mPFC along with a deficient activation of dorsal premotor areas might underlie the neural substrate of conversion paresis.

We further wanted to examine whether the reduction of PMd activation was specific to movement of the affected hand or represented a more general phenomenon. We found that finger-tapping with the affected and non-affected hand as well as bimanual finger-tapping elicited the same inverse dynamics of PMd and mPFC over time. We therefore propose that the reduced PMd and increased mPFC activity reflects a task-independent cortical dysfunction in conversion paresis that gradually disappears with motor recovery.

For both unimanual and bimanual tapping, motor performance with the affected left hand recovered gradually from session to session. It is worth noting that bimanual tapping was less impaired from the very beginning relative to unimanual left hand tapping, although bimanual tapping engaged the affected hand (Fig. 1C). This suggests that performance of the affected left hand can be improved using a bilateral strategy (Helmuth and Ivry, 1996).

Functional connectivity analysis revealed a trend increase in task-based functional connectivity between right mPFC and bilateral PMd in the last sessions after the patient had recovered from hand paresis. This trend was only present during bimanual alternating tapping, which was the most demanding task of the four conditions. An increased functional coupling between right and left PMd was also observed in the bimanual conditions when motor symptoms had resolved. Together, these findings suggest that recovery from conversion paresis is associated with the restoration of task-based functional connectivity between right mPFC and PMd bilaterally, but also between the right and left PMd.

Interestingly, prefrontal-premotor connectivity in the resting-state showed the opposite pattern. Functional coupling between right mPFC and both PMd was stronger in the acute paretic stage and decreased in the last two sessions, when the patient had recovered from hand paresis. In contrast, inter-hemispheric resting-state functional connectivity between right and left PMd was stably expressed throughout all sessions. The gradual decrease in resting-state functional connectivity between mPFC and both PMd (red and yellow curves, Fig. 4) displayed the same time-course as the attenuation in task-related activation of right mPFC during the course of recovery (blue curve, Fig. 2B). It is therefore tempting to speculate that a reduced resting-state connectivity between mPFC and PMd might have driven the opposite temporal dynamics of task-related activity of mPFC (i.e., a decrease over time) and PMd (i.e., an increase over time) in our patient. However, these results also illustrate that the relationship between task-associated activation, task-based and resting-state functional connectivity is not straightforward and needs to be addressed further in future prospective fMRI studies.

An obvious limitation of this single-case study is that we cannot make generalised inferences regarding motor conversion disorder. When interpreting serial fMRI studies, it is important to demonstrate the reproducibility and stability of serial measurements in healthy controls. Therefore, it would have been desirable to assess session-to-session variations in activity and connectivity. In this study, we focused on

functional activation related to recovery from a conversion paresis and functional connectivity was only addressed post-hoc. However, the present study generated new hypotheses that warrant further investigation in future prospective group studies. This would enable to examine whether the dynamic changes in functional activation and connectivity of prefrontal-premotor regions found in our patient is a consistent feature shared among affected patients. Experimental manipulations of motor or cognitive effort as well as emotional engagement would be helpful to provide deeper insights into the involvement of prefrontal, premotor and limbic areas and their dynamic interaction during the recovery from a motor conversion disorder.

## Conclusions

This first longitudinal study on a single patient provides new insights into the neural correlates of conversion paresis. We identified deactivation of premotor and increased activation of prefrontal regions that gradually returned to normal with symptom resolution in a patient with conversion paresis. The inverse activation pattern presumably reflects a cortical dysfunction in conversion paresis which might involve a top-down active inhibitory function of medial prefrontal cortex including the ‘veto’ region in the model of voluntary action on premotor areas. Although these findings are from a single-case study, they provide unique insights into the dysfunction underlying motor conversion and the neural substrate of volitional actions. The hypothesis that motor conversion may be due to excessive medial prefrontal activity and deficient recruitment of dorsal premotor cortex should be addressed prospectively with fMRI or other functional brain mapping techniques in groups of affected patients, including the analyses of functional prefrontal-premotor-motor connectivity.

## Conflicts of interest statement

AMD has received speaker's fee from Biogen Idec and Merck-Serono. Congress fee to ECTRIMS 2010 was covered by Merck-Serono.

FS has served on scientific advisory boards for Biogen, Genzyme, Merck, Novartis and Teva; served as consultant for Biogen; received support for congress participation from Biogen, Novartis and Teva; and received speaker honoraria from Biogen, Genzyme, Merck, Novartis and Teva. His laboratory has received research support from Biogen, EMD Serono and Novartis.

KS has received support for congress participation from Biogen Idec, Sanofi-Genzyme, Merck Serono, Novartis and Teva, and served on advisory board for Novartis and Sanofi-Genzyme.

HS has received honoraria as editor from Elsevier Publishers, Amsterdam, The Netherlands and Springer Publishing, Stuttgart, Germany and received a research fund from Biogen-idec.

KWA and KHM have no conflicts of interest.

## Acknowledgement

This work was supported by the Lundbeck Foundation (Grant of Excellence: Mapping, Modulation & Modeling the Control of Actions; Grant nr. 59-A5399); The Danish Multiple Sclerosis Society (grant no. 9315); intramural research grant of Hvidovre Hospital; and a partial Ph.D. stipend from the University of Copenhagen, Faculty of Health Sciences.

## Appendix A. Supplementary data

Supplementary data related to this article can be found at <https://doi.org/10.1016/j.neuroimage.2018.03.061>.

## References

- Aybek, S., Nicholson, T.R., Draganski, B., Daly, E., Murphy, D.G., David, A.S., Kanaan, R.A., 2014. Grey matter changes in motor conversion disorder. *J. Neurol. Neurosurg. Psychiatry* 85, 236–238.
- Boeckle, M., Liegl, G., Jank, R., Pieh, C., 2016. Neural correlates of conversion disorder: overview and meta-analysis of neuroimaging studies on motor conversion disorder. *BMC Psychiatry* 16, 195.
- Brass, M., Haggard, P., 2007. To do or not to do: the neural signature of self-control. *J. Neurosci.* 27, 9141–9145.
- Brass, M., Haggard, P., 2008. The what, when, whether model of intentional action. *Neuroscientist* 14, 319–325.
- Burgmer, M., Konrad, C., Jansen, A., Kugel, H., Sommer, J., Heindel, W., Ringelstein, E.B., Heuft, G., Knecht, S., 2006. Abnormal brain activation during movement observation in patients with conversion paralysis. *Neuroimage* 29, 1336–1343.
- Diagnostic and Statistical Manual of Mental Disorders, fifth ed. American Psychiatric Association.
- Dum, R.P., Strick, P.L., 1991. The origin of corticospinal projections from the premotor areas in the frontal lobe. *J. Neurosci.* 11, 667–689.
- Friston, K.J., Williams, S., Howard, R., Frackowiak, R.S., Turner, R., 1996. Movement-related effects in fMRI time-series. *Magn. Reson. Med.* 35, 346–355.
- Graziano, M., 2006. The organization of behavioral repertoire in motor cortex. *Annu. Rev. Neurosci.* 29, 105–134.
- Helmuth, L.L., Ivry, R.B., 1996. When two hands are better than one: reduced timing variability during bimanual movements. *J. Exp. Psychol. Hum. Percept. Perform.* 22, 278–293.
- Kanaan, R.A., Craig, T.K., Wessely, S.C., David, A.S., 2007. Imaging repressed memories in motor conversion disorder. *Psychosom. Med.* 69, 202–205.
- Marshall, J.C., Halligan, P.W., Fink, G.R., Wade, D.T., Frackowiak, R.S.J., 1997. The functional anatomy of a hysterical paralysis. *Cognition* 64, B1–B8.
- O'Shea, J., Johansen-Berg, H., Trief, D., Göbel, S., Rushworth, M.F.S., 2007. Functionally specific reorganization in human premotor cortex. *Neuron* 54, 479–490.
- Spence, S.A., Crimlisk, H.L., Cope, H., Ron, M.A., Grasby, P.M., 2000. Discrete neurophysiological correlates in prefrontal cortex during hysterical and feigned disorder of movement. *Lancet* 355, 1243–1244.
- Stone, J., Zeman, A., Simonotto, E., Meyer, M., Azuma, R., Flett, S., Sharpe, M., 2007. fMRI in patients with motor conversion symptoms and controls with simulated weakness. *Psychosom. Med.* 69, 961–969.
- Tiihonen, J., Kuikka, J., Viinamaki, H., Lehtonen, J., Partanen, J., 1995. Altered cerebral blood flow during hysterical paresthesia. *Biol. Psychiatry* 37, 134–135.
- Voon, V., Brezing, C., Gallea, C., Hallett, M., 2011. Aberrant supplementary motor complex and limbic activity during motor preparation in motor conversion disorder. *Mov. Disord.* 26, 2396–2403.