

## Unusual gastric submucosal perforation following multiple magnetic bead ingestion in an infant

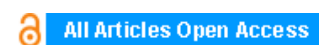
**Ghassan Nakib, Valeria Calcaterra, Balaji Krishnamurthy, Gloria Pelizzo**

### ABSTRACT

**Introduction:** Magnetic beads are hazardous, having potentially lethal consequences if ingested.

**Case Report:** A two-year-old girl, presented to the pediatric emergency department with an history of worsening abdominal pain, nausea and vomiting. The patient appeared in moderate distress. Physical examination revealed abdominal tenderness with guarding and rigidity. On abdominal X-ray examination, nine opaque foreign bodies (magnetic beads) were seen in the left hypochondrium. Explorative gastroscopy was performed and two magnets appeared at the lesser curvature, but not the remaining seven. These were pulled out and another gastroscopic attempt showed appearance of another two of the remaining ones. Removing these, the remaining five were all attached as seen on the X-ray. The magnets must have caused pressure necrosis on a gastric mucosa fold with subsequent limited submucosal perforation making a pouch was the spheres were lodged.

**Conclusion:** The ingestion of multiple magnets may require urgent surgical intervention and early removal because of very high risk of gastrointestinal perforation.



## International Journal of Case Reports and Images (IJCRI)



International Journal of Case Reports and Images (IJCRI) is an international, peer reviewed, monthly, open access, online journal, publishing high-quality, articles in all areas of basic medical sciences and clinical specialties.

Aim of IJCRI is to encourage the publication of new information by providing a platform for reporting of unique, unusual and rare cases which enhance understanding of disease process, its diagnosis, management and clinico-pathologic correlations.

IJCRI publishes Review Articles, Case Series, Case Reports, Case in Images, Clinical Images and Letters to Editor.

**Website: [www.ijcasereportsandimages.com](http://www.ijcasereportsandimages.com)**

# Unusual gastric submucosal perforation following multiple magnetic bead ingestion in an infant

Ghassan Nakib, Valeria Calcaterra, Balaji Krishnamurthy, Gloria Pelizzo

## ABSTRACT

**Introduction:** Magnetic beads are hazardous, having potentially lethal consequences if ingested. **Case Report:** A two-year-old girl, presented to the pediatric emergency department with an history of worsening abdominal pain, nausea and vomiting. The patient appeared in moderate distress. Physical examination revealed abdominal tenderness with guarding and rigidity. On abdominal X-ray examination, nine opaque foreign bodies (magnetic beads) were seen in the left hypochondrium. Explorative gastroscopy was performed and two magnets appeared at the lesser curvature, but not the remaining seven. These were pulled out and another gastroscopic attempt showed appearance of another two of the remaining ones. Removing these, the remaining five were all attached as seen on the X-ray. The magnets must have caused pressure necrosis on a gastric mucosa fold with subsequent limited submucosal perforation making a pouch was the

spheres were logged. **Conclusion:** The ingestion of multiple magnets may require urgent surgical intervention and early removal because of very high risk of gastrointestinal perforation.

**Keywords:** Children, Ingestion, Magnetic beads, Perforation

### How to cite this article

Nakib G, Calcaterra V, Krishnamurthy B, Pelizzo G. Unusual gastric submucosal perforation following multiple magnetic bead ingestion in an infant. Int J Case Rep Images 2017;8(7):451–453.

Article ID: Z01201707CR10805GN

\*\*\*\*\*

doi:10.5348/ijcri-201766-CR-10805

Ghassan Nakib<sup>1</sup>, Valeria Calcaterra<sup>2</sup>, Balaji Krishnamurthy<sup>3</sup>, Gloria Pelizzo<sup>4</sup>

**Affiliations:** <sup>1</sup>MD, Department of Pediatric Surgery, Medclinic Middle East, Medclinic City Hospital Dubai, UAE; <sup>2</sup>MD, Pediatric Unit, Department of Maternal and Children's Health, Fondazione IRCCS Policlinico San Matteo and Department of Internal Medicine, University of Pavia, Pavia, Italy; <sup>3</sup>MD, Pediatric Department, Gastroenterology, Medclinic ME, Medclinic city Hospital Dubai, UAE; <sup>4</sup>MD, Pediatric Surgery Unit, Children's Hospital, Istituto Mediterraneo di Eccellenza Pediatrica, Palermo, Italy.

**Corresponding Author:** Dr. Ghassan Nakib, Department of Pediatric Surgery, Medclinic Middle East, Medclinic City Hospital Dubai, UAE; Email: Ghassan.Nakib@medclinic.ae

Received: 30 January 2017

Accepted: 22 March 2017

Published: 01 July 2017

## INTRODUCTION

Accidental ingestion of foreign bodies is a common problem in children [1–2]. The majority of ingested foreign bodies pass spontaneously without treatment. Magnetic beads are hazardous, having potentially lethal consequences if ingested [3–6].

## CASE REPORT

A two-year-old girl, weight 19 kg presented to the pediatric emergency department with an eight hour history of worsening abdominal pain, nausea and alimentary vomiting. The patient appeared pale with dry mucous membranes and in moderate distress. Vitals signs were as follows: temperature 36.7°C, heart rate 156 bpm, SPO<sub>2</sub> 100%, respiratory rate 26 rpm, blood

pressure 90/72 mmHg. Physical examination revealed abdominal tenderness with guarding and rigidity. The intravenous infusion of crystalloid fluids was started in pediatric emergency department.

On abdominal X-ray examination, there was no free air or dilated bowel loops; however, nine opaque foreign bodies (magnetic beads) were seen in the left hypochondrium (Figure 1A). Explorative gastroscopy was performed and two hypochondrium (Figure 1B), but not the remaining seven. These were pulled out and another gastroscopic attempt showed appearance of another two of the remaining ones. Removing these, the remaining five were all attached as seen on the X-ray (Figure 1C). Gastric perforation was suspected. Laparoscopic assisted enterolysis from the Treitz to terminal ileum was performed and no perforation was seen. Stomach anterior wall was free of any perforations. The magnets must have caused pressure necrosis on a gastric mucosa fold with subsequent limited submucosal perforation making a pouch were the spheres were lodged (Figure 1D). The postoperative period was uneventful and the patient was discharged on the second postoperative day.

## DISCUSSION

Complications from foreign body ingestion in children are uncommon but the ingestion of multiple magnets may require urgent surgical intervention and early removal because of very high risk of gastrointestinal perforation [1–3].

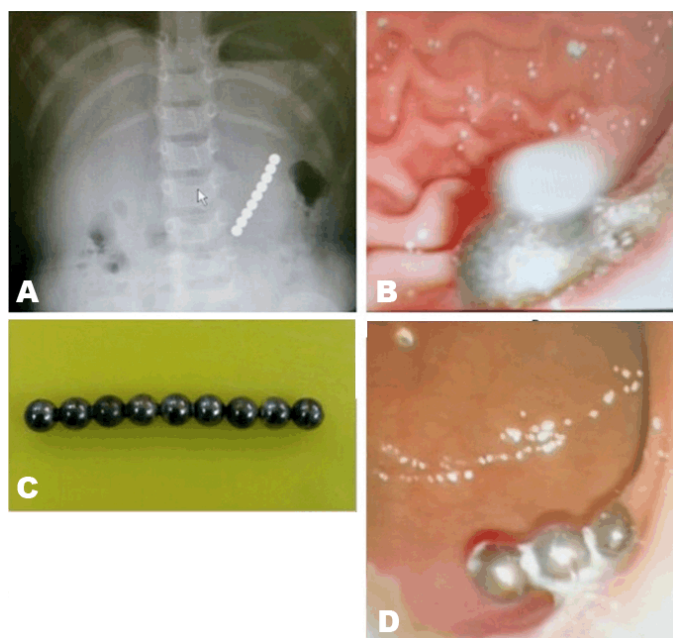


Figure 1: Gastric submucosal perforation following multiple magnet ingestion. Panel (A) Abdominal X-ray examination showing nine opaque foreign bodies with a round shape in the gastric area, (B) Two magnets appeared at the lesser curvature, (C) Ingested magnets, and (D) Submucosal gastric pouch in which the magnetic bead were lodged.

## CONCLUSION

Prevention campaigns from health authorities should start about the hazards of magnetic toys to prevent the appearance of new similar cases.

\*\*\*\*\*

## Author Contributions

Ghassan Nakib – Substantial contributions to conception and design, Acquisition of data, Drafting the article, Revising it critically for important content, Final approval of the version to be published

Valeria Calcaterra – Substantial contributions to conception and design of data, Drafting the article, Revising it critically for important content, Final approval of the version to be published

Balaji Krishnamurthy – Substantial contributions to conception and design, Acquisition of data, Drafting the article, Revising it critically for important content, Final approval of the version to be published

Gloria Pelizzo – Substantial contributions to conception and design of data, Drafting the article, Revising it critically for important content, Final approval of the version to be published

## Guarantor

The corresponding author is the guarantor of submission.

## Conflict of Interest

Authors declare no conflict of interest.

## Copyright

© 2017 Ghassan Nakib et al. This article is distributed under the terms of Creative Commons Attribution License which permits unrestricted use, distribution and reproduction in any medium provided the original author(s) and original publisher are properly credited. Please see the copyright policy on the journal website for more information.

## REFERENCES

1. Kay M, Wyllie R. Pediatric foreign bodies and their management. *Curr Gastroenterol Rep* 2005 Jun;7(3):212–8.
2. Lin MT, Yeung CY, Lee HC, Sheu JC, Wang NL, Lee KS. Management of foreign body ingestion in children: Experience with 42 cases. *Acta Paediatr Taiwan* 2003 Sep–Oct;44(5):269–73.
3. Zgraj O, Awadalla S. Accidental ingestion of magnetic spheres in children. *Ir Med J* 2015 May;108(5):149–50.
4. Paul SP, Shalaby MS. Accidental ingestion of two magnets: Should we intervene? *Br J Hosp Med (Lond)* 2016 Feb;77(2):115.
5. Si X, Du B, Huang L. Multiple magnetic foreign bodies causing Severe digestive tract injuries in a child. *Case Rep Gastroenterol* 2016 Nov 25;10(3):720–7.

6. Kromhout HE, Uijterschout L, Koopman-Keemink Y, Zijp GW, Brus F. Serious gastrointestinal complications due to accidental ingestion of magnetic toy parts. [Article in Dutch]. *Ned Tijdschr Geneesk* 2010;154:A1917.

## SUGGESTED READING

- Kramer RE, Lerner DG, Lin T, Manfredi M, Shah M, Stephen TC. Management of ingested foreign bodies in children: A clinical report of the NASPGHAN Endoscopy Committee. *J Pediatr Gastroenterol Nutr* 2015; 60:562–74.

Access full text article on  
other devices



Access PDF of article on  
other devices



## Edorium Journals: An introduction

Edorium Journals Team

### About Edorium Journals

Edorium Journals is a publisher of high-quality, open access, international scholarly journals covering subjects in basic sciences and clinical specialties and subspecialties.

#### Invitation for article submission

We sincerely invite you to submit your valuable research for publication to Edorium Journals.

### But why should you publish with Edorium Journals?

In less than 10 words - we give you what no one does.

### Vision of being the best

We have the vision of making our journals the best and the most authoritative journals in their respective specialties. We are working towards this goal every day of every week of every month of every year.

### Exceptional services

We care for you, your work and your time. Our efficient, personalized and courteous services are a testimony to this.

### Editorial Review

All manuscripts submitted to Edorium Journals undergo pre-processing review, first editorial review, peer review, second editorial review and finally third editorial review.

### Peer Review

All manuscripts submitted to Edorium Journals undergo anonymous, double-blind, external peer review.

### Early View version

Early View version of your manuscript will be published in the journal within 72 hours of final acceptance.

### Manuscript status

From submission to publication of your article you will get regular updates (minimum six times) about status of your manuscripts directly in your email.

### Our Commitment

#### Six weeks

You will get first decision on your manuscript within six weeks (42 days) of submission. If we fail to honor this by even one day, we will publish your manuscript free of charge.\*

#### Four weeks

After we receive page proofs, your manuscript will be published in the journal within four weeks (31 days). If we fail to honor this by even one day, we will publish your manuscript free of charge and refund you the full article publication charges you paid for your manuscript.\*

### Favored Author program

One email is all it takes to become our favored author. You will not only get fee waivers but also get information and insights about scholarly publishing.

### Institutional Membership program

Join our Institutional Memberships program and help scholars from your institute make their research accessible to all and save thousands of dollars in fees make their research accessible to all.

### Our presence

We have some of the best designed publication formats. Our websites are very user friendly and enable you to do your work very easily with no hassle.

### Something more...

We request you to have a look at our website to know more about us and our services.

\* Terms and condition apply. Please see Edorium Journals website for more information.

We welcome you to interact with us, share with us, join us and of course publish with us.



Edorium Journals: On Web



Browse Journals

CONNECT WITH US

