

Manuscript Details

Manuscript number	PSYN_2018_255_R2
Title	Common and different neural markers in major depression and anxiety disorders: a pilot structural magnetic resonance imaging study
Article type	Full Length Article

Abstract

Although anxiety and depression often co-occur and share some clinical features, it is still unclear if they are neurobiologically distinct or similar processes. In this study, we explored common and specific cortical morphology alterations in depression and anxiety disorders. Magnetic Resonance Imaging data were acquired from 13 Major Depressive Disorder (MDD), 11 Generalized Anxiety Disorder (GAD), 11 Panic Disorder (PD) patients and 21 healthy controls (HC). Regional cortical thickness, surface area (SA), volume and gyrification were measured and compared among groups. We found left orbitofrontal thinning in all patient groups, as well as disease-specific alterations. MDD showed volume deficits in left precentral gyrus compared to all groups, volume and area deficits in right fusiform gyrus compared to GAD and HC. GAD showed lower SA than MDD and PD in right superior parietal cortex, higher gyrification than HC in right frontal gyrus. PD showed higher gyrification in left superior parietal cortex when compared to MDD and higher SA in left postcentral gyrus compared to all groups. Our results suggest that clinical phenotypic similarities between major depression and anxiety disorders might rely on common prefrontal alterations. Frontotemporal and parietal abnormalities may represent unique biological signatures of depression and anxiety.

Keywords	Generalized anxiety disorder; major depressive disorder; panic disorder; brain morphometry; MRI.
Corresponding Author	Giuseppe Delvecchio
Corresponding Author's Institution	Department of Neurosciences and Mental Health, Fondazione IRCCS Ca' Granda Ospedale Maggiore Policlinico, University of Milan
Order of Authors	Eleonora Maggioni, Giuseppe Delvecchio, Marika Grottaroli, Marco Garzitto, Sara Piccin, Carolina Bonivento, Marta Maieron, Serena D'agostini, Giampaolo Perna, Matteo Balestrieri, Paolo Brambilla
Suggested reviewers	Simone Kuehn, Jijun Wang, Gwang-Woo Jeong, Chad Sylvester, Katja Beesdo-Baum

Submission Files Included in this PDF

File Name [File Type]

Cover letter.docx [Cover Letter]

Response_to_reviewers_2nd round revisions.docx [Response to Reviewers]

highlights.docx [Highlights]

Title page.docx [Title Page (with Author Details)]

manuscript_2nd round revisions.docx [Manuscript File]

figure1.tiff [Figure]

To view all the submission files, including those not included in the PDF, click on the manuscript title on your EVISE Homepage, then click 'Download zip file'.

Milan, June 24th, 2019

Dear Prof. Dierks,

Thank You for considering our manuscript entitled "Common and different neural markers in major depression and anxiety disorders: a structural magnetic resonance imaging study" by Eleonora Maggioni, Giuseppe Delvecchio *et al.*

We are grateful to You and the Reviewers for the useful comments and suggestions, which have helped us to greatly improve our manuscript.

The Reviewers' concern and the formatting issues have been addressed in the Rebuttal letter.

Accordingly, all the revisions made appear with tracked changes in the revised manuscript.

We look forward to receiving Your final decision on our manuscript.

Sincerely,

Prof. Paolo Brambilla on behalf of all the authors

Department of Neurosciences and Mental Health, Fondazione IRCCS Ca' Granda Ospedale Maggiore Policlinico, University of Milan, Milan, Italy.

Tel. +39 02-55.03.2717 / 02-5032.0312

Milan, June 20th, 2019

Dear Prof. Dierks,

Thank You for considering our manuscript entitled “Common and different neural markers in major depression and anxiety disorders: a structural magnetic resonance imaging study” by Eleonora Maggioni, Giuseppe Delvecchio *et al.*

We are grateful to You and the Reviewers for the useful comments and suggestions, which have helped us to greatly improve our manuscript.

The Reviewers’ concern and the formatting issues have been addressed in the Rebuttal letter. Accordingly, all the revisions made appear with tracked changes in the revised manuscript.

We look forward to receiving Your final decision on our manuscript.

Sincerely,

Prof. Paolo Brambilla on behalf of all the authors

Department of Neurosciences and Mental Health, Fondazione IRCCS Ca’ Granda Ospedale

Maggiore Policlinico, University of Milan, Milan, Italy.

Tel. +39 02-55.03.2717 / 02-5032.0312

Reviewer #4

- Most of my comments were answered. The present version is improved.

Since the conclusion is limited by the small sample sizes in separate groups, I have a minor comment, which is to lower the tone describing this study as "for the first time". (e.g., in the introduction and the discussion). It is because the use of structural MRI in the differentiation of anxiety disorders from depressive disorders has been reported previously. For example, there is a recent paper done by Hilbert K et al. (Brain Behaviors, 2017 Mar), which also compared structural differences between generalized anxiety disorder and major depression.

RESPONSE: We thank the reviewer for this suggestion. As per reviewer’s suggestion we have now lowered the tone by deleting the expression “for the first time” in the introduction, discussion and conclusion sections.

Editorial formatting report:

Manuscript number	PSYN_2018_255_R1
Title	Common and different neural markers in major depression and anxiety disorders: a pilot structural magnetic resonance imaging study
Article type	Full Length Article
Corresponding author	Giuseppe Delvecchio
Language evaluation	<p>This manuscript is overall well written and comprehensible. It has a few language errors, especially in grammar and punctuation (such as missing commas), which can be fixed through copyediting. Examples are given below:</p> <ol style="list-style-type: none"> 1. In particular, among anxiety diseases, generalized anxiety disorder (GAD) and panic disorder (PD) have among the highest rates of comorbidity with major depressive disorder (MDD)..... 2. Specifically, a key role in their pathogenesis seems to be played by amygdala (Bellani et al., 2011; Etkin et al., 2009; Kim et al., 2012; Massana et al., 2003; Whittle et al., 2014), which is known to be involved in glucocorticoid secretion (Pego et al., 2010; Schuhmacher et al., 2012), emotional processing and fear response (Ressler, 2010; Comte et al., 2016), as well as anterior cingulate (van Tol et al., 2010) and prefrontal cortices (Canu et al., 2015; Shang et al., 2014), which are thought exert executive control on emotional behaviors (Delgado et al., 2008; Etkin et al., 2011). 3. The significant differences emerged from the CT comparisons are listed in Table 2. 4. Significant LGI differences emerged also among the patient groups. 5. The findings on anxiety disorders are fewer but in the same line of ours. 6. The modest sample size limited also the statistical power of the study.
Formatting evaluation	<p>Several formatting changes are required in this manuscript, such as:</p> <p>The highlights do not conform to the 85-character limit.</p> <p>In the title page, the asterisk should be used to denote the corresponding author not the first authors.</p> <p>In the references, periods should be used in journal abbreviations.</p> <p>In Table 1, the asterisk superscript is not defined.</p> <p>In Table 1, the signs used to define abbreviations are inconsistent; i.e. both colon (:) and equal to (=) signs are used to define abbreviations. For example, “MDD: major depressive disorder; HC= Healthy Controls”</p> <p>The spacing after an “=” sign is inconsistent in all the tables. For example, “BPRS= Brief Psychiatric Rating Scale; GAF= Global assessment of functioning”; “HC (n = 21)”.</p>

RESPONSE: We thank the Editor for highlighting these aspects. We have now corrected all the language and formatting errors suggested by the Editor in the new version of the manuscript.

- Investigation of cortical morphology in GAD, PD and MDD
- Shared deficits in PFC may explain the clinical similarities between MDD, PD and GAD
- Diagnosis-specific deficits in frontotemporal and parietal areas in MDD, PD and GAD

Common and different neural markers in major depression and anxiety disorders: a pilot structural magnetic resonance imaging study

Maggioni Eleonora^{a+*}, Delvecchio Giuseppe^{b+*}, Grottaroli Marika^a, Garzitto Marco^c, Piccin Sara^d, Bonivento Carolina^d, Maieron Marta^e, D'Agostini Serena^f, Perna Giampaolo^g, Balestrieri Matteo^d, Brambilla Paolo^{b,h*}.

- a) Department of Neurosciences and Mental Health, Foundation IRCCS Ca' Granda Ospedale Maggiore Policlinico, University of Milan, via F. Sforza 35, Milan, Italy.
- b) Department of Pathophysiology and Transplantation, University of Milan, via F. Sforza 35, Milan, Italy.
- c) Scientific Institute IRCCS 'Eugenio Medea', Polo FVG, via della Bontà 7, San Vito al Tagliamento (PN) Italy.
- d) Unit of Psychiatry, Department of Medicine (DAME), University of Udine, via delle Scienze 206, Udine, Italy.
- e) Department of Physics, Azienda Ospedaliero Universitaria 'S.Maria della Misericordia', P.za S. Maria della Misericordia, Udine, Italy.
- f) Department of Neuroradiology, Azienda Ospedaliero Universitaria 'S.Maria della Misericordia', P.za S. Maria della Misericordia, Udine, Italy.
- g) Department of Clinical Neurosciences, Villa San Benedetto Menni, Hermanas Hospitalarias, FoRiPsi, via Roma 16, Albese con Cassano, Como, Italy.
- h) Scientific Institute IRCCS "E. Medea", via Don Luigi Monza 20, Bosisio Parini (Lc), Italy

⁺₊The two authors contributed equally to the study.

***Corresponding author:**

Prof. Paolo Brambilla,

Current address: Department of Neurosciences and Mental Health

Foundation IRCCS Ca' Granda Ospedale Maggiore Policlinico

Via Francesco Sforza 35

20122 Milano (Italy)

Tel: +39 02-55.03.2717

Fax: +39 02-55.03.5952

E-mail: paolo.brambilla1@unimi.it

Running title:

Brain morphology in major depression and anxiety.

Word count:

Abstract: 197. Text body: ~~4859~~4826. No. Tables: 3. No. Figures: 1.

Conflicts of interest

None.

Ethical standard

The authors assert that all procedures contributing to this work comply with the ethical standards of the relevant national and institutional committees on human experimentation and with the Helsinki Declaration of 1975, as revised in 2008.

Common and different neural markers in major depression and anxiety disorders: a pilot structural magnetic resonance imaging study

Maggioni Eleonora^{a+*}, Delvecchio Giuseppe^{b+*}, Grottaroli Marika^a, Garzitto Marco^c, Piccin Sara^d, Bonivento Carolina^d, Maieron Marta^e, D'Agostini Serena^f, Perna Giampaolo^g, Balestrieri Matteo^d, Brambilla Paolo^{b,h*}.

- a) Department of Neurosciences and Mental Health, Foundation IRCCS Ca' Granda Ospedale Maggiore Policlinico, University of Milan, via F. Sforza 35, Milan, Italy.
- b) Department of Pathophysiology and Transplantation, University of Milan, via F. Sforza 35, Milan, Italy.
- c) Scientific Institute IRCCS 'Eugenio Medea', Polo FVG, via della Bontà 7, San Vito al Tagliamento (PN) Italy.
- d) Unit of Psychiatry, Department of Medicine (DAME), University of Udine, via delle Scienze 206, Udine, Italy.
- e) Department of Physics, Azienda Ospedaliero Universitaria 'S.Maria della Misericordia', P.za S. Maria della Misericordia, Udine, Italy.
- f) Department of Neuroradiology, Azienda Ospedaliero Universitaria 'S.Maria della Misericordia', P.za S. Maria della Misericordia, Udine, Italy.
- g) Department of Clinical Neurosciences, Villa San Benedetto Menni, Hermanas Hospitalarias, FoRiPsi, via Roma 16, Albese con Cassano, Como, Italy.
- h) Scientific Institute IRCCS "E. Medea", via Don Luigi Monza 20, Bosisio Parini (Lc), Italy

⁺₊The two authors contributed equally to the study.

***Corresponding author:**

Prof. Paolo Brambilla,

Current address: Department of Neurosciences and Mental Health

Foundation IRCCS Ca' Granda Ospedale Maggiore Policlinico

Via Francesco Sforza 35

20122 Milano (Italy)

Tel: +39 02-55.03.2717

Fax: +39 02-55.03.5952

E-mail: paolo.brambilla1@unimi.it

Running title:

Brain morphology in major depression and anxiety.

Word count:

Abstract: 197. Text body: ~~4859~~4826. No. Tables: 3. No. Figures: 1.

Conflicts of interest

None.

Ethical standard

The authors assert that all procedures contributing to this work comply with the ethical standards of the relevant national and institutional committees on human experimentation and with the Helsinki Declaration of 1975, as revised in 2008.

Abstract

Although anxiety and depression often co-occur and share some clinical features, it is still unclear if they are neurobiologically distinct or similar processes. In this study, we explored common and specific cortical morphology alterations in depression and anxiety disorders. Magnetic Resonance Imaging data were acquired from 13 Major Depressive Disorder (MDD), 11 Generalized Anxiety Disorder (GAD), 11 Panic Disorder (PD) patients and 21 healthy controls (HC). Regional cortical

thickness, surface area (SA), volume and gyrification were measured and compared among groups. We found left orbitofrontal thinning in all patient groups, as well as disease-specific alterations. MDD showed volume deficits in left precentral gyrus compared to all groups, volume and area deficits in right fusiform gyrus compared to GAD and HC. GAD showed lower SA than MDD and PD in right superior parietal cortex, higher gyrification than HC in right frontal gyrus. PD showed higher gyrification in left superior parietal cortex when compared to MDD and higher SA in left postcentral gyrus compared to all groups. Our results suggest that clinical phenotypic similarities between major depression and anxiety disorders might rely on common prefrontal alterations. Frontotemporal and parietal abnormalities may represent unique biological signatures of depression and anxiety.

Keywords

Generalized anxiety disorder; major depressive disorder; panic disorder; brain morphometry; MRI.

1. Introduction

Ranked among the top ten diseases responsible for disability and mortality, anxiety and depressive disorders are highly prevalent among the general population and frequently comorbid across the entire lifespan (Hranov, 2007; Moffitt et al., 2007; King-Kallimanis et al., 2009). In particular, among anxiety diseases, generalized anxiety disorder (GAD) and panic disorder (PD) have ~~among~~ the highest rates of comorbidity with major depressive disorder (MDD) (Johnson and Lydiard, 1998; Oathes et al., 2015), ultimately leading to greater illness severity and functional impairment, reduced quality of life and poorer clinical outcome (Roy-Byrne et al., 2000). From a clinical point of view, anxiety and mood disorders share some symptoms and symptom-oriented constructs, such as emotion dysregulation (Campbell-Sills et al., 2006; Hofmann et al., 2012), irritability (Vidal-Ribas et al., 2016), attention bias (Abend and Bar-Haim, 2013; Sylvester et al., 2016), impaired social functioning (Saris et al., 2017) and sleep alterations (Mason and Harvey, 2014).

In this line, it is plausible that similar etiology and pathophysiology in anxiety and depression rely on common genetic polymorphisms (Mackinnon et al., 1990) and neurobiological vulnerability (Gulley and Nemeroff, 1993). Indeed, neuroimaging evidence suggested that these disorders share structural, metabolic and functional brain abnormalities in regions within the prefrontal-limbic network, which may moderate both anhedonia and anxiogenesis. Specifically, a key role in their pathogenesis seems to be played by amygdala (Bellani et al., 2011; Etkin et al., 2009; Kim et al., 2012; Massana et al., 2003; Whittle et al., 2014), which is known to be involved in glucocorticoid secretion (Pego et al. 2010; Schuhmacher et al., 2012), emotional processing and fear response (Ressler, 2010; Comte et al., 2016), ~~as well as together with~~ anterior cingulate (van Tol et al., 2010) and prefrontal cortices (Canu et al., 2015; Shang et al., 2014), which are thought exert executive control on emotional behaviors (Delgado et al., 2008; Etkin et al., 2011). Alterations in amygdala-prefrontal connectivity, both structural and functional, have emerged from studies on both anxiety (Kim et al., 2011; Makovac et al., 2016) and depression (Dannlowski et al., 2009; Drevets, 2000). Specifically, these studies suggested the presence of common connectivity deficits in these

disorders by reporting a similar reduced functional coupling of a system implicated in emotion regulation and processing, the corticolimbic circuitry.

Nevertheless, neuroimaging findings also suggest unique neuroanatomical profiles for these disorders. While structural Magnetic Resonance Imaging (MRI) studies consistently reported hippocampal volume reduction (Bellani et al., 2010; Caetano et al., 2004; Sheline et al., 2003; Zhao et al., 2017; Arnone et al., 2012) as well as thickness and volume deficits in the orbitofrontal cortex (Schmaal et al., 2017; Zhao et al., 2017; Arnone et al., 2012) in MDD patients, the findings on anxiety disorders are less consistent. Superior temporal, hypothalamic and basal ganglia volume changes (Hilbert et al., 2015; Terlevic et al., 2013) and temporo-parietal hyper-gyrification (Molent et al., 2017) have been reported in GAD, while increased brainstem (Protopopescu et al., 2006) and reduced volume in the temporal lobe, as a whole, (Brambilla et al., 2002) have been described in PD. Interestingly, one of the few studies that separately compared patients with MDD and anxiety disorders to healthy subjects reported specific gray matter volume deficits in right inferior frontal gyrus in MDD, in left middle and superior temporal cortex in anxiety disorders (van Tol et al., 2010). Of note, a recent research on MDD and social anxiety disorder (SAD) reported common structural alterations in the orbitofrontal-striatal-thalamic circuit along with disorder-specific alterations, in visual processing areas in MDD and in precentral gyrus in SAD (Zhao et al., 2017). A recent study aimed at differentiating MDD from GAD found that frontal and prefrontal volume provided relevant differential information on the two disorders (Hilbert et al., 2017).

Overall, despite evidence suggests both specific and common cerebral bases, a neurobiological model that clearly disentangles anxiety from depression has not been validated so far, and MRI studies that compare these disorders in terms of gray matter morphology are still lacking.

For the first timeIn this context, the present study aims to investigate cortical morphology in MDD, GAD and PD to help clarify their shared and distinct neural substrates. To provide information with improved morphological specificity compared to the existing literature, we evaluated cortical thickness, surface area, volume and gyrification. These parameters reflect partially different properties of the cortex, which in turn are influenced by specific developmental/lifetime processes. Their joint investigation can advance our knowledge of the neuroanatomical underpinnings of anxiety and major depression.

Based on the above-mentioned evidence, we hypothesize shared alterations in regions implicated in emotion regulation, as well as disease-specific abnormalities in portions of frontal, temporal and parietal lobes. Specifically, we expect that, compared to healthy controls, a) major depression and anxiety disorders will show significant deficits in regions within the prefrontal cortex, which may underlie the shared dimension of emotional dysregulation, b) GAD and PD will show similar reduction in regions within the temporo-parietal network, mainly because it might be associated with the core clinical symptoms of anxiety disorders.

2. Materials and methods

2.1 Subjects

Fifty-six participants (20 males, 38.86 ± 12.96 years) took part in the study. Among them, 35 patients were recruited from the Outpatient Psychiatric Clinic of the University Hospital of Udine, Italy: 13 were diagnosed with MDD (4 males, 46.68 ± 12.49 years), 11 with GAD (4 males, 42.43 ± 11.53 years), 11 with PD (5 males, 33.55 ± 9.53 years). Exclusion criteria included the presence of other comorbid axis I disorders, neurological or medical disorders with possible effect on brain development, history of traumatic head injury with loss of consciousness and alcohol or substance abuse. Among patients, 2 with MDD, 3 with PD and 2 with GAD had comorbid personality disorders. The remaining 21 participants were healthy controls (HC) from the local community (7 males, 36.03 ± 13.46 years, 18-66 years), with no significant differences compared to patients in terms of age, gender and handedness ($p < 0.05$). HC had no psychiatric axis I disorders and no history of alcohol or substance abuse, head trauma or neurological or major medical illnesses as well as no history of psychiatric disorders among first-degree relatives. Among patients, 8 with GAD (63.6%), 8 with PD (72.7%) and 12 with MDD (92.3%) were receiving antidepressants (8 paroxetine, 8 sertraline, 4 escitalopram, 3 venlafaxine, 2 amitriptyline, 1 citalopram, 1 duloxetine and 1 fluoxetine). A minority of participants (1 HC, 2 GAD patients, 1 PD patient and 2 MDD patients) was taking part to individual psychotherapy sessions on a weekly or fortnightly basis.

A written informed consent to the study protocol, approved by the competent ethical committee, was obtained from all participants, in accordance with the Declaration of Helsinki and local Ethical Committee guidelines.

2.2 Psychopathological assessment

The clinical diagnoses were based on the Italian version of the Structured Clinical Interview for Axis I DSM-IV disorders (SCID-I) (Spitzer et al., 1992) and confirmed by the clinical consensus of two expert psychiatrists. The absence of psychiatric axis I disorders in HC was determined using a brief non-patient version of the SCID-I. Psychopathological assessment also included the administration of 24-item Brief Psychiatric Rating Scale (BPRS) (Ventura et al., 2000) and Hamilton Anxiety and Depression Rating Scales (HARS and HDRS, respectively) (Hamilton, 1959, 1960). The Global Assessment of Functioning scale (GAF) (Endicott et al., 1976) was used to rate the overall social, occupational and psychopathological functioning. Handedness was determined using the Edinburgh Handedness Inventory (Oldfield, 1971).

2.3 MRI data acquisition

MRI data were acquired using a 1.5T Avanto magnetic resonance (MR) scanner (Siemens, Germany). A standard head coil equipped with 8 channels was used for radiofrequency transmission and reception. The participants' head motion was limited by restraining foam pads. Structural brain images were obtained using a MPRAGE T1-weighted sequence (echo time 3.93 ms, repetition time 2300 ms, voxel size $0.5 \times 0.5 \times 1$ mm³, 160 transversal slices with no gap, matrix size $512 \times 448 \times 160$).

2.4 MRI data processing

Images were processed using FreeSurfer 5.3.0 (FS, <http://surfer.nmr.mgh.harvard.edu>) (Fischl, 2012). For each subject, from the original T1-weighted image, FS performed a brain tissue segmentation and an accurate 3D reconstruction of cortical surfaces. The segmentation output and reconstructed surfaces were visually inspected and manually corrected when necessary. Each subject's cortical model was then parceled into regions of interest (ROIs) based on the Desikan-Killiany atlas (Desikan et al., 2006). Surface-based morphological measures, specifically cortical thickness (CT), surface area (SA), gray matter volume (GMV) and mean curvature (MC), were estimated at the ROI level. To better localize any early defects of cortical development, we additionally computed the local gyrification index (LGI) at each vertex of the reconstructed surface.

In the ROI study, based on clinical knowledge of the disorders and in line with our recent study on anxiety (Molent et al., 2017), we performed the morphological comparison on a subset of Desikan-Killiany ROIs (isthmus, rostral-anterior, caudal-anterior and posterior cingulate cortex; lateral orbitofrontal, medial orbitofrontal, superior frontal, rostral middle frontal, caudal middle frontal and precentral gyri; postcentral, superior parietal, supramarginal and inferior parietal gyri; entorhinal, superior temporal, middle temporal, inferior temporal and fusiform gyri; lateral occipital gyrus; insula). Conversely, the vertex-based LGI comparison was performed on the entire cortical surface.

2.5 Statistical analyses

The demographic, clinical and neuroimaging data (except LGI measures) were compared among groups on Matlab R2015a (The Mathworks, Inc) using in-house scripts based on functions from Statistics and Machine Learning toolbox.

The dependency of clinical parameters on diagnosis was assessed using one-way Analyses of Variance (ANOVAs) followed by post-hoc pairwise comparisons across all diagnostic groups (i.e. patient groups versus HC and between each other). In the ANOVAs, a statistical significance threshold of 0.05 was adopted. In the pairwise comparisons, three levels of significance were considered ($p < 0.05$, $p < 0.01$, $p < 0.001$).

In the neuroimaging regional analyses, in line with our recent study on GAD (Molent et al., 2017), group comparisons were performed using univariate General Linear Model (GLM) designs, where each neuroanatomical measure was modelled considering diagnosis, sex and age. We evaluated one parameter (CT, SA, GMV and MC) and one ROI at a time. In the ROI GLM designs, to exclude confounding effects due to different head dimensions, total intracranial volume (ICV) and hemispheric cortical area were included as covariates in the GMV and SA analyses respectively. Significant effects of diagnosis on global morphology (ICV and hemispheric SA) and ROI parameters were assessed using ANOVAs ($p < 0.05$), followed by post-hoc pairwise comparisons across all couples of groups. In the ROI comparisons, to reduce the false positive rates, a multiple comparison correction was performed, dividing the uncorrected p-value for the number of ROIs in each hemisphere ($n=21$). Both uncorrected ($p < 0.05$, $p < 0.01$) and Bonferroni's corrected ($p < 0.05^*$) p -

values are reported. The vertex-based LGI analyses were performed using the FS QDEC tool. Using the group statistics made available by QDEC, we compared two diagnostic groups at a time through two-tailed *t*-tests. As in the ROI analyses, age and sex were included as covariates, to discard their contribution to LGI. Both uncorrected ($p < 0.01$) and False Discovery Rate corrected ($p < 0.05$, FDR corrected) results are shown.

Secondary correlation analyses were performed to investigate the possible relation between clinical parameters (GAF, BPRS, HARS and HDRS scores) and regional brain morphology (CT, SA, GMV and MC), including case by case the subjects having the parameter of interest. More details on clinical scale scores and information availability can be found in Table 1. We conducted Pearson linear partial correlation analyses between the selected ROI parameter and clinical scale score, while accounting for the contribution of age, gender and, when appropriate, diagnosis. In the volume and area analyses, global measures were included as covariates to remove any confounding effects of head dimension. Both uncorrected ($p < 0.01$) and Bonferroni's corrected ($p < 0.05^*$) correlation values were extracted.

3. Results

3.1 Sample characteristics

The demographic and clinical characteristics of the population are reported in Table 1, together with ANOVA and post-hoc pairwise comparison results. Sex, handedness and language did not differ among groups, whereas differences in age and GAF, BPRS, HDRS and HARS scores emerged ($p < 0.05$). While no post-hoc pairwise differences emerged in terms of age, as expected the GAF scores were much lower in all patient groups compared to controls ($p < 0.001$). The opposite tendency emerged for the BPRS score (GAD vs. HC: $p < 0.001$, MDD and PD vs. HC: $p < 0.05$). Compared to HC, GAD and PD showed higher HARS scores ($p < 0.001$), whereas MDD showed higher scores at the HDRS scale ($p < 0.001$).

3.2 Morphological comparison among diagnostic groups

The statistics, both uncorrected and multiple comparison corrected, concerning the region-based GMV, SA, CT and MC comparisons are reported in Table 2. The significant differences surviving the Bonferroni's correction ($p < 0.05^*$) are illustrated in Figure 1. The vertex-based LGI comparison results are reported in Table 3.

3.2.1 Gray matter volume

The GMV comparison results are reported in Table 2, upper section. Although the four groups did not differ in terms of ICV, regional differences emerged: specifically, the ANOVAs showed a significant diagnosis contribution to GMV in left precentral gyrus ($p < 0.01$) and right fusiform gyrus ($p < 0.01$).

The post-hoc comparisons showed that MDD was characterized by lower GMV than the other groups in left precentral gyrus. Such a difference was moderately significant in MDD vs. PD ($p < 0.05$)

and MDD vs. GAD ($p < 0.01$) comparisons. When MDD patients were compared to HC, the significance survived the Bonferroni correction ($p < 0.05^*$) (Figure 1, a). MDD also showed GMV deficits compared to GAD and HC in right fusiform gyrus ($p < 0.01$).

3.2.2 Surface area

The SA comparison results are summarized in Table 2, second section. While left and right hemispheric SA did not differ among groups, in line with GMV results we found a significant contribution of diagnosis to SA of right fusiform gyrus ($p < 0.01$). In this region, MDD showed lower SA compared to both HC and GAD ($p < 0.05^*$) (Figure 1, b). On the contrary, GAD showed lower SA than MDD in right superior parietal cortex ($p < 0.01$). The same tendency emerged when GAD was compared to PD ($p < 0.05$). A further difference emerged in left postcentral gyrus, showing higher SA in PD compared to HC ($p < 0.01$) and the other patient groups ($p < 0.05$).

3.2.3 Cortical thickness

~~The significant differences emerged from the~~ CT-comparison results are listed in Table 2, third section. The ANOVA showed significant effects of diagnosis on CT in left orbitofrontal cortex (lateral portion) ($p < 0.01$). In this region, the three patient groups showed CT deficits when compared to HC. Such a difference was highly significant in the GAD vs. HC comparison ($p < 0.05^*$) (Figure 1, c), less significant in MDD vs. HC and PD vs. HC ones ($p < 0.05$).

3.2.4. Mean Curvature

The results of the MC group statistics are listed in Table 2, bottom section. We found significant differences among diagnostic groups in right orbitofrontal cortex (medial portion) ($p < 0.05$). In this region, the post-hoc pairwise comparisons revealed higher MC in GAD compared to HC ($p < 0.01$) and MDD ($p < 0.01$).

3.2.5 Gyrfication

The location and statistics of the clusters with significant LGI differences among groups are reported in Table 3 ($p < 0.01$). Compared to HC, only GAD patients revealed increased gyrfication in a cluster of right superior frontal gyrus ($p < 0.001$). Significant LGI differences ~~were also observed~~ emerged also among the patient groups. Specifically, PD patients showed higher LGI in a portion of left superior parietal cortex when compared to MDD ones ($p < 0.01$). Although no clusters survived to the FDR correction ($p < 0.05$), the T statistics of the GAD vs. HC difference in right superior frontal gyrus was close to the FDR threshold.

3.3 Clinical-neuroanatomical analysis

The correlation analyses showed selective associations between clinical scales and cortical morphological parameters, after exclusion of diagnostic contribution. In our sample, we found no associations between (i) regional CT/SA and all clinical scale scores, (ii) HDRS scores and all ROI parameters. Conversely, our results suggest a link between cortical folding and clinical scores. Indeed, MC in right precentral gyrus was positively associated with GAF scores ($\rho = 0.453$, $p = 0.001$, surviving to Bonferroni's correction) and negatively associated with BPRS scores ($\rho = -0.386$, $p =$

0.008), whereas MC in left entorhinal cortex was negatively associated with BPRS scores ($\rho=-0.4113$, $p=0.005$). We also detected a negative correlation between HARS scores and GMV in left fusiform gyrus ($\rho=-0.4361$, $p=0.0099$).

4. Discussion

In the present study, ~~for the first time to our knowledge~~, patients with GAD, PD and MDD were compared with HC and among themselves in terms of cortical morphology. The investigation of cortical thickness, volume, surface area and gyrification, which represents a main asset of the work, has provided specific insights in the structural abnormalities of anxiety and major depression. The integration of the diagnostic comparison with clinical-morphological correlation analyses has allowed to disentangle the contribution of common and distinct symptom dimensions.

Although the limited sample size makes this study a pilot investigation, our results suggest the presence of both common and selective gray matter alterations in the three diagnostic groups, which will be discussed in view of shared and distinct characteristics of anxiety and major depression.

4.1 Orbitofrontal abnormalities in the patient groups

We found orbitofrontal cortex (OFC) thinning in all diagnostic groups compared to HC. Since cortical thickness is thought to be sensitive to maturational changes, this neuroanatomical abnormality may result from developmental processes and underlie functional deficits shared by these disorders.

Indeed, the OFC is a key region involved in decision making (Stalnaker et al., 2015) and in the processing of reward and punishment stimuli (Volz and von Cramon, 2009), abilities often found to be impaired in patients with MDD (Leykin et al., 2011; Martin-Soelch, 2009), GAD (Beesdo et al., 2010; Teng et al., 2016) and PD (Held-Poschardt et al., 2018; Ludewig et al., 2003). This evidence is also supported by previous neuroimaging findings on both anxiety and depression. Structural abnormalities in this region emerged from several neuroimaging studies on MDD. A meta-analysis of brain volume abnormalities in MDD reported reduced volume in OFC - especially in the left hemisphere - in patients compared to HC (Arnone et al., 2012). A more recent publication carried out by the ENIGMA-MDD working group showed that adult MDD patients ($n=1902$) showed reduced cortical thickness in medial OFC, and in other portions of frontal/temporal lobes compared to HC (Schmaal et al., 2017).

~~Notably, The findings on anxiety disorders are fewer but in the same line of ours.~~ The role of OFC in anxiety neurocircuitry has been largely investigated and acknowledged, suggesting a key involvement of this region in the altered fear extinction and top-down inhibition of emotion processing characterizing anxiety (Milad and Rauch, 2007). Cortical thinning in medial OFC, but in the right hemisphere, was suggested as a neuroanatomical precondition for anxiety, being associated with trait anxiety score in healthy volunteers (Kuhn et al., 2011). In this exact region, our GAD sample showed higher curvature compared to HC and MDD. These findings are not in conflict, since curvature is usually negatively correlated with thickness. Of note, our recent study on an

independent sample of GAD patients and HC already highlighted CT deficits in left lateral OFC in GAD (Molent et al., 2017). Conversely, studies on PD described CT deficits in the pars triangularis of the inferior frontal gyrus, enhanced in the left hemisphere (Kang et al., 2017). Structural deficits in left medial OFC recently emerged as a specific trait of PD with agoraphobia (Na et al., 2013), clearing the way for further investigations.

4.2 Unique brain alterations in MDD

Our results showed a significant reduction of GMV within left precentral gyrus in MDD compared to both HC and the other two patient groups. These findings are supported by recent studies that investigated cerebral vulnerability for MDD and mood disorders, highlighting a possible role of precentral region in MDD pathogenesis. In a work focusing on thickness, which is known to contribute to volumetric estimates, decreased CT in left precentral region emerged from first episode drug naïve MDD patients, and progressive cortical thinning in the precentral gyri was suggested as an increased risk factor for mood disorders (Papmeyer et al., 2015). A recent study also hypothesized a role for this region in suicidality, showing that MDD patients with a story of suicidal acts had lower activation in left precentral gyrus compared to non-suicide attempters (Tsuji et al., 2017). Of note, our correlation analyses showed that precentral gyrification (but in the right hemisphere) is proportional to global functioning, which further supports its key role in psychopathology.

We also found that MDD patients had GMV and SA deficits compared to GAD patients and HC in right fusiform gyrus, a region engaged in recognition of facial expressions (Brunye et al., 2017; Grill-Spector and Weiner, 2014). This finding is supported by a recent meta-analysis of voxel-based morphometry studies, which showed that MDD is associated with GMV deficits in right fusiform gyrus (Arnone et al., 2016).

Therefore, overall this evidence suggests that fusiform gyrus deficits might play a key role in the pathophysiology of MDD and of affective disorders in general (Marotta et al., 2018; Hibar et al., 2017) and could explain the specific clinical manifestations of this disabling illness. Indeed, since the fusiform gyrus has been found to be involved in the early visual processing of affective stimuli, it might be plausible that deficits in this structure are linked to one of the most common cognitive features of MDD, the bias toward negatively affective stimuli (Surgulaze et al., 2005). While the right side of fusiform gyrus seems to be involved in MDD, the contralateral region might contribute to anxiety. Indeed, we found an inverse relationship between left fusiform gyrus volume and anxiety symptom severity, which supports the functional involvement of this region in the processing of social anxiety signals (Prehn-Kristensen, 2009).

4.3 Unique brain alterations in GAD

Our results suggest that hyper-gyrification in right frontal cortex represents a specific abnormality of GAD patients compared to HC. Frontal cortical folding abnormalities in GAD emerged from both vertex-based analyses, although as a tendency, and region-based analyses. Local gyrification and regional curvature are different measures of cortical folding computed at different spatial scales.

Their combination allowed to provide deeper insight in the cortical developmental defects associated with GAD. Our findings corroborate evidence from our previous MRI study on GAD and HC, showing superior frontal hyper-gyrification in GAD patients (Molent et al., 2017), and may be linked to prefrontal metabolic and functional alterations already described in GAD (Delvecchio et al., 2017; Diwadkar et al., 2017). Since cortical gyrification results from dynamic processes during brain development (Kim et al., 2016) and is related to the underlying cortical connectivity (Van Essen, 1997), our finding may reflect abnormal connections between right frontal region and the rest of the brain, providing possible insights into GAD pathogenesis.

Moreover, GAD was associated with SA deficits in right superior parietal cortex compared to MDD and PD. Since the only MRI study that compared MDD and GAD did not inspect the parietal lobe (Hilbert et al., 2017), our results cannot be discussed in the light of previous ones. Nonetheless, the involvement of the parietal cortex in GAD is in line with previous evidence from an fMRI study, which reported that during both neutral and anxiety distractors GAD patients showed significantly lower activation than HC in superior parietal gyrus (Moon and Jeong, 2015) as well as from a diffusion study, which reported a disruption of white matter microstructure organization in right parietal cortex in GAD patients compared to HC (Brambilla et al., 2012). The parietal cortex represents an important area involved in spatial orientation, sensory motor integration processes, movement control, movement observation, action prediction, planning and execution (Teixeira et al., 2014). This structure is also involved in the frontoparietal network, whose activity has been demonstrated to be less recruited in GAD patients (Pico-Perez et al., 2017), especially during processing of neutral stimuli (Holzel et al., 2013). Notably, this result further supports the hypothesis that deficits within the parietal cortex might be considered a putative biomarker of GAD, which may underpin its pathophysiology. Indeed, the superior parietal abnormalities in GAD patients compared to the other patient groups might sustain the key deficits often observed in this disorder in respect to other anxiety and mood illnesses, especially the difficulty in concentrating and sleep disturbances.

4.4 Unique brain alterations in PD

In our study, PD patients showed a trend towards hyper-gyrification in a cluster in left superior parietal cortex compared to MDD ones. Although gyrification had never been compared between the two patient groups, an involvement of this region in PD pathophysiology is plausible. Indeed, cerebral blood flow abnormalities in left parieto-temporal cortex were already described in PD (Meyer et al., 2000), moreover the electrical stimulation of this region was found to induce panic attacks (Penfield and Jasper, 1954). Panic symptoms may therefore arise from abnormal perception and sensation processing due to potential parietal alterations, possibly being related to inadequate multisensory integration, and transmission of false input to frontal areas and limbic circuits (LeDoux and Brown, 2017).

Our group of PD patients also revealed larger SA in left postcentral gyrus compared to the other groups. The postcentral gyrus encompasses the primary somatosensory cortex and represents the primary receptor of general bodily sensation (Borich et al., 2015). Interestingly, a previous fMRI study showed that PD patients had greater functional connectivity between somatosensory cortex

and thalamus that was interpreted as linked to greater interoceptive processing (Cui et al., 2016), which plays a key role in symptom generation in PD (Ehlers and Breuer, 1996). Consistently, PD exhibits exaggerated functional connectivity between postcentral gyrus and thalamus (Marchand et al., 2009), which may determine the inadequate integration of stimuli and elaboration of specific somatic feelings, ultimately providing a disturbed awareness of somatosensory information (Domschke and Dannlowski, 2010). It is worth to highlight that the postcentral abnormalities emerged also when PD was compared with MDD and GAD, therefore suggesting that areas involved in somatosensory processing are more likely to specifically characterize patients with somatic symptoms, mainly in interceptive processing, rather than a general chronic and excessive sense of anxiety and worrying, which is a central feature of GAD. Indeed, the structural alteration of the postcentral gyrus might explain the peculiar symptoms of PD, which include the abnormal perception of bodily signals, including the extreme feeling of heartbeat.

4.5 Limitations

Our findings should be considered in light of some limitations. First, the small sample size did not allow to fully balance our sample in terms of age, which however was taken into account in the analysis design. The modest sample size also limited ~~also~~ the statistical power of the study, preventing from extracting subtle structural changes among the groups and from stratifying each patient group based on clinical characteristics that may affect the results. To partially face this issue, we stratified the statistical threshold and discussed the results in view of their significance level. Although all findings need to be confirmed by replications on larger samples, the emergence of significant results from our small sample supports their reliability.

Another issue concerned the substantial comorbidity between mood and anxiety disorders. Although patients with comorbid Axis I disorders were excluded from the comparison, we cannot completely rule out related confounders, including past Axis I and current Axis II comorbidities, from our results. In the clinical-neuroanatomical correlation analyses, the partial availability of clinical scale scores has limited the possibility to explore the structural bases of common symptom dimensions. Finally, it should be remarked that most patients were on antidepressant treatment at the time of the study, which might have had an impact on our morphological parameters, as suggested by previous investigations (Arnone et al., 2013) and therefore limited the generalizability of our findings. Therefore, future larger studies on homogenous drug-naïve samples are needed for better identifying the structural correlates associated with anxiety and depressive illnesses.

4.6 Future directions

In the near future, our surface-based results should be integrated with voxel-based statistics to provide a more complete understanding of the structural correlates of anxiety and major depression.

Since our study remarks the importance of understanding the biological underpinnings of mood and anxiety disorders, future larger neuroimaging studies further investigating the etiology and pathophysiology of these disabling and highly prevalent disorders are warranted. Indeed, the use of

more homogeneous samples, especially in terms of pharmacological treatment and socio-demographic variables, might allow to identify the neurobiological models of these disorders, which may ultimately facilitate the early identification of these diseases and new targeted treatments.

4.7 Conclusive remarks

This study, ~~for the first time to our best knowledge,~~ highlighted the importance of investigating common and specific cortical morphology alterations in PD, GAD and MDD for delineating their neurobiological underpinnings.

In all diagnostic groups, we found orbitofrontal alterations that possibly reflect a similar abnormal top-down cognitive control, which in turn might explain the emotion dysregulation often observed in anxiety and major depression. We also detected unique brain alterations, with MDD showing deficits in frontotemporal structures, and GAD and PD characterized by selective alterations in parietal regions.

Overall, these results suggest that clinical phenotypic similarities between major depression and anxiety may be associated with common neurobiological alterations in the prefrontal cortex. Moreover, they support the hypothesis that GAD and PD share some neural substrates, as expected since they belong to the same nosological class, while being characterized by specific signatures that might explain their key clinical symptoms. Finally, future larger MRI investigations are needed to unveil the role of the frontotemporal and parietal cortices, which may help in refining the differential diagnosis of these illnesses.

Funding sources

Grant support of Dr. Maggioni was provided by the Fondazione Cariplo (grant n° 2016-0908). This study was partly supported by grants from the Italian Ministry of Health (RF-2011-02352308) to Prof. Brambilla and from the Fondazione Cariplo (grant n° 2014:0664) to Prof. Perna.

References

1. Abend, R., Bar-Haim, Y., 2013. Threat-related attention bias in the early stages of cognitive-behavior therapy action for panic disorder. *Biol. Psychiatry* 73, 1041-1042.
2. Arnone, D., McIntosh, A.M., Ebmeier, K.P., Munafò, M.R., Anderson, I.M., 2012. Magnetic resonance imaging studies in unipolar depression: systematic review and meta-regression analyses. *Eur. Neuropsychopharmacol.* 22, 1-16.
3. Arnone, D., McKie, S., Elliott, R., Juhász, G., Thomas, E. J., Downey, D., et al., 2013. State-dependent changes in hippocampal grey matter in depression. *Mol. Psychiatry* 18, 1265.
4. Arnone, D., Job, D., Selvaraj, S., Abe, O., Amico, F., Cheng, Y., et al., 2016. Computational meta-analysis of statistical parametric maps in major depression. *Hum. Brain Mapp.* 37, 1393-1404.
5. Beesdo, K., Pine, D.S., Lieb, R., Wittchen, H.U., 2010. Incidence and risk patterns of anxiety and depressive disorders and categorization of generalized anxiety disorder. *Arch. Gen. Psychiatry* 67, 47-57.
6. Bellani, M., Baiano, M., Brambilla, P., 2010. Brain anatomy of major depression I. Focus on hippocampus. *Epidemiol. Psychiatr. Soc.* 19, 298-301.
7. Bellani, M., Baiano, M., Brambilla, P., 2011. Brain anatomy of major depression II. Focus on amygdala. *Epidemiol. Psychiatr. Sci.* 20, 33-36.
8. Borich, M.R., Brodie, S.M., Gray, W.A., Ionta, S., Boyd, L.A., 2015. Understanding the role of the primary somatosensory cortex: Opportunities for rehabilitation. *Neuropsychologia* 79, 246-255.
9. Brambilla, P., Barale, F., Caverzasi, E., Soares, J.C., 2002. Anatomical MRI findings in mood and anxiety disorders. *Epidemiol. Psychiatr. Soc.* 11, 88-99.
10. Brambilla, P., Como, G., Isola, M., Taboga, F., Zuliani, R., Goljecscek, S., et al., 2012. White-matter abnormalities in the right posterior hemisphere in generalized anxiety disorder: a diffusion imaging study. *Psychol. Med.* 42, 427-434.
11. Brunye, T.T., Moran, J.M., Holmes, A., Mahoney, C.R., Taylor, H.A., 2017. Non-invasive brain stimulation targeting the right fusiform gyrus selectively increases working memory for faces. *Brain Cogn.* 113, 32-39.
12. Caetano, S.C., Hatch, J.P., Brambilla, P., Sassi, R.B., Nicoletti, M., Mallinger, A.G., et al., 2004. Anatomical MRI study of hippocampus and amygdala in patients with current and remitted major depression. *Psychiatry Res.* 132, 141-147.
13. Campbell-Sills, L., Barlow, D.H., Brown, T.A., Hofmann, S.G., 2006. Acceptability and suppression of negative emotion in anxiety and mood disorders. *Emotion* 6, 587-595.
14. Canu, E., Kostic, M., Agosta, F., Munjiza, A., Ferraro, P.M., Pesic, D., et al., 2015. Brain structural abnormalities in patients with major depression with or without generalized anxiety disorder comorbidity. *J. Neurol.* 262, 1255-1265.

15. Comte, M., Schon, D., Coull, J.T., Reynaud, E., Khalfa, S., Belzeaux, R., et al., 2016. Dissociating bottom-up and top-down mechanisms in the cortico-limbic system during emotion processing. *Cereb. Cortex* 26, 144-155.
16. Cui, H., Zhang, J., Liu, Y., Li, Q., Li, H., Zhang, L., et al., 2016. Differential alterations of resting-state functional connectivity in generalized anxiety disorder and panic disorder. *Hum. Brain Mapp.* 37, 1459-1473.
17. Dannlowski, U., Ohrmann, P., Konrad, C., Domschke, K., Bauer, J., Kugel, H., et al., 2009. Reduced amygdala-prefrontal coupling in major depression: association with MAOA genotype and illness severity. *Int. J. Neuropsychopharmacol.* 12, 11-22.
18. Delgado, M.R., Nearing, K.I., Ledoux, J.E., Phelps, E.A., 2008. Neural circuitry underlying the regulation of conditioned fear and its relation to extinction. *Neuron* 59, 829-838.
19. Delvecchio, G., Stanley, J.A., Altamura, A.C., Brambilla, P., 2017. Metabolic alterations in generalised anxiety disorder: a review of proton magnetic resonance spectroscopic studies. *Epidemiol. Psychiatr. Sci.* 26, 587-595.
20. Desikan, R.S., Segonne, F., Fischl, B., Quinn, B.T., Dickerson, B.C., Blacker, D., et al., 2006. An automated labeling system for subdividing the human cerebral cortex on MRI scans into gyral based regions of interest. *Neuroimage* 31, 968-980.
21. Diwadkar, V.A., Re, M., Cecchetto, F., Garzitto, M., Piccin, S., Bonivento, C., et al., 2017. Attempts at memory control induce dysfunctional brain activation profiles in Generalized Anxiety Disorder: An exploratory fMRI study. *Psychiatry Res. Neuroimaging* 266, 42-52.
22. Domschke, K., Dannlowski, U., 2010. Imaging genetics of anxiety disorders. *Neuroimage* 53, 822-831.
23. Drevets, W.C., 2000. Functional anatomical abnormalities in limbic and prefrontal cortical structures in major depression. *Prog. Brain Res.* 126, 413-431.
24. Ehlers, A., Breuer, P., 1996. How good are patients with panic disorder at perceiving their heartbeats? *Biol. Psychol.* 42, 165-182.
25. Endicott, J., Spitzer, R.L., Fleiss, J.L., Cohen, J., 1976. The global assessment scale. A procedure for measuring overall severity of psychiatric disturbance. *Arch. Gen. Psychiatry* 33, 766-771.
26. Etkin, A., Egner, T., Kalisch, R., 2011. Emotional processing in anterior cingulate and medial prefrontal cortex. *Trends Cogn. Sci.* 15, 85-93.
27. Etkin, A., Prater, K.E., Schatzberg, A.F., Menon, V., Greicius, M.D., 2009. Disrupted amygdalar subregion functional connectivity and evidence of a compensatory network in generalized anxiety disorder. *Arch. Gen. Psychiatry* 66, 1361-1372.
28. Fischl, B., 2012. FreeSurfer. *Neuroimage* 62, 774-781.
29. Grill-Spector, K., Weiner, K.S., 2014. The functional architecture of the ventral temporal cortex and its role in categorization. *Nat. Rev. Neurosci.* 15, 536-548.
30. Gulley, L.R., Nemeroff, C.B., 1993. The neurobiological basis of mixed depression-anxiety states. *J. Clin. Psychiatry* 54 Suppl, 16-19.
31. Hamilton, M., 1959. The assessment of anxiety states by rating. *Br. J. Med. Psychol.* 32, 50-55.
32. Hamilton, M., 1960. A rating scale for depression. *J. Neurol. Neurosurg. Psychiatry* 23, 56-62.

33. Held-Poschardt, D., Sterzer, P., Schlagenhaut, F., Pehrs, C., Wittmann, A., Stoy, M., et al., 2018. Reward and loss anticipation in panic disorder: An fMRI study. *Psychiatry Res. Neuroimaging* 271, 111-117.
34. Hilbert, K., Lueken, U., Muehlhan, M., Beesdo-Baum, K., 2017. Separating generalized anxiety disorder from major depression using clinical, hormonal, and structural MRI data: A multimodal machine learning study. *Brain Behav.* 7, e00633.
35. Hilbert, K., Pine, D.S., Muehlhan, M., Lueken, U., Steudte-Schmiedgen, S., Beesdo-Baum, K., 2015. Gray and white matter volume abnormalities in generalized anxiety disorder by categorical and dimensional characterization. *Psychiatry Res.* 234, 314-320.
36. Hofmann, S.G., Sawyer, A.T., Fang, A., Asnaani, A., 2012. Emotion dysregulation model of mood and anxiety disorders. *Depress. Anxiety* 29, 409-416.
37. Holzel, B.K., Hoge, E.A., Greve, D.N., Gard, T., Creswell, J.D., Brown, K.W., et al., 2013. Neural mechanisms of symptom improvements in generalized anxiety disorder following mindfulness training. *Neuroimage Clin.* 2, 448-458.
38. Hranov, L.G., 2007. Comorbid anxiety and depression: illumination of a controversy. *Int. J. Psychiatry Clin. Pract.* 11, 171-189.
39. Johnson, M.R., Lydiard, R.B., 1998. Comorbidity of major depression and panic disorder. *J. Clin. Psychol.* 54, 201-210.
40. Kang, E.K., Lee, K.S., Lee, S.H., 2017. Reduced cortical thickness in the temporal pole, insula, and pars triangularis in patients with panic disorder. *Yonsei Med. J.* 58, 1018-1024.
41. Kim, J.E., Dager, S.R., Lyoo, I.K., 2012. The role of the amygdala in the pathophysiology of panic disorder: evidence from neuroimaging studies. *Biol. Mood Anxiety Disord.* 2, 20.
42. Kim, M.J., Loucks, R.A., Palmer, A.L., Brown, A.C., Solomon, K.M., Marchante, A.N., et al., 2011. The structural and functional connectivity of the amygdala: from normal emotion to pathological anxiety. *Behav. Brain Res.* 223, 403-410.
43. Kim, S.H., Lyu, I., Fonov, V.S., Vachet, C., Hazlett, H.C., Smith, R.G., et al., 2016. Development of cortical shape in the human brain from 6 to 24 months of age via a novel measure of shape complexity. *Neuroimage* 135, 163-176.
44. King-Kallimanis, B., Gum, A.M., Kohn, R., 2009. Comorbidity of depressive and anxiety disorders for older Americans in the national comorbidity survey-replication. *Am. J. Geriatr. Psychiatry* 17, 782-792.
45. Koolschijn, P.C., van Haren, N.E., Lensvelt-Mulders, G.J., Hulshoff Pol, H.E., Kahn, R.S., 2009. Brain volume abnormalities in major depressive disorder: a meta-analysis of magnetic resonance imaging studies. *Hum. Brain Mapp.* 30, 3719-3735.
46. Kuhn, S., Schubert, F., Gallinat, J., 2011. Structural correlates of trait anxiety: reduced thickness in medial orbitofrontal cortex accompanied by volume increase in nucleus accumbens. *J. Affect. Disord.* 134, 315-319.
47. LeDoux, J.E., Brown, R., 2017. A higher-order theory of emotional consciousness. *Proc. Natl. Acad. Sci. U S A* 114, E2016-E2025.
48. Leykin, Y., Roberts, C.S., Derubeis, R.J., 2011. Decision-making and depressive symptomatology. *Cognit. Ther. Res.* 35, 333-341.

49. Ludewig, S., Paulus, M.P., Ludewig, K., Vollenweider, F.X., 2003. Decision-making strategies by panic disorder subjects are more sensitive to errors. *J. Affect. Disord.* 76, 183-189.
50. Mackinnon, A.J., Henderson, A.S., Andrews, G., 1990. Genetic and environmental determinants of the lability of trait neuroticism and the symptoms of anxiety and depression. *Psychol. Med.* 20, 581-590.
51. Makovac, E., Meeten, F., Watson, D.R., Herman, A., Garfinkel, S.N., H, D.C., Ottaviani, C., 2016. Alterations in amygdala-prefrontal functional connectivity account for excessive worry and autonomic dysregulation in generalized anxiety disorder. *Biol. Psychiatry* 80, 786-795.
52. Marchand, W.R., Lee, J.N., Healy, L., Thatcher, J.W., Rashkin, E., Starr, J., et al., 2009. An fMRI motor activation paradigm demonstrates abnormalities of putamen activation in females with panic disorder. *J. Affect. Disord.* 116, 121-125.
53. Martin-Soelch, C., 2009. Is depression associated with dysfunction of the central reward system? *Biochem. Soc. Trans.* 37, 313-317.
54. Mason, E.C., Harvey, A.G., 2014. Insomnia before and after treatment for anxiety and depression. *J. Affect. Disord.* 168, 415-421.
55. Massana, G., Serra-Grabulosa, J.M., Salgado-Pineda, P., Gasto, C., Junque, C., Massana, J., et al., 2003. Amygdalar atrophy in panic disorder patients detected by volumetric magnetic resonance imaging. *Neuroimage* 19, 80-90.
56. Meyer, J.H., Swinson, R., Kennedy, S.H., Houle, S., Brown, G.M., 2000. Increased left posterior parietal-temporal cortex activation after D-fenfluramine in women with panic disorder. *Psychiatry Res.* 98, 133-143.
57. Milad, M.R., Rauch, S.L., 2007. The role of the orbitofrontal cortex in anxiety disorders. *Ann. N-Y Acad. Sci.* 1121, 546-561.
58. Moffitt, T.E., Harrington, H., Caspi, A., Kim-Cohen, J., Goldberg, D., Gregory, A.M et al., 2007. Depression and generalized anxiety disorder: cumulative and sequential comorbidity in a birth cohort followed prospectively to age 32 years. *Arch. Gen. Psychiatry* 64, 651-660.
59. Molent, C., Maggioni, E., Cecchetto, F., Garzitto, M., Piccin, S., Bonivento, C., et al., 2017. Reduced cortical thickness and increased gyrification in generalized anxiety disorder: a 3 T MRI study. *Psychol. Med.*, 1-10.
60. Moon, C.M., Jeong, G.W., 2015. Functional neuroanatomy on the working memory under emotional distraction in patients with generalized anxiety disorder. *Psychiatry Clin. Neurosci.* 69, 609-619.
61. Na, K.S., Ham, B.J., Lee, M.S., Kim, L., Kim, Y.K., Lee, H.J., et al., 2013. Decreased gray matter volume of the medial orbitofrontal cortex in panic disorder with agoraphobia: a preliminary study. *Prog. Neuropsychopharmacol. Biol. Psychiatry* 45, 195-200.
62. Oathes, D.J., Patenaude, B., Schatzberg, A.F., Etkin, A., 2015. Neurobiological signatures of anxiety and depression in resting-state functional magnetic resonance imaging. *Biol. Psychiatry* 77, 385-393.
63. Oldfield, R.C., 1971. The assessment and analysis of handedness: the Edinburgh inventory. *Neuropsychologia* 9, 97-113.
64. Pappmeyer, M., Giles, S., Sussmann, J.E., Kielty, S., Stewart, T., Lawrie, S.M., et al., 2015. Cortical Thickness in Individuals at High Familial Risk of Mood Disorders as They Develop Major Depressive Disorder. *Biol. Psychiatry* 78, 58-66.

65. Pego, J.M., Sousa, J.C., Almeida, O.F., Sousa, N., 2010. Stress and the neuroendocrinology of anxiety disorders. *Curr. Top. Behav. Neurosci.* 2, 97-117.
66. Penfield, W., Jasper, H., 1954. Epilepsy and the functional anatomy of the human brain.
67. Pico-Perez, M., Radua, J., Steward, T., Menchon, J.M., Soriano-Mas, C., 2017. Emotion regulation in mood and anxiety disorders: A meta-analysis of fMRI cognitive reappraisal studies. *Prog. Neuropsychopharmacol. Biol. Psychiatry* 79, 96-104.
68. Prehn-Kristensen, A., Wiesner, C., Bergmann, T. O., Wolff, S., Jansen, O., Mehdorn, H. M., et al., 2009. Induction of empathy by the smell of anxiety. *PloS one* 4, e5987.
69. Protopopescu, X., Pan, H., Tuescher, O., Cloitre, M., Goldstein, M., Engelien, A., et al., 2006. Increased brainstem volume in panic disorder: a voxel-based morphometric study. *Neuroreport* 17, 361-363.
70. Ressler, K. J., 2010. Amygdala activity, fear, and anxiety: modulation by stress. *Biol. psychiatry*, 67, 1117-1119.
71. Roy-Byrne, P.P., Stang, P., Wittchen, H.U., Ustun, B., Walters, E.E., Kessler, R.C., 2000. Lifetime panic-depression comorbidity in the National Comorbidity Survey. Association with symptoms, impairment, course and help-seeking. *Br. J. Psychiatry* 176, 229-235.
72. Saris, I.M.J., Aghajani, M., van der Werff, S.J.A., van der Wee, N.J.A., Penninx, B., 2017. Social functioning in patients with depressive and anxiety disorders. *Acta Psychiatr. Scand.* 136, 352-361.
73. Schmaal, L., Hibar, D.P., Samann, P.G., Hall, G.B., Baune, B.T., Jahanshad, N., et al., 2017. Cortical abnormalities in adults and adolescents with major depression based on brain scans from 20 cohorts worldwide in the ENIGMA Major Depressive Disorder Working Group. *Mol. Psychiatry* 22, 900-909.
74. Schuhmacher, A., Mossner, R., Jessen, F., Scheef, L., Block, W., Belloche, A.C., et al., 2012. Association of amygdala volumes with cortisol secretion in unipolar depressed patients. *Psychiatry Res.* 202, 96-103.
75. Shang, J., Fu, Y., Ren, Z., Zhang, T., Du, M., Gong, Q., et al., 2014. The common traits of the ACC and PFC in anxiety disorders in the DSM-5: meta-analysis of voxel-based morphometry studies. *PLoS One* 9, e93432.
76. Sheline, Y.I., Gado, M.H., Kraemer, H.C., 2003. Untreated depression and hippocampal volume loss. *Am. J. Psychiatry* 160, 1516-1518.
77. Spitzer, R.L., Williams, J.B., Gibbon, M., First, M.B., 1992. The Structured Clinical Interview for DSM-III-R (SCID). I: History, rationale, and description. *Arch. Gen. Psychiatry* 49, 624-629.
78. Stalnaker, T.A., Cooch, N.K., Schoenbaum, G., 2015. What the orbitofrontal cortex does not do. *Nat. Neurosci.* 18, 620-627.
79. Surguladze, S., Brammer, M.J., Keedwell, P., Giampietro, V., Young, A.W., Travis, M.J., et al., 2005. A differential pattern of neural response toward sad versus happy facial expressions in major depressive disorder. *Biol. Psychiatry* 57, 201-209.
80. Sylvester, C.M., Hudziak, J.J., Gaffrey, M.S., Barch, D.M., Luby, J.L., 2016. Stimulus-Driven Attention, Threat Bias, and Sad Bias in Youth with a History of an Anxiety Disorder or Depression. *J. Abnorm. Child. Psychol.* 44, 219-231.
81. Teixeira, S., Machado, S., Velasques, B., Sanfim, A., Minc, D., Peressutti, C., et al., 2014. Integrative parietal cortex processes: neurological and psychiatric aspects. *J. NeuroL. Sci.* 338, 12-22.

82. Teng, C., Otero, M., Geraci, M., Blair, R.J., Pine, D.S., Grillon, C., et al., 2016. Abnormal decision-making in generalized anxiety disorder: Aversion of risk or stimulus-reinforcement impairment? *Psychiatry Res.* 237, 351-356.
83. Terlevic, R., Isola, M., Ragogna, M., Meduri, M., Canalaz, F., Perini, L et al., 2013. Decreased hypothalamus volumes in generalized anxiety disorder but not in panic disorder. *J. Affect. Disord.* 146, 390-394.
84. Tsujii, N., Mikawa, W., Tsujimoto, E., Adachi, T., Niwa, A., Ono, H., et al., 2017. Reduced left precentral regional responses in patients with major depressive disorder and history of suicide attempts. *PLoS One* 12, e0175249.
85. Van Essen, D.C., 1997. A tension-based theory of morphogenesis and compact wiring in the central nervous system. *Nature* 385, 313-318.
86. van Tol, M.J., van der Wee, N.J., van den Heuvel, O.A., Nielen, M.M., Demenescu, L.R., Aleman, A., et al., 2010. Regional brain volume in depression and anxiety disorders. *Arch. Gen. Psychiatry* 67, 1002-1011.
87. Ventura, J., Nuechterlein, K.H., Subotnik, K.L., Gutkind, D., Gilbert, E.A., 2000. Symptom dimensions in recent-onset schizophrenia and mania: a principal components analysis of the 24-item Brief Psychiatric Rating Scale. *Psychiatry Res.* 97, 129-135.
88. Vidal-Ribas, P., Brotman, M.A., Valdivieso, I., Leibenluft, E., Stringaris, A., 2016. The Status of Irritability in Psychiatry: A Conceptual and Quantitative Review. *J. Am. Acad. Child Adolesc. Psychiatry* 55, 556-570.
89. Volz, K.G., von Cramon, D.Y., 2009. How the orbitofrontal cortex contributes to decision making - a view from neuroscience. *Prog. Brain Res.* 174, 61-71.
90. Whittle, S., Lichter, R., Dennison, M., Vijayakumar, N., Schwartz, O., Byrne, M.L., et al., 2014. Structural brain development and depression onset during adolescence: a prospective longitudinal study. *Am. J. Psychiatry* 171, 564-571.
91. Zhao, Y., Chen, L., Zhang, W., Xiao, Y., Shah, C., Zhu, H., et al., 2017. Gray matter abnormalities in non-comorbid medication-naïve patients with major depressive disorder or social anxiety disorder. *EBioMedicine* 21, 228-235.

Tables

Table 1. Characteristics of the sample.

Characteristic ^a	GAD (n=11)	PD (n=11)	MDD (n=13)	HC (n=21)	ANOVA	Pairwise comparison
Gender (M/F)	4/7	5/6	4/9	7/14	n.s.	n.s.
Age	42.43 ± 11.53	33.55 ± 9.53	46.68 ± 12.49	36.03 ± 13.46	F=2.99, p=0.039 (d1=3, d2=52)	n.s.
Language (Italian/other)	10/1	11/0	12/0	20/1	n.s.	n.s.
Handedness (EHI)	15.64 ± 11.40	18.44 ± 3.75	19.64 ± 0.81	17.68 ± 8.67	n.s.	n.s.
GAF	67.91 ± 10.04	66.45 ± 10.32	63.18 ± 8.92	90.75 ± 3.63	F =38.3, p=0.066 × 10 ⁻¹¹ (d1=3, d2=49)	GAD<HC, MDD<HC, PD<HC (p<0.001)
BPRS	50.82 ± 13.05	40.18 ± 13.84	38 ± 11.06	26.83 ± 2.81	F =11.95, p<0.061 × 10 ⁻⁴ (d1=3, d2=47)	GAD>HC (p<0.001), MDD>HC (p<0.05), PD>HC (p<0.05)
HARS	17.91 ± 10.08	15.20 ± 6.24	n.a.	3.84 ± 2.89	F =18.52, p=0.027 × 10 ⁻⁴ (d1=2, d2=37)	GAD>HC (p <0.001), PD>HC (p<0.001)
HDRS	n.a.	n.a.	14.3 ± 5.17	4.30 ± 3.06	F =43.58, p<0.037 × 10 ⁻⁵ (d1=1, d2=28).	MDD>HC (p<0.001)

^a For continuous variables, mean ± standard deviation is given. M=maleMale; F=femaleFemale; GAD=General Anxiety Disorder; PD=: Ppanic Ddisorder; MDD=: major Major depressive Depressive Ddisorder; HC=Healthy Controls; ANOVA=: analysis-Analysis of Of varianceVariance; EHI=Edinburgh handedness-Handedness inventoryInventory; BPRS=Brief Psychiatric Rating Scale; GAF=Global assessment-Assessment of functioningFunctioning; HDRS=Hamilton Depression Rating Scale; HARS=Hamilton Anxiety Rating Scale; n.s.=not significant; n.a.=not available. d1=F-test numerator degree of freedom. d2=F-test denominator degree of freedom.

Table 2. Regional morphological comparison results.

Brain region	Hemisphere	Measure	ANOVA	Pairwise comparisons
Precentral gyrus	Left	Volume	$F=4.49, p=0.008$ (d1=6, d2=49)	MDD<HC: $T=3.47, p<0.05^*$ MDD<GAD: $T=2.84, p<0.01$ MDD<PD: $T=2.08, p<0.05$
Fusiform gyrus	Right	Volume	$F=4.37, p=0.009$ (d1=6, d2=49)	MDD<HC: $T=2.96, p<0.01$ MDD<GAD: $T=3.16, p<0.01$
Postcentral gyrus	Left	Area	$F=3.27, p=0.029$ (d1=6, d2=49)	PD>HC: $T=2.98, p<0.01$ PD>MDD: $T=2.55, p<0.05$ PD>GAD: $T=2.08, p<0.05$
Fusiform gyrus	Right	Area	$F=5.18, p=0.004$ (d1=6, d2=49)	MDD<HC: $T=3.29, p<0.05^*$ MDD<GAD: $T=3.27, p<0.05^*$
Superior parietal cortex	Right	Area	$F=3.19, p=0.031$ (d1=6, d2=49)	GAD<PD: $T=2.25, p<0.05$ GAD<MDD: $T=2.9, p<0.01$
Orbitofrontal cortex, lateral portion	Left	Thickness	$F=4.30, p=0.009$ (d1=5, d2=50)	MDD<HC: $T=2.53, p<0.05$ PD<HC: $T=2.28, p<0.05$ GAD<HC: $T=3.15, p<0.05^*$
Orbitofrontal cortex, medial portion	Right	Curvature	$F=3.86, p=0.015$ (d1=5, d2=50)	GAD>HC: $T=2.69, p<0.01$ GAD>MDD: $T=3.15, p<0.01$

GAD=General Anxiety Disorder; HC=Healthy Controls; PD=~~P~~panic disorderDisorder; MDD=~~major~~Major depressive Depressive disorderDisorder; ANOVA= ~~analysis~~Analysis of Of varianceVariance. T = T statistics; F = F statistics. d1= F -test numerator degrees of freedom. d2= F -test denominator degrees of freedom. ICV= ~~total~~Total intracranial Intracranial volumeVolume.

* Significant after Bonferroni correction ($n=21$).

General Linear Model designs:
ROI volume ~ 1 + Diagnosis + Gender + Age + ICV
ROI thickness ~ 1 + Diagnosis + Gender + Age
ROI area ~ 1 + Diagnosis + Gender + Age + hemispheric area
ROI mean curvature ~ 1 + Diagnosis + Gender + Age.

Table 3. Local gyrification index comparison results.

Result	Brain region	Hemisphere	Cluster size (mm ²)	T -statistics, p -value
GAD > HC	Superior frontal	Right	452.48	$T=3.60, p=0.07 \times 10^{-2}$ (df=24)
PD > MDD	Superior parietal	Left	311.48	$T=3.17, p=0.002$ (df=16)

GAD=General Anxiety Disorder; HC=Healthy Controls; PD=~~P~~panic disorderDisorder; MDD=~~major~~Major depressive Depressive disorderDisorder.

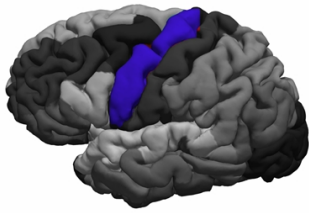
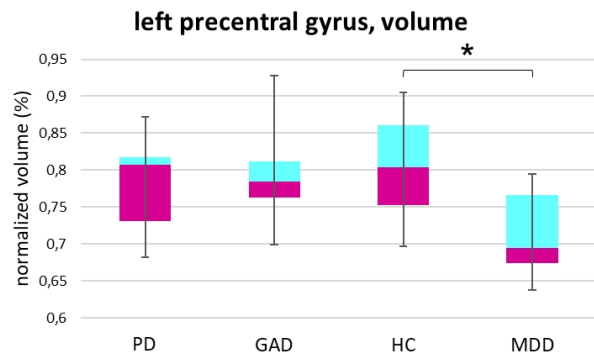
General Linear Model designs:
LGI ~ 1 + Diagnosis + Gender + Age

Figure legends

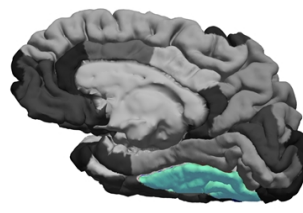
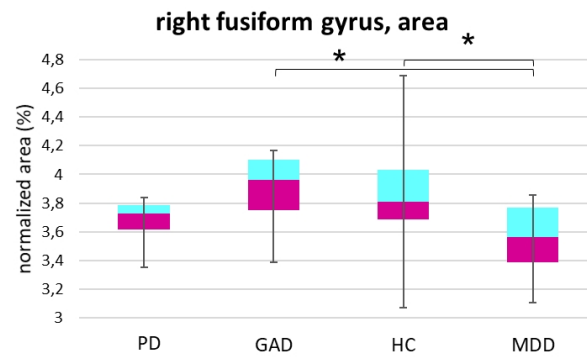
Figure 1. Results of regional morphology comparison. Regions with significant differences in regional morphological parameters (cortical volume, surface area and thickness) among the

four groups of subjects (major depressive disorder (MDD), generalized anxiety disorder (GAD), panic disorder (PD) and healthy controls (HC)) (ANOVAs: $p < 0.05$, post-hoc pairwise comparisons: $p < 0.05^*$, Bonferroni corrected ($n=21$)). The diagrams show the minimum, maximum, median, and 25th and 75th percentiles of the considered morphological parameter in the four groups. The asterisks mark pairwise significant differences surviving Bonferroni correction.

a)



b)



c)

