

## Piezosurgery vs High Speed Rotary Handpiece: a comparison between the two techniques in the impacted third molar surgery

[F.N. BARTULI](#),<sup>1</sup> [F. LUCIANI](#),<sup>1</sup> [E. CADDEO](#),<sup>2</sup> [L. DE CHIARA](#),<sup>3</sup> [M. DI DIO](#),<sup>4</sup> [P. PIVA](#),<sup>1</sup> [L. OTTRIA](#),<sup>5</sup> and [C. ARCURI](#)<sup>6</sup>

<sup>1</sup> PhD Program in “Material for Health, Environment and Energy”, University of Rome “Tor Vergata”

<sup>2</sup> Department of Periodontics “S. Giovanni Calibita - Fatebenefratelli” Hospital

<sup>3</sup> Department Neurosciences, Mental Health, and Sensory Organs, Sapienza University, Rome, School of Medicine and Psychology, Sant’Andrea Hospital, Rome, Italy

<sup>4</sup> U.O.C.C. Odontostomatology, San Giovanni Calibita Hospital, Rome, Italy

<sup>5</sup> Foundation, University of Rome “Tor Vergata”, Department of Clinical Science and Translational Medicine, U.O.C. of Odontostomatologic Clinic

<sup>6</sup> University of Rome “Tor Vergata”, U.O.C.C. Odontostomatology “S. Giovanni Calibita-Fatebenefratelli” Hospital

Correspondence to: Fabio Luciani, Tel. +39 3332244163, E-mail: [fabioluciani@fastwebnet.it](mailto:fabioluciani@fastwebnet.it)

Copyright ©2013 CIC Edizioni Internazionali, Rome, Italy

This article has been [cited by](#) other articles in PMC.

### SUMMARY

Go to:  Go to:

#### Objective

The aim of the Study was to compare the impacted third molar surgical technique by means of the high speed rotary handpiece with the piezoelectric one.

#### Materials and Methods

192 patients have been selected among those who had to undergo a third molar surgical extraction. These patients’ surgeries have been performed by means of one of the techniques, randomly chosen.

Each patient has undergone the same analgesic therapy (paracetamol 1000 mg tablets). Each surgery has been performed by the same surgeon. The patients were asked to fill in a questionnaire concerning the postoperative pain (“happy face pain” rating scale).

#### Results

The average duration of the surgeries performed by means of the high speed rotary handpiece was 32 minutes, while the duration of the ones performed by means of the piezoelectric handpiece was much longer (54 minutes). The postoperative pain values were almost equal.

#### Conclusions

In conclusion, the osteotomy performed by means of the traditional technique still represents the gold standard in the impacted third molar surgery. The piezoelectric technique may be an effective choice, especially for the less skilled surgeons, in order to guarantee the protection of the delicate locoregional anatomical structures.

**Keywords:** third molar, piezosurgery, high speed handpiece

### Introduction

Go to:  Go to:

Third molar surgical removing is one of the most frequent and delicate therapies among the surgical operations dentists must perform (<sup>1</sup>).

High speed rotary handpiece and piezosurgery are both tools the oral Surgeon usually employs for osteotomy and odontotomy during surgical third molar extraction (2). The aim of this study is to compare these two techniques in order to evaluate indications and contraindications, incidents and complications about the former and the latter. Even surgery duration and the patient's discomfort were analyzed and compared in both strategies (3).

## Material and methods

Go to:  Go to:


194 patients have been included in the study: 97 patients have undergone at least one third molar surgical extraction led by the traditional technique, High speed rotary handpiece (Fig. 1), and other 97 patients were operated employing the piezosurgery technique (Fig. 2). Some basic terms were defined to select the patients who would take part in the study:

1. Age between 25 and 35;
2. Diagnosis of at least one third molar, totally or partially bone impacted, in need of surgical extraction (at least in need of a flap incision and osteotomy);
3. A medical history devoid of any systemic pathological condition;
4. A medical history devoid of any pharmacological therapy able to introduce variables into the experiment;
5. No periodontal diseases affecting contiguous teeth.



[Figure 1](#)

Kavo supertorque lux 660.



[Figure 2](#)

Mectron 3.

In order to eliminate any variable linked to the surgeon, such as operative rapidity and pharmacological therapy prescribed, each patient has undergone the same practices.

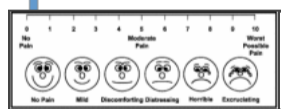
These practices provided three stages and three-and six-month recovery tests.

- First stage:
  - Case sheet writing;
  - Medical history writing;
  - Urine tests;
  - Blood tests;
  - Electrocardiogram.
- Second stage:
  - First stage tests checking;
  - Antibiotic therapy prescription (Amoxicillin + clavulanic acid: 1 g tablets every 12 hours for five days);
  - Before-surgery-antibiotic giving (Amoxicillin + clavulanic acid 1 g, one tablet);
  - Pictures of the areas which are going to be treated;
  - Pictures of the radiographies carried out (Ortopanthomography and TC Dentscan, if it was made);
  - Third molar impaction class recording, in accordance with Pell & Gregory classification;
  - Checking of the Plaque index (PI) on the second molar next to the third molar which is being operated;

- Recording of second molar probing values (pocket depth and loss of attachment);
- Patient preparation;
- Surgery starting-time recording (minutes);
- Surgery carrying out;
- Pictures of the operated tissues;
- Surgery closing time recording (minutes);
- Analgesic therapy administration: paracetamol 1000 mg oral tablets;
- Prescription of mouthwashes (50% hydrogen peroxide and 50% water) twice a day, starting from the day after surgery until the tenth day; patients were moreover advised not to wash and brush their teeth during the whole day of surgery.
- Discharging.

Moreover patients were asked to fill in a form with each postoperative complication (such as swelling, haematomas, edemas, trismus, bleeding, etc.) and to fill in a pain-scale-form reporting the pain referred to fifth and tenth day after surgery ([Fig. 3](#)).

- Third stage (day 10):
  - Healing checking;
  - Plaque index recording;
  - Sutures removal;
  - Pictures of the treated areas;
  - Check of the filled form and scale.
- Fourth stage (day 20):
  - Healing and adverse reactions monitoring;
- Fifth stage (day 90):
  - Healing checking;
  - Plaque Index (PI) on second molars checking;
  - Annotation of second molar probing values (pocket depth and loss of attachment);
  - Pictures of the treated areas;
  - Endoral x-rays of the postoperative site.



[Figure 3](#)

Happy face pain scale.


Third molar surgery, always managed by the same surgeon, consisted in: troncular nerve block and local infiltration anesthesia with 3% mepivacaina without any vasoconstrictor, mucoperiosteal flap design and incision with n°15 Bard-Parker cold scalpel blade, its elevation, osteotomy and odontotomy (if needed), then impacted tooth dislocation and removal. The flap was finally sutured. The suture material used was Vicryl 4-0 USP with a SH-2 needle (SH-1plus for Ethibond Excel one), ½ circle with taper point. SUPER torque LUX 660B high speed handpiece was used.

The burs employed were the tungsten carbide ones manufactured by Sweden & Martina. The bur models were ([Fig. 4](#)):

- Long shank round bur: code 141rs/027caxL;
- Short shank cylinder crosscut bur: code c31rL/016fg;
- Long shank cylinder crosscut bur: code c31rL/016fgxL;

[Figure 4](#)

Employed burs.



The piezoelectric handpiece employed was the Mectron 3. The tips employed were ([Fig. 5](#)):

- Tip OT2; Ref. n°: 03370002;
- Tip OT5; Ref. n°: 03370005;
- Tip OT7; Ref. n°: 03370007;
- Tip EX1; Ref. n°: 03400001;
- Tip EX2; Ref. n°: 03400002;
- Tip EX3; Ref. n°: 03400003.

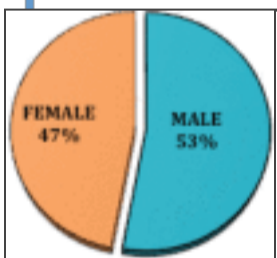


[Figure 5](#)  
Piezo Tips.

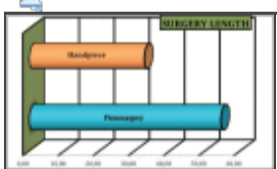
## Results

Go to:  Go to:

Only 192 out of 194 patients have been followed until the last check (day 90). As far as the remaining two patients are concerned, one did not come back for the suture removal, while the other refused to come back for the last check. Therefore the two patients were excluded from the Study. 90 patients (47%) were female, while 102 (53%) were male ([Fig. 6](#)). The patients' average age was 31.4 for women and 31.2 for men. Piezosurgery was employed in 96 cases; rotary handpiece was employed in the other 96 cases. The main length of the operations was 54.50 minutes in those extractions performed by means of piezosurgery, 32.73 minutes in those performed by rotatory handpiece ([Fig. 7](#)). These data comprise 10 minutes of preconditioning time (in which the lapse of time is included from the patient sitting on the dentist's chair to the reaching of an effective anaesthetic depth) and 10 minutes for the suture fixation. As far as the 192 operations are concerned, osteotomy has always been performed, while odontotomy has been performed in 170 cases (88,5%).

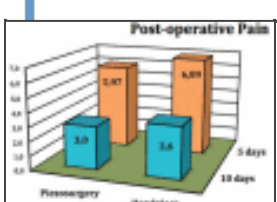


[Figure 6](#)  
Percentage of male and female treated patients.



[Figure 7](#)  
Surgery duration (minutes) by means of the two techniques.

The postoperative pain, evaluated through a questionnaire with the “happy face pain” table filled up by each patient, showed a mean of 5.43 on the fifth day and a mean of 3.3 on the tenth day after surgery. The values obtained by the pain scale are shown in the [Figure 8](#). It appears clear that the postoperative pain is almost equal either in those extractions performed by means of highspeed rotary handpiece or in those by means of piezosurgery. A slight exudate and a slightly hyperaemic mucosa have been shown in three surgical sites after 10 days. During the suture removal, the mucosa were hyperaemic and hypertrophic only in two cases.

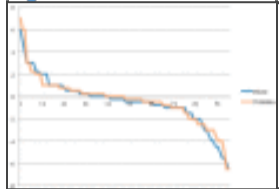


[Figure 8](#)  
Post-Operative Pain.



A hypertrophy after 20 days has been found out in three surgical sites. After 90 days the recovery was complete. A slight gingival recession (1mm) has been shown in one case. Only one patient had to repeat the antibiotic therapy after 30 days from the surgery. Each alveolus after 90 days showed a total recovery except a hypertrophy, found out in the last check, which was afterwards treated by means of a gingivectomy. Recovery quality after 90 days.

The difference between the values obtained by the preoperative probing (by means of a CP 15 periodontal probe) on the second molar next to the extracted third molar and those obtained by the postoperative one was analysed. The [Figure 9](#) shows the recovery curves: positive values mean a loss of attachment, while the negative ones a gain of attachment. It appears that the surgical site recovery quality is independent from the employed technique. From the radiographic point of view, no recovery anomalies or delays have been noticed.



[Figure 9](#)

Surgical site recovery after the surgery performed by rotary and piezoelectric handpieces.

## Discussion

[Go to:](#)  [Go to:](#)

Clinical data obtained from the 192 treated patients can recommend the employment either of burs placed in high velocity rotary handpieces or of piezoelectric tools.

In our experiment no intraoperative incidents have occurred (except one fracture of a “long shank cylinder crosscut” bur, which had been taken up from the alveolus by means of little forceps) and each patient has cooperated during the surgery and the checks. Bacterial plaque localization (recorded by means of the Plaque Index - PI) has not been found out to be linked to the site, and it has not influenced the recovery processes.

As regards the Plaque Indexes, as a matter of fact, no statistically significant differences have been shown during the different study checks (preoperatorial, first, tenth, twentieth and ninetieth day).

The periodontal recovery has been shown by the probing values, which were mainly better than the starting ones (4). The real loss of attachment was very slight: 0.18 mm of recovery in the buccal probing site; a loss of 0.49 mm on the disto-buccal one; a gain of 0.6 mm in the disto-oral site. These results were independent of the employed technique. All the adverse reactions have occurred within four weeks from the surgery. The values concerning the postoperative pain, calculated in accordance with the “happy face pain” table by means of a questionnaire filled up by each patient, were mainly about 6.43 (distressing), so it can be regarded as adequate to this kind of surgery (an impacted third molar extraction).

## Conclusions

[Go to:](#)  [Go to:](#)

Both the extraction techniques employed in the Study are effective. The employment of piezoelectric tools (piezosurgery) can certainly be chosen when the surgeon is less skilled: the damage of important and delicate anatomical structures, such as vases, nerves, the mucosa of the maxillary sinus, etc., can be more likely to happen in less skilled hands (5). Piezosurgery can also be recommended when the third molar has particularly dangerous or unusual positions (for instance very deep in the mandible or next to those anatomical structures which are not to be damaged). However, we must underline that piezoelectric tools are still much slower than handpieces; by employing piezosurgery we extend the duration of the surgery a lot, especially during the hard tissues cutting (6). Our school, more than ten-year-old experienced, has always employed burs placed on high-speed rotatory handpieces in both osteotomy and odontotomy (we always prefer several odontotomies to osteotomy), with no real incident or complication ever. The employment of rotary handpieces allows the lowering of the surgery duration, the consequent improvement of the patient’s compliance and a better and quicker tissues recovery due to a shorter surgical trauma.

## Acknowledgments

[Go to:](#)  [Go to:](#)

## References

Go to:  Go to:

1. Labanca M, Azzola F. Piezoelectric surgery: Twenty years of use. *Br J Oral Maxillofac Surg.* 2008;46:265. [[PubMed](#)]
2. Leiser Y. Surgical approach to impacted mandibular third molars. Operative classification. *J Oral Maxillofac Surg.* 2010;68:628. [[PubMed](#)]
3. Blakenburg JJ, Both CJ, Borstlap WA. Sound levels of the piezosurgery. Risk of permanent damage to hearing. *Ned Tijdschr.* 2007;114(11):451–454. [[PubMed](#)]
4. Iтро A, Lupo G, Marra A, Carotenuto A, Coccozza E, Filipi M, D'Amato S. The piezoelectric osteotomy technique compared to the one with rotary instruments in the surgery of included third molars. A clinical study *Minerva Stomatol.* 2012;61(6):247–253. [[PubMed](#)]
5. Iтро A, Lupo G, Carotenuto A, Filipi M, Coccozza E, Marra A. Benefits of piezoelectric surgery in oral and maxillofacial surgery. Review of literature. *Minerva Stomatol.* 2012;61(5):213–224. [[PubMed](#)]
6. Dym H, Weiss A. Exodontia: tips and techniques for better outcomes. *Dent Clin North Am.* 2012;56(1):245–266. [[PubMed](#)]

---

Articles from Oral & Implantology are provided here courtesy of **CIC Edizioni Internazionali**