

INVISALIGN TREATMENT IN PERIODONTAL PATIENT: CASE REPORT

A. BARLATTANI JR., G. MAMPIERI, L. OTTRIA, P. BOLLERO

University of Rome "Tor Vergata", Department of Odontostomatological Science
Foundation PTV Policlinico Tor Vergata

SUMMARY

Invisalign treatment in periodontal patient: case report

Scope of work. To evaluate the results obtained from the use of removable orthodontic aligners in patients with periodontal and systemic issues to improve the aesthetics of the smile.

Materials and methods. Invisalign technique, a new technique based on the use of orthodontic removable transparent overlay representing the mechanotherapy. This technique through a dedicated software (Clin-Check) enables you to view the 3D resolution of the malocclusion.

Results. In the case study examined the results support the Invisalign treatment in periodontal patients with a systemic disease, both for an easier home oral hygiene and also to maintain alignment and an aesthetic smile achieved without the use of invasive techniques.

Conclusion. The Invisalign orthodontic treatment is ideal for patients with periodontal problems. The removal of the masks ensures control of normal oral hygiene but also requires the cooperation of the patient during the treatment.

Key words: periodontal patient, Werlhof disease, Invisalign, cosmetic smile.

RIASSUNTO

Trattamento invisalign in paziente parodontale: case report

Scopo del lavoro. Valutare i risultati ottenibili in seguito all'utilizzo di mascherine ortodontiche rimovibili in pazienti con problematiche sistemiche e parodontali per migliorare l'estetica del sorriso.

Materiali e metodi. Impiego della metodica Invisalign, una nuova tecnica ortodontica basata sull'utilizzo di mascherine trasparenti rimovibili che rappresentano la meccanoterapia. Questa si avvale di un software dedicato (Clin-Check) tramite cui è possibile visualizzare in 3D la risoluzione della malocclusione.

Risultati. Nel caso clinico esaminato i risultati ottenuti depongono sicuramente a favore del trattamento invisalign nei pazienti parodontali con affezioni a carattere sistemico, sia per le facilitate manovre di mantenimento domiciliare dell'igiene orale, sia per l'allineamento e l'estetica del sorriso raggiunti senza l'ausilio di tecniche invasive.

Conclusioni. È possibile affermare che l'Invisalign è un trattamento ortodontico ideale per pazienti con problematiche parodontali. La possibilità di rimuovere le mascherine garantisce il controllo di una corretta igiene orale, ma richiede la collaborazione del paziente nelle fasi dell'intero trattamento.

Parole chiave: paziente parodontale, morbo di Werlhof, invisalign, estetica del sorriso.

Introduction

An aesthetic smile is an important aspect of rehabilitation, which involves a psychical function which is often underestimated.

Indeed, nowadays a beautiful smile affects the perception that people have of themselves, therefore, important for interpersonal relations. In this context, orthodontic therapy plays a remarkably important role with substantial improvements, not only regarding

oral health, but also to the quality of life in general. In 1997, the U.S. company Align Tech. introduced on the market a new therapeutic method Invisalign (1, 5), able to realign the elements through a series of removable and invisible dental appliances in transparent polymer (2, 3).

In the past the use of heat impression masks were limited only to the phase of restraint at the end of orthodontic treatment. In 1945 removable disposals were used to treat malocclusions.

The use of removable aligners during active orthodontic treatment started in the last decade (4, 6).

Invisalign is based on a sophisticated three-dimensional graphic technology, capable of designing and creating a series of personalised transparent masks, that would allow the gradual movement of teeth (5). The collaboration of the patient is very important for the therapeutic success, he must constantly wear the alignators in order to obtain the desired movements (18 hours). The real innovation of the method is represented by Invisalign Clin Check (5, 9).

This highly realistic three-dimensional digital simulation, allows both clinicians and patients to see the therapeutic process from beginning to the end.

In analysing each aspect of this treatment the cooperation and motivation of the patient is required (7).

Furthermore, the ability of removing the aligners helps the oral hygiene. Invisalign is a therapeutic method, that doesn't change the patients lifestyle but helps him to adapt to it. The Invisalign technique, which was introduced on the U.S. market in 1999 and 2001 in Europe can be considered the basis for the most innovative therapies of modern orthodontics applied to adult patients (8).

Invisalign technique

Invisalign is a new technique able to resolve some orthodontic malocclusions without the use of traditional fixed equipment (1). It favours the use of clear, removable transparent masks that represent the mechanotherapy (3).

The real innovation of the methodology is represented by Clin Check, a digital three-dimensional simulation that allows clinicians and the patients to see a film on the computer tracking the movements from beginning to end of the dental treatment (5, 7).

The Aligners, made of transparent thermoplastic polymer, allow a tooth movement of 0,15-0,25 mm; they must be worn at least 18 hours a day and have to be replaced every 15 days with the next aligner (2, 5). The possibility of removing these alignments can at the same time help to control daily oral hygiene. Some types of movement are favoured by the "Attachments" forms at the dental composite used in relation to their shape and positioning that determine

movements such as intrusion, extrusion, rolling, fluid, torque, up righting of the root (5). In order to provide masks without defect it is crucial to make impressions in PVC in order to obtain precise study models (10).

Case report

A 61 year old patient came to our observation complaining of a relational problem regarding poor aesthetics of the smile (Figs. 1, 2). An anamnestic examination, showed that the patient was suffering from Werlhof disease.

On examination it showed a severe crowding in the superior (Fig. 5) and middle inferior dental arch (Fig. 6), with the presence of cross bite against the elements 1.5, 2.4, 2.5 (Figs. 3, 4).

From the radiographic examination, rx endoral and ortopanoramica (Fig. 7), a significant bone loss was found in the upper arch.

The survey confirmed the periodontal data and radiographs and showed diffuse bleeding, signs of active disease. Some dental elements showed a grade II mobility. In a functional examination no signs of suffering were found of the temporo mandibular joint.

Treatment plan

In view of the case history, a non-invasive treatment was chosen that would resolve the periodontal (11, 12), aesthetic and functional problems without recurring to complex surgical rehabilitation. The patient was sent to the orthodontist for an evaluation. After the basic periodontal therapy had determined a significant reduction of the inflammation and had decreased the mobility of the 1.1-1.2-1.4-3.1 dental elements.

The Patient's desire was to improve the smile, but without going through fixed type traditional orthodontics.

Therefore it was decided to use the Invisalign treatment to improve the results.

The Upper dental alignment was obtained by re-

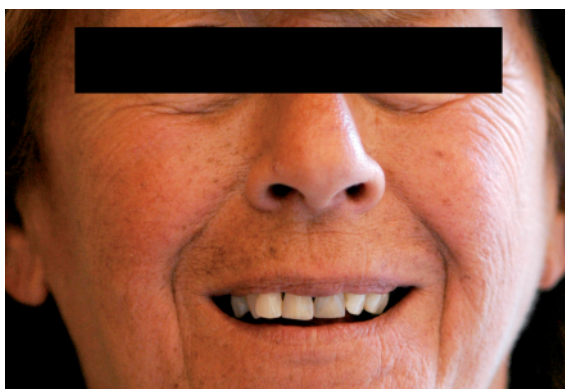

Figure 1
The smile of the patient before treatment (t0).

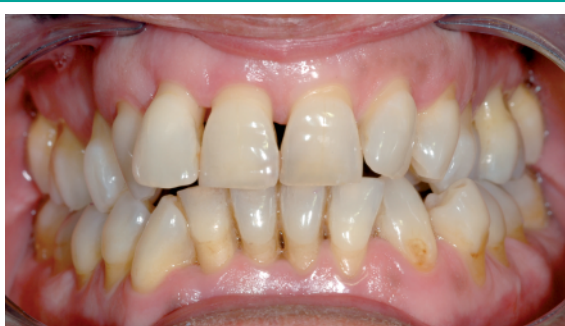

Figure 2
Frontal view (t0).

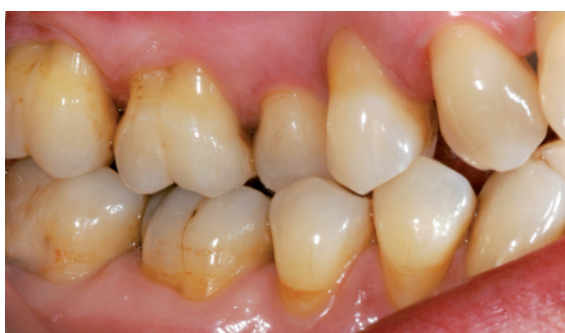

Figure 3
Lateral view right (t01).

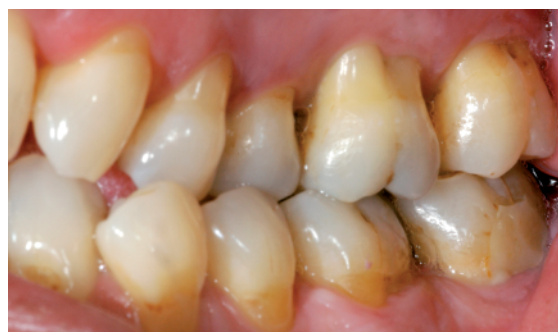

Figure 4
Lateral view left (t0).

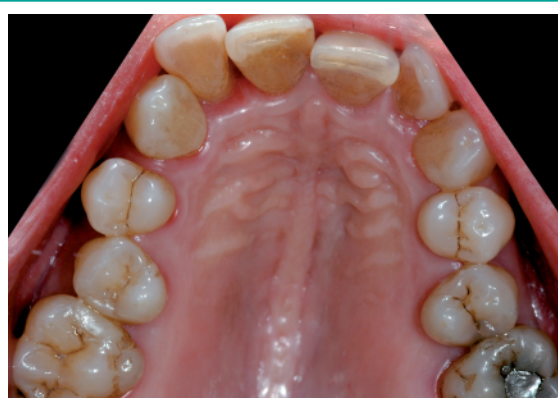

Figure 5
Occlusal view of the upper arch (t0).

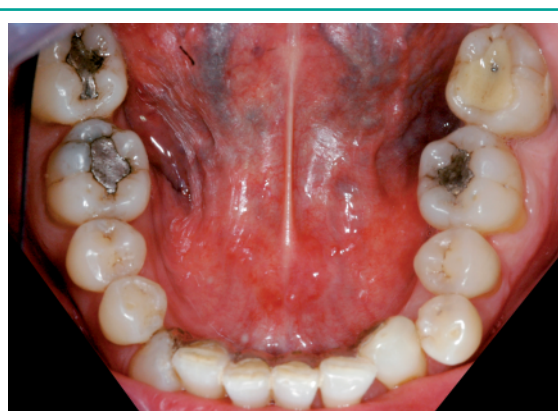

Figure 6
Occlusal view of the lower arch (t0).

covering the space through an interproximal reduction of the the front area of the canines. An intrusion of 1.1 and 1.2, reduction in overjet and rotations of 1.3 and 2.3 (Figs. 8, 11).

It was decided to perform a splinting in gold for periodontal reasons from 1.4 to 2.4 (Fig. 9) in order to fix the dental elements.

The same treatment in gold for periodontal reasons in the lower arch from 3.3 to 4.3 (Fig. 10)

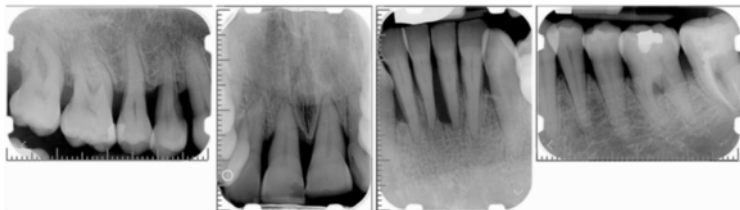
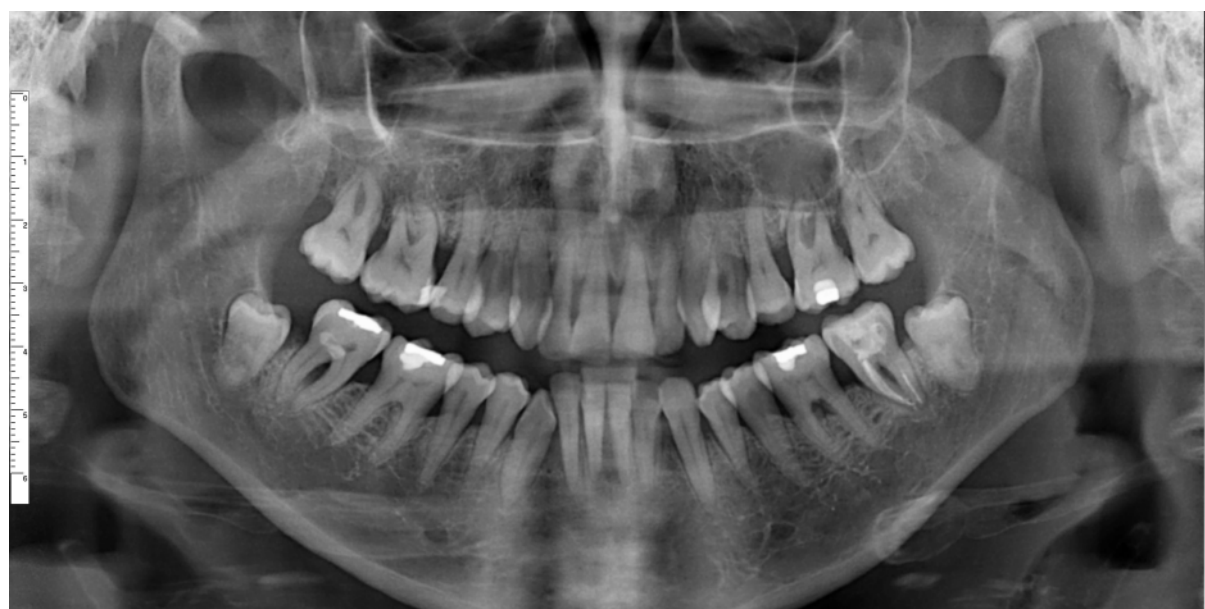

Figure 7
Rx intraoral and ortopantomica before treatment (t0).

Clin check

The Clin-Check developed by the Align Technology showed the complete alignment after 19 mask applications, using only 3 aligners in order to obtain an hypercorrection of the rotations of 2.2 and 2.3. Horizontal rectangular Attachments were made on 1.4 and 2.4 in order to obtain anchorage. Egg shaped attachments on 2.1 and 2.2 have the function to facilitate the intrusion of 1.1 and 1.2.

Vertical rectangular attachments have been provided on 1.3 and 2.3 in order to determine the rotation of these elements.

The retraction of 1.2 was planned to obtain the alignment and to reduce the overjet.

The recovery of space for the alignment, as described,

was obtained by interproximal reduction from canine to canine (IPR).

Conclusions

The treatment described is an agreement between the aesthetic needs of the patient and a real clinical possibility. Invisalign could be a valid solution to face aesthetic problems in patients with severe systemic diseases, when it is not advisable to intervene with complex implant-prosthetic rehabilitations.

From our point of view this solution can be a valid therapeutic alternative, that would allow to a good aesthetic and functional result, minimizing the patients difficulties respecting the “primum non nocere.”

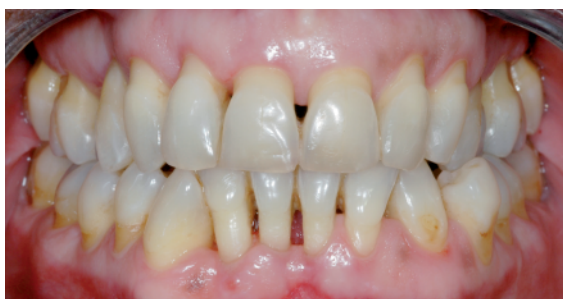

Figure 8
Frontal view after treatment (t1).

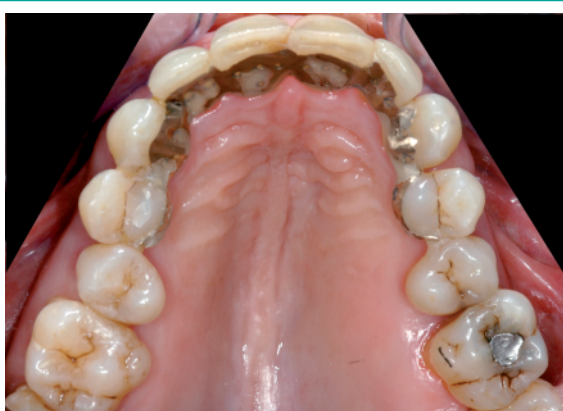

Figure 9
Occlusal view of the upper arch after treatment (t1).

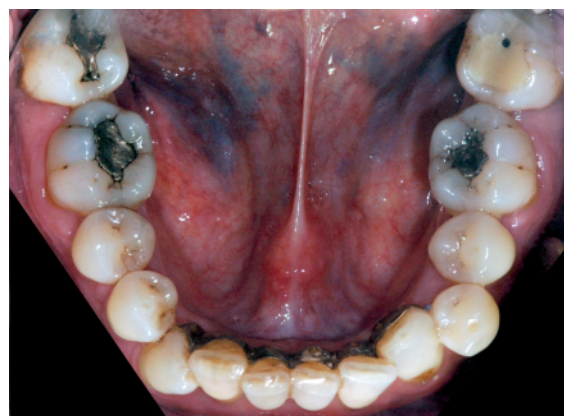

Figure 10
Occlusal view of the lower arch after treatment (t1).

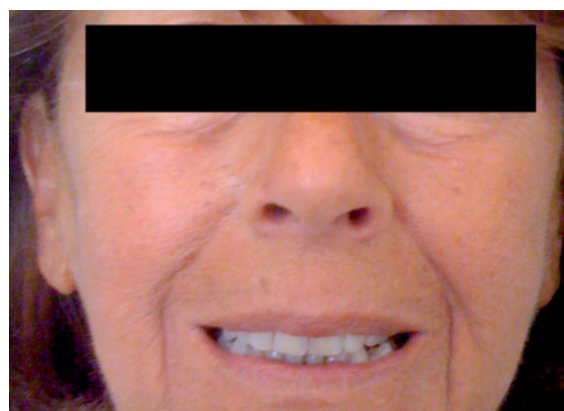

Figure 11
The smile of the patient after treatment (t1).

References

1. Tuncay OC (Editor) The Invisalign system. Quintessence Publishing 2006- 1°ed.
2. Mc Namara JA, Kramer KL, Juenker JP. Invisible retainers. JCO 1985; 19(8):570-578.
3. McNamara JA jr, Brudon WL. Invisible retainers and aligners. In McNamara JA. jr., Brudon WL (eds). Orthodontics and Dentofacial Orthopedics. Ann Arbor:Needham 2001;475-486.
4. Miller RJ, Kuo E, Choi W. Validation of Align Technology's Treat III™ digital model superimposition tool and its case application. Orthodontics & Craniofacial Research 2003;6,143-149.
5. Align Technology, <http://www.invisalign.com>
6. Boyd RL, Oh H, Fallah M., Vlaskalic V. An update on present and future considerations of aligners. J Calif Dent Assoc 34-2006;793-805.
7. Nedwed V, Miethke RR. Motivation, acceptance and problema of Invisalign patients. J Orofac Orthop 66,2005;162-173.
8. Boyd RL. Complex orthodontic treatment using a new protocol for the Invisalign appliance. JCO Vol. XLI (9) 2007; 525-547.
9. Giancotti A, Muzzi F, Santini F, Arcuri C. Nuovo metodo di trattamento in ortodonzia nell'adulto. Dental Cadmos 7,2006;1-14.
10. Farah JW, Powers JM. Elastomeric impression materials. The Dental Advisor December 2003; Vol 20, No 10;2-4.
11. Turatti G, Womack R, Bracco P. Incisor intrusion with invisalign treatment of an adult periodontal patient. J Clin Orthod 2006 mar; 40(3):171-4.
12. Miethke RR, Vogts S. A comparison of the periodontal health of patients during treatment with the invisalign system and with fixed orthodontic appliances. J Orofac Orthop 2005 may; 66(3):219-29.

Correspondence to:

Dr.ssa Alberta Barlattani

Tel.: +39.06.20900691

E-mail: albertabarlattani@libero.it