



Bachelor Degree in Biomedical Engineering  
Academic Year (2017-2018)

*Bachelor Thesis*

# BUILDING AND VALIDATION OF LOW-COST BREAST PHANTOMS FOR INTERVENTIONAL PROCEDURES

---

Author

María Teresa Ruiz Alba

Tutor

David García Mato

Leganés, June 2018



*This page was intentionally left blank*

## ABSTRACT

Breast cancer is one of the types of cancer with the highest incidence in female population. Current treatment for breast cancer is lumpectomy, a breast conserving tumor excision procedure based on localizing the tumor with the help of hook-wire needle placement. Although this constitutes the standard approach in clinical practice, these procedures do not ensure the complete removal of the lesion due to the demonstrated high rate of positive margins.

Improvements in these techniques are needed in order to reduce the number of second interventions, which usually involve mastectomy. Here is where ultrasound-guided interventions with real-time position tracking find their place. The problem is that these techniques require a high level of expertise and they present long learning curves. Therefore, training is needed in order to get from these tools their highest potential and have a real impact in the life of patients.

For this purpose, breast phantoms were manufactured using liquid vinyl in order to achieve a mammary mimicking tissue. Optimal manufacturing technique was determined based on a gold-standard (commercial phantom). CT and ultrasound imaging were used to assess the identification of lesions. In addition, manufactured breast phantoms were evaluated by an expert clinician and surgical navigation was tested. This was done with the purpose of validating the breast phantom as a training tool useful for improving the outcomes of these procedures.

The results indicated that the optimized formula achieved for the manufacturing of low-cost breast phantoms was suitable for training the skillset required in the interventions related with breast cancer treatment.

**Keywords:** breast phantom; training; ultrasound-guided interventions.

*This page was intentionally left blank*

## **AGRADECIMIENTOS**

En primer lugar, me gustaría agradecer a David su apoyo, ayuda, ánimos constantes y por ser el mejor tutor que podría haber tenido. También agradecer a Javier Pascau la oportunidad que me brindó al ofrecerme este proyecto, así como su interés durante el mismo por saber las dificultades que se me presentaban.

A todos mis profesores de la Universidad Carlos III de Madrid por haberme enseñado tanto estos cuatro años de carrera y despertar mi inquietud por temas que desconocía.

A mi familia, por animarme cada vez que las cosas no salían bien y motivarme a ser mejor cada día, por estar siempre ahí.

A mis amigas, por acompañarme en los que han sido los mejores cuatro años de mi vida. Por las interminables semanas de comedor y biblioteca, por acompañarme en este camino en el que hemos compartido mucho estrés y varias decepciones, pero todas juntas nos hemos apoyado como una familia. Pero sobre todo gracias por nuestras charlas en el césped, nuestros viajes y todo lo que nos queda.

## INDEX

ABSTRACT .....	III
AGRADECIMIENTOS .....	V
1. INTRODUCTION .....	1
1.1. CONTEXT AND EARLY DIAGNOSIS .....	1
1.2. CURRENT STANDARD FOR TREATMENT .....	3
1.3. IMPROVEMENTS .....	5
1.3.1. INTRAOPERATIVE ULTRASOUND .....	6
1.3.2. SURGICAL NAVIGATION .....	8
1.4. BREAST PHANTOMS FOR TRAINING .....	9
1.5. STATE OF THE ART .....	10
1.5.1. BREAST PHANTOM BUILDING .....	10
1.5.2. SURGICAL NAVIGATION ON BREAST PHANTOMS .....	12
1.6. LEGAL FRAMEWORK .....	13
2. MOTIVATION AND OBJECTIVES .....	14
3. MATERIALS AND METHODS .....	16
3.1. BREAST PHANTOM BUILDING .....	16
3.1.1. MATERIALS .....	16
3.1.2. BUILDING PROCESS .....	17
3.1.3. EXPERIMENTAL WORKFLOW .....	19
3.2. BREAST PHANTOM VALIDATION .....	30
3.2.1 ULTRASOUND IMAGES ACQUISITION .....	30
3.2.2. CT IMAGES ACQUISITION .....	33
3.2.3. EVALUATION BY EXPERT CLINICIAN .....	33
3.2.4. TESTING SURGICAL NAVIGATION .....	34
4. RESULTS AND DISCUSSION .....	37

4.1. ULTRASOUND IMAGES.....	37
4.1.1. BREAST MIMICKING TISSUE ANALYSIS .....	38
4.1.2. TUMOR COMPOSITION ANALYSIS.....	44
4.1.3. BREAST PHANTOM MANUFACTURED WITH OPTIMIZED FORMULA.....	48
4.2. CT IMAGES.....	48
4.3. EVALUATION BY AN EXPERT CLINICIAN .....	50
4.4. SURGICAL NAVIGATION .....	51
5. CONCLUSIONS AND FUTURE WORK.....	53
5.1. CONCLUSIONS .....	53
5.2. FUTURE WORK .....	54
6. PROJECT BUDGET .....	55
BIBLIOGRAPHY .....	58

## LIST OF FIGURES

Fig. 1. Main cancer types for females worldwide in 2012 from [2].	1
Fig. 2. Cancer in Spain in 2014. A): Cancer mortality profile for females. B): Cancer incidence in females from [5].	2
Fig. 3. Projections of a breast with a hooked wire localized small impalpable mass from Cranial-Caudal (CC) and Latero-Medial (LM) views respectively, from [9].	5
Fig. 4. Intraoperative ultrasonography image guidance for wire placement through the tumor. (A): the needle (above) and the wire (below) used in the procedure. (B): the wire is passed through the needle. (C): tumor targeting and localization with the wire through the needle using ultrasonography guidance. (D): the needle is removed and the wire is left sticking out of the patient's breast. (E-F): ultrasonography imaging used to check that the tumor, indicated by the black arrow, is traversed by the wire, indicated with white arrows. From [14].	7
Fig. 5. Final phantom showing its flexibility, from [17]	11
Fig. 6. Experimental procedure to obtain final phantom, from [18]. The image at the left shows how the tumors were placed. Image at the right shows the appearance of the final phantom.	11
Fig. 7. Sonogram of two olives inside the phantom simulating deep breast lesions, from [19].	12
Fig. 8. Commercial breast phantom from the company CIRS.	17
Fig. 9. Schematic representation of the main parts in a manufactured breast phantom.	19
Fig. 10. Schematic representation of the small breast phantoms in the mold.	20
Fig. 11. Schematic representation of the layer distribution in the breast phantom manufactured for the third experiment.	26
Fig. 12. Top view of the two layers in the phantom. At the left is layer 1: (A) tumor with low cellulose quantity, (B) tumor without cellulose, (C) tumor with high quantity of cellulose. The sketch at the right corresponds to layer 2: (D) same concentration of cellulose as C, (E) same composition as B and (F) same composition as A.	27
Fig. 13. Flowchart that summarizes the process for building breast phantoms.	29
Fig. 14. Developed software application for the acquisition of US images. US image of the manufactured phantom is displayed on the right side of the screen.	31
Fig. 15. Ultrasound images from different slices of phantom 1 from experiment 1. In both images it can be observed the yellow selection area of the same size and shape which is used, in this case, to obtain data from the ultrasound contrast tissue. The bright horizontal line corresponds to the table above which the phantom was resting on when acquiring the images. It appears due to the depth parameter of the ultrasound system. In the left image it can be observed a tumor placed on the interface between both tissues.	32
Fig. 16. Setup of the CT image acquisition process of the manufactured phantoms and the commercial phantom.	33
Fig. 17. The image at the left shows a schematic representation of the navigation setup, from [7]. The image at the right shows the real instruments used: (A) is the reference, which generates the electromagnetic field; (B) the ultrasound probe with its position	



tracker sensor at the upper end; (C) manufactured breast phantom (phantom 10); (D) needle for tumor localization; (E) stylus that simulates the cautery.....	34
Fig. 18. Tumor contouring in the final manufactured phantom (phantom 10).....	35
Fig. 19. Breast phantom shape modelling. The tumor is represented by the green model, and the surface model of the phantom is built from the red points taken with the stylus, which is the yellow object model. ....	36
Fig. 20. Ultrasound image from the commercial phantom showing breast mimicking tissue. ....	37
Fig. 21. Ultrasound images from manufactured breast phantoms with cellulose (left) and without cellulose (right). The image on the left corresponds to phantom 7 and the image on the right, to phantom 5.....	38
Fig. 22. Boxplot with the mean values distribution for each ultrasound contrast tissue composition. ....	39
Fig. 23. Boxplot with the median values distribution for each ultrasound contrast tissue composition. ....	39
Fig. 24. Boxplot with the standard deviation values distribution for each ultrasound contrast tissue composition.....	40
Fig. 25. Boxplot of the mean values measured from the manufactured phantoms in experiment 2. ....	41
Fig. 26. Boxplot of the median values measured from the manufactured phantoms in experiment 2. ....	42
Fig. 27. Boxplot of the standard deviation values measured from the manufactured phantoms in experiment 2. ....	43
Fig. 28. Ultrasound image from the commercial phantom showing a lesion (top right) surrounded by breast mimicking tissue. ....	44
Fig. 29. Ultrasound images from the manufactured phantom in experiment 3 (phantom 9). The first image shows a tumor with low cellulose concentration placed in layer 1. The image at the right shows a high cellulose concentration tumor also in layer 1. ....	45
Fig. 30. Boxplot showing the mean values distribution for each type of tumor composition. ....	46
Fig. 31. Boxplot showing the median values variation for each type of tumor composition. ....	46
Fig. 32. Boxplot showing the variation in the standard deviation values for each type of tumor composition.....	47
Fig. 33. Ultrasound image from phantom 10 showing a high cellulose concentration lesion.....	48
Fig. 34. CT coronal, sagittal and axial image planes from the phantoms in experiment 2. ....	49
Fig. 35. Intensity thresholding segmentation in 3D Slicer of the tumor and the breast mimicking tissue from the CT images of the manufactured phantoms. ....	49
Fig. 36. 3D model of a small breast phantom from experiment 2 with a tumor inside..	50
Fig. 37. US image-guided insertion for tumor localization on the manufactured final breast phantom. In the left image the blue arrow indicates the needle approaching the	

lesion. In the image at the right, the arrow points the needle already inserted in the tumor..... 51

Fig. 38. Navigation display showing the breast model containing the tumor model. The position of the different tools is displayed in real time: cautery (yellow) and needle (blue)..... 52

**LIST OF TABLES**

Table 1. Summary of the different compositions for the breast mimicking tissue in the  
manufactured phantoms..... 28

Table 2. Human Resources Costs ..... 55

Table 3. Technical equipment costs. .... 56

Table 4. Laboratory material costs. .... 56

Table 5. Estimated total budget for the project. .... 57

## 1. INTRODUCTION

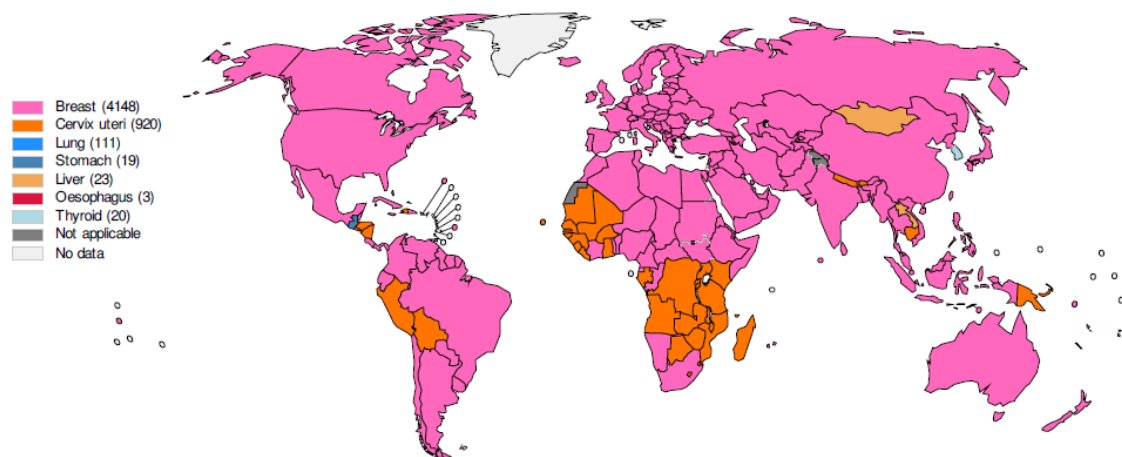
### 1.1. CONTEXT AND EARLY DIAGNOSIS

**Cancer** is a disease produced by the cell proliferation in an abnormal and uncontrolled way, disregarding the normal cell division steps, followed by the invasion and colonization of different body parts that are normally reserved for other cells.

There exist specific mechanisms that control cell proliferation for tissues to renew and repair themselves. During their replication, cells must occupy their specific place, do their function and do not invade other tissues of the organism. But, when a single cell misbehaves due to a mutation or genetic alteration that allows it to survive and divide when it should not, it causes a disruption in the tissue organization leading to different diseases, among which cancer is included. When cancer cells invade surrounding tissues and reach distant sites of the organism, metastasis occurs [1].

Among the different types of cancer that are classified based on the tissue affected by the abnormal cell proliferation, one of the most important is **breast cancer**.

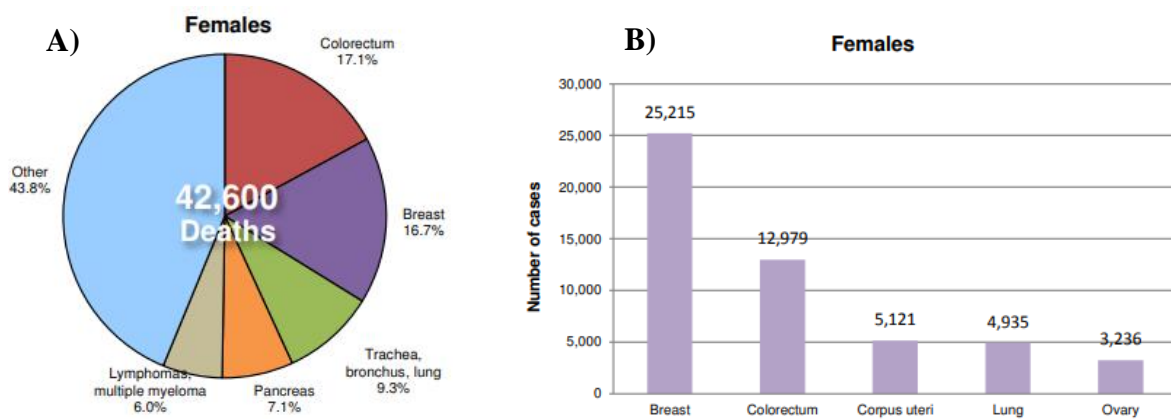
According to the World Health Organization (WHO), breast cancer is the most common cancer type in women both in the developed and developing world [2], [3] (**Fig.1**). The incidence of breast cancer is increasing in developing countries due to the increment in life expectancy, urbanization and adoption of developed-countries lifestyles.



**Fig. 1.** Main cancer types for females worldwide in 2012 from [2].

In the case of Spain, in 2014, the statistics collected by the World Health Organization (WHO) stated that one of the most remarkable causes of death in females was breast cancer (**Fig.2.A**). Even though Spain is a developed country where public health care is available for women to undergo breast exams and mammograms, breast cancer presents a high incidence in the population. An early detection and cancer screening is crucial to ensure the survival of the highest percentage of affected women as possible, and to continue decreasing the mortality rate of breast cancer (**Fig.2.B**).

**Early diagnosis** can be defined as the early identification of cancer in patients who have presented symptoms and signs of the disease. On the other hand, cancer screening is the process of identifying unrecognized or pre-clinical cancer lesions in a target population that has not presented symptoms to the disease and are apparently healthy [4].



**Fig. 2.** Cancer in Spain in 2014. **A)**: Cancer mortality profile for females. **B)**: Cancer incidence in females from [5].

Improvements in imaging techniques, informed patients and extended screening mammography have influenced an increase in the percentage of women diagnosed with breast cancer in an early stage [6].

The aim is to identify the breast tumor in the earliest stage as possible in order to give the patient an immediate diagnosis and the corresponding treatment. The sooner the cancer is detected the more chances the patient has to beat the disease, improving the chances of survival and quality of life during the process [4].

## 1.2. CURRENT STANDARD FOR TREATMENT

When breast cancer is discovered in its early stage, the standard surgical treatment used to fight the abnormality is a breast conserving tumor excision known as **lumpectomy**. In this surgical procedure the tumor is removed conserving as much surrounding healthy tissue as possible trying to avoid positive margins. After the intervention, the excision margins have to undergo a histological analysis to ensure that tumoral tissue has been removed completely [7].

It is common that the results of the histological analysis indicate that cancer cells have not been completely removed, which leads to the performance of a re-excision lumpectomy in order to obtain clear margins and minimize the possibility of cancer recurrence. Total mastectomy, which involves the removal of the whole affected breast, is usually the second intervention performed deriving in worst aesthetic results. This causes additional trauma to the patient and delays in posterior complementary treatments [7], [8]. Therefore, in order to prevent these situations, positive margins in lumpectomy is a problem that needs to be solved.

Although lumpectomy presents the problem of positive margins, its long-term survival is equivalent to mastectomy. Hence lumpectomy is the preferred treatment due to the less psychological impact to the patient and improved cosmetics. However, due to the high incidence of breast cancer, the reduction of positive margins is necessary to have a meaningful impact on population health and on the costs of the healthcare system [7].

The high rate of positive margins can be justified by two characteristics of the tumor and breast tissue: most of the abnormalities are not superficial therefore they are not palpable, making difficult to the surgeon the complete tumor excision since they don't have neither visual nor tactile feedback to ensure its complete removal. The second characteristic is that the breast tissue is very deformable, allowing tumor movements [7]. Due to these breast cancer features, preoperative images, used in order to assist the surgeon and the radiologist on tumor localization, may only give approximate information about its position during the intervention.

The current standard approach in lumpectomy for tumor targeting is the **wire localization technique**; it is especially useful for non-palpable breast lesions since their accurate localization is a key step in order to achieve their complete excision, and at the same time conserving the breast shape as best as possible [9] .

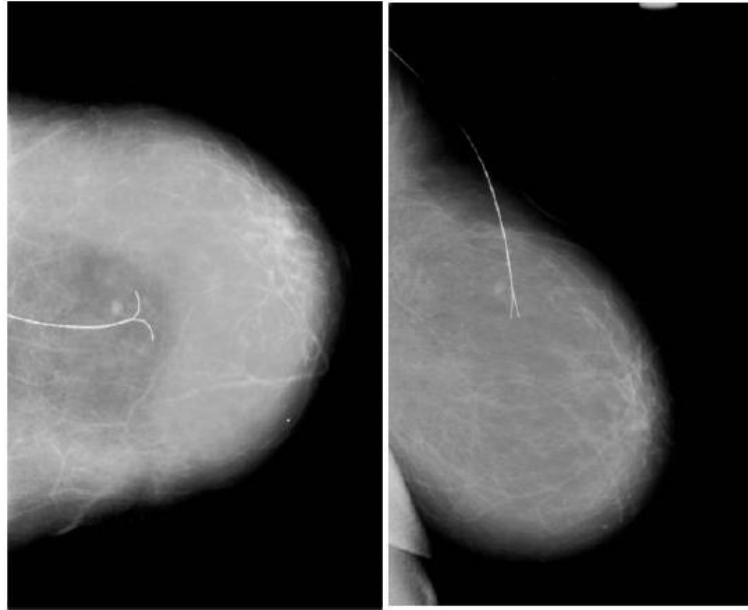
The process is done as a pre-surgical step in which the radiologist, in charge of performing the hook wire localization, needs image guidance of the breast so that the hooked tip of the wire can be precisely inserted in the tumor [9]. This guided insertion is most commonly done with mammography and medical ultrasound (sonography); MRI can also be used, although its role as an imaging guidance technique for hook wire localization is not the usual way to proceed [10].

Usually mammography or sonography guidance are selected in order to perform the abnormality localization; it can depend on the imaging technique used in the study previously performed for the tumor detection, on which of them shows better the affected area, or also on the preference of the surgeon [11].

Once the image guidance technique is chosen, a needle is inserted through the patient's breast following its progression through the images until it reaches the abnormality. This insertion is performed under local anaesthesia. Then a wire is passed through the hollow needle until its tip is inserted in the tumor; after that, the needle is removed and the wire is left sticking out of the patient's breast with its hooked tip traversing the abnormality [9].

The image below is an example of the result of this process: it shows a mammogram that has been acquired to ensure that the wire is correctly placed through the tumor (**Fig.3**). This step is crucial because the success in the surgical procedure will highly depend on the work that the radiologist has previously done localizing and targeting the tumor with the hooked wire.

Finally, during the surgery, surgeons follow the hooked wire through the tissue and the lesion (with certain healthy tissue margin) is removed. The excised mass is analysed through radiography to check that tumoral tissue has been precisely excised. This procedure has to be done as fast as possible because from this result depends the continuation or the end of the surgery, since it will allow to determine if there are negative margins in the excised tumor or not.



**Fig. 3.** Projections of a breast with a hooked wire localized small impalpable mass from Cranial-Caudal (CC) and Latero-Medial (LM) views respectively, from [9].

Specialists like radiologists and surgeons need to develop certain skills in order to perform their roles in the best possible way. These capabilities have to be learnt and refined through training and, where possible, outside the real clinical practice to protect patients from mistakes or inaccuracies which could make the process longer and more traumatic.

This training is especially necessary for techniques such as hook wire placement guided with ultrasound imaging, in order to practice the ability of correlating information from images of patients' studies and the reality presented in the breast tissue during the intervention.

### 1.3. IMPROVEMENTS

Hook wire localization is a very useful and well-established technique as a step previous to the intervention, which helps with the targeting of impalpable breast lesions facilitating the surgery to the physician, but it also presents some problems that need to be taken into account.

Some of these problems and disadvantages include the process of placing the wire, which is very challenging particularly in dense breast tissue or when the abnormality is very deep close to the chest muscles, causing discomfort to the patient. Also, once in place, the wire can be displaced, migrate or be crosscut [12].



All these complications can make harder for the surgeon the tumor localization during the intervention, therefore leading to the high rate of positive margins that can later derive in a second intervention, usually mastectomy, making the process more traumatic for the patient [7].

The high incidence of positive margin rates is produced by the inaccuracies and collateral problems of hook wire localization. Some of them include the displacement of the abnormality mass traversed by the hooked tip, causing on the surgeon an insufficient spatial appreciation or awareness of the tumor size. It also has to be taken into account that radiologists, when placing the wire through the lesion, are being guided by images, normally mammography. In the case of the surgeon, the intervention is performed using the information provided by the radiologist from previous imaging studies of the patient, and from the previous localization of the tumor [7]. Therefore, the surgeon's ability to correlate information from at least three different sources is something that needs to be developed and trained.

Hence it can be seen that all the process of breast cancer localization and surgical removal is based on estimations performed by the professionals in charge, implying that the intervention's success has a high dependence on their experience, skillset and precision, leading in some cases to the removal of inaccurate carcinogenic breast tissue masses that result in positive margins.

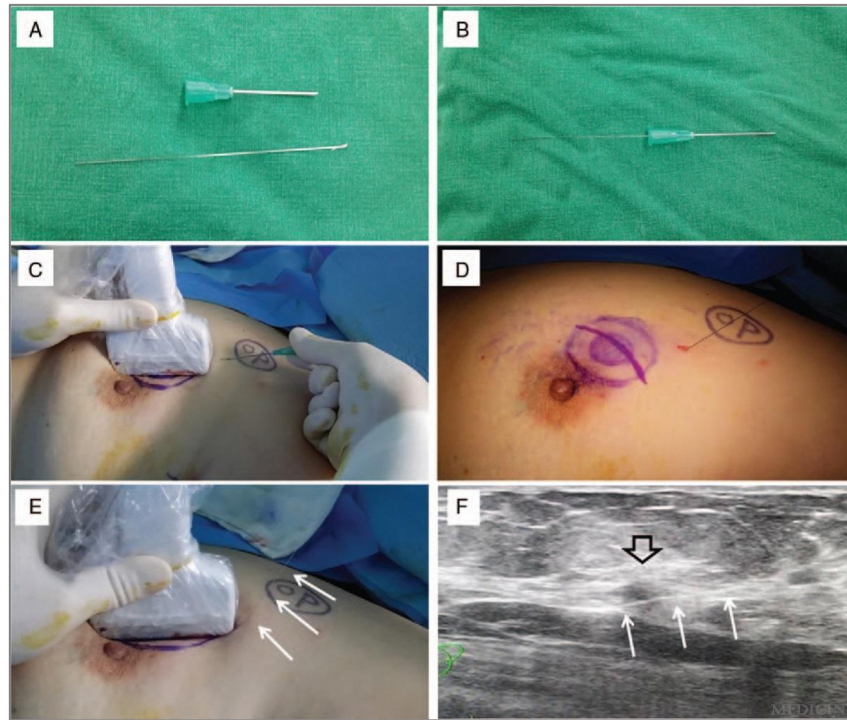
### 1.3.1. INTRAOPERATIVE ULTRASOUND

Surgeries like these cannot depend so much on the intuition and estimation of the surgeon. For this reason, an imaging system used at real-time inside the operating room would be very helpful for the surgeon by providing constant feedback on the tumor localization with respect to the position of the tools used during the excision.

In this context, **intraoperative ultrasound** can be used by surgeons during tumor excision allowing them to do an estimation of the distance between the cautery and the tumor margin in the ultrasound image [7].

This intraoperative technique is known as Continuous Ultrasound-guided Breast Excision (CUBE); it allows the dissection of the breast abnormality with a continuous visualization of its margins, optimizing as much as possible the resection of the tumor. This technique also provides real-time adjustment in order to ensure the maximum rate of negative margins as possible (**Fig.4**), increasing in this way the chances of the patient

to avoid a second intervention that usually ends up in complete breast removal (mastectomy). Finally, CUBE technique improves as well the cosmetic results of the breast since this procedure reduces the amount of resected tissue necessary to restore patient's health [13].



**Fig. 4.** Intraoperative ultrasonography image guidance for wire placement through the tumor. (A): the needle (above) and the wire (below) used in the procedure. (B): the wire is passed through the needle. (C): tumor targeting and localization with the wire through the needle using ultrasonography guidance. (D): the needle is removed and the wire is left sticking out of the patient's breast. (E-F): ultrasonography imaging used to check that the tumor, indicated by the black arrow, is traversed by the wire, indicated with white arrows. From [14].

There are a lot of evidences showing that intraoperative ultrasound for tumor monitoring and visual localization reduces the rate of positive margins. It has been demonstrated that this technique provides the necessary accuracy for localization of non-palpable and palpable breast tumors, since higher rates of negative margins and optimum resection volumes have been obtained in patients undergoing breast conserving surgery (BCS) [6].

But, although intraoperative ultrasound has obtained optimum results in some studies, it is not still the standard clinical practice when breast tumor localization has to be performed. This is due to the fact that intraoperative ultrasound or ultrasound-guided surgery requires a combination of sonography and skills including accuracy,

coordination and precision, that are difficult to learn and have to be trained by professionals before entering the operating room.

The long and difficult learning curves to acquire these capabilities, added to the fact that its apprenticeship is not included in surgical formation programs, makes very difficult the incorporation of intraoperative ultrasound as the routine clinical practice [7].

Nevertheless, the positive margin rate obtained with intraoperative ultrasound, although lower than the one obtained with wire localization technique, is still a significant and considerable amount [7].

### 1.3.2. SURGICAL NAVIGATION

Even though it is a big step forward compared to hook wire localization, intraoperative ultrasound still does not provide the accuracy needed to ensure negative margins. Additional guidance to achieve better support, references and visual feedback for the surgeon is essential in order to ensure success in the breast tumor excision intervention.

These improvements in the way the tumor is localized and excised are provided to the surgeon by **computerized surgical navigation**, which allows real-time tracking of the surgical instruments with respect to the tumor target. This additional support brings a lot of benefits with a direct impact in the surgeon's confidence, therefore leading to an even bigger reduction in positive margins.

Real-time position tracking has already been used for marking breast tumors using magnetic resonance image (MRI)-guidance before performing breast conserving surgery or lumpectomy [15]. Taking as reference the use of MRI-guidance for tumor localization through surgical navigation, this technique can also be done with ultrasound.

Some studies have suggested the use of ultrasound-guided surgical navigation, where the position of the cautery is tracked in real-time with respect to the tumor position [7]. This system allows the surgeon to visualize tumor margins during the procedure maintaining or even increasing the rate of negative margins and preventing unnecessary and excessive removal of healthy breast tissue.

These procedures and techniques require the confidence given by experience in order to make the process less traumatic for the patient and to reduce the cosmetic impacts in the affected breast. It is also necessary to excise the tumor in the most optimal way as

possible, preserving the highest allowed percentage of healthy surrounding tissue and decreasing positive margins in the resected volume.

In order to achieve all of these objectives, radiologists and surgeons need to be very well prepared and to acquire some of the necessary skills and more hands-on the field experience, training is necessary. Because of that, ideally breast phantoms should be designed and used for training of clinicians to localize lesions using X-rays or ultrasound.

#### **1.4. BREAST PHANTOMS FOR TRAINING**

Image-guided needle placement and in particular US-guided tumor localization, has become a very important tool to obtain and perform accurate diagnosis and therapy, especially important for breast cancer. This new way of targeting the tumor offers significant advantages over the conventional surgical procedures, since they contribute reducing pain, complications, time and overall costs [16].

Although this technique presents many advantages, placing a needle in a target position with the help of image guidance, can be a complex and very delicate task that requires fine and precise tool control and hand-eye coordination by the physician. In the case of breast cancer, this process gets even more difficult since the tumor targets in the mammary tissue can be non-palpable and move with the surrounding tissue due to its non-rigidity [16]. Therefore, the practitioners or trainees who will face at some point in their medical career a real surgical intervention, need to show confidence and experience which traditionally have been acquired on patients under the supervision of a senior physician.

The traditional way of learning medical techniques and procedures, expose the patients to the lack of experience of trainees in such important processes and the higher probability of errors during the intervention. In order to improve the learning curve of medical students, to increase their confidence and experience and to fix better the concepts and procedures by learning in a non-stressful situation, simulation models constitute an essential tool, since they resemble the real clinical situations providing objective and quantitative feedback for the trainees about their performance.

Simulation models cover from cadaver models to pure virtual reality. The traditional training practice of using cadavers has been left partially behind mainly due to ethical issues. Regarding virtual simulation models, they are useful for advanced trainees to

learn and acquire superior and excellent skills in the technique, but this method separates practitioners from the real physical world and the clinical environment [16]. The physical context which involves tools, dimensions and even the illumination of the environment are very important to be familiar with at the early stages of learning, and this is lost with pure computer simulators.

In this gap between cadaver models and virtual simulators is where the synthetic phantom models have their place and fit perfectly to the needs of the medical community in the learning stage [16]. These phantoms combine the advantages of physical dimensionality with the objective feedback provided by computers in a training situation.


In particular, breast phantoms in combination with US-guided needle placement and surgical navigation, provide the perfect set for trainees to be confident in breast cancer treatment procedures and also provide a more comfortable experience to the patient.

## **1.5. STATE OF THE ART**

Several studies have been published with the purpose of providing training protocols and methods for medical students. Multiple methods have been proposed for breast phantoms building using different materials and techniques. Moreover, there are few studies showing the use of surgical navigation on breast phantoms in order to test them for training of real clinical practice.

### **1.5.1. BREAST PHANTOM BUILDING**


Different combinations of materials and processes have been tested in order to achieve the optimal design for breast phantoms. Materials such as resin and plasticizer have been used to simulate breast tissue and to obtain different ratios of breast glandular tissue, modulating in this way the density of the phantom [17]. The problem of the manufacturing process of this breast phantom is the time that takes to build one, which is around 48h including the time to allow that the mixture of material poured into the mold sets well.



**Fig. 5.** Final phantom showing its flexibility, from [17] .

While in this first study they focused on achieving a good ultrasound contrast tissue that resembled with reliability the glandular and adipose tissue fractions, they did not include in the phantoms any lesions nor tumors that could allow medical professionals to acquire further training experience.

In a more recent study, a different composition for building breast phantoms was tried out. Polyvinyl chloride plastisol (PVCP) was used as the main base material to obtain these ultrasound-visible breast phantoms. In order to simulate the glandular breast tissue, graphite powder was used. Tumors were included, and they were done with different ratios of PVCP and graphite powder in order to obtain several types of lesions [18].

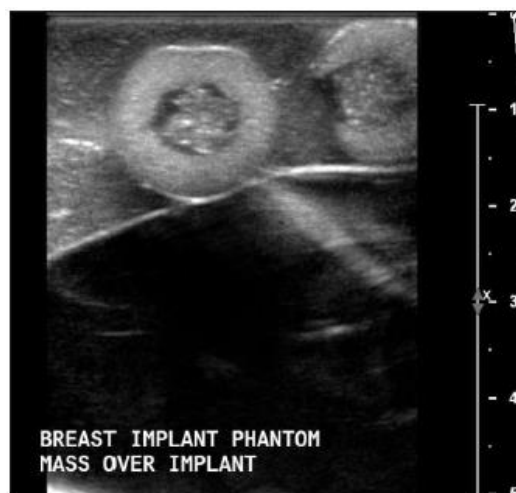

**Fig. 6.** Experimental procedure to obtain final phantom, from [18]. The image at the left shows how the tumors were placed. Image at the right shows the appearance of the final phantom.

These two studies were selected to show a general overview of what is the state of the art in breast phantom building. As it can be observed, the problem with both articles is the lack of resemblance in shape of the manufactured phantom with a breast. The fact of

having a similar shape to a real breast is important in order to get familiar with the correlation between the hand-probe movement over a curved surface and the ultrasound imaging planes.

Other problems found in recent studies related with breast phantom building for ultrasound-guided interventions is that the lesions introduced are visible from the outside [19], therefore making the training less similar to a real clinical practice, where the skin of the patient makes impossible to see underlying structures. Also, in this study olives are used in order to simulate breast lesions or tumors. This makes that the phantom is not useful for long periods of time since the olives expire inside.



**Fig. 7.** Sonogram of two olives inside the phantom simulating deep breast lesions, from [19].

### 1.5.2. SURGICAL NAVIGATION ON BREAST PHANTOMS

In the field of surgical navigation, few studies have been published in which the suitability of synthetic breast phantoms as training tools is evaluated through the testing of image-guided interventions in combination with surgical navigation.

One of the few and most recent works that defines the state of the art in this field is the one in which this bachelor thesis is based on [7]. In this study, during the simulation all the devices used such as the cautery, the needle for hook wire placement and the ultrasound probe are electromagnetically tracked. The relationship between the surgical instruments and the ultrasound imaging planes can be visualized and trained with this method.

In conclusion, several breast phantoms have been developed with different materials focusing on research, but few of them have reached medical students with the purpose



of being used as training tools. Even fewer studies have been published in which surgical navigation is tried out in these phantoms in order to have a feasible feedback about the type of tissue taken in the biopsy and reduce in this way the positive margin rates once the surgical intervention is performed.

This makes surgical navigation for breast tumor excision in combination with synthetic breast phantoms very necessary in order to give medical professionals a reliable feedback and have the opportunity to practice, prior to real interventions, with breast phantoms appropriately developed.

## **1.6. LEGAL FRAMEWORK**

The phantoms manufactured in this bachelor thesis have been developed as a training tool for junior radiologists, surgeons and medical students in general; they are not intended for real clinical practice, neither to be in direct contact with the patients therefore, the “EU rules to ensure safety of medical devices” legislation does not have to be followed [20] .

As there is not going to be any economical transaction since the phantoms are not intended to be sold, no European regulation has to be followed in these terms. Moreover, as for the development of this project it was not required any experimentation with animals, we were exempt as well of following this legislation.

Finally, for the manufacturing process of the breast phantoms, the bioengineering laboratory facilities of Universidad Carlos III de Madrid were used, therefore the regulation related with the correct and safe use of laboratories and experiments with chemical products affect the development of this bachelor thesis.



## 2. MOTIVATION AND OBJECTIVES

The **motivation** for this bachelor thesis is to provide training for medical professionals in the techniques involved in the treatment of breast cancer, such as hook wire placement for tumor localization and the posterior surgery for breast tumor excision. The training tool developed in this project allows them to practice the varied skillset needed for this type of interventions in which precision and confidence are key for an optimal performance of the practitioner. What is pursued is that the trainees have a first encounter with the patient being already confident and prepared, instead of undergoing a very stressful situation in which having mistakes is almost not contemplated and the learning experience is not as profitable as it could be using the breast phantoms.

In this way, trainees will face the real clinical practice being better qualified and with more solid knowledge about the mistakes that they can commit. All this comes as a result of training with breast phantoms visible in ultrasound images for guidance in needle placement, and posterior simulation and tracking with surgical navigation.

To take all this to practice, breast phantoms need to be developed. These phantoms should allow the visualization of lesions and healthy tissue using imaging techniques, such as ultrasound or X-ray imaging. This will be achieved finding the optimal components and manufacturing process for the breast phantom.

In order to do that, several **objectives** need to be established and followed. Their accomplishment is necessary to achieve an optimal low-cost breast phantom presenting all the important characteristics required for the training of junior physicians and students so that they develop valuable skills, useful when facing real clinical practice. Therefore, the objectives of this bachelor thesis are the following:

- Optimization of breast phantom building method: find the optimal ratio between the main components of the phantom to obtain realistic US and CT images where lesions can be identified. In order to achieve this goal, several experiments were performed for the ultrasound contrast tissue of the phantom and the lesions or tumors added to it.
- Building the phantoms with a similar shape, density and elastic properties to a normal breast in order to achieve a more realistic simulated environment during

training. Ideally, the phantoms will allow users to perform tissue excisions using conventional surgical instruments.

- Validation of the breast phantoms through ultrasound (US) and CT imaging. US and CT images of the manufactured breast phantoms were acquired and compared with images of the gold-standard (commercial breast phantom).
- Testing ultrasound-guided needle insertion for tumor localization. Clinical ultrasound system was used to localize lesions and to guide a needle insertion in the breast phantom.
- Testing surgical navigation based on electromagnetic tracking system and ultrasound guidance.

### 3. MATERIALS AND METHODS

#### 3.1. BREAST PHANTOM BUILDING

Human breast consists on different soft tissues such as adipose, glandular, stroma and lactiferous ducts [17]. In order to simplify our breast phantom preserving a reliable ultrasound imaging contrast, only glandular and adipose tissue have been taken into account when manufacturing the ultrasound contrast tissue. This part is the main component of the breast phantom and it appears as the image background when localizing lesions.

##### 3.1.1. MATERIALS

The materials that have been used for the building of the breast phantoms in this bachelor thesis have been chosen taking as reference a recipe proposed by the Laboratory of Percutaneous Surgery (PerkLab) (Queen's University, Kingston, ON, Canada) [7]. The products used are the following:

- Super soft liquid vinyl: main material of the phantom for mimicking breast tissue. It becomes mostly transparent when reaching temperatures higher than 200°.
- Softener: used to achieve different densities of the overall phantom affecting directly on the rigidity and consistency.
- Cellulose: used to provide ultrasound contrast to the phantoms by mimicking different ratios of glandular and adipose tissue.
- Calcium sulfate: used to increase density of lesions, making them visible in X-ray imaging.
- Plastic colorant: used to provide a more realistic appearance to phantoms by simulating skin color and opacity.


The laboratory facilities and devices necessary to build the breast phantoms are:

- Fume hood: to extract the toxic gases released during the process of heating the plastics.
- Hot plate with magnetic stirrer and a magnet: to heat homogeneously the materials and to keep a constant stirring of the mixture reducing formation of bubbles.
- Gloves

- Wooden stirring sticks
- Measuring cups
- Beaker: to measure more accurately the volumes of plastic used.
- Precision weighing balance: to measure cellulose and calcium sulfate quantities.
- Spatula: the size of a normal laboratory spatula is what the measurement ‘tsp’ (table spoon) during the methods explanation is referred to.
- Ceramic molds

### 3.1.2. BUILDING PROCESS

In this section, the main steps and components needed in the manufacturing process for each of the parts that form the breast phantom are explained. In order to do this, the materials listed above are mixed in different proportions to build the skin, the ultrasound contrast tissue and the lesions or tumors placed over the glandular/adipose tissue mimicking component. The objective is to obtain the optimal ratio between the different materials so that the manufactured phantom resembles the consistency and ultrasound imaging contrast of a commercial breast phantom taken as reference (gold-standard) (**Fig.8**).



**Fig. 8.** Commercial breast phantom from the company CIRS.

### *SKIN*

The skin is the outermost part of the phantom and is the one in direct contact with the ultrasound probe. Therefore, it has to be made of a material that allows ultrasound waves to penetrate and trying to avoid the formation of bubbles, which reflect the ultrasound signal making difficult to image deeper structures in the phantom.

It is composed of 50 ml of super soft liquid vinyl and drops of caramel colorant. First of all, these 50 ml are poured into a measuring cup and placed on the hot plate. The liquid vinyl is homogeneously mixed while its temperature is progressively increased so a translucent and watery consistency is achieved.

This whole process of heating up the plastic has to be done on a fume hood, so that all the released gases are extracted and not inhaled by the user. Once the plastic has turned from white to a translucent appearance at approximately 240° Celsius degrees (depends on the technique used for heating the liquid vinyl), caramel colorant is added while keeping the stirring motion. The amount of colorant that has to be added depends on the desired opacity and colour.

When all the added colorant has been homogeneously mixed with the super soft liquid vinyl, the mixture is poured on the breast mold while it is tilted to different angles and describing a circular motion so that the mixture covers all the surface of the container. This has to be done until the plastic acquires a viscous consistency and it does not settle at the bottom of the mold.

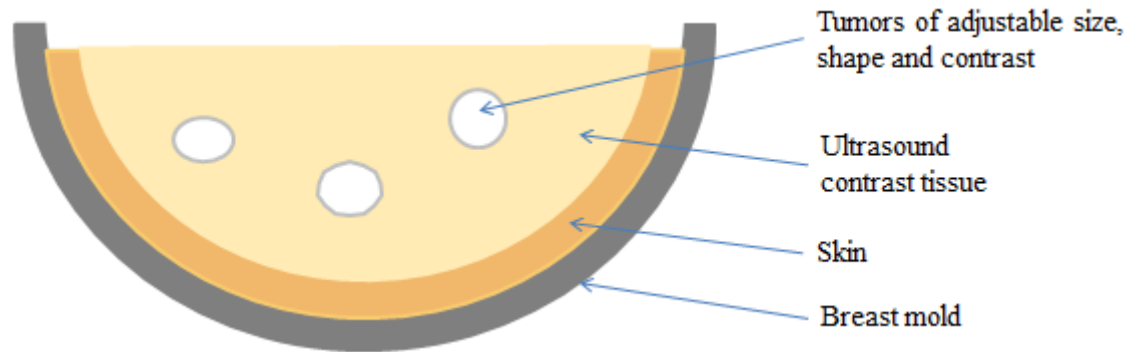
It must be taken into account that the liquid vinyl solidifies very quickly (in less than one minute), and complete coverage of the walls of the mold must be achieved in a short time while getting a smooth inner skin surface. This is important since later on, the ultrasound contrast tissue will be poured over it and when solidifying, some bubbles could appear in the interface between this component and the skin, causing partial reflection of the ultrasound waves.

### *TUMORS OR LESIONS*

The basic tumor composition consists on super soft liquid vinyl with calcium sulfate for X-ray contrast and cellulose for ultrasound contrast. Different ratios between the materials used to manufacture the tumors have been evaluated during the experiments in the following section in order to determine the optimal combination.

### ULTRASOUND CONTRAST TISSUE

This is the part of the phantom that will mimic the glandular/adipose tissue. The materials used are super soft liquid vinyl, plastic softener and cellulose powder. The best ratio between these three components has been determined experimentally and the process followed to determine it, is explained in the next section.



**Fig. 9.** Schematic representation of the main parts in a manufactured breast phantom.

### 3.1.3. EXPERIMENTAL WORKFLOW

In order to obtain the most optimal balance between super soft liquid vinyl, softener and cellulose for the ultrasound contrast tissue, as well as the most suitable amount of calcium sulfate and cellulose for the fabrication of the tumors, several experiments were performed.

#### PRELIMINARY TESTING: FIRST BREAST PHANTOM

Preliminary testing was performed with the objective of familiarizing with the building process and the characteristics of the materials, allowing us to get experience and correct for mistakes during the manufacturing procedure.

Several tests were performed to determine the optimal heating technique for the particular liquid vinyl used in this project. These tests were also helpful in order to determine the adequate time for heating the plastic as well as the most suitable steps to take when increasing progressively the temperature.

In this way, it was found that the plastic cannot be heated very quickly and instead, it should be done slowly increasing the temperature as it may get burnt acquiring a yellow tone. The moment in which the liquid vinyl has been sufficiently heated can be deduced when it acquires a translucent look and a watery consistency.

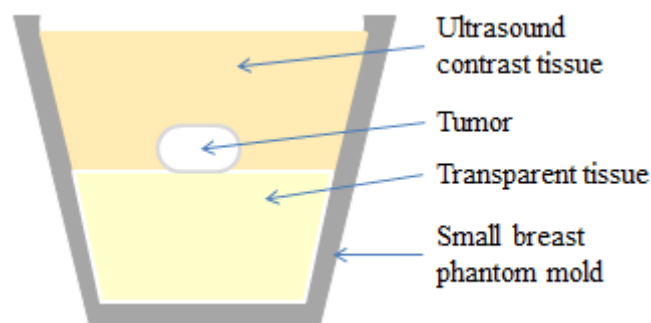
The materials used during the testing procedure were useful for building the first breast phantom, i.e. with skin, ultrasound contrast tissue, transparent tissue and tumor. The transparent tissue was manufactured with the same materials as the ultrasound contrast tissue except for the cellulose, which is the one providing contrast. This layer was poured into the breast phantom mold after the lesions were embedded in the ultrasound contrast tissue.

This first breast phantom was also helpful to determine that the use of wooden sticks as stirring method is not beneficial for the manufacturing of phantoms. This way of stirring the plastic introduces a lot of air, producing bubbles which reflect the sound waves, hence appearing very bright and affecting the ultrasound image contrast. Instead, the magnetic stirrer was proved to stir the plastic more homogeneously therefore introducing less bubbles.

#### *EXPERIMENT 1: OPTIMAL CONSISTENCY DETERMINATION*

In this experiment, two pairs of phantoms with different composition were made in order to find the most appropriate consistency. This was achieved by varying the proportions of liquid vinyl and softener in the ultrasound contrast tissue, main components of the bulk of the phantom.

In **Fig.10** it can be observed the main parts of the small phantoms that were built in this first experiment. They were manufactured without skin because for this part of the workflow the objective is to study and evaluate the properties of the bulk of the phantom, i.e. the ultrasound contrast tissue, and in these terms, the skin has no influence.



**Fig. 10.** Schematic representation of the small breast phantoms in the mold.

Two different ratios of liquid vinyl and softener were evaluated in this experiment. For this purpose, two phantoms were manufactured for each of the two ratios under study. For the posterior analysis, the average of each pair of phantoms was computed for a more reliable evaluation.

The difference between each pair of phantoms relies on the ultrasound contrast tissue since the embedded tumors present the same composition. Therefore, the explanation on how the tumor models have been obtained is common for both pairs of phantoms in experiment 1 and also for the two pair of phantoms of experiment 2:

- Tumor building process: a big sample of tumor was manufactured in order to have enough for further experiments, since the characteristics of the material used allow cutting it in different shapes and sizes. 250 ml of super soft liquid vinyl were initially heated until approximately 245 °C. Once the watery consistency was achieved, 4 tsp of calcium sulfate were added in order to make the tumors visible targets in CT imaging. Half a tsp of cellulose was also added so that the lesions can give contrast as well in ultrasound imaging. These two powders are not very soluble in the plastic so it is very important to stir very well in order to achieve the most uniform distribution as possible.

The small breast phantom mold used was calculated to have a volume of 66 ml therefore, all measurements and percentages indicated to define the composition of each part, are referred to this volume. The composition of the two pair of manufactured phantoms in this stage of the experimental workflow is explained below:

#### Phantoms 1 and 2

Each phantom is composed of transparent tissue, ultrasound contrast tissue and a tumor placed in the interface between both tissue layers. In this case, the ratio between plastic and softener was set to 75% super soft liquid vinyl and 25% softener for both, the transparent and the US contrast tissue.

Since the whole mold has a volume of 66 ml and there are two main tissues, each one is going to occupy 33 ml. When measuring the volume of the selected mold, it has to be taken into account that a tumor mass with a certain volume will be later introduced. Therefore, with the percentage indicated above, as they are the same for both tissues and the total volume for each one is also the same (33 ml), the volume needed of each component will be 24.75 ml of super soft liquid vinyl and 8.25 ml of softener.



Apart from this, we have to be able to differentiate the ultrasound contrast tissue in the images, therefore cellulose has to be added. The quantity of cellulose needed has been calculated taken as reference the amount used in the recipe. In here for every 200 ml of plastic (super soft liquid vinyl and softener), half a table spoon (tsp) of cellulose was used. With the help of the balance and considering that the table spoon is the size of a spatula from the laboratory, it was approximately obtained that half a tsp corresponds to 0.5 g.

Therefore, since half a tsp was used in 200 ml, it is needed 0.0825 of a tsp for 33 ml. Taking as reference the 0.5 g of cellulose in half a tsp, 0.0825 tsp will correspond to approximately 0.08 g of cellulose per 33 ml of plastic. In preliminary tests it was proved that this quantity of cellulose produced very bright ultrasound images, hence smaller concentrations of cellulose were chosen during the experimental workflow.

In order to prepare the mixture, 99 ml of super soft liquid vinyl and 33 ml of plastic softener were poured into a measuring cup. These quantities come from:

- Super soft liquid vinyl: (24.75 ml for the transparent tissue + 24.75 ml for ultrasound contrast tissue) \* 2 (since two phantoms of equal composition were built at the same time) = 99 ml.
- Plastic softener: (8.25 ml + 8.25 ml) \* 2 = 33 ml.

Therefore, a total volume of 132 ml (99 ml + 33 ml) were placed in the hot plate and heated until a watery consistency was obtained. When the mixture was ready, two small breast phantom ceramic molds were filled to half of their volume. This first layer of plastic corresponds to the transparent tissue, as it can be seen in **Fig. 10**.

After this, approximately 66 ml of plastic were left in the measuring cup, which corresponds to 33 ml of ultrasound contrast tissue per mold. It is important to keep heating the remaining volume to avoid solidification and keep the watery consistency. To this mixture, 0.04 g of cellulose were added.

Once the cellulose was homogeneously blended with the plastic, a small tumor was placed on top of the transparent tissue, which by the time the ultrasound contrast tissue was prepared, it would be almost solid. After placing the lesion, the remaining 66 ml of plastic with cellulose left in the measuring cup were poured into each of the two molds, therefore forming the last layer of the small breast phantoms, i.e. the ultrasound contrast tissue.

### Phantoms 3 and 4

In this case, the amount of softener was increased changing in this way the consistency of the phantom. Now the ratio for both, transparent tissue and ultrasound contrast tissue is 65% super soft liquid vinyl and 35 % of plastic softener.

Similar molds with a volume of 66 ml were used. Therefore, each tissue in the phantom had a total capacity of 33 ml again. Taking into account the percentages indicated above, 21.45 ml of super soft liquid vinyl and 11.55 ml of plastic softener were needed per 33 ml, meaning that these quantities were the ones needed for each tissue.

Two phantoms were manufactured simultaneously. Therefore, in order to know the amount of material that had to be poured in the measuring cup, the final volume was multiplied by 2:

- Super soft liquid vinyl: (21.45 ml for transparent tissue + 21.45 ml for US contrast tissue) \* 2 phantoms = 85.8 ml. This quantity is rounded to 86 ml to make it easier in terms of measuring the amount of liquid vinyl.
- Plastic softener: (11.55 ml + 11.55 ml) \* 2 = 46.2 ml. This volume is rounded to 46 ml for the same reasons as the liquid vinyl.

The calculated rounded measurements, 86 ml and 46 ml were added to the measuring cup giving a total volume of 132 ml. The process was repeated, the mixture was heated up in the hot plate while it was being permanently stirred until it acquired a translucent look and bubbles were not visible in the mixture. Then, half of this volume (66 ml) was poured into each breast phantom mold until the mixture reached approximately half of each mold.

As the main objective of experiment 1 is focused on the rigidity and consistency of the breast phantom, the amount of cellulose used for the ultrasound contrast tissue in both pair of phantoms was kept the same, at 0.04 g / 66ml. Therefore, the same amount of cellulose used before, 0.04 g, was added to the remaining 66 ml of heated plastic in the measuring cup obtaining in this way the ultrasound contrast tissue.

Finally, before pouring this mixture into the mold, a tumor was placed on top of the transparent tissue as it had previously been done, and the mixture in the measuring cup was poured until filling completely the mold.

## *EXPERIMENT 2: OPTIMAL CONTRAST DETERMINATION*

This second experiment was performed in order to determine the amount of cellulose required to generate the desired contrast when acquiring the US images. With this purpose, again two pairs of phantoms were built each one with different cellulose concentration but keeping the same proportion of liquid vinyl and plastic softener in both compositions: 65% super soft liquid vinyl and 35 % plastic softener.

These two new pairs of phantoms were manufactured without transparent tissue. Therefore, the total mold volume (66 ml) is occupied just by the ultrasound contrast tissue. The material used to simulate the lesions or tumors was taken from the manufactured sample in experiment 1.

### Phantoms 5 and 6

The objective with these two phantoms is to evaluate the influence of cellulose in the ultrasound imaging contrast of the phantoms.

Hence, the composition for each of them consists of 43 ml of super soft liquid vinyl and 23 ml of plastic softener; no cellulose is added.

The process was repeated; the 132 ml of plastic (66 ml x 2) were poured into the measuring cup and heated in the hot plate with magnetic stirring. Finally, half of the heated translucent volume of plastic was poured into each mold. Once the mixture in the mold was partially solidified, a tumor was introduced and the rest of the plastic left in the measuring cup was poured into the phantom mold.

### Phantoms 7 and 8

This second pair of phantoms was also composed of 43 ml of liquid vinyl and 23 ml of softener. In this case, cellulose was added with a concentration of 0.08 g in 132 ml, which is the same as 0.04 g / 66 ml. Once the mixture was ready to be poured into the mold and after waiting a few minutes, a small tumor was introduced.

*EXPERIMENT 3: DETERMINATION OF THE MOST ADEQUATE TUMOR COMPOSITION*

The objective of this third experiment is to determine the optimal balance between calcium sulfate and cellulose in order to obtain the most adequate composition for the lesions inside the phantom.

Three different tumor compositions were tested:

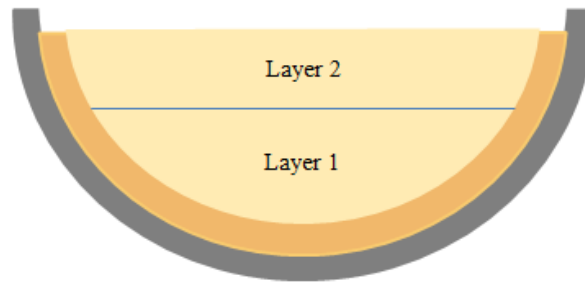
- Tumor without cellulose: this is composed of 125 ml of super soft liquid vinyl (this volume has been chosen according to the amount of tumor material that was estimated to be needed considering also further experiments) and 2 tsp of calcium sulfate for CT contrast. Cellulose was not added.
- Tumor with low cellulose concentration: 125 ml of super soft liquid vinyl, 2 tsp of calcium sulfate and 0.2 g of cellulose. The amount of cellulose has been derived according to the proportions used initially in the first CT visible target (tumor) fabricated.

The relation between cellulose and volume of plastic used in the recipe taken as initial reference is of half a tsp of cellulose (which as previously said, is equivalent to 0.5 g) in 250 ml of plastic, therefore for 100 ml the corresponding amount of cellulose is 0.2 g.

Then, the reference for the measurements is 0.2 g of cellulose per 100 ml of plastic. As the objective is to manufacture this tumor to give normal contrast, the proportion set as standard was considered to be a bit high, since the quantities established in the recipe made tumors appear very bright in the ultrasound images. Therefore, the ratio for this tumor composition was decreased to 0.16 g of cellulose per 100 ml of plastic which corresponds to 0.2 g in 125 ml.

- Tumor with high cellulose concentration: the composition used here is the same as in the first experiment which was 0.2 g of cellulose per 100 ml. In terms of the same volume of plastic as the other two types of tumor compositions, it would correspond to 0.25 g of cellulose per 125 ml of plastic, which implies a small but noticeable increase in contrast.

In order to evaluate how each tumor type was seen in ultrasound imaging, they were embedded into a phantom. This new breast phantom, which is referred to as phantom 9 in **Table 1** at the end of this chapter and in the results and discussion section, was manufactured with two layers in which tumors with different size, shape and composition were distributed.



**Fig. 11.** Schematic representation of the layer distribution in the breast phantom manufactured for the third experiment.

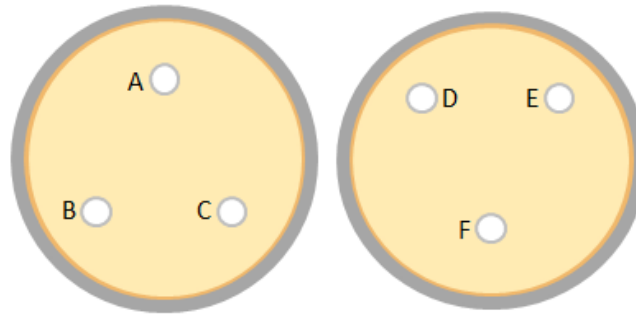
The fabrication process for this phantom is as follows: first, the skin was manufactured and placed in the mold, then the bulk of the phantom, where the different tumors were embedded, was built with super soft liquid vinyl, plastic softener and cellulose, i.e. it is ultrasound contrast tissue.

For this phantom, it was desired to increase the amount of cellulose so that the contrast of the background in the ultrasound images was more similar to the commercial phantom. Therefore, if previously 0.04 g of cellulose were used in 66 ml for ultrasound contrast tissue, in 100 ml (considering this volume as the reference) there would be 0.06 gr of cellulose. Hence, in order to slightly increase the contrast in ultrasound imaging, the amount of cellulose in this new phantom was changed to 0.08 gr per 100 ml.

The phantom is composed of 65% of super soft liquid vinyl and 35% of plastic softener. Moreover, cellulose concentration of 0.08 g per 100 ml was used.

The mold for the big breast phantom has a volume capacity of 450 ml, which indicates the total amount of ultrasound contrast tissue that needs to be manufactured. According to the ratio indicated above, 293 ml of liquid vinyl and 157 ml of softener were used. The amount of cellulose added was 0.36 g for the 450 ml.

The method followed to pour the heated 450 ml of plastic with cellulose was layer by layer. The main objective was to distribute the tumors of different composition in separate layers so that they were in different depths with respect to the ultrasound waves emitted from the probe (**Fig.11** and **Fig.12**).



**Fig. 12.** Top view of the two layers in the phantom. At the left is layer 1: (A) tumor with low cellulose quantity, (B) tumor without cellulose, (C) tumor with high quantity of cellulose. The sketch at the right corresponds to layer 2: (D) same concentration of cellulose as C, (E) same composition as B and (F) same composition as A.

#### *EXPERIMENT 4: FINAL BREAST PHANTOM WITH OPTIMIZED FORMULA*

The last phantom manufactured in this project was done gathering all the characteristics determined during the experimental workflow as the optimal ones for ultrasound contrast tissue and also for the tumors or CT visible targets inside. This breast phantom is called phantom 10 in **Table 1** and also in the results and discussion chapter.

The main parts of this final breast phantom are the skin, the ultrasound contrast tissue and the lesions inside; its final appearance is schematically represented in **Fig. 9**. The process followed in the fabrication of each component is similar to the one described in previous experiments:

- Skin: 50 ml of super soft liquid vinyl were used. Once this volume was heated until it acquired a watery consistency, drops of caramel colorant were added.
- Ultrasound contrast tissue: the ratio of liquid vinyl and softener used is 65 % super soft liquid vinyl and 35 % plastic softener. Taking into account the mold volume capacity (450 ml), the amount of required material is 293 ml and 157 ml respectively.

In order to compute the amount of cellulose that had to be added to the mixture, the standard of 0.08 g per 100 ml previously determined is taken as reference. Hence, for 450 ml, 0.36 g of cellulose were needed to achieve the desired contrast.

Two different measuring cups were used for the preparation of the ultrasound contrast tissue; of the total 450 ml of mixture, 225 ml were poured in each measuring cup. This was done in order to allow the heat coming from the base to

distribute more evenly through the plastic volume and for the stirring motion to be more effective. When heat is not uniformly distributed, the top layers of mixture tend to present a very viscous consistency.

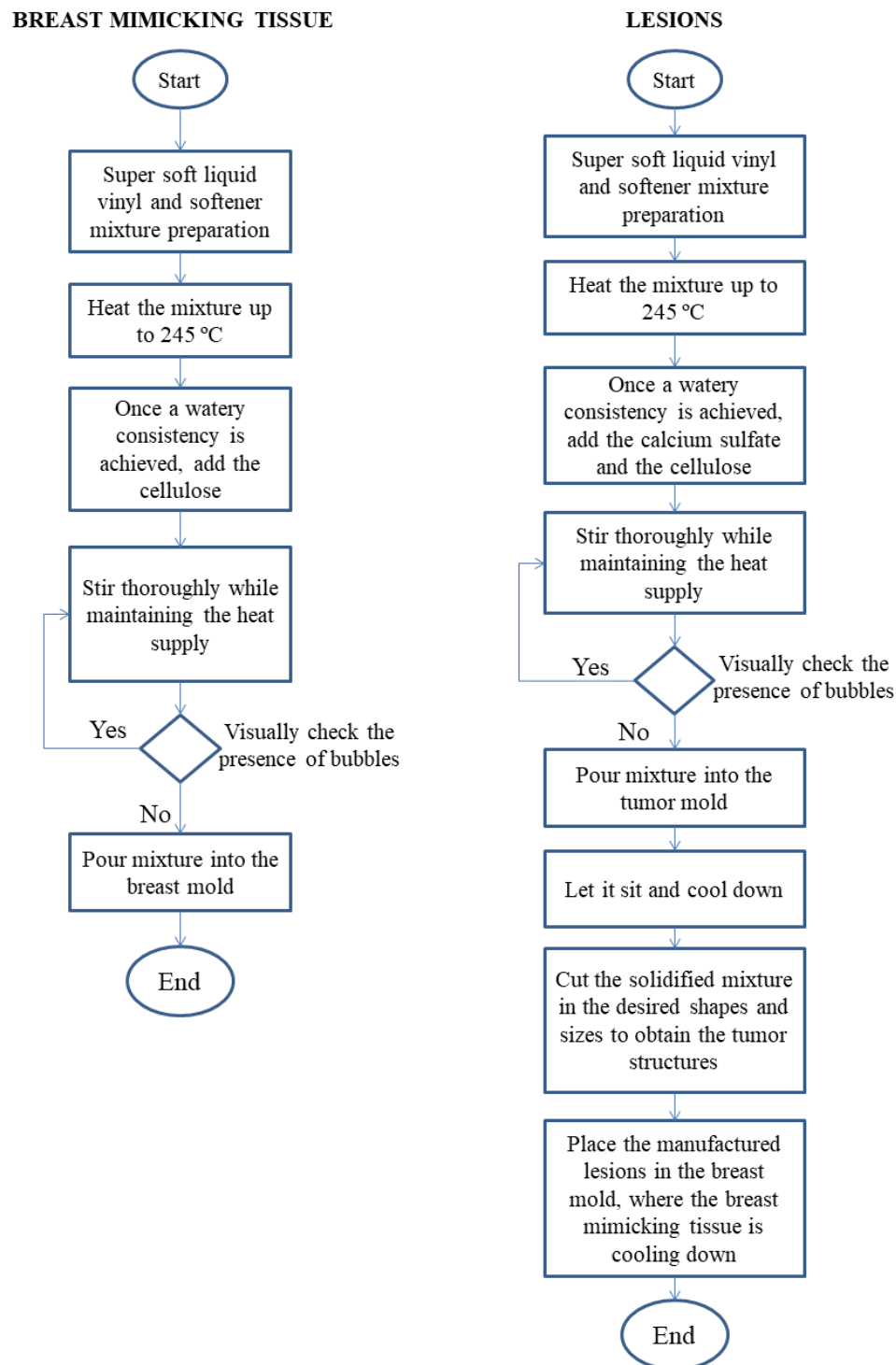
- Tumors: the material fabricated in experiment 3 was cut in different sizes and shapes in order to obtain three small tumors: two of them with high ultrasound contrast, i.e. high quantity of cellulose, and the third one with the lower cellulose quantity. These three lesions were placed in the breast phantom in known locations in order to make easier their identification when acquiring the ultrasound images.

In the table below, it can be observed the different percentages and proportions of materials used in each phantom during the experimental workflow:

	Ultrasound contrast tissue			Transparent tissue	
	Super soft liquid vinyl	Plastic softener	Cellulose	Super soft liquid vinyl	Plastic softener
Phantoms 1 & 2 (Experiment 1)	75 %	25 %	0.06 g / 100 ml	75 %	25 %
Phantoms 3 & 4 (Experiment 1)	65 %	35 %	0.06 g / 100 ml	65 %	35 %
Phantoms 5 & 6 (Experiment 2)	65 %	35 %	-	-	-
Phantoms 7 & 8 (Experiment 2)	65 %	35 %	0.06 g / 100 ml	-	-
Phantoms 9 & 10 (Experiments 3&4)	65 %	35 %	0.08 g / 100 ml	-	-

**Table 1.** Summary of the different compositions for the breast mimicking tissue in the manufactured phantoms.

In the diagram below (**Fig.13**), the manufacturing process followed for the lesions and for the breast mimicking tissue is summarized:



**Fig. 13.** Flowchart that summarizes the process for building breast phantoms.



### 3.2. BREAST PHANTOM VALIDATION

In order to determine the optimal breast phantom composition, US and CT image acquisition were performed on the phantoms manufactured on the different experiments. Moreover, an expert clinician evaluated the characteristics of the phantoms for their use in medical training. Finally, surgical navigation based on real-time tool tracking and US image-guidance was tested on the final breast phantom.

#### 3.2.1 ULTRASOUND IMAGES ACQUISITION

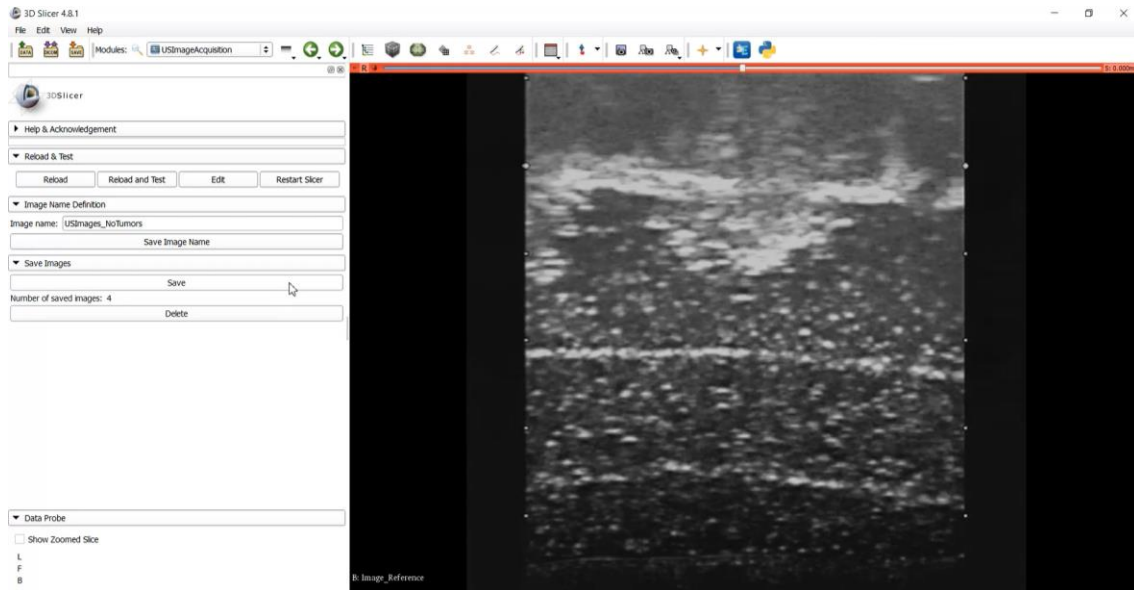
For the acquisition of US images, an ultrasound system, Hitachi EUB 8500 model with a L47M probe and depth of 50 mm was used. Moreover, a computer and a frame grabber device were needed to receive and store the images acquired by the ultrasound system. In terms of software, PLUS Toolkit and 3D Slicer open source applications were used for data collection and management.

The frame grabber is a converter which captures the ultrasound images from the video port of the ultrasound system and sends the images to the computer through a USB port. Images received by the frame grabber are collected by PLUS Toolkit, which contains the device specific SDK.

PLUS (Public software Library for Ultrasound) toolkit is an open-source software platform which provides several methods for tracking the position of interventional tools in general, and also for the acquisition of ultrasound images and the spatial and temporal calibration [21]. This software is able to interact and collect data from many different commercial ultrasound and tracking devices used in medical interventions. PLUS toolkit collects images and tracking information from devices, and sends the collected data using OpenIGTLink communication protocol.

Using this communication protocol, the collected data can be received in 3D Slicer, an open-source software platform that is used for three-dimensional visualization, image processing and medical image informatics [22].

For the purpose of validating the manufactured breast phantoms in this project, a 3D Slicer application for **ultrasound image acquisition** was developed (using Python programming language) with the aim of automatizing US images recording and to export them in a suitable format for posterior analysis (**Fig. 14**). The developed application is able to access the images received from the frame grabber and to export those images in .PNG format into the path selected by the user.



**Fig. 14.** Developed software application for the acquisition of US images. US image of the manufactured phantom is displayed on the right side of the screen.

The US images were acquired placing the ultrasound probe in close contact with the surface of the phantom. An ultrasound gel was used in-between the probe and the breast phantom in order to adjust impedances between the air and the phantom surface (skin), avoiding in this way the reflection of the sound waves before going deeper in the phantom.

Once the images were recorded, they were analysed using ImageJ which is an open source software for image processing and analysis based in Java programming language and developed by the National Institute of Health (NIH) [23].

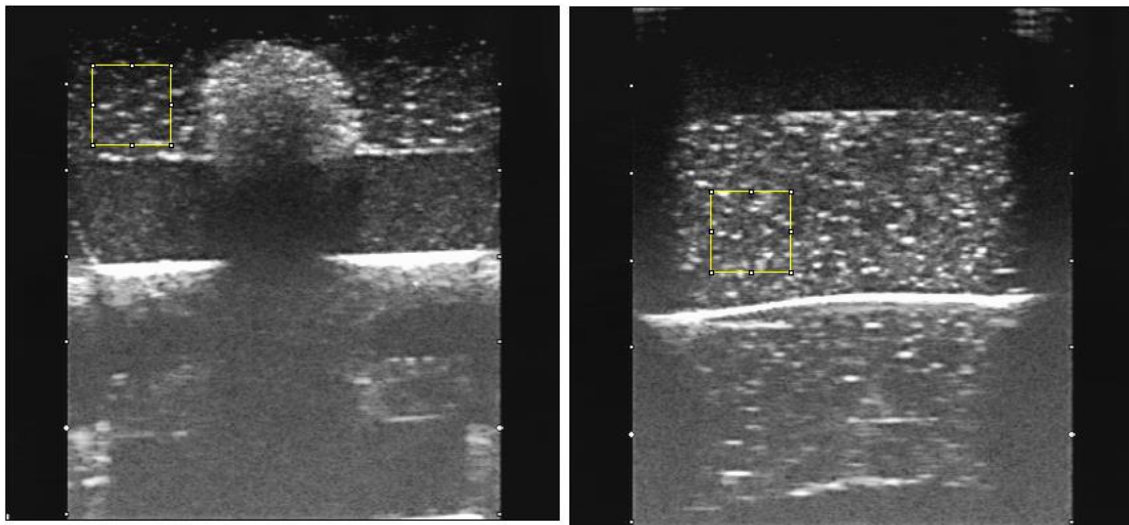
For the analysis, ROI Manager tool from ImageJ was used. It allowed the selection of the same area, in terms of size and shape, in a stack of images. Once the selection area was placed on the region of the image that wanted to be analysed, statistics (mean, standard deviation and median values) of the pixels within the region could be computed and exported into a .CSV file.

Due to the speckle appearance of the ultrasound contrast tissue with bright spots spread over a darker background, the mean and the median were measured in order to have more information about the same selected area.

Choosing only the mean as the variable to determine the optimal composition of ultrasound contrast tissue is not the most accurate method to follow, since it is affected

by outliers. On the other hand, the median is suitable for skewed distributions in order to derive a central tendency, therefore in case that the intensity distribution in the selected area is not symmetrical, considering the mean and the median values help with choosing the most appropriate composition.

The standard deviation in the selected area is also taken into account. It provides information about how concentrated around the mean is the data or, in other words, how different are the intensity pixel values between them. If the obtained value is high, it means that the data set is very spread and there is a big difference between the intensity values of the pixels in the selected area, whereas if the value is small, it would mean that the data is more concentrated around the mean of the sample. In terms of ultrasound image analysis, the standard deviation provides additional information about the texture; it has to be taken into account that the mean is used to obtain the standard deviation, therefore it is affected as well by outliers.

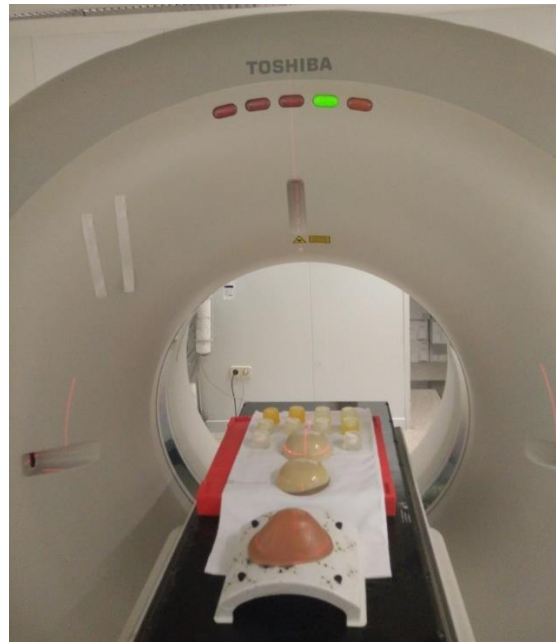


**Fig. 15.** Ultrasound images from different slices of phantom 1 from experiment 1. In both images it can be observed the yellow selection area of the same size and shape which is used, in this case, to obtain data from the ultrasound contrast tissue. The bright horizontal line corresponds to the table above which the phantom was resting on when acquiring the images. It appears due to the depth parameter of the ultrasound system. In the left image it can be observed a tumor placed on the interface between both tissues.

### 3.2.2. CT IMAGES ACQUISITION

**CT images** from the built phantoms were also obtained in order to assess the X-ray contrast of the tumors introduced, which is given by the calcium sulfate used during the manufacturing process of the lesions.

A Toshiba Aquilion CT scanner from the Oncology department in Hospital General Universitario Gregorio Marañón (HGUGM) in Madrid was used for the image acquisition process of the manufactured phantoms (**Fig. 16**). A predefined CT acquisition protocol for breast imaging was used for the acquisition. Acquired CT images were exported for analysis in DICOM image format.



**Fig. 16.** Setup of the CT image acquisition process of the manufactured phantoms and the commercial phantom.

### 3.2.3. EVALUATION BY EXPERT CLINICIAN

The constructed breast phantoms were evaluated by an expert radiologist from Hospital General Universitario Gregorio Marañón.

The expert evaluated the physical characteristics of the phantoms (consistency, size and shape). In addition, the radiologist performed several ultrasound-guided needle insertions. Finally, biopsies were performed on the phantoms using a breast biopsy gun to evaluate the feasibility of this procedure on the manufactured phantoms.

### 3.2.4. TESTING SURGICAL NAVIGATION

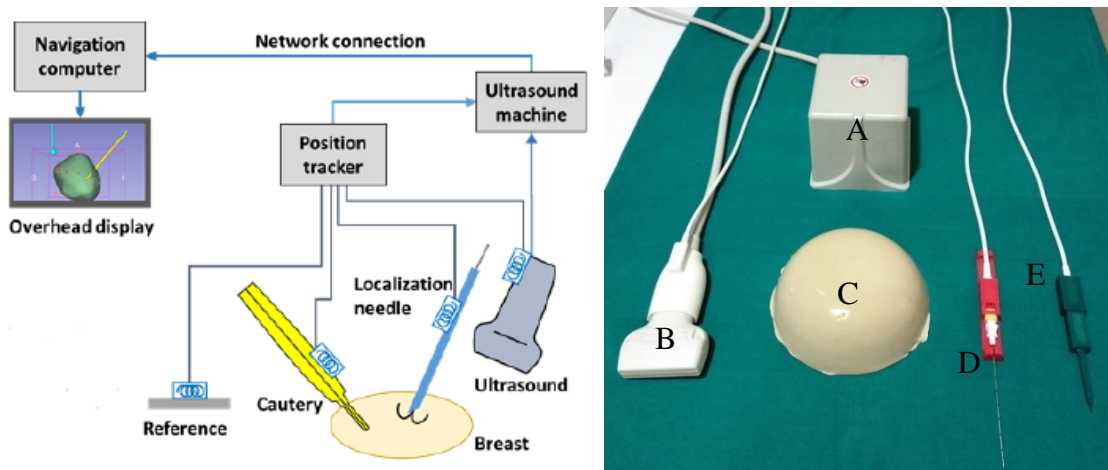
Final breast phantom was posteriorly tested in order to see its suitability for ultrasound-guided needle insertion for tumor localization and also, to validate its use as a surgical navigation training tool.

In order to take this to practice, the same connections explained before using the PLUS Server application, 3D Slicer and OpenIGTLink were established.

Regarding ultrasound imaging, a frame grabber device was used to collect US images from the ultrasound system and to send them to the computer. Then, they were transmitted to the 3D Slicer platform using PLUS toolkit.

For the real-time tracking of the surgical tools and ultrasound probe, an Ascension TrakStar electromagnetic tracking system was used. This system is based on a field generator which generates a spatially varying magnetic field. Then, the position and orientations of sensors (containing coils) can be computed by measuring the magnetic field. Three of these sensors were used to track the position of the ultrasound probe, localization needle and cautery (stylus), (**Fig. 17**). The tracking information provided by this system is collected using PLUS toolkit and sent to the 3D Slicer application using OpenIGTLink communication protocol.

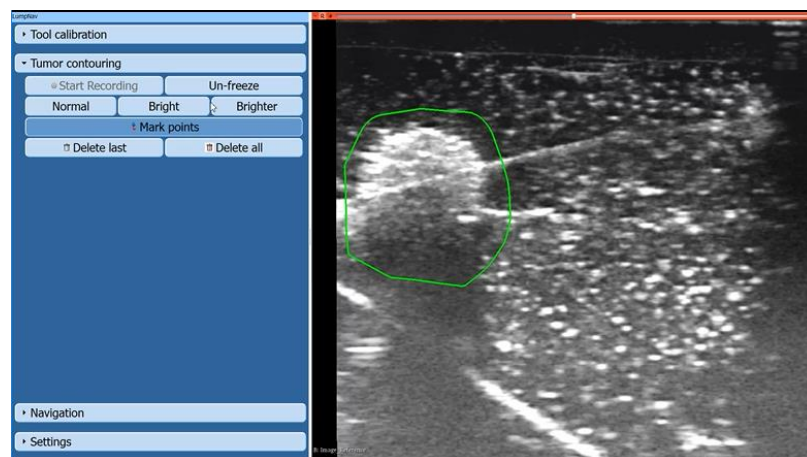
PLUS toolkit library is in charge of synchronizing the data collected at real time from the ultrasound probe and the tracker, as well as for the temporal and spatial calibration [7].



**Fig. 17.** The image at the left shows a schematic representation of the navigation setup, from [7] . The image at the right shows the real instruments used: (A) is the reference, which generates the electromagnetic field; (B) the ultrasound probe with its position tracker sensor at the upper end; (C) manufactured breast phantom (phantom 10); (D) needle for tumor localization; (E) stylus that simulates the cautery.

The steps followed in order to perform the validation through surgical navigation are the following:

1. Calibration of the surgical instruments used in the navigation which are the needle and the stylus that simulates a cautery. This calibration is needed in order to calculate the offset between the tool tip with respect to the electromagnetic sensor attached on the tool.
2. Needle insertion in the tumor with US image guidance. US probe is moved over the skin surface until a lesion is localized. Once it is localized, the needle is inserted following the ultrasound image plane until it is observed that the needle traverses the tumor.
3. Tumor contouring: over the US image of the localized lesion displayed on the navigation computer, several points are marked surrounding it and leaving a few millimetres of distance between the marked area and the tumor in the image so that positive margins are prevented (**Fig. 18**). These points have to be selected in US images obtained from transversal planes in order to create the 3D model of the tumor. Once the tumor has been contoured in these orthogonal US images, a final scan over the lesion area should be performed by the operator. This must be done with the objective of checking that the whole tumor mass is surrounded by the generated 3D model and that the desired margins have been well established.



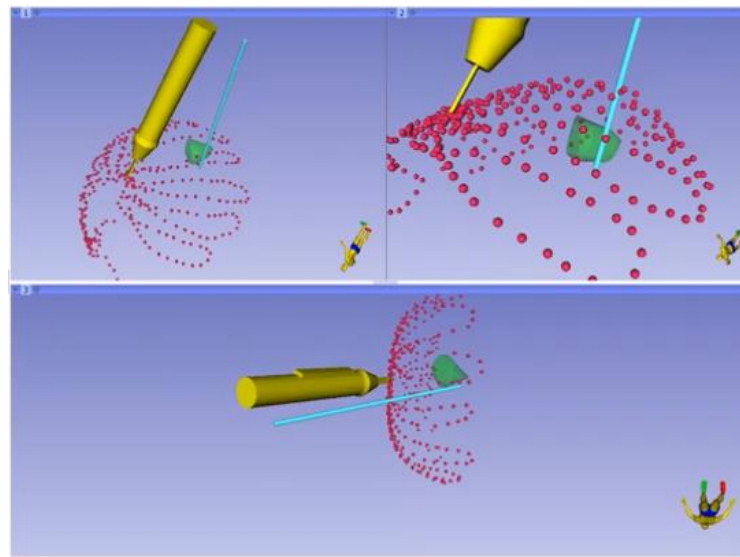
**Fig. 18.** Tumor contouring in the final manufactured phantom (phantom 10).

At the same time that the tumor boundary points are selected by the practitioner, they are saved in the coordinate system of the needle [7], therefore both the tumor model and the tip of the needle are related. In this way, the frequent tumor motions



in the breast tissue are compensated since the needle tip position is tracked in real-time using the electromagnetic tracking system.

With the purpose of improving spatial orientation, the skin surface of the breast phantom was modelled by recording points along the surface using the stylus tool (**Fig. 19**). From this point cloud, an approximated 3D model can be generated and included in the surgical navigation view. Therefore, skin and tumor 3D models are displayed with respect to the position of surgical tools.



**Fig. 19.** Breast phantom shape modelling. The tumor is represented by the green model, and the surface model of the phantom is built from the red points taken with the stylus, which is the yellow object model.

4. Navigation of the cautery to the tumor. Once the tools are calibrated and the tumor model has been created, the navigation software displays the distance in real time from the cautery tip (stylus tip) to the tumor surface. This was done during the excision of the tumor. If the cautery tip traverses the predefined tumor margins, a visual and acoustic feedback is given to the user so that tool position can be corrected.

## 4. RESULTS AND DISCUSSION

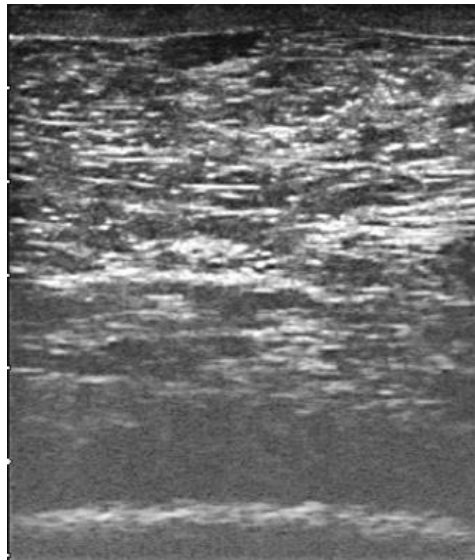
In this bachelor thesis, different processes have been followed in order to accomplish the objectives initially proposed. The collected data along the project has been analysed and the results obtained with the corresponding interpretation and discussion, are presented in this chapter. This ultimately will lead to the final conclusions exposed in the next chapter.

### 4.1. ULTRASOUND IMAGES

This section is divided in the four experiments explained in the methods chapter. From each step of the experimental workflow, some results have been obtained and are represented in the form of three graphs (mean, median and standard deviation).

These experiments allowed reaching the optimal formula in terms of consistency and contrast that was being pursued for the final phantom in order to resemble the commercial one, chosen as gold-standard. Results from the optimal tumor composition have been also obtained.

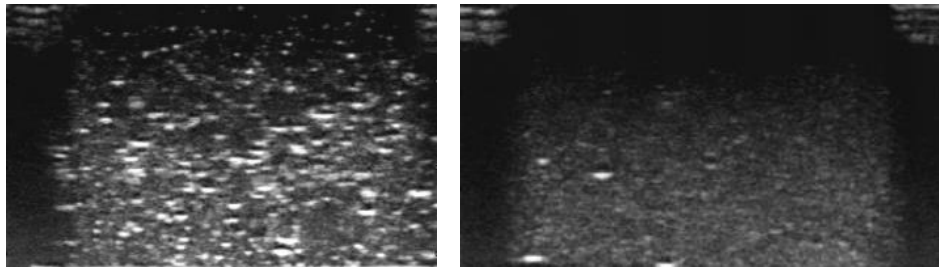
As it was previously explained in the methods chapter, several ultrasound images have been obtained for each manufactured phantom. In **Fig. 20** it is shown one of the several ultrasound images taken from the commercial phantom and from which data was collected to obtain the values taken as gold standard.



**Fig. 20.** Ultrasound image from the commercial phantom showing breast mimicking tissue.



To illustrate some of the images used to obtain the presented results, a sample of the ultrasound images acquired from the manufactured breast phantoms are shown in the next figure (**Fig. 21**). The left image presents ultrasound contrast due to the cellulose added. This does not happen in the right image since no cellulose was added to the phantom. The few bright spots that can be observed in this picture are due to the presence of bubbles, which produce a high reflection of the ultrasound waves.



**Fig. 21.** Ultrasound images from manufactured breast phantoms with cellulose (left) and without cellulose (right). The image on the left corresponds to phantom 7 and the image on the right, to phantom 5.

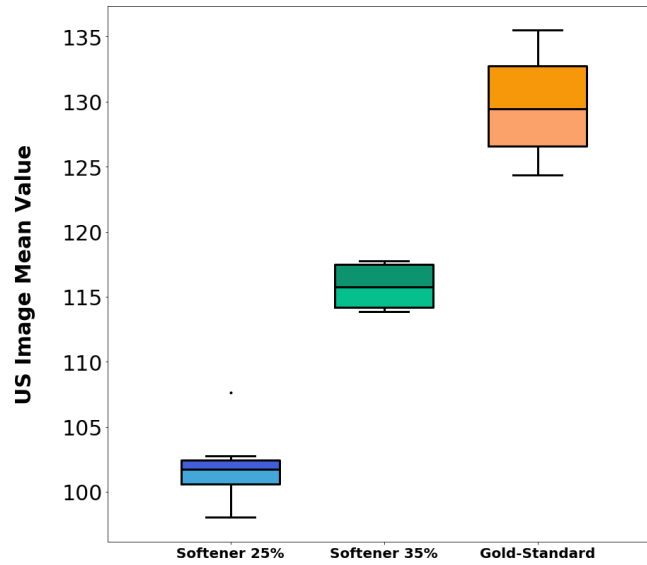
#### 4.1.1. BREAST MIMICKING TISSUE ANALYSIS

Two main features are going to be analysed and discussed for the ultrasound contrast tissue. These features are consistency and contrast, and they determine the resemblance of the manufactured phantoms to breast tissue.

##### *CONSISTENCY*

The data collected from the ultrasound images analysis of the phantoms manufactured in experiment 1, has been used in this section in order to obtain the results showed in the form of graphs. The interpretation and discussion of these graphs have allowed us to determine the most appropriate consistency. Three different metrics were computed from the ultrasound images and used in the analysis: mean, median and standard deviation.

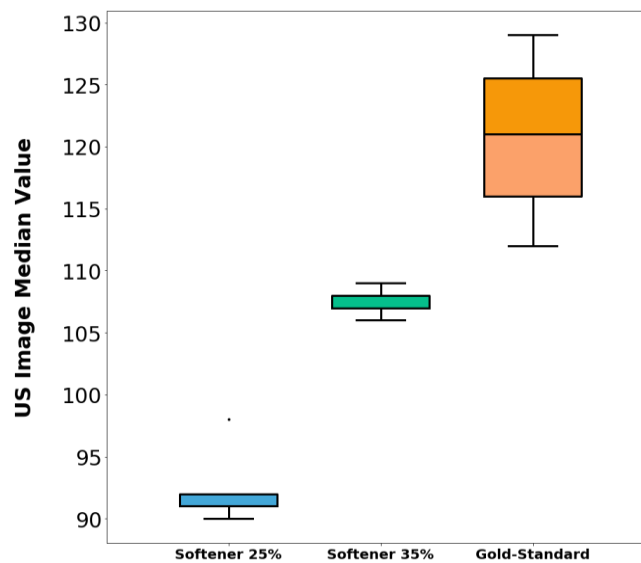
Starting with the graph representing the mean values (**Fig. 22**) it can be observed that the composition that is closer to the gold standard is the one with 35 % softener and 65% liquid vinyl. Even though the gold-standard boxplot presents bigger variation, there is still a noticeable gap between the central mean value of both compositions.



**Fig. 22.** Boxplot with the mean values distribution for each ultrasound contrast tissue composition.

In order to obtain complementary information, it is necessary to look at the graph of the median values for a better interpretation of the results. This is because, as explained in the methods section, the mean variable is more affected by outliers in the sample whereas the median is more suitable for skewed distributions, therefore the combination of the results from both graphs will lead to a more reliable interpretation.

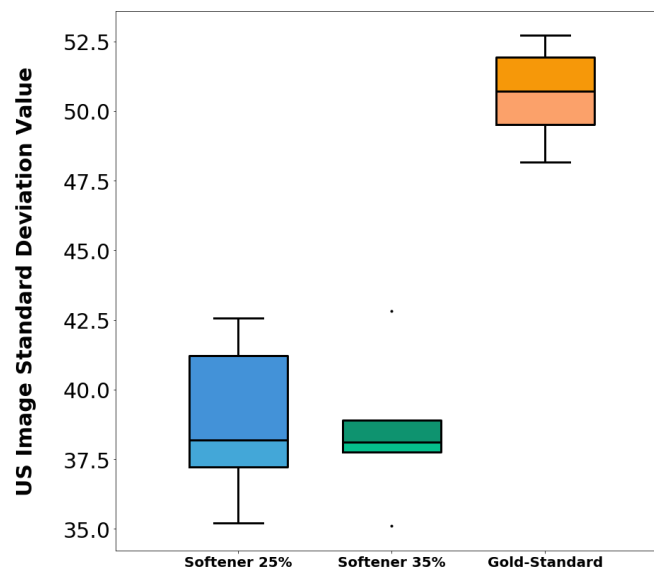
In this way, the boxplot for the median values (**Fig. 23**) demonstrates that a proportion of at least 35% of softener should be used in order to achieve a consistency similar to the gold-standard.



**Fig. 23.** Boxplot with the median values distribution for each ultrasound contrast tissue composition.

The decision of considering the 35% of softener as the optimal composition for the consistency was made not only taking into account the interpretation of the results shown in the graphs, but also considering the feedback provided by an expert clinician that evaluated the phantoms with the different compositions. This is further explained in section 4.3.

Finally, the results obtained for the standard deviation values are shown in **Fig. 24**. It can be observed the high value that the gold-standard presents compared to the other two compositions, which do not show a noticeable difference between them.



**Fig. 24.** Boxplot with the standard deviation values distribution for each ultrasound contrast tissue composition.

The evaluation of the standard deviation metric is not relevant for the assessment of the consistency of the phantoms, and it is more appropriate to evaluate the texture of the phantoms. This is why the standard deviation is more significant for the evaluation of the second feature: the contrast.

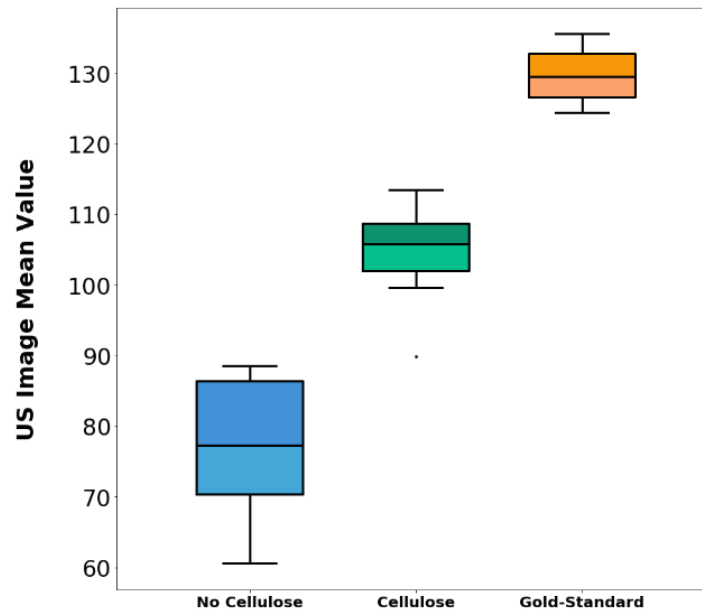
### CONTRAST

For this section, the results obtained from the image analysis of the manufactured phantoms in experiment 2, are interpreted and discussed in order to decide the optimal concentration of cellulose based on the image contrast.

In experiment 2, two different compositions for the ultrasound contrast tissue were studied. First, phantoms without any cellulose were manufactured. A low ultrasound contrast was expected. Also, phantoms with cellulose were fabricated; from them, increased ultrasound contrast was expected.

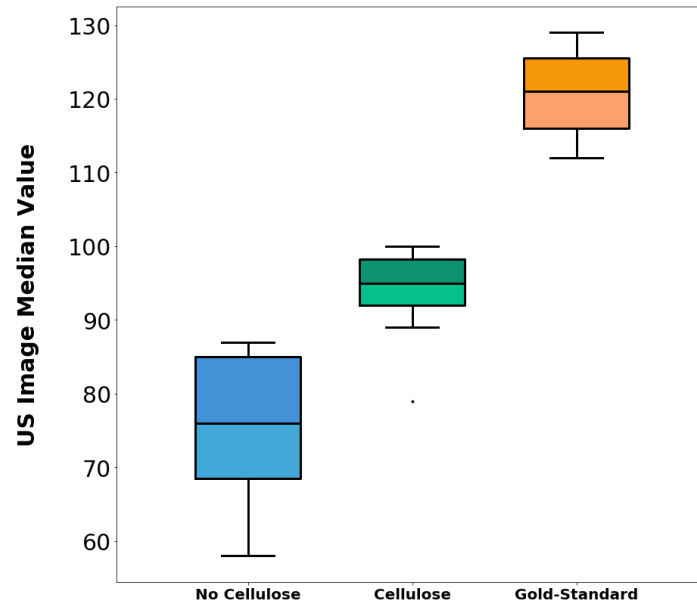
For the interpretation of these results it is useful to recall that cellulose adds to the ultrasound image a granulated effect which results from the high reflection of the ultrasound waves by the cellulose powder. This produces an increase in the amplitude of the echo received compared to the image background, appearing as bright spots of high intensity pixel value.

With all this in mind, looking at the results plotted in **Fig. 25**, it can be observed how the gold-standard presents the highest mean value; this is because the structure of the commercial phantom, as it can be appreciated in **Fig. 20**, is very heterogeneous and has fibres of different densities and compositions, resulting in many areas with high intensity values.



**Fig. 25.** Boxplot of the mean values measured from the manufactured phantoms in experiment 2.

As it was previously deduced, from the compositions of the manufactured phantoms, the most similar one to the gold standard is the composition with cellulose. This interpretation is reinforced by the median values results, shown in **Fig. 26**.

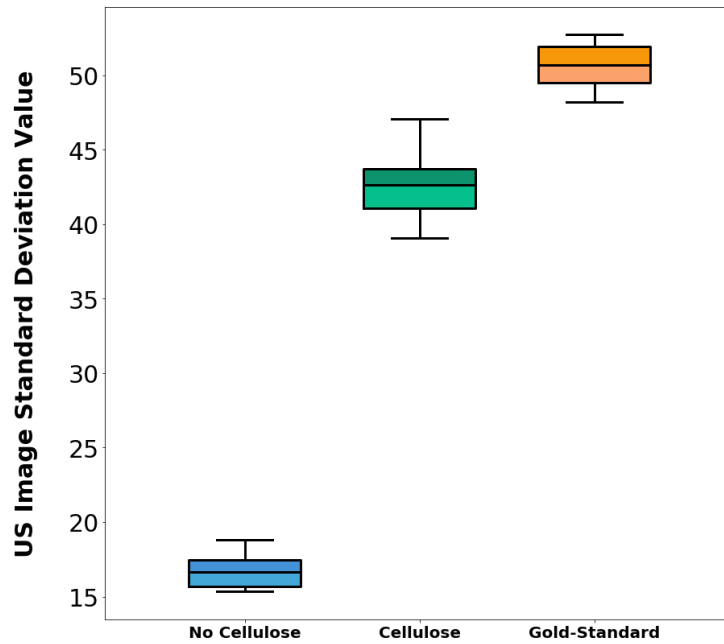


**Fig. 26.** Boxplot of the median values measured from the manufactured phantoms in experiment 2.

However, in both graphs **Fig 25** and **Fig. 26**, it can be observed that the mean and median values of the phantoms without cellulose are higher than expected. This may be due to the fact that magnetic stirring was not used during manufacturing and bubbles appear within the phantom, leading to dispersed bright spots in the ultrasound images.

Although the composition without cellulose shows abnormally high mean and median values, it is still the smallest one, showing the importance of adding cellulose in order to achieve an adequate contrast in the image (similar to the gold-standard).

Finally, the standard deviation results are represented in **Fig. 27**:



**Fig. 27.** Boxplot of the standard deviation values measured from the manufactured phantoms in experiment 2.

In the figure above, difference in standard deviation values between the phantoms' ultrasound contrast tissue with and without cellulose can be observed. High values are obtained for the phantoms containing cellulose as well as for the gold standard. On the other hand, a very low value of this variable is obtained for the samples without cellulose.

As previously said, the standard deviation measures how spread out is a set of values, or in other words, how heterogeneous is the data set being analysed. The high value of this variable for the commercial phantom is already known to be due to the heterogeneous inner composition with different fibres and other simulated tissues. This effect is achieved in the low-cost breast phantoms developed in this project by adding cellulose during the manufacturing process. This gives the phantoms a speckle appearance visible when acquiring ultrasound images, which resembles the heterogeneity present inside the more complex and expensive gold-standard phantom.

Therefore, after analysing the ultrasound images taken from the phantoms, the composition chosen as the most suitable for the ultrasound contrast tissue in terms of consistency, was 65% super soft liquid vinyl and 35 % plastic softener.

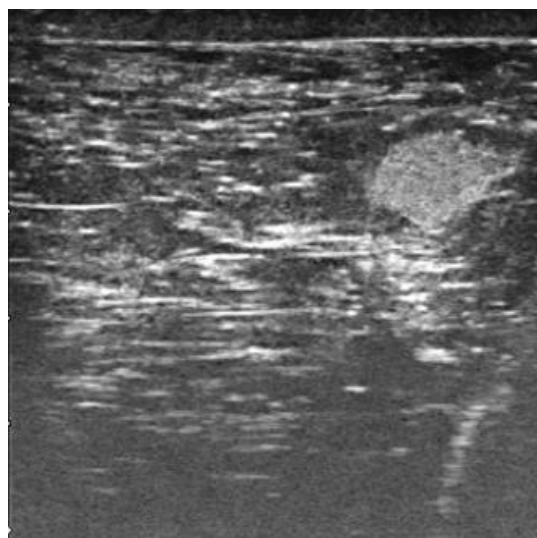Finally, in the case of the contrast, it was also observed that the composition which better resembles the gold standard needs to have cellulose added **at least** in a concentration of 0.06 gr/100 ml, which is the concentration used in experiment 2 for the composition with cellulose.

#### 4.1.2. TUMOR COMPOSITION ANALYSIS

The breast phantom manufactured in experiment 3 contains the three different tumor compositions analysed in this section. This is done with the purpose of determining which is the most appropriate composition for the better resemblance to the gold standard, but also taking into account the evaluation from an expert (section 4.3).

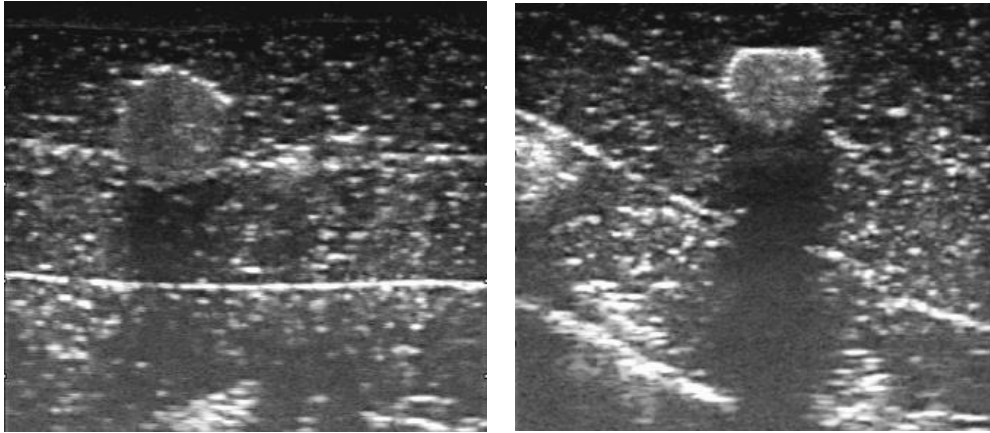
Although tumors with different echogenicity can be manufactured, this project is focused on resembling the hyperechoic lesions in the commercial phantom, which are the tumors that appear brighter than usual in the ultrasound images.

These ultrasound images were obtained from different slices containing the lesions introduced in the built phantom. As it was the case for the ultrasound contrast tissue in the previous section, in order to evaluate which is the most suitable tumor composition, the data collected from their analysis was compared to the results obtained from the lesions inside the commercial phantom (gold-standard). In **Fig. 28** it can be observed one of the ultrasound images taken from this reference phantom showing a tumor embedded in its structure and close to the surface.



**Fig. 28.** Ultrasound image from the commercial phantom showing a lesion (top right) surrounded by breast mimicking tissue.

In order to illustrate the source of the data in this section from which the results for the different tumor compositions come from, a sample of the images acquired is shown in the figure below.



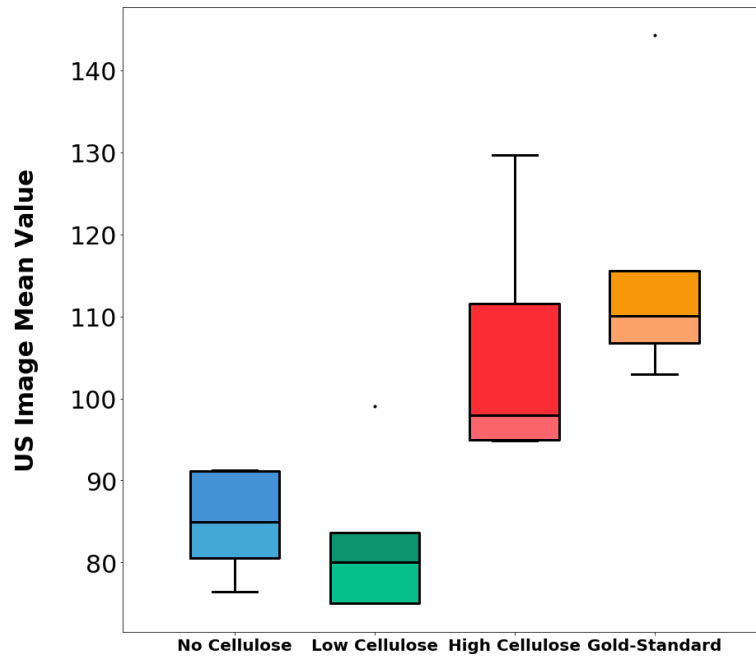
**Fig. 29.** Ultrasound images from the manufactured phantom in experiment 3 (phantom 9). The first image shows a tumor with low cellulose concentration placed in layer 1. The image at the right shows a high cellulose concentration tumor also in layer 1.

As it was previously done to analyse the ultrasound contrast tissue, three boxplots showing the results for the mean, median and standard deviation metrics were also obtained for the analysis of the tumor composition.

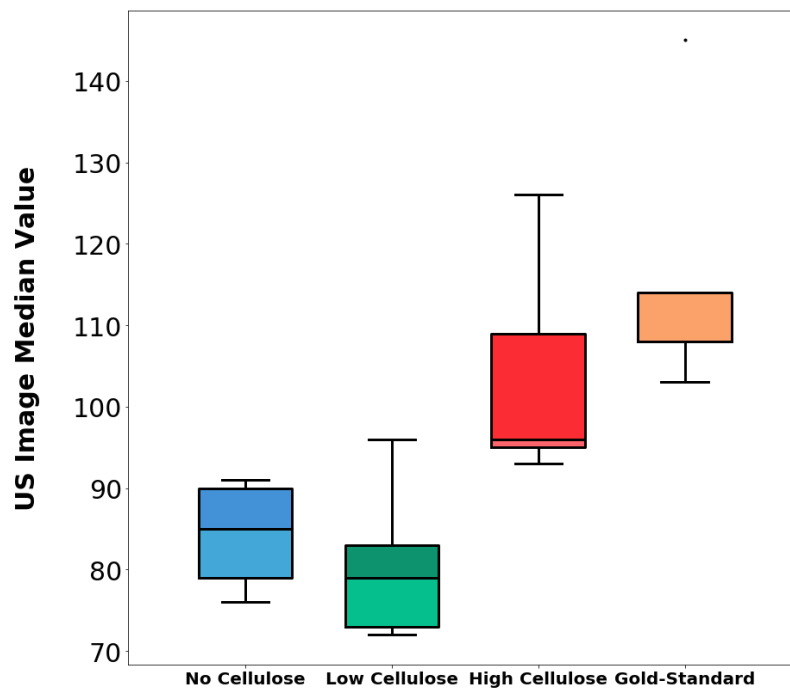
In **Fig. 30** and **Fig.31** it can be observed that the composition with the highest concentration of cellulose is the one that better resembles the gold standard. But in the case of the low cellulose concentration, it shows lower values for the mean and median than the composition without cellulose, which does not coincide with the expected results.

This small unexpected difference may be due to the bubbles that appeared in the surface of the lesion with low cellulose concentration during the manufacturing process. The high reflection of the ultrasound waves produced by these bubbles caused that the pixels in the inner area of the tumor, adopted lower intensity values in the ultrasound images than what it should correspond them.





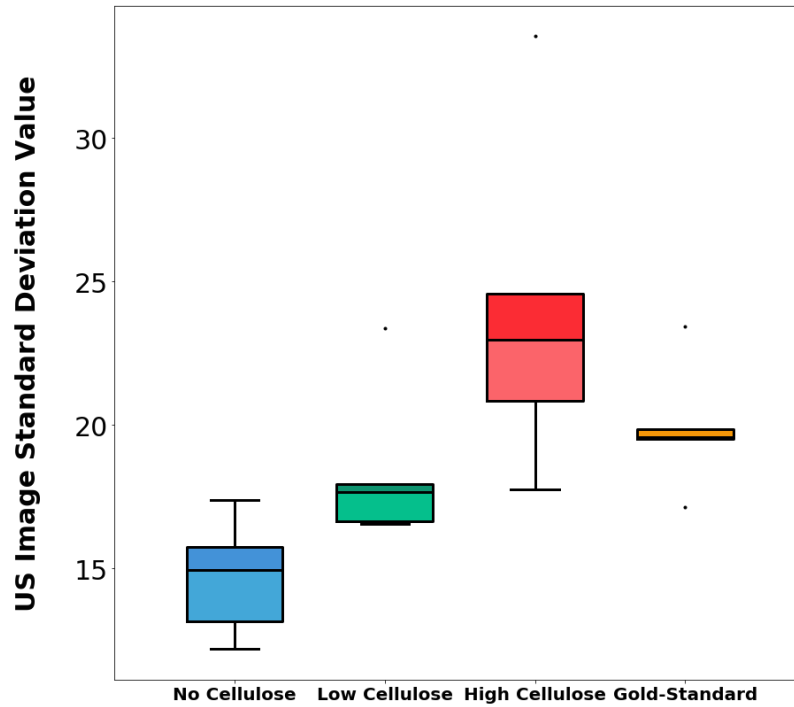
**Fig. 30.** Boxplot showing the mean values distribution for each type of tumor composition.



**Fig. 31.** Boxplot showing the median values variation for each type of tumor composition.

Evaluating as well the results obtained from the standard deviation (**Fig. 32**) which is more useful in terms of interpreting the contrast of the images, the results obtained fit the expectations.

As it can be seen in **Fig. 28**, the pixels that form the interior of the lesion do not present a high variation between their intensity values, hence showing a smaller central standard deviation value than the high cellulose composition, but higher than the formula with low cellulose concentration.



**Fig. 32.** Boxplot showing the variation in the standard deviation values for each type of tumor composition.

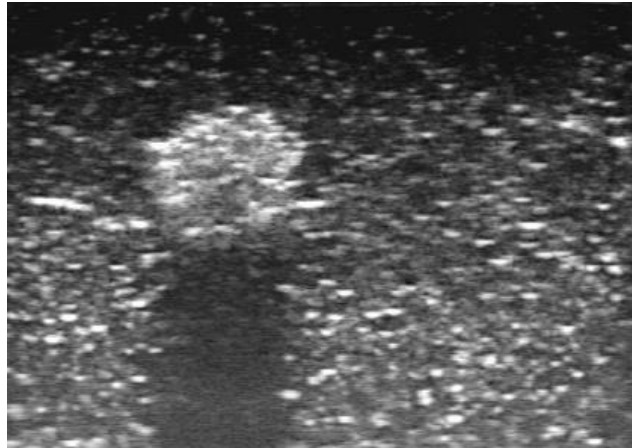
In the manufactured phantoms, the standard deviation values increase with the amount of cellulose used therefore, tumors without cellulose present a low value, while lesions manufactured with high cellulose quantity have the highest value of standard deviation, mainly due to the speckle appearance produced by the increasing use of cellulose.

Finally, according to the results obtained, it was concluded that the optimal cellulose concentration for the tumor composition was in between the low and the high cellulose concentrations under study. This is why phantom 10, which was built using the optimized formula, was made with two lesions of high cellulose concentration and a third tumor with low cellulose concentration.

#### 4.1.3. BREAST PHANTOM MANUFACTURED WITH OPTIMIZED FORMULA

The phantoms with cellulose used in section 4.1.1 in order to analyse the contrast of the ultrasound images were manufactured with 0.06 gr/100 ml of cellulose. As it has been observed in the boxplots of that section, there is still a considerable difference between the composition with cellulose and the gold-standard, this is why it was decided to increase the concentration of cellulose to 0.08gr /100ml in the phantom 10, which was manufactured with the optimized formula.

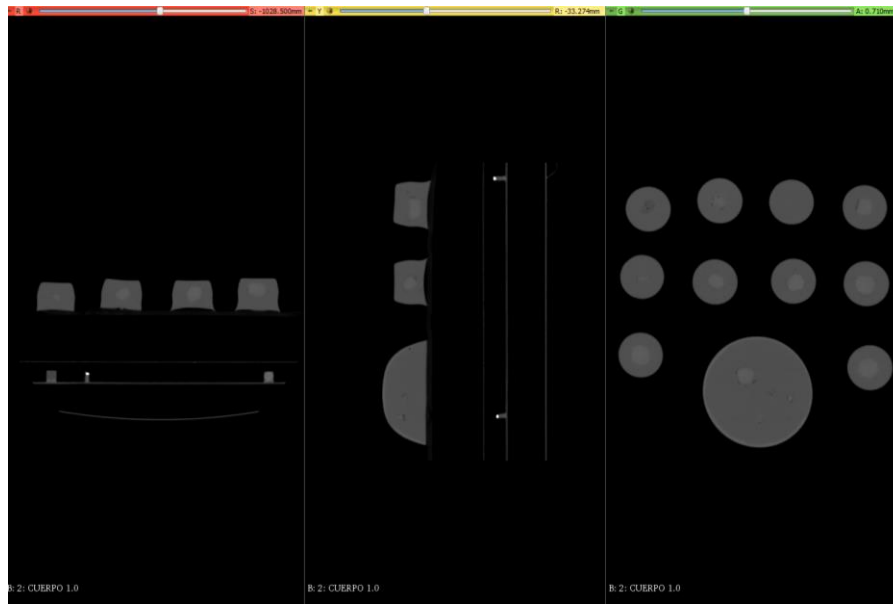
In **Fig. 33** an ultrasound image of this phantom is shown. The tumor can be well distinguished from the image background while this presents as well high contrast. The ultrasound images acquired on this phantom suggest that optimized formula can be used to build breast phantoms where lesions can be easily identified and localized using ultrasound imaging, and with a similar contrast to the gold-standard.



**Fig. 33.** Ultrasound image from phantom 10 showing a high cellulose concentration lesion.

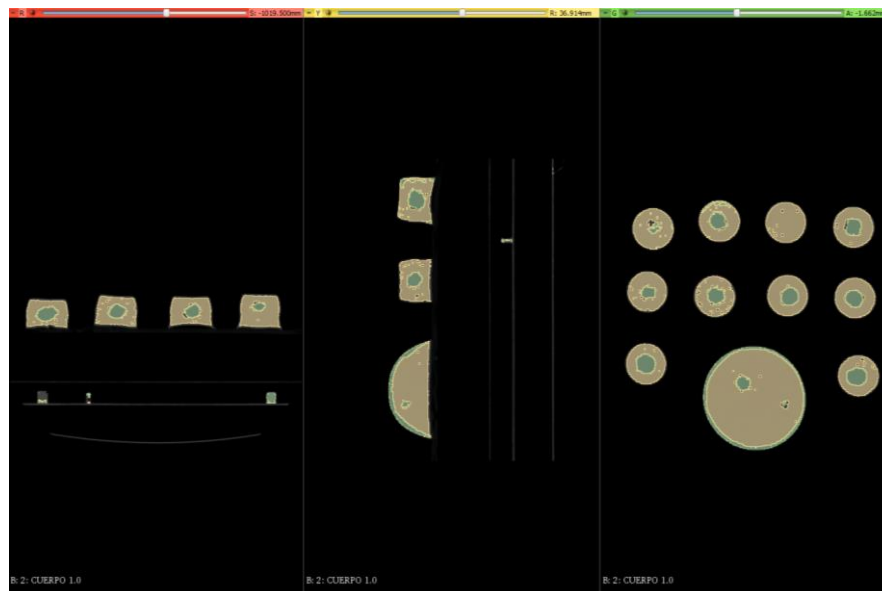
#### 4.2. CT IMAGES

The manufactured breast phantoms were built with the purpose of being visible as well with X-rays. In **Fig. 34** it can be observed how the breast mimicking tissue is well distinguished from the tumor, which has higher intensity values in the CT images due to an increased density. This CT scan has been obtained from the setup shown in **Fig. 16**.



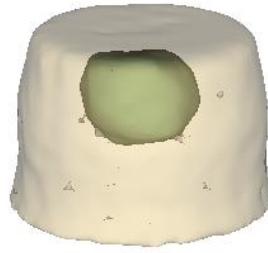**Fig. 34.** CT coronal, sagittal and axial image planes from the phantoms in experiment 2.

An intensity-based segmentation through thresholding was performed using 3D Slicer. In **Fig. 35** the difference between lesions and surrounding tissue can be observed. With these CT images, bubbles inside the phantoms can be well distinguished; they appear in the form of small dark areas.



**Fig. 35.** Intensity thresholding segmentation in 3D Slicer of the tumor and the breast mimicking tissue from the CT images of the manufactured phantoms.

Due to this difference in intensity of the different parts in the breast phantom, 3D models of phantoms can be generated from the CT acquisition (**Fig. 36**).



**Fig. 36.** 3D model of a small breast phantom from experiment 2 with a tumor inside.

#### 4.3. EVALUATION BY AN EXPERT CLINICIAN

The expert clinician evaluated the final breast phantom manufactured with the optimized formula. The expert determined the rigidity of the breast phantom to be appropriate and similar to the average rigidity of patients' breasts. Regarding resistance of the tissue to needle insertion, the manufactured breast phantom presented a similar behaviour in comparison with real breast tissue.

The US image contrast of the phantoms was found to be not very realistic due to the speckle appearance produced by the cellulose. However, the expert observed an improved ultrasound visualization of the phantom using the optimized formula. The expert approved the phantoms for training purposes since the main objective of this project is to manufacture breasts phantoms containing lesions which can be identified using ultrasound imaging. If lesions can be identified, the phantom can be used for training hand-eye coordination needed for ultrasound imaging of the breast tissue and ultrasound-guided needle insertions for tumor localization. Moreover, the manufacturing process of the phantoms allows the user to include lesions of desired size and position within the breast.

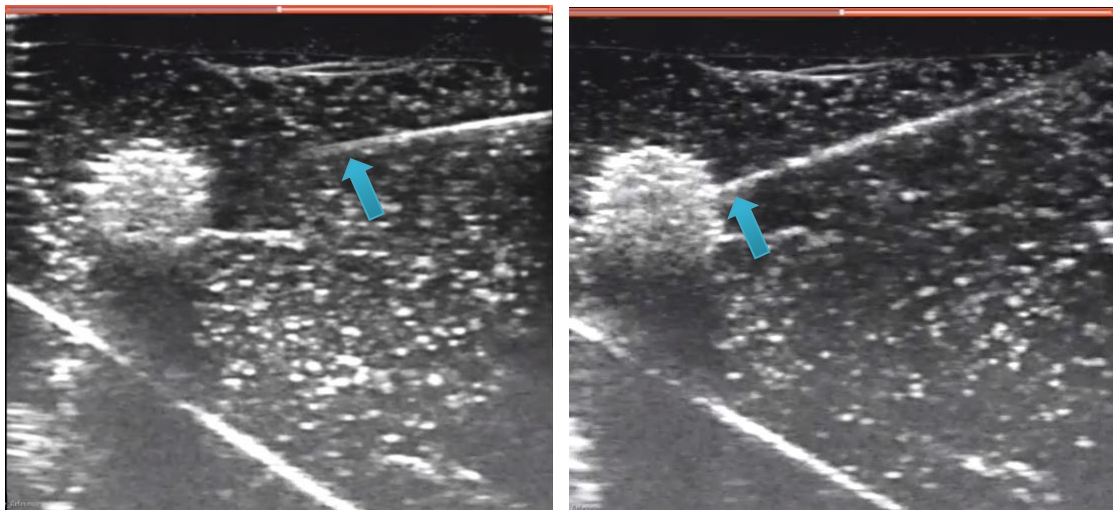
The main drawback that the expert found on the phantoms was the behaviour of the phantom material when biopsies were performed. Expert clinician performed several biopsies using a breast biopsy gun and detected that the trajectory of the biopsy needle leaves a track in the ultrasound contrast tissue of the phantom which does not disappear when the needle is extracted. This issue limits the number of training sessions that can

be performed with each phantom since the track alters the contrast of the image appearing as a bright line.

As a general conclusion, taking into account that the phantoms are not intended to be used as a training tool for understanding ultrasound images or learning how to interpret them, the expert confirmed that the phantoms fitted very well the main objectives of being suitable for training US-image guided interventions and navigation.

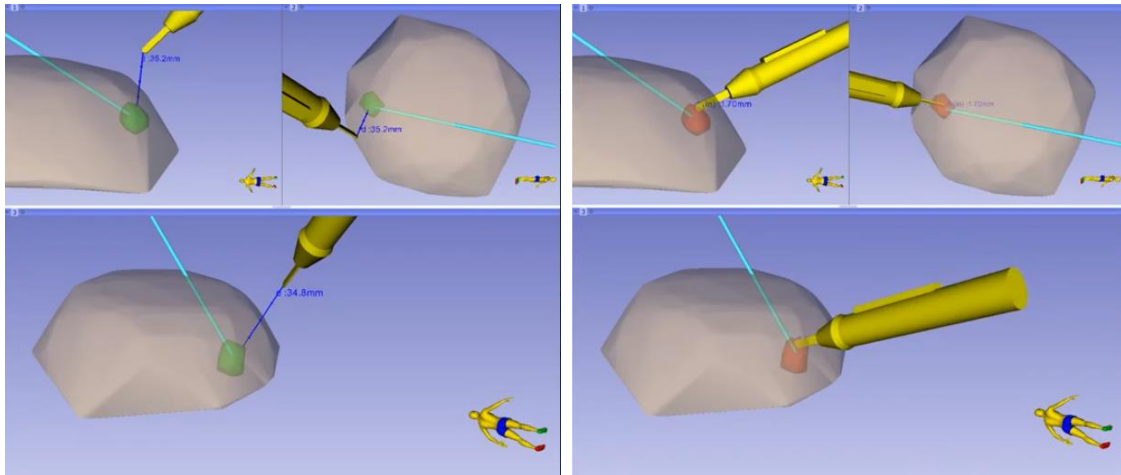
#### 4.4. SURGICAL NAVIGATION

The results obtained from the surgical navigation validation include the ultrasound-guided needle insertion for tumor localization images (**Fig. 37**) obtained from the built breast phantom.



**Fig. 37.** US image-guided insertion for tumor localization on the manufactured final breast phantom. In the left image the blue arrow indicates the needle approaching the lesion. In the image at the right, the arrow points the needle already inserted in the tumor.

Also, in this section are included the images obtained from the navigation performed on the phantom. This was displayed in the navigation computer screen with all the movements of the surgical instruments with respect to the 3D model obtained from the previous breast shape modelling step, useful for providing spatial orientation and guidance to the practitioner (**Fig. 38**).



**Fig. 38.** Navigation display showing the breast model containing the tumor model. The position of the different tools is displayed in real time: cautery (yellow) and needle (blue).

As it can be observed in the figure above, the cautery (stylus) is referenced to the lesion since all the tumor contouring points designated to form the 3D model of the lesion were saved in the coordinate system of the needle tip which traverses the lesion and moves rigidly with it. In this way, the distance from the cautery tip to the tumor surface can be computed in real-time and displayed on screen. Once the tumor has been found and is touched by the cautery, it is indicated by the tumor model colour, which turns into red. The distance that the cautery tip has been introduced into the lesion is also indicated.

The validation of the breast phantom with a simulated image-guided intervention, allowed to prove that it was manufactured with the suitable consistency and image contrast in order to fulfil the necessary requirements to be useful as a training tool.

## 5. CONCLUSIONS AND FUTURE WORK

### 5.1. CONCLUSIONS

The main goal of this project was the manufacturing and validation of low-cost breast phantoms that fulfilled the requirements needed in terms of shape, rigidity and consistency to be used by medical students and professionals as training tools for interventional procedures.

The phantoms were built with the purpose of mimicking the appearance of breast tissue affected by a tumor. Although its resemblance with the ultrasound image contrast of a reference commercial phantom was not completely achieved due to the speckle appearance caused by the cellulose, an optimal formula was reached based on the feedback provided by an expert clinician and on the results obtained from ultrasound and X-ray images analysis.

From this analysis it was concluded that the optimal formula for the ultrasound contrast tissue was composed of 65% super soft liquid vinyl, 35% plastic softener and a cellulose concentration of 0.08g/100ml. In the case of the lesions introduced in the breast phantom, the optimal formula was determined to be 125 ml of super soft liquid vinyl, 2 tsp of calcium sulfate and a concentration of cellulose varying between 0.2g/125 ml and 0.25g/125 ml, depending on the desired ultrasound image contrast.

The testing of ultrasound image-guided interventions for tumor localization in combination with surgical navigation was used as well to evaluate the suitability of the breast phantoms as training tools. Even though this way of practicing the skillset needed for these demanding interventions is not yet introduced in the surgical curricula, the expert clinician and a medical student who tested the phantoms, considered them as a great resource for training to which, nowadays, medical trainees do not have access.

Further improvements on the formula of the breast phantom would be needed in order to make the training experience more realistic and closer to the real clinical practice. In this way, the skills acquired would be more refined increasing the practitioners' confidence in their abilities. This will ultimately have a direct impact in the reduction of positive margins during tumor excision surgeries, producing an improvement in the efficiency of the treatments.



## 5.2. FUTURE WORK

In the future, several improvements related to the manufacturing process of the breast phantom models could be implemented.

First, the cellulose could be changed to other substance that gave as well contrast in ultrasound imaging but dissolves better in the super soft liquid vinyl, reducing in this way the granulated appearance of the images. Also, the material used to fabricate the bulk of the phantom, i.e. the ultrasound contrast tissue, could be changed so that when training biopsies in the phantom, needle tracks do not appear. A possible solution to this problem keeping the use of the super soft liquid vinyl, could be to heat the phantom a little bit so that the plastic gets softer and the fissure opened gets blended and smoothened. This has not been tested yet, so its efficacy should be determined in future studies.

In order to improve the outcome from the training of biopsies through ultrasound image guidance, it could be beneficial for the practitioner to stain the tumors with a different colour from the surrounding breast tissue mimicking material. In this way, when performing a biopsy, they can be sure that the extracted sample taken from the phantom comes from the tumor, or in case of failing, be sure that they have not performed well.

## 6. PROJECT BUDGET

### HUMAN RESOURCES COSTS

These costs are referred to the salary of the personnel involved in the project:

PERSONNEL	SALARY (€/HOUR)	HOURS	TOTAL COST (€)
Project coordinator	20	430	8,600
Bachelor student	10	560	5,600
<b>TOTAL</b>			<b>14,200</b>

**Table 2.** Human Resources Costs

### TECHNICAL EQUIPMENT COSTS

The expenditures coming from the technical equipment refer to the devices necessary for the image acquisition process and surgical navigation. Laboratory instruments and facilities were also needed for breast phantom building; this is indicated in the table below as “Laboratory equipment” and is referred to the magnetic stirrer, measuring cups, precision weighting balance, fume hood, etc. It is also indicated the open-source software used for the development of this project which is referred to ImageJ, 3D Slicer, PLUS Toolkit and Python:

Equipment	Average lifetime (years)	Unit Cost (€)	Depreciation per year (€)	Time dedicated	Total cost (€)
Laboratory equipment	5	5,000	1,000	4 months	333
Ultrasound machine	6	60,000	10,000	15 hours	17.12
Frame grabber	5	160	32	15 hours	0.06
Personal computer	5	700	140	6 months	70
Office 2010 license	2	140	70	6 months	35

Electromagnetic tracking system	5	10,000	2,000	4 hours	0.91
Open-source software	-	0	0	6 months	0
CT scan image	-	200	-	-	200
<b>TOTAL</b>					<b>656.09</b>

**Table 3.** Technical equipment costs.

### LABORATORY MATERIAL COSTS

In here it is included the costs of all the materials used for the building of the breast phantoms:

<b>LABORATORY MATERIAL</b>	<b>UNITS</b>	<b>AMOUNT PER UNIT</b>	<b>COST / UNIT (€)</b>	<b>TOTAL COST</b>
<b>Super soft liquid vinyl</b>	2	5 Liters	70	140
<b>Plastic softener</b>	2	1 Liter	17.90	35.8
<b>Plastic colorant</b>	2	35 ml	4	8
<b>Cellulose powder</b>	1	500 g	46.20	46.20
<b>Calcium sulfate</b>	1	250 g	33.70	33.70
<b>TOTAL</b>				<b>263.70</b>

**Table 4.** Laboratory material costs.

## SUMMARY OF THE COSTS

DESCRIPTION	ESTIMATED TOTAL COSTS
Human resources	14,200
Technical equipment	656.09
Laboratory material	263.70
ESTIMATED TOTAL BUDGET	15,119.79

**Table 5.** Estimated total budget for the project.

## BIBLIOGRAPHY

- [1] B. Alberts *et al.*, “Cell Communities: Tissues, Stem Cells and Cancer,” in *Essential Cell Biology*, 2014, pp. 712–724.
- [2] International Agency for Research on Cancer, “No Title,” *World Health Organization*, 2012. [Online]. Available: [http://gco.iarc.fr/today/online-analysis-map?mode=cancer&mode\\_population=who&population=900&sex=2&cancer=15&type=0&statistic=0&prevalence=0&color\\_palette=default&projection=natural-earth](http://gco.iarc.fr/today/online-analysis-map?mode=cancer&mode_population=who&population=900&sex=2&cancer=15&type=0&statistic=0&prevalence=0&color_palette=default&projection=natural-earth).
- [3] “Breast cancer: prevention and control,” *World Health Organization*, 2018. [Online]. Available: <http://www.who.int/cancer/detection/breastcancer/en/>.
- [4] WHO, *Guide To Cancer Early Diagnosis*. 2017.
- [5] “Breast Cancer statistics in Spain,” *World Heal. Organ.*, 2014.
- [6] H. Pan *et al.*, “Intraoperative Ultrasound Guidance Is Associated with Clear Lumpectomy Margins for Breast Cancer: A Systematic Review and Meta-Analysis,” *PLoS One*, vol. 8, no. 9, pp. 1–8, 2013.
- [7] T. Ungi *et al.*, “Navigated Breast Tumor Excision Using Electromagnetically Tracked Ultrasound and Surgical Instruments,” *IEEE Trans. Biomed. Eng.*, vol. 63, no. 3, pp. 600–606, 2016.
- [8] J. F. Waljee, E. S. Hu, L. A. Newman, and A. K. Alderman, “Predictors of Re-excision among Women Undergoing Breast-Conserving Surgery for Cancer,” *Ann. Surg. Oncol.*, vol. 15, no. 5, 2008.
- [9] M. J. Dimitrovska, N. Mitreska, M. Lazareska, E. S. Jovanovska, A. Dodevski, and A. Stojkoski, “Hook wire localization procedure and early detection of breast cancer - our experience,” *Maced. J. Med. Sci.*, vol. 3, no. 2, pp. 273–277, 2015.
- [10] S. H. Heywang-Koebrunner, I. Schreer, and S. Barter, *Diagnostic Breast Imaging*. 2014.
- [11] A. Rose and L. Wylie, “Breast Hookwire Localisation,” *Inside Radiology*, 2017. .
- [12] M. S. Sajid, U. Parampalli, Z. Haider, and R. Bonomi, “Comparison of radioguided occult lesion localization (ROLL) and wire localization for non-palpable breast cancers: A meta-analysis,” *J. Surg. Oncol.*, vol. 105, no. 8, pp. 852–858, 2012.
- [13] E. Tummel, R. Betzold, K. Gallagher, and V. S. Klimberg, “The CUBE Technique: Continuous Ultrasound-Guided Breast Excision,” *Ann. Surg. Oncol.*, vol. 21, no. 10, pp. 3354–3355, 2014.
- [14] Y. D. Shin *et al.*, “Comparison of outcomes of surgeon-performed intraoperative ultrasonography-guided wire localization and preoperative wire localization in nonpalpable breast cancer patients undergoing breast-conserving surgery: A retrospective cohort study,” *Medicine (Baltimore)*, vol. 96, no. 50, 2017.
- [15] M. Tomikawa *et al.*, “Real-Time 3-Dimensional Virtual Reality Navigation System with Open MRI,” *J. Am. Coll. or Surg.*, vol. 210, no. 6, 2010.

- [16] T. Ungi *et al.*, “Perk tutor: An open-source training platform for ultrasound-guided needle insertions,” *IEEE Trans. Biomed. Eng.*, vol. 59, no. 12, pp. 3475–3481, 2012.
- [17] T. Fujisaki, M. Kimura, H. Saitoh, S. Abe, and T. Hiraoka, “Production design and evaluation of a novel breast phantom with various breast glandular fractions,” *Radiat. Med. - Med. Imaging Radiat. Oncol.*, vol. 24, no. 10, pp. 647–652, 2006.
- [18] I. M. De Carvalho *et al.*, “Polyvinyl chloride plastisol breast phantoms for ultrasound imaging,” *Ultrasonics*, vol. 70, pp. 98–106, 2016.
- [19] J. Sutcliffe, R. L. Hardman, N. C. Dornbluth, and K. A. Kist, “A novel technique for teaching challenging ultrasound-guided breast procedures to radiology residents,” *J. Ultrasound Med.*, vol. 32, no. 10, pp. 1845–1854, 2013.
- [20] EU Commission, “New EU rules to ensure safety of medical devices,” *European Commission-Fact Sheet*. 2017.
- [21] A. Lasso, T. Heffter, A. Rankin, C. Pinter, T. Ungi, and G. Fichtinger, “PLUS: open-source toolkit for ultrasound-guided intervention systems,” vol. 61, no. 10, pp. 2527–2537, 2014.
- [22] “3D Slicer.” [Online]. Available: <https://www.slicer.org/>.
- [23] “ImageJ.” [Online]. Available: <https://imagej.nih.gov/ij/>.