

<https://helda.helsinki.fi>

---

## Management of sacral fractures

Lindahl, Jan

2019

---

Lindahl, J 2019, ' Management of sacral fractures ', Suomen ortopedia ja traumatologia , vol. 42 , no. 1 , pp. 14-23 . < [http://www.soy.fi/files/sot\\_42\\_1\\_2019\\_web.pdf](http://www.soy.fi/files/sot_42_1_2019_web.pdf) >

---

<http://hdl.handle.net/10138/313448>

---

unspecified  
publishedVersion

---

*Downloaded from Helda, University of Helsinki institutional repository.*

*This is an electronic reprint of the original article.*

*This reprint may differ from the original in pagination and typographic detail.*

*Please cite the original version.*

# Management of sacral fractures

Jan Lindahl

Helsinki University Central Hospital, Helsinki, Finland

Pelvic ring disruptions are relatively rare injuries and account for approximately 1% of fractures that require hospitalization among people  $\geq 16$  years in Finland (1). High-energy unstable pelvic ring disruptions are frequently associated with multiple concomitant injuries. Among patients with multiple-traumas, up to 25% have pelvic ring injuries (2-4), which also are a significant source of mortality and morbidity (5-8).

During the past few decades, the rate of osteoporotic pelvic fractures in the older population has increased consistently (9,10). Low-energy fractures in osteoporotic patients are defined as fragility fractures of the pelvis (FFP). The term "fragility fracture" is used instead of stress, fatigue or insufficiency fracture to describe osteoporosis-associated fractures due to a minor trauma or with no obvious trauma history (11,12). Fragility fractures of the sacrum (FFS) are often combined with a fracture of the anterior pelvic ring; hence they are classified as a part of fragility fractures of the pelvis (FFP). Because of low-energy trauma mechanism, multiple injuries are rare in these patients. Survival rate of FFP can be compared to survival rate of hip fractures. One year mortality is 27% (13).

Fracture patterns in the sacrum range from crush lesions in the lateral sacrum to spinopelvic dissociations. Various options for management for different type of sacral fractures have been proposed.

## Classification

### Pelvic ring injuries

According to AO/OTA classification system the pelvic ring fractures are graded into three types, A, B, and C, in order of increasing severity (14). Type A injuries are stable fractures, which fall into two categories. The first category includes fractures that do not involve the ring, which include isolated transverse fractures of the sacrum below the SI-joint level (61-A3), avulsion fractures, and fractures of the iliac

wing. The second category includes direct-blow fractures in the anterior arch; these involve pubic rami and/or symphysis pubis.

Type B injuries are rotationally unstable but vertically and posteriorly stable. They may be caused by external rotatory forces (open book injuries) or internal rotatory forces (lateral compression injuries). In type B lateral compression injury (61-B2), the hemipelvis is typically driven into an inward and upward rotation, which causes shortening and vertical displacement at the rami fracture site or disruption of the SP (overlap of the pubis). The posterior sacroiliac complex, typically the anterior part of the lateral sacrum is impacted, but there is no vertical instability, because the posterior ligaments are intact. A lateral compressive force may cause two types of injury. In one type, anterior and posterior lesions occur on the same side, and in the other type, displacements occur on opposite (contralateral) sides. The ligaments of the pelvic floor remain intact, which ensures vertical and posterior stability.

Type C injuries are completely unstable fractures, which exhibit both rotational and translational instability (61-C1). Posterior pelvic ring injuries form the basis of the subgroups; a fracture through the posterior ilium (C1.1), sacroiliac dislocation and fracture dislocation (C1.2), and sacral fractures (C1.3). The posterior injury may be bilateral. The bilateral posterior lesion may be vertically stable on one side and unstable on the other (61-C2), or unstable on both sides (61-C3).

### Sacral fractures

Sacral fracture patterns are commonly categorized using the Denis classification system (15). It divides sacral fractures into three zones: alar (zone 1), foraminal (zone 2) and central (zone 3). Denis, Davis and Comfort (15) found that injury to nerves occurred in 5.9% of fractures lateral to sacral foramina. In transforaminal fractures 28.4% of patients had a neurological deficit. Central fractures had the highest prevalence (56.7%) of nerve injury.

## Spinopelvic dissociation

The spinopelvic dissociation is a rare, high-energy injury pattern located in the sacrum. It is characterized by bilateral vertical sacral fractures in conjunction with a transverse sacral fracture. Denis's system does not recognize the combination of bilateral vertical and transverse fracture lines that cause spinopelvic dissociation. This injury causes the spine and upper central segment of the sacrum to dissociate from the pelvic ring and caudal sacral segments.

Roy-Camille et al. (1985) described the spinopelvic dissociation injury, but they classified only the transverse sacral fracture, not the bilateral vertical fracture components (16). Roy-Camille et al. divided transverse sacral fractures into three types. However, the Roy-Camille classification of these fractures (1985) is not prognostic of neurological impairment after operative treatment (17). The outcome study of H-shaped sacral fracture with spinopelvic dissociation by Lindahl et al. (2014) showed that neurological recovery and clinical outcome were associated with the degree of initial translational displacement of the transverse sacral fracture (17). Therefore it is useful to subcategorize transverse sacral fractures, as partially displaced or completely displaced, and add these subcategories to the original Roy-Camille type 2 and 3 sacral fractures. According to this modified classification system of transverse sacral fractures: type 1 is a flexion injury without translational displacement; type 2a is a flexion injury with partial anterior translational displacement of the caudal sacral segment; type 2b is a flexion injury with complete anterior translational displacement of the caudal sacral segment; type 3a is an extension injury with partial posterior translational displacement of the caudal sacral segment; and type 3b is an extension injury with complete posterior translational displacement of the caudal sacral segment (17).

In addition to H-shaped injuries, other possible sacral fracture patterns that occur with spinopelvic dissociations include the U-, Y-, and T-shaped sacral fractures (18-22).

## Fragility fractures of the pelvis (FFP)

The Rommens and Hofmann classification system of fragility fractures of the pelvis (FFP) differentiate isolated anterior or posterior pelvic injuries as well as a combinations of these including the degree

of displacement and hence the degree of pelvic instability (23). It divides FFP into four types: type I are isolated injuries of the anterior pelvic ring; type II represent non-displaced fractures of the sacrum; type III exhibit a higher degree of instability presenting a complete unilateral sacral or sacroiliac complex disruption and a complete fracture of the anterior pelvic ring with some degree of displacement; and type IV are injuries with bilateral displaced posterior lesions. A bilateral sacral fracture connected with a transverse fracture line is classified as FFP type IVb, functionally being a highly unstable spinopelvic dissociation. A combination of bilateral posterior pelvic disruption including a sacral fracture and an anterior pelvic ring injury is classified as FFP type IVc.

## Radiographic examination

The anteroposterior (AP) pelvic radiograph is the principal diagnostic tool and gold standard for assessing patients with suspected pelvic injuries. An AP pelvic radiograph is mandatory for the initial assessment in the emergency evaluation, and it provides in most cases the diagnosis. CT is very sensitive for detecting pelvic fractures and identifying associated injuries that often accompany the pelvic fracture. CT scans are best for delineating the posterior anatomy, and they are extremely useful for identifying injuries of the sacroiliac complex, the sacrum, SI-joint, or iliac wing (24). Moreover, CT is very valuable for assessing of pelvic stability. CT images clearly indicate whether a posterior pelvic injury is impacted and stable or disrupted and unstable (14).

Anteroposterior pelvis radiograph and CT show the vertical sacral fracture lines. However, the diagnosis of traumatic spinopelvic dissociations is often missed or delayed in AP pelvic radiograph because of the difficulty in imaging the upper sacrum and the frequency of concomitant severe injuries. Angulation of the fractured sacral segment can produce a paradoxical inlet view of the upper sacrum on the standard anteroposterior pelvic radiograph (18). Delayed diagnosis is avoided by high clinical suspicion, early lateral sacral radiographs, and pelvic CT sagittal reconstructions.

Diagnostics of fragility fractures of the pelvis is more challenging, because conventional pelvis radiographs have a lower sensitivity in detecting low-energy sacral fractures than high-energy sacral

fractures. When a fracture of the pubic rami is diagnosed, a CT-scan of the pelvis is performed to assess the full extent of the injury. FFS often show a discontinuation of the anterior sacral cortex laterally to the sacral foramina with only minor displacement. Sometimes, a small crush zone medially to the SI-joint can be detected (11). In elderly patients conventional radiographs of the lumbar spine are also carried out to exclude other pathologies in elderly suffering from low back pain. Magnetic resonance imaging (MRI) of the lumbar spine and sacrum can be used to exclude occult osteoporotic fractures of the sacrum or the lumbar spine (25).

Three-dimensional (3D) image reconstructions based on CT scans of the pelvis provide considerable information on the location and stability of pelvic fractures. 3D CT enhances the understanding of each fracture lines and the separate fragments by simulating the gross anatomy of the injured pelvis. In particular, rotational deformities and displacements of the pelvis are best visualized with 3D CT. Pelvic AP radiography and CT with 3D image reconstructions will confirm the type of pelvic injury, the presence or absence of instability, and the degree of each displacements. It is necessary to acquire 3D CT images prior to a definitive surgical treatment of an unstable pelvic fracture. 3D CT facilities are currently available in most trauma centres; therefore, oblique pelvic inlet and outlet views are no longer essential for diagnostics or for preoperative planning.

### *Neurologic injury*

AO/OTA type C1.3 fractures of the sacrum may result in a neurologic injury in up to 40 % of cases (26) and sacral fracture-dislocations with spinopelvic dissociation in up to 100 % of cases (17,27). The nerve injury may involve more than one nerve root, and be unilateral or bilateral depending on the fracture pattern and location. The injury can range from a neuropraxic injury due to nerve contusion or shearing injury, to transection of nerve roots.

In H-shaped sacral fractures with spinopelvic dissociation, the transverse fractures are angled, and they undergo translational displacement, or even complete fracture displacement. This condition results in gross spinopelvic instability and neurological deficits in the cauda equina. Another common

presentation is an injury to the L5 and S1 nerve roots associated with vertical sacral fracture lines. The L5 nerve root can be injured as a result of vertical shear displacement of the sacrum and is often accompanied by a fracture of the transverse process of L5. A S1 nerve root injury is associated with transforaminal (zone II) sacral fractures (15).

Clinical examination of trauma patients sustaining sacral fractures requires both examination of lower extremity sensory and motor function, and examination to identify injuries to the lower sacral plexus. A rectal examination is performed to evaluate sphincter contraction and to exclude possible rectal injury as a sign of an open pelvic fracture. Light touch and pinprick sensation should be assessed for the perianal dermatomes of S2 to S5.

### *Conservative treatment*

In type B lateral compression injuries, the anterior part of the sacrum or the sacroiliac complex is typically impacted, but there is no vertical instability. These compression type fractures of the lateral sacral ala can be treated non-operatively. If the hemipelvis is internally rotated and there is a clear displacement on the rami fracture site, partial weight-bearing on the affected side is recommended for 4 to 6 weeks.

Most fragility fractures (FFP type 1 and 2 injuries) of the pelvis can be treated non-operatively (23). They are minor lesions with little instability. Treatment consists of pain medication and mobilization out of bed and weight-bearing in the limit of pain of the injured side. As soon as the pain intensity diminishes, full weight-bearing will be achieved. When intense pain persists or increases, additional CT examinations are recommended in order to exclude fractures or displacements that may not have been visible or present at admission. Pain can persist for as long as six to eight weeks after the minor trauma.

### *Surgical treatment*

#### **Vertically unstable sacral fractures**

An external fixator applied anteriorly cannot restore enough stability to an unstable type C disruption of the pelvic ring to allow mobilization of the patient without risking redisplacement of

the fracture (14,26,28). Therefore open or closed reduction and internal fixation has become the method of choice for stabilization of type C pelvic ring injuries with sacral fractures.

Biomechanical studies have shown that the best stability in type C pelvic ring injuries can be achieved by internal fixation of the posterior and anterior pelvic ring injuries (14,29). Therefore fixation of any associated anterior pelvic ring injury is essential to improve the fixation stability of the whole pelvic ring (30,31). However, non-displaced and stable rami fractures might be treated non-operatively.

Sacral fractures are the most difficult to reduce and stabilise. Biomechanical studies have demonstrated differences in stiffness of fixation constructs in sacral fractures (32,33). Following anatomic reduction, there are several different type of fixation techniques for vertically unstable sacral fractures including iliosacral screws, transiliac bars, transiliac plates, local small plates, and spinal instruments.

**Iliosacral screw fixation.** Iliosacral screw fixation is the gold standard for fixation of vertically unstable sacral fractures. Severely displaced sacral fractures are typically approached posteriorly, with the patient in the prone position, through a vertical incision medial to the posterior superior iliac spine without releasing the gluteal muscles from the outer side of the iliac crest. The sacral fracture is observed and reduced with forceps. After achieving reduction, the sacral fracture is fixed with two percutaneously placed 7.0-7.3 mm fully threaded cannulated screws (through a separate small lateral skin incision) from the outer aspect of the ilium through the SI-joint into the body of S1 under fluoroscopic guidance. Minimally displaced sacral fractures are suitable for closed reduction, either in the supine or prone position, and percutaneous IS-screw fixation. The screws should be placed at least past the midline of the sacrum.

Three dimensional computer-assisted navigation facilitates screw placement with less radiation and a similar operation time, compared to the conventional fluoroscopy-guided procedure (34). A three-dimensional image intensifier can also be used intra-operatively to control the quality of reduction and to guide correct placement of the iliosacral-screws.

**Ilio-iliac techniques.** There are four main options: extraosseous transiliac bars (sacral bars), intraosseous sacral bars, ilio-iliac plates (35,36), and an ilio-iliac internal fixator (37). Ilio-iliac plating techniques have some disadvantages, including limited reduction possibilities, bilateral bridging of the SI-joint in the unilateral injury pattern, difficulty in precontouring the plate, and a higher rate of symptomatic implants (35,38).

**Direct plate fixation.** A sacral fracture fixation with small fragment implants (small sacral plates) has been introduced as an alternative approach (39,40). This direct plating technique might be useful in sacral fractures lateral to the sacral foramina (Denis zone I). However, in transforaminal sacral fractures (zone II), short local plates cannot be used without screw penetration into the sacral canal; therefore, these fractures require longer transverse plates that pass over the midline.

**Combined techniques.** In patients with a comminuted sacral fracture a threaded compression transiliac rod might be used to anchor the injured hemipelvis to the contralateral ilium to help supplement iliosacral screw fixation (Töölö hospital experience).

### *Spinopelvic dissociation*

Treatment for a H-shaped sacral fracture with spinopelvic dissociation has evolved from a non-operative approach to open reduction and segmental lumbopelvic fixation (16,17,27,41). The goals of treatment are realignment, restoration of spinopelvic stability, and decompression of the neural injury indirectly with fracture reduction and/or directly with a sacral laminectomy. Fixation is achieved by connecting the lumbar spine to the ilium with segmental spinal fixation system. Allen and Ferguson (1984) were the first to report on their experience with the Galveston technique, where the distal fixation points are located on the posterior part of the iliac wings, above the sciatic notch, and between the laminae (42).

Töölö Hospital lumbopelvic fixation technique (17). A staged reconstruction is performed when a combined H-shape sacral fracture and an additional anterior pelvic ring injury is present. The injuries of

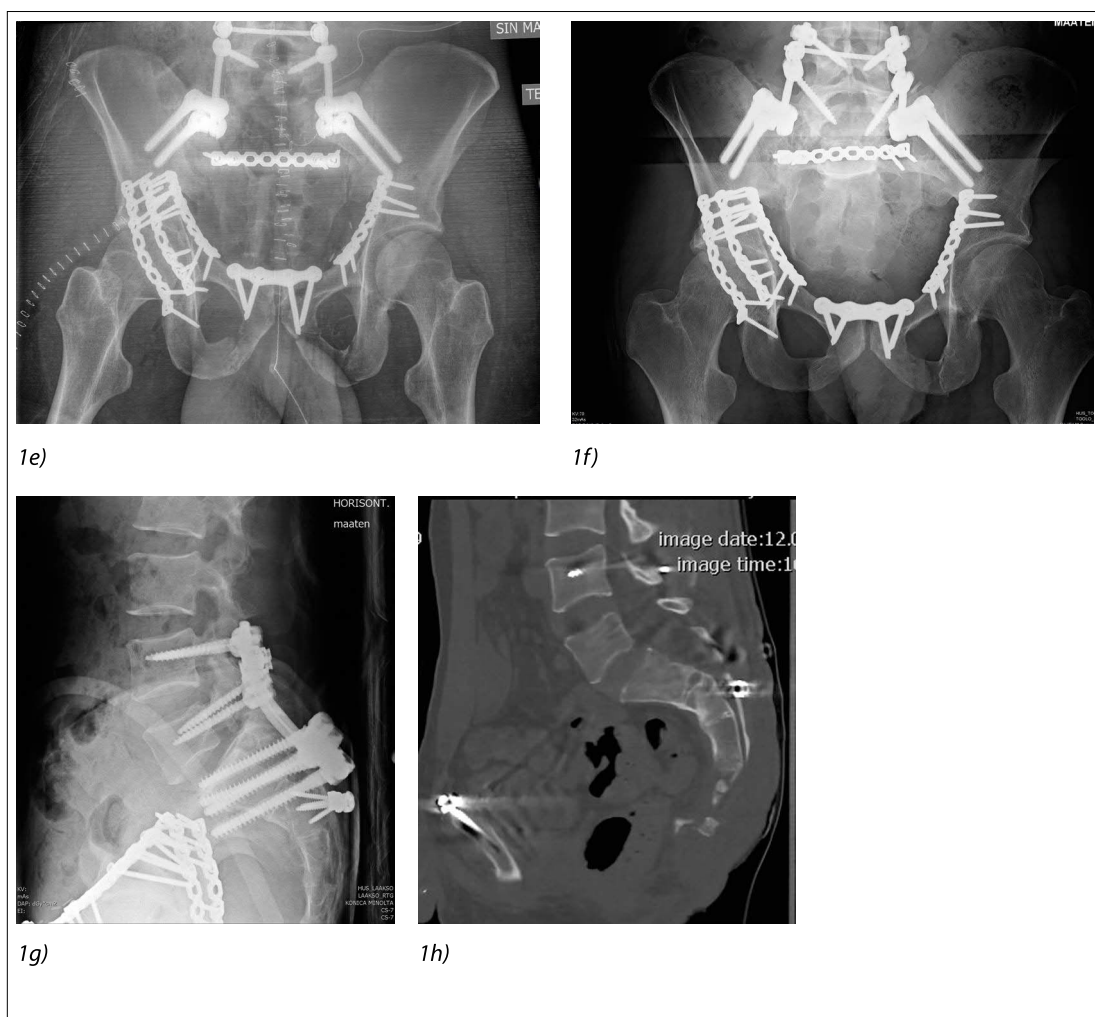
the anterior part of the pelvic ring are most commonly operated on first (Figure 1). The method for lumbopelvic fixation includes two pairs of 6-mm lumbar pedicle screws, bilateral 6-mm longitudinal rods, one or two transverse connectors, and two pairs of 8-mm iliac screws. Longitudinal rods are connected to L4 and L5 pedicle screws after having been contoured to lie close to the posterior lamina of the sacrum and medial to the PSISs. One or two transverse connecting rods between longitudinal rods are used to secure the fixation. The operative reduction and correction of displacements and rotational deformities of both hemipelvises and the caudal segment of the sacrum are performed using two pairs of reduction clamps and caudal distraction of the distal part of the sacrum. The longitudinal rods fixed to

pedicle screws act as a counter force for the final vertical correction of the sacral fracture components. Simultaneous reduction of the hemipelvis into a dorsal direction by traction is performed by the second pair of reduction clamps. To achieve this goal, simultaneous bilateral manual femoral traction and hyperextension of both hip joints are also used. When accurate reduction is obtained, the lumbar spine and central upper sacral segment is fixed to the pelvic ring by placing two pairs of 8-mm iliac screws into the iliac bones with the Galveston technique (42) and connecting them to the longitudinal rods with special clamps.

Indirect decompression of the lumbar (vertical fracture lines) and sacral neural roots (the transverse fracture line) is achieved through reduction of all the sacral fracture components (Figure 1).

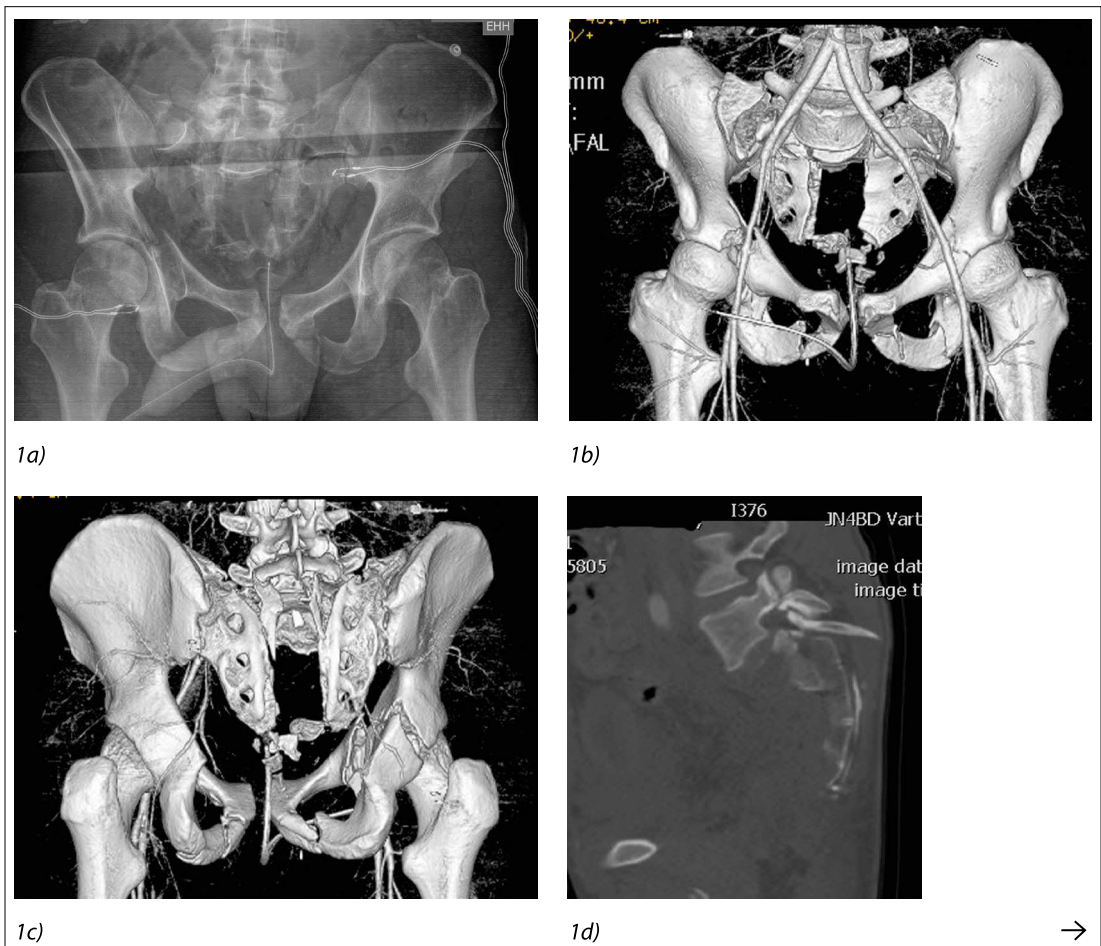

Figure 1...



*Figure 1. A staged reconstruction of a T-shaped sacral fracture-dislocation with spinopelvic instability, cauda equina injury and bilateral L5-S1 nerve roots injuries, in a 32 years-old male who jumped from the fifth floor. (a-c) Bilateral acetabular fractures, a T-type fracture on the right side, an anterior column fracture on the left side, and disruption of the symphysis pubis associated with spinopelvic dissociation are shown in pelvis x-ray (a) and 3D-reconstructed images of the anterior (b) and the posterior pelvis (c). (d) CT image shows a comminuted type 3b transverse sacral fracture with complete translational fracture displacement at the level of S2. (e-f) Pelvis x-ray images (post op and 2,5 years after the operation) and (g-h) lateral x-ray and sagittal CT image show the result of the three-stage pelvic reconstruction. The first stage consisted of anterior fixation of both acetabulum fractures and the symphysis pubis; the second stage consisted of a segmental lumbopelvic fixation and an additional transverse plate fixation of the sacrum, and the third stage consisted posterior fixation the the right acetabulum. Two and half years from the trauma, the patient was able to walk without aids, had slight pelvic pain at rest (VAS 2-3/10), and reported slight deficiencies in micturition and slight bowel dysfunction.*

Direct decompression by sacral laminectomy is recommended to perform for all completely displaced transverse sacral fracture with occlusion of the central sacral canal and in the patients

in which a clear translational displacement remained in the transverse fracture line after the final reduction as assessed by a true lateral sacral fluoroscopic view.

## FFP

Rommens and Hofmann (2013) recommend surgical treatment in FFP (type 3 and 4), if patient is not able to mobilize out of bed during the first 3-5 days despite pain therapy or if increasing dislocation of fracture fragments during the early follow-up period is noticed (23). Displaced (unstable) FFS are treated with minimal-invasive fracture fixation, either by transsacral screws (Figure 2) or bilateral iliosacral screws (23,43). In FFP with a concomitant displaced anterior pelvic ring injury, anterior fixation is recommended (12). However, if FFP is diagnosed with delay and a strong callus formation in the anterior part of the pelvis is visible, the rami fractures can be treated non-operatively. H- or U-type fracture patterns functionally represent a spinopelvic dissociation. These injuries are unstable and should be fixed in a minimal invasive way in cases with no or only slight displacement. However, if gross displacement is present, a lumbopelvic stabilization is recommended.

## Outcomes

In a systematic review of treatment modalities and outcomes of pelvic ring disruptions, Papakostidis et al. (31) concluded, that fixation of all the injured elements of the pelvic ring yield better anatomical results compared to more non-operative therapeutic strategies. From the functional point of view walking capacity was proved to be significantly better in the groups of operative treatment compared to non-operative group.

Poor outcomes correlate with the injury pattern of the posterior part of the pelvic ring. Sacral fractures and sacroiliac dislocations result in higher rates of back pain than posterior iliac fracture types (26). The presence of lumbosacral plexus injury correlates to unsatisfactory functional results. Functional results are also affected by poor reduction results and loss of alignment (26,30,31,44). Conversely, it is unusual to obtain a satisfactory functional result in the presence of a fair or poor fracture reduction (26,30).

Segmental lumbopelvic fixation is a reliable treatment method for H-shaped sacral fracture with spinopelvic dissociation and it provides sufficient stability for fracture union with a low rate of complications and long-term sequelae (17). In spinopel-

vic dissociations, quality of reduction in terms of residual postoperative vertical and AP displacements in the vertical sacral fracture lines and translational displacement and kyphosis in the transverse sacral fracture, is associated with the clinical outcome. Accurate reduction of all sacral fracture components is associated with better clinical outcome (17).

## Conclusions

High-energy pelvic ring disruptions are relatively uncommon injuries. However, the incidence of FFS seems to be underestimated and the diagnosis is frequently made with delay. Prolonged low back pain or pain in the sacrum area in the elderly, especially if a low-energy trauma has occurred, should raise the suspicion of FFS. CT-scan of the pelvis should be performed early in these cases to get the right diagnosis. Sacral fracture patterns range from vertically stable crush lesions of the lateral sacrum to completely unstable bilateral fractures of the sacrum with spinopelvic dissociation. Various options for management for different type of sacral fractures have been proposed. Iliosacral screw fixation is still the gold standard for the fixation of vertically unstable sacral fractures including FFS. H-shaped sacral fractures, and other possible sacral fracture patterns that occur with spinopelvic dissociations and gross spinopelvic instability, are treated with segmental lumbopelvic stabilization.



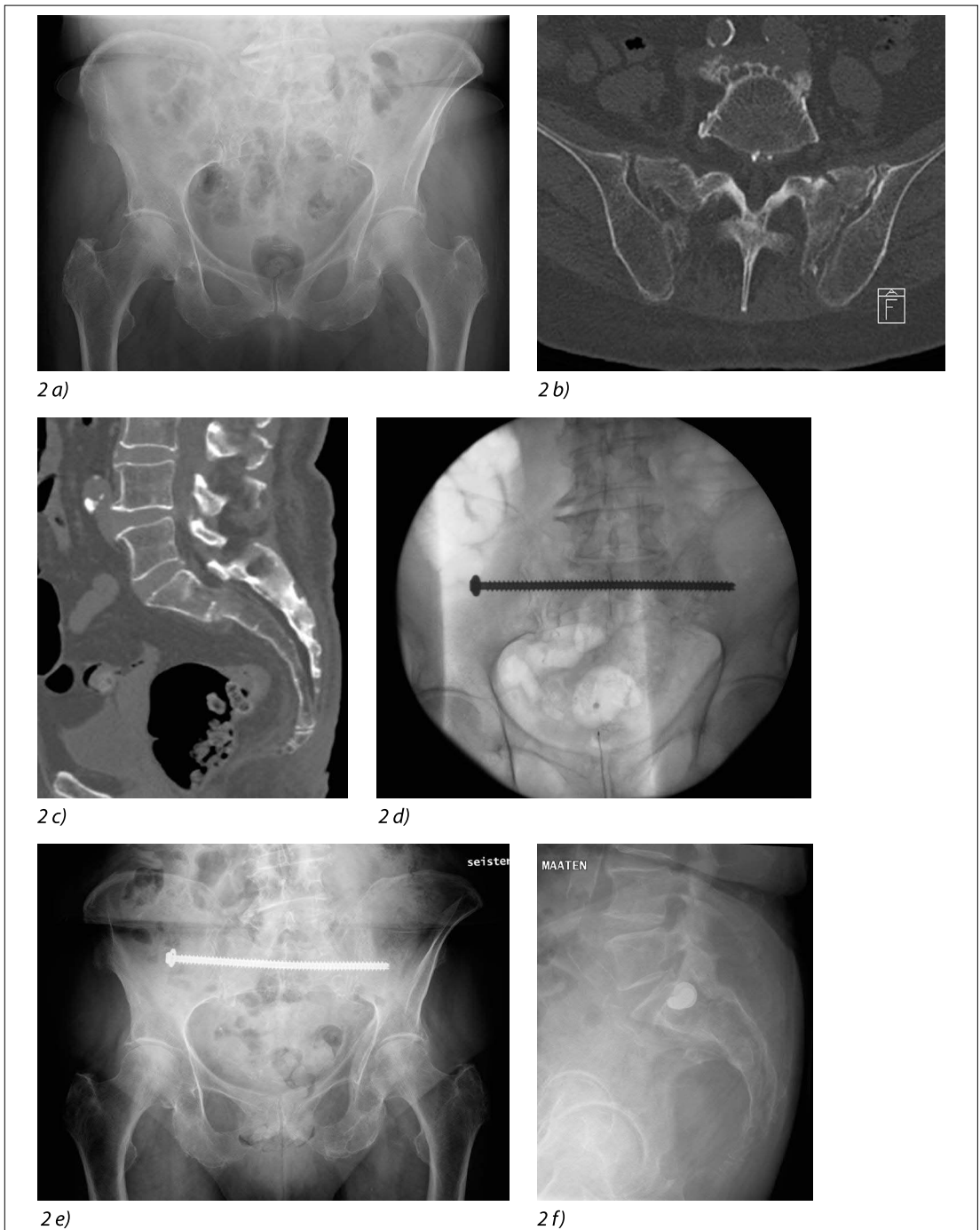


Figure 2. Treatment of a U-shaped fragility fracture of the sacrum in a 83 year-old female who had a low-energy falling accident. Prolonged pain in the sacrum raised the suspicion of FFS. (a) Pelvis x-ray shows no fracture, but (b-c) CT images two weeks later show a minimally displaced U-shaped sacral fracture. Because the patient was not able to mobilize out of bed during the first two weeks, surgical treatment was performed. (d-e) Pelvis x-ray images and (f) lateral sacral image show a transsacral screw fixation. Two years from the accident, the patient was asymptomatic and was able to walk normally.

## References

1. Somersalo A, Paloneva J, Kautiainen H, Lönnroos E, Heinänen M, Kiviranta I. Incidence of fractures requiring inpatient care. *Acta Orthop* 2014;85:525-530.
2. Ragnarsson B, Jacobsson B. Epidemiology of pelvic fractures in a Swedish county. *Acta Orthop Scand* 1992;63:297-300.
3. Giannoudis PV, Grotz MR, Tzioupis C, Dinopoulos H, Wells GE, Bouamra O, Lecky F. Prevalence of pelvic fractures, associated injuries, and mortality: The United Kingdom perspective. *J Trauma* 2007;63:875-883.
4. Matewski D, Szymkowiak E, Bilinski P. Analysis of management of patients with multiple injuries of the locomotor system. *Int Orthop* 2008;32:753-758.
5. McMurtry R, Walton D, Dickinson D, Kellam J, Tile M. Pelvic disruption in the polytraumatized patient: A management protocol. *Clin Orthop Relat Res* 1980;151:22-30.
6. Gilliland MD, Ward RE, Barton RM, Miller PW, Duke JH. Factors affecting mortality in pelvic fractures. *J Trauma* 1982;22:691-693.
7. Tötterman A, Glott T, Madsen JE, Roise O. Unstable sacral fractures. Associated injuries and morbidity at 1 year. *Spine* 2006;31:E628-E635.
8. Lykomiros VA, Papavasiliou KA, Alzeer ZM, Sayegh FE, Kirkos JM, Kapetanios GA. Management of traumatic sacral fractures: A retrospective case-series study and review of the literature. *Injury* 2010;41:266-272.
9. Kannus P, Palvanen M, Niemi S, Parkkari J, Jarvinen M. Epidemiology of osteoporotic pelvic fractures in elderly people in Finland: Sharp increase in 1970-1997 and alarming projections for the new millennium. *Osteoporos Int* 2000;11:443-448.
10. Tosounidis G, Holstein JH, Culemann U, Holmen-schlager F, Stuby F, Pohlemann T. Changes in epidemiology and treatment of pelvic ring fractures in Germany: An analysis on data of German Pelvic Multicenter Study Groups I and III (DGU/AO). *Acta Chir Orthop Traumatol Čech* 2010;77:450-456.
11. Rommens PM, Wagner D, Hofmann A. Surgical management of osteoporotic pelvic fractures: a new challenge. *Eur J Trauma Emerg Surg* 2012;38:499-509.
12. Wagner D, Ossendorf C, Gruszka D, Hofmann A, Rommens PM. Fragility fractures of the sacrum: how to identify and when to treat surgically?. *Eur J Trauma Emerg Surg* 2015;41:349-362.
13. Morris RO, Sonibare A, Green DJ, Masud T. Closed pelvic fractures: characteristics and outcomes in older patients admitted to medical and geriatric wards. *Postgrad Med J* 2000;76:646-650.
14. Tile M: *Fractures of the Pelvis and Acetabulum*. Ed 2. Williams & Wilkins, Baltimore 1995.
15. Denis F, Davis S, Comfort T. Sacral fractures: An important problem. Retrospective analysis of 236 cases. *Clin Orthop Relat Res* 1988;227:67-81.
16. Roy-Camille R, Saillant G, Gagna G, Mazel C. Transverse fracture of the upper sacrum: Suicidal jumper's fracture. *Spine* 1985;10:838-845.
17. Lindahl J, Mäkinen TJ, Koskinen SK, Söderlund T. Factors associated with outcome of spinopelvic dissociation treated with lumbopelvic fixation. *Injury* 2014;45:1914-1920.
18. Nork SN, Jones CB, Harding SP, Mirza SK, Routt Jr MLC. Percutaneous stabilization of U-shaped sacral fractures using iliosacral screws: Technique and early results. *J Orthop Trauma* 2001;15:238-246.
19. Hunt N, Jennings A, Smith M. Current management of U-shaped sacral fractures or spino-pelvic dissociation. *Injury* 2002;33:123-126.
20. Robles LA. Transverse sacral fractures. *Spine J* 2009;9:60-69.
21. Gripnau AJG, Boele van Hensbroek PB, Haverlag R, Ponsen KJ, Been HD, Goslings JC. U-shaped sacral fractures: Surgical treatment and quality of life. *Injury* 2009;40:1040-1048.
22. Yi C, Hak DJ. Traumatic spinopelvic dissociation or U-shaped sacral fracture: A review of the literature. *Injury* 2012;43:402-408.
23. Rommens PM, Hofmann A. Comprehensive classification of fragility fractures of the pelvic ring: recommendations for surgical treatment. *Injury*. 2013;44:1733-44.
24. Olson SA, Pollak AN. Assessment of pelvic ring stability after injury. Indications for surgical stabilization. *Clin Orthop Relat Res* 1996;329:15-27.
25. Lyders EM, Whitlow CT, Baker MD, Morris PP. Imaging and treatment of sacral insufficiency fractures. *AJNR*. 2010;31:201-10.
26. Lindahl J, Hirvensalo E, Böstman O, Santavirta S. Failure of reduction with an external fixator in the treatment of injuries of the pelvic ring: Long term evaluation of 110 patients. *J Bone Joint Surg (Br)* 1999;81-B:955-62.
27. Schildhauer TA, Bellabarba C, Nork SE, Barei DP, Routt Jr MLC, Chapman JR. Decompression and lumbopelvic fixation for sacral fracture-dislocations with spino-pelvic dissociation. *J Orthop Trauma* 2006;20:447-457.
28. Kellam JF: The role of external fixation in pelvic disruptions. *Clin Orthop Relat Res* 1989;241:66-82.
29. Leighton RK, Waddell JP, Bray TJ, Chapman MW, Simpson L, Martom RB, Sharkey NA. Biomechanical testing of new and old fixation devices for vertical shear fractures of the pelvis. *J Orthop Trauma* 1991;5:313-7.
30. Lindahl J, Hirvensalo E. Outcome of operatively treated type-C injuries of the pelvic ring. *Acta Orthop* 2005;76:667-78.
31. Papakostidis C, Kanakaris NK, Kontakis G, Giannoudis PV. Pelvic ring disruptions: treatment modalities and analysis of outcomes. *Int Orthop* 2009;33:329-338.
32. Gorczyca JT, Varga E, Woodsite T, et al. The strength of iliosacral lag screws and transiliac bars in the fixation of vertically unstable pelvic injuries with sacral fractures. *Injury* 1996;27:561-564.

33. Zwiener CM, van den Bosch EW, Hoek van Dijke GA, et al. Cyclic loading of sacroiliac screws in Tile C pelvic fractures. *J Trauma* 2005;58:1029-34.
34. Zwingmann J, Konrad G, Kotter E, Südkamp NP, Oberst M. Computer-navigated iliosacral screw insertion reduces malposition rate and radiation exposure. *Clin Orthop Relat Res* 2009; 467:1833–1838.
35. Krappinger D, Larndorfer R, Struve P, Rosenberger R, Arora R, Blauth M. Minimally invasive transiliac plate osteosynthesis for type C injuries of the pelvic ring: A clinical and radiological follow-up. *J Orthop Trauma* 2007;21:595-602.
36. Hao T, Changwei Y, Zhang Q. Treatment of posterior pelvic ring injuries with minimally invasive percutaneous plate osteosynthesis. *Int Orthop* 2009;33:1435-1439.
37. Dienstknecht T, Berner A, Lenich A, Nerlich M, Fuechtmeier B. A minimally invasive stabilizing system for dorsal pelvic ring injuries. *Clin Orthop Relat Res* 2011;469:3209-3217.
38. Suzuki T, Hak D, Ziran B, Adams S, Stahel P, Morgan S, Smith W. Outcome and complications of posterior transiliac plating for vertically unstable sacral fractures. *Injury* 2009;40:405-409.
39. Pohlemann T, Bosch U, Gänsslen A, Tschorne H: The Hannover experience in management of pelvic fractures. *Clin Orthop Relat Res* 1994; 305: 69-80.25.
40. Gänsslen A, Pape HC, Lehmann U, Lange U, Krettek C, Pohlemann T. Die operative therapie von instabilen sacrum frakturen. *Zentralbl Chir* 2003;128:40-45.
41. Lindahl J, Hirvensalo E. Transpedikulaarinen fiksaatio-olaitte pirstaleisten sakrummurtumien hoidossa. *Finnish Journal of Orthopaedics and Traumatology* 1998;21(3):219-224.
42. Allen BL, Ferguson RL. The Galveston technique for L rod instrumentation of the scoliotic spine. *Spine* 1982;7:276-284.
43. Sanders D, Fox J, Starr A, Sathy A, Chao J. Trans-sacral-transiliac screw stabilization: Effective for recalcitrant pain due to sacral insufficiency fracture. *J Orthop Trauma* 2016;30:469-473.
44. Pohlemann T, Gänsslen A, Schellwald O, Culemann U, Tschorne H: Outcome after pelvic ring injuries. *Injury* 1996;27(Suppl 2):S-B31-38.