

Contents lists available at [ScienceDirect](http://www.sciencedirect.com)

Respiratory Medicine Case Reports

journal homepage: <http://www.elsevier.com/locate/rmcr>

A case of axillary lymphadenitis caused by *Mycobacterium intracellulare* in an immunocompetent patient

Junko Itano^a, Kadoaki Ohashi^{b,*}, Satoru Senoo^a, Naohiro Oda^a, Kazuya Nishii^a, Akihiko Taniguchi^a, Nobuaki Miyahara^c, Yoshinobu Maeda^a, Katsuyuki Kiura^b

^a Department of Hematology, Oncology and Respiratory Medicine, Okayama University Graduate School of Medicine, Dentistry and Pharmaceutical Sciences, Okayama, Japan

^b Department of Respiratory Medicine, Okayama University Hospital, Okayama, Japan

^c Department of Medical Technology, Okayama University Graduate School of Health Sciences, Okayama, Japan

ARTICLE INFO

Keywords:

Axillary lymphadenitis

Mycobacterium avium complex infection*Mycobacterium intracellulare*

ABSTRACT

Axillary lymphadenitis caused by non-tuberculous mycobacteria is rare and has been reported in immunocompromised hosts. Herein, we report the case of a 67-year-old man without immunodeficiency who developed right axillary lymphadenitis caused by *Mycobacterium intracellulare* and showed a small nodular shadow in the left pulmonary apex. Biopsy of the right axillary lymph node revealed several epithelioid granulomas, and the culture of the lymph node aspirate yielded *Mycobacterium intracellulare*. The lymph node lesion and left lung apex shadow resolved spontaneously after careful outpatient monitoring. This case suggests that axillary lymphadenitis could be caused by *Mycobacterium intracellulare* in an immunocompetent patient.

1. Introduction

Nontuberculous mycobacteria (NTM) is a granulomatous infection caused by acid-fast bacilli other than the tubercle bacillus and *Mycobacterium leprae* [1,2]. These include *Mycobacterium avium* complex (MAC), which is mainly composed of two types: *M. avium* and *M. intracellulare*. A number of reports indicate that these bacterial strains have different pathogenicities [3]. NTM widely inhabits natural water and soil; therefore, in humans the route of infection is varied, and includes inhalation of aerosols and oral/intestinal tract transmission. In addition to the lungs, these infections can also be observed in the lymph nodes, skin, soft tissue, bone, and wound surfaces [4,5]. Among these pathologies, lymphadenitis caused by NTM generally occurs in the head and neck and is often reported in human immunodeficiency virus (HIV)-positive children and adults [6,7]. The most common site of lymphadenitis caused by NTM in healthy children is the neck, and it rarely develops in the axillary lymph nodes. Within the scope of our literature search we found no reports of axillary lymphadenitis caused by *M. intracellulare* in non-immunocompromised, HIV-negative adults. Herein we report a unique case of axillary lymphadenitis secondary to *M. intracellulare* in an immunocompetent adult patient who exhibited spontaneous remission.

2. Case report

A 67-year-old man was referred to our department after his local doctor detected a 15-mm nodular shadow in the upper lobe of his right lung. The nodule had remained unchanged for 10 months (Fig. 1A and B). The patient's temperature was 36.5 °C, his heart rate was 78 beats per minute, and percutaneous arterial oxygen saturation was 98% in room air. Symptoms such as cough, sputum, shortness of breath, and weight loss were not observed. His medical history included hypertension, chronic obstructive pulmonary disease, dyslipidemia, and internal carotid artery stenosis, and he had a history of smoking 20 cigarettes a day for 43 years. His family history was unremarkable. He had no history of pet ownership, overseas travel, or excessive exposure to dust. Laboratory results on admission included a white cell count of 6610/mm³ (reference range 3300–8600/mm³) with white blood cell differentiation ratios of 72.5% neutrophils (reference range 35%–73.0%), 18.3% lymphocytes (reference range 20.0%–52%), 4.2% eosinophils (reference range 0.0%–11.0%), 0.4% basophils (reference range 0.0%–2.0%), 4.6% monocytes (reference range 0.0%–13.0%), and hemoglobin 14.3 g/dL (reference range 13.5–17.0 g/dL), platelet count 192,000/mm³ (reference range 150,000–350,000/mm³), C-reactive protein 0.03 mg/dL (reference range 0.0–0.3 mg/dL), carcinoembryonic antigen 4.26

* Corresponding author. Department of Respiratory Medicine, Okayama University Hospital, 2-5-1, Shikata-cho, Okayama, 700-8558, Japan.

E-mail address: kohashi@cc.okayama-u.ac.jp (K. Ohashi).

<https://doi.org/10.1016/j.rmcr.2019.100947>

Received 18 July 2019; Received in revised form 12 October 2019; Accepted 12 October 2019

Available online 14 October 2019

2213-0071/© 2019 The Authors.

Published by Elsevier Ltd.

This is an open access article under the CC BY-NC-ND license

(<http://creativecommons.org/licenses/by-nc-nd/4.0/>).

ng/mL (reference range 0.0–5.00 ng/mL), and cytokeratin-19 fragments 3.3 ng/mL (reference range 0.0–2.8 ng/mL). An interferon-gamma (IFN γ)-releasing assay (IGRA) (QuantiFERON-TB Gold^R) was positive at 0.49 IU/mL. Tests for cryptococcus antigen and HIV antibodies were negative. Chest computed tomography (CT) revealed a 15-mm nodular shadow with slightly irregular margins in the upper lobe of the right lung (Fig. 1). Only normal bacterial flora were detected via sputum culture, and *Mycobacterium* smear, tuberculosis (Tb)-polymerase chain reaction (PCR), and MAC-PCR were negative, as was acid-fast bacilli culture. Ultrasound-guided bronchoscopy confirmed the locations of the lesions, then transbronchial biopsy, bronchial brushing, and bronchial lavage were performed. Histological investigations did not reveal any indications of malignancy or granuloma, and the cytological results of bronchial washing and brushing were negative for malignancy. Bronchial lavage culture only yielded normal bacterial flora, and a *Mycobacterium* smear was negative in the culture test as were Tb-PCR, MAC-PCR, and acid-fast bacilli culture tests. Based on these results no definitive diagnosis was reached with regard to the nodular shadow in the upper lobe of the right lung, and therefore the patient was instructed to comply with careful monitoring on an outpatient basis.

The patient was monitored as an outpatient for 18 months, during which time no changes in the size or characteristics of the nodular shadow in the right upper lobe of the lung were observed (Fig. 2A). A small 5-mm node appeared as a new lesion in the left lung apex, however, and it gradually increased to 10 mm over the course of 10 months (Fig. 2B). Enlargement of the right axillary lymph node was also observed. No enhancement effect was detected via contrast CT (Fig. 2C). Accumulation was detected in the left lung apex and right axillary lymph node via positron emission tomography-CT (Fig. 2D), but no accumulation was depicted in the right lung nodule. The patient had no fever, cough, or sputum which could suggest disseminated MAC, and the right axillary lymph node was not painful, therefore blood culture tests for acid-fast bacteria were not performed. QuantiFERON-TB Gold^R was slightly elevated at 0.93 IU/mL, and anti-MAC antibodies were positive at 1.51 U/mL (reference range 0.0–0.69 U/mL). Angiotensin-converting enzyme level was 1.9 U/L (reference range 8.3–21.4 U/L) and soluble interleukin-2 receptor level was 478 U/mL (reference range 122–496 U/mL). Combined with the fact that no bilateral hilar lymphadenopathy or skin, ocular, or cardiovascular complications were observed, it was surmised that sarcoidosis was unlikely to be the cause of the lung nodule and enlargement of the right axillary lymph nodes.

The new lesion, which was depicted as a small nodular shadow in the left lung apex, was in contact with the proximal subclavian artery, and performing a surgical lung biopsy to achieve a definitive diagnosis would have been difficult. Hence, a biopsy was obtained from the right axillary lymph node under local anesthesia for diagnostic purposes. Large numbers of epithelioid granulomas and multinucleated giant cells were detected in the biopsy tissue (Fig. 3). *M. intracellulare* was identified via mycobacterium culture of the biopsy needle aspirate fluid from

the right axillary lymph node, therefore lymphadenitis caused by *M. intracellulare* was diagnosed. Multidrug antimicrobial therapy including clarithromycin was considered, but at the patient's request, his condition was monitored on an outpatient basis instead. Interestingly the nodule in the left upper lobe gradually shrunk over the course of one year, as did the right axillary lymph nodes (Fig. 4A and B). The nodule had almost disappeared after 18 months (Fig. 4C). Anti-MAC antibody was not increased after the left lung apex lesion had disappeared compared to the level recorded when right lymphangitis had appeared (1.45 U/mL vs. 1.51 U/mL; range 0.0–0.69 U/mL). No relapse was observed throughout the 18 months following the biopsy. During the subsequent follow-up period the lesion in the right upper lobe did not exhibit any changes in size or other characteristics (Fig. 1).

3. Discussion

Axillary lymphadenitis caused by *M. avium* complex is rare, and has been reported in immunocompromised hosts [8,9]. To the best of our knowledge, the present report is the first describing axillary lymphadenitis caused by *M. intracellulare* in an immunocompetent host. Because the present patient was asymptomatic, he received no treatment and was instead carefully monitored on an outpatient basis. The right axillary lymph node lesion and left apical lung shadow resolved spontaneously. This clinical course suggests that the left apical lung shadow was caused by *M. intracellulare*, which induced the right axillary lymphadenitis. Neither the size nor the characteristics of the nodule in the upper lobe of the right lung changed over the course of a series of clinical observations, and no acid-fast bacteria (including *M. intracellulare* and *M. tuberculosis*) were detected at the site; thus it was considered to be an old lesion, although it may have been the focus of the *Mycobacterium* infection.

There are multiple reports of patients with NTM presenting with extrapulmonary lesions [5,10,11]. Most of those patients were either children with lymphadenitis caused by NTM or immunocompromised adults with underlying diseases, many of whom were infected with HIV [12]. The condition commonly occurs in the neck, and it has been suggested that the reason for this is that NTM—which adheres to the inside of the oral cavity or pharynx—enters via the tonsillar lymph nodes and induces the development of lymphadenitis of the neck or both the head and the neck. Reports describing cases of axillary lymphadenitis caused by NTM are limited, and the cause may be related to trauma, especially tenosynovitis [13], or HIV infection [8]. There is also one report of an 8-month-old infant with axillary lymphadenitis caused by MAC [9], but notably, that infant was HIV-positive. The detailed mechanisms involved in the pathogenesis of lymphadenitis caused by NTM in non-immunocompromised patients are unknown.

Anti-IFN γ autoantibody can reportedly induce a form of adult-onset immunodeficiency that causes disseminated MAC and can spread to the lungs as well as many other organs, such as lymph nodes or bone [14].

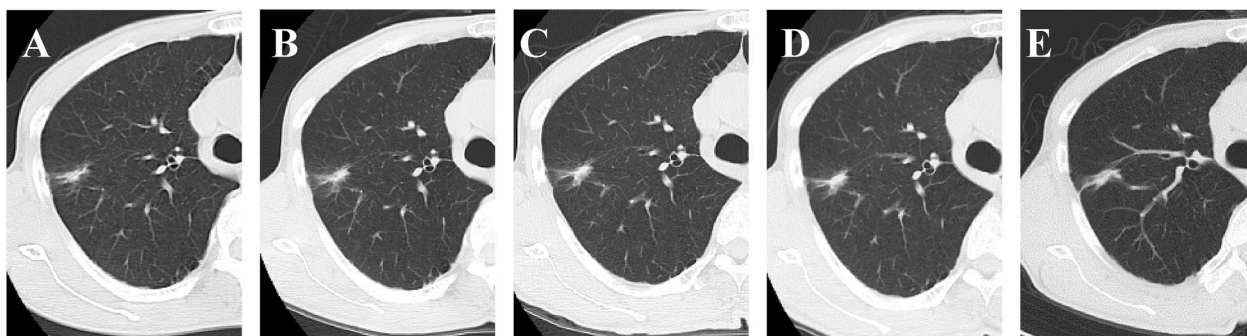


Fig. 1. Chest computed tomography of the nodule in the upper lobe of the right lung. No change was observed during the course of observation. A. The nodule when it was first detected. B. Ten months after the time from 1A. C. Eighteen months after the time from 1B (the same period represented in Fig. 4A). D. Twelve months after the time represented in Fig. 1C (the same period represented in Fig. 4B). E. Eighteen months after the time from Fig. 1C (the same period represented in Fig. 4C).

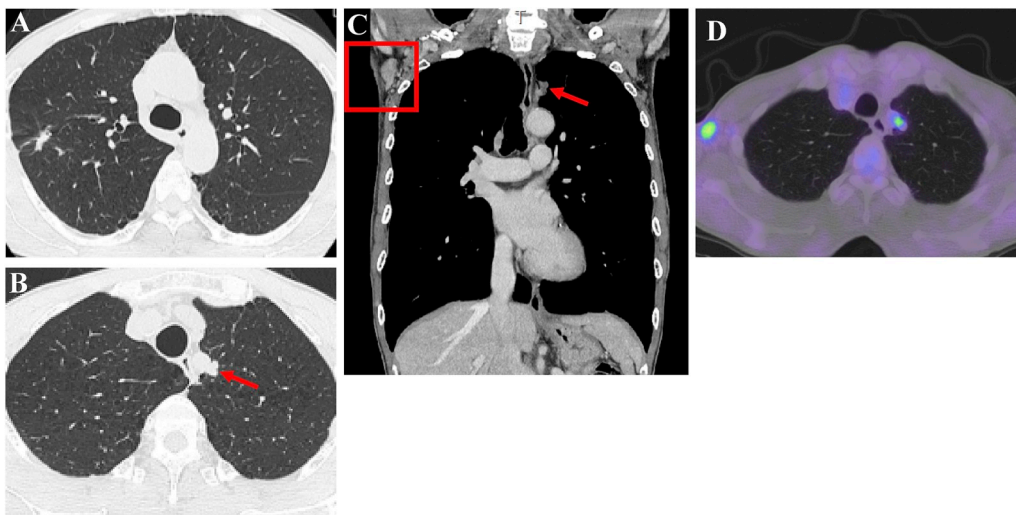


Fig. 2. A. Chest computed tomography (CT) revealed a 15-mm irregularly shaped nodule in the upper lobe of the right lung. The nodule shadow was unchanged after 10 months of observation. B. Chest CT revealed a small new 5-mm nodular lesion in the left lung apex, which gradually increased in size over the course of 10 months (red arrow). C. Enlargement of the right axillary lymph nodes, with no enhancement effect (red square). D. Positron emission tomography-CT depicting 18F-fluorodeoxyglucose uptake in the left lung apex and right axillary lymph nodes. (For interpretation of the references to colour in this figure legend, the reader is referred to the Web version of this article.)

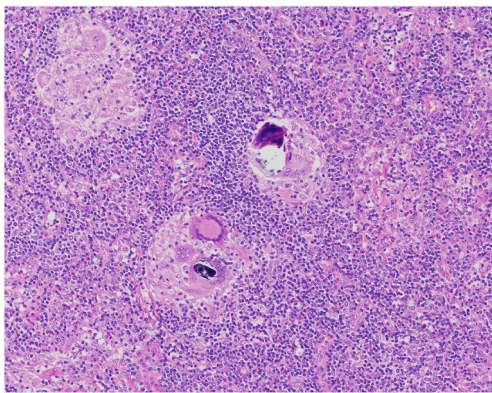


Fig. 3. The right axillary lymph nodes where biopsied. Hematoxylin and eosin staining depicted a large number of epithelioid granulomas and multinucleated giant cells in the tissue.

Notably, however, anti-IFN γ autoantibody was not assessed in the present patient because IGRA was measurable. Given that IGRA is unmeasurable in patients with anti-IFN γ neutralized-antibody [15], we believe that the present patient was negative for the autoantibody.

The American Thoracic Society/Infectious Disease Society of America guidelines [4] recommend surgical resection in cases of lymphadenitis caused by NTM. Multidrug antimicrobial therapy including clarithromycin is recommended in difficult resections and cases resistant to surgical resection. Some studies indicate that surgical treatment may be preferable [16,17], and it has been suggested that surgery is warranted in children before the formation of skin fistulae [17]. Conversely, in one study it was concluded that surgical resection is not always necessary [18], and in a prospective study with a small number of subjects comparing an antibiotic treatment group with an observation group there was no significant difference in lymph node shrinkage [19]. There has been much conjecture about treatments for lymphadenitis caused by NTM [4,16–19], but the optimal treatment methods remain controversial.

In conclusion, above we have described a case of right axillary

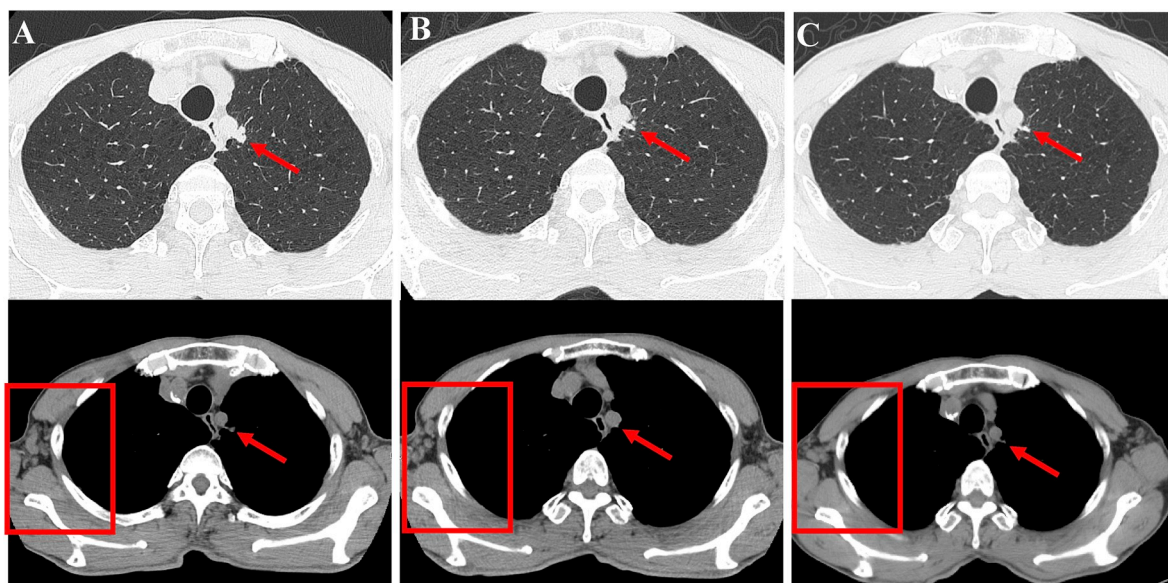


Fig. 4. A. Nodules in the left upper lobe (red arrow) and right axillary lymph node (red square) before lymph node biopsy. B. Lesions 1 year after biopsy. C. Chest nodule and axillary lymph nodes after 18 months. (For interpretation of the references to colour in this figure legend, the reader is referred to the Web version of this article.)

lymphadenitis secondary to *M. intracellulare* in an immunocompetent adult. No previous reports of axillary lymphadenitis caused by *M. intracellulare* in a non-immunocompromised patient were identified within the scope of our literature search. Further studies investigating detailed mechanisms of pathogenesis, early diagnosis, and treatment methods are warranted.

Declaration of Competing Interest

The authors declare that they have no conflicts of interest.

Acknowledgments

Foremost, we thank the patient and his family. We are also grateful to Hiromi Nakashima and Kyoko Maeda for their technical support, and Editage (www.editage.jp) for English language editing. The authors state that they have no conflicts of interest.

References

- [1] M.J. Donohue, Increasing nontuberculous mycobacteria reporting rates and species diversity identified in clinical laboratory reports, *BMC Infect. Dis.* 18 (2018) 163.
- [2] H. Namkoong, A. Kurashima, K. Morimoto, Y. Hoshino, N. Hasegawa, M. Atoet, et al., Epidemiology of pulmonary nontuberculous mycobacterial disease, Japan. *Emerg. Infect. Dis.* 22 (2016) 1116–1117.
- [3] J. van Ingen, S.A. Bendien, W.C. de Lange, W. Hoefsloot, P.N. Dekhuijzen, M. J. Boeree, et al., Clinical relevance of non-tuberculous mycobacteria isolated in the Nijmegen-Arnhem region, The Netherlands, *Thorax* 64 (2009) 502–506.
- [4] D.E. Griffith, T. Aksamit, B.A. Brown-Elliott, A. Catanzaro, C. Daley, F. Gordin, et al., An official ATS/IDSA statement: diagnosis, treatment, and prevention of nontuberculous mycobacterial diseases, *Am. J. Respir. Crit. Care Med.* 175 (2007) 367–416.
- [5] E. Henkle, K. Hedberg, S.D. Schafer, K.L. Winthrop, Surveillance of extrapulmonary nontuberculous mycobacteria infections, Oregon, USA, 2007–2012, *Emerg. Infect. Dis.* 2 (2017) 1627–1630.
- [6] J. Amir, Non-tuberculous mycobacterial lymphadenitis in children: diagnosis and management, *Isr. Med. Assoc. J.* 12 (2010) 49–52.
- [7] E. Wolinsky, Mycobacterial lymphadenitis in children: a prospective study of 105 nontuberculous cases with long-term follow-up, *Clin. Infect. Dis.* 20 (1995) 954–963.
- [8] J.J. Cortez-Escalante, A.M. Dos Santos, C. Garnica Gde, A.L. Sarmiento, C.N. Castro, G.A. Romero, et al., Mediastinitis and pericardial effusion in a patient with AIDS and disseminated *Mycobacterium avium* infection: a case report, *Rev. Soc. Bras. Med. Trop.* 45 (2012) 407–409.
- [9] S. Mahapatra, A. Mahapatra, S. Tripathy, G. Rath, A.K. Dash, A. Mahapatra, *Mycobacterium avium intracellulare* complex associated extrapulmonary axillary lymphadenitis in a HIV-seropositive infant—a rare case report, *Indian J. Med. Microbiol.* 23 (2005) 192–194.
- [10] T. Adzic-Vukicevic, A. Barac, A. Blanka-Protic, M. Laban-Lazovic, B. Lukovic, V. Skodric-Trifunovic, et al., Clinical features of infection caused by nontuberculous mycobacteria: 7 years' experience, *Infection* 46 (2018) 357–363.
- [11] J. Umrao, D. Singh, A. Zia, S. Saxena, S. Sarsaiya, S. Singh, et al., Prevalence and species spectrum of both pulmonary and extrapulmonary nontuberculous mycobacteria isolates at a tertiary care center, *Int. J. Mycobacteriol.* 5 (2016) 288–293.
- [12] P. Blanc, H. Dutronc, O. Peuchant, F.A. Dauchy, C. Cazanave, D. Neau, et al., Nontuberculous mycobacterial infections in a French hospital: a 12-year retrospective study, *PLoS One* 11 (2016) e0168290.
- [13] D. Anim-Appiah, B. Bono, E. Fleegler, N. Roach, R. Samuel, A.R. Myers, et al., *Mycobacterium avium* complex tenosynovitis of the wrist and hand, *Arthritis Rheum.* 51 (2004) 140–142.
- [14] S.K. Browne, P.D. Burbelo, P. Chetchotisakd, Y. Suputtamongkol, S. Kiertiburanakul, P.A. Shaw, et al., Adult-onset immunodeficiency in Thailand and Taiwan, *N. Engl. J. Med.* 367 (2012) 725–734.
- [15] U.I. Wu, Y.C. Chuang, W.H. Sheng, H.Y. Sun, Y.T. Jhong, J.Y. Wang, et al., Use of QuantiFERON-TB Gold In-tube assay in screening for neutralizing anti-interferon- γ autoantibodies in patients with disseminated nontuberculous mycobacterial infection, *Clin. Microbiol. Infect.* 24 (2018) 159–165.
- [16] J.A. Lindeboom, E.J. Kuijper, E.S. Bruijnesteijn van Coppenraet, R. Lindeboom, J. M. Prins, Surgical excision versus antibiotic treatment for nontuberculous mycobacterial cervicofacial lymphadenitis in children: a multicenter, randomized, controlled trial, *Clin. Infect. Dis.* 44 (2007) 1057–1064.
- [17] P. Rives, M. Joubert, E. Launay, A. Guillouzoic, F. Espitalier, O. Malarid, Cervicofacial non-tuberculous mycobacteria: a report of 30 cases, *Eur. Ann. Otorhinolaryngol. Head Neck Dis.* 133 (2016) 107–111.
- [18] R.L. Harris, P. Modayil, J. Adam, M. Sharland, P. Heath, T. Planche, et al., Cervicofacial nontuberculous mycobacterium lymphadenitis in children: is surgery always necessary? *Int. J. Pediatr. Otorhinolaryngol.* 73 (2009) 1297–1301.
- [19] J.A. Lindeboom, Conservative wait-and-see therapy versus antibiotic treatment for nontuberculous mycobacterial cervicofacial lymphadenitis in children, *Clin. Infect. Dis.* 52 (2011) 180–184.